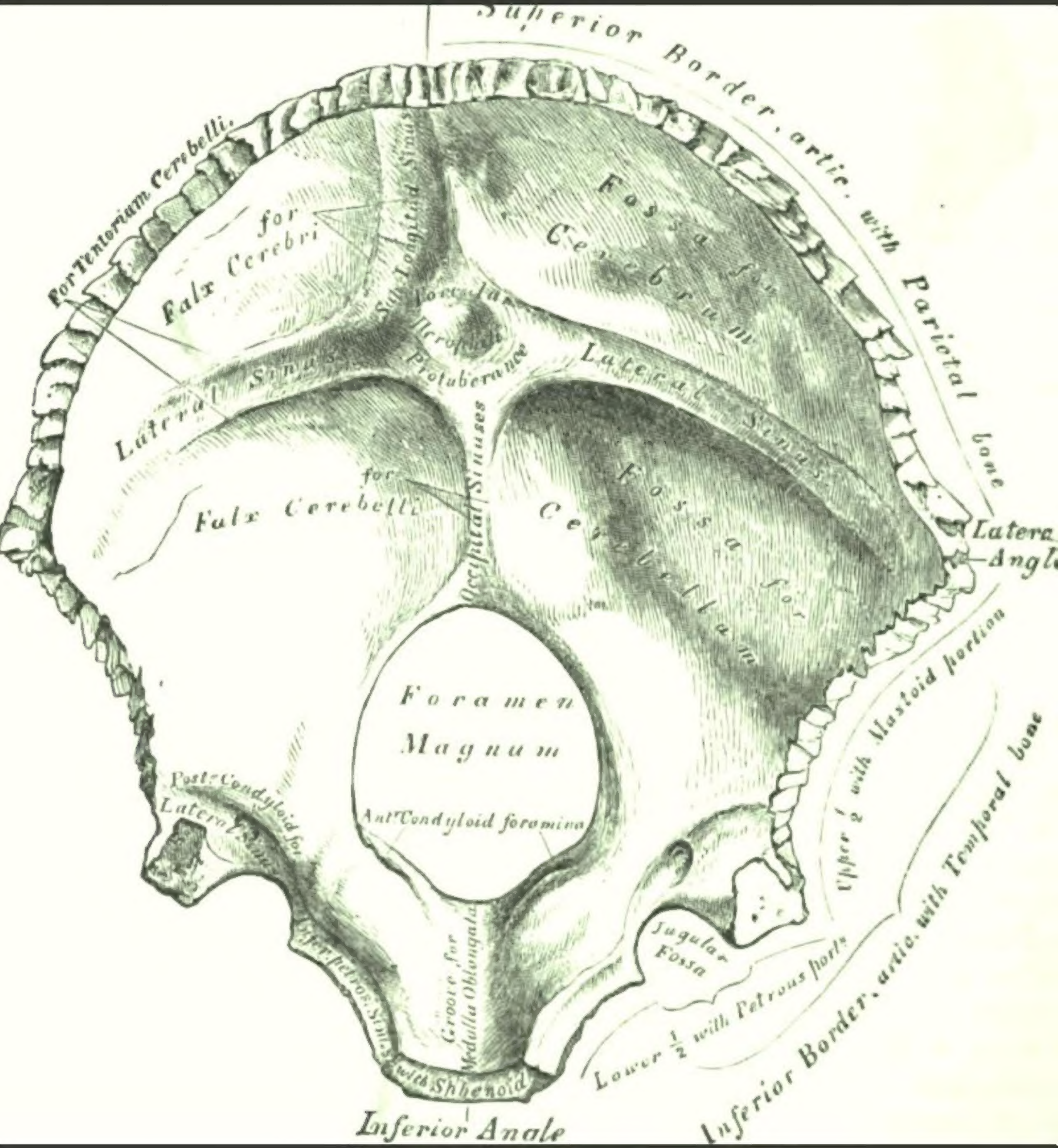
Superior Border. artic. with Parietal bone
Lateral Angle
For Tentorium Cerebelli.
for Falx Cerebri
Sulc. Longitud. Sinus
Fossa for Cerebrum
Torcular Herophili
Protuberance
Lateral Sinus
Lateral Sinus
for Falx Cerebelli
Occipital Sinuses
Fossa for Cerebellum
Foramen Magnum
Post. Condyloid for.
Lateral Sinus
Ant. Condyloid foramina
Upper ½ with Mastoid portion
Inferior Border. artic. with Temporal bone
Jugular Fossa
Lower ½ with Petrous port.
Infer. petros. Sinus
Groove for Medulla Oblongata
with Sphenoid
Inferior Angle

Anatomy, descriptive and surgical

Henry Gray

AUG 1 8 1977

Lane Medical Library
Stanford University Medical Center

Gift

LANE MEDICAL LIBRARY
STANFORD UNIVERSITY
MEDICAL CENTER
STANFORD, CALIF. 94305

Fowler.

Department

ty of Penns

LANE MEDICAL LIBRARY
STANFORD UNIVERSITY
MEDICAL CENTER
STANFORD, CALIF. 94305

Geo. W. Fowler.
Medical Department of
~~State~~ University of Pennsylvania

Res:
No 210 South 36th St.
Philadelphia
Pa.

ANATOMY,

DESCRIPTIVE AND SURGICAL.

BY

HENRY GRAY, F.R.S.,

FELLOW OF THE ROYAL COLLEGE OF SURGEONS; LECTURER ON ANATOMY AT ST. GEORGE'S HOSPITAL MEDICAL SCHOOL.

THE DRAWINGS BY H. V. CARTER, M.D.,

LATE DEMONSTRATOR OF ANATOMY AT ST. GEORGE'S HOSPITAL.

WITH ADDITIONAL DRAWINGS IN LATER EDITIONS.

EDITED BY

T. PICKERING PICK,

SURGEON TO AND LECTURER ON SURGERY AT, ST. GEORGE'S HOSPITAL; SENIOR SURGEON, VICTORIA HOSPITAL FOR CHILDREN; MEMBER OF THE COURT OF EXAMINERS, ROYAL COLLEGE OF SURGEONS OF ENGLAND.

A NEW AMERICAN FROM THE ELEVENTH ENGLISH EDITION.

THOROUGHLY REVISED AND RE-EDITED WITH ADDITIONS

BY WILLIAM W. KEEN, M.D.,

PROFESSOR OF SURGERY IN THE WOMAN'S MEDICAL COLLEGE OF PENNSYLVANIA; PROFESSOR OF ARTISTIC ANATOMY IN THE PENNSYLVANIA ACADEMY OF THE FINE ARTS; FORMERLY LECTURER ON ANATOMY IN THE PHILADELPHIA SCHOOL OF ANATOMY; SURGEON TO ST. MARY'S HOSPITAL; FELLOW OF THE COLLEGE OF PHYSICIANS OF PHILADELPHIA, ETC.

TO WHICH IS ADDED

LANDMARKS, MEDICAL AND SURGICAL.

BY LUTHER HOLDEN, F.R.C.S.

WITH ADDITIONS BY WILLIAM W. KEEN, M.D.

PHILADELPHIA:
LEA BROTHERS & CO.
1887.

LANE LIBRARY. STANFORD UNIVERSITY

Entered, according to the Act of Congress, in the year 1887 by
LEA BROTHERS & CO.,
In the Office of the Librarian of Congress. All rights reserved.

WESTCOTT & THOMSON,
Stereotypers and Electrotypers, Philada.

WILLIAM J. DORNAN,
Printer, Philada.

TO

SIR BENJAMIN COLLINS BRODIE, BART.,

F.R.S., D.C.L.,

SERJEANT-SURGEON TO THE QUEEN,

CORRESPONDING MEMBER OF THE INSTITUTE OF FRANCE,

This Work is Dedicated

IN ADMIRATION OF

HIS GREAT TALENTS

AND IN REMEMBRANCE OF

MANY ACTS OF KINDNESS SHOWN TO THE AUTHOR

FROM AN

EARLY PERIOD OF HIS PROFESSIONAL CAREER

PREFACE TO THE NEW AMERICAN EDITION.

At the request of the American Publishers I have subjected the new English edition of Gray's *Anatomy* to a careful revision, and have superintended its passage through the press. At first sight it would seem almost a work of supererogation to attempt even a criticism of a book which has carried on its title-page the names of some of the most distinguished English anatomists; yet I trust that my labors will prove not unfruitful.

In addition to the correction of minor and obvious typographical errors in the English sheets, and many similar corrections in the cuts, the whole of Gray's masterpiece has received a more methodical arrangement, and many cross-references both to text and cuts have been inserted for the convenience of the student. The text has been unaltered, except in two portions. At my request, Prof. John A. Ryder of the University of Pennsylvania revised the section on Development. A good many small but important changes he found necessary in the text, and in some instances paragraphs were rewritten as footnotes. His own personal views on many of the details of Embryology will be more accurately and more fully expressed in a work on that subject which he is now preparing.

In the section on the Brain I rejected the English cuts showing the sulci and convolutions, and substituted the more accurate and generally-adopted plates of Ecker. The text was correspondingly inaccurate, and could not be adapted to the new illustrations without a few changes, which it is hoped will facilitate the study of this difficult part of anatomy. I have also carefully described the Cerebral Circulation, and have added a section on Cerebral Localization and Topography—subjects of great and increasing importance, especially in view of the recent rapid strides in Cerebral Surgery. The chief anatomical text-book in the English language ought not, I think, to be behind in this department, but should lend its aid to further progress by giving the fullest and most accurate knowledge attainable. Among the other additions to the text may be noted also paragraphs on the action of the muscles of the foot-sole; a more accurate description of the Pectoralis major, Supinator longus, and Thenar muscles; and a careful description of the palmar fascia.

In all, one hundred and thirteen new engravings have been added, of which many are original. These, with their descriptive matter, and likewise all my other additions, have been distinguished by brackets. Among these new illustrations are many of the most obvious utility, such as a series of sections through important joints; a series of frozen sections through the trunk, the extremities, and the female pelvis; cuts illustrating the histology of various tissues; the shoulder and pelvic girdles; the interior of the nose and the larynx; the development and occlusion of the teeth and the absorption of the alveolar processes; the structure of the muscles; the ligamentum nuchæ; the Occipito-frontal and Interosseous muscles; the palmar fascia; a series giving the points for the application of electricity to the muscles; a series on the circulation of the brain and spinal cord; another series to illustrate cerebral localization and topography; another on the cutaneous distribution of the nerves; a number of cuts to elucidate the anatomy of the cerebrum; two showing the sympathetic nerve; and others illustrating the peritoneum, the muscularis mucosæ, the female perineum, and the genito-urinary organs of both sexes. Wherever practicable, colors have been introduced to distinguish the veins, arteries, and nerves, so that in the colored edition the American additions shall be in harmony with this novel feature of the latest English original. There is scarcely a section of the work, therefore, which has not been extensively enriched in the matter of illustrations.

The text has been prefaced with a paper "On the Systematic Use of the Living Model in Teaching Anatomy," and in the section on the Muscles those postures, resisted motions, and athletic exercises have been noted which I have found in teaching to be best adapted for showing the form and action of individual muscles. The additional interest thus infused into the subject will lead the student to use his own person as an ever-present living model—a habit possessing the greatest possible usefulness. My experience in lecturing before the Pennsylvania Academy of the Fine Arts has convinced me also of the great advantages to be derived by teachers as well as students from a thorough study of the masterpieces of sculpture, which are generally available at least in large cities. Among the most valuable for this purpose may be mentioned the Fighting Gladiator, the Dying Gladiator, the Wrestlers, the Ilyssus, the Theseus, the Laocoön, Angelo's Night and Morning, Milo of Crotona, the Venus de Milo, the Torso, the Farnese Hercules, the Antinoüs, and others. Additional instruction may be obtained by the use of the electric current, which furnishes a convenient means of demonstrating the action of individual muscles or of groups of muscles. Plates have been inserted to facilitate the use of this method of investigation.

I have again revised Holden's well-known *Landmarks*, and made still further additions, all of which are indicated by brackets.

WILLIAM W. KEEN.

1729 CHESTNUT STREET, PHILADELPHIA,
October 1, 1887.

PREFACE TO THE ELEVENTH EDITION.

IN this edition considerable alterations have been made. The Introduction of former editions has been incorporated in the body of the work, for the most part in the form of two sections—one on General Anatomy, the other on Development. These have been entirely rewritten, in order to keep pace with the ever-increasing activity of research in these branches of the science of Anatomy. Some portions of the Introduction have, however, been removed from their former position and introduced in their appropriate places in other parts of the work; as, for instance, the minute structure of the spinal cord, which has been inserted, with the general description of this part, in the section devoted to the Nervous System.

The whole of the work has undergone a careful revision; many clerical errors and errors in point of detail have been corrected. In the section on Osteology an endeavor has been made to give more accurately the time for the appearance of the several centres of ossification of the bones, though this is a point on which anatomists differ, and which probably varies in different cases. In the section on Arthrology the movement or movements permitted in each joint have been carefully revised, and the muscles by which these movements are effected have been given. In the section on Myology the action of each muscle or group of muscles has been carefully considered, and many alterations and corrections made. The anomalous muscles mentioned in former editions have been excluded. It was thought that, interesting as these anomalous conditions may be to the scientific anatomist, they were scarcely necessary, and were to a certain extent out of place in a textbook intended for the use of the student of Anatomy. The other parts of the work, and especially that devoted to Microscopic Anatomy, have been carefully revised, and some alterations in arrangement and detail have been introduced.

The whole of the arteries, veins, and nerves in the woodcuts have been colored, and it is hoped that this will give additional clearness to the illustrations and enhance the value of the work.[1] In the section on Osteology the dotted lines showing the attachment of the muscles have also been colored. These have all been done in one color, and not, as is the practice in some works of Anatomy, in two colors, the one showing the so-called "origin," and the other the "insertion" of the muscle. It was felt that, as the origin and insertion are absolutely fixed in only a very small number of muscles, and that the greater number can be made to act from either extremity, this practice was misleading to the student, and caused him to attach too great importance to one action of a muscle which it might possess over any other.

The Editor is deeply indebted to many friends for their assistance in the preparation of this edition. Especially are his warmest thanks due to Mr. Ross, Demonstrator of Anatomy at St. George's Hospital, not only for many valuable hints and suggestions, and for the time and trouble he has devoted to investigating several subjects on which there appeared to be a difference of opinion amongst anatomists, but also for the assistance he has rendered in passing the pages through the press. To Dr. Délépine, Lecturer on Physiology at St. George's Hospital, and to Mr. B. T. Lowne, Lecturer on Physiology at the Middlesex Hospital, his best thanks are due for their kindness in revising the sections on General Anatomy and Development respectively.

The Editor's pupils, Mr. Codd, Mr. Le Cronier Lancaster, and Mr. Barton, have also rendered him valuable assistance in the work.

[[1] The American edition is published both with and without colors.]

CONTENTS.

PAGE
On the Systematic Use of the Living Model as a Means of Illustration in Teaching Anatomy . . . 33

General Anatomy.

PAGE
The Blood . . . 35
The Lymph and Chyle . . . 39
The Animal Cell . . . 40
Epithelium . . . 42
Connective Tissues . . . 45
Pigment . . . 50
Cartilage . . . 50
  Fibro-cartilage . . . 52
  Yellow or Reticular Cartilage . . . 53
Bone . . . 54
  Development of Bone . . . 59
Muscular Tissue . . . 64
  Unstriped Muscle . . . 67
Nervous Tissue . . . 68
  The Brain . . . 72
  The Nerves . . . 72
  The Sympathetic Nerves . . . 74
  Terminations of Nerves . . . 74
  The Ganglia . . . 77
The Vascular System . . . 78
  The Arteries . . . 78
  The Capillaries . . . 81
  The Veins . . . 83
  The Lymphatics . . . 84
  The Lymphatic Glands . . . 87
The Skin and its Appendages . . . 89
  The Nails . . . 92
  The Hair . . . 92
  The Sebaceous Glands . . . 94
  The Sudoriferous Glands . . . 94
Serous Membranes . . . 95
Synovial Membranes . . . 96
Mucous Membranes . . . 96
Secreting Glands . . . 97

Development.

Growth and Development of the Body . . . 99
The Ovum . . . 99
  Fecundation of . . . 101
  Segmentation of . . . 101
Division of Blastodermic Membrane . . . 102
First Rudiments of the Embryo . . . 103
The Amnion . . . 109
The Chorion . . . 110
The Allantois . . . 111
The Decidua . . . 111
The Placenta . . . 113
Development of the Embryo proper . . . 113
  The Spine . . . 113
  The Cranium and Face . . . 115
  The Nervous Centres . . . 118
  The Nerves . . . 120
  The Eye . . . 121
  The Ear . . . 122
  The Nose . . . 123
  The Skin, Glands, and Soft Parts . . . 123
  The Limbs and Muscles . . . 124
  The Blood-vascular System . . . 124
    The Vitelline Circulation . . . 124
    The Placental Circulation . . . 126
  The Veins . . . 128
The Alimentary Canal and its Appendages . . . 130
The Respiratory Organs . . . 132
The Urinary Organs . . . 132
The Generative Organs . . . 135
  Male Organs . . . 135
  Female Organs . . . 135
  External Organs . . . 137
Chronological Table of the Development of the Fœtus . . . 139

DESCRIPTIVE AND SURGICAL ANATOMY.

Osteology.

The Skeleton . . . 141
Number and Form of the Bones . . . 141

The Spine.

General Characters of a Vertebra . . . 143
Characters of the Cervical Vertebræ . . . 143
Atlas . . . 144
Axis . . . 145
Vertebra Prominens . . . 147
Characters of the Dorsal Vertebræ . . . 147
Peculiar Dorsal Vertebræ . . . 149
Characters of the Lumbar Vertebræ . . . 149
Structure of the Vertebræ . . . 150
Development of the Vertebræ . . . 150
  " " Atlas . . . 151
  " " Axis . . . 152
  " " Seventh Cervical . . . 152
  " " Lumbar Vertebræ . . . 152
Progress of Ossification in the Spine . . . 152
Sacrum . . . 152
Coccyx . . . 157
Of the Spine in general . . . 158

The Skull.

Bones of the Cranium . . . 160
  Occipital Bone . . . 160
  Parietal Bones . . . 164
  Frontal Bone . . . 166
  Temporal Bones . . . 170
  Sphenoid Bone . . . 176
  Ethmoid Bone . . . 181
  Development of the Cranium . . . 183
  The Fontanelles . . . 184
  Wormian Bones . . . 184
  Congenital Fissures and Gaps . . . 184
Bones of the Face:
  Nasal Bones . . . 185
  Superior Maxillary Bones . . . 186

PAGE
Bones of the Face:
    Lachrymal Bones 191
    Malar Bones 192
    Palate Bones 193
    Inferior Turbinated Bones 196
    Vomer 197
    Lower Jaw 197
    Changes produced in Lower Jaw by Age 200
Sutures of the Skull 202
Vertex of the Skull 204
Base of the Skull, Internal Surface 205
    Anterior Fossa 206
    Middle Fossa 206
    Posterior Fossa 207
Base of Skull, External Surface 208
Lateral Region of the Skull 211
Temporal Fossa 211
Zygomatic Fossa 212
Spheno-maxillary Fossa 212
Anterior Region of the Skull 213
Orbits 214
Nasal Fossæ 215
Hyoid Bone 219

THE THORAX.

The Sternum 220
The Ribs 224
Peculiar Ribs 226
Costal Cartilages 228

THE UPPER EXTREMITY.

The Shoulder 229
The Clavicle 229
The Scapula 233
The Humerus 237
The Forearm 242
    The Ulna 243
    The Radius 248
The Hand 250
    The Carpus 250
        Bones of the Upper Row 250
        Bones of the Lower Row 252
The Metacarpus 255
Peculiar Characters of the Metacarpal Bones. 256
Phalanges 257
Development of the Bones of the Hand 259

THE LOWER EXTREMITY.

Os Innominatum 260
    Ilium 261
    Ischium 261
    Pubes 261
Development of the Os Innominatum 266
The Pelvis 267
Differences between the Male and Female Pelvis 270
The Femur 270
The Leg 276
    Patella 277
    Tibia 278
    Fibula 281
The Foot 284
    Tarsus 284
    Os Calcis 284
    Cuboid 287
    Astragalus 288
    Scaphoid 289
    Internal Cuneiform 289
    Middle Cuneiform 290
    External Cuneiform 290
    Metatarsal Bones 291
    Phalanges 292
Development of the Bones of the Foot 294
Sesamoid Bones 294

The Articulations.

Structures composing the Joints 296
    Articular Lamella of Bone 296
    Ligaments 296
    Synovial Membrane 296
    Bursæ 297
    Synovia 297
Forms of Articulation:
    Synarthrosis 297
    Amphiarthrosis 298
    Diarthrosis 298
Movements of Joints 300

ARTICULATIONS OF THE TRUNK.

Articulations of the Vertebral Column 301
    " " Atlas with the Axis 306
    " " Spine with the Cranium. 309
    " " Atlas with the Occipital Bone 309
    " " Axis with the Occipital Bone 309
Temporo-maxillary Articulation 310
Articulations of the Ribs with the Vertebræ:
    Costo-vertebral 313
    Costo-transverse 314
Articulations of the Cartilages of the Ribs with the Sternum and Ensiform Cartilage 315
Interchondral Articulations 317
Ligaments of the Sternum 317
Articulation of the Pelvis with the Spine 318
    " " Sacrum and Ilium 319
Ligament between the Sacrum and Ischium 320
Articulation of the Sacrum and Coccyx 320
    " " Pubes 321

ARTICULATIONS OF THE UPPER EXTREMITY.

Sterno-clavicular 322
Scapulo-clavicular 324
Proper Ligaments of the Scapula 326
Shoulder-joint 326
Elbow-joint 329
Radio-ulnar Articulations 332
Wrist-joint 335
Articulations of the Carpus 336
Carpo-metacarpal Articulations 338
Metacarpo-phalangeal Articulations 340
Articulations of the Phalanges 341

ARTICULATIONS OF THE LOWER EXTREMITY.

Hip-joint 342
Knee-joint 346
Articulations between the Tibia and Fibula 353
Ankle-joint 354
Articulations of the Tarsus 357
Tarso-metatarsal Articulations 360
Articulations of the Metatarsal Bones 361
Metatarso-phalangeal Articulations 361
Articulations of the Phalanges 361

Muscles and Fasciæ.

General Description of Muscle 362
    " " Tendons 364
    " " Aponeuroses 364
    " " Fascia 364

MUSCLES AND FASCIÆ OF THE CRANIUM AND FACE.

Subdivision into Groups 365

Cranial Region.

Dissection 366
Occipito-frontalis 366

Auricular Region.

Dissection 369
Attollens Aurem: Attrahens Aurem. 369
Retrahens Aurem: Actions 369

PAGE

Palpebral Region.

Dissection . . . 369
Orbicularis Palpebrarum . . . 370
Corrugator Supercilii . . . 370
Tensor Tarsi: Actions . . . 371

Orbital Region.

Dissection . . . 371
Levator Palpebræ . . . 371
Rectus Superior, Inferior, Internal and External Recti . . . 371
Superior Oblique . . . 372
Inferior Oblique . . . 373
Actions: Surgical Anatomy . . . 373

Nasal Region.

Pyramidalis Nasi . . . 374
Levator Labii Superioris Alæque Nasi . . . 374
Dilatator Naris, Anterior and Posterior . . . 374
Compressor Nasi . . . 374
" Narium Minor . . . 374
Depressor Alæ Nasi: Actions . . . 374

Superior Maxillary Region.

Levator Labii Superioris (Proprius) . . . 375
Levator Anguli Oris . . . 375
Zygomatici: Actions . . . 375

Inferior Maxillary Region.

Dissection . . . 376
Levator Labii Inferioris . . . 376
Depressor Labii Inferioris . . . 376
Depressor Anguli Oris . . . 376

Intermaxillary Region.

Dissection . . . 377
Orbicularis Oris . . . 377
Buccinator . . . 377
Risorius . . . 378
Actions . . . 378

Temporo-maxillary Region.

Masseter . . . 378
Temporal Fascia . . . 379
Dissection . . . 379
Temporal . . . 379

Pterygo-maxillary Region.

Dissection . . . 380
External Pterygoid . . . 380
Internal Pterygoid . . . 381
Actions . . . 381

MUSCLES AND FASCIÆ OF THE NECK.

Subdivision into Groups . . . 381

Superficial Region.

Dissection . . . 382
Superficial Cervical Fascia . . . 382
Platysma Myoides . . . 382
Deep Cervical Fascia . . . 383
Sterno-mastoid . . . 385
Boundaries of the Triangles of the Neck . . . 385
Actions . . . 385
Surgical Anatomy . . . 386

Infrahyoid Region.

Dissection . . . 386
Sterno-hyoid . . . 386
Sterno-thyroid . . . 386
Thyro-hyoid . . . 387
Omo-hyoid . . . 387
Actions . . . 388

Suprahyoid Region.

Dissection . . . 388
Digastric . . . 388
Stylo-hyoid . . . 388
Mylo-hyoid . . . 389
Genio-hyoid . . . 389
Actions . . . 389

PAGE

Lingual Region.

Dissection . . . 389
Genio-hyo-glossus . . . 390
Hyo-glossus . . . 390
Lingualis and Intrinsic Fibres of Tongue . . . 391
Stylo-glossus . . . 392
Palato-glossus . . . 392
Actions . . . 392

Pharyngeal Region.

Dissection . . . 392
Inferior Constrictor . . . 392
Middle Constrictor, Superior Constrictor . . . 393
Stylo-pharyngeus . . . 394
Actions . . . 394

Palatal Region.

Dissection . . . 394
Levator Palati . . . 394
Tensor Palati . . . 394
Azygos Uvulæ . . . 395
Palato-glossus . . . 396
Palato-pharyngeus . . . 396
Actions . . . 396
Surgical Anatomy . . . 396

Vertebral Region (Anterior).

Rectus Capitis Anticus Major . . . 397
Rectus Capitis Anticus Minor . . . 397
Rectus Lateralis, Longus Colli . . . 398

Vertebral Region (Lateral).

Scalenus Anticus, Scalenus Medius . . . 398
Scalenus Posticus . . . 398
Actions . . . 399

MUSCLES AND FASCIÆ OF THE TRUNK.

Subdivision into Groups . . . 399

Muscles of the Back.

Subdivision into Layers . . . 399

First Layer.

Dissection . . . 399
Trapezius . . . 400
Ligamentum Nuchæ . . . 401
Latissimus Dorsi . . . 401

Second Layer.

Dissection . . . 403
Levator Anguli Scapulæ . . . 403
Rhomboideus Minor and Major . . . 403
Actions . . . 403

Third Layer.

Dissection . . . 404
Serratus Posticus Superior and Inferior . . . 404
Vertebral Aponeurosis . . . 405
Splenius Capitis and Colli . . . 405
Actions . . . 405

Fourth Layer.

Dissection . . . 406
Erector Spinæ . . . 406
Sacro-lumbalis . . . 406
Musculus Accessorius ad Sacro-lumbalem . . . 406
Cervicalis Ascendens . . . 406
Longissimus Dorsi . . . 406
Transversalis Colli . . . 406
Trachelo-mastoid . . . 408
Spinalis Dorsi . . . 408
Spinalis Colli . . . 408
Complexus, Biventer Cervicis . . . 408

Fifth Layer.

Dissection . . . 409
Semispinalis Dorsi and Colli . . . 409
Multifidus Spinæ . . . 409
Rotatores Spinæ . . . 409
Supraspinales . . . 410
Interspinales . . . 410

PAGE
Extensor Coccygis . . . 410
Intertransversales . . . 410
Rectus Capitis Posticus Major and Minor . . . 410
Obliquus Inferior . . . 410
Obliquus Superior . . . 411
Actions . . . 411

Muscles of the Abdomen.

Dissection . . . 412
Obliquus Externus . . . 412
Obliquus Internus . . . 414
Transversalis . . . 415
Lumbar Fascia . . . 416
Rectus . . . 417
Pyramidalis, Quadratus Lumborum . . . 418
Linea Alba . . . 418
Lineæ Semilunares, Lineæ Transversæ . . . 419
Actions . . . 419

MUSCLES AND FASCIÆ OF THE THORAX.

Intercostal Fasciæ . . . 420
External and Internal Intercostals . . . 420
Infracostales, Triangularis Sterni . . . 420
Levatores Costarum . . . 421
Actions . . . 421

Diaphragmatic Region.

Diaphragm . . . 422
Actions . . . 425

MUSCLES AND FASCIÆ OF THE UPPER EXTREMITY.

Subdivision into Groups . . . 425
Dissection of Pectoral Region and Axilla . . . 426
Fasciæ of the Thorax . . . 426

Anterior Thoracic Region.

Pectoralis Major . . . 427
Costo-coracoid Membrane . . . 429
Pectoralis Minor . . . 429
Subclavius . . . 429
Actions . . . 429

Lateral Thoracic Region.

Serratus Magnus . . . 430
Actions . . . 430

Acromial Region.

Deltoid . . . 432
Actions . . . 432

Anterior Scapular Region.

Subscapular Fascia . . . 433
Subscapularis: Actions . . . 433

Posterior Scapular Region.

Dissection . . . 433
Supraspinous Fascia . . . 433
Supraspinatus . . . 433
Infraspinous Fascia . . . 433
Infraspinatus . . . 434
Teres Minor . . . 434
Teres Major . . . 435
Actions . . . 435

Anterior Humeral Region.

Deep Fascia of Arm . . . 435
Coraco brachialis . . . 436
Biceps . . . 436
Brachialis Anticus . . . 437
Actions . . . 437

Posterior Humeral Region.

Triceps . . . 438
Subanconeus: Actions . . . 438

Muscles of Forearm.

Deep Fascia of Forearm . . . 439

Anterior Brachial Region, Superficial Layer.

Pronator Radii Teres . . . 440
Flexor Carpi Radialis . . . 440
Palmaris Longus . . . 441
Flexor Carpi Ulnaris . . . 441
Flexor Digitorum Sublimis . . . 441

Anterior Brachial Region, Deep Layer.

PAGE
Flexor Profundus Digitorum . . . 442
Flexor Longus Pollicis . . . 442
Pronator Quadratus . . . 443
Actions . . . 444

Radial Region.

Dissection . . . 444
Supinator Longus . . . 444
Extensor Carpi Radialis Longior . . . 445
Extensor Carpi Radialis Brevior . . . 445

Posterior Brachial Region, Superficial Layer.

Extensor Communis Digitorum . . . 446
Extensor Minimi Digiti . . . 446
Extensor Carpi Ulnaris . . . 446
Anconeus . . . 447

Posterior Brachial Region, Deep Layer.

Supinator Brevis . . . 447
Extensor Ossis Metacarpi Pollicis . . . 447
Extensor Primi Internodii Pollicis . . . 447
Extensor Secundi Internodii Pollicis . . . 448
Extensor Indicis . . . 448
Actions . . . 449

Muscles and Fasciæ of the Hand.

Dissection . . . 449
Anterior Annular Ligament . . . 449
Posterior Annular Ligament . . . 450
Palmar Fascia . . . 450

Muscles of the Hand.

Radial Region . . . 452
Ulnar Region . . . 454
Middle Palmar Region . . . 455
Actions . . . 457

Surgical Anatomy of the Muscles of the Upper Extremity.

Fractures of the Clavicle . . . 457
" " Acromion Process . . . 458
" " Coracoid Process . . . 458
" " Humerus . . . 458
" " Ulna . . . 459
" " Olecranon . . . 459
" " Radius . . . 459

MUSCLES AND FASCIÆ OF THE LOWER EXTREMITY.

Subdivision into Groups . . . 461

Iliac Region.

Dissection . . . 462
Iliac Fascia . . . 462
Psoas Magnus . . . 463
Psoas Parvus . . . 463
Iliacus . . . 463
Actions . . . 465

Anterior Femoral Region.

Dissection . . . 465
Fasciæ of the Thigh: Superficial Fascia . . . 465
Deep Fascia (Fascia Lata . . . 465
Saphenous Opening . . . 466
Iliac and Pubic Portions of Fascia Lata . . . 466
Tensor Vaginæ Femoris . . . 466
Sartorius . . . 467
Quadriceps Extensor, Crureus . . . 467
Rectus Femoris . . . 467
Vastus Externus . . . 468
Vastus Internus and Crureus . . . 468
Subcrureus: Actions . . . 469

Internal Femoral Region.

Dissection . . . 470
Gracilis . . . 470
Pectineus . . . 470
Adductor Longus . . . 470
Adductor Brevis . . . 471

d by Google

PAGE
Adductor Magnus 471
Actions 472

Gluteal Region.

Dissection 472
Gluteus Maximus 473
Gluteus Medius 474
Gluteus Minimus 474
Pyriformis 475
Obturator Membrane 475
Obturator Internus 475
Gemelli 476
Quadratus Femoris 476
Obturator Externus 476
Actions 477

Posterior Femoral Region.

Dissection 477
Biceps 477
Semitendinosus, Semimembranosus 478
Actions 478
Surgical Anatomy of Hamstring Tendons . . 479

MUSCLES AND FASCIÆ OF THE LEG.

Dissection of Front of Leg 479
Deep Fascia of the Leg 479
Muscles of the Leg 479

Anterior Tibio-fibular Region.

Tibialis Anticus 479
Extensor Proprius Pollicis 480
Extensor Longus Digitorum 480
Peroneus Tertius: Actions 481

Posterior Tibio-fibular Region, Superficial Layer.

Dissection 481
Gastrocnemius 482
Soleus 483
Tendo Achillis, Plantaris 483
Actions 484

Posterior Tibio-fibular Region, Deep Layer.

Deep Transverse Fascia of Leg 484
Popliteus 484
Flexor Longus Pollicis 484
Flexor Longus Digitorum, Tibialis Posticus . 485
Actions 486

Fibular Region.

Peroneus Longus 486
Peroneus Brevis 486
Actions 487
Surgical Anatomy of Tendons around Ankle. 487

MUSCLES AND FASCIÆ OF THE FOOT.

Anterior Annular Ligament 487
Internal Annular Ligament 488
External Annular Ligament 488
Plantar Fascia 488

Muscles of the Foot, Dorsal Region.

Extensor Brevis Digitorum 489

Plantar Region.

Subdivision into Groups 489
Subdivision into Layers 489
First Layer 489
Second Layer 491
Third Layer 492
Fourth Layer 493

Surgical Anatomy of the Muscles of the Lower Extremity.

Fracture of the Neck of the Femur 494
" " Femur below Trochanter Minor 494
" " Femur above the Condyles . 495
" " Patella 495
" " Tibia 495
" " Fibula, with Dislocation of the Foot outward 495
[THE ACTION OF INDIVIDUAL MUSCLES, AS SHOWN BY ELECTRICITY . . . . 496]

The Arteries.

General Anatomy.

Subdivision into Pulmonary and Systemic . 501
Distribution of—Where found 501
Mode of Division—Anastomoses 501
Pulmonary Artery 502

ARCH OF THE AORTA.

Dissection 503
Ascending Part of Arch 504
Transverse Part of Arch 504
Descending Part of Arch 505
Peculiarities, Surgical Anatomy 506
Branches 507
Peculiarities of Branches 507
Coronary Arteries 507

Arteria Innominata.

Relations 508
Peculiarities 508
Surgical Anatomy 509

Common Carotid Arteries.

Course and Relations 510
Peculiarities, Surgical Anatomy 510

External Carotid Artery.

Course 512
Relations 514
Surgical Anatomy 514
Branches 514

Superior Thyroid Artery.

Course and Relations 514
Branches 514
Surgical Anatomy 515

Lingual Artery.

Course and Relations 515
Branches 515
Surgical Anatomy 516

Facial Artery.

Course and Relations 516
Branches 517
Peculiarities 519
Surgical Anatomy 519

Occipital Artery.

Course and Relations 519
Branches 519
Posterior Auricular Artery 520
Ascending Pharyngeal Artery 520

Temporal Artery.

Course and Relations 521
Branches 521
Surgical Anatomy 521

Internal Maxillary Artery.

Course 521
Relations 522
Peculiarities 522
Branches from First Portion 523
" " Second Portion 523
" " Third Portion 524

SURGICAL ANATOMY OF THE TRIANGLES OF THE NECK.

Anterior Triangular Space.

Inferior Carotid Triangle 525

PAGE
Superior Carotid Triangle 526
Submaxillary Triangle 526

Posterior Triangular Space.

Occipital Triangle 527
Subclavian Triangle 527

Internal Carotid Artery.

Cervical Portion 528
Petrous Portion 528
Cavernous Portion 528
Cerebral Portion 529
Peculiarities, Surgical Anatomy 530
Branches 530
  Ophthalmic Artery 530
  Cerebral Branches of Internal Carotid 533

[BLOOD-VESSELS OF THE BRAIN.]

[Carotid and Vertebral Set 534
Ganglionic Arterial System 536
Cortical Arterial System 537
Anterior Cerebral 537
Middle Cerebral or Sylvian 537
Posterior Cerebral 538
Nutrient Branches 539]

ARTERIES OF THE UPPER EXTREMITY.

Subclavian Arteries.

First Part of Right Subclavian Artery 542
First Part of Left Subclavian Artery 543
Second Part of Subclavian Artery 543
Third Part of Subclavian Artery 544
Peculiarities 544
Surgical Anatomy 544
Branches 546
  Vertebral Artery and its Branches 546
  Basilar Artery and its Branches 549
  Cerebellar Branches of Vertebral 549
  Circle of Willis 550
  Thyroid Axis 550
  Inferior Thyroid 550
  Suprascapular Artery 550
  Transversalis Colli 551
  Internal Mammary 551
  Superior Intercostal 552
  Deep Cervical Artery 552

SURGICAL ANATOMY OF THE AXILLA 553

Axillary Artery.

First Portion 554
Second Portion 554
Third Portion 555
Peculiarities, Surgical Anatomy 555
Branches 556

Brachial Artery.

Relations 559
Bend of the Elbow 559
Peculiarities of Brachial Artery 559
Surgical Anatomy 560
Branches 561

Radial Artery.

Relations 562
Deep Palmar Arch 563
Peculiarities 563
Surgical Anatomy 563
Branches 564

Ulnar Artery.

Relations 566
Superficial Palmar Arch 566
Peculiarities of Ulnar Artery 567
Surgical Anatomy 567
Branches 567

DESCENDING AORTA 569

THORACIC AORTA.

Course and Relations 570
Surgical Anatomy 570
Branches 570

ABDOMINAL AORTA.

PAGE
Course 571
Relations 573
Surgical Anatomy 573
Branches 574
  Cœliac Axis, Gastric Artery 574
  Hepatic Artery 574
  Splenic Artery 576
  Superior Mesenteric Artery 577
  Inferior Mesenteric Artery 579
  Suprarenal Arteries 580
  Renal Arteries 580
  Spermatic Arteries 581
  Phrenic Arteries 581
  Lumbar Arteries 581
  Middle Sacral Artery 582

COMMON ILIAC ARTERIES.

Course and Relations 582
Peculiarities, Surgical Anatomy 583

Internal Iliac Artery.

Course and Relations 584
Peculiarities 585
Surgical Anatomy 585
Branches 586
  Vesical Arteries 586
  Hemorrhoidal Arteries 586
  Uterine and Vaginal Arteries 586
  Obturator Artery 587
  Internal Pudic Artery 588
  Sciatic Artery 590
  Ilio-lumbar Artery 591
  Lateral Sacral Artery 591
  Gluteal Artery 591

External Iliac Artery.

Course 591
Relations 592
Surgical Anatomy 592
Deep Epigastric Artery 593
Deep Circumflex Iliac Artery 593

Femoral Artery.

Course and Relations 594
Scarpa's Triangle 594
Peculiarities of the Femoral Artery 596
Surgical Anatomy 596
Branches 597
Profunda Artery and its Branches 598

Popliteal Artery.

Course and Relations 599
Popliteal Space 600
Peculiarities 601
Surgical Anatomy 601
Branches 603

Anterior Tibial Artery.

Course and Relations 603
Peculiarities, Surgical Anatomy 603
Branches 605

Dorsalis Pedis Artery.

Course and Relations 605
Peculiarities, Surgical Anatomy 606
Branches 606

Posterior Tibial Artery.

Course and Relations 607
Peculiarities, Surgical Anatomy 607
Branches 608

Peroneal Artery.

Course and Relations 608
Peculiarities 609
Plantar Arteries 610

The Veins.

PAGE

General Anatomy.

Subdivision into Pulmonary, Systemic, and Portal 611
Anastomoses of Veins 611
Superficial Veins, Deep Veins, Venæ Comites. 611
Sinuses 612
Pulmonary Veins 612

Veins of the Head and Neck.

Facial Vein 613
Temporal Vein 614
Internal Maxillary Vein 614
Temporo-maxillary Vein 614
Posterior Auricular Vein, Occipital Vein 615

Veins of the Neck.

External Jugular Vein 615
Posterior External Jugular Vein 615
Anterior Jugular Vein 615
Internal Jugular Vein 616
Lingual and Pharyngeal 616
Thyroid Veins, Vertebral Veins 616
Veins of the Diploë 617

Cerebral Veins.

Superficial Cerebral Veins 618
Deep Cerebral Veins 618
Cerebellar Veins 619

Sinuses of the Dura Mater.

Superior Longitudinal Sinus 619
Inferior Longitudinal, Straight 620
Lateral and Occipital Sinuses 620
Cavernous Sinuses 621
Circular Petrosal 621
Inferior Petrosal 622
Transverse Sinuses 622
Superior Petrosal Sinus 622

PAGE

VEINS OF THE UPPER EXTREMITY.

Superficial Veins 623
Deep Veins 623
Axillary Vein 625
Subclavian Vein 625
Innominate Veins 625
Peculiarities of 626
Internal Mammary Veins 626
Inferior Thyroid Veins 626
Superior Intercostal Veins 627
Superior Vena Cava 627
Azygos Veins 627
Bronchial Veins 628
Spinal Veins 628

VEINS OF THE LOWER EXTREMITY.

Internal Saphenous Vein 630
External Saphenous Vein 631
Popliteal Vein 631
Femoral Vein 631
External Iliac Vein 631
Internal Iliac Vein 631
Common Iliac Veins 632
Inferior Vena Cava 633
Peculiarities 633
Lumbar and Spermatic Veins 633
Ovarian and Renal Veins 634
Suprarenal Veins 634
Phrenic Veins 634
Hepatic Veins 634

PORTAL SYSTEM OF VEINS.

Inferior Mesenteric Vein 634
Superior Mesenteric Vein 634
Splenic Vein 635
Gastric Veins 635
Portal Vein 635
Cardiac Veins 636
Coronary Sinus 637

The Lymphatics.

General Anatomy.

Subdivision into Deep and Superficial 638
Lymphatic or Conglobate Glands 638
Thoracic Duct 639
Right Lymphatic Duct 640

Lymphatics of Head, Face, and Neck.

Superficial Lymphatic Glands of Head 640
“ Lymphatics of the Head 640
“ “ of the Face 641
Deep Lymphatics of the Face 641
“ “ of the Cranium 641
Superficial Cervical Glands 642
Deep Cervical Glands 642
Superficial and Deep Cervical Lymphatics 642

Lymphatics of the Upper Extremity.

Superficial Lymphatic Glands 643
Deep Lymphatic Glands 643
Axillary Glands 643
Superficial Lymphatics of Upper Extremity 644
Deep Lymphatics of Upper Extremity 644

Lymphatics of the Lower Extremity.

Superficial Inguinal Glands 644
Deep Lymphatic Glands 645
Anterior Tibial Gland 645
Deep Popliteal Glands 645
Deep Inguinal Glands 645
Gluteal and Ischiatic Glands 645
Superficial Lymphatics of Lower Extremity 645
Internal Group 645
External Group 646
Deep Lymphatics of Lower Extremity 646

Lymphatics of Pelvis and Abdomen.

Deep Lymphatic Glands of Pelvis 646
External Iliac Glands 646
Internal Iliac Glands 646
Sacral Glands 646
Lumbar Glands 646
Superficial Lymphatics of Wall of Abdomen 646
Superficial Lymphatics of Gluteal Region 647
“ “ of Scrotum and Perineum 647
“ “ of Penis 647
“ “ of Labia, Nymphæ, and Clitoris 648
Deep Lymphatics of Pelvis and Abdomen 648
Lymphatics of Bladder 648
“ of Rectum 648
“ of Uterus 648
“ of Testicle 648
“ of Kidney 648
“ of Liver 648
Lymphatic Glands of Stomach 649
Lymphatics of Stomach 649
Lymphatic Glands of Spleen 649
Lymphatics of Spleen 649

Lymphatic System of the Intestines.

Lymphatic Glands of Small Intestine (Mesenteric Glands) 649
Lymphatic Glands of Large Intestine 649
Lymphatics of Small Intestine (Lacteals) 649
“ of Large Intestine 649

Lymphatics of Thorax.

Deep Lymphatic Glands of Thorax 649
“ Intercostal Glands 649

d by Google

PAGE
Deep Internal Mammary Glands 650
" Anterior Mediastinal Glands 650
" Posterior Mediastinal Glands 650
Superficial Lymphatics on Front of Thorax 650
Deep Lymphatics of Thorax 650
" Intercostal Lymphatics 650
" Internal Mammary Lymphatics 650
Lymphatics of Diaphragm 650
Bronchial Glands 650
Lymphatics of Lung 650
Cardiac Lymphatics 650
Thymic Lymphatics 651
Thyroid Lymphatics 651
Lymphatics of Œsophagus 651

Nervous System.

General Anatomy.

Subdivision into Cerebro-spinal Axis, Ganglia, and Nerves 652

THE SPINAL CORD AND ITS MEMBRANES.

Dissection 652
Membranes of the Cord 652
Dura Mater 652
Arachnoid 653
Pia Mater 654
Ligamentum Denticulatum 654
Spinal Cord 654
Fissures of Cord 655
Columns of Cord 655
Structure of the Cord 656
Minute Anatomy of the Cord 656
Neuroglia 656
White Substance 657
Gray Substance 658
Origin of the Spinal Nerves in the Cord . . . 660
Central Canal of the Cord 661

THE BRAIN AND ITS MEMBRANES.

Membranes of the Brain 661

Dura Mater.

Structure 661
Arteries, Veins, Nerves 662
Glandulæ Pacchioni 662
Processes of the Dura Mater 662
Falx Cerebri 662
Tentorium Cerebelli 663
Falx Cerebelli 663

Arachnoid Membrane.

Subarachnoid Space 663
Cerebro-spinal Fluid 664
Pia Mater 664

THE BRAIN.

Subdivision into Cerebrum, Cerebellum, Pons Varolii, Medulla Oblongata 664
Weight of Brain 665

Medulla Oblongata.

Anterior Pyramids 666
Lateral Tract and Olivary Body 666
Restiform Bodies 666
Posterior Pyramids 666
Posterior Surface of Medulla Oblongata . . 667
Structure of Medulla Oblongata 667
" of Anterior Pyramid 667
" of Lateral Tract 667
" of Olivary Body 667
" of Restiform Body 668
Septum of Medulla Oblongata 668
Gray Matter of Medulla Oblongata 668

Pons Varolii.

Structure 670
Transverse Fibres 670
Longitudinal Fibres 672
Septum 672

Cerebrum.

Upper Surface of Cerebrum 672
Convolutions 672
Sulci 673
Fissure of Sylvius 675
Sulci: Fissure of Rolando 675
Parieto-occipital Fissure 675
Lobes:
Frontal Lobe 676
Parietal Lobe 676
Occipital Lobe 677
Temporo-sphenoidal Lobe 677
Central Lobe [Insula] 677
Calloso-marginal Fissure 678
Parieto-occipital Fissure 678
Calcarine Fissure 678
Collateral Fissure 679
Dentate Fissure 679
Gyrus Fornicatus 679
Marginal Convolution 679
Quadrate Lobe 680
Cuneate Lobe 680
Uncinate Gyrus 680
Temporo-sphenoidal Lobe 680
[Cerebral Localization and Topography . . . 681
Motor Centres 681
Landmarks on the Skull 684
Bony Points 684
Sutures 684
Relation of Fissures and Convolutions to Landmarks on the Skull 685
Fissure of Rolando 685
Fissure of Sylvius 686
Precentral Sulcus 686
Inferior Frontal Sulcus 686
Superior Frontal Sulcus 686
Intraparietal Sulcus 686
Parieto-occipital Fissure . . . . 687]
Base of the Brain 687
General Arrangement of the Parts composing the Cerebrum 690
Interior of the Cerebrum 690
Corpus Callosum 691
Lateral Ventricles 692
Corpus Striatum 693
Tænia Semicircularis 694
Choroid Plexus 694
Corpus Fimbriatum 695
Hippocampus 696
Transverse Fissure 697
Septum Lucidum 697
Fifth Ventricle 697
Fornix 698
Velum Interpositum 699
Thalamus Opticus 699
Third Ventricle 700
Commissures of Third Ventricle . . 700
Foramen of Monro 702
Pineal Gland 702
Corpora Quadrigemina 702
Valve of Vieussens 703
Corpora Geniculata 703
Internal Structure of Cerebrum 703
Gray Matter of the Cortex 703
" " Basal Ganglia 705
Central Gray Matter of the Cerebrum 706
White Matter of the Cerebrum 706
Diverging Fibres 706
Commissural Fibres 707

Cerebellum.

Its Position, Size, Weight, etc. 708
Cerebellum, Upper Surface 708
" Under Surface 709

PAGE
Lobes of the Cerebellum 710
Internal Structure of the Cerebellum 710
White Matter of Cerebellum 711
Peduncles of Cerebellum 711
Gray Matter of Cerebellum 711
Fourth Ventricle 712
  Lining Membrane 714
  Choroid Plexuses 714

Cranial Nerves.

Subdivision into Groups 715
Olfactory Nerve 716
Optic Nerve 717
  " Tracts 717
  " Commissure 717
Motor Oculi Nerve 718
Pathetic Nerve 719
Trifacial Nerve 719
  Gasserian Ganglion 720
Ophthalmic Nerve 720
  Lachrymal, Frontal, and Nasal Branches 721
Ophthalmic Ganglion 722
Superior Maxillary Nerve 723
Spheno-palatine Ganglion 725
Inferior Maxillary Nerve 727
  Auriculo-temporal Branch 728
  Gustatory Branch 729
  Inferior Dental Branch 729
Otic Ganglion 729
Submaxillary Ganglion 730
Abducens Nerve 731

Relations of the Orbital Nerves:

  in the Cavernous Sinus 732
  in the Sphenoidal Fissure 732
  in the Orbit 732
Facial Nerve 732
  Branches of Facial Nerve 734
Auditory Nerve 736
Glosso-pharyngeal Nerve 736
Pneumogastric (Vagus) Nerve 738
Spinal Accessory Nerve 741
Hypoglossal Nerve 742

Spinal Nerves.

Roots of the Spinal Nerves 744
  Origin of Anterior Roots 744
  " of Posterior Roots 744
Ganglia of the Spinal Nerves 745

[Divisions of the Spinal Nerves.]

Anterior Divisions of the Spinal Nerves 745
Posterior Divisions of the Spinal Nerves 745
[Points of Origin and Emergence of the Spinal Nerves 745]

CERVICAL NERVES.

Roots of the Cervical Nerves 746
Posterior Divisions of the Cervical Nerves 747
Anterior Divisions of the Cervical Nerves 749

Cervical Plexus.

Superficial Branches of the Cervical Plexus 750
Deep Branches of the Cervical Plexus 751

Brachial Plexus.

Branches above the Clavicle:

  Posterior Thoracic, Suprascapular 754

Branches below the Clavicle:

  Anterior Thoracic 755
  Subscapular Nerves 755
  Circumflex Nerve 756
  Musculo-cutaneous Nerve 756
  Internal Cutaneous Nerve 756
  Lesser Internal Cutaneous Nerve 757
  Median Nerve 759
  Ulnar Nerve 761
  Musculo-spiral Nerve 762
  Radial Nerve 763
  Posterior Interosseous Nerve 764

DORSAL NERVES.

Roots of the Dorsal Nerves 764
Posterior Divisions of the Dorsal Nerves 764
Anterior Divisions of the Dorsal Nerves 764
First Dorsal Nerve 766
Intercostal Nerves 766
Upper Dorsal Nerves 766
Intercosto-humeral Nerve 766
Lower Dorsal Nerves 766
Last Dorsal Nerve 767

LUMBAR NERVES.

Root of Lumbar Nerves 767
Posterior Divisions of Lumbar Nerves 767
Anterior Divisions of Lumbar Nerves 767

Lumbar Plexus.

Branches of Lumbar Plexus 768
Ilio-hypogastric Nerve 769
Ilio-inguinal and Genito-crural Nerves 770
External Cutaneous Nerve 770
Obturator Nerve 770
Accessory Obturator Nerve 773
Anterior Crural Nerve 773
Branches of Anterior Crural 773
  Middle Cutaneous 773
  Internal Cutaneous 773
  Long Saphenous 774
  Muscular and Articular Branches 774

SACRAL AND COCCYGEAL NERVES.

Roots of, Origin of 775
Posterior Sacral Nerves 775
Coccygeal Nerve 775
Anterior Sacral Nerves 775

Sacral Plexus.

Superior Gluteal Nerve 778
Pudic Nerve 778
Small Sciatic Nerve 778
Great Sciatic Nerve 780
Internal Popliteal Nerve 780
Short Saphenous Nerve 781
Posterior Tibial Nerve 781
Plantar Nerves 781
External Popliteal or Peroneal Nerve 782
Anterior Tibial Nerve 782
Musculo-cutaneous Nerve 783

Sympathetic Nerve.

Subdivision of, into Parts 784
Branches of the Ganglia, General Description of 784
Cervical Portion of the Gangliated Cord 787
Superior Cervical Ganglion 787
Carotid and Cavernous Plexuses 789
Middle Cervical Ganglion 790
Inferior Cervical Ganglion 791
Thoracic Part of the Gangliated Cord 791
Great Splanchnic Nerve 791
Lesser Splanchnic Nerve 791
Smallest Splanchnic Nerve 791

PAGE
Lumbar Portion of the Gangliated Cord . . . 792
Pelvic Portion of the Gangliated Cord . . . 792

THE GREAT PLEXUSES OF THE SYMPATHETIC.

The Cardiac Plexuses 792
The Great Cardiac Plexus 792
The Superficial Cardiac Plexus 793
The Coronary Plexuses 793
The Solar Plexus 793
The Phrenic Plexus 794
The Suprarenal Plexus 794
The Renal Plexus 794
PAGE
The Spermatic Plexus 794
The Cœliac Plexus 794
The Superior Mesenteric Plexus 796
The Aortic Plexus 796
The Inferior Mesenteric Plexus 796
The Hypogastric Plexus 796
The Pelvic Plexus 796
The Inferior Hemorrhoidal Plexus 796
The Vesical Plexus 796
Prostatic Plexus 796
Vaginal Plexus 797
Uterine Plexus 797

Organs of Sense.

TONGUE.

Papillæ of 800
Glands of 800
Fibrous Septum of 801
Arteries and Nerves of 801

NOSE.

Cartilages of 802
Muscles of 803
Skin 803
Mucous Membrane 803
Arteries, Veins, and Nerves 803

Nasal Fossæ.

Mucous Membrane of 803
    Peculiarities of, in Superior, Middle, and Inferior Meatuses 804
Arteries, Veins, and Nerves of Nasal Fossæ . 804

EYE.

Situation, Form of 805
Tunics of 806
Sclerotic 806
Cornea 807
Choroid 809
Ciliary Processes 810
Iris 810
Membrana Pupillaris 812
Ciliary Muscle 812
Retina 812
Structure of Retina 813
" " at Yellow Spot 816
Arteria Centralis Retinæ 816

Humors of the Eye.

Aqueous Humor 816
    Anterior Chamber 816
    Posterior Chamber 816
Vitreous Body 817
Crystalline Lens and its Capsule 817
Changes Produced in the Lens by Age . . . 818
Suspensory Ligament of Lens 818
Canal of Petit 818
Vessels of the Globe of the Eye 819
Nerves of Eyeball 819

Appendages of the Eye.

Eyebrows 819
Eyelids 819
    Structure of the Eyelids 819
Tarsal Cartilages 820
Meibomian Glands 820
Eyelashes 821
Conjunctiva 821
Carunculæ Lachrymales 821

Lachrymal Apparatus.

Lachrymal Gland 821
" Canals 822
" Sac 822
Nasal Duct 822

EAR.

Pinna, or Auricle 823
Structure of the Pinna 823
Ligaments of the Pinna 823
Muscles of the Pinna 824
Arteries, Veins, and Nerves of the Pinna . . 824
Auditory Canal 825

Middle Ear, or Tympanum.

Cavity of Tympanum 826
Eustachian Tube 828
Membrana Tympani 829
    Structure of 829
Ossicles of the Tympanum 829
Ligaments of the Ossicula 830
Muscles of the Tympanum 830
Mucous Membrane of Tympanum 831
Arteries of Tympanum 831
Veins and Nerves of Tympanum 831

Internal Ear, or Labyrinth.

Vestibule 832
Semicircular Canals:
    Superior Semicircular Canal 833
    Posterior Semicircular Canal 833
    External Semicircular Canal 833
Cochlea:
    Central Axis of, or Modiolus 833
    Spiral Canal of 833
Scala Tympani, Scala Vestibuli, and Scala Media 834
The Organ of Corti 835
Perilymph 837
Membranous Labyrinth 837
Utricle and Saccule 837
Membranous Semicircular Canals 837
Endolymph 838
Otoliths 838
Vessels of the Labyrinth 838
Auditory Nerve, Vestibular Nerve 838
Cochlear Nerve 838

VISCERA.

Organs of Digestion and their Appendages.

Subdivisions of the Alimentary Canal 839
The Mouth 839
The Lips 839
The Cheeks 840
The Gums 840

TEETH.

General Characters of 840
Permanent Teeth 841
Incisors and Canine 841
Bicuspids, Molars 841

PAGE
- Temporary or Milk Teeth . . . 843
- Structure of the Teeth . . . 843
- Ivory or Dentine . . . 844
- Enamel . . . 845
- Cortical Substance . . . 845
- Development of the Temporary Teeth . . . 846
- " " Permanent Teeth . . . 848
- Eruption of the Teeth . . . 849

PALATE.

- Hard Palate . . . 850
- Soft Palate . . . 850
- Uvula, Pillars of the Soft Palate . . . 851
- Mucous Membrane, Aponeurosis, and Muscles of Soft Palate . . . 851

Tonsils.

- Arteries . . . 851
- Veins and Nerves of Tonsils . . . 852

SALIVARY GLANDS.

Parotid Gland.

- Stenson's Duct . . . 853
- Vessels and Nerves of Parotid Gland . . . 853

Submaxillary Gland.

- Wharton's Duct . . . 853
- Vessels and Nerves of Submaxillary Gland . 854

Sublingual Gland.

- Vessels and Nerves of . . . 854
- Structure of Salivary Glands . . . 854

PHARYNX.

- Structure of Pharynx . . . 856

ŒSOPHAGUS.

- Relations of Œsophagus . . . 857
- Surgical Anatomy . . . 857
- Structure of Œsophagus . . . 858

ABDOMEN.

- Boundaries . . . 858
- Apertures of . . . 859
- Regions . . . 859

PERITONEUM.

- Reflections Traced . . . 860
- Foramen of Winslow . . . 866
- Lesser Omentum . . . 867
- Great Omentum . . . 867
- Gastro-splenic Omentum . . . 867
- Mesentery . . . 867
- Mesocæcum . . . 868
- Mesocolon, Mesorectum, Appendices Epiploicæ . . . 868

STOMACH.

- Situation . . . 869
- Splenic End, Pyloric End . . . 869
- Cardiac and Pyloric Orifices . . . 869
- Greater and Lesser Curvatures . . . 869
- Surfaces . . . 870
- Ligaments of . . . 870
- Alterations in Position . . . 870
- Pylorus . . . 870
- Structure of Stomach . . . 871
- Serous and Muscular Coats . . . 871
- Mucous Membrane . . . 872
- Gastric Follicles . . . 872
- Vessels and Nerves of Stomach . . . 874

SMALL INTESTINE.

- Duodenum . . . 874
  - Ascending Portion . . . 874
  - Descending Portion . . . 875
  - Transverse Portion . . . 875
- Vessels and Nerves of Duodenum . . . 876
- Jejunum . . . 876
- Ileum . . . 876
- Structure of Small Intestine . . . 876
- Serous and Muscular Coats . . . 876
- Mucous Membrane . . . 877
- Epithelium and Valvulæ Conniventes . . . 877
- Villi—their Structure . . . 877
- Simple Follicles . . . 879
- Duodenal Glands . . . 879
- Solitary Glands . . . 880
- Agminate, or Peyer's Glands . . . 880

LARGE INTESTINE.

- Cæcum . . . 882
  - Appendix Cæci Vermiformis . . . 882
  - Ileo-cæcal Valve . . . 882
- Colon . . . 883
  - Ascending . . . 883
  - Transverse . . . 883
  - Descending . . . 883
  - Sigmoid Flexure . . . 885
- Rectum . . . 886
  - Upper Portion . . . 886
  - Middle Portion . . . 886
  - Lower Portion . . . 886
- Structure of Large Intestine . . . 886
- Serous and Muscular Coats . . . 887
- Circular and Mucous Coats . . . 887
- Epithelium, Simple Follicles . . . 888
- Solitary Glands . . . 888

LIVER.

- Size, Weight, Position of . . . 889
- Its Surfaces and Borders . . . 889
- Changes of Position . . . 889
- Ligaments:
  - Longitudinal . . . 889
  - Lateral . . . 890
  - Coronary . . . 890
  - Round Ligament . . . 891
- Fissures:
  - Longitudinal . . . 891
  - Fissure of Ductus Venosus . . . 891
  - Portal Fissure . . . 891
  - Fissures for Gall-bladder and Vena Cava. 891
- Lobes:
  - Right . . . 891
  - Left . . . 892
  - Quadratus, Spigelii . . . 892
  - Caudatus . . . 892
- Vessels of Liver . . . 892
- Nerves of Liver . . . 892
- Structure of Liver . . . 892
- Serous Coat, Fibrous Coat . . . 892
- Lobules . . . 893
- Hepatic Cells . . . 893
- Hepatic Artery . . . 894
- Portal Vein . . . 894
- Hepatic Veins . . . 894
- Biliary Ducts . . . 895

GALL-BLADDER.

- Structure . . . 896
  - Biliary Ducts . . . 896
  - Hepatic Duct . . . 896
  - Common Choledic and Cystic Ducts . . . 896
  - Structure of Biliary Ducts . . . 897

PANCREAS.

- Dissection . . . 897
- Relations . . . 897
- Duct . . . 898
- Structure . . . 898
- Vessels and Nerves . . . 899

SPLEEN.

- Relations . . . 899
- Size and Weight . . . 899
- Structure of Serous and Fibrous Coats . . . 900
- Proper Substance . . . 900
- Splenic Artery, distribution . . . 901
- Malpighian Corpuscles . . . 902
- Capillaries of Spleen . . . 902
- Veins of Spleen . . . 903
- Lymphatics and Nerves . . . 903

Thorax.

PAGE
Boundaries of 904
Superior Opening, Base 904
Parts passing through Upper Opening 904

PERICARDIUM.

Structure 904
Fibrous Layer 905
Serous Layer 905

HEART.

Position, Size 906
Subdivision into Four Cavities 907
Circulation of Blood in Adult 907
Auriculo-ventricular and Ventricular Grooves. 907

Right Auricle.

Openings 908
Valves 908
Relics of Fœtal Structure 909
Musculi Pectinati 909

Right Ventricle.

Openings 909
Tricuspid Valve 909
Chordæ Tendineæ and Columnæ Carneæ . .
Semilunar . . . .

Left Auricle.

Sinus, Appendix . . . .
Openings, Musculi Pectinati . . . .

Left Ventricle.

Openings . . . .
Mitral and Semilunar Valves . . . .
Endocardium . . . .

Structure of Heart.

Fibrous Rings . . . .
Muscular Structure . . . .
" " of Auricles . . . .
" " of Ventricles . . . . . .
Vessels and Nerves of Heart . . . .
Peculiarities in Vascular System of Fœtus .
Foramen Ovale, Eustachian Valve . . . . .
Ductus Arteriosus . . . .
Umbilical or Hypogastric Arteries . . . .
Fœtal Circulation . . . .
Changes in Vascular System at Birth . . .

Organs of Voice and Respiration.

THE LARYNX.

Cartilages of the Larynx 919
Thyroid Cartilage 919
Cricoid 920
Arytenoid Cartilages 920
Cartilages of Santorini and Wrisberg . . 921
Epiglottis 921
Ligaments of the Larynx 921
Ligaments connecting the Thyroid Cartilage with the Os Hyoides 921
Ligaments connecting the Thyroid Cartilage with the Cricoid 922
Ligaments connecting the Arytenoid Cartilages to the Cricoid 922
Ligaments of the Epiglottis 922
Superior Aperture of the Larynx 922
Cavity of the Larynx 923
Glottis 923
False Vocal Chords 923
True Vocal Chords 924
Ventricle of Larynx, Sacculus Laryngis . . 924
Muscles of Larynx 924
Crico-thyroid 924
Crico-arytænoideus posticus 924
" " lateralis 925
Arytænoideus 925
Thyro-arytænoideus 925
Muscles of the Epiglottis 926
Thyro-epiglottideus 926
Arytæno-epiglottideus, superior 926
" " inferior 926
Actions of Muscles of Larynx 926
Mucous Membrane of Larynx 927
Glands, Vessels, and Nerves of Larynx . . . 927

TRACHEA.

Relations 927
Bronchi 927
Structure of Trachea . . . .
Surgical Anatomy of Laryngo-tracheal Region . . . .

THE PLEURÆ.

Reflections . . . .
Vessels and Nerves . . . .

MEDIASTINA.

Superior Mediastinum . . . .
Anterior Mediastinum . . . .
Middle Mediastinum . . . .
Posterior Mediastinum . . . .

THE LUNGS.

Surfaces . . . .
Borders and Lobes . . . .
Root of Lung . . . .
Weight, Color, and Properties of Substance of Lung . . . .
Structure of Lung . . . .
Serous Coat and Subserous Areolar Tissue . .
Parenchyma and Lobules of Lung . . . . .
Bronchi, Arrangement of, in Substance of Lung . . . .
Structure of Smaller Bronchial Tubes . . . .
The Air-cells . . . .
Pulmonary Artery . . . .
Pulmonary Capillaries and Veins . . . . . .
Bronchial Arteries and Veins . . . .
Lymphatics and Nerves of Lung . . . . . .

THYROID GLAND.

Structure . . . .
Vessels and Nerves . . . .

THYMUS GLAND.

Structure . . . .
Vessels and Nerves . . . .

The Urinary Organs.

KIDNEYS.

Relations 944
Dimensions, Weight 945
General Structure 945
Cortical Substance 946
Medullary Substance 946
Minute Structure 946
Malpighian Bodies . . . .
" Tufts . . . .
" Capsule . . . .
Tubuli Uriniferi, Course . . . .
" " Structure . . . .
Renal Blood-vessels . . . .
" Veins . . . .

PAGE
Venæ Rectæ . . . 951
Lymphatics and Nerves . . . 951

URETERS.

Situation, Calices . . . 952
Course, Relations, Structure . . . 952

SUPRARENAL CAPSULES.

Relations, Structure . . . 953
Vessels . . . 954
Nerves . . . 955

THE PELVIS.

Boundaries, Contents . . . 955

Bladder.

Shape, Position, Relations . . . 955
Urachus . . . 955
Subdivisions . . . 956
Ligaments . . . 957
Structure . . . 957
Interior of Bladder . . . 958
Vessels and Nerves . . . 959

Male Urethra.

Divisions . . . 959
Structure . . . 960

Male Generative Organs.

PROSTATE GLANDS.

Position, Size, and Weight . . . 962
Structure . . . 963
Vessels and Nerves . . . 963
Cowper's Glands . . . 963

PENIS.

Root . . . 964
Glans Penis . . . 964
Body . . . 964
Corpora Cavernosa . . . 964
Erectile Tissue . . . 965
Arteries of the Penis . . . 965
Corpus Spongiosum . . . 966
The Bulb . . . 966
Structure of Corpus Spongiosum . . . 966
Lymphatics of the Penis . . . 966
Nerves of the Penis . . . 966

THE TESTES AND THEIR COVERINGS.

Scrotum . . . 967
Other Coverings of the Testis . . . 967
Vessels and Nerves of the Coverings of the Testis . . . 968

Spermatic Cord.

Its Composition . . . 968
Relations of, in Inguinal Canal . . . 968
Arteries of the Cord . . . 968
Veins of the Cord . . . 968
Lymphatics and Nerves of the Cord . . . 969

TESTES.

Form and Situation . . . 969
Size and Weight . . . 969
Coverings . . . 969
  Tunica Vaginalis . . . 969
  Tunica Albuginea . . . 970
  Mediastinum Testis . . . 970
  Tunica Vasculosa . . . 970
Structure of the Testis . . . 970
Lobules of the Testis . . . 970
Tubuli Seminiferi . . . 970
Arrangement in Lobuli . . . 970
  " in Mediastinum Testis . . . 970
  " in Epididymis . . . 971
Vas Aberrans . . . 971
Vas Deferens, Course, Relations . . . 972
  Structure . . . 972
Vesiculæ Seminales . . . 972
  Form and Size . . . 972
  Relations . . . 973
  Structure . . . 973
Ejaculatory Ducts . . . 973
The Semen . . . 973

DESCENT OF THE TESTES.

Gubernaculum Testis . . . 974
Canal of Nuck . . . 975

Female Organs of Generation.

Mons Veneris, Labia Majora, Labia Minora . . . 976
Clitoris, Meatus Urinarius . . . 977
Hymen . . . 977
Glands of Bartholine . . . 978
Female Bladder . . . 978
  " Urethra . . . 978
  " Rectum . . . 979

Vagina.

Relations . . . 979
Structure . . . 979

Uterus.

Situation, Form, Dimensions . . . 980
Fundus, Body, and Cervix . . . 981
Ligaments . . . 981
Cavity of the Uterus . . . 981
Structure . . . 981
Vessels and Nerves . . . 983
Its Form, Size, and Situation . . . 983
  " in the Fœtus . . . 983
Its Form at Puberty . . . 983
  " during and after Menstruation . . . 983
  " during Pregnancy . . . 983
  " after Parturition . . . 983
  " in Old Age . . . 983

Appendages of the Uterus.

Fallopian Tubes . . . 984
  Structure . . . 984
Ovaries . . . 984
  Structure . . . 985
  Graafian Vesicles . . . 986
Discharge of the Ovum . . . 987
Corpus Luteum . . . 987
Ligament of the Ovary . . . 988
Round Ligaments . . . 988
Vessels and Nerves of Appendages . . . 988

Mammary Glands.

Situation and Size, Nipple . . . 988
Structure of Mamma . . . 989
Vessels and Nerves . . . 989

Surgical Anatomy of Inguinal Hernia.

COVERINGS OF INGUINAL HERNIA.

Dissection . . . 991
Superficial Fascia . . . 991
Superficial Vessels and Nerves . . . 991
Deep Layer of Superficial Fascia . . . 991
Aponeurosis of External Oblique . . . 992

PAGE
External Abdominal Ring 993
Pillars of the Ring 993
Intercolumnar Fibres 993
" Fascia 993
Poupart's Ligament 994
Gimbernat's Ligament 994
Triangular Ligament 994
Internal Oblique Muscle 994
Cremaster 994
Transversalis Muscle 995
Spermatic Canal 996
Fascia Transversalis 996
Internal Abdominal Ring 996
Subserous Areolar Tissue 996
Epigastric Artery 996
Peritoneum 996

[*General Remarks upon Hernia.*

Openings of Herniæ 997
Peculiar Coverings of Herniæ 997]

INGUINAL HERNIA.

Oblique Inguinal Hernia 998
Course and Coverings of Oblique Hernia 998
Seat of Stricture 998
Scrotal Hernia 998
Bubonocele 998
Congenital Hernia 999
Infantile Hernia 999

DIRECT INGUINAL HERNIA.

Course and Coverings of the Hernia 999
PAGE
Seat of Stricture 999
Incomplete Direct Hernia 1000
Comparative Frequency of Oblique and Direct Hernia 1000
Diagnosis of Oblique and Direct Hernia 1000

SURGICAL ANATOMY OF FEMORAL HERNIA.

Dissection 1000
Superficial Fascia 1000
Cutaneous Vessels 1000
Internal Saphenous Vein 1000
Superficial Sympathetic Glands 1001
Cutaneous Nerves 1001
Deep Layer of Superficial Fascia 1001
Cribriform Fascia 1001
Fascia Lata 1001
  Iliac Portion 1001
  Pubic Portion 1002
Saphenous Opening 1003
Femoral Arch 1003
Gimbernat's Ligament 1003
Femoral Sheath 1003
Deep Femoral Arch 1005
Femoral Canal 1006
Femoral or Crural Ring 1007
Position of Parts around the Ring 1007
Septum Crurale [or Femorale] 1007
Descent of Femoral Hernia 1008
Coverings of Femoral Hernia 1008
Varieties of Femoral Hernia 1008
Seat of Stricture 1009

Surgical Anatomy of Perineum and Ischio-rectal Region.

Ischio-rectal Region.

Dissection 1010
Boundaries 1010
Superficial Fascia 1011
Corrugator Cutis Ani 1011
External Sphincter 1011
Internal Sphincter 1011
Ischio-rectal Fossa 1011
Position of Parts contained in 1012

Perineum.

Boundaries and Extent 1012
Superficial Layer of Superficial Fascia 1013
Deep Layer of Superficial Fascia 1013
Course taken by the Urine in Rupture of the Urethra 1014
Muscles of the Perineum (Male):
  Accelerator Urinæ 1014
  Erector Penis 1014
  Transversus Perinæi 1014
Muscles of the Perineum (Female):
  Sphincter Vaginæ 1015
  Erector Clitoridis 1015
  Transversus Perinæi 1015
Deep Perineal Fascia 1015
  Anterior Layer 1016
  Posterior Layer 1016
Parts between the Two Layers 1017
Compressor Urethræ 1017
Cowper's Glands 1017
Pudic Vessels and Nerves 1017
Artery of the Bulb 1017
Levator Ani 1017
  Relations, Actions 1018
Coccygeus 1018
  Relations, Actions 1019
Position of Viscera at Outlet of Pelvis 1019
Prostate Gland 1019
Parts concerned in the Operation of Lithotomy 1019
Parts Divided in the Operation 1021
Parts to be Avoided in the Operation 1021
Abnormal Course of Arteries in the Perineum 1021

Pelvic Fascia.

Obturator Fascia 1022
Recto-vesical Fascia 1022

SURGICAL ANATOMY OF THE TRIANGLES OF THE NECK 525
SURGICAL ANATOMY OF THE AXILLA 553
SURGICAL ANATOMY OF THE BEND OF ELBOW 559
SURGICAL ANATOMY OF SCARPA'S TRIANGLE 594
SURGICAL ANATOMY OF THE POPLITEAL SPACE 600
SURGICAL ANATOMY OF THE LARYNGO-TRACHEAL REGION 930

LANDMARKS, MEDICAL AND SURGICAL.

PAGE

THE HEAD.

Scalp: its Density—Arteries of Scalp—Skull-cap—Anterior Fontanelle—Frontal Sinuses—Mastoid Process—Occipital Protuberance—Posterior Inferior Angle of the Parietal Bone—Lines of Cerebral Sinuses—Middle Meningeal Artery—Thickness of Skull-cap—Levels of the Brain—Ear—Cerebral Localization and Topography . 1026, 1027

THE FACE.

Foramina for Branches of Fifth Nerve—Pulley for Superior Oblique Muscle—Lower Jaw—Zygoma—Seventh Nerve—Parotid Duct—Temporal and Facial Arteries—Eyelids and Eyes—Puncta Lachrymalia—Lachrymal Sac—Nasal Duct—Nose and Nasal Cavities—Lips—Mouth—Teeth—Throat—Antrum—Posterior Nares—Tonsils—Features 1027-1031

THE NECK.

Skin—Subcutaneous Veins—Parts in Central Line—Os Hyoides—Thyroid Cartilage—Cricoid Cartilage—Trachea—Sterno-mastoid Muscle—Sterno-clavicular Joint—Apex of Lung in the Neck—Supraclavicular Fossa—Subclavian Artery—Phrenic Nerve 1031-1034

THE CHEST.

Peculiarities in the Female—Parts behind First Bone of Sternum—Rules for Counting the Ribs—Interval below Clavicle—Internal Mammary Artery—Outline of Heart on Chest-wall—Apex of the Heart—Valves of the Heart—Where to Auscult the Valves of the Heart—Outline of the Lungs—Anterior Mediastinum—Reflection of Pleura 1034-1037

THE BACK.

Median Furrow—Spines of Vertebræ—Division of the Trachea—Origins of the Spinal Nerves—Movements of the Spine—Position and Motions of Scapula . . . 1037-1040

THE ABDOMEN.

Abdominal Lines—Umbilicus—Parts behind the Linea Alba—Peritoneum—Division of the Aorta—Bony Prominences—Spine of the Ilium—Spines of the Pubes—Poupart's Ligament, or Crural Arch—Abdominal Rings—Inguinal Canal—Spermatic Cord—Epigastric Artery—Abdominal Viscera—Liver—Gall-bladder—Stomach—Pylorus—Spleen—Pancreas—Kidney—Large Intestine—Colotomy—Small Intestine—Bladder 1041-1046

THE PERINEUM.

Bony Framework—Raphé—Central Point of the Perineum—Triangular Ligament—Anus—Landmarks in the Rectum—Urethra—Prostate Gland—Direction of the Anus and that of the Rectum—Introduction of Catheters—Urethra in the Child . 1046-1048

THE THIGH.

Poupart's Ligament, or Crural Arch—Furrow at the Bend of the Thigh—Saphenous Opening—Femoral Ring—Lymphatic Glands in the Groin—Trochanter Major—Nélaton's Line—Spine of the Ilium—Compression of Femoral Artery—Sartorius—Line of Femoral Artery . . 1048-1050

THE BUTTOCKS.

Bony Landmarks—Fold of the Buttock—Gluteal Artery—Pudic Artery 1050, 1051

THE KNEE.

Bony Points—Ligamentum Patellæ—Prepatellar Bursa—Synovial Membrane of Knee—Popliteal Tendons—Popliteal Bursa—Popliteal Artery—Peroneal Nerve . 1051-1053

THE LEG AND ANKLE.

Bony Points—Malleoli—Tendo Achillis—Tendons behind the Inner Ankle—Tendons behind the Outer Ankle—Tendons in Front of the Ankle—Popliteal Artery—Anterior Tibial Artery—Posterior Tibial Artery—Saphena Veins 1053-1055

THE FOOT.

Points of Bone—Lines of Joints—Dorsal Artery—Bursa—Plantar Arteries—Plantar Fascia 1055-1056

THE ARM.

Clavicle—Bony Points of the Shoulder—Tuberosities—Coraco-acromial Ligament—Axilla—Axillary Artery—Brachial Artery—Bend of Elbow—Cutaneous Veins—Landmarks of Elbow—Olecranon—Relations of the Olecranon and Condyles—Bursæ—Interosseous Arteries—Lymphatic Gland 1056-1059

THE FOREARM AND WRIST.

Ulna—Radius—Carpus—Pulse—Great Carpal Bursa—"Tabatière anatomique"—Tendons on the Back of the Wrist—Lines of Arteries 1059-1061

THE HAND.

Furrow in Palm—Interdigital Folds—Digital Furrows—Palmar Arterial Arches—Digital Arteries—Metacarpal Joint of Thumb—Sesamoid Bones—Subcutaneous Veins—Interosseous Arteries—Digital Bursæ—Knuckles and Digital Joints . . 1061, 1062

PALPATION BY THE RECTUM 1062

EXAMINATION PER VAGINAM 1063

INDEX 1065

LIST OF ILLUSTRATIONS.

The illustrations, when copied from any other work, have the author's name affixed. When no such acknowledgment is made the drawing is to be considered original.

General Anatomy.

FIG.			PAGE
1.	Human Blood-corpuscles	*Kölliker.*	36
2.	Blood-corpuscles	*Harley.*	37
3.	Changes in Shape of Colorless Corpuscles	*Kirkes.*	37
[4.	Isolated Plaques in Normal Blood	*Osler.*]	38
5.	Blood-crystals	*Harley.*	39
6.	Chyle from the Lymphatics	*do.*	40
7.	Pavement Epithelium	*do.*	43
8.	Columnar Epithelium	*Kölliker.*	43
9.	Goblet-cells	*Klein and Noble Smith.*	43
10.	Spheroidal Epithelium	*Harley.*	44
11.	Ciliated Epithelium	*Kölliker.*	44
12.	Endothelium, with Stomata	*Klein.*	44
13.	White Fibrous Tissue	*Harley.*	45
14.	Connective Tissue	*Klein and Noble Smith.*	46
15.	Tendon-cell	*Schäfer.*	46
16.	Yellow Elastic Tissue	*Harley.*	47
17.	Connective-tissue Corpuscles	*Klein and Noble Smith.*	47
18.	Retiform Connective Tissue		48
19.	Adipose Tissue	*Harley.*	49
20.	Development of Fat	*Klein and Noble Smith.*	49
21.	Pigment-cells of Retina		50
22.	Human Cartilage-cells	*Kölliker.*	51
23.	Costal Cartilage in Old Age	*Harley.*	52
24.	Fibro-cartilage	*do.*	52
25.	Yellow Cartilage	*do.*	53
26.	Transverse Section of Bone	*Kölliker.*	56
27.	Transverse Section of Bone	*Sharpey.*	56
28.	Nucleated Bone-cells	*Klein and Noble Smith.*	57
29.	Longitudinal Section of Bone	*Kölliker.*	57
[30.	Fibula after Maceration in Acetic Acid	*Dalton.*]	58
31.	Section of Bone after Removal of Earthy Portion	*Harley.*	58
32.	Ossification of Fœtal Cartilage	*Rollett.*	59
33.	Ossification of Limb-bone of Cat	*Schäfer.*	60
34.	Ossification of Limb-bone of Rabbit	*Klein and Noble Smith.*	60
35.	Transverse Section of Fœtal Femur	*Frey.*	61
36.	Ossification of Fœtal Cartilage	*do.*	61
37.	Intramembranous Ossification	*do.*	63
38.	Transverse Section of Muscle	*Kölliker.*	64
39.	Human Muscular Fibre	*do.*	65
40.	Structure of Muscular Fibre	*Todd and Bowman.*	65
41.	Structure of Muscular Fibre	*Quain.*	66
42.	Krause's Membrane	*Klein and Noble Smith.*	66
43.	Muscular Fibres of the Heart	*Schweigger-Seidel.*	67
44.	Non-striated Muscular Fibre	*Harley.*	68
45	Muscular Fibre-cells	*Kölliker.*	68
46.	Nerve-vesicles from Gasserian Ganglion	*Todd and Bowman.*	69
47.	Nerve-vesicles from Brain	*Harley.*	69
48.	Human Nerve-tubes	*Kölliker.*	70
[49.	Diagram of Structure of Medullated Nerve-fibre	*From Allen.*]	70
[50.	Nerve-fibre from the Sciatic Nerve of the Rabbit	*do.*]	70
51.	Nerve-tubes of Eel	*Todd and Bowman.*	71
52.	Nervous Branch from Sympathetic	*Frey.*	71
53.	Section of Nerve	*Klein and Noble Smith.*	73
54.	Tactile Corpuscles	*Kölliker.*	76
55	Pacinian Corpuscles	*Todd and Bowman.*	76
56.	Motorial End-plates	*Kühne.*	77
57.	Section through a Microscopic Ganglion	*Klein and Noble Smith.*	78
58.	Section of Artery and Vein	*do.*	79

FIG.
59. Longitudinal Section of Artery and Vein . . . *Kölliker.*
[60. Section of Injected Lung . . . *E. A. Schäfer.*]
[61. Longitudinal Section of Bone . . . *Kölliker.*]
[62. Small Artery, showing Structure of its Walls . . . *Landois.*]
63. Capillary Vessels . . . *Frey.*
64. Capillary Vessels . . . *Kölliker.*
65. Section of Thoracic Duct . . . *do.*
66. Stomata of Serous Membrane . . . *Frey.*
[67. Origin of Lymphatics from Central Tendon of Diaphragm of the Rabbit . . . *Landois.*]
[68. Perivascular Lymphatics . . . *do.*]
69. Section of Lymphatic Gland . . . *Frey.*
70. Follicle from Lymphatic Gland . . . *do.*
71. Medullary Structure from Lymphatic Gland . . . *do.*
72. Minute Structure of Lymphatic Gland . . .
73. Sectional View of the Skin and its Appendages . . . *Kölliker.*
74. Section of Skin . . .
[75. Epidermis detached from Derma . . . *Hirschfeld and Leveillé.*]
76. Transverse Section of Hair-follicle . . . *Beisiadecki.*
77. Varieties of Secreting Glands . . .
78. Ovum of Sow . . . *M. Barry.*
79. Human Ovum . . . *Kölliker.*
80. Fertilization of Ovum . . . *Selenka.*
81. Diagram of the Division of the Yolk . . . *Kölliker.*
82. Vitelline Spheres . . . *Van Beneden.*
[83. Rabbit's Ovum after Impregnation . . . *Foster and Balfour.*]
84. Section of Blastoderm . . . *do.*
85. Diagrams of the Development of the Three Layers of the Blastodermic Membrane, transverse sections . . . *Beaunis and Bouchard.*
86. Similar Diagrams, antero-posterior sections . . . *do.*
87. Embryonic Area of Rabbit . . . *Kölliker.*
88. Transverse Section through Embryo Chick . . . *Foster and Balfour.*
89. Diagrammatic Section through Ovum . . . *Quain.*
90. Transverse Diagrammatic Section . . .
91. Human Embryo of Four Weeks . . . *Quain.*
[92. Diagrammatic Section of Human Uterus, Embryo *in situ* . . . *Longet.*]
93. Transverse Section through Embryo Chick . . . *Foster and Balfour.*
94. Primitive Vertebral Column of Embryo . . . *Kölliker.*
95. Longitudinal Section of Head of Embryo . . . *do.*
96. Vertical Section of Head of Embryo . . . *Mihalkovics.*
97. Face of an Embryo . . . *Coste.*
98. Section of the Medulla . . . *Kölliker.*
99. Diagram of Development of Lens . . . *Remak.*
100. Diagrammatic Section through Fœtal Eyeball . . . *Quain.*
101. Development of Blood-vessels . . . *Klein.*
102. Heart of Embryo, Fifth Week . . . *Baer.*
103. Diagram of Formation of Aortic Arches and Large Arteries . . . *Kölliker.*
104. Primitive Veins . . . *Dalton.*
105. Diagram of the Formation of the Main Systemic Veins . . . *Kölliker.*
106. Development of Alimentary Canal . . . *Thompson.*
107. Early Form of Alimentary Canal . . . *Kölliker.*
108. Wolffian Body in the Asexual Stage of Embryo . . . *Farre.*
109. Diagram of Primitive Urogenital Organs . . . *Quain.*
110. Adult Ovary, Parovarium, and Fallopian Tube . . . *Farre.*
111. Female Genital Organs of Embryo . . . *Alfred T. Muller.*
112. Development of External Genital Organs . . . *Ecker.*

Osteology.

113. A Cervical Vertebra . . .
114. Atlas . . .
115. Axis . . .
116. Seventh Cervical Vertebra . . .
117. A Dorsal Vertebra . . .
118. Peculiar Dorsal Vertebra . . .
119. Lumbar Vertebra . . .
120-122. Development of a Vertebra . . . *Quain.*
123. Atlas . . . *do.*
124. Axis . . . *do.*
125. Lumbar Vertebra . . . *do.*
126. Sacrum, anterior surface . . .
127. Vertical Section of the Sacrum . . .
128. Sacrum, posterior surface . . .
129-131. Development of Sacrum . . . *Quain.*
132. Coccyx, anterior and posterior surfaces . . .
133. Lateral View of Spine . . .
134. Occipital Bone, outer surface . . .
135. Occipital Bone, inner surface . . .
136. Occipital Bone, development of . . . *Quain.*
137. Parietal Bone, external surface . . .
138. Parietal Bone, internal surface . . .

FIG. PAGE
139. Frontal Bone, outer surface . . . 167
140. Frontal Bone, inner surface . . . 168
141. Frontal Bone at Birth . . . 169
142. Temporal Bone, outer surface . . . 170
[143. Section through Mastoid Cells . . . *W. W. Keen.*] 172
144. Temporal Bone, inner surface . . . 172
145. Temporal Bone, petrous portion . . . 173
146. Temporal Bone, development of . . . *Quain.* 175
147. Sphenoid Bone, superior surface . . . 176
148. Sphenoid Bone, anterior surface . . . 177
149. Sphenoid Bone, posterior surface . . . 179
150. Plan of the Development of Sphenoid . . . 180
151. Ethmoid Bone, outer surface . . . 181
152. Perpendicular Plate of Ethmoid, enlarged . . . 182
153. Ethmoid Bone, inner surface of right lateral mass, enlarged . . . 183
154. Skull at Birth, showing the anterior and posterior fontanelles . . . 184
155. Lateral Fontanelles . . . 184
156. Nasal Bone, outer surface . . . 185
157. Nasal Bone, inner surface . . . 185
158. Superior Maxillary Bone, outer surface . . . 186
159. Superior Maxillary Bone, inner surface . . . 188
160. Under Surface of Hard Palate . . . 190
161. Development of Superior Maxillary Bone . . . *Quain.* 190
162. Lachrymal Bone, outer surface . . . 191
163. Malar Bone, outer surface . . . 192
164. Malar Bone, inner surface . . . 192
165. Palate Bone, internal view, enlarged . . . 194
166. Palate Bone, posterior view, enlarged . . . 194
167. Inferior Turbinated Bone, inner surface . . . 196
168. Inferior Turbinated Bone, outer surface . . . 196
169. Vomer . . . 197
170. Lower Jaw, outer surface . . . 198
171. Lower Jaw, inner surface . . . 198
172. Side View of the Lower Jaw at Birth . . . 201
173. Side View of the Lower Jaw at Puberty . . . 201
174. Side View of the Lower Jaw in the Adult . . . 201
175. Side View of the Lower Jaw in Old Age . . . 201
[176. Absorption of Alveolar Processes . . . *M. H. Cryer.*] 202
177. Base of Skull, inner surface . . . 205
178. Base of Skull, outer surface . . . 209
179. Side View of the Skull . . . 211
180. Anterior Region of Skull . . . 214
181. Nasal Fossæ, outer wall . . . 216
182. Nasal Fossæ, inner wall or septum . . . 217
[183. Transverse Vertical Section of Nasal Fossæ . . . *Hirschfeld and Leveillé.*] 218
[184. Naso-pharynx, viewed from behind . . . *Zaufal.*] 218
185. Hyoid Bone, anterior surface . . . 219
186. Sternum and Costal Cartilages, anterior surface . . . 221
187. Sternum, posterior surface . . . 221
188-191. Development of Sternum . . . *Quain.* 223
192. A Rib . . . 224
193. Vertebral Extremity of a Rib . . . 225
194-198. Peculiar Ribs . . . 227
199. Left Clavicle, anterior surface . . . 231
200. Left Clavicle, inferior surface . . . 231
201. Left Scapula, anterior surface, or venter . . . 232
202. Left Scapula, posterior surface, or dorsum . . . 234
203. Plan of the Development of the Scapula . . . 236
204. Left Humerus, anterior surface . . . 239
205. Left Humerus, posterior surface . . . 240
206. Plan of the Development of the Humerus . . . 242
[207. Angles at Elbows and Knees . . . *W. W. Keen.*] 242
208. Bones of the Left Forearm, anterior surface . . . 244
209. Bones of the Left Forearm, posterior surface . . . 246
210. Plan of the Development of the Ulna . . . 247
211. Plan of the Development of the Radius . . . 249
212. Bones of the Left Hand, dorsal surface . . . 251
213. Bones of the Left Hand, palmar surface . . . 253
214. Plan of the Development of the Hand . . . 258
[215. Shoulder Girdle . . . *Henle.*] 259
[216. Pelvic Girdle . . . *do.*] 259
217. Os Innominatum, external surface . . . 260
218. Os Innominatum, internal surface . . . 262
219. Plan of the Development of the Os Innominatum . . . 266
220. Male Pelvis (adult) . . . 267
221. Female Pelvis (adult) . . . 268
222. Vertical Section of the Pelvis, with lines indicating the axes of the pelvis . . . 269
223. Right Femur, anterior surface . . . 272
224. Right Femur, posterior surface . . . 273
225. Diagram showing the Structure of the Neck of the Femur . . . *Ward.* 275
226. Plan of the Development of the Femur . . . 276
227. Right Patella, anterior surface . . . 277

FIG. PAG
228. Right Patella, posterior surface 27
229. Tibia and Fibula, anterior surface 27
230. Tibia and Fibula, posterior surface 27
231. Plan of the Development of the Tibia 28
232. Plan of the Development of the Fibula 28
233. Bones of the Right Foot, dorsal surface 28
234. Bones of the Right Foot, plantar surface 28
235. Plan of the Development of the Foot 28

Articulations.

236. Vertical Section of Two Vertebræ and their Ligaments, front view 30
237. Occipito-atloid and Atlo-axoid Ligaments, front view 30
238. Occipito-atloid and Atlo-axoid Ligaments, posterior view 30
239. Articulation between Odontoid Process and Atlas *Arnold.* 30
240. Occipito-axoid and Atlo-axoid Ligaments 30
241. Temporo-maxillary Articulation, external view 31
242. Temporo-maxillary Articulation, internal view 31
243. Temporo-maxillary Articulation, vertical section 31
244. Costo-vertebral and Costo-transverse Articulations, anterior view 31
245. Costo-transverse Articulation *Arnold.* 31
246. Chondro-sternal, Chondro-xiphoid, and Interchondral Articulations, anterior view 31
247. Articulations of Pelvis and Hip, anterior view 31
248. Articulations of Pelvis and Hip, posterior view 31
249. Vertical Section of the Symphysis Pubis 32
250. Sterno-clavicular Articulation 32
251. Shoulder-joint, Scapulo-clavicular Articulations, and proper Ligaments of Scapula 32
[252. Vertical Section through Shoulder-joint, arm vertical *Henle.*] 32
[253. Vertical Section through Shoulder-joint, arm horizontal *do.*] 32
254. Left Elbow-joint, showing anterior and internal ligaments 33
255. Left Elbow-joint, showing posterior and external ligaments 331
[256. Section through Elbow-joint, in Extension *Henle.*] 331
[257. Section through Elbow-joint, in Flexion *do.*] 331
258. Ligaments of Wrist and Hand, anterior view *Arnold.* 33
259. Ligaments of Wrist and Hand, posterior view *do.* 33
260. Vertical Section of Wrist, showing the synovial membranes 33
[261. Relations of Knuckles and Webs of Fingers *W. W. Keen.*] 34
262. Articulations of the Phalanges 341
263. Left Hip-joint, laid open 34
[264. Hip-joint, showing Y-ligament *Bigelow.*] 34
265. Hip-joint, laid open from the pelvis to show the ligamentum teres put on the stretch by rotation of the femur outward 34
266. Hip-joint, laid open from the pelvis to show the ligamentum teres put on the stretch by adduction of the femur in the flexed position 34
267. Muscles in Relation with Hip *Barton.* 34
[268. Vertical Section through Hip-joint *Henle.*] 34
269. Right Knee-joint, anterior view 34
270. Right Knee-joint, posterior view 34
271. Right Knee-joint, showing internal ligaments 34
272. Head of Tibia, with semilunar cartilages, seen from above 34
[273. Sagittal Section of Knee-joint *Volz.*] 35
274. Ankle-joint: Tarsal and Tarso-metatarsal Articulations, internal view 35
275. Ankle-joint: Tarsal and Tarso-metatarsal Articulations, external view 35
[276. Coronal Section of Ankle and Foot *Volz.*] 35
[277. Sagittal Section of Ankle and Foot *do.*] 35
278. Ligaments of Plantar Surface of the Foot 35
279. Synovial Membranes of the Tarsus and Metatarsus *Arnold.* 361

Muscles and Fasciæ.

[280. Arrangement of Muscular Fibres in Muscles *Beaunis and Bouchard.*] 36
281. Plan of Dissection of the Head, Face, and Neck 367
282. Muscles of the Head, Face, and Neck 36
[283. Typical Wrinkles in Forehead *W. W. Keen.*] 36
[284. Frontal and Ocular Muscles *Henle.*] 370
285. Muscles of the Right Orbit 372
286. The Relative Position and Attachment of the Muscles of the Left Eyeball 372
287. The Temporal Muscle 379
288. The Pterygoid Muscles 380
289. Cervical Fascia 383
290. Muscles of the Neck and Boundaries of the Triangles 384
291. Muscles of the Neck, anterior view *Quain.* 387
292. Muscles of the Tongue, left side 390
293. Superficial Lingualis and Intrinsic Vertical Fibres of the Tongue 391
294. Relative Positions of Intrinsic and Extrinsic Muscles of the Tongue 391
295. Muscles of the Pharynx, external view 393
296. Muscles of the Soft Palate 395
297. The Prevertebral Muscles *Quain.* 397
298. Plan of Dissection of the Muscles of the Back 400
[299. Ligamentum Nuchæ *Henle.*] 401

FIG. PAGE
300. Muscles of the Back, first, second, and part of the third layer . . . *Quain.* 402
301. Muscles of the Back, deep layers . . . 407
302. Plan of Dissection of Abdomen . . . 412
303. The External Oblique Muscle . . . 413
304. The Internal Oblique Muscle . . . 415
305. The Transversalis, Rectus, and Pyramidalis . . . 416
306. Transverse Section of Abdomen in Lumbar Region . . . *Quain.* 417
307. The Diaphragm, under surface . . . 422
[308. Coronal Section of Trunk . . . *Henle.*] 423
[309. Sagittal Section of Trunk . . . *do.*] 423
310. Plan of Dissection of Upper Extremity . . . 426
311. Muscles of the Chest and Front of the Arm, superficial view . . . 428
312. Muscles of the Chest and Front of the Arm, with the boundaries of the axilla . . . 431
313. Muscles on the Dorsum of the Scapula and the Triceps . . . 434
[314. Section through Middle of Right Upper Arm . . . *Heath from Béraud.*] 437
315. Front of the Left Forearm, superficial muscles . . . 440
[316. Section through Middle of Right Forearm . . . *Heath from Béraud.*] 443
317. Front of the Left Forearm, deep muscles . . . 443
318. Posterior Surface of Forearm, superficial muscles . . . 445
319. Posterior Surface of Forearm, deep muscles . . . 448
320. Transverse Section through the Wrist, showing the annular ligaments and the canals for the passage of the tendons . . . 450
[321. Palmar Fascia, seen from above . . . *W. W. Keen.*] 451
[322. Palmar Fascia, seen from beneath . . . *do.*] 452
323. Muscles of the Left Hand, palmar surface . . . 453
[324. Adductor Interosseous Muscle of Ring Finger of Right Hand . . . *Duchenne.*] 456
325. Dorsal Interossei of Left Hand . . . 456
326. Palmar Interossei of Left Hand . . . 456
327. Fracture of the Middle of the Clavicle . . . *Hind.* 458
328. Fracture of the Surgical Neck of the Humerus . . . *do.* 458
329. Fracture of the Humerus above the Condyles . . . *do.* 459
330. Fracture of the Olecranon . . . *do.* 459
331. Fracture of Shaft of the Radius . . . *do.* 460
332. Fracture of the Lower End of the Radius . . . *do.* 460
333. Plan of Dissection of Lower Extremity, front view . . . 463
334. Muscles of the Iliac and Anterior Femoral Regions . . . 463
[335. Section of Right Thigh at Apex of Scarpa's Triangle . . . *Heath.*] 468
336. Muscles of the Internal Femoral Region . . . *Quain.* 471
337. Plan of Dissection of Lower Extremity, posterior view . . . 473
338. Muscles of the Hip and Thigh . . . 474
339. Muscles of the Front of the Leg . . . 480
[340. Section of Right Leg in Upper Third . . . *Heath from Béraud.*] 481
341. Muscles of the Back of the Leg, superficial layer . . . 482
342. Muscles of the Back of the Leg, deep layers . . . 484
343. Muscles of the Sole of the Foot, first layer . . . 490
344. Muscles of the Sole of the Foot, second layer . . . 491
345. Muscles of the Sole of the Foot, third layer . . . 492
346. Dorsal Interossei . . . 493
347. The Plantar Interossei . . . 493
348. Fracture of the Neck of the Femur within the Capsular Ligament . . . *Hind.* 494
349. Fracture of the Femur below the Trochanters . . . *do.* 494
350. Fracture of the Femur above the Condyles . . . *do.* 495
351. Fracture of the Patella . . . *do.* 495
352. Oblique Fracture of the Shaft of the Tibia . . . *do.* 496
353. Fracture of the Fibula, with Dislocation of the foot outward (Pott's fracture) . . . *do.* 496
[354. **Motor-points of Head and Neck** . . . *Ziemssen.*] 496
[355. **Motor-points of Trunk** . . . *do.*] 497
[356. **Motor-points of Upper Outer Part of Arm** . . . *do.*] 497
[357. **Motor-points of Upper Inner Part of Arm** . . . *do.*] 497
[358. **Motor-points of Inner Part of Lower Arm** . . . *do.*] 498
[359. **Motor-points of Outer Part of Lower Arm** . . . *do.*] 498
[360. **Motor-points of Anterior Part of Upper Leg** . . . *do.*] 499
[361. **Motor-points of Posterior Part of Upper Leg** . . . *do.*] 499
[362. **Motor-points of Outer Part of Lower Leg and Foot** . . . *do.*] 500
[363. **Motor-points of Inner Part of Lower Leg and Foot** . . . *do.*] 500

Arteries.

364. The Arch of the Aorta and its Branches . . . 503
365. Plan of the Branches of the Arch of the Aorta . . . 503
366. Surgical Anatomy of the Arteries of the Neck . . . 513
367. Plan of the Branches of the External Carotid . . . 513
368. The Arteries of the Face and Scalp . . . 517
369. The Internal Maxillary Artery and its Branches . . . 522
370. Plan of the Branches of the Internal Maxillary Artery . . . 522
[371. Diagram of Triangles of Right Side of Neck . . . *W. W. Keen.*] 525
372. The Internal Carotid and Vertebral Arteries . . . 529
373. The Ophthalmic Artery and its Branches . . . 531
374. The Arteries of the Base of the Brain . . . 533
[375. Diagram of Vessels at Base of Cerebrum . . . *Charcot.*] 535
[376. **Transverse Section of Cerebral Hemispheres, showing vessels** . . . *Duret.*] 535

Digitized

FIG. P
[377. Vascular Areas of Upper Surface of Cerebrum . . . . *Duret.*]
[378. Vascular Areas of Inner Surface of Right Hemisphere . . . . *Ecker and Duret.*]
[379. Vascular Areas of Outer Surface of Left Hemisphere . . . . *do. do.*]
[380. Area of Distribution of Middle Cerebral Artery . . . . . . *Charcot.*]
[381. Vascular Areas of Brain, from below . . . . . . *Ecker and Duret.*]
[382. Mode of Division of Cerebral Arteries . . . . . . *Duret.*]
[383. Distribution of Arteries to Gray and White Matter . . . . . . *do.*]
384. Plan of the Branches of the Right Subclavian Artery . . . . . .
[385. Distribution of Blood-vessels and Ganglion-cells in Spinal Cord . . . . *Young.*]
[386. Vascular Supply of Medulla Oblongata . . . . . . *Ross.*]
387. The Scapular and Circumflex Arteries . . . . . .
388. The Axillary Artery and its Branches . . . . . .
389. The Surgical Anatomy of the Brachial Artery . . . . . .
390. The Surgical Anatomy of the Radial and Ulnar Arteries . . . . . .
391. Ulnar and Radial Arteries, deep view . . . . . .
392. Arteries of the Back of the Forearm and Hand . . . . . .
393. The Abdominal Aorta and its Branches . . . . . .
[394. Diagram of Branches of Cœliac Axis . . . . . . *W. W. Keen.*]
395. The Cœliac Axis and its Branches, the liver having been raised and the lesser omentum removed . . . . . .
396. The Cœliac Axis and its Branches, the stomach having been raised and the transverse mesocolon removed . . . . . .
397. The Superior Mesenteric Artery and its Branches . . . . . .
[398. Diagram of Mesenteric Arteries . . . . . . *W. W. Keen.*]
399. The Inferior Mesenteric Artery and its Branches . . . . . .
400. Arteries of the Pelvis . . . . . .
401. Variations in Origin and Course of Obturator Artery . . . . . .
402. The Internal Pudic Artery and its Branches in the Male . . . . . .
403. The Arteries of the Gluteal and Posterior Femoral Regions . . . . . .
404. Surgical Anatomy of the Femoral Artery . . . . . .
405. The Popliteal, Posterior Tibial, and Peroneal Arteries . . . . . .
406. Surgical Anatomy of the Anterior Tibial and Dorsalis Pedis Arteries . . . . . .
[407. Relation of Parts behind Inner Malleolus . . . . . . *Hirschfeld and Leveillé.*]
408. The Plantar Arteries, superficial view . . . . . .
409. The Plantar Arteries, deep view . . . . . .

Veins.

410. Veins of the Head and Neck . . . . . .
411. Veins of the Diploë, as displayed by the removal of the outer table of the skull *Breschet.*
412. Vertical Section of the Skull, showing the sinuses of the dura mater . . . . . .
413. Plan showing Relation of Structures in Cavernous Sinus . . . . . .
414. The Sinuses at the Base of the Skull . . . . . .
415. Relation of Structure passing through the Jugular Foramen . . . . . .
416. The Superficial Veins of the Upper Extremity . . . . . .
417. The Venæ Cavæ and Azygos Veins, with their formative branches . . . . . .
418. Transverse Section of a Dorsal Vertebra, showing the spinal veins . . . . *Breschet.*
419. Vertical Section of Two Dorsal Vertebræ, showing the spinal veins . . . . *do.*
420. The Internal or Long Saphenous Vein and its Branches . . . . . .
421. The External or Short Saphenous Vein . . . . . .
422. The Portal Vein and its Branches . . . . . . *Quain.*

Lymphatics.

423. The Thoracic and Right Lymphatic Ducts . . . . . .
424. The Superficial Lymphatics and Glands of the Head, Face, and Neck . . . . *Mascagni.*
425. The Deep Lymphatics and Glands of the Neck and Thorax . . . . *do.*
426. The Superficial Lymphatics and Glands of the Upper Extremity . . . . *do.*
427. The Superficial Lymphatics and Glands of the Lower Extremity . . . . *do.*
428. The Deep Lymphatic Vessels and Glands of the Abdomen and Pelvis . . . . *do.* 6

Nervous System.

429. The Spinal Cord and its Membranes 6
430. Transverse Section of the Spinal Cord and its Membranes . . . . *Arnold.* 6
431. Spinal Cord, side view: plan of the fissures and columns . . . . *Quain.* 6
432. Transverse Sections of the Cord . . . . *Arnold.* 6
433. Transverse Section of the Spinal Cord . . . . *Klein and Noble Smith.* 6
434. Columns of the Cord 6
435. Transverse Section of Gray Matter of Cord . . . . *J. L. Clarke.* 6
436. Transverse Section of Gray Matter of Cord . . . . *do.* 6
437. Longitudinal Section of Cord . . . . *do.* 6
438. Transverse Section through the White Matter of the Cord . . . . *Klein and Noble Smith.* 6
439. Transverse Section through Spinal Canal . . . . *do. do.* 6
440. Medulla Oblongata and Pons Varolii, anterior surface 6
441. Posterior Surface of Medulla Oblongata 6
442. Transverse Section of Medulla Oblongata . . . . *Arnold.* 6
443. The Columns of the Medulla Oblongata and their Connection with the Cerebrum and Cerebellum . . . . *Altered from Arnold.* 6

FIG. PAGE
[444. Diagram of Gray Masses and Conducting Paths of Spinal Cord and Brain . . . *Flechsig.*] 670
445. Plan of the Course of the Fibres through the Medulla to the Brain . . . . . *H. E. Clark.* 671
446. Upper Surface of the Brain, the arachnoid having been removed 673
[447. View of Brain, from above . . . . *Ecker.*] 674
[448. Outer Surface of Left Hemisphere . . . . *do.*] 675
[449. View of Brain, from below . . . . *do.*] 677
[450. Inner Surface of Right Hemisphere . . . . *do.*] 678
[451. Head, showing Motor Regions of Brain . . . . *Horsley.*] 679
[452. Head, showing Motor Regions of Brain . . . . *do.*] 680
[453. Side View of Brain of Man, motor centres . . . . *Ferrier.*] 682
[454. Top View of Brain of Man, motor centres . . . . *do.*] 682
[455. Cerebral Centres for Movements of Upper Face and Angle of Mouth . . . . . . *Horsley.*] 683
[456. Cerebral Centres for Movements of Vocal Chords . . . . *do.*] 683
[457. Cerebral Centres for Movements of Lower Face and Floor of Mouth . . . . . . *do.*] 683
[458. Cerebral Centres for Movements of Shoulder . . . . *do.*] 683
[459. Cerebral Centres for Movements of Elbow and Wrist . . . . *do.*] 683
[460. Cerebral Centres for Movements of Thumb . . . . *do.*] 683
[461. Cerebral Centres for Movements of Combined Synchronous Action of Both Limbs *do.*] 683
[462. Cerebral Centres for Movements of Lower Limb . . . . *do.*] 683
[463. Cerebral Centres for Movements of Head and Neck and Conjugate Deviation of Eyes . . . . *do.*] 684
[464. Skull, showing points named by Broca . . . . *Broca.*] 685
[465. Fissures and Convolutions of Brain . . . . *Horsley.*] 686
466. Base of the Brain 688
467. Section of the Brain, made on a level with the corpus callosum 691
[468. Cast of Cavities (Ventricles) of Brain . . . . *Féré.*] 692
[469. Transverse Vertical Section of Human Brain . . . . *Dalton.*] 693
[470. Horizontal Section of Brain of Child . . . . *Flechsig.*] 694
471. The Lateral Ventricles of the Brain 695
472. Transverse Vertical Section of the Brain . . . . *After Hirschfeld and Leveillé.* 696
473. Transverse Section of the Middle Horn of the Lateral Ventricle . . . . . . *F. A. Barton.* 697
474. The Fornix, Velum Interpositum, and Middle or Descending Cornu of the Lateral Ventricle 698
475. The Third and Fourth Ventricles 700
476. Vertical Median Section of Encephalon, showing the parts in the middle line. *After Sappey.* 701
477. Gray Matter of the Cerebral Cortex . . . . *Meynert.* 704
478. Upper Surface of the Cerebellum 709
479. Under Surface of the Cerebellum 709
480. Vertical Section of the Cerebellum . . . . *Arnold.* 710
481. Vertical Section through Gray Matter of Cerebellum . . . . *Klein and Noble Smith.* 712

Cranial Nerves.

482. The Optic Nerves and Optic Tracts 717
483. Course of the Fibres in the Optic Commissure . . . . *Bowman.* 717
484. Nerves of the Orbit, seen from above . . . . *After Arnold.* 718
485. Nerves of the Orbit and Ophthalmic Ganglion, side view . . . . *do.* 720
[486. Diagram of Fifth Nerve and its Ganglia . . . . *W. W. Keen.*] 722
487. Distribution of the Second and Third Divisions of the Fifth Nerve and Submaxillary Ganglion . . . . *After Arnold.* 724
488. The Spheno-palatine Ganglion and its Branches 726
489. The Otic Ganglion and its Branches . . . . *After Arnold.* 730
[490. Sensory Nerves of Head and Face . . . . *Flower.*] 731
491. Relation of Structures passing through Sphenoidal Fissure 732
492. The Course and Connections of the Facial Nerve in the Temporal Bone . . *After Bidder.* 732
493. The Nerves of the Scalp, Face, and Side of the Neck 734
494. Origin of the Glosso-pharyngeal, Pneumogastric, and Spinal Accessory Nerves, their Ganglia and Communications . . . . *Bendz.* 736
495. Course and Distribution of the Glosso-pharyngeal, Pneumogastric and Spinal Accessory Nerves 737
496. Hypoglossal Nerve, Cervical Plexus, and their Branches 742

Spinal Nerves.

[497. Relation of Spinal Nerves to Various Motor, Sensory, and Reflex Functions of Spinal Cord . . . . *Gowers.*] 746
498. Posterior Divisions of the Upper Cervical Nerves 748
499. Plan of the Cervical Plexus 751
500. Plan of the Brachial Plexus 753
[501, 502. Cutaneous Nerves of the Trunk and Upper Extremity . . . . *Flower.*] 757
503. Cutaneous Nerves of Right Upper Extremity, anterior view 758
504. Cutaneous Nerves of Right Upper Extremity, posterior view 758
505. Nerves of the Left Upper Extremity, front view 760
506. The Suprascapular, Circumflex, and Musculo-spiral Nerves 762
507. The Posterior Branches of the Spinal Nerves . . . . *After Hirschfeld and Leveillé.* 765
508. Plan of the Lumbar Plexus 768
509. The Lumbar Plexus and its Branches . . . . *Altered from Quain.* 769
510. Cutaneous Nerves of the Lower Extremity, front view 771
511. Nerves of the Lower Extremity, front view 771
[512. Cutaneous Nerves of Lower Extremity . . . . *Flower.*] 772

FIG.
513. The Posterior Sacral Nerves . . . . Altered from Ellis.
514. The Sacral Plexus and its Branches . . . .
515. Cutaneous Nerves of the Lower Extremity, posterior view . . . . . .
516. Nerves of the Lower Extremity, posterior view . . . . . .
517. The Plantar Nerves . . . .
[518. Diagram of the Sympathetic Nerve . . . . Flower.]
519. The Sympathetic Nerve . . . .
[520. Cervical and Thoracic Portion of the Sympathetic Nerve . . . . . Sappey.]
[521. Lumbar and Sacral Portions of the Sympathetic Nerve . . . . . do.]
522. Ganglia and Nerves of Gravid Uterus . . . . After R. Lee.

Organs of Sense.

523. Upper Surface of the Tongue . . . .
524. The Three Kinds of Papillæ of the Tongue, magnified . . . . . Bowman.
525. Minute Structure of Taste-goblet . . . .
526, 527. Cartilages of the Nose . . . . Arnold.
528. Bones and Cartilages of Septum of Nose, right side . . . . . do.
529. Nerves of Septum of Nose, right side . . . . do.
[530. Horizontal Section of Eyeball . . . . Allen.]
531. The Choroid and Iris, enlarged . . . . Altered from Zinn.
532. The Veins of the Choroid, enlarged . . . . Arnold.
533. The Arteries of the Choroid and Iris, the sclerotic having been mostly removed, enlarged . . . . Arnold.
534. The Arteria Centralis Retinæ, Yellow Spot, etc., the anterior half of the eyeball being removed, enlarged . . . .
535, 536. Vertical Sections of the Human Retina . . . . Frey.
537. Layers of the Retina . . . . Altered from Schultze.
538. The Crystalline Lens, hardened and divided, enlarged . . . . . . Arnold.
539. The Meibomian Glands, etc., seen from the inner surface of the eyelids . . . . do.
540. The Lachrymal Apparatus, right side . . . .
541. The Pinna, or Auricle, outer surface . . . .
542. The Muscles of the Pinna . . . . Arnold.
543. A Front View of the Organ of Hearing, right side . . . . . . Scarpa.
544. View of Inner Wall of Tympanum, enlarged . . . .
[545. Vertical Section of Right Eustachian Tube, Tympanic Cavity, and Mastoid Cells . Politzer.]
546. The Small Bones of the Ear, seen from the outside, enlarged . . . . . Arnold.
547. The Osseous Labyrinth, laid open, enlarged . . . . Sömmerring.
548. The Cochlea, laid open, enlarged . . . . Arnold.
549. Longitudinal Section of the Cochlea, showing the relations of the scalæ, etc. . . C. Stewart.
550. Floor of the Scala Media, showing the organ of Corti, etc. . . . . . . do.
551. The Membranous Labyrinth . . . . do.

Organs of Digestion and their Appendages.

552. Sectional View of the Nose, Mouth, Pharynx, etc. . . . .
553. The Permanent Teeth, external view . . . .
[554. Occlusion of Permanent Teeth . . . . Litch.]
555. The Temporary or Milk Teeth, external view . . . .
556. Vertical Section of a Molar Tooth . . . .
557. Vertical Section of a Bicuspid Tooth, magnified . . . . . . After Retzius.
558. Transverse Section of the Root of a Tooth . . . . Waldeyer.
559. Vertical Section of the Lower Jaw of an Early Human Fœtus . . . . . do.
560. Dental Sac of a Human Embryo, at an advanced stage of development . . . . Frey.
[561. Denture of Seven-Year-Old Child . . . . Litch.]
562. The Salivary Glands . . . .
563. Section of Submaxillary Gland . . . . Kölliker.
564. Termination of Nerves in Salivary Cells . . . . Pflüger.
565. Minute Anatomy of Compound Racemose Gland . . . . . . Sariotti.
566. The Regions of the Abdomen and their Contents (edge of costal cartilages in dotted outline) . . . .
567. The Reflections of the Peritoneum, as seen in a vertical section of the abdomen . . . . Altered from Quain.
568. Plan of the Peritoneum . . . .
[569. Layers of Peritoneum . . . . Cruveilhier.]
570. The Reflection of the Peritoneum, as seen in a transverse section of the abdomen . . . . .
571. Diagram to show the Lines along which the Peritoneum leaves the Wall of the Abdomen to invest the Viscera . . . . Delépine.
572. The Mucous Membrane of the Stomach and Duodenum, with the bile-ducts . . . . . .
573. The Muscular Coat of the Stomach . . . .
574. Minute Anatomy of Mucous Membrane of Stomach . . . .
575. Relations of the Duodenum . . . .
[576. Vertical Section of the Mucous Membrane of the Jejunum of a Dog . . . . . Allen.]
577. Diagrammatic Section of a Villus . . . . Watney.
578. Two Villi, magnified . . . .
579. Transverse Section of Crypts of Lieberkühn . . . . . Klein and Noble Smith.
580. Longitudinal Section of Crypts of Lieberkühn . . . . . do. do.
581. Transverse Section through three of Peyer's Follicles, from the rabbit . . . . Frey.
582. Patch of Peyer's Glands, from the lower part of the ileum . . . .
583. A Portion of the Above, magnified . . . . Boehm.

FIG. PAGE
584. Vertical Section of one of Peyer's Patches, from man, injected through its lymphatic canals . . . *Frey.* 881
585. The Cæcum and Colon laid open, to show the ileo-cæcal valve . . . 882
586. Diagram of the Relations of the Large Intestine and Kidneys, from behind . . . 884
587. The Relations of the Viscera and Large Vessels of the Abdomen, from behind . . . 885
588. Minute Structure of Large Intestine . . . *C. Stewart.* 888
589. Meissner's Plexus . . . *Klein and Noble Smith.* 888
590. The Liver, upper surface . . . 890
591. The Liver, under surface . . . 890
592. Longitudinal Section of an Hepatic Vein . . . *Kiernan.* 893
593. Longitudinal Section of a Small Portal Vein and Canal . . . *do.* 893
594. Vessels of Lobules of Liver . . . *Klein.* 894
595. Origin of Bile-ducts . . . *Herring.* 895
596. A Transverse Section of a Small Portal Canal and its Vessels . . . *Kiernan.* 895
597. The Pancreas and its Relations . . . 898
598. Transverse Section of the Spleen, showing the trabecular tissue and the splenic vein and its branches . . . 900
599. Transverse Section of the Human Spleen, showing the distribution of the splenic artery and its branches . . . 901
600. Part of Malpighian Capsule of Spleen . . . *Klein and Noble Smith.* 902
601. Minute Structure of Spleen . . . 903

The Thorax.

602. Front View of the Thorax, showing the relation of the Thoracic Viscera to the walls of the Chest . . . 905
603. The Right Auricle and Ventricle laid open, the anterior walls of both being removed . . . 907
604. The Left Auricle and Ventricle laid open, the posterior walls of both being removed . . . 910
605. Plan of the Fœtal Circulation . . . 917

Organs of Voice and Respiration.

606. Side View of the Thyroid and Cricoid Cartilages . . . 919
607. The Cartilages of the Larynx, posterior view . . . 920
608. The Larynx and Adjacent Parts, seen from above . . . 922
609. Vertical Section of the Larynx and Upper Part of the Trachea . . . 923
[610. Laryngeal Image during Phonation . . . *Seiler.*] 923
[611. Laryngeal Image during Quiet Breathing . . . *Mackenzie.*] 923
612. Muscles of Larynx, side view, right ala of thyroid cartilage removed . . . 925
613. Interior of the Larynx, seen from above, enlarged . . . *Willis.* 925
614. Front View of Cartilages of Larynx: the Trachea and Bronchi . . . 928
615. Transverse Section of the Trachea, just above its Bifurcation, with a Bird's-eye view of the interior . . . 928
616. Surgical Anatomy of the Laryngo-tracheal Region . . . 930
617. A Transverse Section of the Thorax, showing the relative position of the viscera and the reflections of the pleuræ . . . 932
618. The Posterior Mediastinum . . . 933
619. Front View of the Heart and Lungs . . . 935
620. The Roots of the Lungs and Posterior Pulmonary Plexus, seen from behind . . . 938
621. Minute Structure of Thyroid Gland . . . *Frey.* 939
622. Minute Structure of Thyroid Gland . . . *Baber.* 940
623. Minute Structure of Thymus Gland . . . *Frey.* 942
624. Minute Structure of Thymus Gland . . . *Watney.* 943

The Urinary and Generative Organs.

625. Vertical Section of Kidney . . . 945
626. Uriniferous Tubes . . . 946
627. Minute Structure of Kidney . . . 947
628. Malpighian Body . . . 947
629. A Uriniferous Tube . . . 948
630. Descending Limb of Uriniferous Tube . . . *Klein.* 949
631. Straight Tube . . . *do.* 949
632. Transverse Section of Kidney . . . *do.* 950
633. Diagrammatic Sketch of Kidney . . . 950
634. A Portion of Fig. 633, enlarged . . . 950
635. Diagrammatic Representation of the Blood-vessels of the Cortex of the Kidney. . *Ludwig.* 951
636. Vertical Section of Suprarenal Capsule . . . *Elberth.* 954
637. Cortical Portion of Suprarenal Capsule . . . *Frey.* 954
638. Transverse Section through the Cortical Substance of the Suprarenal Capsule . . *do.* 954
639. Vertical Section of Bladder, Penis, and Urethra . . . 956
640. Superficial Layer of Epithelium of Bladder . . . *Klein and Noble Smith.* 958
641. Deep Layers of Epithelium of Bladder . . . *do. do.* 958
642. The Bladder and Urethra laid open . . . 959
[643. Diagram of Urethra in Natural Condition . . . *Thompson.*] 960
644. Transverse Section of the Prostate Gland . . . 962
[645. Cross-section of Penis . . . *Cruveilhier.*] 964
646. Structure of the Corpus Cavernosum . . . *Langer.* 966

FIG. PAGE
647. Transverse Section through the Left Side of the Scrotum and the Left Testicle. *Delépine.* 967
648. The Testis *in situ* 969
649. Vertical Section of the Testis 972
650. Base of the Bladder *Haller.* 973
[651. Descent of Testes and Formation of Tunica Vaginalis *Heath.*] 974
[652. Descent of Testes and Formation of Tunica Vaginalis *do.*] 974
[653. Descent of Testes and Formation of Tunica Vaginalis *do.*] 974
654. The Vulva 976
655. Section of Female Pelvis 977
[656. Antero-posterior Section of Pelvic Organs of Virgin *D. Berry Hart.*] 978
[657. Horizontal Section of Body, showing relations of fundus uteri *Savage.*] 980
[658. Ovarian, Uterine, and Vaginal Arteries *Hyrtl.*] 982
[659. Posterior View of Uterine Appendages *Henle.*] 985
660. The Uterus and its Appendages *Wilson.* 985
661. Section of an Ovary *Schrön.* 986
662. Section of a Graafian Vesicle *Von Baer.* 986

The Surgical Anatomy of Inguinal Hernia.

663. Inguinal Hernia, superficial dissection 992
664. Inguinal Hernia, showing the internal oblique, cremaster, and spermatic canal 994
665. Inguinal Hernia, showing the Transversalis Muscle, the transversalis fascia, and the internal abdominal ring 995
[666. Diagram of Coverings of Hernia *W. W. Keen.*] 997
667. Varieties of Oblique Inguinal Hernia 998
668. Femoral Hernia, superficial dissection 1002
669. Femoral Hernia, showing fascia lata and saphenous opening 1003
670. Femoral Hernia, showing femoral canal 1005
671. Structures which Pass beneath Femoral Arch 1006
672. Hernia, the Relations of the Femoral and Internal Abdominal Rings 1006

Surgical Anatomy of the Perineum and Ischio-rectal Region.

673. Dissection of the Perineum and Ischio-rectal region 1001
674. The Perineum, superficial dissection 1012
675. The Superficial Muscles and Vessels of the Perineum 1013
[676. Muscles of Female Perineum *Savage—Luschka.*] 1015
[677. Female Perineum *Savage.*] 1016
[678. Structures between the Two Layers of Deep Perineal Fascia *Wilson.*] 1017
679. Deep Perineal Fascia 1018
680. A View of the Position of the Viscera at the Outlet of the Pelvis 1019
681. A Transverse Section of the Pelvis, showing the pelvic fascia from behind. *After Wilson.* 1020
682. Side View of the Pelvic Viscera of the Male Subject, showing the pelvic and perineal fascia 1022

LANDMARKS, MEDICAL AND SURGICAL.

683. Outline of the Heart, its Valves, and the Lungs 1035
[684. Diagram showing the Approximate Relation to the Spinal Nerves of the various Motor, Sensory, and Reflex Functions of the Spinal Cord *Gowers.*] 1039
685. Opisthotonos 1040

ON THE SYSTEMATIC USE OF THE LIVING MODEL AS A MEANS OF ILLUSTRATION IN TEACHING ANATOMY.

THE following paper (here slightly altered and expanded) was read by the American Editor at the London International Medical Congress in 1881, and is reprinted in the hope that it will stimulate anatomical teachers to use the living model in their lectures, and students to observe the same facts on each other or on their own persons. In his own anatomical lectures the Editor has used this method now for some seventeen or eighteen years, and it has been his experience that not a few teachers, as well as many pupils, have expressed their interest and profit in observing the marked advantages of the method. It throws an entirely new light on the practical applications of anatomy to the every-day wants of the doctor, and enlivens what is otherwise not seldom a dry subject. No teacher who ever tries it will ever be willing to dispense with it.

"In one sense, what I wish to suggest is not a novelty. Long ago, Sir Charles Bell, having learned the value of the living model in his lectures on fractures and dislocations, was accustomed to introduce a powerful muscular fellow to his class with the striking and suggestive remark that, however familiar they might be with the body as affected by disease or accident, 'not one of them, perhaps, had ever looked on the natural body itself.' Of late, Mr. Christopher Heath has followed out Bell's idea in more than one noteworthy publication, while Mr. Holden in his 'Landmarks, Medical and Surgical,' has given us an admirable illustration of how much anatomy may be learned by a careful study of the exterior of the body.

"What I wish, therefore, formally to urge upon teachers of anatomy is not that the living model should be used occasionally, but *regularly;* not as a rarity, but as a *constant* means of illustration—as much so as the cadaver or the skeleton.

"In disease we have not to deal with the dissected body, but with the normal living, moving body; and while it is needful that we know each dissected part, yet if we would know the body thoroughly and practically we must study it as a reconstructed undissected whole. Accustomed to the normal form, relation, and consistence, the eye and the hand can well judge in the clinic room of what is abnormal; and no dissection of the dead body—altered not only by post-mortem change, but also by artificial means for preservation from decay, and by altered relations from the removal of the skin and further dissections—can replace such familiarity.

"What might be called 'Postural Anatomy' is almost impossible in the dead. The subject must lie practically on the back or the belly, with muscles relaxed, motionless arms and legs. The living model can simulate the patient; can stand, sit, stoop, lie on the back, etc.; bend forward, backward, laterally; swing the arms or legs, flex, extend, abduct, adduct them; can expire or inspire; can contract or relax at will all the muscles or a single one,—thus changing not only the outline of the body in general, but the local forms, the resistance of the tissues, the reciprocal relations of bones, joints, muscles, vessels, and viscera; the arteries can be felt beating in many parts of the body, and their bony, muscular, or mathematical relations studied; the veins can be filled by moderate constriction; the form, extent, and consistence of the chief abdominal and thoracic viscera can be accurately determined. And when the anatomist has shown the part under discussion in the dissected body, he then turns to the living model and shows it there by the eye, by the touch, by measurement from some fixed point, by line, or by percussion.

"Not only should the model be used passively, as it were—that is, at rest—and actively by various gestures in various postures, etc., but especially by strongly-resisted motions. This may be by lifting heavy weights, swinging from rings by one or both arms, lifting the body while holding on to the rings or a bar, and by seizing the arm, leg, etc. of the model and resisting his motions in various actions. The female model also should be used to some extent, and under proper restrictions, in order to show the differences of form, motion, posture, development, etc.

"Of course, in many parts of the body the living model, like the cadaver, is not needed for lecture purposes; but in studying the bones, joints, muscles, arteries, veins, most nerves and most viscera, he should be always at hand for ready reference. The model should be varied, like the cadaver, to suit the object in view—a muscular athlete being selected when on the muscles, a leaner man for the arteries, nerves, etc. These last can be admirably indicated by the now commonly used so-called indelible pencil with aniline lead, which, by previously wetting the skin, will instantly mark a purple line, dot, cross, etc., or by it the name of the part, if desired, can be written on the moistened skin. The eye of the student thus catches what the touch and the observation of the teacher have ascertained. The position of the palmar arches and of Poupart's ligament are striking illustrations of this. Unless the relation of the arches to the web of the thumb be pointed out, any student from his dissection would inevitably place them much lower down than they really are, because, in dissecting, the skin has been removed long before the arteries have been reached; and unless Poupart's ligament be accurately determined by fixing its bony attachments by touch, and then drawing its line, we are very apt to mistake inguinal and femoral hernia.

"Incidentally, also, I may say that I have found it very useful to study the cadaver, not only horizontally, on a rotating table, as we generally do, but in the vertical position. I place two hooks in the skull, just above the ears, and suspend the body from the ceiling by a pulley, using also a cross-piece with cords and self-adjusting pulleys, by which the arms can be raised at will and the body easily rotated. The skeleton, cadaver, and model are thus all in the same posture, and no mental transposition of relations is necessary in passing from the one to the other."

In revising this edition of Gray's *Anatomy* I have indicated in many places what can be learned by the above method. In the case of the muscles I have suggested special gestures and resisted motions by which particular muscles may best be shown. My experience at the Academy of the Fine Arts, however, shows me that models vary very much in this respect, as well as in their comprehension of just what action is desired, and teachers may find that other gestures or poses than the one stated may bring the muscles into better relief in other models.

ANATOMY,

DESCRIPTIVE AND SURGICAL.

GENERAL ANATOMY.

THE **fluids** of the body, which are intended for its nutrition, are the lymph, the chyle, and the blood. There are other fluids also which partially subserve the same purpose, as the saliva, the gastric juice, the bile, the intestinal secretion; and others which are purely excrementitious, as the urine. But there is no need to describe the rest in this place, since they are the secretions of special organs, and are described, as far as is judged necessary for the purposes of this work, in subsequent pages. We shall here speak first of the blood, and next of the lymph and chyle.

THE BLOOD.

The blood is a thickish, opaque fluid, of a bright red or scarlet color when it flows from the arteries, of a dark red or purple color when it flows from the veins. It is viscid, and has a somewhat clammy feeling; it is salt to the taste, and has a peculiar faint odor. It has an alkaline reaction. Its specific gravity at 60° F. is about 1.055, and its temperature is generally about 100° F., though varying slightly in different parts of the body.

General Composition of the Blood.—When blood is drawn from the body and allowed to stand, it solidifies in the course of a very few minutes into a jelly-like mass, which has the same appearance and volume as the fluid blood, and, like it, looks quite uniform. Soon, however, drops of a transparent yellowish fluid begin to ooze out from the surface of this mass and to collect around it. Coincidently with this the clot begins to contract, so that in the course of about twenty-four hours the original mass of coagulated blood has become separated into two parts: a "clot" or "coagulum," considerably smaller and firmer than the first-formed jelly-like mass, and a large quantity of yellowish fluid, the *serum*, in which the clot floats.

The clot thus formed consists of a solid, colorless material called *fibrin*, and a large number of minute cells or corpuscles called *blood-corpuscles*, which are entangled and enclosed in the fibrin. The fibrin is formed during the act of solidification. In the fluid blood in the living body there are two substances, named *fibrinogen* and *fibrino-plastin*, which may be termed fibrin-factors. These two materials, when withdrawn from the body, become acted upon by a third material, also contained in the blood, and named a *fibrin-ferment*, and unite together, forming a solid substance, *fibrin*. This latter in its process of solidification encloses and entangles the blood-corpuscles, and thus the clot is formed.

We may now consider the constituents of the blood in another way: If a drop of blood is placed in a thin layer on a glass slide and examined under the microscope, it will be seen to consist of a number of minute bodies or corpuscles floating in a clear fluid; and on more minute examination it will be found that these corpuscles are of two kinds. The one kind, greatly preponderating over the other in point of numbers, are termed the *colored corpuscles;* the other, fewer in number and less conspicuous, are termed the *colorless* corpuscles. From this we learn that blood is a fluid holding a large number of corpuscles of two varieties in suspension. The fluid is named *liquor sanguinis*, or *plasma*, and must not be confused with the serum spoken of above in connection with the coagulation of the blood. It is serum and something more, for it contains one at least of the elements or factors from which fibrin is formed. The relation of these various constituents of blood to each other will be easily understood by a reference to the subjoined plan:

$$\text{Blood}\begin{cases}\text{Corpuscles}\begin{cases}\text{Colored}\\ \text{Colorless}\end{cases}\\ \text{Liquor sanguinis}\begin{cases}\text{Fibrin}\\ \text{Serum.}\end{cases}\end{cases}\left.\begin{matrix}\text{Colored}\\ \text{Colorless}\\ \text{Fibrin}\end{matrix}\right\}\text{Clot.}$$

The **blood-corpuscles, blood-disks, blood-globules** are, as before stated, of two kinds: the red or colored, and the white or colorless corpuscles. The relative proportion of the one to the other has been variously estimated, and no doubt varies under different circumstances. Thus venesection, by withdrawing a large proportion of the red globules, and by favoring the absorption of lymphatic fluid into the blood, greatly increases the relative proportion of the white corpuscles. Klein states that in healthy human blood there appears to be one white corpuscle for 600–1200 red ones. The proportion of corpuscles, colored and colorless combined, to liquor sanguinis is in one hundred volumes of blood about thirty-six volumes of the former to sixty-four of the latter.

Colored corpuscles when examined under the microscope are seen to be circular disks, biconcave in profile, having a slight central depression, with a raised border (Fig. 1, *b*). When viewed with a moderate magnifying power, this central depression looks darker than the edge. When examined singly by transmitted light, their color appears to be of a faint reddish-yellow when derived from arterial blood, and greenish-yellow in venous blood. It is to their aggregation that blood owes its red hue. Their size varies slightly even in the same drop of blood, but it may be stated that their average diameter is about $\frac{1}{3200}$ of an inch, their thickness about $\frac{1}{12000}$, or nearly one-quarter of their diameter. Besides these, especially in some anæmic and diseased conditions, certain corpuscles are found of a much smaller size, about one-third or one-half the size of the ordinary one. These, however, are very scarce in normal blood. The number of red corpuscles in the blood is enormous; between 4,000,000 and 5,000,000 are contained in a cubic millimeter. Power states that the red corpuscles of an adult would present an aggregate surface of about 3000 square yards. Human blood-disks present no trace of a nucleus. They consist of a tough, elastic, transparent stroma, uniformly pervaded by a coloring matter named *hæmoglobin*. *Hæmoglobin* is a proteid compound of a very complex constitution (C_{600}, H_{960}, N_{154}, FeS_3, O_{179}). It has a great affinity for oxygen, and when removed from the body crystallizes readily under certain circumstances. It is readily soluble in water, and the addition of this fluid to a drop of blood speedily dissolves out hæmoglobin from the corpuscle.

FIG. 1.



Human Blood-globules: *a*, seen from the surface; *b*, seen from the side; *c*, united in rouleaux; *d*, rendered spherical by water; *e*, decolorized by the same; *f*, blood-globules shrunk by evaporation.

If the web of a frog's foot is spread out and examined under the microscope, the blood is seen to flow in a continuous stream through the vessels, and the corpuscles show no tendency to adhere to each other or to the wall of the vessel.

Doubtless the same is the case in the human body; but when drawn and examined on a slide without reagents, the blood-globules often collect into heaps like rouleaux of coins (Fig. 1, *c*).

During life the red corpuscles may be seen to change their shape under pressure, so as to adapt themselves to some extent to the size of the vessel. They are also highly elastic, for they speedily recover their shape when the pressure is removed. They are soon influenced by the medium in which they are placed and by the specific gravity of the medium. In water they swell up, lose their color, and cease to be visible, leaving the white corpuscles in the field. Solutions of salt or sugar, denser than the serum, give them a stellate or crenated appearance, and the usual shape may be restored by diluting the solution to the proper point. The same crenated outline may be produced as the first effect of the passage of an electric shock. A solution of salt or sugar of the same specific gravity as serum merely separates the blood-globules mechanically without changing their shape.

The **white corpuscles** (Fig. 2) are rather larger than the red in human blood, measuring from about $\frac{1}{2000}$ to $\frac{1}{2500}$ of an inch in diameter. When absolutely at rest they are rounded or spheroidal, but under ordinary circumstances their form is very various, and they have the remarkable property of undergoing "amœboid" changes (Fig. 3). That is to say, they have the power of sending out finger-shaped or filamentous processes of their own substance, by which they move and take up granules from the surrounding substance. In locomotion the corpuscle pushes out a process of its substance—a pseudopodium, as it is called—and then shifts the rest of the body into it. In the same way, when any granule or particle comes in its way it wraps a pseudopodium round it, and then, withdrawing it, lodges the particle in its own substance. By means of these amœboid properties they have the power of wandering or emigrating from the blood-vessels by penetrating their coats, and thus finding their way into the perivascular spaces.

FIG. 2.



a, white corpuscles of human blood; *d*, red corpuscles (high power).

FIG. 3.



Human colorless Blood-corpuscle, showing its successive changes of outline within ten minutes when kept moist on a warm stage (Schofield).

The white corpuscle may be taken as the type of a true animal cell. It has no limiting membrane, but consists of a mass of transparent albuminous substance, called *protoplasm*, containing one or more nuclei. These nuclei become more perceptible on the addition of acetic acid. The protoplasm contains bright granules, generally of a fatty nature.

The white corpuscles are very similar to, if not identical with, the corpuscles of lymph and chyle, and they also bear a strong resemblance to the cells found in pus. From the fact that cells exactly like the colorless corpuscles are being constantly furnished to the blood by the lymphatic vessels, the chyle-ducts (and even the liver in the fœtus), and also from their varying proportions in different parts of the circulation and in different pathological conditions, the colorless corpuscles are often regarded—with, at any rate, some probability—as an earlier stage of the colored blood-disks, but the evidence in favor of this cannot be regarded as conclusive.

There can be no doubt that during embryonic life the white corpuscles, which are first formed from certain cells of the mesoblast, are converted into red corpuscles. Another important source of the red corpuscles is the red marrow of bones, in which the marrow-cells are converted into colored blood-corpuscles by the loss of their nuclei and by their protoplasm becoming tinged with yellow. It is probable, also, that the spleen may be a place for the formation of red corpuscles. This theory, which was formerly universally believed, and was then discarded for the hypothesis that the spleen was concerned in the destruction of the red corpuscles, has lately been revived by Bizzozero. The question must still be regarded as *sub judice.* The proportion of white corpuscles appears to vary considerably in different parts of the circulation, being much larger in the blood of the splenic vein and hepatic vein than in other parts of the body, while in the splenic artery they are very scanty.

[**Blood-plaques.**—There is also a "third corpuscle" in the blood, known variously as "hæmatoblasts" and by other names, but best by the name given them by Bizzozero, "blood-plates" or "blood-plaques." They are colorless protoplasmic disks, constant in mammalian blood, measuring 1.5 to 3.5 micromillimeters, and about in the ratio of one to eighteen or twenty red ones, as a rule. They are colorless, homogeneous, or finely granular, probably without a nucleus. They are increased in number in a large number of diseases, and bear an important relation to the coagulation of the blood, and especially to the formation of thrombi. (For the most recent views on this interesting element in the blood, see Prof. Wm. Osler's "Cartright Lectures," *Med. News*, April 3, 1886.)]

[Fig. 4.

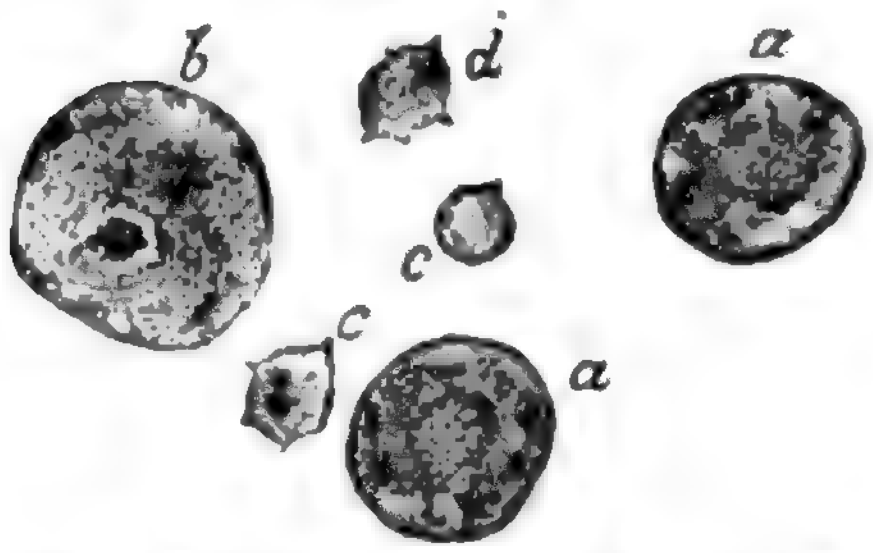

Isolated Plaques in Normal Blood—osmic acid, 1 per cent. (one-twelfth im.; Ziess): *a*, red corpuscles; *b*, a white corpuscle; *c*, *c*, plaques with slightly irregular margins; *d*, plaque with faint granular appearance in centre, as if nucleated (Osler).]

The **liquor sanguinis**, or **plasma**, is the fluid part of the blood, and is composed of a permanently fluid portion, the *serum*, and of fibrin-factors, which unite spontaneously when out of the body, and by their union form a solid substance, *fibrin*. These two fibrin-factors are named *fibrinogen* and *fibrino-plastin* or *paraglobulin*. Fibrino-plastin is probably contained partly in solution in the plasma and partly in the colorless corpuscles, and can be obtained by diluting the liquor sanguinis with ten times its volume of ice-cold water, and then transmitting through it a stream of carbon dioxide. Fibrinogen may be obtained in the same way as fibrino-plastin, but the liquor sanguinis must be still further diluted and the current of carbon dioxide must pass for a much longer time. When these two fibrin-factors are withdrawn from the body, their union to form fibrin is probably brought about by the agency of a third body, called a *fibrin-ferment*. This ferment is not supposed to pre-exist in the blood, but is formed after the blood is withdrawn from the body by the breaking down of some of the white corpuscles. Fibrin may be obtained by whipping the blood, after it has been withdrawn from the body, with a bundle of twigs, to which the fibrin, as it coagulates, adheres. Fibrin may also be obtained by filtering the freshly-drawn blood of an animal in whom the corpuscles are large, care being taken to retard coagulation as long as possible. Under these circumstances the corpuscles are retained on the filter, and the liquor sanguinis, passing through, coagulates and separates into fibrin, free from corpuscles and serum.

Fibrin, thus obtained, is a white or buff-colored substance, presenting a stringy appearance, and under the microscope exhibiting fibrillation. When exposed to the air for some time it becomes hard, dry, brown, and brittle. It is a proteid compound, insoluble in hot or cold water, alcohol, or ether. Under the influence of dilute hydrochloric acid it swells up, but does not dissolve; but when thus swollen it is easily dissolved by a solution of pepsin. If heated for a considerable time in a solution of dilute hydrochloric acid, it gradually dissolves.

Serum is the fluid liquor sanguinis after the fibrin-factors have been separated from it. It is a straw-colored fluid, having a specific gravity 1.027, with an alkaline reaction. Upon boiling it becomes solid, on account of the albumen which it contains. It contains also salts, fatty matters, sugar, and gases.

Gases of the Blood.—When blood is exposed to the vacuum of an air-pump, about half its volume is given off in the form of gases. These are carbonic acid, oxygen, and nitrogen. The relative quantities in 100 volumes of arterial and venous blood, at 0° C. and 1 m. pressure of mercury, are shown in the accompanying table:

	Oxygen.	Carbonic Acid.	Nitrogen.
Arterial blood	16 vols.	30 vols.	1 to 2 vols.
Venous blood	6 to 10 vols.	35 vols.	1 to 2 vols.

Roughly stated, they are as follows: Carbonic acid, about two-thirds of the whole quantity of gas, oxygen rather less than one-third, nitrogen below one-tenth (Huxley). The greater quantity of the oxygen is in loose chemical combination with the hæmoglobin of the blood-corpuscles, but some part is simply absorbed, just as it would be by water. The carbonic acid is in a state of chemical combination with the salts of the serum, especially the sodium, with which it is combined, partly as a carbonate and partly as a bicarbonate. The nitrogen is unimportant. It (or at least the greater part of it) is merely absorbed from the atmosphere under the pressure to which the blood is exposed, and can therefore be mechanically removed.

Blood-crystals.—Hæmoglobin, as stated above, when separated from the blood-corpuscles, readily undergoes crystallization. These crystals, named *hæmoglobin crystals*, all belong, with the exception of those obtained from the squirrel, to the rhombic system. In human blood they are elongated prisms (Fig. 5, A). In the squirrel they are hexagonal plates. Other crystals may be obtained by mixing dried blood with an equal quantity of common salt and boiling it with a few drops of glacial acetic acid. A drop of the mixture placed on the slide will show the crystals on cooling. These are named hæmin crystals, and consist of small acicular prisms (Fig. 5, B). Occasionally in old blood-clots a third form of crystal is found, the hæmatoidin crystal (Fig. 5, C).

Fig. 5.



Blood-crystals: A, Hæmatin Crystals from Human Blood. B, Hæmin Crystals from Blood treated with Acetic Acid. C, Hæmatoidin Crystals from an old Apoplectic Clot.

LYMPH AND CHYLE.

The **Lymph** is a transparent, colorless, or slightly yellow fluid, which is conveyed by a system of vessels, named *lymphatics*, into the blood. These vessels take their rise in nearly all parts of the body, and take up from the worn-out tissues that portion which is still available for purposes of nutrition, and return it into the veins close to the heart, there to be mixed with the mass of the blood. The greater number of these lymphatics empty themselves into one main duct, the *thoracic duct*, which passes along the front of the spine and opens into one of the large veins at the root of the neck. The remainder empty themselves in a smaller duct, which terminates in the corresponding vein on the opposite side of the neck.

The **Chyle** is an opaque, milky-white fluid, absorbed by the villi of the small intestines from the food, and carried by a set of vessels similar to the lymphatics, named *lacteals*, to the commencement of the thoracic duct, where it is intermingled with the lymph and poured into the circulation through the same channels. It must be borne in mind that these two sets of vessels, lymphatics and lacteals, though differing in name, are identical in structure, and that the character of the fluid they convey is different only while digestion is going on. At other times the lacteals convey a transparent, nearly colorless fluid not to be distinguished from lymph. Both these sets of vessels, in their passage to the central duct, pass through certain small glandular bodies, termed *lymphatic glands*, where their contents undergo elaboration.

Lymph, as its name implies, is a watery fluid. It closely resembles the liquor sanguinis, and contains about 5 per cent. of albumên and 1 per cent. of salts. When examined under the microscope it is found to consist of a clear colorless fluid in which are floating a number of corpuscles, *lymph-corpuscles*. The bodies are identical in structure, and not to be distinguished from the white blood-corpuscles previously described. They vary in number in different parts of the lymphatic vessels, and indeed are said by Kölliker to be absent in the smaller ones. They are always increased in number after the passage of the lymph through a lymphatic gland, and are said to be increased in size as the fluid ascends higher in the course of the circulation.

Chyle is a milk-white fluid which exactly resembles lymph in its physical and chemical properties, except that it has, in addition to the other constituents of lymph, an enormous number of fatty granules, "the molecular basis of chyle;" and it is to the presence of these molecules that chyle owes its milky color. Under the microscope it presents a number of corpuscles, named "chyle-corpuscles," which are indistinguishable from lymph-corpuscles or white blood-cells, and the molecular basis, consisting principally of fatty granules of extreme minuteness (Fig. 6, *a*), but also of a few small oil-globules. Lymph and chyle after their passage through their respective glands, if withdrawn from the body and allowed to stand, separate more or less completely into a clear liquid, which is identical with the serum of the blood, and a thin jelly-like clot consisting of fibres in which lymph-corpuscles or chyle-corpuscles and fatty molecules, as the case may be, are entangled.

Fig. 6.

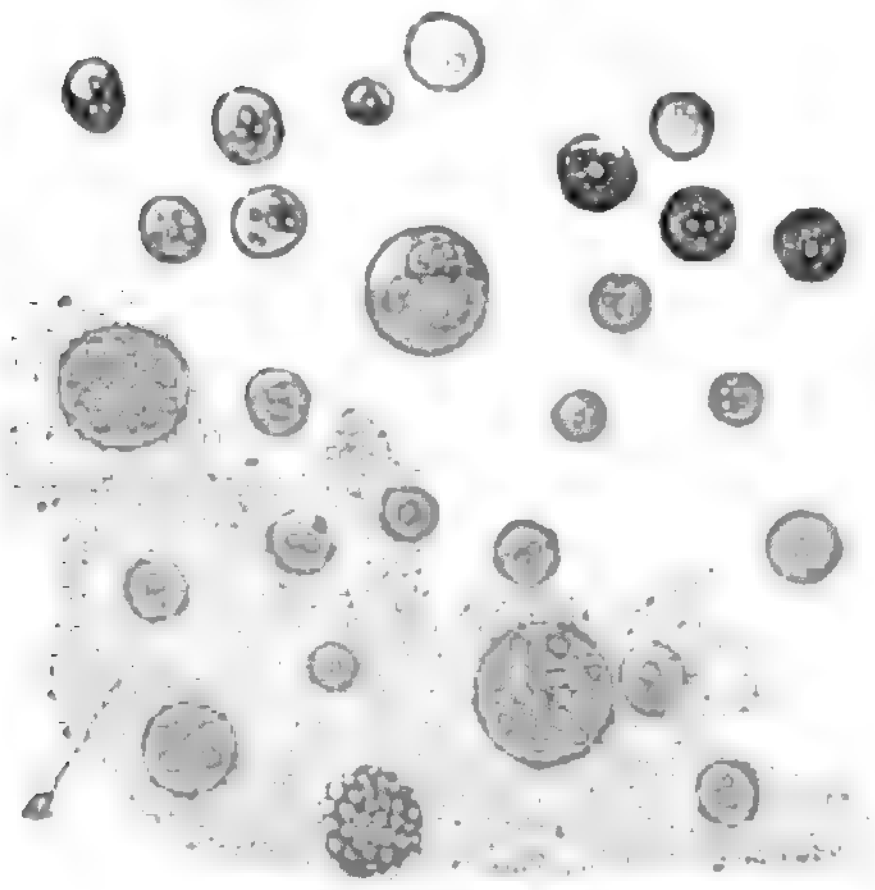

Chyle from the Lacteals.

If the contents of the thoracic duct are examined, especially after a meal, there may be found in it corpuscles with a reddish tinge. These are regarded as *immature* red corpuscles, or lymph- and chyle-corpuscles in process of transformation into blood-globules. They frequently give to the surface of clotted chyle and lymph a pinkish hue. They must not be mistaken for mature blood-globules, which are sometimes found in lymph and chyle, and which are regarded by most observers as accidental—*i. e.* produced by the manipulations of the dissector.

THE ANIMAL CELL.

All the tissues and organs of which the body is composed were originally developed from a microscopic body (the *ovum*), consisting of a soft, gelatinous, granular material enclosed in a membrane, and containing a vesicle, or small spherical body, inside which are one or more solid spots. (See Fig. 79.) This may be regarded as a perfect cell. Moreover, all the solid tissues can be shown to consist largely of similar bodies, differing, it is true, in external form, but essentially similar to an ovum. These are also cells.

In the higher organisms all such cells may be defined as "nucleated masses of protoplasm of microscopic size." The two essentials, therefore of an animal cell in the higher organisms are the presence of a soft, gelatinous, granular material, similar to that found in the ovum, and which is usually styled *protoplasm*, and a small spherical body imbedded in it, and termed a *nucleus*;[1] the remaining constituents of the ovum—viz. its limiting membrane and the solid spot contained in the nucleus, called the *nucleolus*—not being considered essential to the cell, and in fact many cells existing without them.

Protoplasm (*sarcode*, *blastema*, *germinal matter*, or *bioplasm*) is a proteid compound which cannot analytically be distinguished from albumen. It is of a semifluid, viscid consistence, and appears either as a hyaline substance, homogeneous and clear, or as a granular substance, consisting of minute molecules imbedded in a transparent matrix. The molecules are regarded by some as adventitious material taken in from without, and often probably of a fatty nature, since they are frequently soluble in ether. Under certain circumstances protoplasm shows a more definite structure, consisting of minute striæ or fibrils arranged in a clear transparent matrix, or even a honeycombed reticulum, containing in its interstices a homogeneous substance. Protoplasm is insoluble in water, coagulates at 130° F., and has a great affinity for certain staining reagents, as logwood or carmine.

The most striking characteristics of protoplasm are its vital properties of *motion* and *nutrition*. By motion is meant the power which protoplasm has of changing its shape and position by some internal power in itself, which enables it to thrust out from its main body an irregular process, into which the whole of the protoplasmic substance is gradually drawn, so that the mass comes to occupy a new position. This, on account of its resemblance to the movements observed in the amœba or proteus animalcule, has been termed "amœboid movement." Ciliary movement, or the vibration of hair-like processes from the surface of any structure, may also be regarded as a variety of the motion with which protoplasm is endowed. Nutrition is the power which protoplasm has of attracting to itself the materials of growth from surrounding matter. When any foreign particle comes in contact with the protoplasmic substance, it becomes incorporated in it by being enwrapped by one or more processes projected from the parent mass and enclosing it. When thus taken up, it may remain in the substance of the protoplasm for some time without change, and finally may be extruded again.

The *Nucleus* is a minute body imbedded in the protoplasm, and usually of a spherical or oval form, its size generally varying in proportion to the size of the cell. It is usually surrounded by a well-defined wall, and is regarded as a portion of the protoplasmic substance set apart for the purposes of reproduction. It differs chemically from the ordinary protoplasm in containing nuclein, in its power of resisting the action of acids and alkalies, in its imbibing more intensely the stain of carmine, hæmatoxylin, etc., and in its remaining unstained by some reagents which color ordinary protoplasm; as, for example, nitrate of silver.

The process of reproduction commences in the nucleus, and may be brought about either by segmentation or by gemmation. In reproduction by segmentation or fission the nucleus first splits by becoming constricted in its centre, and thus assuming an hour-glass shape. This leads to a cleavage or division of the whole protoplasmic mass of the cell; and thus we find that two new cells have been formed, consisting of the same substance as the original one, and each containing a nucleus. These daughter-cells are of course at first smaller than the original mother-cell; but they grow, and the process may be repeated in them, so that multiplication may rapidly take place. This mode of division or cleavage is termed

---

[1] In certain lower forms of life masses of protoplasm without any nucleus have been described by Huxley and others as cells.

direct division, in contradistinction to another mode of division, in which the nucleus shows slow movements and complicated changes prior to its division. This is termed *indirect division*, or *karyokinesis*. These changes consist briefly in the fibrils of the nuclear network becoming convoluted, and thus forming a sort of rosette or star-shaped figure. This subsequently divides into two stars, around each of which a membrane appears, and thus we have two new or daughter-nuclei. The cell-protoplasm subsequently either divides, and we thus get two complete cells, or, remaining undivided, we have a two-nucleated cell.

In reproduction by gemmation, a budding-off or separation of a portion of the nucleus and parent-cell takes place, and, becoming separated, forms a new organism.

The *cell-wall*, which is not an essential constituent, and in fact is often absent, consists of a flexible, transparent, structureless or finely-striated membrane which is permeable to fluids. As far as is known, every animal cell is derived from a pre-existing cell. The death of cells is accomplished either by their mechanical detachment from the surface, preceded possibly by their bursting and discharging their contents, or by various forms of degeneration—fatty, pigmentary, or calcareous.

EPITHELIUM.

All the surfaces of the body—the external surface of the skin, the internal surface of the digestive and respiratory tracts, the closed serous cavities, the inner coat of the vessels, and the ducts of all glands—are covered by one or more layers of simple cells, called *epithelium* or *epithelial cells*, which serve various purposes, both as a protective layer and as an agent in secretion. Thus, in the skin the main purpose served by the epithelium (here called the *epidermis*) is that of protection. As the surface is worn away by the agency of friction or change of temperature new cells are supplied, and thus the surface of the true skin and the vessels and nerves which it contains are defended from damage. In the gastro-intestinal mucous membrane and in the glands the epithelial cells appear to be the principal agents in separating the secretion from the blood or from the alimentary fluids. In other situations (as the nose, fauces, and respiratory passages) the chief office of the epithelial cells appears to be to maintain an equable temperature by the moisture with which they keep the surface always slightly lubricated. In the serous cavities they also keep the opposed layers moist, and thus facilitate their movements on each other. Finally, in all internal parts they ensure a perfectly smooth surface.

Of late years there has been a tendency on the part of many histologists to divide these several epithelial linings into two classes—into (1) *epithelial tissue proper*, consisting of nucleated protoplasmic cells, which form continuous masses on the skin and mucous surfaces and the linings of the ducts and alveoli of secreting and excreting glands; and (2) *endothelium*, which is composed of a single layer of flattened transparent squamous cells, joined edge to edge in such a manner as to form a membrane of cells. This is found on the free surfaces of the serous and synovial membranes, as the lining membrane of the heart, blood-vessels, and lymphatics; on the surface of the brain and spinal cord; and in the anterior chamber of the eye. And, though the separation must be an artificial one, since every gradation of transition between the two classes may be observed, it would seem advisable for the purposes of description to employ it.

1. **True epithelial tissue** consists of one or more layers of cells united together by an interstitial cement-substance, supported on a basement-membrane, and naturally group themselves into two classes, according as there are a single layer of cells (*simple epithelium*) or more than one (*stratified epithelium*). The various kinds of epithelium, whether arranged in a single layer or in more than one layer, are usually spoken of as tessellated or pavement, columnar, spheroidal or glandular, and ciliated.

The *pavement* epithelium (Fig. 7) is composed of flat nucleated scales of various shapes, usually polygonal, and varying in size. These cells fit together by their edges like the tiles of a mosaic pavement. The nucleus is generally flattened, but may be spheroidal. The flattening depends upon the thinness of the cell. The protoplasm of the cell presents a fine reticulum or honeycombed network, which gives to the cell the appearance of granulation. This kind of epithelium is found on the surface of the skin (epidermis) and on mucous surfaces which are subjected to friction. The nails, hairs, and in animals the horns, are a variety of this kind of epithelium.

Fig. 7.

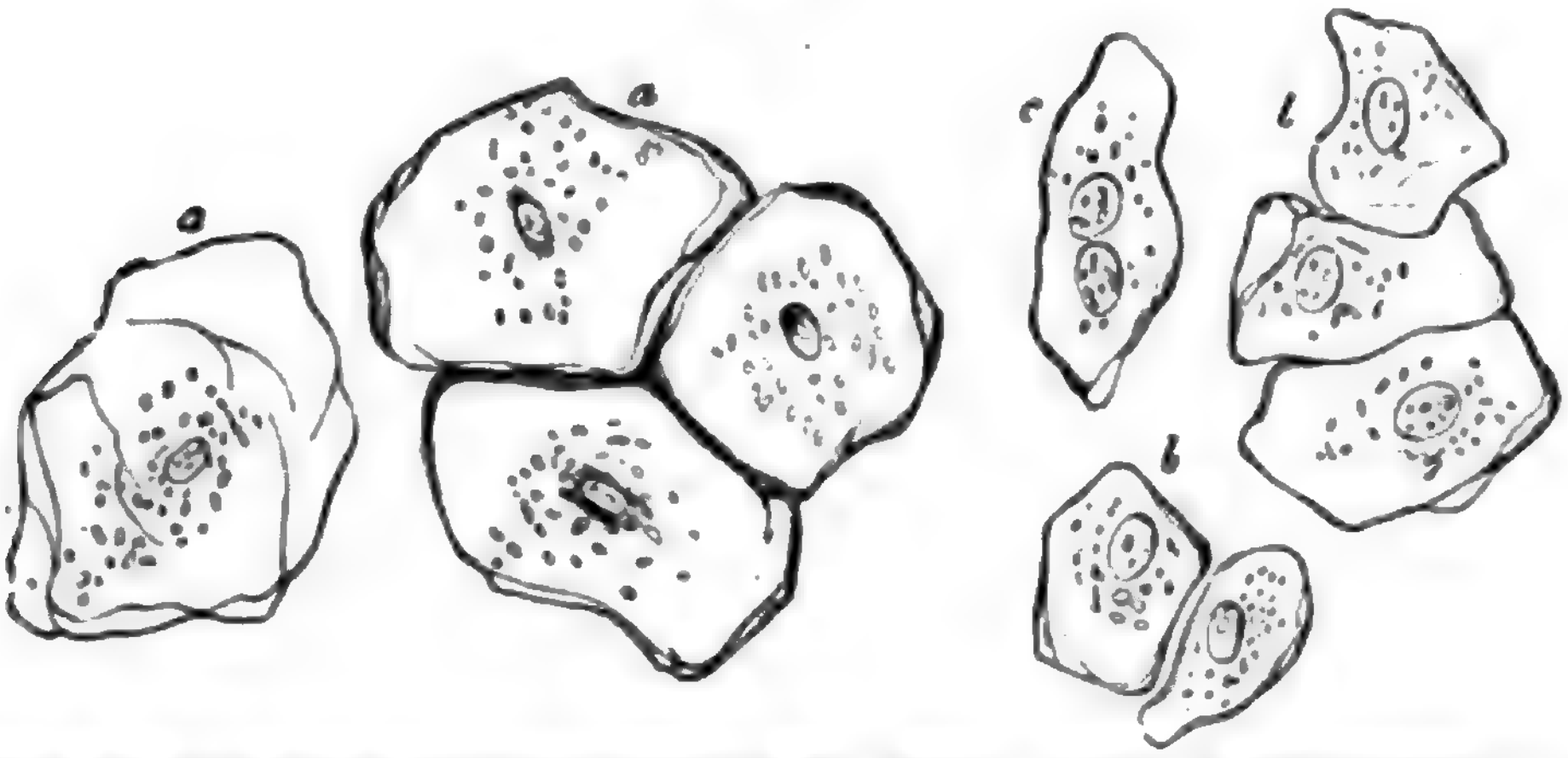

Epithelial Cells in the Oral Cavity of Man (magnified 350 times): *a*, large; *b*, middle-sized; *c*, the same with two nuclei.

The *columnar* or *cylindrical* epithelium (Fig. 8) is formed of cylindrical or rod-shaped cells, each containing a nucleus, and set together so as to form a complete membrane. The cells have a prismatic figure, more or less flattened from mutual pressure, and are set upright on the surface on which they are supported. Their protoplasm is always more or less longitudinally striated, and they contain a nucleus which is oval in shape and contains an intranuclear network.

This form of epithelium covers the mucous membrane of nearly the whole gastro-intestinal tract and the glands of that part, the greater part of the urethra, the vas deferens, the prostate, Cowper's glands, Bartholini's glands, and a portion of the uterine mucous membrane.

Fig. 8.

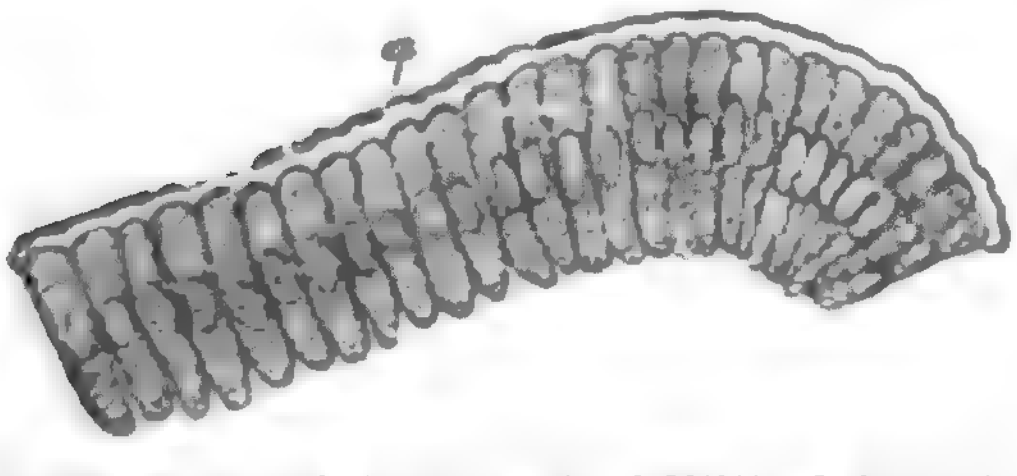

Epithelium of the Intestinal Villi of the Rabbit (magnified 300 times): *a*, basement-membrane.

Fig. 9.

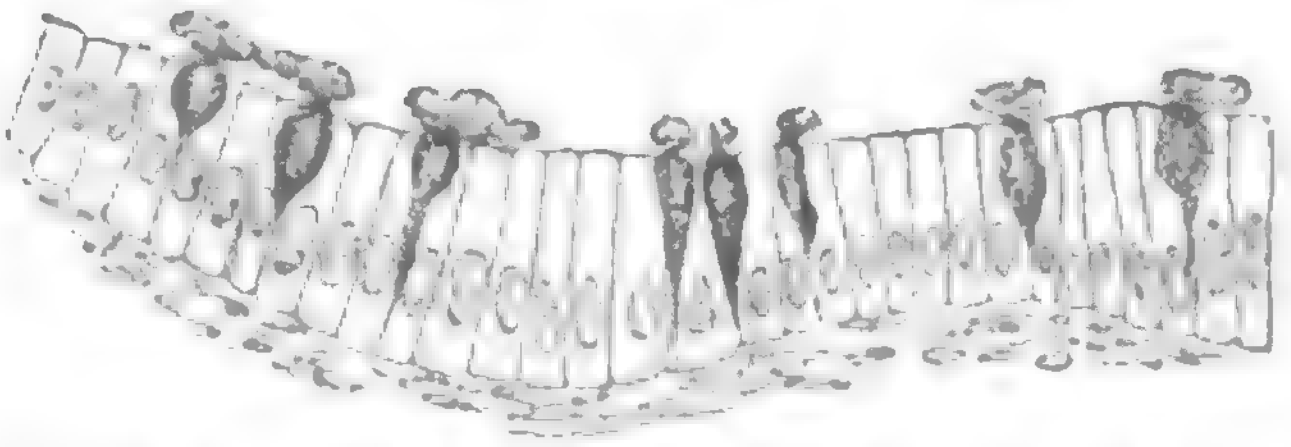

Simple Columnar Epithelium from the Mucous Membrane of the Intestine, with goblet-cells pouring out their contents (Klein and Noble Smith).

Goblet or *chalice* cells are a modification of the columnar cell. They appear to be formed by a conversion in shape of the columnar epithelium (ciliated or otherwise) consequent on the secretion, into the interior of the cell, of *mucin*, the chief organic constituent of mucus, which distends the upper part of the cell, while the nucleus is pressed down toward its deep part, until the cell bursts and the mucus is discharged on to the surface of the mucous membrane, as shown in Fig. 9.

The *spheroidal* or glandular epithelium (Fig. 10) is composed of circular or polyhedral cells. Like other forms of epithelium cells, the protoplasm is a fine reticulum, which gives to the cell the appearance of granulation. They are found in the terminal recesses of secreting glands, and the protoplasm of the cells usually contains the materials which the cells secrete

Ciliated epithelium (Fig. 11) may be of any of the preceding forms, but usually inclines to the columnar shape. It is distinguished by the presence of minute processes, which are direct prolongations of the cell-protoplasm, like hairs or eyelashes (cilia) standing up from the free surface. If the cells are examined during life or immediately on removal from the living body (for which in the human subject the removal of a nasal polypus offers a frequent opportunity) in tepid water, the cilia will be seen in lashing motion; and if the cells are separate, they will often be seen to be moved about in the field by that motion.

FIG. 10.



Spheroidal Epithelium (magnified 250 times).

FIG. 11.

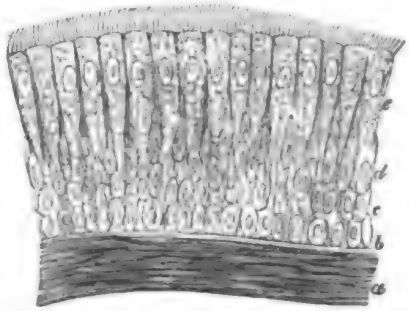

Ciliated Epithelium from the Human Trachea (magnified 350 times): *a*, innermost layers of the elastic longitudinal fibres; *b*, homogeneous innermost layers of the mucous membrane; *c*, deepest round cells; *d*, middle elongated; *e*, superficial, bearing cilia.

The situations in which ciliated epithelium is found in the human body are—the respiratory tract from the nose downward, the tympanum and Eustachian tube, the Fallopian tube and upper portion of the uterus, the vasa efferentia, coni vasculosi and first part of the excretory duct of the testicle, and the ventricles of the brain and central canal of the spinal cord.

Stratified epithelium consists of several layers of cells superimposed one on the top of the other and varying greatly in shape. The cells of the deepest layer are for the most part columnar in form, and as a rule form a single layer, placed vertically on the supporting membrane; above these are several layers of spheroidal cells, which as they approach the surface become more and more compressed, until the superficial layers are found to consist of flattened scales, the margins of which overlap one another so as to present an imbricated appearance. Another form of stratified epithelium is found in what has been termed *transitional* epithelium, such as exists in the ureters and urinary bladder. Here the cells of the most superficial layer are cubical, with depressions on their under surfaces which fit on to the rounded ends of the cells of the second layer, which are pear-shaped, the apices touching the basement-membrane. Between their tapering points are a third variety of cells, filling in the intervals between them, and of smaller size than those of the other two layers.

FIG. 12.

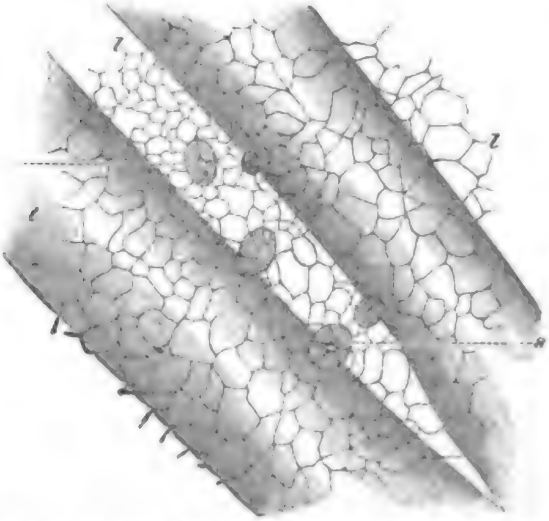

Part of Peritoneal Surface of the Central Tendon of Diaphragm of Rabbit, prepared with nitrate of silver *s*, stomata; *l*, lymph-channels; *t*, tendon-bundles (from *Handbook for the Physiological Laboratory*, Klein).

2. **Endothelium.**—As before stated, endothelial cells are flattened, transparent, squamous cells, attached by their margins by a semifluid homogeneous cement-sub-

stance, so as to form a continuous *endothelial* membrane. Though, for the most part, these cells are squamous, in some places cells may be found, either isolated or occurring in patches, which are polyhedral or even columnar. These cells are frequently to be found lining the stomata of serous membranes, and are supposed to be endothelial cells in an active state of division (Fig. 12). As a rule, the endothelial cells are polygonal in outline, with sinuous or jagged margins, and are in close apposition, the amount of cohesive matter uniting them being so slight as not to be apparent. Their protoplasmic substance appears to be granular, but consists of fibrillæ arranged in a network, in which the nucleus is contained, limited by a membrane and having a well-developed reticulum.

CONNECTIVE TISSUES.

By the term **connective tissue** we mean a number of tissues which possess this feature in common: viz. that they serve the general purpose in the animal economy of supporting and connecting the tissues of the frame. These tissues may differ considerably from each other in external appearance, but they present, nevertheless, many points of relationship with each other, and are moreover developed from the same embryonal elements. They are divided into three great groups: (1) the fibrous connective tissues; (2) cartilage; and (3) bone.

The Fibrous Connective Tissues.—Three principal forms or varieties of fibrous connective tissue are recognized: (1) White fibrous tissue; (2) yellow elastic tissue; (3) areolar tissue. They are all composed of a matrix in which cells are imbedded, and between the cells are fibres of two kinds, the white and yellow or elastic. The difference between the three forms of tissue depends on the relative proportion of the two kinds of fibre, in the first variety enumerated the *white fibre* preponderating, in the second variety the *yellow elastic* fibres being greatly in excess of the white, and in the third form, areolar tissue, the two are blended in much more equal proportions.

The **white fibrous tissue** (Fig. 13) is a true connecting structure, and serves three purposes in the animal economy. It serves to bind bones together in the form of ligaments; it serves to connect muscles to bones or other structures in the form of tendons; and it forms an investing or protecting structure to various organs in the form of membranes. Examples of where it serves this latter office are to be found in the muscular fasciæ or sheaths, the periosteum, and perichondrium; the investments of the various glands (such as the tunica albuginea testis, the capsule of the kidney, etc.), the investing sheath of the nerves (perineurium) and of various organs, as the penis and the eye (sheath of the corpora cavernosa and corpus spongiosum and sclerotic). But in all these parts the student must bear in mind that the elastic tissue enters in greater or less proportion. It presents to the naked eye the appearance of silvery-white glistening fibres, covered over with a quantity of loose, flocculent tissue which binds the fibres together and carries the blood-vessels. It is not possessed of any elasticity, and has only the very slightest extensibility; it is exceedingly strong, so that upon the application of any external violence the bone with which it is connected will fracture before the fibrous tissue will give way. When examined under the microscope it is found to consist of waving bands or bundles of minute, transparent, homogeneous filaments or fibrillæ held together by an albuminous semifluid cement-substance (Fig. 14). In ligaments and tendons these bun-

FIG. 13.

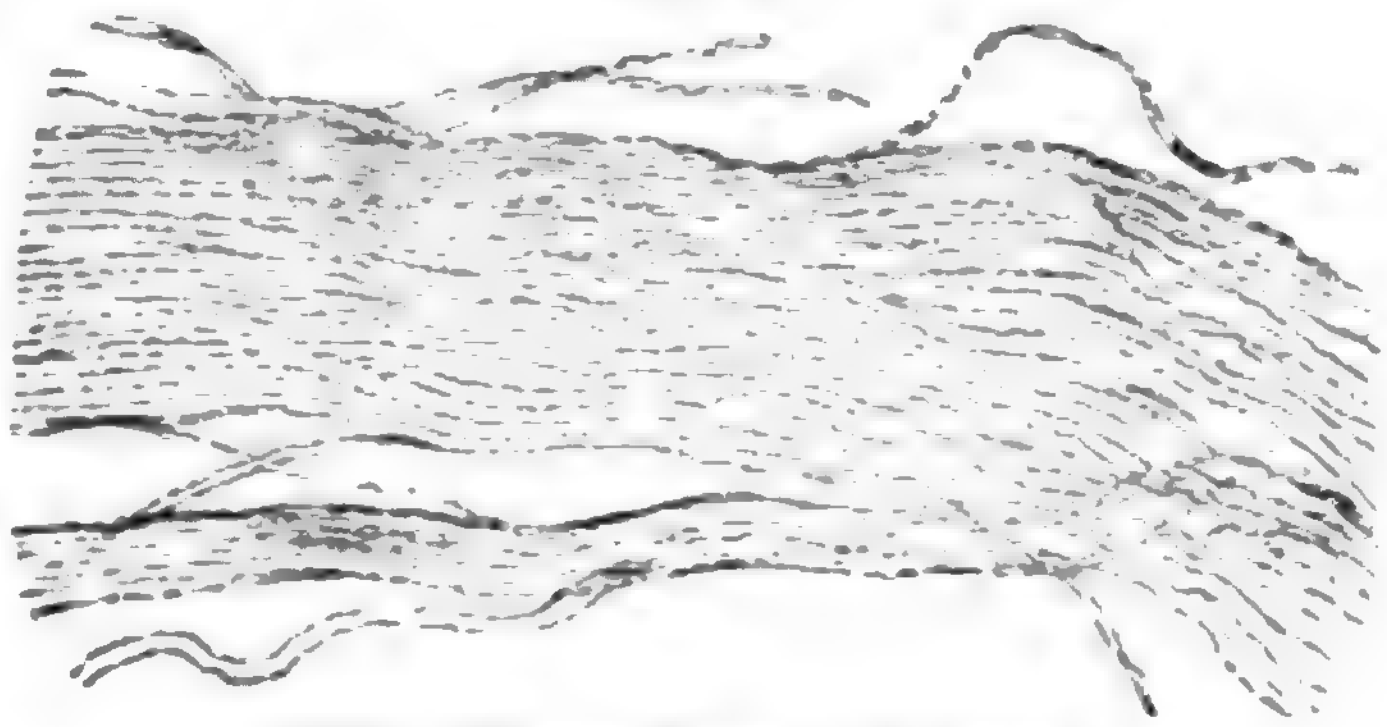

White Fibrous Tissue (high power).

dles run parallel with each other; in membranes they intersect one another in different places. The bundles have a tendency to split up longitudinally or send off slips to join other bundles and receive others in return. The cells occurring in white fibrous tissue are often called "tendon-cells." They are situated on the surface of groups of bundles, and are quadrangular in shape, arranged in rows in single file, each cell being separated from its neighbors by a narrow line of cement-substance. The nucleus is generally situated at one end of the cell, the nucleus of the adjoining cell being in close proximity to it (Fig. 15). Upon the addition of acetic acid to white fibrous tissue it swells up into a glassy-looking, indistinguishable mass. When boiled in water it is converted almost completely into gelatin.

Fig. 14.



Connective Tissue (Klein and Noble Smith): *a*, the white fibrous element — a layer of more or less sharply-outlined, parallel, wavy bundles of connective-tissue fibrils. On the surface of this layer is *b*, a network of fine elastic fibres.

Fig. 15.

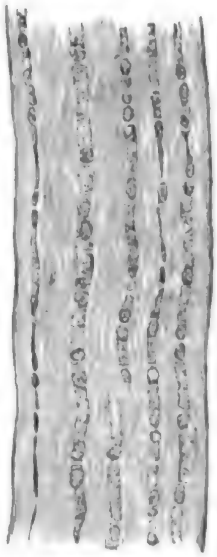

Tendon of Mouse's Tail, stained with logwood, showing chains of cells between the tendon-bundles (from *Quain's Anatomy*, E. A. Schäfer).

Yellow Elastic Tissue.—In certain parts of the body a tissue is found which when viewed in mass is of a yellowish color, and is possessed of great elasticity; so that it is capable of considerable extension, and when the extending force is withdrawn returns at once to its original condition. This is yellow elastic tissue, in which the elastic fibres greatly preponderate, to the almost complete exclusion of the white fibrous element. It is found in this condition in the ligamenta subflava, in the vocal cords, in the longitudinal coat of the trachea and bronchi, in the inner coats of the blood-vessels, especially the larger arteries, and to a very considerable extent in the thyro-hyoid, crico-thyroid, and stylo-hyoid ligaments. It is also found in the ligamentum nuchæ of the lower animals. When viewed under the microscope (Fig. 16), it is seen to consist of an aggregation of curling fibres with a well-defined outline. They are considerably larger in size than the fibrillæ of the white fibrous element, and vary much, being from the $\frac{1}{24000}$ to $\frac{1}{4000}$ of an inch in diameter. The fibres form bold and wide curves, branch, and freely anastomose with each other. They are homogeneous in appearance, and have a tendency to curl up, especially at their broken ends. In some parts, where the fibres are broad and large and the network close, the tissue presents the appearance of a membrane, with gaps or perforations corresponding to the intervening space. This is to be found in the inner coat of the arteries, and to it the name of *fenestrated membrane* has been given by Henle. The yellow elastic fibres remain unaltered by acetic acid.

Areolar tissue is so called because its meshes are easily distended, and thus separated into areolæ or spaces, which all open freely into each other, and are consequently easily blown up with air or permeated by fluid when injected into any part of the tissue. Such spaces, however, do not exist in the natural condition of the body, but the whole tissue forms one unbroken membrane composed of a number of interlacing fibres, variously superimposed. Hence the term "the cellular membrane" is in many parts of the body more appropriate than its more modern equivalent. The chief use of the areolar tissue is to bind parts together; while by the laxity of its fibres and the permeability of its areolæ it allows them to move on each other, and affords a ready exit for inflammatory and other effused fluids. It is one of the most extensively distributed of all the tissues in the body. It is found beneath the skin in a continuous layer all over the body, connecting it to the subjacent parts. In the same way it is situated beneath the mucous and serous membrane. It is also found between muscles, vessels, and nerves, forming investing sheaths for them and connecting them with surrounding structures. In addition to this, it is found in the interior of organs, binding together the various lobes and lobules of the compound glands, the various coats of the hollow viscera, and the fibres of muscles, etc., and thus forms one of the most important connecting media of the various structures or organs of which the body is made up. In many parts the areolæ or interspaces of areolar tissue are occupied by fat-cells, constituting *adipose tissue*, which will presently be described.

FIG. 16.



Yellow Elastic Tissue (high power).

Areolar tissue presents to the naked eye a flocculent appearance, somewhat like spun silk. When stretched out, it is seen to consist of delicate soft elastic threads interlacing each other in every direction, and forming a network of extreme delicacy. When examined under the microscope, it is seen to consist of white fibres and elastic fibres intercrossing in all directions, and united together by a homogeneous cement or ground-substance, and filled by cellular elements, which contain the protoplasm out of which the whole is developed and regenerated.

These cell-spaces may be brought into view by treating the tissue with nitrate of silver and exposing it to the light. This will color the fibres and ground-substance, leaving the cell-spaces unstained.

The cells of areolar tissue (Fig. 17) are of two kinds: 1, flattened transparent cells, with an oblong nucleus and more or less branched, and often united together by thin-branched processes; and 2, granular cells, some of which are of the size of white blood-corpuscles, and like them possessed of amœboid movements: others are of larger size, and do not exhibit amœboid movements to any appreciable extent. They lie imbedded in the ground-substance, and in some

FIG. 17.

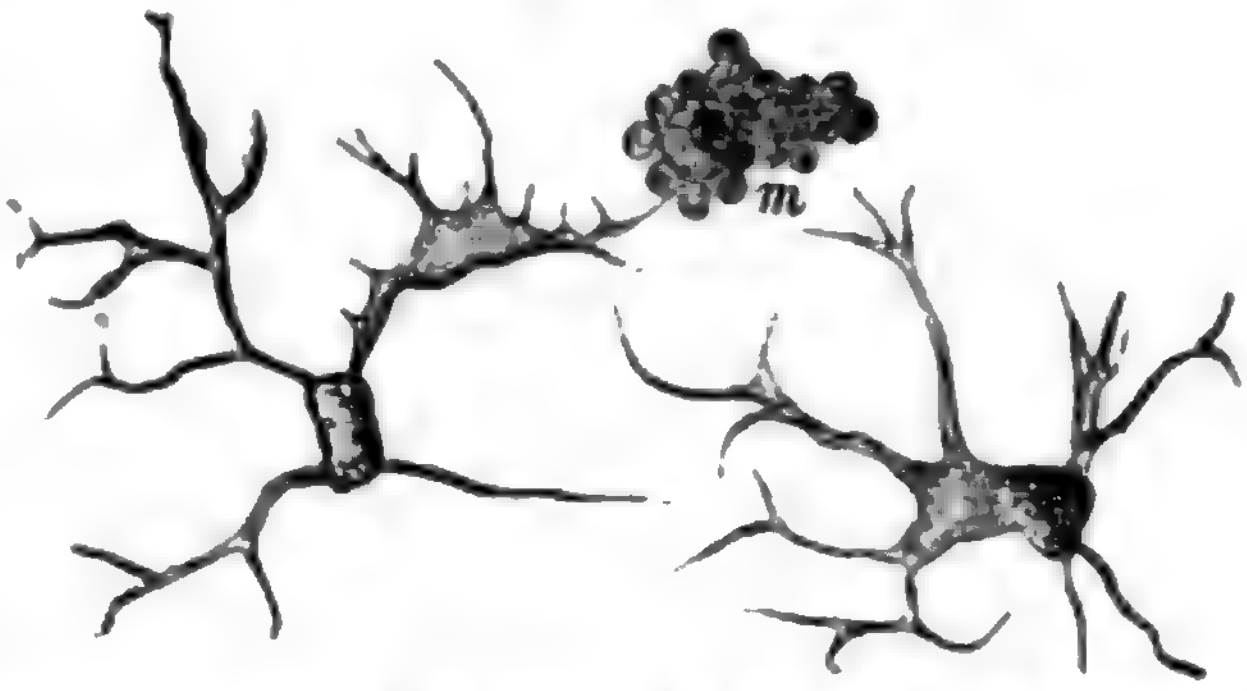

Connective-tissue Corpuscles (Klein and Noble Smith): *m*, migratory connective-tissue cell. The other two are the ordinary branched cells, each with an oblong nucleus.

situations, where the areolar tissue is loose and the spaces large so as to contain several cells, they form a sort of lining for it. In other situations, where the tissue forms a membranous layer, the flattened cells, here unbranched, form an epithelial-like covering to its surface.

Vessels and Nerves of Connective Tissue.—The *blood-vessels* of connective tissue are very few—that is to say, there are few actually destined for the tissue itself, although many vessels may permeate one of its forms, the areolar tissue, carrying blood to other structures. In white fibrous tissue the blood-vessels usually run parallel to the longitudinal bundles and between them, sending transverse communicating branches across, and in some forms, as the periosteum and dura mater, being fairly numerous. In the yellow elastic tissue the blood-vessels also run between the fibres, and do not penetrate them. *Lymphatic* vessels are very numerous in most forms of connective tissue, especially in the areolar tissue beneath the skin and the mucous and serous surfaces. They are also found in abundance in the sheaths of tendons, as well as in the tendons themselves. *Nerves* are to be found in the white fibrous tissue, where they terminate in a special manner; but it is doubtful whether any nerves terminate in areolar tissue; at all events, they have not yet been demonstrated, and the tissue is possessed of very little sensibility.

Development of Connective Tissue.—Fibrous connective tissue is developed from embryonic connective-tissue cells derived from the mesoblast. At an early period of development it consists of nucleated cells and a muco-albuminous fluid, which subsequently becomes a pellucid jelly and forms the ground-substance. In this ground-substance the two varieties of fibres become developed. As to the manner in which they do so, there are two theories, some believing that they are developed from the protoplasm of the cells, others that they are formed by a deposit in the ground-substance. In the former case the protoplasm of the cells is converted wholly into elementary fibres, the nucleus disappearing; or else the peripheral part of the protoplasm produces the fibrous tissue, the original cell growing again to its original size, and then throwing off a fresh portion to form a new cell, and itself persisting in contact with the fibres it has formed as a permanent connective-tissue corpuscle.

Yellow elastic fibres are said by some to be formed by the processes of stellate embryonal cells, which, joining with processes of other cells, form the elastic fibres.

Three special forms of connective tissue must be described: the mucoid, the lymphoid or retiform, and basement-membranes.

1. The **mucoid** or **gelatinous** exists chiefly in the "jelly of Wharton," which forms the bulk of the umbilical cord and in some other situations in the fœtus, as in the pulp of young teeth and in certain stages of the development of connective tissue in various regions. In the adult the vitreous humor of the eye is formed of the same material. This tissue consists of nucleated cells, which branch and become connected so as to form trabeculæ, in which is contained a jelly-like substance containing the chemical principle of mucus, or *mucin*, and in smaller quantities albumen, but no gelatin. Sometimes, as in the vitreous humor of the eye, the cells disappear and the jelly only remains.

2. **Retiform, adenoid,** or **lymphoid** connective tissue (Fig. 18) is found extensively in many parts of the body, often surrounding the minute blood-vessels and forming the commencement of lymphatic channels. It is formed of an interlacement of very fine fibres, at the nodal points of which stellate cells are situated. The interstices of the fibres are filled with the rounded granular corpuscles of the lymph. The *neuroglia*, or fine gelatinous connective tissue which supports the nervous elements in the cerebro-spinal axis and in the retina, is regarded as a modified form of the retiform connective tissue.

FIG. 18.

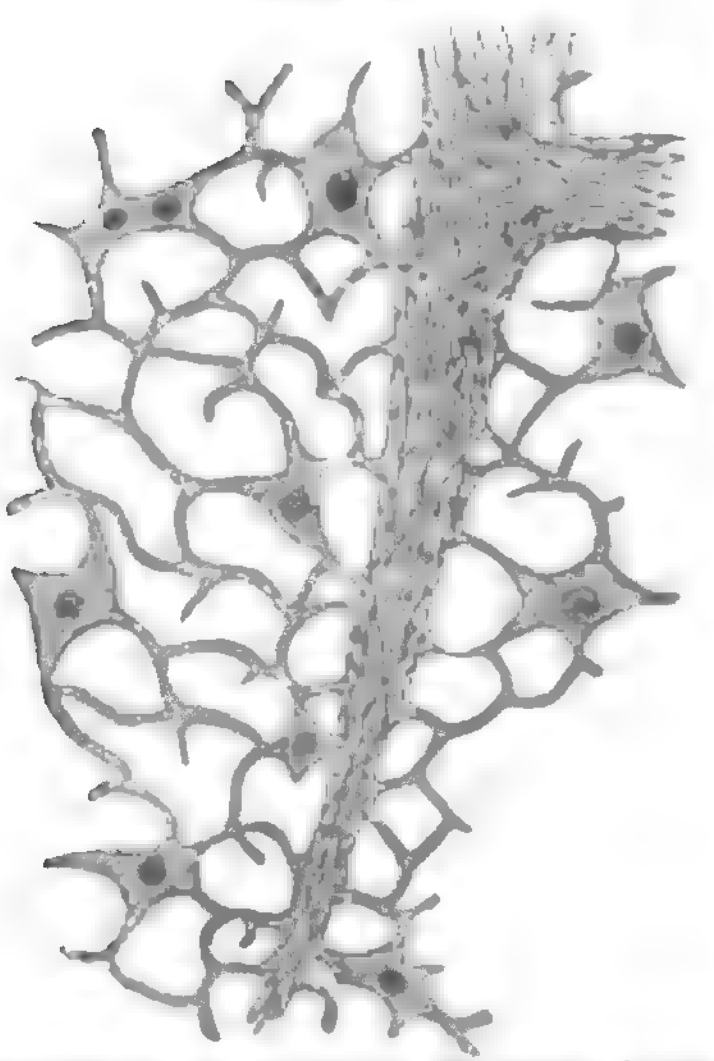

Retiform Connective Tissue, from the cortical part of the lymphatic glands.

3. **Basement-membranes,** formerly described as homogeneous membranes, are really a form of connective tissue. They constitute the supporting membrane, or membrana propria, supporting the epithelium of mucous membranes or secreting glands, and in other situations. By means of staining with nitrate of silver they may be shown to consist of flattened cells in close apposition, and form therefore an example of an epithelioid arrangement of connective-tissue cells.

Adipose Tissue.—In almost all parts of the body the ordinary areolar tissue contains a variable quantity of adipose or fatty tissue. The principal situations where it is not found are the subcutaneous tissue of the eyelids, the penis and scrotum, the nymphæ, within the cavity of the cranium, and in the lungs, except near their roots. Nevertheless, its distribution is not uniform, in some parts being collected in great abundance, as in the subcutaneous tissue, especially of the abdomen, around the kidneys, on the surface of the heart between the furrows, and in some other situations. Lastly, fat enters largely into the formation of the marrow of bones. A distinction must, however, be made between fat and adipose tissue, the latter being a distinct tissue—the former an oily matter, which in addition to forming adipose tissue is also widely present in the body, as in the fat of the brain and liver and in the blood and chyle, etc.

Fig. 19.

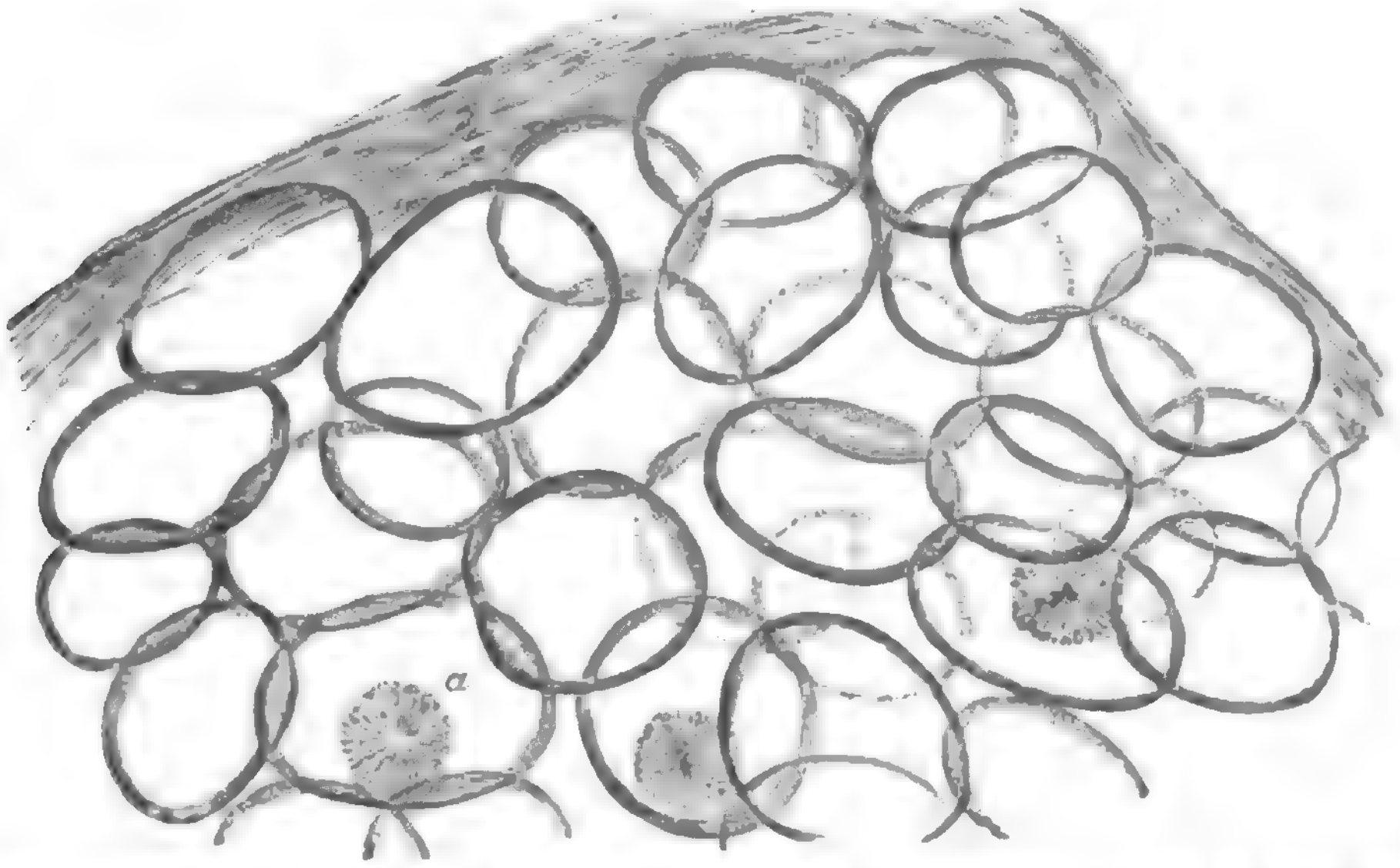

Adipose Tissue (high power): *a*, star-like appearance, from crystallization of fatty acids.

Fig. 20.

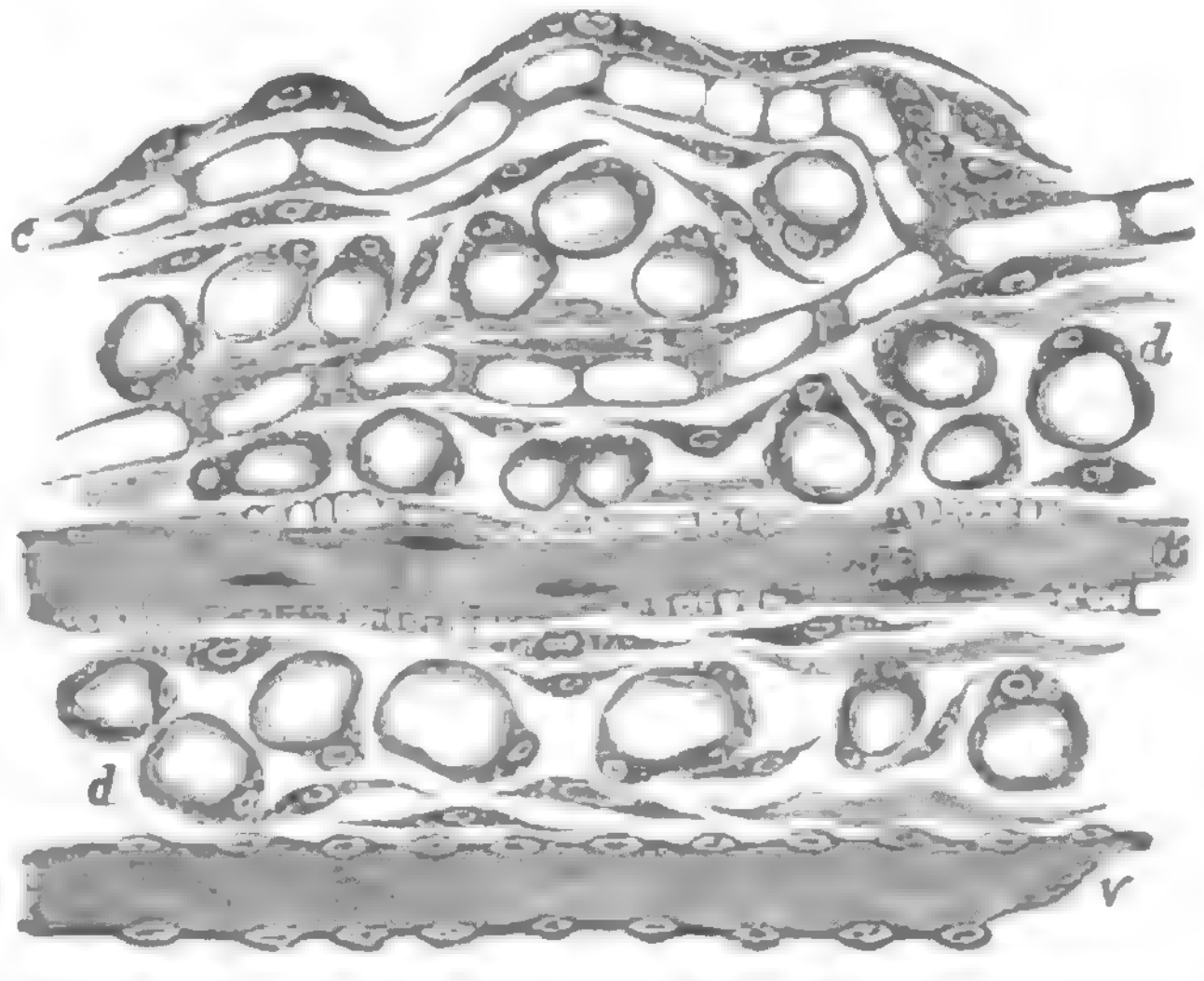

Development of Fat (Klein and Noble Smith): *a*, minute artery; *v*, minute vein; *c*, capillary blood-vessels in the course of formation: they are not hollowed out yet completely, there being still left in them protoplasmic septa; *d*, the ground-substance, containing numerous nucleated cells, some of which are more distinctly branched and flattened than others, and appear therefore more spindle-shaped.

Adipose tissue (Fig. 19) consists of a number of vesicles varying in size, but of about the average diameter of $\frac{1}{500}$ of an inch. They are formed of an exceedingly delicate structureless membrane filled with fatty matter, which is liquid during life, but becomes solidified after death. They are round or spherical where they have not been subjected to pressure; otherwise they assume a more or less angular outline. A nucleus is always present, and can be easily demonstrated by staining with logwood; in the natural condition it is so compressed by the contained oily matter as to be scarcely recognizable. These fat-cells are contained in clusters in the areolar of fine connective tissue, and are held together mainly by a network of capillary blood-vessels, which are distributed to them.

Fat is an inorganized substance, consisting of a liquid material (glycerin) in combination with certain fatty acids, stearic, palmitic, and oleic. Sometimes the acids separate spontaneously before the fat is examined, and are seen under the microscope in a crystalline form, as in Fig. 19, *a*. By boiling the tissue in ether or strong alcohol, the fat may be extracted from the vesicle, which is then seen empty and shrunken.

Fat is said to be first detected in the human embryo about the fourteenth week. According to Klein, the fat-cells are formed by the transformation of the protoplasmic connective-tissue corpuscles, into which small globules of fat find their way, and increase until they distend the corpuscle into the thin mantle of protoplasm which forms the cell-wall, and in which its nucleus is still to be seen (Fig. 20). Others of the connective-tissue corpuscles are transformed into the vessels and the lymphatic tissue which accompanies the vessels.

PIGMENT.

In various parts of the body *pigment* is found; most frequently in epithelium-cells and the cells of connective tissue. Pigmented epithelial cells are found forming the external layer of the retina (Fig. 21) and on the posterior surface of the iris. Pigment is also found in the epithelial cells of the deeper layers of the cuticle in some parts of the body, such as the areola of the nipple and in colored patches of skin, and especially in the skin of the colored races, and also in hair. It is also found in the epithelial cells of the olfactory regions and of the membranous labyrinth of the ear.

FIG. 21.



Pigment-cells of Retina.

In the connective-tissue cells pigment is frequently met with in the lower vertebrates. In man it is found in the choroid coat of the eye, and in the iris of all but the light-blue eyes and the albino. It is also occasionally met with in the cells of retiform tissue and in the pia mater of the upper part of the spinal cord. These cells are characterized by their larger size and branched processes, which, as well as the body of the cells, are filled with granules. The pigment consists of dark-brown or black granules of very small size, closely packed together within the cells, but not invading the nucleus. Occasionally the pigment is yellow, and when occurring in the cells of the cuticle constitutes "freckles."

CARTILAGE.

Cartilage is a non-vascular structure which is found in various parts of the body—in adult life chiefly in the joints, in the parietes of the thorax, and in various tubes, such as the air-passages, nostrils, and ears, which are to be kept permanently open. In the fœtus at an early period the greater part of the skeleton is cartilaginous. As this cartilage is afterward replaced by bone, it is called *temporary*, in contradistinction to that which remains unossified during the whole of life, and which is called *permanent*.

Cartilage is divided, according to its minute structure, into true or hyaline cartilage, fibrous or fibro-cartilage, and yellow or elastic or reticular cartilage. Besides these varieties met with in the adult human subject, there is a variety called *cellular cartilage*, which consists entirely, or almost entirely, of cells, united in some cases by a network of very fine fibres, in other cases apparently destitute of any intercellular substance. This is found in the external ear of rats, mice, and some other animals, and is present in the chorda dorsalis of the human embryo, but is not found in any other human structure. The various cartilages in the body are also classified, according to their function and position, into articular, interarticular, costal, and membraniform.

FIG. 22.

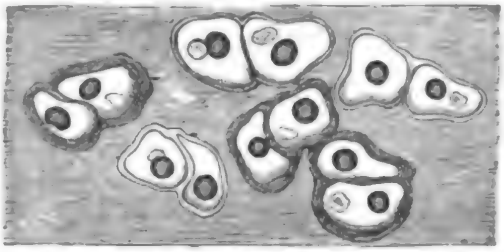

Human Cartilage-cells, from the Cricoid Cartilage (magnified 350 times).

Hyaline cartilage, which may be taken as the type of this tissue, consists of a gristly mass of a firm consistence, but of considerable elasticity and of a pearly-bluish color. Except where it coats the articular ends of bones it is enveloped in a fibrous membrane, the *perichondrium*, from the vessels of which it imbibes its nutritive fluids, being itself destitute of blood-vessels; nor have any nerves been traced into it. Its intimate structure is very simple. If a thin slice is examined under the microscope, it will be found to consist of cells of a rounded or bluntly angular form lying in groups of two or more in a granular or almost homogeneous matrix (Fig. 22). The cells when arranged in groups of two or three have generally a straight outline where they are in contact with each other, and in the rest of their circumference are rounded. The cell-contents consist of clear translucent protoplasm containing minute granules, and imbedded in this are one or two nuclei, having usually a granular appearance, but occasionally being clear and occupied by one or more nucleoli. The cells are imbedded in cavities in the matrix called *cartilage lacunæ*, which are lined by a distinct transparent membrane called the *capsule*. Each lacuna is generally occupied by a single cell, but during the division of the cells it may contain two, four, or eight cartilage-cells. By boiling the cartilage for some hours and treating it with concentrated mineral acid, the capsule may be freed from the matrix, and can then be demonstrated as a distinct vesicle containing the cells. By exposure to the action of an electric shock the cell assumes a jagged outline and shrinks away from the interior of the capsule.

The matrix is transparent and apparently without structure, or else presents a dimly granular appearance, like ground glass. According to some observers, after prolonged maceration bundles of fine connective-tissue fibres may be noticed in it. It is believed by some histologists that the matrix is permeated by a number of fine channels which connect the lacunæ with each other, and that these canals communicate with the lymphatics of the perichondrium, and thus the structure is permeated with a current of nutritious fluid.

The articular cartilages, the temporary cartilages, and the costal cartilages are all of the hyaline variety. They present minute differences in the size and shape of their cells and in the arrangement of their matrix. In the articular cartilages, which show no tendency to ossification, the matrix is finely granular under a high power; the cells and nuclei are small and are disposed parallel to the surface in the superficial part, while nearer to the bone they become vertical. Articular cartilages have a tendency to split in a vertical direction, probably from some peculiarity in the intimate structure or arrangement of the component parts of the matrix. In disease this tendency to a fibrous splitting becomes very manifest. Articular cartilage is not covered by perichondrium, at least on its free surface, where it is exposed to friction, though a layer of connective tissue can be traced in the adult over a small part of its circumference continuous with that of the synovial membrane; and here the cartilage-cells are more or less branched, and pass insensibly into the branched connective-tissue corpuscles of the synovial membrane.

Articular cartilage forms a thin incrustation upon the joint-surfaces of the bones, and its elasticity enables it to break the force of any concussion, whilst its smoothness affords ease and freedom of movement. It varies in thickness according to the shape of the bone on which it lies; where this is convex, the cartilage is thickest at the centre, where the greatest pressure is received; and the reverse is the case on the concave surfaces of the bones. Articular cartilage appears to imbibe its nutriment partly from the vessels of the neighboring synovial membrane, partly from those of the bone upon which it is implanted. Mr. Toynbee has shown that the minute vessels of the cancellous tissue as they approach the articular lamella dilate and form arches, and then return into the substance of the bone.

Temporary cartilage and the process of its ossification will be described with Bone.

In the **costal cartilages** the cells and nuclei are large and the matrix has a tendency to fibrous striation, especially in old age (Fig. 23). These cartilages are also very prone to ossify. In the thickest parts of the costal cartilages a few large vascular channels may be detected. This appears at first sight an exception to the statement that cartilage is a non-vascular tissue, but is not so really, for the vessels give no branches to the cartilage-substance itself, and the channels may rather be looked upon as involutions of the perichondrium. The ensiform cartilage may be regarded as one of the costal cartilages, and the cartilages of the nose and of the larynx and trachea resemble them in microscopical characters, except the epiglottis and cornicula laryngis, which are of the reticular variety. The hyaline cartilages, especially in adult and advanced life, are prone to calcify; that is, to say, to have their matrix permeated by the salts of lime without any appearance of true bone. The process of calcification occurs also, and still more frequently, according to Rollett, in such cartilages as those of the trachea, which are prone afterward to conversion into true bone.

FIG. 23.

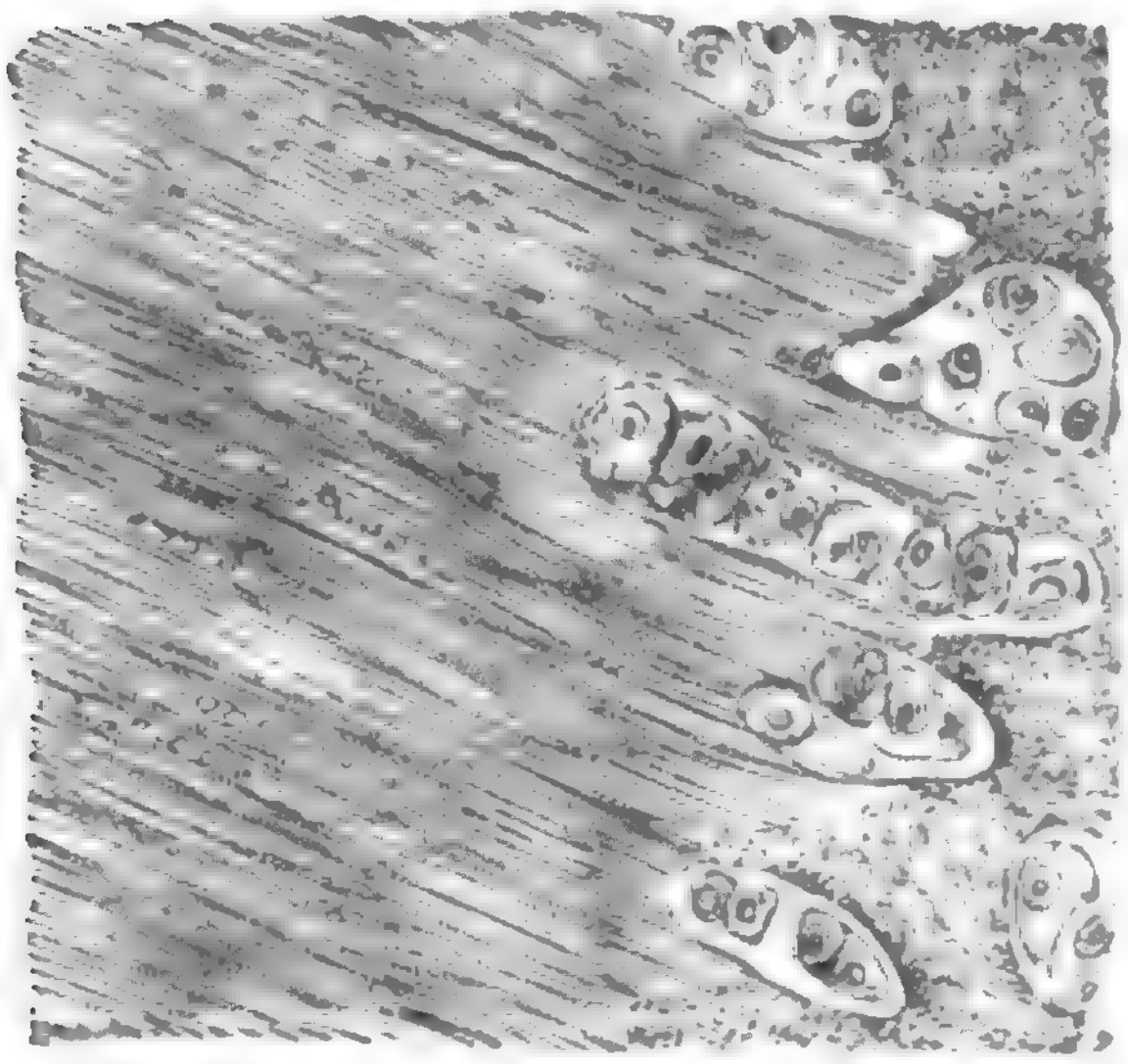

Costal Cartilage from a Man seventy-six years of age, showing the development of fibrous structure in the matrix. In several portions of the specimen two or three generations of cells are seen enclosed in a parent cell-wall (high power).

Fibro-cartilage consists of a mixture of white fibrous tissue and cartilaginous tissue in various proportions; it is to the first of these two constituents that its flexibility and toughness are chiefly owing, and to the latter its elasticity. When examined under the microscope it is found to be made up of fibrous connective tissue arranged in bundles, with cartilage-cells between the bundles, which to a certain extent resemble tendon-cells, but may be distinguished from them by being surrounded by an investing capsule and by their being less flattened (Fig. 24). The fibro-cartilages admit of arrangement into four groups—interarticular, connecting, circumferential, and stratiform.

FIG. 24.

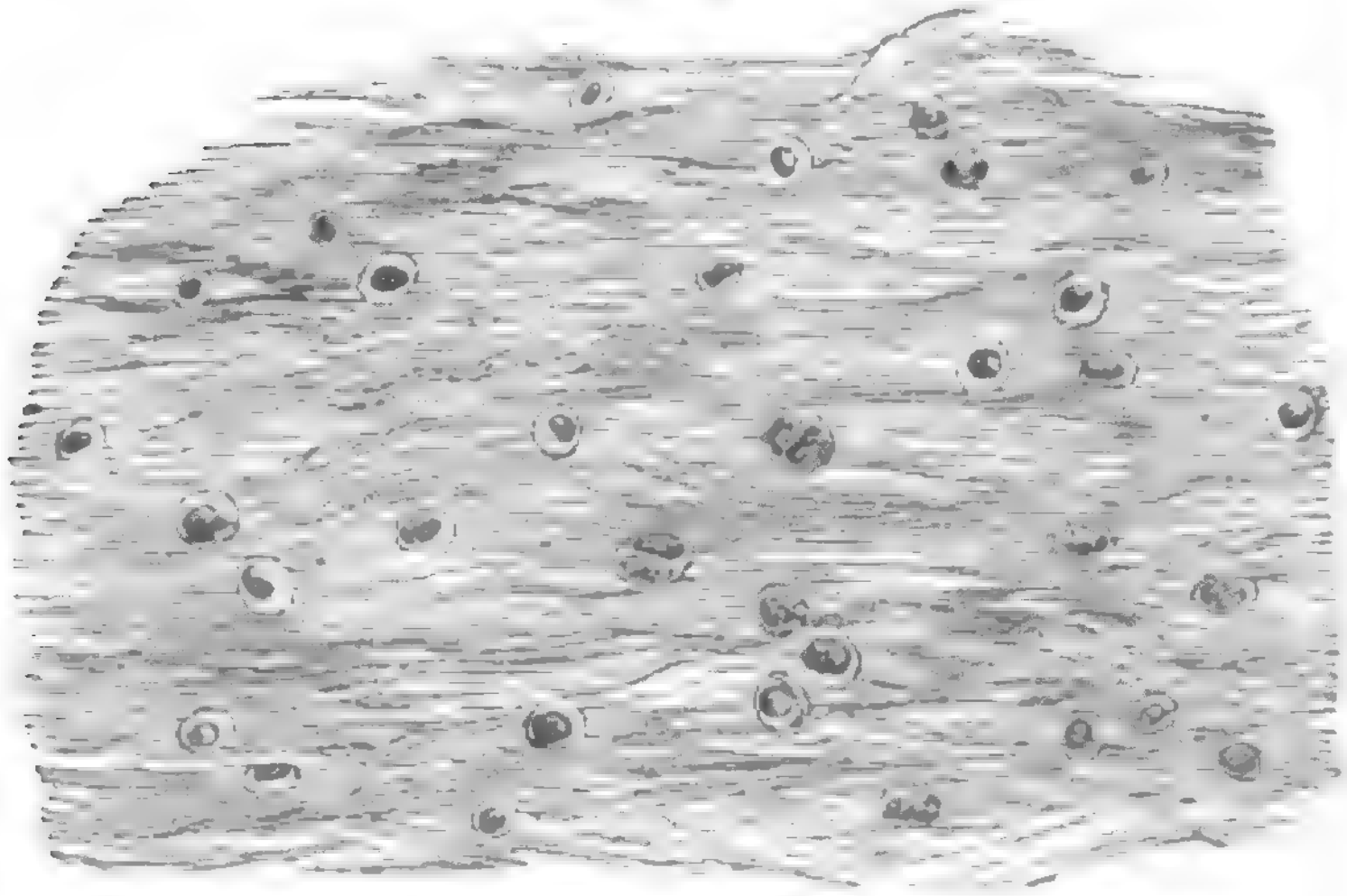

White Fibrous Cartilage from the Semilunar Disk of the Patellar Joint of an Ox (magnified 100 times).

The interarticular fibro-cartilages (*menisci*) are flattened fibro-cartilaginous plates, of a round, oval, triangular, or sickle-like form, interposed between the articular cartilages of certain joints. They are free on both surfaces, thinner toward their centre than at their circumference, and held in position by their margins and extremities being connected to the surrounding ligaments. The synovial membrane of the joint is prolonged over them a short distance from their attached margins. They are found in the temporo-maxillary, sterno-clavicular, acromio-clavicular, wrist, and knee joints. These cartilages are usually found in those joints which are most exposed to violent concussion and subject to frequent movement. Their use is to maintain the apposition of the opposed surfaces in their various motions, to increase the depth of the articular surfaces and give ease to the gliding movement, to moderate the effects of great pressure, and to deaden the intensity of the shocks to which the parts may be submitted. Professor Humphry has pointed out that these interarticular fibro-cartilages serve an important purpose in increasing the variety of movements in a joint. Thus, in the knee-joint there are two kinds of motion—viz. angular movement and rotation—although it is a hinge-joint, in which, as a rule, only one variety of motion is permitted; the former movement taking place between the condyles of the femur and the interarticular cartilage, the latter between the cartilage and the head of the tibia. So, also, in the temporo-maxillary joint, the upward and downward movement of opening and shutting the mouth takes place between the cartilage and the jaw-bone, the grinding movement between the glenoid cavity and the cartilage, the latter moving with the jaw-bone.

The **connecting fibro-cartilages** are interposed between the bony surfaces of those joints which admit of only slight mobility, as between the bodies of the vertebræ and the pubic bones. They form disks which adhere closely to both of the opposed bones, and are composed of concentric rings of fibrous tissue, with cartilaginous laminæ interposed, the former tissue predominating toward the circumference, the latter toward the centre.

The **circumferential fibro-cartilages** consist of a rim of fibro-cartilage which surrounds the margin of some of the articular cavities, as the cotyloid cavity of the hip and the glenoid cavity of the shoulder; they serve to deepen the articular surface and to protect the edges of the bone.

The **stratiform fibro-cartilages** are those which form a thin layer in osseous grooves through which the tendons of certain muscles glide. Small masses of fibro-cartilages are also developed in the tendons of certain muscles where they glide over bones, as in the tendons of the peroneus longus and the tibialis posticus.

The **yellow, or reticular, elastic cartilage** is found in the human body in the auricle of the external ear, the Eustachian tubes, the cornicula laryngis, and the epiglottis. It consists of cartilage-cells and a matrix, the latter being pervaded in every direction, except immediately around each cell, by a network of yellow elastic fibres branching and anastomosing in all directions (Fig. 25). The fibres resemble those of yellow elastic tissue, both in appearance and in being unaffected by acetic acid; and according to Rollett their continuity with the elastic fibres of the neighboring tissue admits of being demonstrated.

FIG. 25.

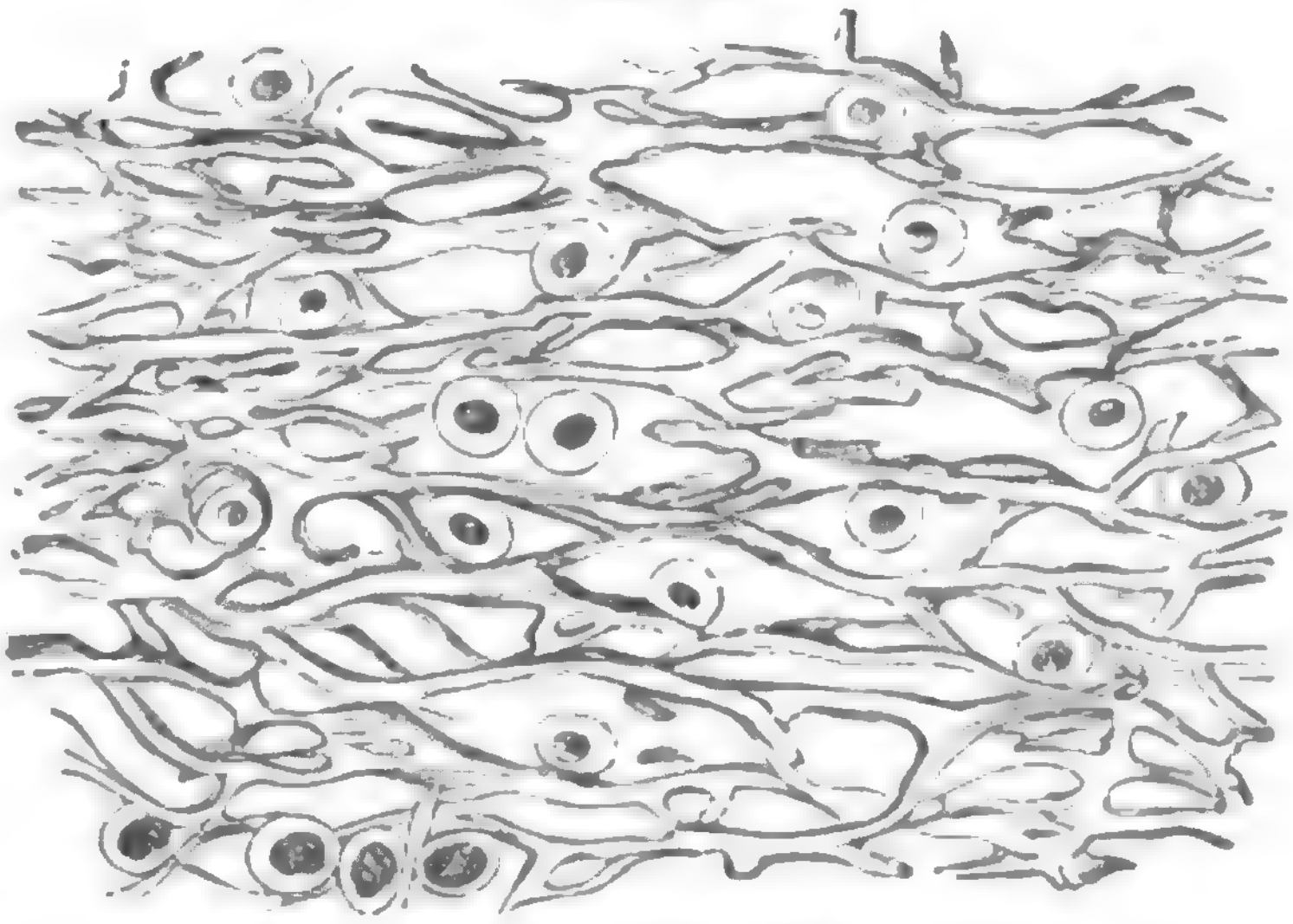

Yellow Cartilage, Ear of Horse (high power.)

The distinguishing feature of cartilage as to its chemical composition is that it yields on boiling a substance called *chondrin*, very similar to gelatin, but differing from it in not being precipitated by tannin. According to Kühne, there is a small amount of gelatin in hyaline cartilage. Virchow believes that the semilunar disks in the knee-joint are wrongly denominated cartilages, since they yield no chondrin on boiling; and he appears to regard them as a modification of a tendinous structure, which, however, agrees with the cartilages in the important particular of being non-vascular.

BONE.

Structure and Physical Properties of Bone.—Bone is one of the hardest structures of the animal body; it possesses also a certain degree of toughness and elasticity. Its color, in a fresh state, is of a pinkish-white externally and deep red within. On examining a section of any bone it is seen to be composed of two kinds of tissue, one of which is dense and *compact* in texture, like ivory; the other consists of slender fibres and lamellæ, which join to form a reticular structure; this, from its resemblance to lattice-work, is called *cancellous.* The compact tissue is always placed on the exterior of the bone; the cancellous is always internal. The relative quantity of these two kinds of tissue varies in different bones and in different parts of the same bone, as strength or lightness is requisite. Close examination of the compact tissue shows it to be extremely porous, so that the difference in structure between it and the cancellous tissue depends merely upon the different amount of solid matter and the size and number of spaces in each, the cavities being small in the compact tissue and the solid matter between them abundant, while in the cancellous tissue the spaces are large and the solid matter in smaller quantity.

Bone during life is permeated by vessels and is enclosed in a fibrous membrane, the *periosteum*, by means of which many of these vessels reach the hard tissue. If the periosteum is stripped from the surface of the living bone, small bleeding points are seen which mark the entrance of the periosteal vessels; and on section during life every part of the bone will be seen to exude blood from the minute vessels which ramify in it. The interior of the bones of the limbs presents a cylindrical cavity filled with marrow and lined by a highly vascular areolar structure called the *medullary membrane* or *internal periosteum*, which, however, is rather the areolar envelope of the cells of the marrow than a definite membrane.

The **Periosteum** adheres to the surface of the bones in nearly every part, excepting at their cartilaginous extremities. Where strong tendons or ligaments are attached to the bone the periosteum is incorporated with them. It consists of two layers closely united together, the outer one formed chiefly of connective tissue, containing occasionally a few fat-cells; the inner one, of elastic fibres of the finer kind, forming dense membranous networks, which can be again separated into several layers. In young bones the periosteum is thick and very vascular, and is intimately connected at either end of the bone with the epiphysial cartilage, but less closely with the shaft, from which it is separated by a layer of soft blastema containing a number of granular corpuscles or "osteoblasts," in which ossification proceeds on the exterior of the young bone. Later in life the periosteum is thinner, less vascular, and the osteoblasts have become converted into an epithelial layer, which is separated from the rest of the periosteum in many places by cleft-like spaces, which are supposed to serve for the transmission of lymph. The periosteum serves as a nidus for the ramification of the vessels previous to their distribution in the bone; hence the liability of bone to exfoliation or necrosis when denuded of this membrane by injury or disease. Fine nerves and lymphatics, which generally accompany the arteries, may also be demonstrated in the periosteum.

The **Marrow** not only fills up the cylindrical cavity in the shafts of the long bones, but also occupies the spaces of the cancellous tissue and extends into the larger bony canals (Haversian canals) which contain the blood-vessels. It differs in composition in different bones. In the shafts of adult long bones the marrow is of a *yellow* color, and contains, in 100 parts, 96 of fat, 1 of areolar tissue and vessels, and 3 of fluid, with extractive matter, and consists of a matrix of fibrous tissue supporting numerous blood-vessels and cells, most of which are fat-cells, but some few are "marrow-cells." In the flat and short bones, in the articular ends of the long bones, in the bodies of the vertebræ, in the cranial diploë, and in the sternum and ribs, it is of a *red* color, and contains, in 100 parts, 75 of water and 25 of solid matter, consisting of albumen, fibrin, extractive matter, salts, and a mere trace of fat. The red marrow consists of a small quantity of areolar tissue, blood-vessels, and numerous cells, some few of which are fat-cells, but the great majority roundish nucleated cells, the true "marrow-cells" of Kölliker. These marrow-cells resemble in appearance the white corpuscles of the blood, and, like them, possess amœboid movements. Occasionally they may be seen to possess a slightly pinkish hue, and it has been stated by Neumann that they are then in a transitional stage between marrow-cells and red blood-corpuscles, and that one of the sources of blood-globules is the marrow of the spongy bones.

Giant-cells (*myelo-plaques, osteoclasts*), large, multinucleated, protoplasmic masses, are also to be found in both sorts of adult marrow.

Vessels of Bone.—The blood-vessels of bone are very numerous. Those of the compact tissue are derived from a close and dense network of vessels ramifying in the periosteum. From this membrane vessels pass into the minute orifices in the compact tissue, running through the canals which traverse its substance. The cancellous tissue is supplied in a similar way, but by a less numerous set of larger vessels, which, perforating the outer compact tissue, are distributed to the cavities of the spongy portion of the bone. In the long bones numerous apertures may be seen at the ends near the articular surfaces, some of which give passage to the arteries of the larger set of vessels referred to; but the most numerous and largest apertures are for the veins of the cancellous tissue, which run separately from the arteries. The medullary canal in the shafts of the long bones is supplied by one large artery (or sometimes more), which enters the bone at the nutrient foramen (situated in most cases near the centre of the shaft), and perforates obliquely the compact structure. The medullary or nutrient artery, usually accompanied by one or two veins, sends branches upward and downward to supply the medullary membrane which lines the central cavity and the adjoining canals. The ramifications of this vessels anastomose with the arteries both of the cancellous and compact tissues.[1] In most of the flat and in many of the short spongy bones one or more large apertures are observed, which transmit to the central parts of the bone vessels corresponding to the medullary arteries and veins. The veins emerge from the long bones in three places (Kölliker): (1) by one or two large veins which accompany the artery; (2) by numerous large and small veins at the articular extremities; (3) by many small veins which arise in the compact substance. In the flat cranial bones the veins are large, very numerous, and run in tortuous canals in the diploic tissue, the sides of the canals being formed by a thin lamella of bone perforated here and there for the passage of branches from the adjacent cancelli. The same condition is also found in all cancellous tissue, the veins being enclosed and supported by osseous structure, and having exceedingly thin coats. When the bony structure is divided, the vessels remain patulous, and do not contract in the canals in which they are contained. Hence the constant occurrence of purulent absorption after amputation in those cases where the stump becomes inflamed and the cancellous tissue is infiltrated and bathed in pus.

Lymphatic Vessels, in addition to those found in the periosteum, have been traced by Cruikshank into the substance of bone, and Klein describes them as running in the Haversian canals. *Nerves* are distributed freely to the periosteum, and accompany the nutrient arteries into the interior of the bone. They are said by Kölliker to be most numerous in the articular extremities of the long bones, in the vertebræ, and in the larger flat bones.

Minute Anatomy.—The intimate structure of bone, which in all essential particulars is identical in the compact and cancellous tissue, is most easily studied in a transverse section from the compact wall of one of the long bones after maceration, such as is shown in Fig. 26.

If this is examined with a rather low power, the bone will be seen to be map-

---

[1] This view is not, however, entertained by all anatomists. Mr. Charles Stuart believes that, in many cases at all events, the vessels of the periosteum supply only the circumferential lamellæ on the surface of the shaft of the bone, which are formed from this membrane, and that the whole of the rest of its structure is supplied by the vessels of the medullary membrane, and that only very exceptionally does any anastomosis take place between the two sets of vessels. Certainly, in one microscopic section which I had an opportunity of examining through the kindness of Mr. Stuart this appeared to be the case.

Fig. 26.

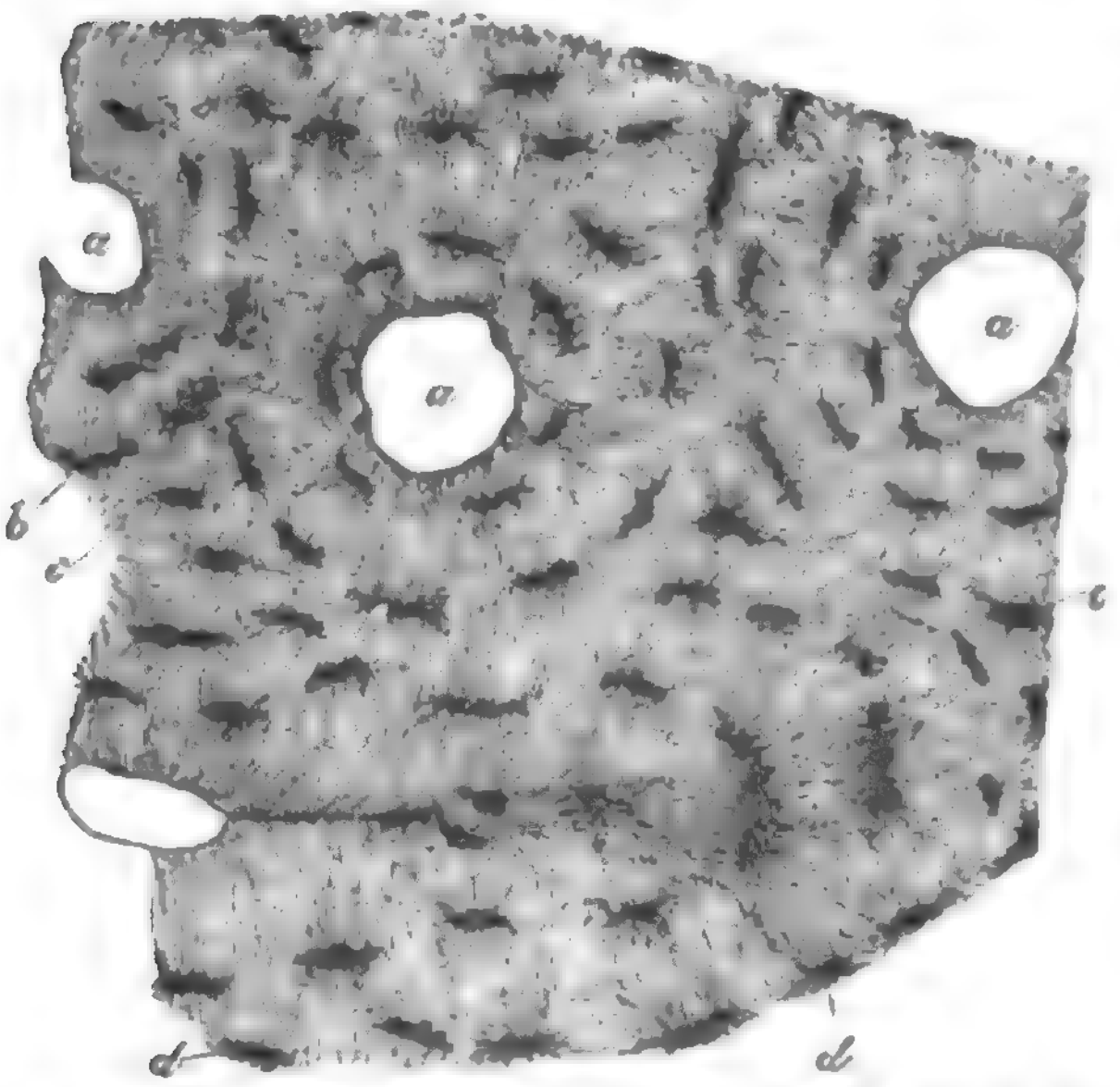

From a Transverse Section of the Diaphysis of the Humerus (magnified 350 times): *a*, Haversian canals; *b*, lacunæ, with their canaliculi in the lamellæ of these canals; *c*, lacunæ of the interstitial lamellæ; *d*, others at the surface of the Haversian systems, with canaliculi going off from one side.

ped out into a number of circular districts, each one of which consists of a central hole surrounded by a number of concentric rings. These districts are termed *Haversian systems;* the central hole is an *Haversian canal*, and the rings around are layers of bone-tissue arranged concentrically around the central canal, and termed *lamellæ*. Moreover, on closer examination it will be found that between these lamellæ, and therefore also arranged concentrically around the central canal, are a number of little dark specks, the *lacunæ*, and that these lacunæ are connected with each other and with the central Haversian canal by a number of fine dark lines which radiate like the spokes of a wheel, and are called *canaliculi*. All these structures, the Haversian canal, the concentric lamellæ, the lacunæ, and the canaliculi, may be seen in any single Haversian system forming a circular district round a central canal. Between these circular systems, filling in the irregular intervals which are left between them, are other lamellæ, with their lacunæ and canaliculi, running in various directions, but more or less curved (Fig. 27). These are termed *interstitial* lamellæ. Again, other lamellæ, for the most part found on the surface of the bone, are arranged concentrically to the circumference of bone, constituting, as it were, a single Haversian system of the whole bone, of which the medullary cavity would represent the Haversian canal. These latter lamellæ are termed *circumferential*, or by some authors *primary* or *fundamental*, lamellæ, to distinguish them from those laid down around the axis of the Haversian canals, which are then termed secondary or special lamellæ.

Fig. 27.



Transverse Section of Compact Tissue of Bone (magnified about 150 diameters—Sharpey).

The *Haversian canals*, seen as round holes in a transverse section of bone at or about the centre of each Haversian system, may be demonstrated to be true canals if a longitudinal section be made, as in Fig. 29. It will then be seen that these round holes are tubes cut across, which run parallel with the longitudinal axis of the bone for a short distance, and then branch and communicate. They vary considerably in size, some being as large as $\frac{1}{200}$ of an inch in diameter; the average size being, however, about $\frac{1}{500}$ of an inch. Near the medullary cavity the canals are larger than those near the surface of the bone. Each canal contains a blood-vessel, one or two lymphatics, and the larger ones also contain a small quantity of marrow. Those on the surface of the bone open by minute orifices, and those near the medullary cavity open in the same way into this space, so that the whole of the bone is permeated by a system of blood-vessels running through the bony canals in the centre of the Haversian systems.

The *lamellæ* are thin plates of bone-tissue encircling the central canal, and might be compared, for the sake of illustration, to a number of sheets of paper pasted one after another around a central hollow cylinder. After macerating a piece of bone in dilute mineral acid these lamellæ may be stripped off in a longitudinal direction as thin films. If one of these is examined with a high power under the microscope, it will be found to be composed of a finely reticular structure, presenting the appearance of lattice-work made up of very slender, transparent fibres, decussating obliquely, and coalescing at the points of intersection so as to form an exceedingly delicate network. In many places the various lamellæ may be seen to be held together by tapering fibres, which run obliquely through them, pinning or bolting them together. These fibres were first described by Sharpey, and were named by him *perforating fibres.*

The *lacunæ* are situated between the lamellæ and consist of a number of oblong spaces. In an ordinary microscopic section, viewed by transmitted light, they appear as dark, oblong, opaque spots, and were formerly believed to be solid cells. Subsequently, when it was seen that the Haversian canals were channels which lodge the vessels of the part, and the canaliculi minute tubes by which the plasma of the blood circulates through the tissue, it was taught that the lacunæ were hollow spaces filled during life with the same fluid, and only lined (if lined at all) by a delicate membrane. But this view appears also to be delusive. Examination of the structure of the bone when recent led Virchow to believe that the lacunæ are really filled up during life with a nucleated cell, the processes from which pass down the canaliculi—a view which is now universally received (Fig. 28). It is by means of these cells that the fluids necessary for nutrition are brought into contact with the ultimate tissue of bone.

FIG. 28.

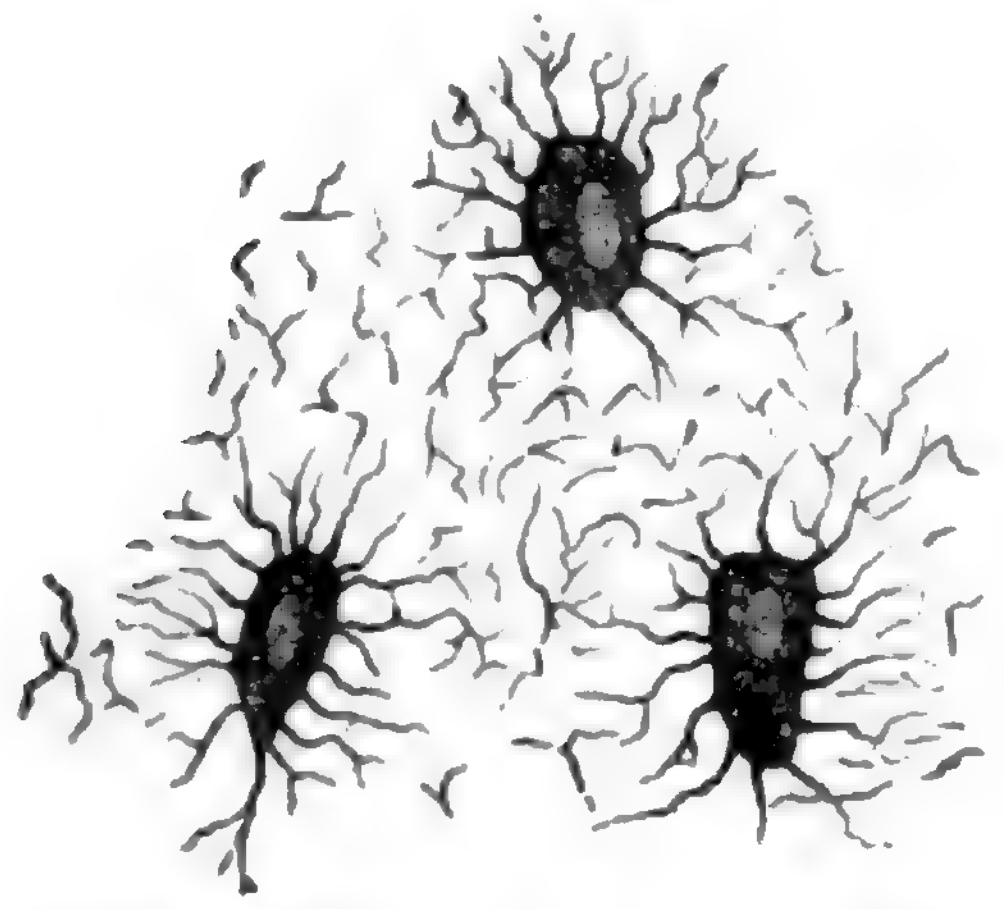

Nucleated Bone-cells and their Processes, contained in the bone-lacunæ and their canaliculi respectively (from a section through the vertebra of an adult mouse—Klein and Noble Smith).

FIG. 29.

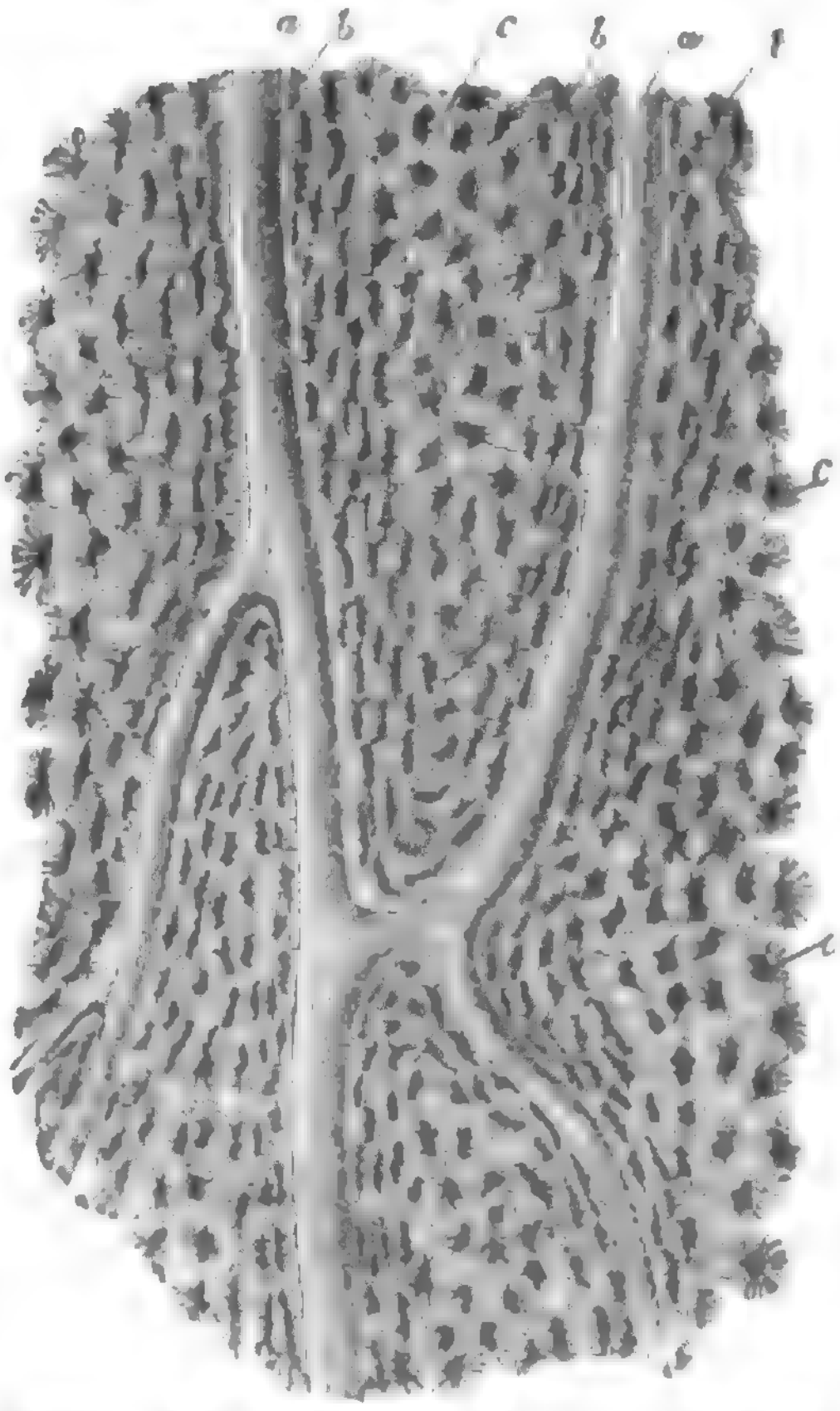

Section parallel to the surface from the Shaft of the Femur (magnified 100 times): *a*, Haversian canals; *b*, lacunæ seen from the side; *c*, others seen from the surface in lamellæ which are cut horizontally.

The *canaliculi* are exceedingly minute channels which pass *across* the lamellæ and connect the lacunæ with neighboring lacunæ and also with the Haversian canal. From this central canal a number of the canaliculi are given off, which radiate from it and open into the first set of lacunæ arranged around the Haversian canal between the first and second lamellæ. From these lacunæ a second set of canaliculi are given off, which pass outward to the next series of lacunæ, and so on until these reach the periphery of the Haversian system; here the canaliculi given off from the last series of lacunæ do not communicate with the lacunæ of neighboring Haversian systems, but after passing outward for a short distance form loops and return to their own lacunæ. Thus every part of an Haversian system is supplied with nutrient fluids derived from the vessels in the Haversian canals and traversing the canaliculi and lacunæ.

The *bone-cells* are contained in the lacunæ, which, however, they do not completely fill. They are flattened nucleated cells, which Virchow has shown are homologous with those of connective tissue. The cells are branched, and the branches, especially in young bones, pass with the canaliculi from the lacunæ.

If a longitudinal section be examined, as in Fig. 29, the appearances are identical. The appearance of concentric rings is replaced by that of lamellæ or rows of lacunæ parallel to the course of the Haversian canals, and these canals appear like half-tubes instead of circular spaces. The tubes are seen to branch and communicate, so that each separate Haversian canal runs only a short distance. In other respects the structure has much the same appearance as in transverse sections.

In sections of thin plates of bone (as in the walls of the cells which form the cancellous tissue) the Haversian canals are absent and the canaliculi open into the spaces of the cancellous tissue (medullary spaces), which thus have the same functions as the Haversian canals in the more compact bone.

Chemical Composition.—Bone consists of an animal and an earthy part intimately connected together.

The animal part of a bone may be obtained by immersing the bone for a considerable time in dilute mineral acid, after which process the bone comes out exactly the same shape as before, but perfectly flexible, so that a long bone (one of the ribs, for example) can easily be tied in a knot (Fig. 30). If now a transverse section be made (Fig. 31), the same general arrangement of the Haversian canals, lamellæ, lacunæ, and canaliculi is seen, though not so plainly as in the ordinary section.

[Fig. 30.

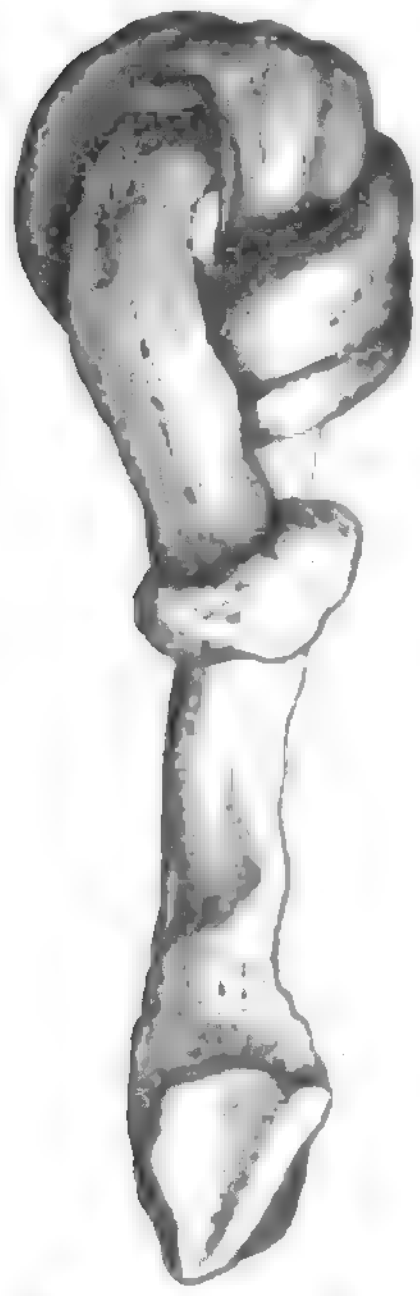

Fibula tied in a knot after maceration in a dilute acid (from a specimen preserved in spirits). (Dalton).]

Fig. 31.

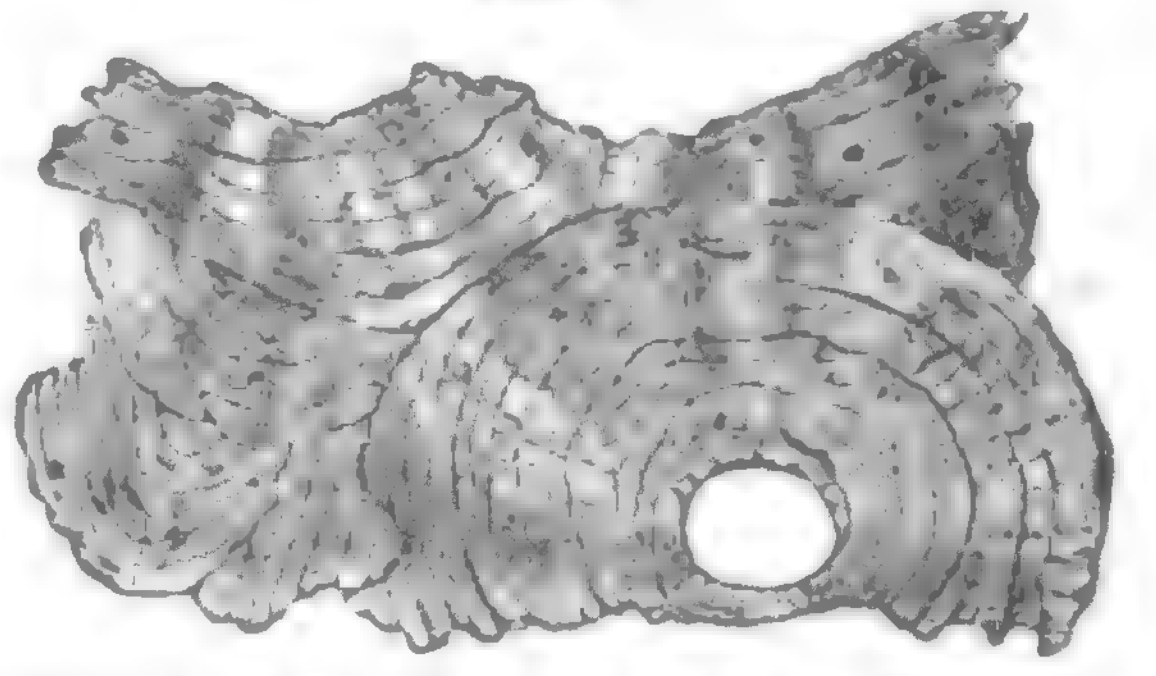

Section of Bone after the removal of the earthy matter by the action of acids.

The earthy part may be obtained separate by calcination, by which the animal mater is completely burnt out. The bone will still retain its original form, but it will be white and brittle, will have lost about one-third of its original weight, and will crumble down with the slightest force. The earthy matter confers on bone its hardness and rigidity, and the animal matter its tenacity.

The animal base is often called cartilage, but differs from it in structure, in the fact that it is softer and more flexible, and that when boiled with a high pressure it is almost entirely resolved into gelatin.

The organic constituent of bone forms about *one-third*, or 33.3 per cent.; the inorganic matter, *two-thirds*, or 66.7 per cent.; as is seen in the subjoined analysis of Berzelius:

Organic matter	Gelatin and blood-vessels	33.30
Inorganic or Earthy matter	Phosphate of lime	51.04
	Carbonate of lime	11.30
	Fluoride of calcium	2.00
	Phosphate of magnesia	1.16
	Soda and chloride of sodium	1.20
		100.00

Some chemists add to this about 1 per cent. of fat.

Some difference exists in the proportion between the two constituents of bone at different periods of life. In the child the animal matter predominates, whereas in aged people the bones contain a larger proportion of earthy matter, and the animal matter is deficient in quantity and quality. Hence in children it is not uncommon to find, after an injury to the bones, that they become bent or only partially broken, whereas in old people the bones are more brittle and fracture takes place more readily. Some of the diseases also to which bones are liable mainly depend on the disproportion between the two constituents of bone. Thus in the disease called rickets, so common in the children of the poor, the bones become bent and curved, either from the superincumbent weight of the body or under the action of certain muscles. This depends upon some defect of nutrition by which bone becomes deprived of its normal proportion of earthy matter, whilst the animal matter is of unhealthy quality. In the vertebræ of a rickety subject Dr. Bostock found in 100 parts 79.75 animal and 20.25 earthy matter.

DEVELOPMENT OF BONE.

Fig. 32.

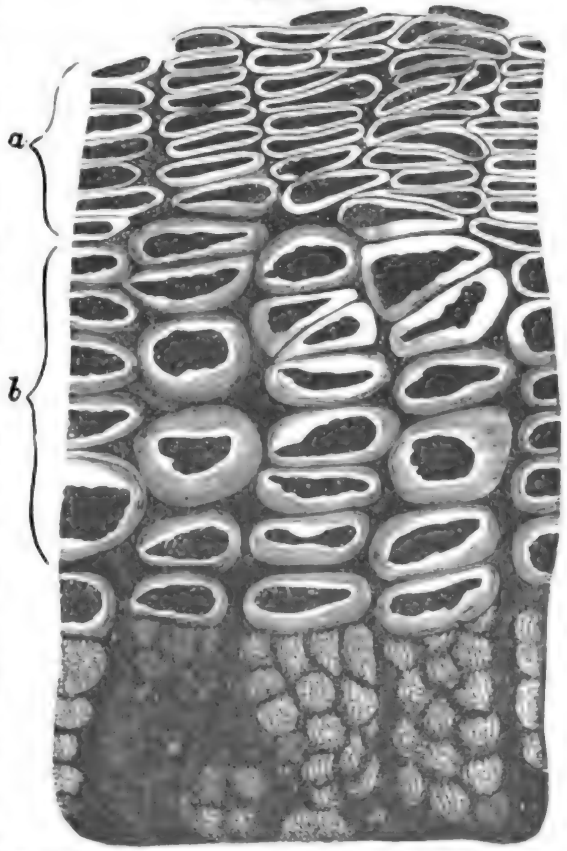

Longitudinal Section through the Ossifying Portion of a Long Bone in the Human Embryo: *a*, cartilaginous region; *b*, region of calcified matrix.

In the fœtal skeleton some bones, such as the long bones of the limbs, are cartilaginous; others, as the cranial bones, are membranous. Hence two kinds of ossification are described: the *intracartilaginous* and the *intramembranous;* and to these a third is sometimes added, the *subperiosteal*, which, however, is the same as the second, only taking place under different circumstances.

Intracartilaginous Ossification.—Just before ossification begins the bone is entirely cartilaginous, and in a long bone, which may be taken as an example, the process commences in the centre and proceeds toward the extremities, which for some time remain cartilaginous. Subsequently a similar process commences in one or more places in those extremities, and gradually extends through it. The extremity does not, however, become joined to the shaft of the bone until growth has ceased, but remains separated by a layer of cartilaginous tissue termed *epiphysial cartilage.*

The first step in the ossification of the cartilage is that the cartilage-cells, at the point where ossification is commencing, and which is termed a *centre of ossification*, enlarge and arrange themselves in rows (Fig. 32). The matrix in which they are imbedded increases in quantity, so that the cells become further separated from each other. A deposit of calcareous material now takes place in this matrix between the rows of cells, so that they now become separated from each other by longitudinal columns of calcified matrix, presenting a granular and opaque appearance. Here and there the matrix between two cells of the same row also becomes calcified, and thus we have transverse bars of calcified substance stretching across from one calcareous column to another. Thus we have longitudinal groups of the cartilage-cells enclosed in oblong cavities the walls of which are formed of calcified matrix. These cavities are called the *primary areolæ* (Sharpey).

At the same time that this process is going on in the centre of the cartilage of which the fœtal bone consists, certain changes are taking place on its surface. This is covered by a very vascular membrane, the *periosteum*, on the inner surface of which—that is to say, on the surface in contact with the cartilage—are a number of cells called *osteoblasts*. By the agency of these cells a thin layer of bony tissue is being formed between the periosteum and the cartilage by the *intramembranous* mode of ossification presently to be described. We have, then, in this first stage of ossification, two processes going on simultaneously: in the centre of the carti-

FIG. 33.

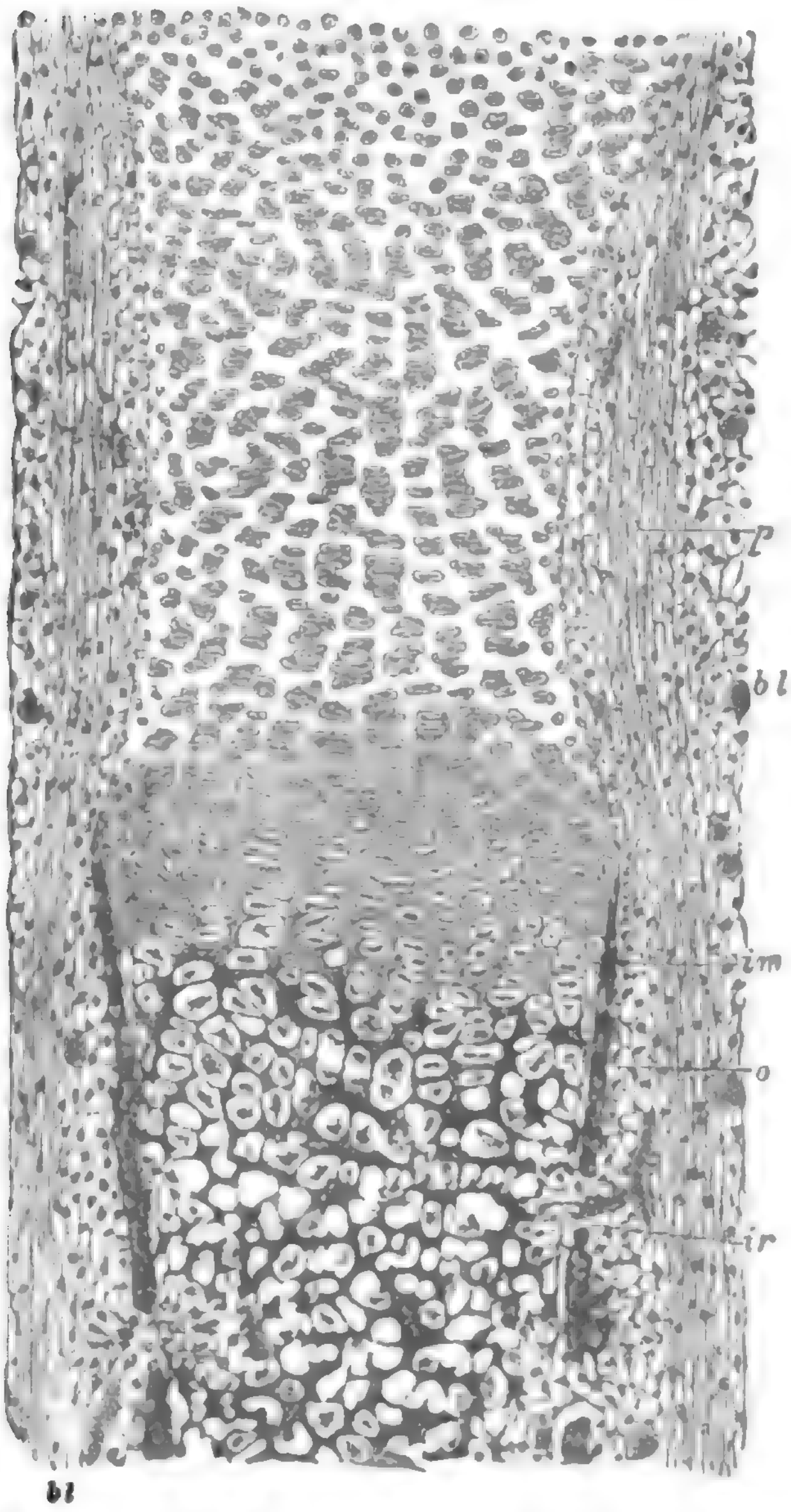

Section of Fœtal Bone of Cat: *ir*, irruption of the subperiosteal tissue; *p*, fibrous layer of the periosteum; *o*, layer of osteoblasts; *im*, subperiosteal bony deposit; *bl*, blood-vessels occupied by blood-corpuscles (from *Quain's Anatomy*, E. A. Schäfer).

FIG. 34

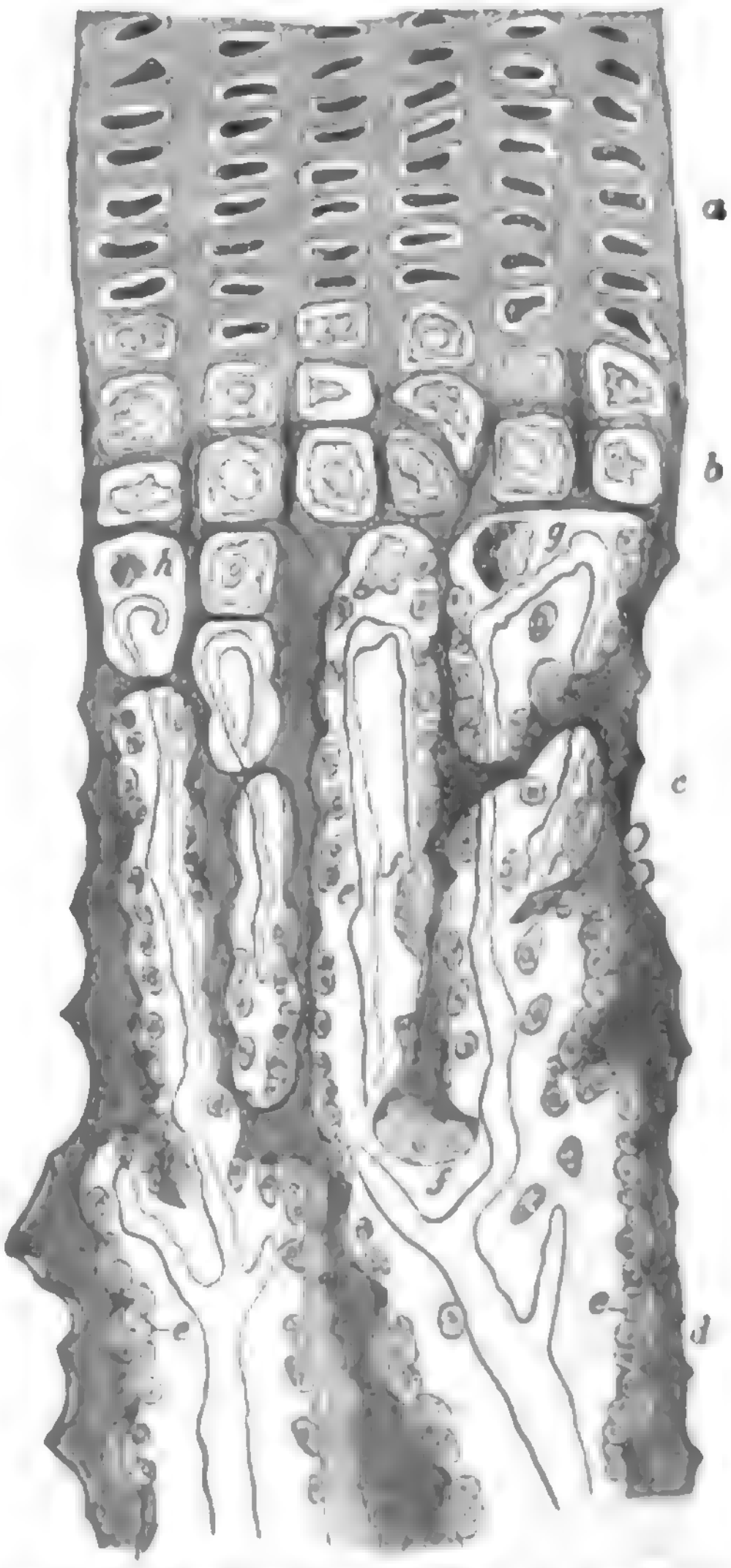

Part of a Longitudinal Section of the Developing Femur of a Rabbit: *a*, flattened cartilage-cells; *b*, enlarged cartilage-cells; *c*, *d*, newly-formed bone; *e*, osteoblasts; *f*, giant-cells or osteoblasts; *g*, *h*, shrunken cartilage-cells (from *Atlas of Histology*, Klein and Noble Smith).

lage the formation of a number of oblong spaces formed of calcified matrix and containing the cartilage-cells enlarged and arranged in groups, and on the surface of the cartilage the formation of a layer of true membrane-bone. The second stage consists in the prolongation into the cartilage of processes of the deeper or osteogenetic layer of the periosteum. The processes consist of blood-vessels and cells (osteoblasts). They excavate passages through the new-formed bony layer by absorption, and pass through it into the calcified matrix (Fig. 33). Wherever these processes come in contact with the calcified walls of the primary areolæ they absorb it, and thus cause a fusion of the original cavities and the formation of larger spaces, which are termed the *secondary areolæ* (Sharpey) or *medullary spaces* (Müller). In these secondary spaces the original cartilage-cells disappear, and their cavities become filled with embryonic marrow, consisting of osteoblasts and vessels, and derived, at all events in part, in the manner described above from the osteogenetic layer of the periosteum. What becomes of the cartilage-cells is not finally determined. By most histologists they are believed to be converted, after division, into osteoblasts, and so assist in forming the embryonic marrow. Others, on the other hand, believe that they are simply absorbed and take no part in the formation of bone.

Thus far, then, we have got enlarged spaces (secondary areolæ), the walls of which are still formed by calcified cartilage-matrix, containing an embryonic marrow, derived from the processes sent in from the osteogenetic layer of the periosteum, and consisting of blood-vessels and round cells, osteoblasts (Fig. 34), some of which probably are derived from the division of the original cartilage-cells, which have disappeared. The walls of these secondary areolæ are at this time of only inconsiderable thickness, but they now become thickened by the deposition of layers of new

FIG. 35.

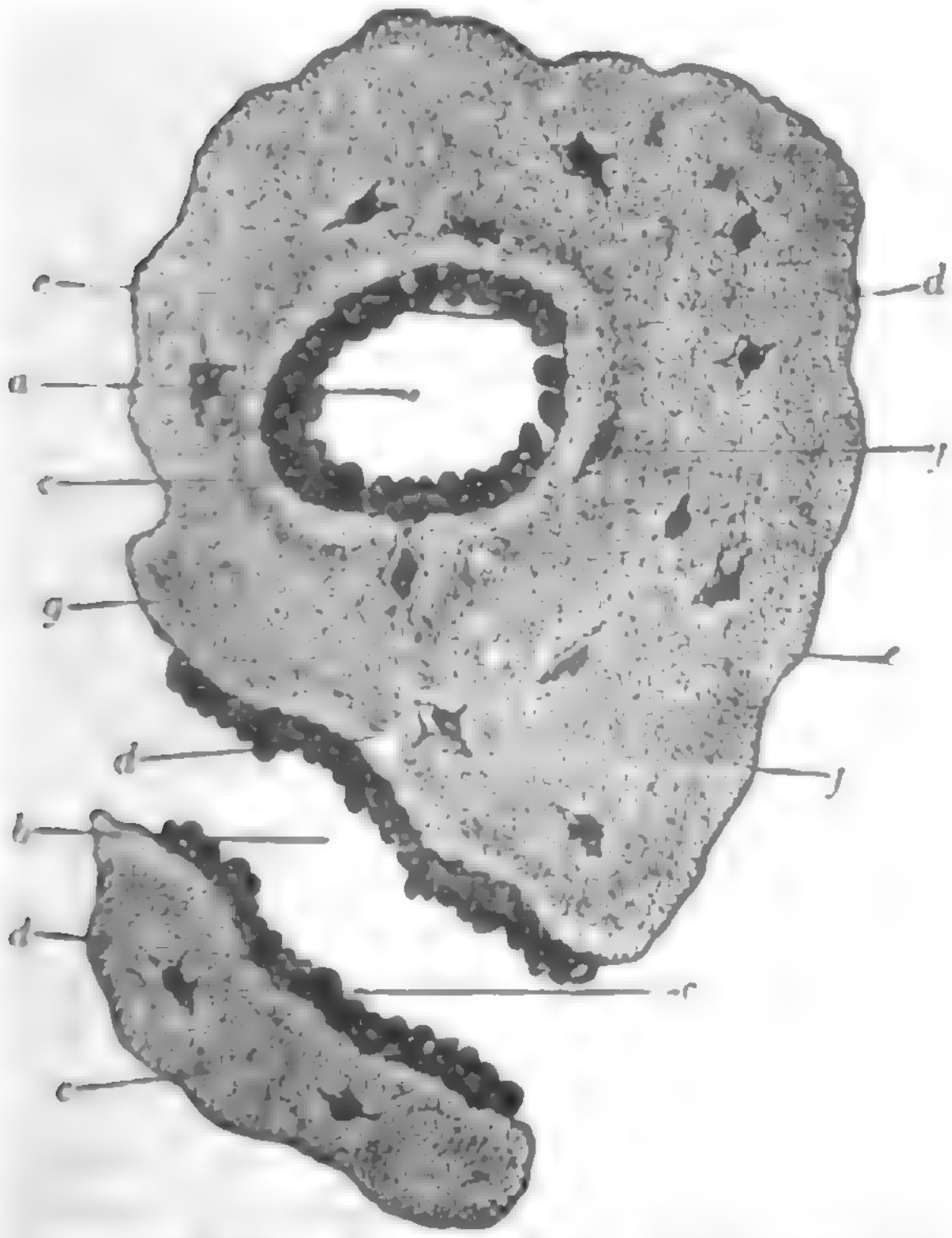

Transverse Section from the Femur of a Human Embryo about eleven weeks old: *a*, medullary sinus cut transversely, and *b*, another longitudinally; *c*, osteoblasts; *d*, newly-formed osseous substance of a lighter color; *e*, that of greater age; *f*, lacunæ with their cells; *g*, a cell still united to an osteoblast.

FIG. 36.

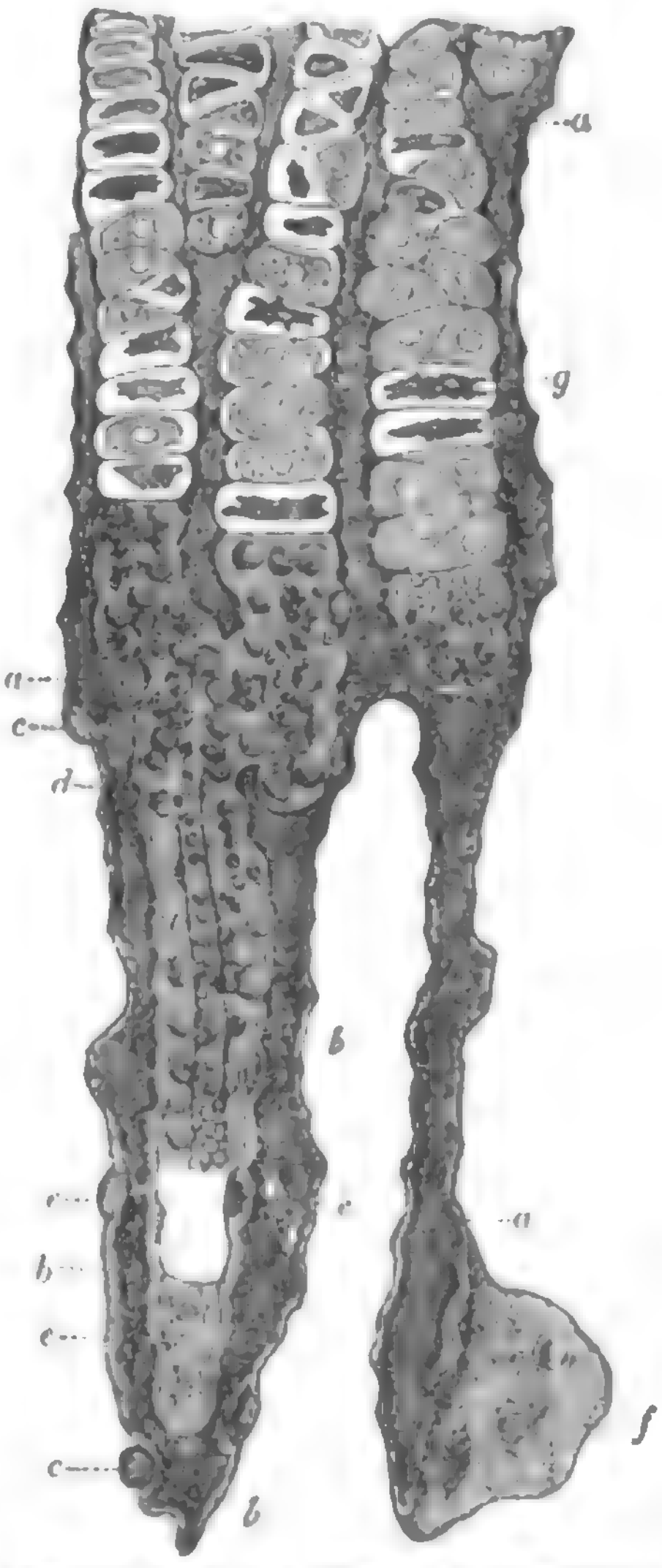

Vertical Section from the Edge of the Ossifying Portion of the Diaphysis of a Metatarsal Bone from a Fœtal Calf (after Müller): *a*, ground mass of the cartilage; *b*, of the bone; *c*, newly-formed bone-cells in profile, more or less imbedded in intercellular substance; *d*, medullary canal in process of formation, with vessels and medullary cells; *e*, *f*, bone-cells on their broad aspect; *g*, cartilage-capsules arranged in rows, and partly with shrunken cell-bodies.

bone on their interior. This process takes place in the following manner: Some of the osteoblasts of the embryonic marrow, after undergoing rapid division, arrange themselves as an epithelioid layer on the surface of the wall of the space (Fig. 35). This layer of osteoblast forms a bony stratum, and thus the wall of the space becomes gradually covered with a layer of true osseous substance. On this a second layer of osteoblasts arrange themselves, and in their turn form an osseous layer. By the repetition of this process the original cavity becomes very much reduced in size, and at last only remains as a small circular hole in the centre, containing the remains of the embryonic marrow; that is, a blood-vessel and a few osteoblasts. This small cavity constitutes the Haversian canal of the perfectly ossified bone. The successive layers of osseous matter which have been laid down and which encircle this central canal constitute the lamellæ of which, as we have seen, each Haversian system is made up. As the successive layers of osteoblasts form osseous tissue, certain of the osteoblastic cells remain included between the various bony layers. These continue persistent and remain as the corpuscles of the future bone, the spaces enclosing them forming the lacunæ (Fig. 36). The mode of the formation of the canaliculi is not known.

Such are the changes which may be observed at one particular point, the centre of ossification. While they have been going on here, a similar process has been proceeding in the same manner toward the end of the shaft, so that in the ossifying bone all the changes described above may be seen in different parts, from the true bone in the centre of the shaft to the hyaline cartilage at the extremities. The bone thus formed differs from the bone of the adult in being more spongy and less regularly lamellated.

Thus far, then, we have followed the steps of a process by which a solid bony mass is produced having vessels running into it from the periosteum, Haversian canals in which those vessels run, medullary spaces filled with fœtal marrow, lacunæ with their contained bone-cells, and canaliculi growing out of these lacunæ.

This process of ossification, however, is not the origin of the whole of the skeleton, for even in those bones in which the ossification proceeds in a great measure from a single centre situated in the cartilaginous shaft of a long bone, a considerable part of the original bone is formed by intramembranous ossification beneath the perichondrium or periosteum; so that the girth of the bone is increased by bony deposit from the deeper layer of this membrane. The shaft of the bone is at first solid, but a tube is hollowed out in it by absorption around the vessels passing into it, which becomes the medullary canal. This absorption is supposed to be brought about by large "giant-cells," which have long been recognized as a constituent of fœtal marrow, and which are believed by Kölliker to have the power of absorbing or dissolving bone; and he has therefore named them "osteoclasts." They vary in shape and size, and are known by containing a large number of clear nuclei, sometimes as many as twenty. The occurrence of similar cells in some tumors of bones has led to such tumors being denominated "myeloid."

As more and more bone is removed by this process of absorption from the interior of the bone to form the medullary canal, so more and more bone is deposited on the exterior from the periosteum, until at length the bone has attained the shape and size which it is destined to retain during adult life. As the ossification of the cartilaginous shaft extends toward the articular ends, it carries with it, as it were, a layer of cartilage, or the cartilage grows as it ossifies, and thus the bone is increased in length. During this period of growth the articular end, or epiphysis, remains for some time entirely cartilaginous; then a bony centre appears in it, and it commences the same process of intracartilaginous ossification; but this process never extends to any great distance. The epiphyses remain separated from the shaft by a narrow cartilaginous layer for a definite time. This layer ultimately ossifies, the distinction between shaft and epiphysis is obliterated, and the bone assumes its completed form and shape. The same remarks also apply to the processes of bone which are separately ossified, such as the trochanters of the femur. The bones, having been formed, continue to grow until the body has acquired its full stature. They increase in length by ossification continuing to extend in the epiphysial cartilage, which goes on growing in advance of the ossifying process. They increase in circumference by deposition of new bone from the deeper layer of the periosteum on their external surface, and at the same time an absorption takes place from within by which the medullary cavity is increased.

The medullary spaces which characterize the cancellous tissue are produced by the absorption of the original fœtal bone in the same way as the original medullary canal is formed. The distinction between the cancellous and compact tissue appears to depend essentially upon the extent to which this process of absorption has been carried; and we may perhaps remind the reader that in morbid states of the bone inflammatory absorption produces exactly the same change, and converts portions of bone naturally compact into cancellous tissue.

Intramembranous Ossification.—The intramembranous ossification is that by which the bones of the vertex of the skull are entirely formed. In the bones which are so developed no cartilaginous mould precedes the appearance of the bone-tissue. In the membrane which occupies the place of the future bone a little network of bony spiculæ is first noticed radiating from the point of ossification. When these rays of growing bone are examined by the microscope, they are found to consist of a network of fine clear fibres and granular corpuscles, with a ground-substance between. The fibres are termed *osteogenic* fibres, and soon become dark and granular from calcification, and as they calcify they are found to enclose the granular corpuscles or "osteoblasts" (Fig. 37). The calcification not only involves the osteogenic fibres, but also the ground-substance of the tissue in which they are contained. The corpuscles at first lie upon the osteogenic fibres, so that they can be removed by brushing the specimen with a hair-pencil in order to render the fibres clear; but they gradually become involved in the ossifying matrix and form the corpuscles of the future bone, the spaces in which they are enclosed constituting the lacunæ. As the tissue increases in thickness vessels shoot into it, grooving for themselves spaces or channels which become the Haversian canals. Thus, the intramembranous and intracartilaginous processes of ossification are similar in their more essential features.

FIG. 37.

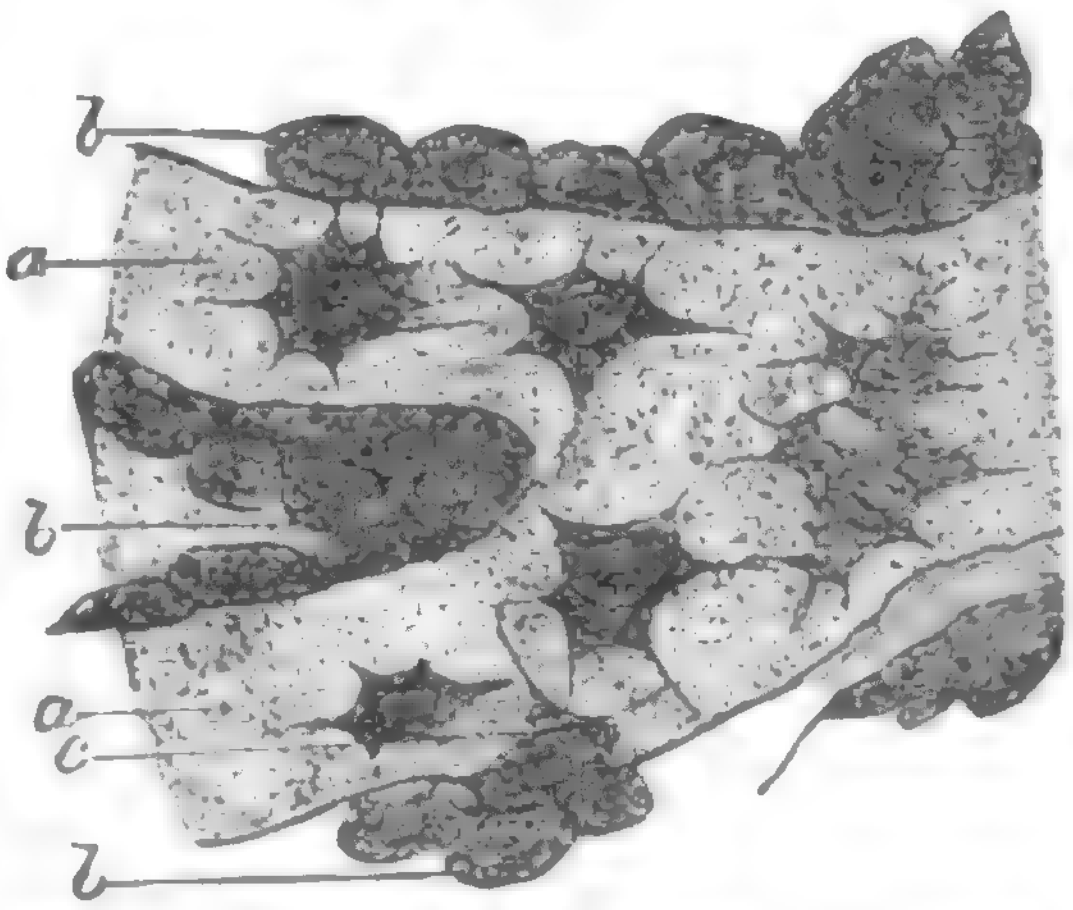

Osteoblasts from the Parietal Bone of a Human Embryo thirteen weeks old (after Gegenbauer): *a*, bony septa with the cells of the lacunæ; *b*, layers of osteoblasts; *c*, the latter in transition to bone-corpuscles.

The number of ossific centres is different in different bones. In most of the short bones ossification commences by a single point in the centre, and proceeds toward the circumference. In the long bones there is a central point of ossification for the shaft or diaphysis, and one or more for each extremity, the epiphysis. That for the shaft is first to appear. The union of the epiphyses with the shaft takes place in the reverse order to that in which their ossification began, and appears to be regulated by the direction of the nutrient artery of the bone. Thus, the nutrient arteries of the bones of the arm and forearm are directed toward the elbow, and the epiphyses of the bones forming this joint become united to the shaft before those at the opposite extremity. In the lower limb, on the other hand, the nutrient arteries pass in a direction from the knee; that is, upward in the femur, downward in the tibia and fibula; and in them it is observed that the upper epiphysis of the femur and the lower epiphysis of the tibia and fibula become first united to the shaft.

Where there is only one epiphysis, the medullary artery is directed toward that end of the bone where there is no additional centre, as toward the acromial end of the clavicle, toward the distal end of the metacarpal bone of the thumb and great toe, and toward the proximal end of the other metacarpal and metatarsal bones.

Besides these epiphyses for the articular ends, there are others for projecting parts or processes which are formed separately from the bulk of the bone. For an account of these the reader must be referred to the description of the individual bones in the sequel.

A knowledge of the exact periods when the epiphyses become joined to the shaft is often of great importance in medico-legal injuries. It also aids the surgeon in the diagnosis of many of the injuries to which the joints are liable; for it not infrequently happens that on the application of severe force to a joint the epiphysis becomes separated from the shaft, and such injuries may be mistaken for fracture or dislocation.

MUSCULAR TISSUE.

The **Muscles** are formed of bundles of reddish fibres endowed with the property of contractility. Two kinds of muscular tissue are found in the animal body—viz. that of voluntary or animal life, and that of involuntary or organic life. The muscles of animal life (striped muscles) are capable of being put in action and controlled by the will. They are composed of bundles of fibres enclosed in a delicate web called the *internal perimysium*, in contradistinction to the sheath of areolar tissue which invests the entire muscle, the *external perimysium*. The bundles are termed *fasciculi;* they are prismatic in shape, of different sizes in different muscles, and for the most part placed parallel to one another, though they have a tendency to converge toward their tendinous attachments. Each fasciculus is made up of a bundle of *fibres*, which also run parallel with each other, and which are separated from one another by a delicate connective tissue derived from the perimysium, and termed *endomysium* (Fig. 38).

FIG. 38.

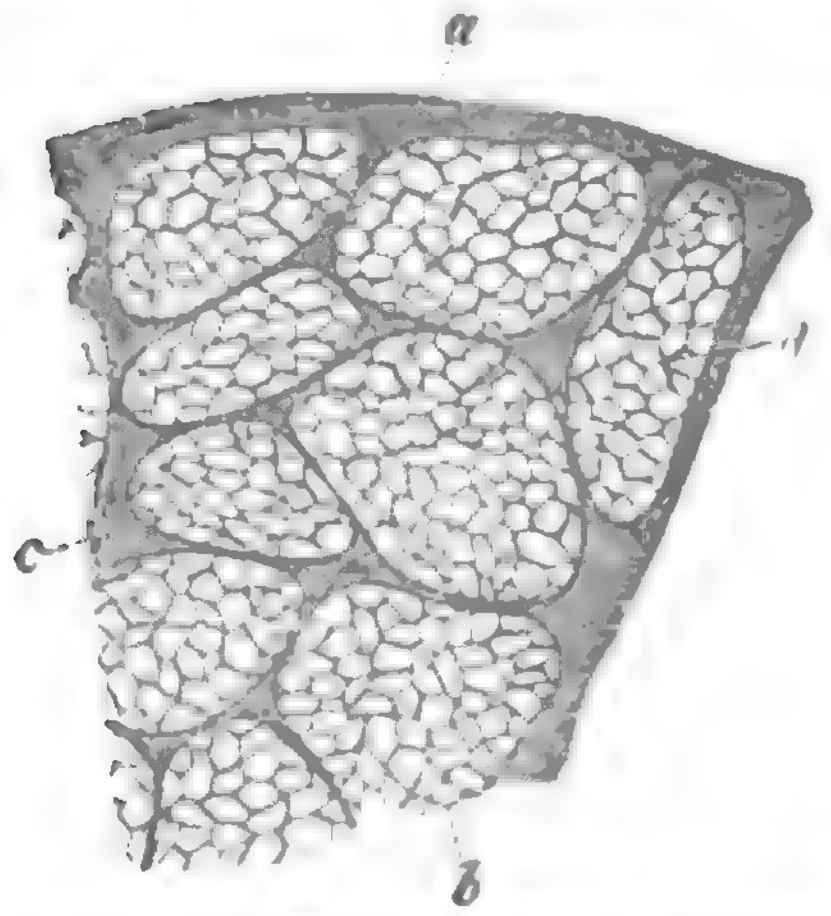

Transverse Section from the Sterno-mastoid in Man (magnified 50 times): *a*, external perimysium; *b*, fasciculus; *c*, internal perimysium; *d*, fibre.

A *muscular fibre* may be said to consist of a soft contractile substance enclosed in a tubular sheath, named by Bowman the *sarcolemma*. The fibres are cylindrical or prismatic in shape, and are of no great length, not extending, it is said, farther than an inch and a half. They end either by blending with the tendon or aponeurosis, or else by becoming drawn out into a tapering extremity which is connected to the neighboring fibre by means of the sarcolemma. Their breadth varies in man from $\frac{1}{200}$ to $\frac{1}{500}$ of an inch, the average of the majority being about $\frac{1}{400}$. As a rule, the fibres do not divide or anastomose; but occasionally, especially in the tongue and facial muscles, the fibres may be seen to divide into several branches. The precise mode in which the muscular fibre joins the tendon has been variously described by different observers. It may, perhaps, be sufficient here to say that the sarcolemma, or membranous investment of the muscular fibre, appears to become blended with the tissue of the tendon and prolonged more or less into the tendon, so that the latter forms a kind of sheath around the fibre for a longer or shorter distance. When muscular fibres are attached to the skin or mucous membranes their fibres are described by Hyde Salter as becoming continuous with those of the areolar tissue.

The *sarcolemma* or tubular sheath of the fibre is a transparent, elastic, and apparently homogeneous membrane of considerable toughness, so that it will sometimes remain entire when the included substance is ruptured. (See Fig. 39.) On the internal surface of the sarcolemma in Mammalia, and also in the substance of the fibre in the lower animals, elongated nuclei are seen (Fig. 56), and in connection with these a row of granules, apparently fatty, is sometimes observed. Upon examination of a muscular fibre by transmitted light under a sufficiently high power, it is found to be apparently marked by alternate light and dark bands or striæ, which pass transversely or somewhat obliquely round the fibre (Fig. 39). The dark and light bands are of nearly equal breadth, and alternate with great regularity. They vary in breadth from about the $\frac{1}{1200}$ to the $\frac{1}{1700}$ of an inch. Other striæ pass longitudinally over the fibres, though they are less distinct than the former. This longitudinal striation gives the fibre the appearance of being made up of a bundle of fibrillæ. The muscular fibre can be broken up either in a longitudinal or transverse direction (Fig. 40). If hardened in alcohol it can be broken up longitudinally, and forms the so-called fibrillæ of which some suppose the fibre to be made up. Each fibril is marked by transverse striæ, and appears to consist of a single row of minute quadrangular particles, named "sarcous elements" by Bowman. A still further division, however, is capable of being made, and each of these fibrillæ may be divided into minute threads (Fig. 41, B, *d*), consisting of an alternate dark and light spot. After exposure to the action of dilute hydrochloric acid, the muscular fibre can be broken transversely (Fig. 40, B). It then forms disks or plates consisting of the same quadrangular particles, attached by their lateral surfaces.

Fig. 39.

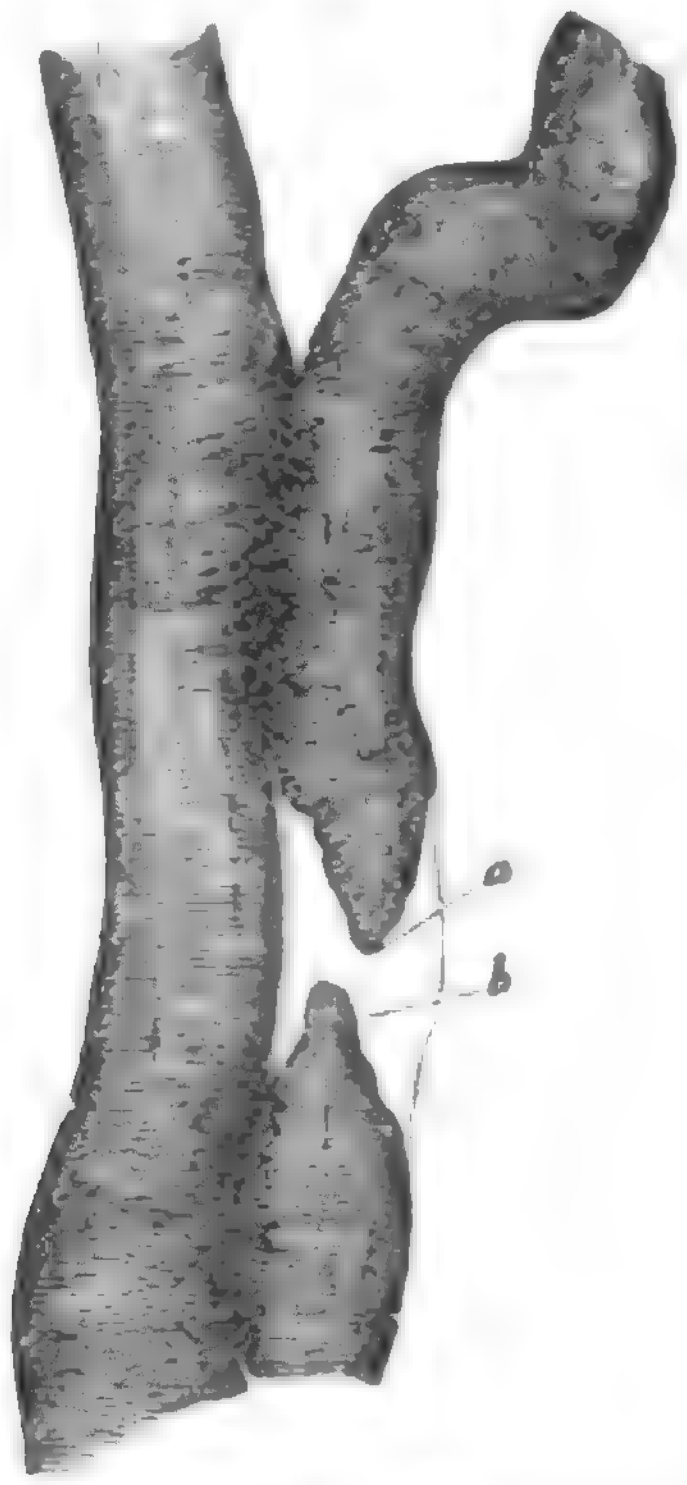

Two Human Muscular Fibres (magnified 350 times): In the one, the bundle of fibrillæ (*b*) is torn, and the sarcolemma (*a*) is seen as an empty tube.

Fig. 40.

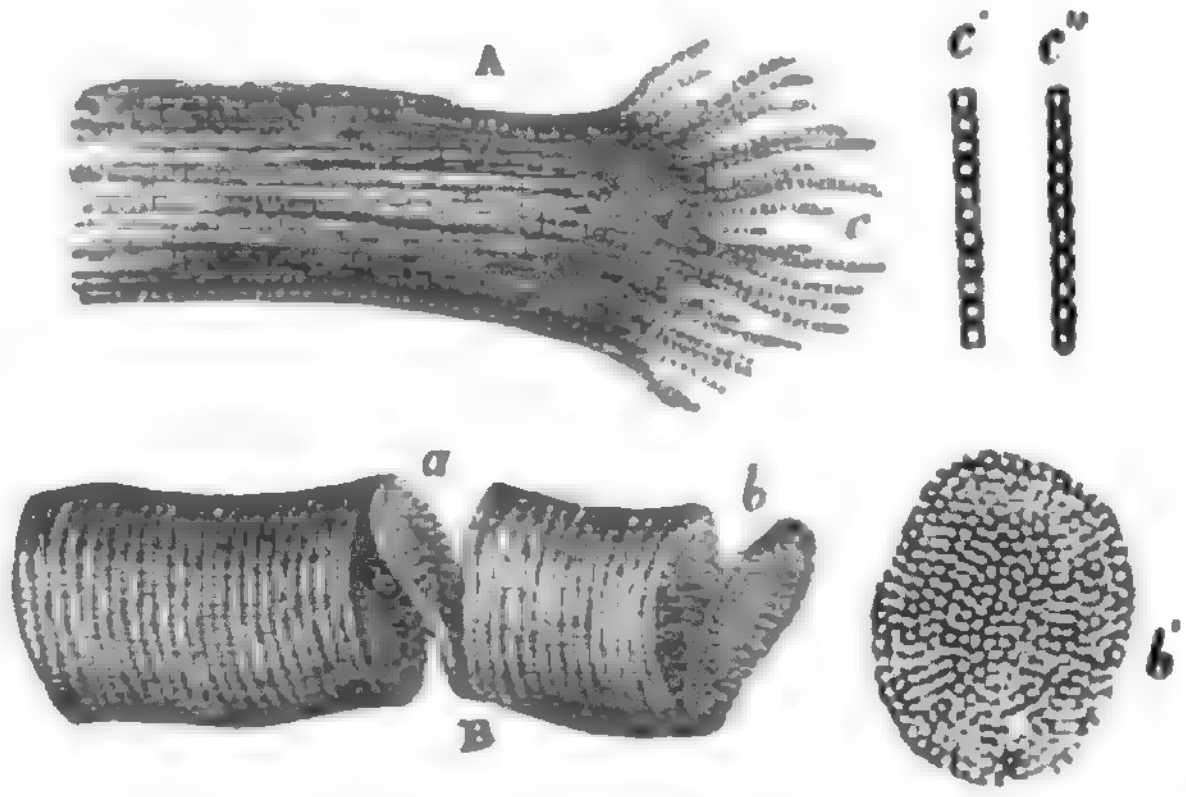

Fragments of Striped Elementary Fibres, showing a cleavage in opposite directions (magnified 300 diameters). A, longitudinal cleavage. The longitudinal and transverse lines are both seen. Some longitudinal lines are darker and wider than the rest, and are not continuous from end to end. This results from partial separation of the fibrillæ. *c*, fibrillæ separated from one another by violence at the broken end of the fibre, and marked by transverse lines equal in width to those on the fibre; *c' c''* represent two appearances commonly presented by the separated single fibrillæ (more highly magnified); at *c'* the borders and transverse lines are all perfectly rectilinear, and the included spaces perfectly rectangular; at *c''* the borders are scalloped and the spaces bead-like. When most distinct and definite the fibrilla presents the former of these appearances.

B, transverse cleavage: the longitudinal lines are scarcely visible. *a*, incomplete fracture following the opposite surfaces of a disk which stretches across the interval and retains the two fragments in connection. The edge and surfaces of this disk are seen to be minutely granular, the granules corresponding in size to the thickness of the disk and to the distance between the faint longitudinal lines; *b*, another disk nearly detached; *b'*, detached disk, more highly magnified, showing the sarcous elements.

Upon closer examination with a very high power the appearances become more complicated, and are susceptible of various interpretations. The transverse striation, which in Figs. 39 and 40 appears as a mere alternation of dark and light bands, is resolved into the appearance shown in Fig. 41, which shows a series of broad dark bands separated by a light band, which is itself divided into two by a dark streak. This streak is termed Krause's membrane; it is continuous at each end with the sarcolemma investing the muscular fibre. Thus it may be said that the fibre is divided into a number of transverse compartments by this membrane, each compartment containing in the centre a dark plate with a bright border above and below—that is to say, between the dark central part and the membrane of Krause. This appearance is explained by some as depending on some optical property of the investment of the separate sarcous elements. Thus it is supposed that the sarcous elements have an opaque interior, and are united to each other by a transparent envelope or cell-membrane, the sides of which cohere so closely as only to show a single line, while their ends are united by some different material which breaks up the light and causes a dark band or row of dark dots in the centre of the transparent streak formed by the cohesion of the two cell-membranes. Mr. Schäfer describes the sarcous elements as formed by an aggregation of rod-like masses of protoplasm, having rounded ends, and believes that the two bright bands and intervening row of dark dots are the result of the diffraction of the light around these rounded ends, "just as a minute oil-globule in water appears surrounded with a bright halo when examined under the microscope." Krause describes the structure of striped muscle somewhat differently. The dark line which separates the two transparent disks seen in Fig. 32 between the rows of sarcous elements is a transparent homogeneous membrane, the *membrane* of ***Krause***, continuous with the sarcolemma (Fig. 42). The transparent band on either side of this membrane (transparent lateral disk) separates on either side the sarcous elements from the membrane of Krause. The whole space comprised between two adjacent membranes of Krause and the corresponding sarcolemma is called a muscle-compartment. Within these compartments is contained the muscular substance, consisting of a central, dim, doubly-refracting disk, which occupies the greater portion of the compartment, but is separated above and below from Krause's membrane by a thin layer of transparent, homogeneous fluid-substance which is singly refracting. The central doubly-refracting portion is the true contractile substance, and appears to be homogeneous, but in reality is made up of a number of rod-shaped elements. This gives the appearance of longitudinal striation, after post-mortem changes have taken place, which is not visible during life. In the centre of this contractile substance a transparent lighter band can sometimes be discerned; this is known as the median disk of Hensen.

FIG. 41.

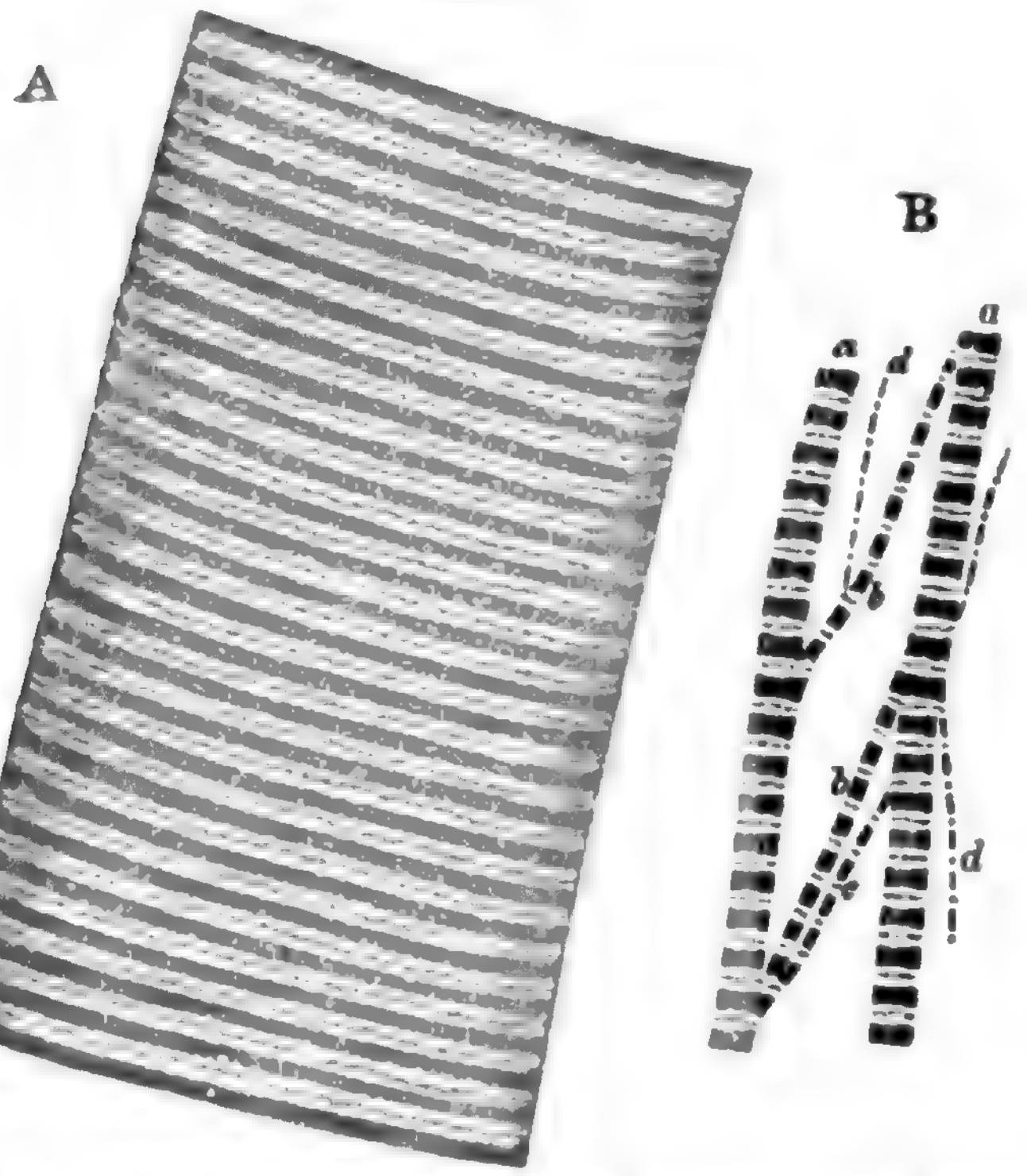

A, portion of a Medium-sized Human Muscular Fibre (magnified nearly 800 diameters).
B, separated Bundles of Fibrils, equally magnified: *a, a*, larger, and *b, b*, smaller collections; *c*, still smaller; *d, d*, the smallest which could be detached.

FIG. 42.



Part of a Striped Muscular Fibre of Hydrophylus, prepared with absolute alcohol (magnified 300 diameters—Klein and Noble Smith): *a*, sarcolemma; *b*, membrane of Krause: owing to contraction during hardening the sarcolemma shows regular bulgings. At the side of Krause's membrane is the transparent lateral disk. The chief mass of a "muscle-compartment" is occupied by the contractile disk composed of sarcous elements. Several nuclei of muscle-corpuscles are shown, and in them a minute network.

This form of muscular fibre composes the whole of the voluntary muscles, all the muscles of the ear, those of the larynx, pharynx, tongue, the upper half of the œsophagus, the heart, and the walls of the large veins at the point where they open into it. The fibres of the heart, however, differ very remarkably from those of other striped muscles. They are smaller by one-third, and their transverse striæ are by no means so distinct. The fibres are made up of distinct quadrangular cells joined end to end (Fig. 43). Each cell contains a clear oval nucleus situated near the centre of the cell. The extremities of the cells have a tendency to branch or divide, the subdivisions uniting with offsets from other cells, and thus producing an anastomosis of the fibres (Fig. 43). The connective tissue between the bundles of fibres is much less than in ordinary striped muscle, and no sarcolemma has been proved to exist.

The *capillaries* of striped muscle are very abundant and form a sort of rectangular network, the branches of which run longitudinally between the muscular fibres, and are joined at short intervals by transverse anastomosing branches.

Nerves are profusely distributed to striped muscle. The mode of their termination will be described on a subsequent page.

The existence of *lymphatic* vessels in striped muscle has not been ascertained, though they have been found in tendons and in the sheath of the muscle.

FIG. 43.



Anastomosing Muscular Fibres of the Heart, seen in a longitudinal section. On the right the limits of the separate cells with their nuclei are exhibited somewhat diagrammatically.

The **unstriped muscle**, or **muscle of organic life**, is found in the walls of the hollow viscera—viz. the lower half of the œsophagus and the whole of the remainder of the gastro-intestinal tube; in the trachea and bronchi; in the gall-bladder and ductus communis choledochus; in the pelvis and calices of the kidney, the uterus, bladder, and urethra; in the female sexual organs—viz. the Fallopian tubes, the uterus (enormously developed in pregnancy), the vagina, the broad ligaments, and the erectile tissue of the clitoris; in the male sexual organs—viz. the dartos scroti, the vas deferens and epididymis, the vesiculæ seminales, the prostate gland, and the corpora cavernosa; in the ducts of certain glands, as in Wharton's duct; in the capsule and trabeculæ of the spleen; in the mucous membranes forming the muscularis mucosæ; in the arteries, veins, and lymphatics; in the iris; and in the skin.

Plain or unstriped muscular fibre is made up of spindle-shaped cells called *contractile fibre-cells*, collected into bundles and held together by a cement-substance in which are contained some connective-tissue corpuscles (Fig. 44). These bundles are further aggregated into larger bundles or flattened bands, and bound together by ordinary areolar tissue.

The *contractile fibre-cells* (Fig. 45) are elongated, spindle-shaped, nucleated cells of various lengths, averaging from $\frac{1}{600}$ to $\frac{1}{300}$ of an inch in length and $\frac{1}{4500}$ to $\frac{1}{3500}$ of an inch in breadth. On transverse section they are more or less polyhedral in shape from mutual pressure. They present a distinctly longitudinally striated appearance, and consist of an elastic cell-wall containing a central bundle of fibrillæ representing the contractile substance, and an oval or rod-like nucleus, which includes, within a membrane, a fine network communicating at the poles of the nucleus with the contractile fibres (Klein). The adhesive interstitial substance which connects the fibre-cells together represents the endomysium, or delicate connective tissue which binds the fibres of striped muscular tissue into fasciculi, while the tissue connecting the individual bundles together represents the perimysium. The unstriped muscle, as a rule, is not under the control of the will, nor is the contraction rapid and involving the whole muscle, as is the case with the muscles of animal life. The membranes which are composed of the unstriped muscle slowly contract in a part of their extent, generally under the influence of a mechanical stimulus, as that of distension or of cold; and then the contracted part slowly relaxes while another portion of the membrane takes up the contraction. This peculiarity of action is most strongly marked in the intestines, constituting their *vermicular motion*.

Chemical Composition of Muscle.—In chemical composition the muscular fibres of both forms consist mainly of a proteid substance—myosin—which Dr. M.

Foster speaks of as intermediate between fibrin and globulin. It is readily converted by the action of dilute acids into syntonin or acid-albumen, and by the action of dilute alkalies into alkali-albumen. Muscle which is neutral or slightly alkaline in reaction when at rest is rendered acid by contraction, from the development probably of sarcolactic acid. After death muscle also exhibits an acid reaction, but this appears to be due to post-mortem change.

FIG. 44.

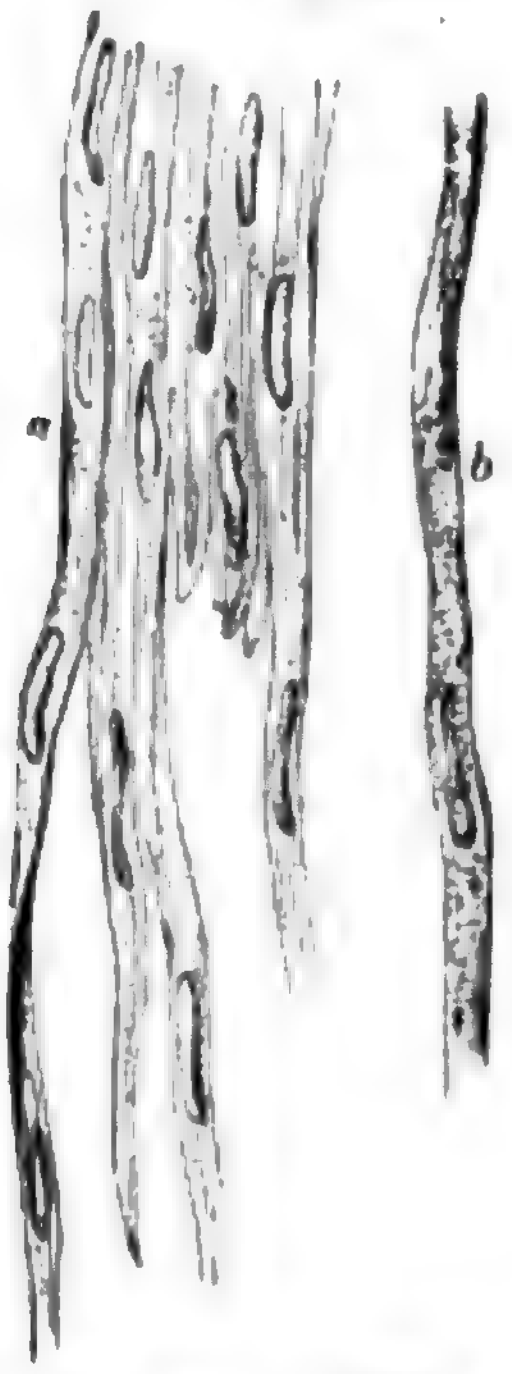

Non-striated Elementary Fibres from the Human Colon: *a*, treated with acetic acid, showing the corpuscles; *b*, fragment of a detached fibre not touched with acid.

FIG. 45.

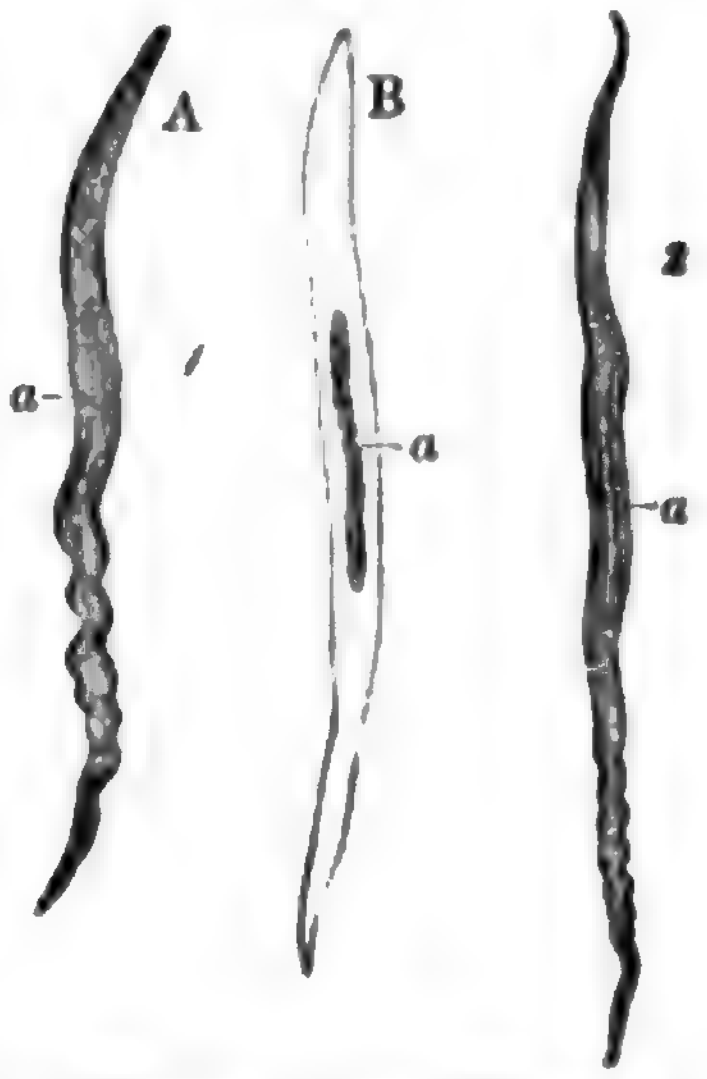

Muscular Fibre-cells from Human Arteries: 1, from the popliteal artery; A, without; B, with acetic acid. 2, from a branch of the anterior tibial; *a*, nuclei of the fibres (magnified 350 times).

NERVOUS TISSUE.

The **nervous tissues** of the body are comprised in two great systems—the *cerebro-spinal* and the *sympathetic;* and each of these systems consists of a *central organ*, or series of central organs, and of *nerves*.

The *cerebro-spinal* system comprises the brain (including the medulla oblongata), the spinal cord, the cranial nerves, the spinal nerves, and the ganglia connected with both these classes of nerves. The *sympathetic* system consists of a double chain of ganglia, with the nerves which go to and come from them. It is not directly connected with the brain or spinal cord, though it is so indirectly by means of its numerous communications with the cranial and spinal nerves.

All these nervous tissues are composed chiefly of two different structures—the *gray* or *vesicular*, and the *white* or *fibrous*. It is in the former, as is generally supposed, that nervous impressions and impulses originate, and by the latter that they are conducted. Hence the gray matter forms the essential constituent of all the ganglionic centres, both those separated in the ganglia and those aggregated in the cerebro-spinal axis; while the white matter is found in all the commissural portions of the nerve-centres and in all the cerebro-spinal nerves. The nerves of the sympathetic system are chiefly composed of a somewhat different material in structure, which is named *gray* or *gelatinous* nerve-fibre. This form of nerve-fibre is also found in some of the cerebro-spinal nerves.

The **gray or vesicular nervous substance** is distinguished by its dark reddish-gray color and soft consistence. It is found in the brain, spinal cord, and various ganglia intermingled with the fibrous nervous substance, and also in some of the nerves of special sense, and in gangliform enlargements which are found here and there in the course of certain cerebro-spinal nerves. It is composed, as its name implies, of vesicles or corpuscles, commonly called nerve- or ganglion-corpuscles, containing nuclei and nucleoli: the vesicles are imbedded either in a finely granular substance destitute of any nucleated sheath, as in the brain, or else contained in a hyaline capsule lined by a more or less continuous layer of nucleated endothelial cells, as in the ganglia. Each vesicle consists of a finely granular protoplasmic material, of a reddish or yellowish-brown color, which occasionally presents patches of a deeper tint caused by the aggregation of pigment-granules (Fig. 46). No distinct limiting membrane or cell-wall has been ascertained to exist. The nucleus is, as a rule, a large, well-defined, round, vesicular body, often presenting an intranuclear network, and containing a nucleolus which is peculiarly clear and brilliant. The nerve-corpuscles vary in shape and size; some are small, spherical or ovoid, with a general even outline, such as those frequently found in the spinal ganglia; others are more or less angular, as in the ganglia of the sympathetic; others, again, are caudate or stellate in shape, and are characterized by their large size and by their having one or more tail-like processes issuing from them, which occasionally divide and subdivide into numerous branches (Fig. 47). These are found in greatest number in the gray matter of the spinal cord. Still others are flask-shaped, as in the cortex of the cerebellum, or conical, as in the cerebral convolutions. For the most part, nerve-cells have one or more processes, and they are distinguished by the number of these processes, as unipolar, bipolar, or multipolar cells. These processes are very delicate, apparently tubular, and contain a similar granular material to that found within the corpuscle. Some of the processes terminate in fine transparent fibres, which become lost among the other elements of the nervous tissue; others may be traced until, after losing their granular appearance, they become continuous with an ordinary nerve-fibre.

FIG. 46.

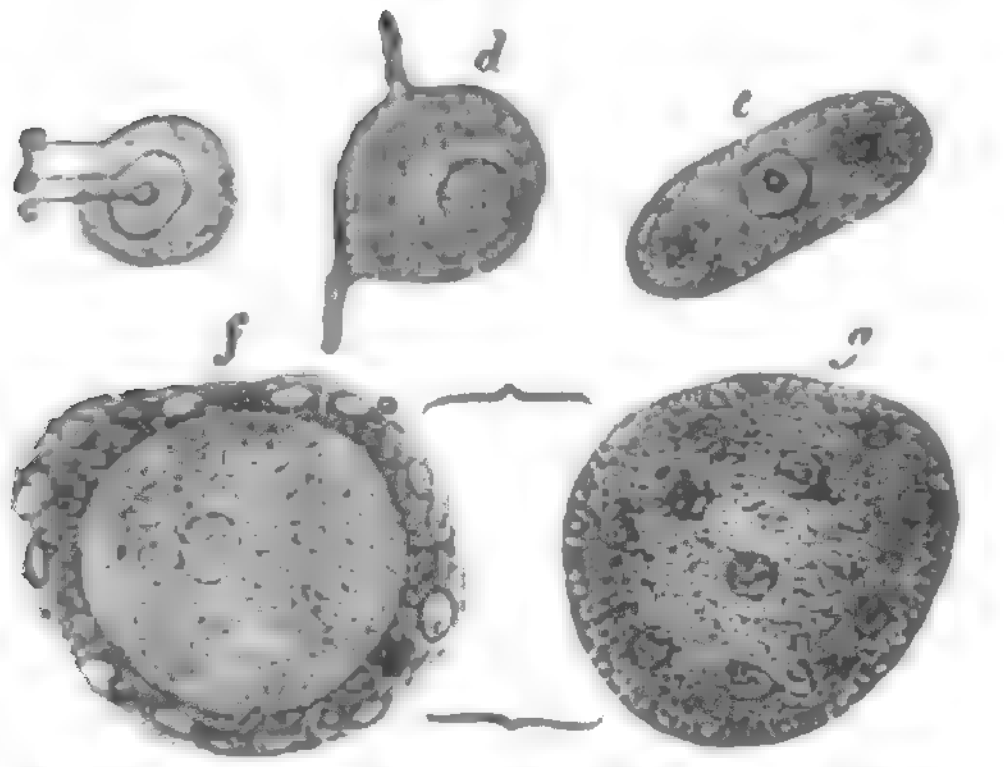

Nerve-vesicles from the Gasserian Ganglion of the Human Subject: *a*, a globular one with defined border; *b*, its nucleus; *c*, its nucleolus; *d*, caudate vesicle; *e*, elongated vesicle with two groups of pigment-particles; *f*, vesicle surrounded by its sheath or capsule of nucleated particles; *g*, the same, the sheath only being in focus (magnified 300 diameters).

FIG. 47.

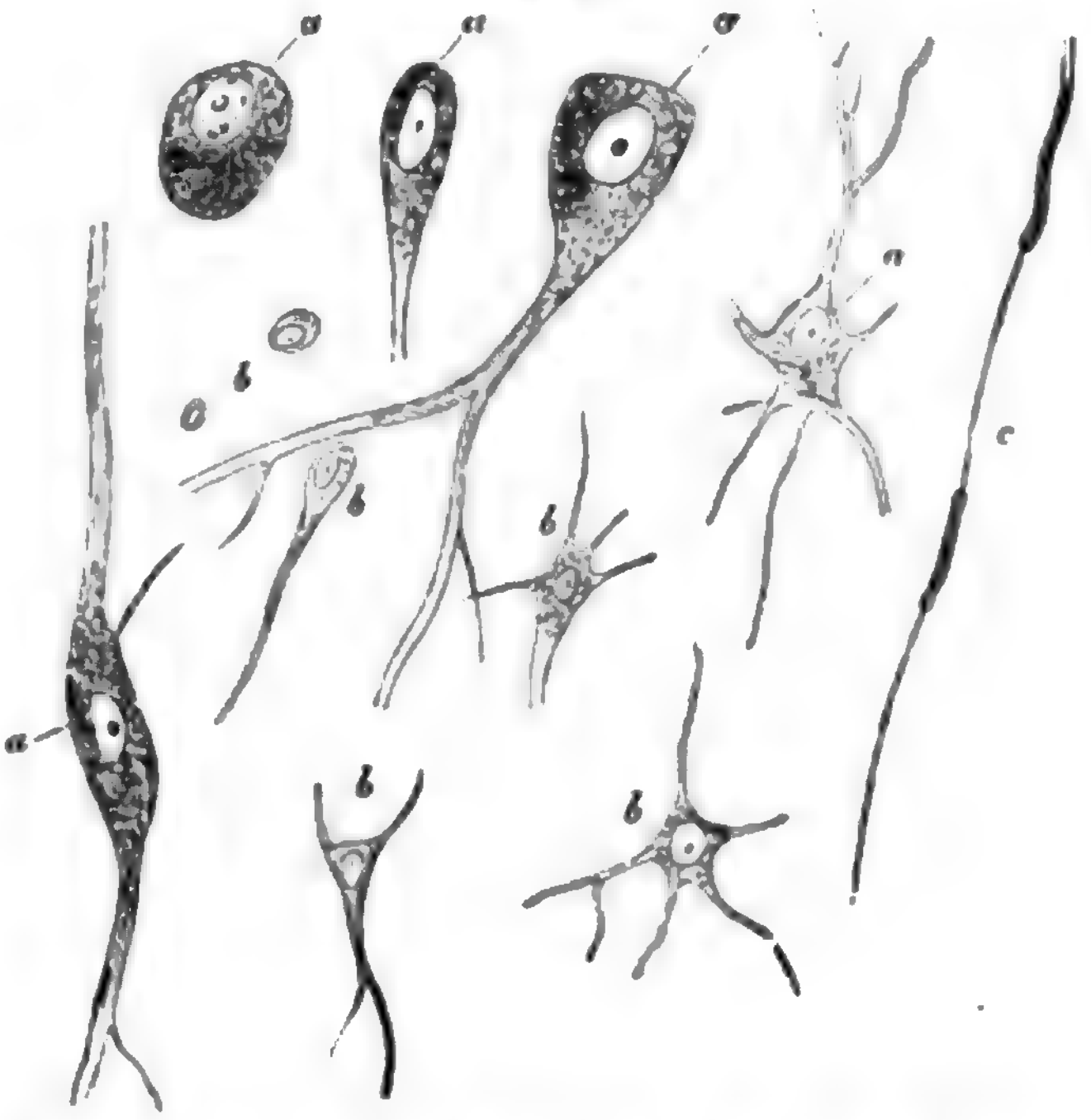

Nerve-vesicles from the inner part of the Gray Matter of the Convolutions of the Human Brain (magnified 350 times): Nerve-cells—*a*, larger; *b*, smaller; *c*, nerve-fibre with axis-cylinder.

The **white** or **fibrous** nerve-substance or *nerve-fibre* is found universally in the nervous cords, and also constitutes a great part of the brain and spinal cord. The fibres of which it consists are of two kinds—the medullated or white fibres, and the non-medullated or gray fibres.

The **medullated** [or **dark-bordered**] fibres form the white part of the brain and spinal cord, and also the greater part of the cerebro-spinal nerves, and give to these structures their opaque white aspect. When perfectly fresh they appear to be homogeneous; but soon after removal from the body they present, when examined by transmitted light, a double outline or contour, as if consisting of two parts. The central portion is named the *axis-cylinder* of Purkinje; around this is a sort of sheath of fatty material named the *white substance* of Schwann, which gives to the fibre its double contour, and the whole is enclosed in a delicate membrane, the *neurilemma*[1] or *primitive sheath* (Fig. 48).

FIG. 48.

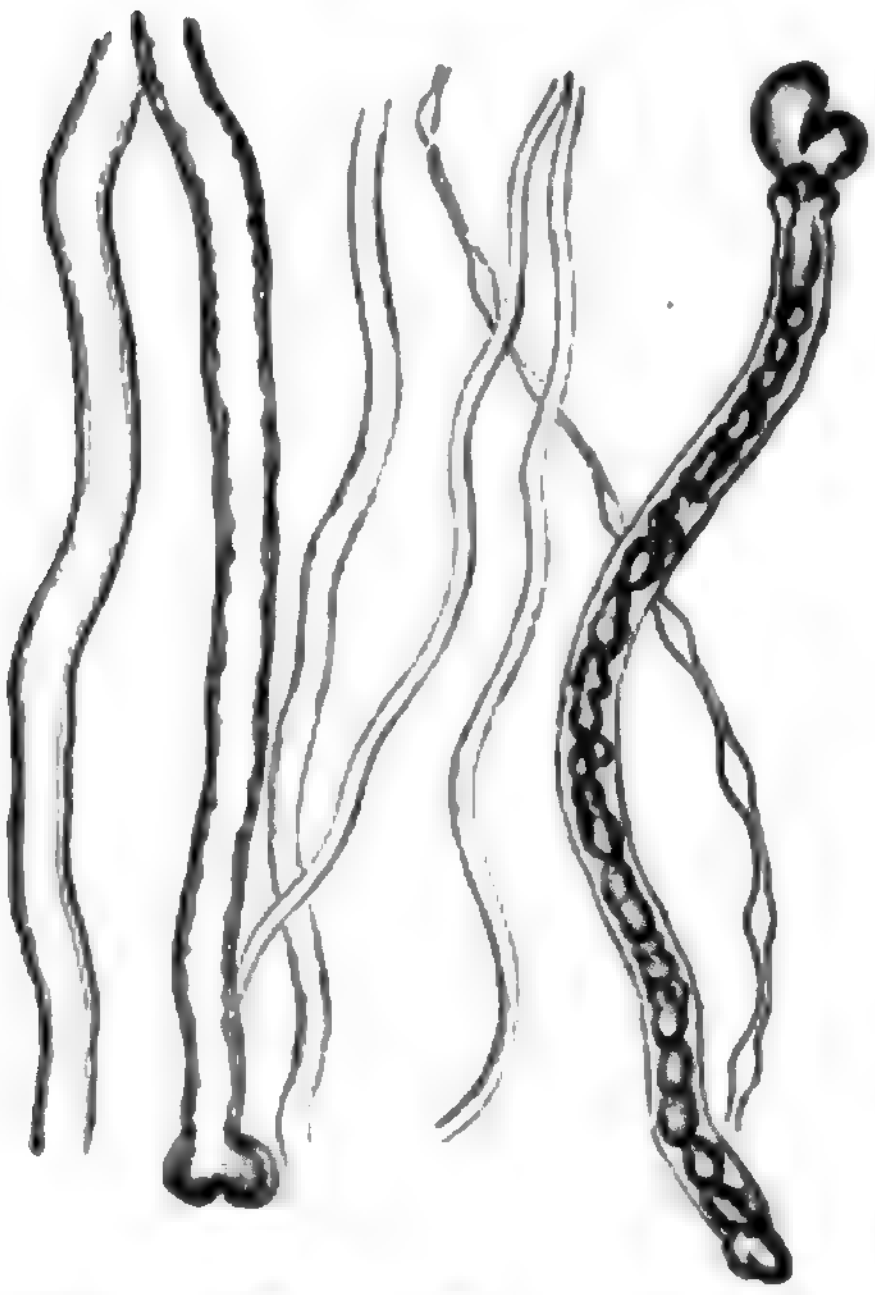

Human Nerve-tubes (magnified 350 times). Three of them are fine, one of which is varicose, one of middling thickness, and with a single contour, and three thick, two of which are double-contoured, and one with grumous contents.

The *axis-cylinder* (Fig. 49) constitutes about one-half or one-third of the nerve-tube, the white substance being greater in proportion in the nerves than in the central organs. It is perfectly transparent, and is therefore indistinguishable in a perfectly fresh and natural state of the nerve. It is described by Kölliker as being distinguished from the white substance by the fact that, though soft and flexible, it is not fluid and viscid, but firm and elastic, somewhat like coagulated albumen, with which it appears for the most part also to agree in its chemical characters. When examined under a high power it presents the appearance of a longitudinal striation, as if composed of very fine homogeneous fibrillæ held together in a faintly granular interstitial material. Occasionally at its termination the axis-cylinder of a fibre may be seen to break up into exceedingly fine fibrillæ, confirming the view of its fibrillar structure. These fibrillæ have been termed the *primitive fibrillæ* of Schultze. The axis-cylinder is said to be enveloped in a very delicate hyaline sheath which separates it from the white matter of Schwann.

[FIG. 49.



Diagram of Structure of Medullated Nerve-fibre: 1, neurilemma or sheath of Schwann; 2, medullary sheath; 3, axis-cylinder.]

[FIG. 50.

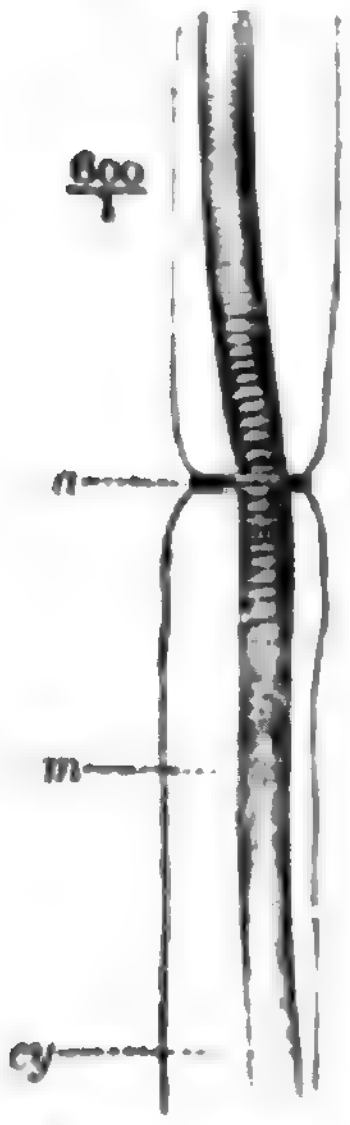

Nerve-fibre from Sciatic Nerve of Rabbit, after action of nitrate of silver: *a*, ring formed by thickened membrane of Schwann (node of Ranvier); *m*, white substance of Schwann rendered transparent by glycerin; *cy*, cylinder-axis, which just above and below the level of the annular constriction presents the lines of Frommann.]

The *medullary sheath* or *white matter* of Schwann is regarded as being a fatty matter in a fluid state, which insulates and protects the essential part of the nerve—the axis-cylinder. The white matter varies in thickness to a very considerable extent, in some forming a layer of extreme thinness, so as to be scarcely distinguishable; in others forming about one-half the nerve-tube. The size of the nerve-fibres, which varies from $\frac{1}{1200}$ to $\frac{1}{2000}$ of an inch, depends mainly upon the amount of the white substance, though the axis-cylinder also varies in size within certain limits. The white substance of Schwann does not always form a continuous sheath to the axis-cylinder, but undergoes interruptions in its continuity at regular intervals, giving to the fibre the appearance of constriction at these points. These were first described by Ranvier, and are known as the *nodes of Ranvier* (Fig. 50). The portion of nerve-fibre between two nodes is called an internodal segment. The neurilemma or primitive

---

[1] In older histological works the term "neurilemma" is used to designate the fibrous envelope of the whole nerve, now called "perineurium."

sheath is not interrupted at the nodes, but passes over them as a continuous membrane. Each internodal segment contains an oval nucleus imbedded in the medullary sheath, and occasionally more than one nucleus may be seen in the same internode. Medullated nerve-fibres, when examined, frequently present a beaded or varicose appearance: this is due to manipulation and pressure causing the oily matter to collect into drops, and in consequence of the extreme delicacy of the primitive sheath even slight pressure will cause the transudation of the fatty matter, which collects as drops of oil outside the membrane. This is, of course, promoted by the action of ether (Fig. 51).

The *neurilemma* or *primitive sheath* (sometimes called the *tubular membrane* or *nucleated sheath of Schwann*) at first appears structureless, but when stained with nitrate of silver is seen to consist of nucleated endothelial cells. The nuclei of these cells are oval and somewhat flattened, and bear a definite relation to the nodes of Ranvier, one nucleus generally lying in the centre of each node, though in some few instances two nuclei may be found in the same node.

FIG. 51.

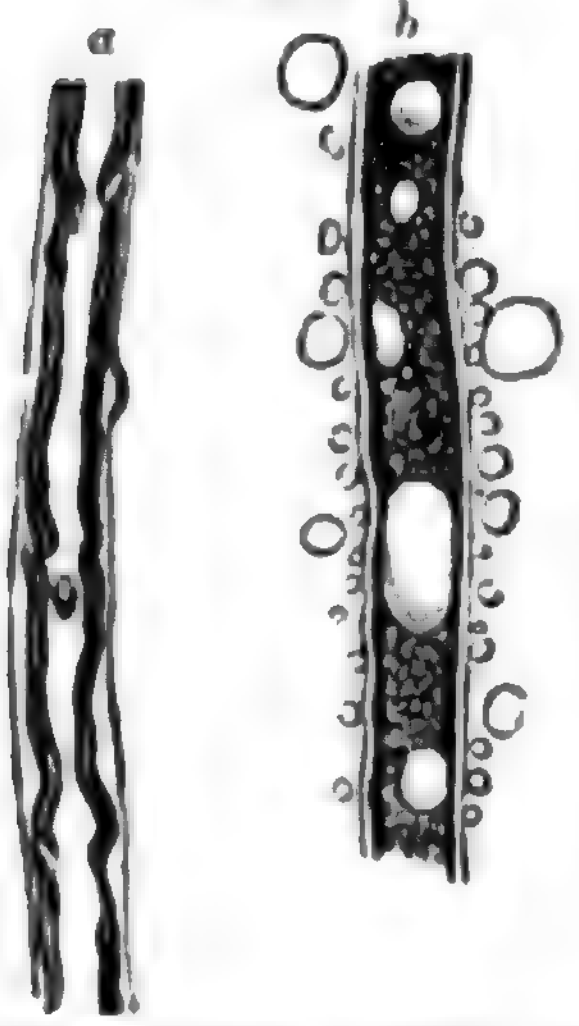

a, Nerve-tube of the Common Eel in Water. The delicate line on its exterior indicates the tubular membrane. The dark double-edged inner one is the white substance of Schwann, slightly wrinkled; *b*, the same in ether. Several oil-globules have coalesced in the interior, and others have accumulated around the exterior of the tube. The white substance has in part disappeared (magnified 300 diameters).

FIG. 52.

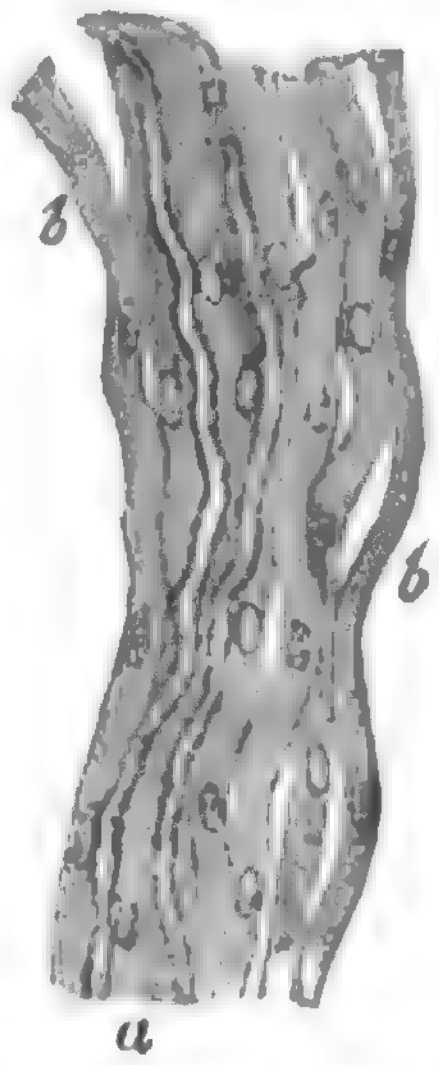

A Small Nervous Branch from the Sympathetic of a Mammal: *a*, two dark-bordered nerve-tubes among a number of Remak's fibres, *b*.

Non-Medullated Fibres.—Most of the nerves of the sympathetic system, and some of the cerebro-spinal (see especially the description of the olfactory nerve), consist of another variety of nervous fibres, which are called the *gray* or *gelatinous* nerve-fibres—*fibres of Remak* (Fig. 52). These consist of a bundle of finely-striated fibrillæ enclosed in a sheath. Nuclei may be detected at intervals in each fibre, which Schultze believes to be situated in the sheath of the nerve-fibre, as in the medullated variety. In external appearance the gelatinous nerves are semi-transparent and gray or yellowish-gray. The individual fibres vary in size, generally averaging about half the size of the medullated fibres; but, on the one hand, the primitive fibrillæ formed by breaking up of the cerebro-spinal fibres, as above mentioned, are of hardly appreciable thickness, while, on the other hand, some of the gelatinous fibres (especially those on the olfactory bulb) are said to be three or four times as thick as those of the cerebro-spinal nerves.

Chemical Composition.—The different portions of the nervous system are composed of the two above-described kinds of nervous structure, the chemical composition of which is shown by the following analysis by Lassaigne, which represents the relative proportion of the different constituents composing the gray and white matter of the brain:

	Gray.	White.
Water	85.2	73.0
Albuminous matter	7.5	9.9
Colorless fat	1.0	13.9
Red fat	3.7	0.9
Osmazome and lactates	1.4	1.0
Phosphates	1.2	1.3

It appears from this analysis that the cerebral substance consists of albumen dissolved in water, combined with fatty matter and salts. The fatty matters consist of cerebrin, neurin, and lecithin. The two latter were first described by Liebreich as a crystalline phosphuretted fat, which he termed protagon. It seems probable, however, that it is simply a mixture of neurin and lecithin. Cholesterin is also described as one of the chemical constituents of the nervous tissues, being found in conjunction with lecithin. The salts are the phosphates of potash, soda, lime, magnesia, and iron, sulphate of potash and chloride of sodium, with traces of silica. According to Vauquelin, the cord contains a larger proportion of fat than the brain; and according to L'Héritier, the nerves contain more albumen and more soft fat than the brain.

The nervous structures are divided, as before mentioned, into two great systems—viz. the *cerebro-spinal*, comprising the brain and spinal cord, the nerves connected with these structures, and the ganglia situated on them; and the *sympathetic*, consisting of a double chain of ganglia and the nerves connected with them. All these structures require separate consideration; they are composed of the two kinds of nervous tissue above described, intermingled in various proportions, and having, in some parts, a very intricate arrangement.

The **Brain,** or **Encephalon,** is that part of the cerebro-spinal system which is contained in the cavity of the skull. It is divided into several parts, named the medulla oblongata, pons, cerebellum, and cerebrum. In these parts the gray or vesicular nervous matter is found partly on the surface of the brain, forming the convolutions of the cerebrum, which are in the most direct relation to the mental faculties, and the laminæ of the cerebellum, the functions of which are still a matter of dispute. Again, gray matter is found in the interior of the brain, collected into large and distinct masses or ganglionic bodies, such as the corpus striatum, optic thalamus, and corpora quadrigemina; the functions of which bodies, so far as they have been ascertained, have been found to be connected with some of the main organic endowments of the body, such as voluntary motion, sensation, and sight. Finally, gray matter is found intermingled intimately with the white, but without definite arrangement, as in the corpora dentata of the medulla and cerebellum, or the gray matter in the pons and the floor of the fourth ventricle. Such scattered masses of gray matter are—in many instances, at any rate—connected, to all appearance, with the origin of particular nerves. In some situations their use is unknown.

The proper nervous matter, both in the brain and spinal cord, is traversed and supported by a network of fine connective tissue. This has been termed by Virchow the *neuroglia*, and is supposed to be the source of one of the forms of the tumor described by that author under the name *glioma*.

The white matter of the brain is divisible into three distinct classes of fibres. These are, in the first place, the nerves which arise in the gray matter and pass out through the cranial foramina. Next, the fibres which connect the brain with the spinal cord; that is to say, those which are usually traced upward from the columns of the spinal cord, through the medulla oblongata, into the encephalon, chiefly by means of the anterior pyramids, fasciculi teretes, and restiform bodies, passing through the pons and crura cerebri to expand into the corpora striata, optic thalamus, and convolutions (*corona radiata*), and by means of the restiform bodies into the cerebellum. The other class of white fibres in the brain are commissural, some of the commissures serving to connect different parts of the same hemisphere together (as the fornix, processus e cerebello ad testes, etc.) or even different parts of the same section or organ, as the arciform fibres of the medulla. Most of these commissures are longitudinal, while others, as the corpus callosum and the transverse fibres of the pons Varolii, are transverse, serving to connect opposite hemispheres together, and thus probably securing the single action of a double organ.

The manner in which the gray and white matter are intermingled in the brain and spinal cord is very intricate, and can only be fully understood by a careful study of the details of its descriptive anatomy in the sequel. The further consideration of this subject will therefore be deferred until after the description of the various divisions of which the cerebro-spinal system is made up.

The **Nerves** are round or flattened cords formed of the nerve-fibres already described. They are connected at one end with the cerebro-spinal centre or with the ganglia, and are distributed at the other end to the various textures of the body; they are subdivided into two great classes—the *cerebro-spinal*, which proceed from the cerebro-spinal axis, and the *sympathetic* or *ganglionic* nerves, which proceed from the ganglia of the sympathetic.

The **Cerebro-spinal nerves** consist of numerous nerve-fibres collected together and enclosed in a membranous sheath (Fig. 53). A small bundle of primitive fibres enclosed in a tubular sheath is called a *funiculus;* if the nerve is of small size, it may consist only of a single funiculus, but if large, the funiculi are collected together into larger bundles or fasciculi, which are bound together in a common membranous investment, and constitute the nerve.

FIG. 53.

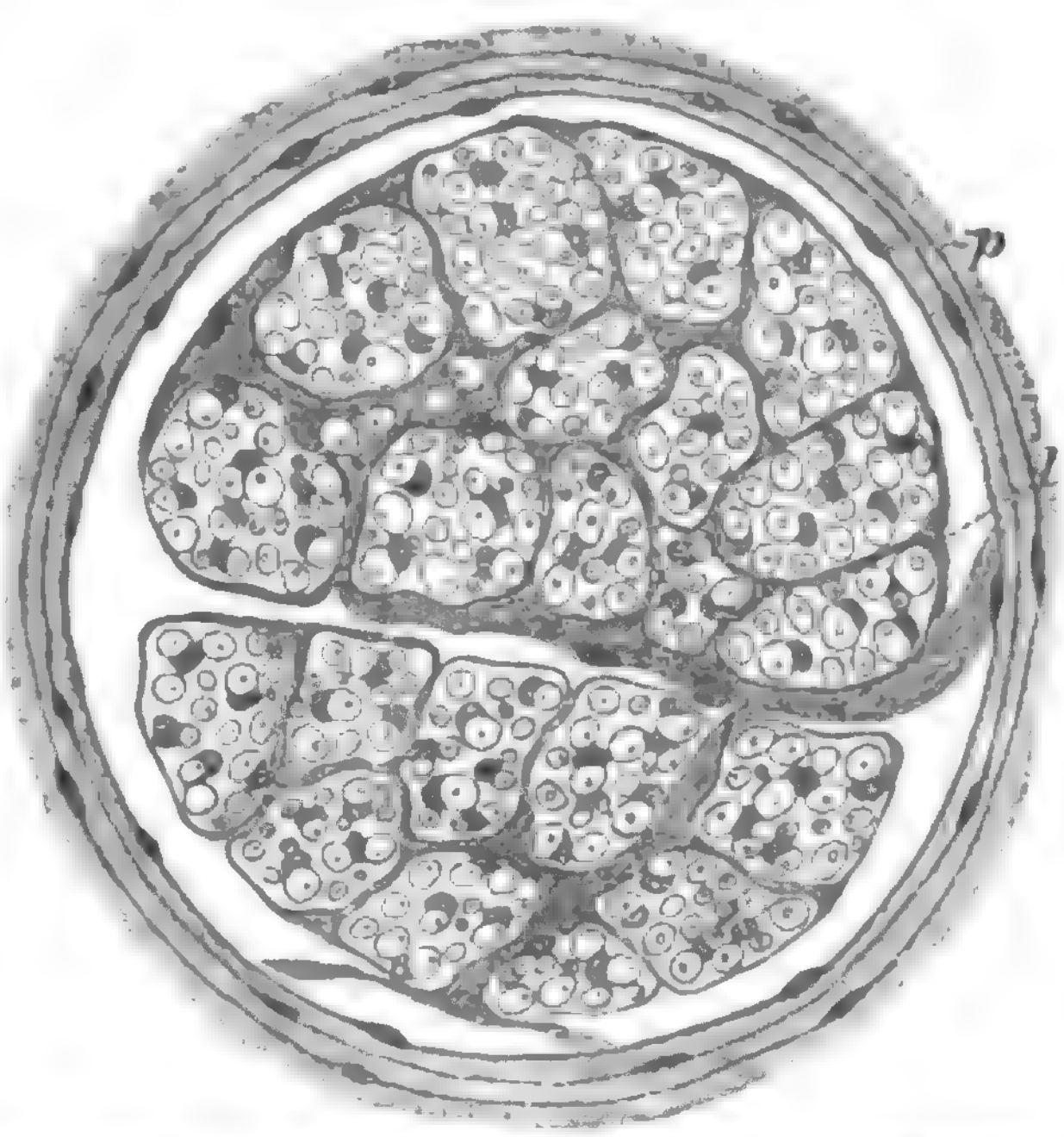

Transverse Section through a Microscopic Nerve, representing a compound nerve-bundle, surrounded by perineurium (magnified 120 diameters). The medullated fibres are seen as circles with a central dot—viz. medullary sheath and axis-cylinder in transverse section. They are imbedded in endoneurium containing numerous nuclei, which belong to the connective-tissue cells of the latter (Klein and Noble Smith): *p*, perineurium, consisting of laminæ of fibrous connective tissues, alternating with flattened nucleated connective-tissue cells: *l*, lymph-space between perineurium and surface of nerve-bundle.

In structure the common membranous investment, or sheath of the whole nerve, which is called the *epineurium*, as well as the septa given off from it, and which separate the fasciculi, consists of areolar tissue, composed of white and yellow elastic fibres, the latter existing in great abundance. The tubular sheath of the funiculi, called the *neurilemma* or *perineurium*, consists of a fine, smooth, transparent membrane, which may be easily separated, in the form of a tube, from the fibres it encloses; in structure it consists of connective tissue, which has a distinctly lamellar arrangement, consisting of several lamellæ, separated from each other by spaces containing lymph. The cerebro-spinal nerves consist almost exclusively of the medullated nerve-fibres, the non-medullated existing in very small proportions.

The blood-vessels supplying a nerve terminate in a minute capillary plexus, the vessels composing which run, for the most part, parallel with the funiculi; they are connected together by short transverse vessels forming narrow oblong meshes, similar to the capillary system of muscle.

The nerve-fibres, as far as is at present known, do not coalesce, but pursue an uninterrupted course from the centre to the periphery. In separating a nerve, however, into its component funiculi, it may be seen that they do not pursue a perfectly insulated course, but occasionally join at a very acute angle with other funiculi proceeding in the same direction; from this branches are given off, to join again in like manner with other funiculi. It must be remembered, however, that in these communications the nerve-fibres do not coalesce, but merely pass into the sheath of the adjacent nerve, become intermixed with its nerve-fibres, and again pass on, to become blended with the nerve-fibres in some adjoining funiculus.

Nerves, in their course, subdivide into branches, and these frequently communicate with branches of a neighboring nerve. In the subdivision of a nerve, the filaments of which it is composed are continued from the trunk into the branches, and at their junction with the branches of neighboring nerves the filaments pass to become intermixed with those of the other nerves in their further progress; in no instance, however, have the separate nerve-fibres been shown to inosculate. The communications which take place between two or more nerves form what is called a *plexus*.

Sometimes a plexus is formed by the primary branches of the trunks of the nerves —as the cervical, brachial, lumbar, and sacral plexuses—and occasionally by the terminal funiculi, as in the plexuses formed at the periphery of the body. In the formation of a plexus the component nerves divide, then join, and again subdivide in such a complex manner that the individual funiculi become interlaced most intricately, so that each branch leaving a plexus may contain filaments from each of the primary nervous trunks which form it. In the formation also of smaller plexuses at the periphery of the body there is a free interchange of the funiculi and primitive fibres. In each case, however, the individual filaments remain separate and distinct, and do not inosculate with one another.

It is probable that through this interchange of fibres the different branches passing off from a plexus have a more extensive connection with the spinal cord than if they each had proceeded to be distributed without such connection with other nerves. Consequently, the parts supplied by these nerves have more extended relations with the nervous centres; by this means, also, groups of muscles may be associated for combined action.

The **Sympathetic nerves** are constructed in the same manner as the cerebro-spinal nerves, but consist mainly of non-medullated fibres collected into funiculi and enclosed in a sheath of connective tissue. There is, however, in these nerves a certain admixture of medullated fibres, the amount of which varies in different nerves. They may be known by their color. Those branches of the sympathetic which present a well-marked gray color are composed more especially of gelatinous nerve-fibres, intermixed with a few medullated fibres, whilst those of a white color contain more of the latter fibres and a few of the former. Occasionally, the gray and white cords run together in a single nerve, without any intermixture, as in the branches of communication between the sympathetic ganglia and the spinal nerves or in the communicating cords between the ganglia.

The nerve-fibres, both of the cerebro-spinal and sympathetic system, convey impressions of a twofold kind. The sensory nerves, called also *centripetal* or *afferent* nerves, transmit to the nervous centres impressions made upon the peripheral extremities of the nerves, and in this way the mind, through the medium of the brain, becomes conscious of external objects. The *motor* nerves, called also *centrifugal* or *efferent* nerves, transmit impressions from the nervous centres to the parts to which the nerves are distributed, these impressions either exciting muscular contraction or influencing the processes of nutrition, growth, and secretion.

Origin and Termination of Nerves.—By the expression "the termination of nerve-fibres" is signified their connections with the nerve-centres and with the parts they supply. The former are sometimes called their *origin* or *central* termination, the latter their *peripheral* termination. The origin in some cases is single; that is to say, the whole nerve emerges from the nervous centre by a single root; in other instances the nerve arises by two or more roots, which come off from different parts of the nerve-centre, sometimes widely apart from each other; and it often happens that when a nerve arises in this way by two roots the functions of these two roots are different; as, for example, in the spinal nerves, each of which arises by two roots, the anterior of which is motor, and the posterior sensory. The point where the nerve-root or roots emerge from the nervous centre is named the *superficial* or *apparent* origin, but the fibres of which the nerve consists can be traced for a certain distance into the nervous centre to some portion of the gray substance, which constitutes the *deep* or *real* origin of the nerve. The exact manner in which the fibres of which the nerve-root is made up arise at their deep origin is, to a certain extent, uncertain. But it would appear probable that there are two modes in which they originate and are connected with the nerve-cells. If the multipolar nerve-cells are examined, it will be found that one at least of their processes does not branch; this process is named the *axial-cylinder* process, and at first has all the characters of an axis-cylinder. Soon, however, it acquires a medullary sheath, and has been traced to be directly continuous with a nerve-fibre. Other processes of a multipolar cell divide and subdivide as they pass away from the cell, until at last they form branches of extreme tenuity and form an excessively minute network. These processes apparently consist of cell-protoplasm, and are named *protoplasm* processes. From the network which they form minute medullated nerve-fibres arise. So that it would appear that nerve-fibres arise—first, directly through the passage of the non-branched axis-cylinder process into a fibre; and secondly, through the minute network formed by the branched protoplasm processes.

Peripheral Terminations of Nerves.—The manner in which nerve-fibres terminate peripherally are several, and may be conveniently studied in the sensory and motor nerves respectively. **Sensory** nerves would appear to terminate either in minute primitive fibrillæ or networks of these, or else in special terminal organs, which have been termed *peripheral end-organs*, and of which there are three principal varieties—viz. the end-bulbs of Krause, the tactile corpuscles of Wagner, and the Pacinian corpuscles.

When a medullated nerve-fibre approaches its termination the white substance of Schwann suddenly disappears, leaving only the axis-cylinder surrounded by the neurilemma, and we have now a non-medullated fibre. This undergoes repeated division, and after a time loses its neurilemma, and consists only of an axis-cylinder, which can be seen, in preparations stained with chloride of gold, to be made up of fine varicose fibrils. Finally, the axis-cylinder breaks up its constituent primitive nerve-fibrillæ, which anastomose with one another, thus forming a network, and often present regular varicosities. This network passes between the elements of the tissue to which the nerves are distributed, and, as is believed by some, actually forms a connection with the cells of the tissue or else simply comes in contact with them. In this way nerve-fibres have been found to terminate in the epithelium of the skin and mucous membranes and in the anterior epithelium of the cornea.

The **End-bulbs of Krause** are minute oblong or cylindrical corpuscles, into the interior of which the axis-cylinder of the nerve-fibre passes and terminates in a coiled plexiform mass or in a bulbous extremity. The corpuscle consists of a simple nucleated capsule containing a soft homogeneous core, in which the termination of the axis-cylinder is contained. The white matter of Schwann ceases abruptly as the axis-cylinder enters the corpuscle, but the neurilemma is continued inward with the axis-cylinder, and forms an investment of the core, lining the interior of the capsule. The end-bulbs have been described as occurring in the conjunctivæ (where, in man, they are spheroidal in shape), in the mucous membrane of the mouth, and in the cutis and mucous membrane of the penis, clitoris, and vagina, where they are termed *genital corpuscles*.

The **Tactile Corpuscles of Wagner** (Fig. 54) are described by him as oval-shaped bodies made up of a soft structureless core, in which the nerve-fibres terminate by bulbous enlargements, the whole being enclosed in a capsule of connective tissue, so arranged in superimposed laminæ as to present a resemblance to a miniature fir-cone; and he regarded them as directly concerned in the sense of touch. Kölliker considers that the central part of the papillæ generally consists of a connective tissue more homogeneous than that of the outer part, surrounded by a sort of sheath of elastic fibres; and he believes that these corpuscles are merely a variety of this structure. The nerve-fibres, according to this observer, run up in a waving course to the corpuscle, not penetrating it, but forming two or three coils round it, and finally join together in loops. It would appear, however, that the medullated fibre winds round the corpuscle once or twice, and then loses its medullary sheath and penetrates as an axis-cylinder into the interior of the corpuscle, and there branches, the branches pursuing a coiled direction within the capsule and terminating in bulbous enlargements. These tactile corpuscles have been described as occurring in the papillæ of the skin of the fingers and toes. They are not found in all the papillæ; but from their existence in those parts in which the skin is highly sensitive it is probable that they are specially concerned in the sense of touch, though their absence from the papillæ of other tactile parts shows that they are not essential to this sense.

The **Pacinian Corpuscles**[1] (Fig. 55) are found in the human subject chiefly on the nerves of the fingers and toes, lying in the subcutaneous tissue; but they have also been described as connected with the nerves of the joints, in the genital organs of man, and in some other situations. Each of these corpuscles is attached to and encloses the termination of a single nerve-fibre. The corpuscle, which is perfectly visible to the naked eye (and which can be most easily demonstrated in the mesentery of a cat), consists of a number of concentric layers of cellular tissue, between which Todd and Bowman have figured capillary vessels as running. The tissue of each lamella is lax, and the interstices between its fibres are filled by a considerable quantity of watery fluid; it is covered on each surface by a layer of epithelioid cells. The nerve at its entrance into this body parts with its white substance, and the axis-cylinder runs forward into a kind of cavity in the centre of the corpuscle containing a core of homogeneous material, to terminate in a rounded knob or end, sometimes bifurcating previously, in which case each branch has a similar arrangement. Grandry, who has examined these corpuscles with very high magnifying powers, describes the axis-cylinder as exhibiting a very well-marked fibrillar structure, and the bulbous end as consisting of a mass of granules into which the fibrils run, diverging as they approach it. The investing capsules are from thirty to sixty in number, the outer being more or less separated from each other by a clear fluid—lymph—while the inner are more closely applied together. Schultze calls attention to the striking resemblance between the central part or core of these Pacinian corpuscles and Krause's end-bulbs above described.

---

[1] Often called in German anatomical works "corpuscles of Vater."

FIG. 54.

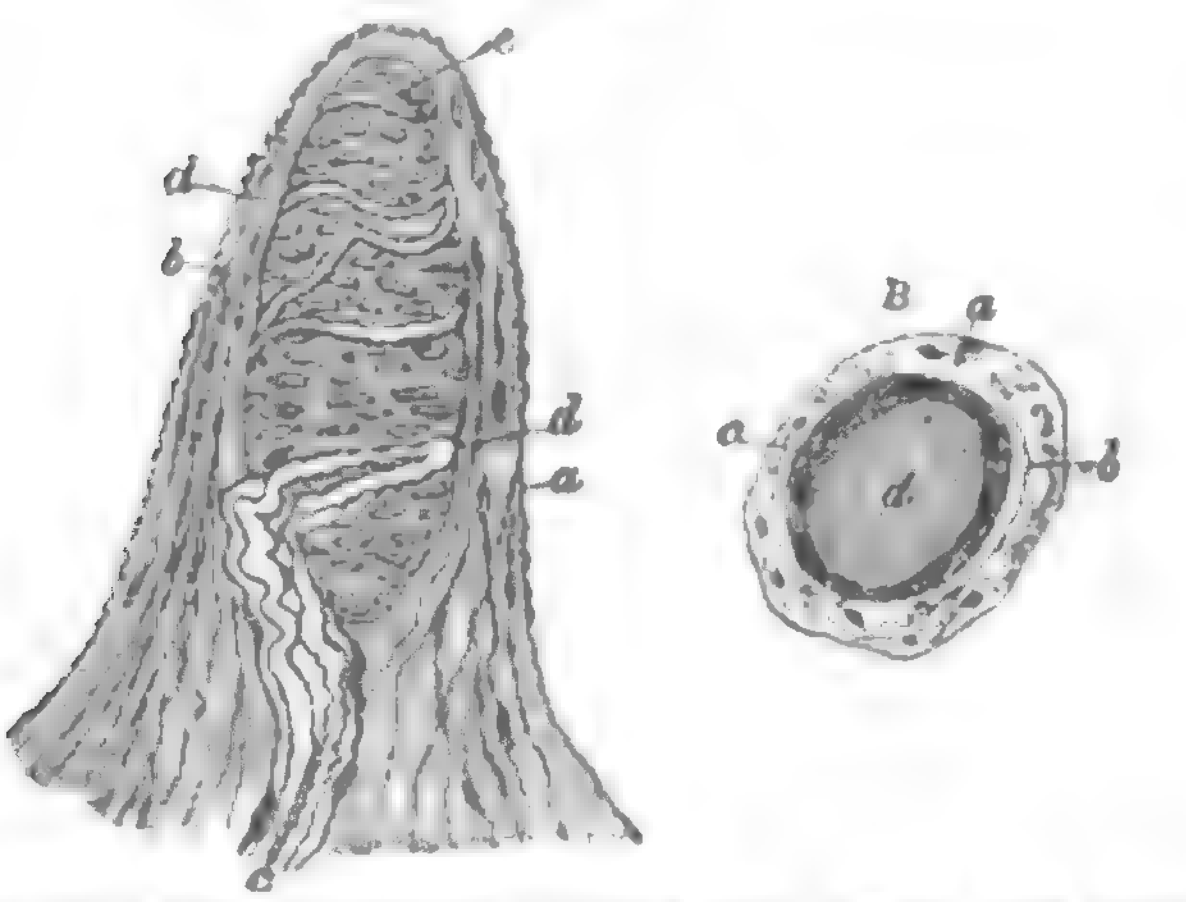

From the Human Subject, treated with acetic acid (magnified 350 times): A, side view of a papilla of the hand; *a*, cortical layer; *b*, tactile corpuscle, with transverse nuclei; *c*, small nerve of the papilla, with neurilemma; *d*, its two nervous fibres running with spiral coils around the tactile corpuscle; *e*, apparent termination of one of these fibres.

B, a tactile papilla seen from above, so as to show its transverse section; *a*, cortical layer; *b*, nerve-fibre; *c*, outer layer of the tactile body, with nuclei; *d*, clear interior substance.

FIG. 55.

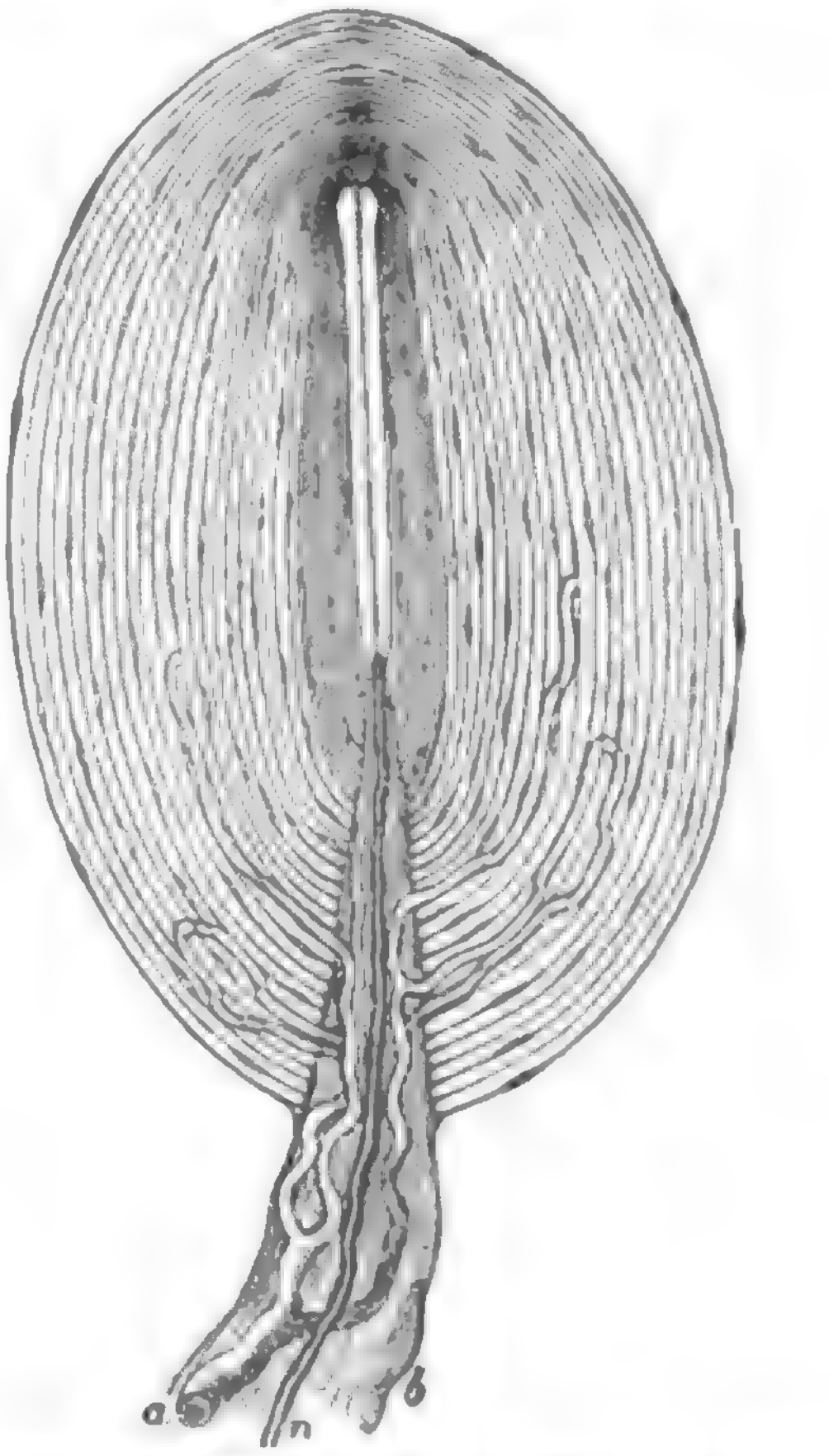

Pacinian Corpuscle, with its system of capsules and central cavity: *a*, arterial twig, ending in capillaries, which form loops in some of the intercapsular spaces, and one penetrates to the central capsule; *b*, the fibrous tissue of the stalk prolonged from the perineurium; *n*, nerve-tube advancing to the central capsule, there losing its white substance, and stretching along the axis to the opposite end, where it is fixed by a tubercular enlargement.

In the organs of special sense the nerves terminate in cells which are modified epithelium-cells, and have received the name of *sensory* or *nerve-epithelium* cells. The axis-cylinder, after dividing into fibrils, ends in epithelium-cells variously modified, and to the peripheral extremity of which are often connected peculiar styliform processes. These cells will be more particularly described in the sequel, in connection with the description of the organs of special sense.

Motor nerves are to be traced either into unstriped or striped muscular fibres. In the **unstriped** or **involuntary** muscles the nerves are derived from the sympathetic, and are composed mainly of the non-medullated fibres. Near their terminations they divide into a number of branches, which communicate and form an intimate plexus. At the junction of the branches small nuclear bodies are situated. From these plexuses minute branches are given off, which divide and break up into the ultimate fibrillæ of which the nerve is composed. These fibrillæ course between the involuntary muscle-cells, and, according to Elischer, terminate on the surface of the cell, opposite the nucleus, in a minute swelling. Arnold and Frankenhäuser believed that these ultimate fibrillæ penetrated the muscular cell and ended in the nucleus. More recent observation has, however, tended to disprove this.

In the **striped** or **voluntary** muscle the nerves supplying striped muscular fibre are derived from the cerebro-spinal nerves, and are composed mainly of medullated fibres. The nerve, after entering the sheath of the muscle, breaks up into fibres or bundles of fibres which form plexuses, and gradually divide until, as a rule, a single nerve-fibre enters a single muscular fibre. Sometimes, however, if the muscular fibre is long, more than one nerve-fibre enters it. Within the muscular fibre the nerve terminates in a special expansion, called by Kühne, who first accurately described them, *motorial end-plates* (Fig. 56).[1] The nerve-fibre on approaching the muscular fibre suddenly loses its white matter of Schwann, which abruptly terminates; the nucleated sheath becomes continuous with the sarcolemma of the muscle, and only the axis-cylinder enters the muscular fibre, where it immediately spreads out, ramifying like the roots of a tree, immediately beneath the sarcolemma, and is imbedded in a layer of granular matter containing a number of clear oblong nuclei, the whole constituting an end-plate from which the contractile wave of the muscular fibre is said to start.

FIG. 56.

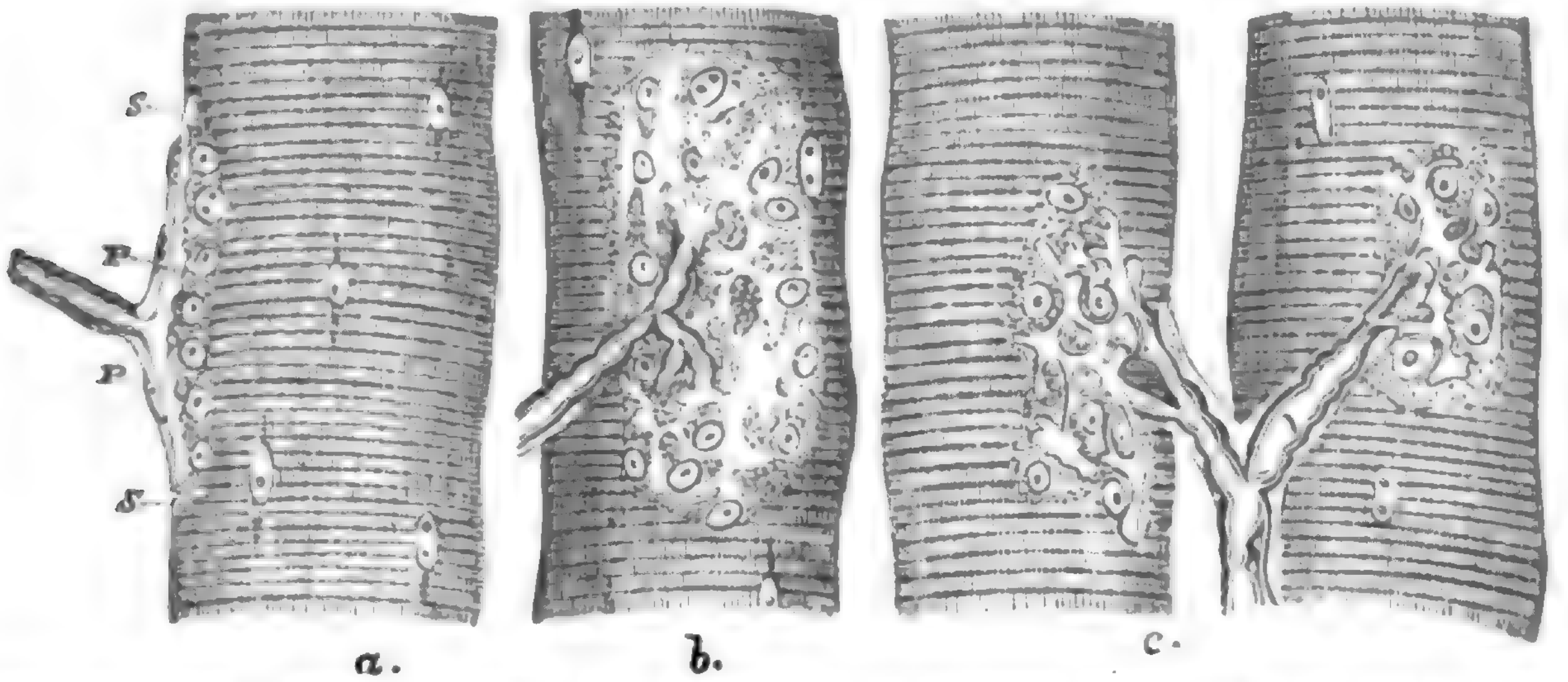

Muscular Fibres of *Lacerta viridis*, with the terminations of nerves: *a*, seen in profile; P, P, the nerve-end plates, S, S, the base of the plate, consisting of a granular mass with nuclei; *b*, the same, as seen in looking at a perfectly fresh fibre, the nervous ends being probably still excitable. (The forms of the variously divided plate can hardly be represented in a woodcut by sufficiently delicate and pale contours to reproduce correctly what is seen in nature.) *c*, the same as seen two hours after death from poisoning by curare.

The **Ganglia** may be regarded as separate and independent nervous centres, of smaller size and less complex structure than the brain, connected with each other, with the cerebro-spinal axis, and with the nerves in various situations. They are found on the posterior root of each of the spinal nerves, on the posterior or sensory root of the fifth cranial nerve, on the facial nerve, on the glosso-pharyngeal and pneumogastric nerves, and on the branches of certain spinal nerves. They are also found in a connected series along each side of the vertebral column, forming the trunk of the sympathetic, and on the branches of that nerve, generally in the plexuses or at the point of junction of two or more nerves with each other or with branches of the cerebro-spinal system. On section they are seen to consist of a reddish-gray substance traversed by numerous white nerve-fibres; they vary considerably in form and size; the largest are found in the cavity of the abdomen; the smallest, not visible to the naked eye, exist in considerable numbers upon the nerves distributed to the different viscera. The ganglia are invested by a smooth and firm, closely-adhering, membranous envelope consisting of dense areolar tissue; this sheath is continuous with the perineurium of the nerves, and sends numerous processes into the interior of the ganglion, which support the blood-vessels supplying its substance.

---

[1] They had, however, previously been noticed, though not accurately described, by Doyère, who named them "nerve-hillocks."

In structure all ganglia are essentially similar (Fig. 57), consisting of the same structural elements as the other nervous centres—viz. a collection of *vesicular nervous matter* traversed by tubular and gelatinous *nerve-fibres*. The vesicular nervous matter consists of nerve- or ganglion-cells, most of which appear to be free and of a round or oval form; these are more especially seated near the surface of the ganglion; others are unipolar, bipolar, or multipolar, and their caudate processes give origin to nerve-fibres. In the ganglion the nerve-cells are usually enclosed in a transparent capsule with nuclei on its inner surface. The nerve-fibres on entering the ganglion lay aside their perineurium, which becomes continuous with the capsule. Some of the fibres run through the ganglion without being connected with the cells, others arise from the caudate processes of the cells.

FIG. 57.

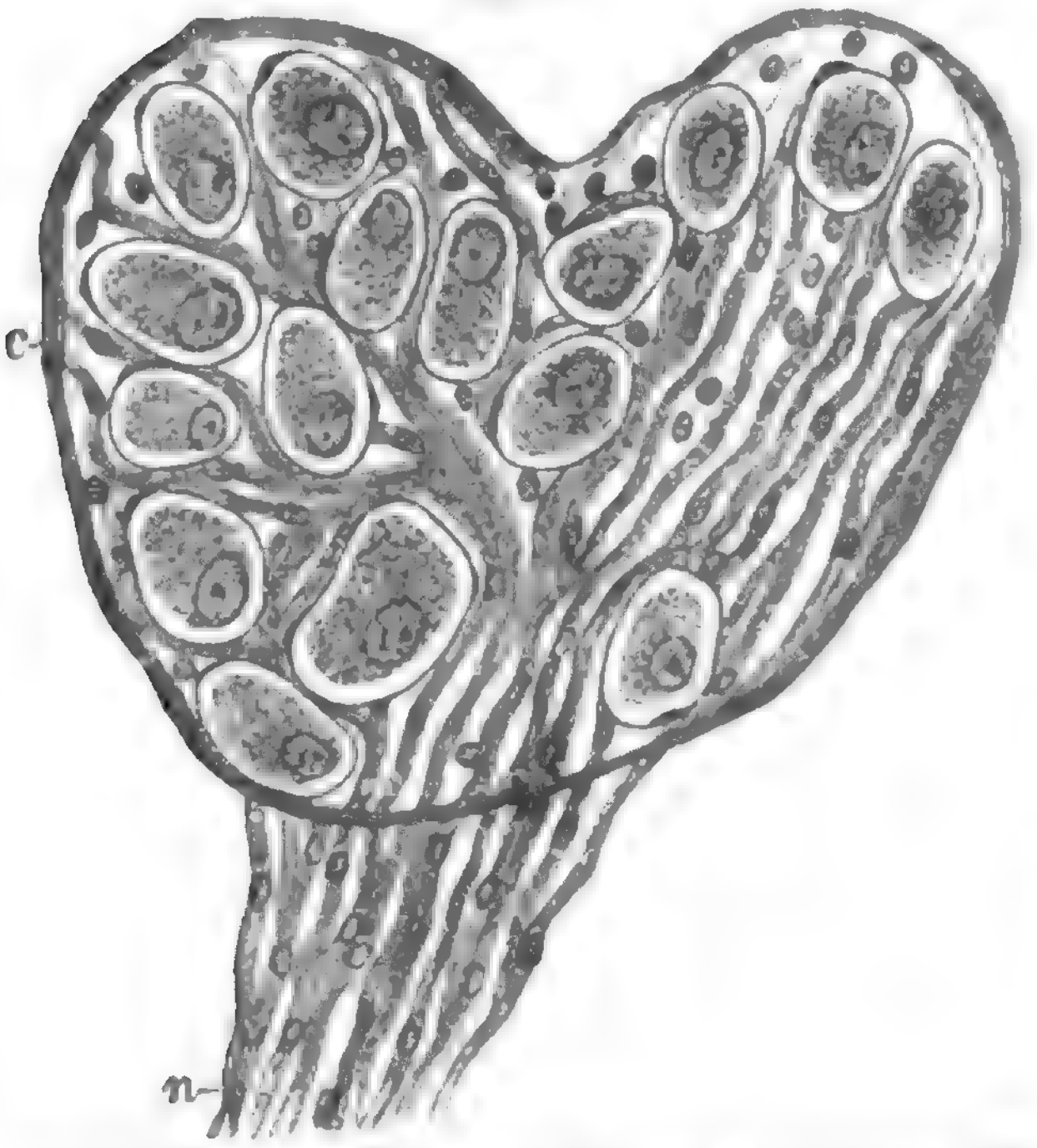

Section through a Microscopic Ganglion (magnified 300 diameters—Klein and Noble Smith): *c*, capsule of the ganglion; *n*, nerve-fibres passing out of the ganglion. The nerve-fibres which entered the ganglion are not represented. The nerve-fibres are ordinary medullated fibres, but the details of their structure are not shown, owing to the low magnifying power. The ganglion-cells are invested by a special capsule lined by a few nuclei, which are here represented as if contained *in* the capsule.

A remarkable modification of the bipolar nerve-cell is found in the sympathetic ganglia, especially in the frog, but also in some few instances in the mammal. The cells are pear-shaped, and from the narrow end two processes arise—one a straight axis-cylinder process, into which the substance of the ganglion is prolonged; the other, a thin fibre, winds spirally round the straight fibre, and then passes away from the cell in the opposite direction, and becomes invested with a medullary sheath and neurilemma of its own, and constitutes a medullated fibre, while the straight axis-cylinder process forms a non-medullated fibre.

THE VASCULAR SYSTEM.

The **Vascular System**, exclusive of its central organ, the heart, is divided into four classes of vessels: the *arteries*, *capillaries*, *veins*, and *lymphatics*; the minute structure of which we will now proceed briefly to describe, referring the reader to the body of the work for all that is necessary in the details of their ordinary anatomy.

Structure of Arteries (Fig. 58).—The arteries are composed of three coats: internal or endothelial coat (*tunica intima* of Kölliker); middle [muscular and elastic] circular coat [*tunica media*]; and external cellular coat, or *tunica adventitia*.

The two inner coats together are very easily separated from the external, as by the ordinary operation of tying a ligature on an artery. If a fine string be tied forcibly upon an artery and then taken off, the external coat will be found undivided, but the internal coats are divided in the track of the ligature, and can easily be further dissected from the outer coat. The inner coat can be separated from the middle by a little maceration, or it may be stripped off in small pieces; but on account of its friability it cannot be separated as a complete membrane. It is a fine, transparent, colorless structure which is highly elastic, and is commonly corrugated into longitudinal wrinkles.

The *inner* coat [*tunica intima*] consists of—1. A layer of pavement-epithelium, the the cells of which are polygonal, oval, or fusiform, and have very distinct round or oval nuclei. This endothelium, as it is now generally called, is brought into view most distinctly by staining with nitrate of silver. 2. A subepithelial layer, consisting of delicate connective tissue with branched cells lying in the interspaces of the tissue. 3. An elastic or fenestrated layer, which consists of an elastic membrane containing a network of elastic fibres, having principally a longitudinal direction, and in which, under the microscope, small elongated apertures or perforations may be seen, giving it a fenestrated appearance. It was therefore called by Henle the *fenestrated membrane.* This membrane forms the chief thickness of the inner coat, and can be separated into several layers, some of which present the appearance of a network of longitudinal elastic fibres, and others present a more membranous character, marked by pale lines having a longitudinal direction. In arteries of less than a line in diameter the subepithelial layer consists of a single layer of stellate cells, and the connective tissue is only largely developed in the large-sized vessels. The fenestrated membrane in microscopic arteries is a very thin layer, but in the larger arteries, and especially in the aorta, it has a very considerable thickness.

FIG. 58.

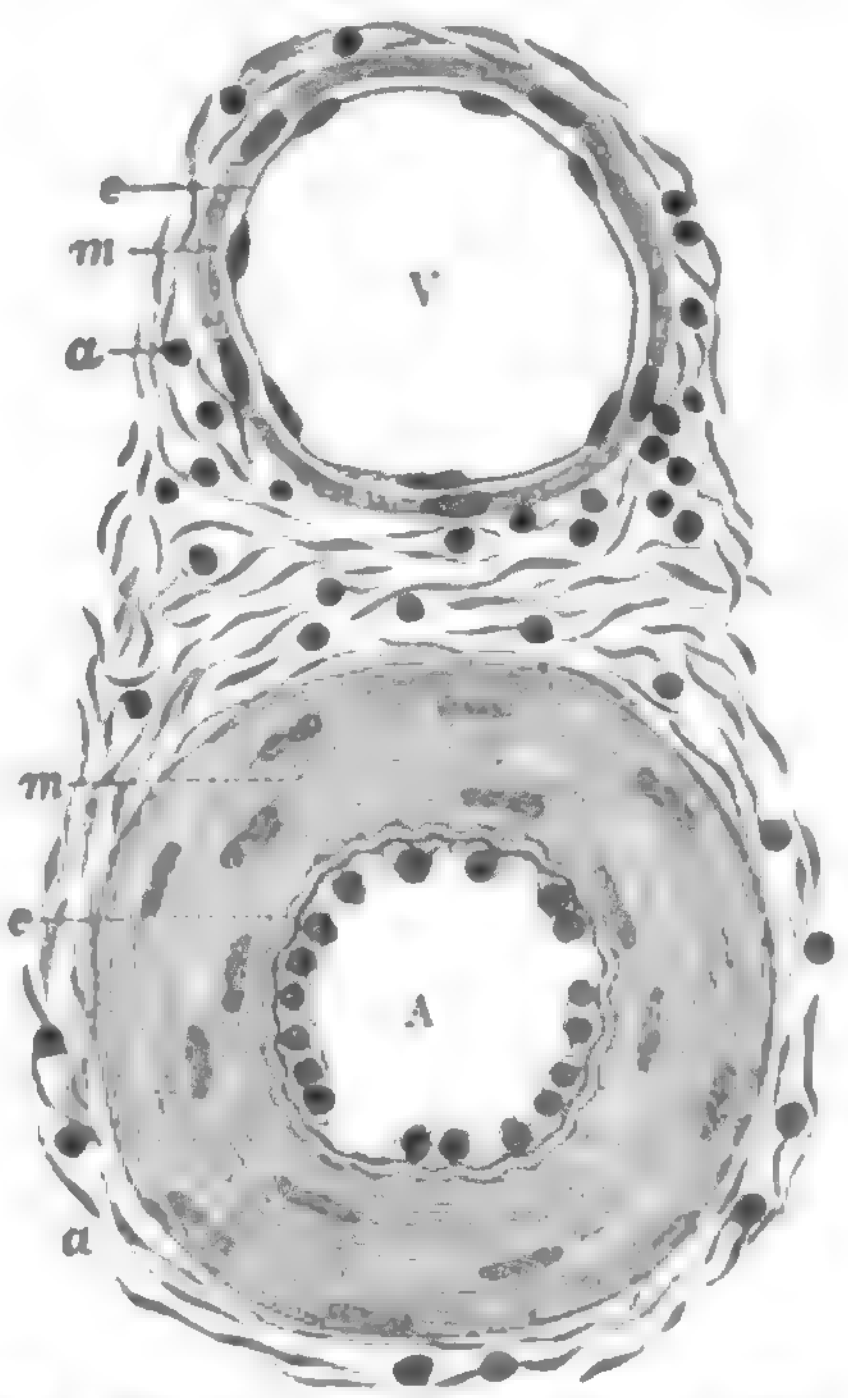

Transverse Section through a Small Artery and Vein of the Mucous Membrane of the Epiglottis of a Child (magnified about 350 diameters—Klein and Noble Smith): A, artery showing the nucleated endothelium, *e*, which lines it: the vessel being contracted, the endothelial cells appear very thick. Underneath the endothelium is the wavy elastic intima. The chief part of the wall of the vessel is occupied by the circular muscle-coat, *m*; the staff-shaped nuclei of the muscle-cells are well seen. Outside this is *a*, part of the adventitia. This is composed of bundles of connective-tissue fibres, shown in section, with the nuclei of the connective-tissue corpuscles. The adventitia gradually merges into the surrounding connective tissue.

V, vein showing a thin endothelial membrane, *e*, raised accidentally from the intima, which on account of its delicacy is seen as a mere line on the media, *m*. This latter is composed of a few circular unstriped muscle-cells; *a*, the adventitia, similar in structure to that of an artery.

The *middle* coat (*tunica media*) is distinguished from the inner by its color and by the transverse [*i. e.* circular] arrangement of its fibres, in contradistinction to the longitudinal direction of those of the inner coat. [It consists of two elements, the *elastic* and the *muscular.* The *elastic* predominates largely in the aorta and its branches. These are distended by the blood forced into them by the systole of the heart, and by their gradual contraction during the diastole they keep up the continuous blood-current. The elastic element gradually diminishes as we go from the heart toward the periphery. The *muscular* element gradually increases as we go from the aorta toward the smaller arteries, where it reaches its maximum. Its function is, by its contraction and relaxation, to regulate the amount of blood sent to any part. It diminishes, and finally disappears, as we leave the smaller arteries and approach the capillaries.] In the largest arteries this coat is of great thickness, of a yellow color, and highly elastic: it diminishes in thickness and becomes redder in color as the arteries become smaller, and finally becomes very thin and disappears. In small arteries this coat is purely muscular, consisting of muscular fibre-cells (Fig. 45) united to form lamellæ which vary in number according to the size of the artery, the very small arteries having only a single layer, and those not larger than one-tenth of a line in diameter three or four layers. In arteries of medium size (Fig. 59) this coat becomes thicker in proportion to the size of the vessel; its layers of muscular tissue are more numerous and intermixed with numerous fine elastic fibres which unite to form broad-meshed networks. In the larger vessels, as the femoral, superior mesenteric, cœliac axis, external iliac, brachial, and popliteal arteries, the elastic fibres unite to form lamellæ, which alternate with the layers of muscular fibre. In the largest arteries the muscular tissue is only slightly developed, and forms about one-third or one-fourth of the whole substance of the middle coat; this is especially the case in the aorta and trunk of the pulmonary artery, in which the individual cells of the muscular layer are imperfectly formed, while in the carotid, axillary, iliac, and subclavian arteries the muscular layer of the middle coat is more developed. The elastic lamellæ are well marked, may amount to fifty or sixty in number, and alternate regularly with the layers of muscular tissue. They are most distinct and arranged with great regularity in the abdominal aorta, innominate artery, and common carotid.

FIG. 59.

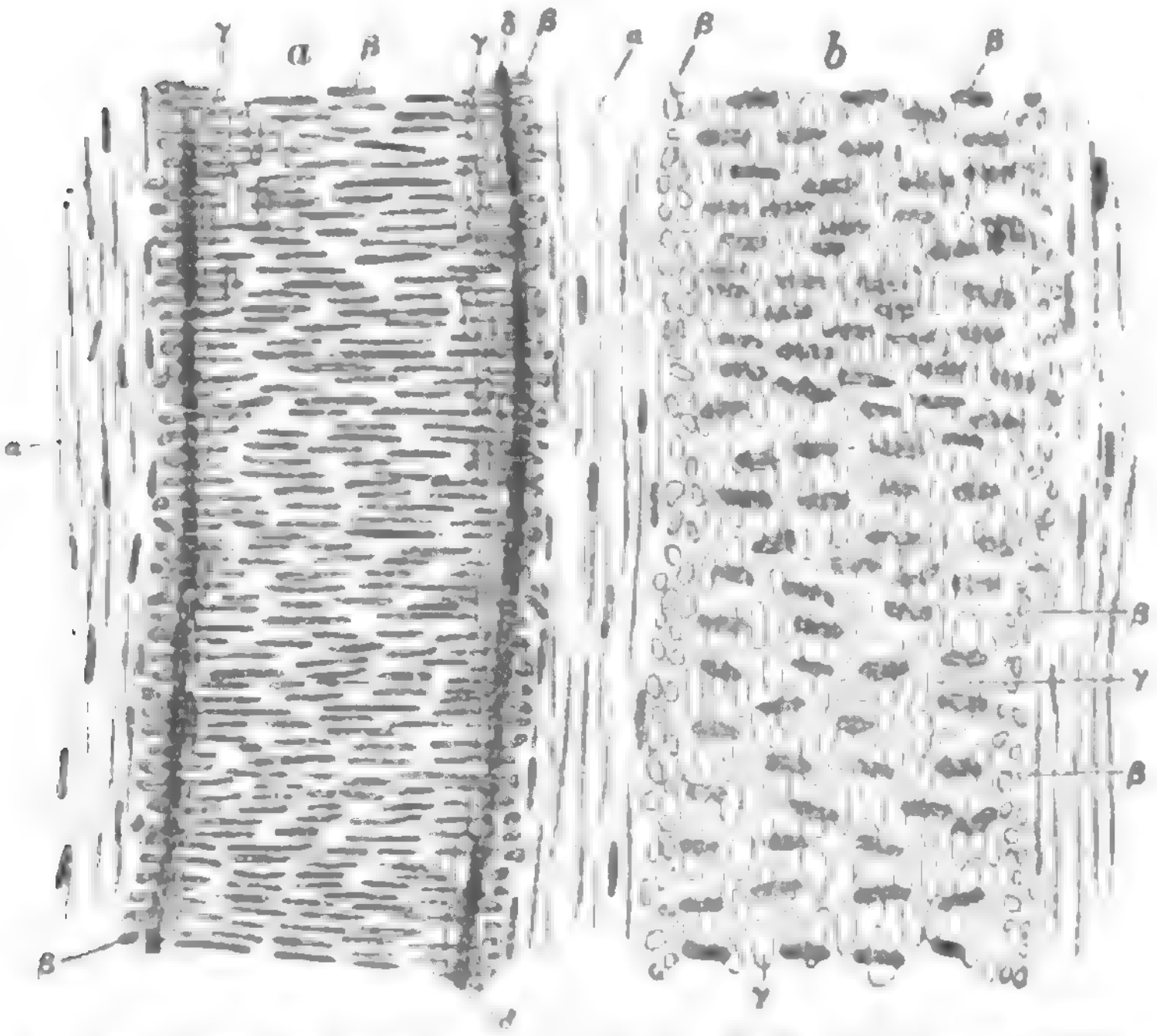

a, Artery from the Mesentery of a Child, .062‴, and *b*, vein .067‴ in diameter, treated with acetic acid and magnified 350 times: α, tunica adventitia, with elongated nuclei; β, nuclei of the contractile fibre-cells of the tunica media, seen partly from the surface, partly apparent in transverse section; γ, nuclei of the endothelial cells; δ, elastic longitudinal fibrous coat.

The *external* coat (*tunica adventitia*) consists mainly of connective tissue, and contains elastic fibres in all but the smallest arteries. In the largest vessels the external coat is relatively thin, but in small arteries it is as thick or thicker than the middle coat. In arteries of the medium size, and above it, the external coat is formed of two layers, the outer of which consists of connective tissue containing an irregular elastic network, while the inner is composed of elastic tissue only. The inner elastic coat is very distinct in the carotid, femoral, brachial, profunda femoris, mesenteric, and cœliac axis, the elastic fibres being often arranged in lamellæ. In the smaller arteries the external tunic consists of a single layer of mixed connective tissue and elastic fibres; while in the smallest arteries, just above the capillaries, the elastic fibres are wanting, and the connective tissue, of which the coat is composed, becomes more homogeneous the nearer it approaches the capillaries, and is gradually reduced to a thin membranous envelope, which finally disappears.

Some arteries have extremely thin coats in proportion to their size; this is especially the case in those situated in the cavity of the cranium and spinal canal, the difference depending on the greater thinness of the external and middle coats. The arteries in their distribution throughout the body are included in a thin fibro-areolar investment, which forms what is called their sheath. In the limbs this is usually formed by a prolongation of the deep fascia; in the upper part of the thigh it consists of a continuation downward of the tranversalis and iliac fasciæ of the abdomen; in the neck, of a prolongation of the deep cervical fascia. The included vessel is loosely connected with its sheath by a delicate areolar tissue, and the sheath usually encloses the accompanying veins, and sometimes a nerve. Some arteries, as those in the cranium, are not included in sheaths.

All the larger arteries are supplied with blood-vessels like the other organs of the body; they are called the *vasa vasorum* [*i. e.* vessels of the vessels]. These nutrient vessels arise from a branch of the artery or from a neighboring vessel at some considerable distance from the point at which they are distributed; they ramify in the loose areolar tissue connecting the artery with its sheath, and are distributed to the external coat, but do not, in man, penetrate the other coats—[hence the danger, in ligating an artery in its continuity, of separating the sheath from it to any great extent], though in some of the larger mammals some few vessels have been traced into the middle coat. Minute veins serve to return the blood from these vessels; they empty themselves into the venæ comites in connection with the artery.

Arteries are also supplied with nerves, which are derived chiefly from the sympathetic, but partly from the cerebro-spinal system. They form intricate plexuses upon the surfaces of the larger trunks, the smaller branches being usually accompanied by single filaments. The branches derived from these plexuses penetrate the external coat, and are principally distributed to the muscular tissue of the middle coat. [These nerves regulate automatically the calibre of the vessels, and hence the blood-supply, both in health and disease.]

[For the lymph-spaces surrounding the blood-vessels (perivascular spaces) see the Lymphatic System, p. 87.]

The Capillaries.—The smaller arterial branches (excepting those of the cavernous structures of the sexual organs, of the spleen, and in the uterine placenta) terminate in a network of vessels which pervade nearly every tissue of the body. These vessels, from their minute size, are termed capillaries (*capillus*, a "hair"). They are interposed between the smallest branches of the arteries and the commencing veins, constituting a network the branches of which maintain the same diameter throughout, the meshes of the network being more uniform in shape and size than those formed by the anastomoses of the small arteries and veins.

The *diameter* of the capillaries varies in the different tissues of the body, their usual size being about $\frac{1}{3000}$ of an inch. The smallest are those of the brain and the mucous membrane of the intestines; and the largest, those of the skin and the marrow of bone, where they are stated to be as large as $\frac{1}{1200}$ of an inch.

The *form* of the *capillary net* varies in the different tissues, the meshes being generally rounded or elongated. The *rounded form of mesh* [Fig. 60] is most common, and prevails where there is a dense network, as in the lungs, in most glands and mucous membranes, and in the cutis; here the meshes are more or less angular, sometimes nearly quadrangular or polygonal, more frequently irregular.

[Fig. 60.

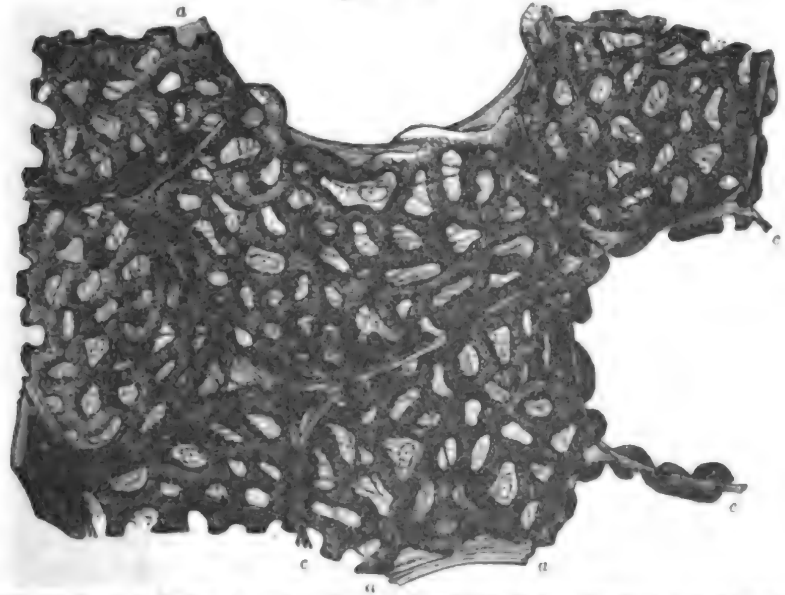

Section of Injected Lung, including several contiguous alveoli (highly magnified): *a, a*, free edges of alveoli; *c, c*, partitions between neighboring alveoli, seen in section; *b*, small arterial branch giving off capillaries to the alveoli. The looping of the vessels to either side of the partitions is well exhibited. Between the capillaries is seen the homogeneous alveolar wall with nuclei of connective-tissue corpuscles and elastic fibres (Schäfer's *Histology*).]

Elongated meshes (Fig. 61) are observed in the bundles of fibres and tubes composing muscles and nerves, the meshes being usually of a parallelogram form, the long axis of the mesh running parallel with the long axis of the nerve and fibre. Sometimes the capillaries have a *looped* arrangement, a single vessel projecting from the common network and returning after forming one or more loops, as in the papillæ of the tongue and skin. The number of the capillaries and the size of the meshes determine the degree of vascularity of a part. The closest network and the smallest interspaces are found in the lungs and in the choroid coat of the eye. In these situations the interspaces are smaller than the capillary vessels themselves. In the kidney, in the conjunctiva, and in the cutis the interspaces are from three to four times as large as the capillaries which form them, and in the brain from eight to ten times as large as the capillaries in their long diameter, and from four to six times as large in their transverse diameter. In the cellular coat of the arteries the width of the meshes is ten times that of the capillary vessels. As a general rule, the more active the function of the organ is, the closer is its capillary net and the larger its supply of blood, the network being very narrow in all growing parts, in the glands, and in the mucous membranes; wider in bones and ligaments, which are comparatively inactive; and nearly altogether absent in tendons, in which very little organic change occurs after their formation.

FIG. 61.

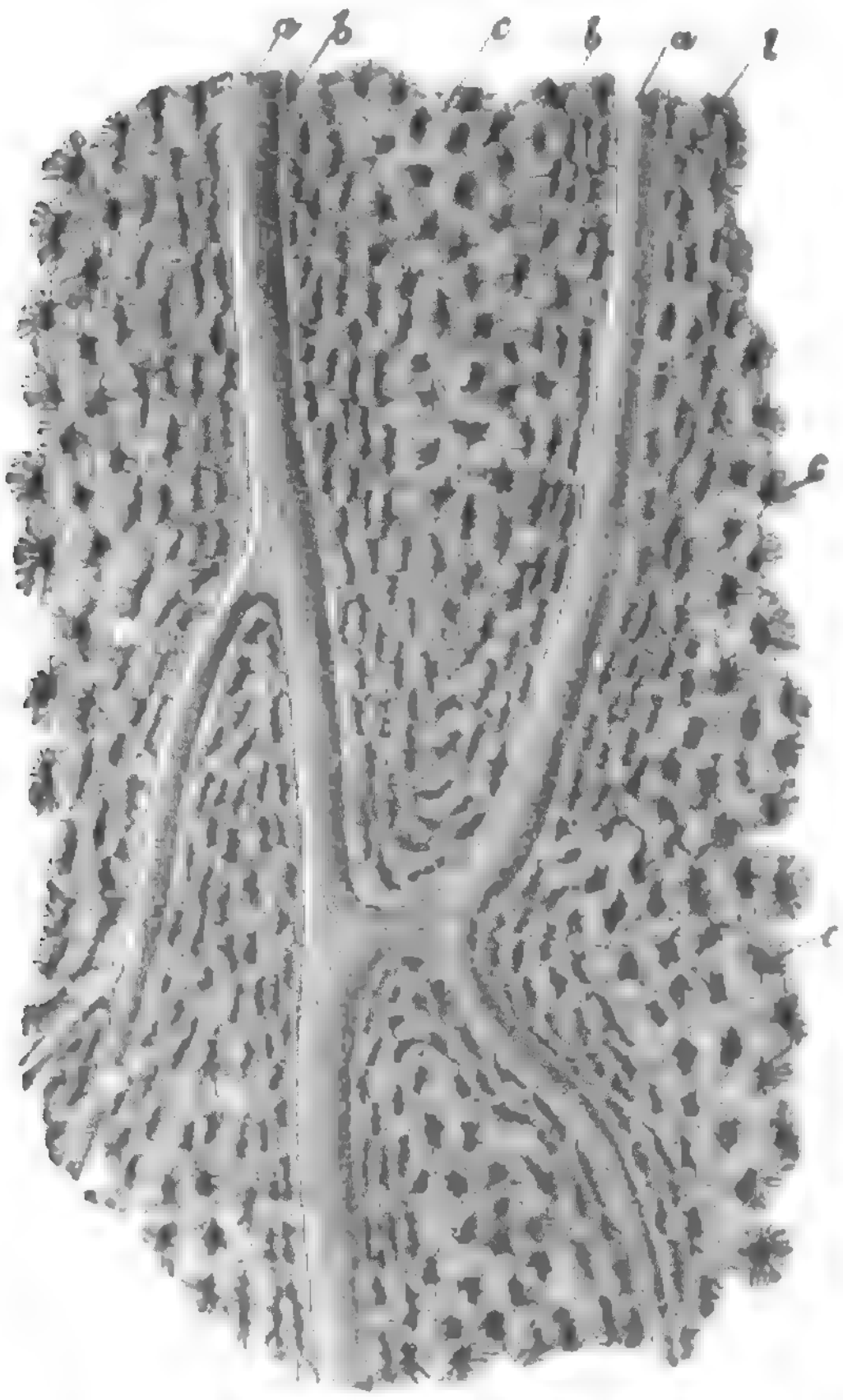

Section parallel to the surface from the Shaft of the Femur (magnified 100 times : *a*, Haversian canals; *b*, lacunæ seen from the side; *c*, others seen from the surface in lamellæ which are cut horizontally.

[FIG. 62.

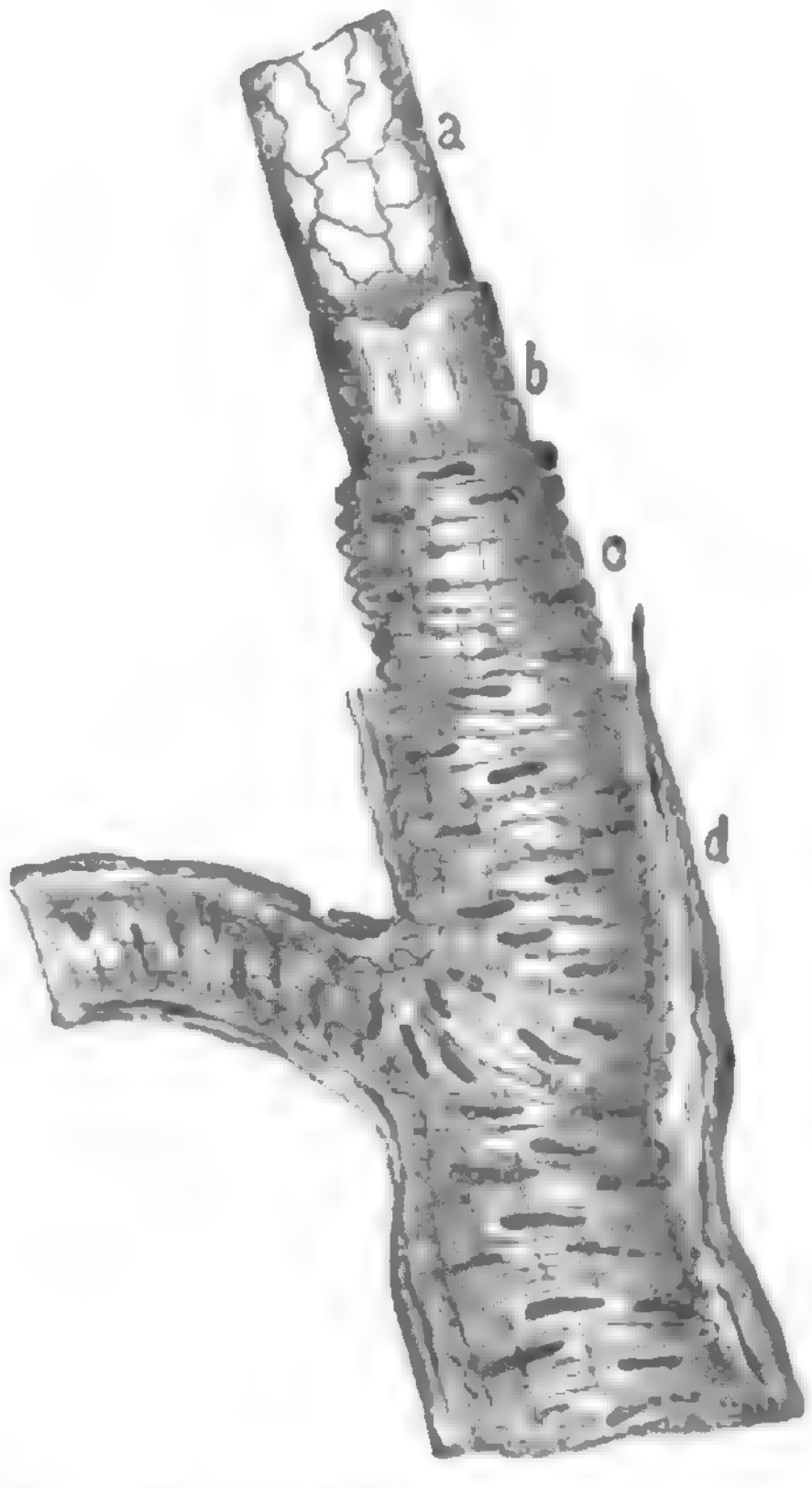

Small Artery to show the various layers which compose its walls: *a*, endothelium; *b*, internal elastic lamina; *c*, circular muscular fibres of the middle coat; *d*, the connective-tissue outer coat (tunica adventitia (Landois' *Physiology*, edit. by Stirling).]

Structure.—The walls of the capillaries consist of a fine, transparent endothelial layer, composed of cells joined edge to edge by an interstitial cement-substance, and continuous with the endothelial cells which line the arteries and veins. [The capillaries consist, therefore, purely of the tunica intima, which is reduced wholly or almost wholly to the endothelium. This fits them admirably for their function of the easy egress (exosmosis) of the fluid pabulum and the oxygen carried by the blood to all parts of the body, and the easy ingress (endosmosis) of the carbonic acid and other products of destruction by use of the various organs and tissues in solution. As we approach the arteries on one side or the veins on the other, the remaining two coats are gradually added to the intima (Fig. 62).] When stained with nitrate of silver the edges which bound the epithelial cells are brought into view (Figs. 62 and 63). These cells are of large size and of an irregular polygonal or lanceolate shape, each containing an oval nucleus, which may be brought into view by carmine or logwood. Between their edges, at various points of their meeting, roundish dark spots are sometimes seen, which have been described as stomata, though they are closed by intercellular substance. They have been believed to be the situation through which the white corpuscles of the blood, when migrating through the blood-vessels, emerge; but this view, though probable, is not universally accepted.

Fig. 64.

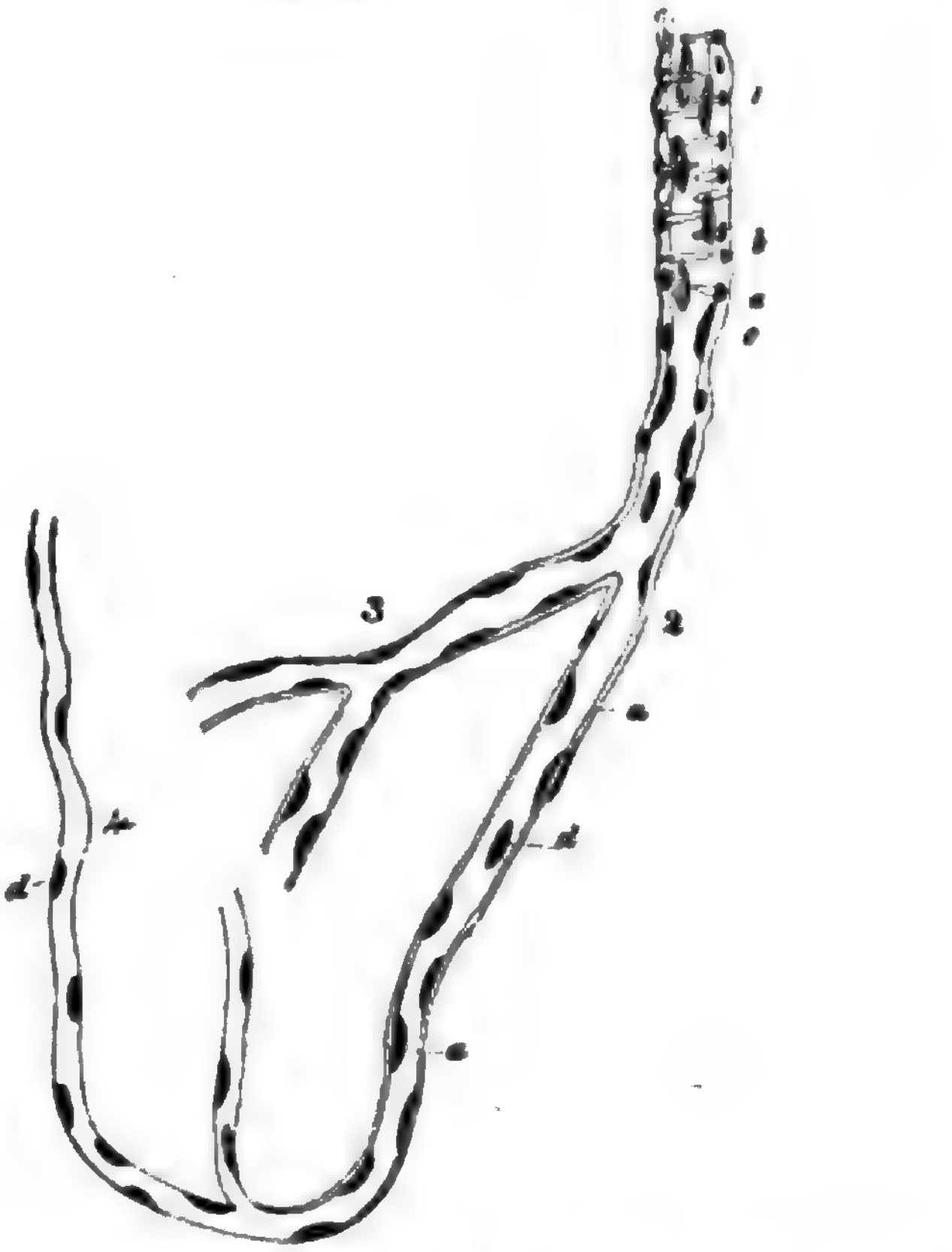

Finest Vessels on the Arterial Side, from the Human Brain (magnified 300 times): 1, smallest artery; 2, transition vessel; 3, coarser capillaries; 4, finer capillaries; *a*, structureless membrane still with some nuclei, representative of the tunica adventitia; *b*, nuclei of the muscular fibre-cells; *c*, nuclei within the small artery, perhaps appertaining to an endothelium; *d*, nuclei in the transition-vessels.

Fig. 63.

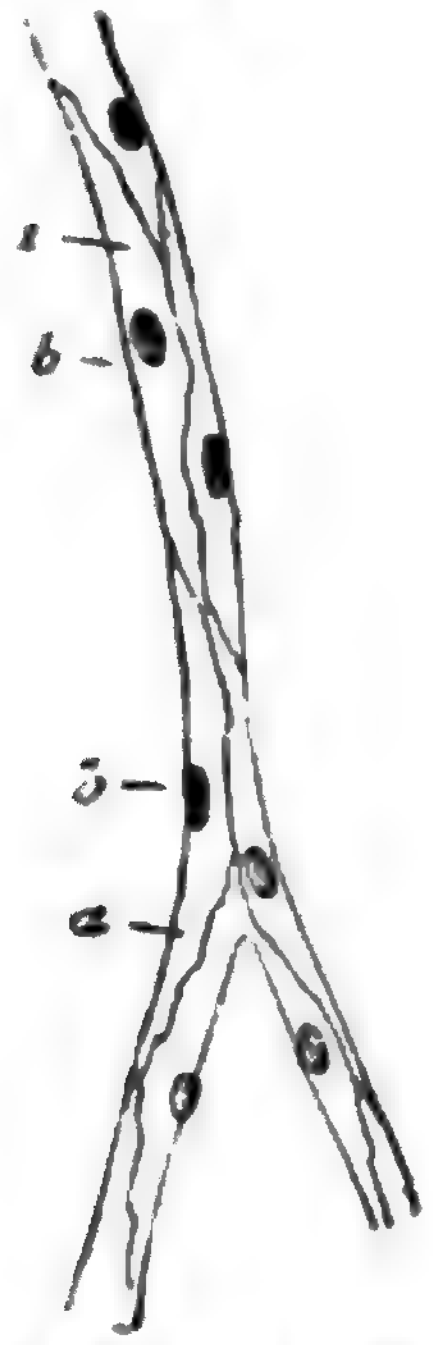

Capillaries from the Mesentery of a Guinea-pig, after treatment with solution of nitrate of silver: *a*, cells; *b*, their nuclei.

In many situations a delicate sheath or envelope of fine connective tissue is found around the simple capillary tube, particularly in the larger ones; and in other places, especially in the glands, the capillaries are invested with retiform lymphatic tissue.

In the largest capillaries (which ought, perhaps, to be described rather as the smallest arteries) traces of an epithelial lining and of circular transverse muscular fibres are to be seen (Fig. 64).

The **Veins**, like the arteries, are composed of three coats—internal, middle, and external; and these coats are, with the necessary modifications, analogous to the coats of the arteries, the internal being the epithelial, the middle the muscular, and the external the connective or areolar. The main difference between the veins and the arteries is in the comparative weakness of the middle coat of the former; and to this it is due that the veins do not stand open when divided, as the arteries do, and that they are passive rather than active organs of the circulation.

In the veins immediately above the capillaries the three coats are hardly to be distinguished. The endothelium is supported on an outer membrane separable into two layers, the outer of which is the thicker, and consists of a delicate, nucleated membrane (adventitia), while the inner is composed of a network of longitudinal elastic fibres (intima). In the veins next above these in size (one-fifth of a line, according to Kölliker) a muscular layer and a layer of circular fibres can be traced, forming the middle coat, while the elastic and connective elements of the outer coat become more distinctly perceptible. In the middle-sized veins the typical structure of these vessels becomes clear. The endothelium is of the same character as in the arteries, but its cells are more oval, less fusiform. It is supported by a connective-tissue layer consisting of a delicate network of branched cells, and external to this is a layer of longitudinal elastic fibres, but seldom any appearance of a fenestrated membrane. This constitutes the *internal* coat. The *middle* coat is composed of a thick layer of connective tissue with elastic fibres, intermixed, in some veins, with a transverse layer of muscular fibres. The white fibrous element is in considerable excess, and the elastic fibres are in much smaller proportion in the veins than in the arteries. The outer coat consists of areolar tissue, as in the arteries, with longitudinal elastic fibres. In the largest veins the outer coat is from two to five times thicker than the middle coat, and contains a large number of longitudinal muscular fibres. This is most distinct in the hepatic part of the inferior vena cava and at the termination of this vein in the heart, in the trunks of the hepatic veins, in all the large trunks of the vena portæ, in the splenic, superior mesenteric, external iliac, renal, and azygos veins. In the renal and portal veins it extends through the whole thickness of the outer coat, but in the other veins mentioned a layer of connective and elastic tissue is found external to the muscular fibres. All the large veins which open into the heart are covered for a short distance with a layer of striped muscular tissue continued on to them from the heart. Muscular tissue is wanting in the veins—(1) of the maternal part of the placenta; (2) in most of the cerebral veins and sinuses of the dura mater; (3) in the veins of the retina; (4) in the veins of the cancellous tissue of bones; (5) in the venous spaces of the corpora cavernosa. The veins of the above-mentioned parts consist of an internal endothelial lining supported on one or more layers of areolar tissue.

Most veins are provided with *valves*, which serve to prevent the reflux of the blood. They are formed by a reduplication of the inner coat, strengthened by connective tissue and elastic fibres, and are covered on both surfaces with endothelium. Their form is semilunar. They are attached by their convex edge to the wall of the vein; the concave margin is free, directed in the course of the venous current, and lies in close apposition with the wall of the vein as long as the current of blood takes its natural course: if, however, any regurgitation takes place, the valves become distended, their opposed edges are brought into contact, and the current is intercepted. Most commonly, two such valves are found placed opposite each other, more especially in the smaller veins or in the larger trunks at the point where they are joined by smaller branches; occasionally there are three, and sometimes only one. The wall of the vein immediately above the point of attachment of each segment of the valve is expanded into a pouch or sinus, which gives to the vessel, when injected or distended with blood, a knotted appearance. [This can readily be seen and the position of the valves located by applying a moderately tight bandage around one's arm, and then opening and closing the fist several times to increase the blood-flow.] The valves are very numerous in the veins of the extremities, especially of the lower extremities, these vessels having to conduct the blood against the force of gravity. They are absent in the very small veins, also in the venæ cavæ, the hepatic veins, portal vein and its branches, the renal, uterine, and ovarian veins. A few valves are found in the spermatic veins, and one also at their point of junction with the renal vein and inferior vena cava in both sexes. The cerebral and spinal veins, the veins of the cancellated tissue of bone, the pulmonary veins, and the umbilical vein and its branches are also destitute of valves. They are occasionally found, few in number, in the venæ azygos and intercostal veins.

The veins are supplied with nutrient vessels, *vasa vasorum*, like the arteries. Nerves also are distributed to them in the same manner as to the arteries, but in much less abundance.

The **Lymphatic** vessels—including in this term the **Lacteal** vessels, which are identical in structure with them—are composed of three coats. The *internal* is an endothelial and elastic coat. It is thin, transparent, slightly elastic, and ruptures sooner than the other coats. It is composed of a layer of elongated endothelial cells with serrated margins, by which the adjacent cells are dovetailed into one another. These are supported on a single layer of longitudinal elastic fibres. The *middle* coat is composed of smooth, muscular, and fine elastic fibres, disposed in a transverse direction. The *external*, or fibro-areolar coat, consists of filaments of areolar tissue intermixed with smooth muscular fibres, longitudinally or obliquely disposed. It forms a protective covering to the other coats, and serves to connect the vessel with the neighboring structures. The above description applies only to the larger lymphatics; in the smaller vessels there is no muscular or elastic coat, and their structure consists only of a connective-tissue coat, lined by endothelium. The *thoracic duct* (Fig. 65) is a somewhat more complex structure than the other lymphatics; it presents a distinct subendothelial layer of branched corpuscles similar to that found in the arteries, and in the middle coat is a layer of connective tissue with its fibres arranged longitudinally. The lymphatics are supplied by nutrient vessels, which are distributed to their outer and middle coats; but no nerves have at present been traced into them.

Fig. 66.

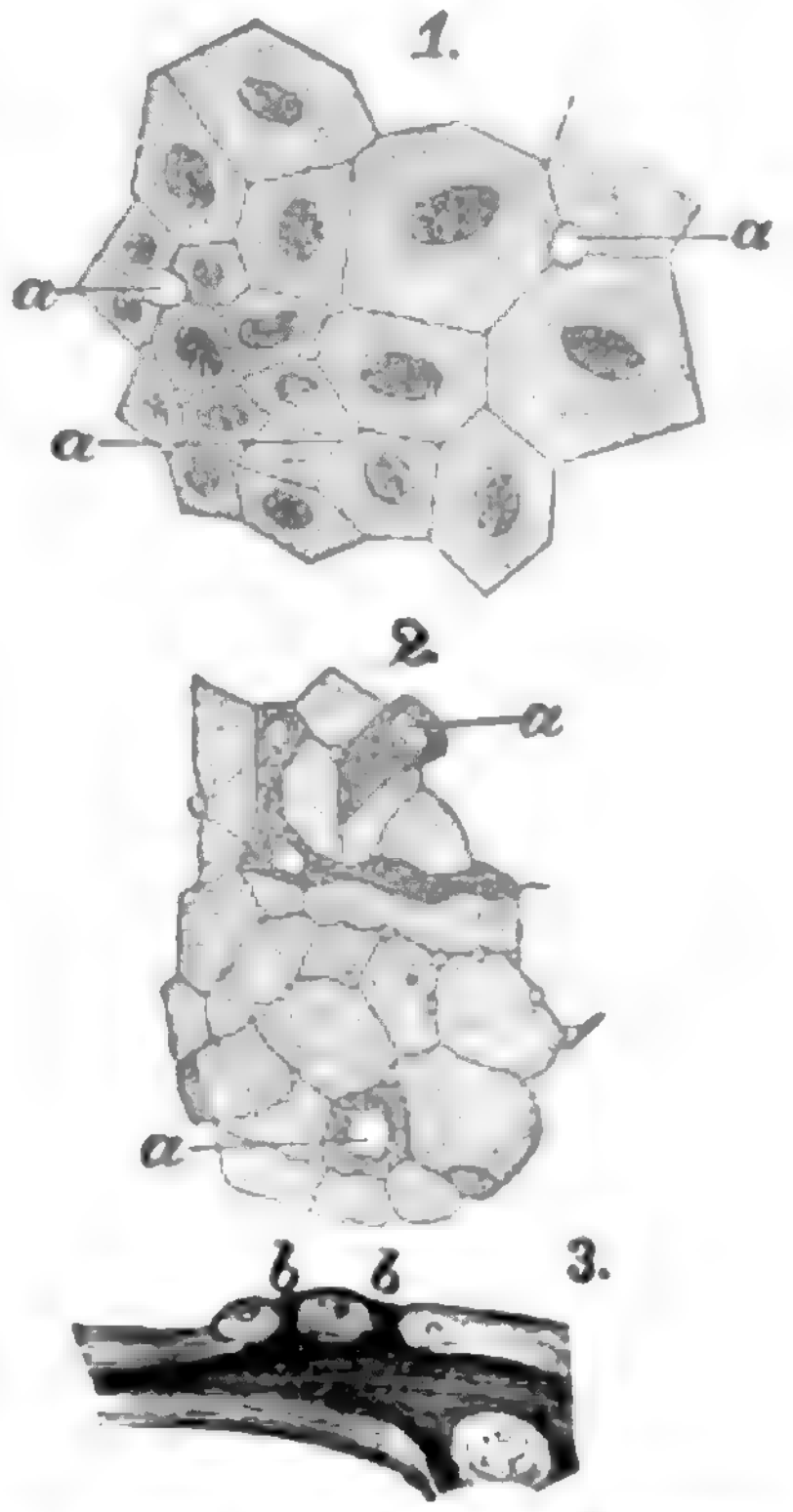

1. Endothelium from the under surface of the *centrum tendineum* of the rabbit: *a*, pores or stomata. 2. Endothelium of the mediastinum of the dog: *a*, pores. 3. Section through the pleura of the same animal: *b*, free orifices of short lateral passages of the lymph-canals (copied from Ludwig, Schweigger-Seydel, and Dybkowsky).

Fig. 65.



Transverse Section through the Coats of the Thoracic Ducts of Man (magnified 30 times): *a*, endothelium, striated lamellæ, and inner elastic coat; *b*, longitudinal connective tissue of the middle coat; *c*, transverse muscles of the same; *d*, tunica adventitia, with *e*, the longitudinal muscular fibres.

The lymphatics are very generally provided with *valves*, which assist materially in effecting the circulation of the fluid they contain. These valves are formed of a thin layer of fibrous tissue lined on both surfaces by endothelium. Their form is semilunar; they are attached by their convex edge to the sides of the vessel, the concave edge being free and directed along the course of the contained current. Usually two such valves, of equal size, are found opposite one another; but occasionally exceptions occur, especially at or near the anastomoses of lymphatic vessels. Thus, one valve may be of very rudimentary size, and the other increased in proportion.

The valves in the lymphatic vessels are placed at much shorter intervals than in the veins. They are most numerous near the lymphatic glands, and they are found more frequently in the lymphatics of the neck and upper extremity than in the lower. The wall of the lymphatics immediately above the point of attachment of each segment of a valve is expanded into a pouch or sinus, which gives to these vessels, when distended, the knotted or beaded appearance which they present. Valves are wanting in the vessels composing the plexiform network in which the lymphatics usually originate on the surface of the body.

[The lymphatic system is an appendix to the blood-vessels, the latter, especially by the capillaries, supplying the oxygen and food to all the tissues, the former carrying off most of the waste products, and also acting as absorbents. The lymphatic vessels arise in several ways. One is in *lymph-spaces* (Fig. 67) of the connective tissues. Another is in the *lacteals*, vessels in the intestinal villi (see their description), which begin by blind or closed extremities. During digestion these vessels are filled with the white chyle, but at other times by the colorless lymph. A third origin of the lymphatics is in *perivascular and perineural spaces*. These exist especially around the smaller blood-vessels of the nerve-centres, the bones, the retina, the liver, and under the sheath of the optic and some other nerves.

[Fig. 67.

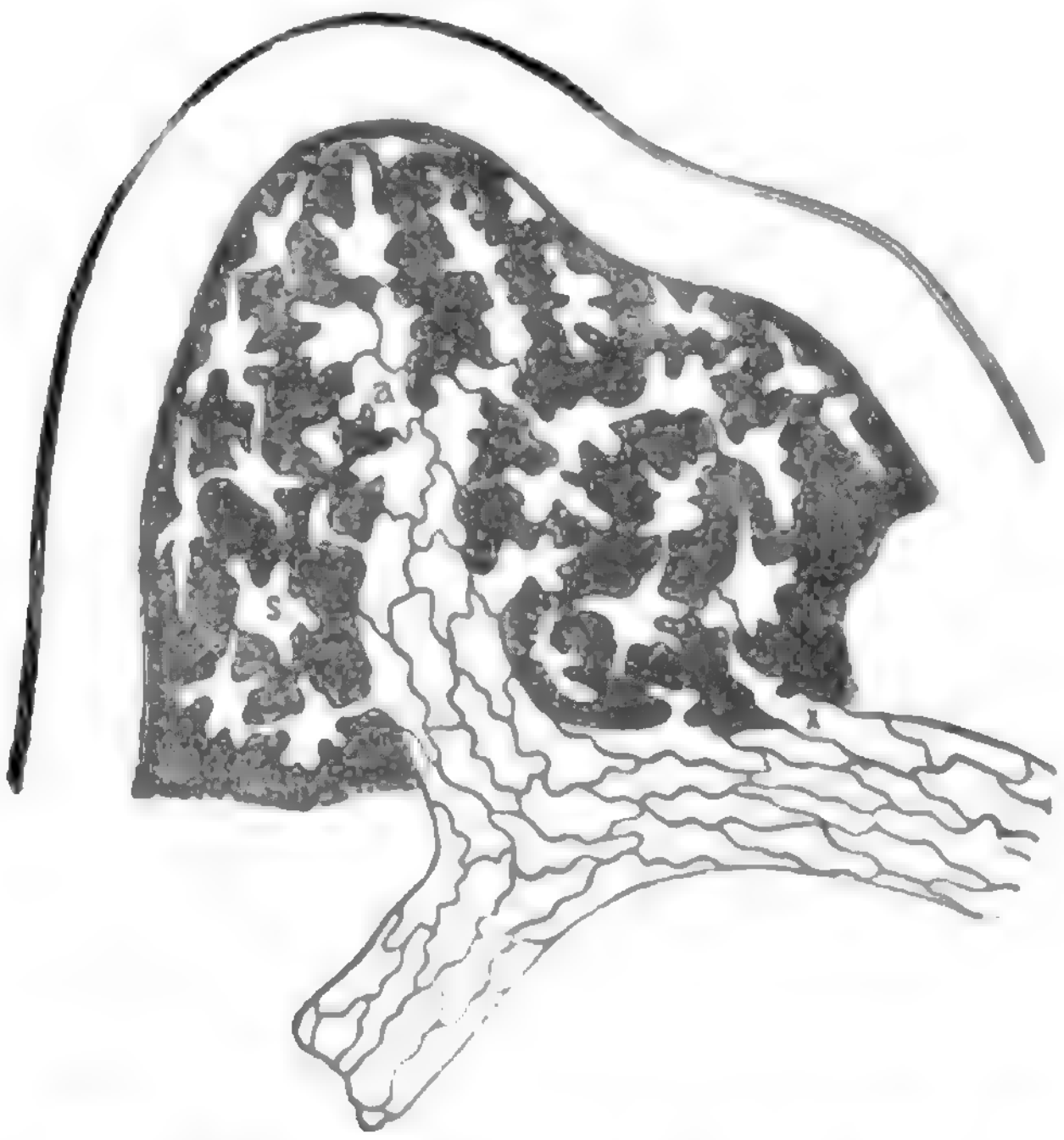

Origin of Lymphatics from the Central Tendon of the Diaphragm of the Rabbit (semi-diagrammatic): *s*, the juice-canals, communicating at *x* with the lymphatics; *a*, origin of the lymphatics by the confluence of several juice-canals (Landois' *Physiology*, edit. by Stirling).]

[Fig. 68.

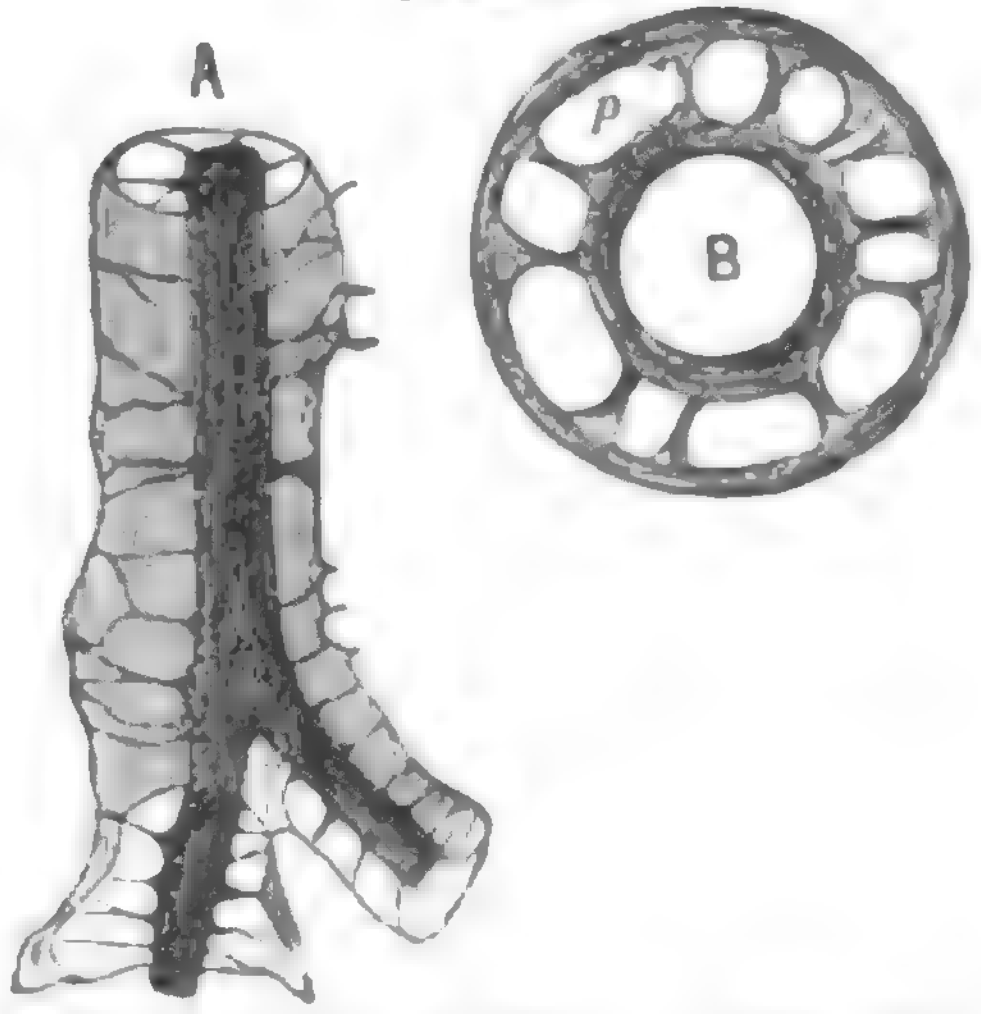

Perivascular Lymphatics: A, aorta of tortoise. B, artery from the brain; *p*, perivascular lymph-space (Landois' *Physiology*, edit. by Stirling).]

In Fig. 68 the perivascular spaces are shown around the aorta of the tortoise (A), which is visible to the naked eye, and (B) around a small cerebral artery. A fourth origin is by *stomata*, or openings between the endothelial cells lining the walls of the large serous cavities (Fig. 12, p. 44). These serous cavities, the arachnoid, aqueous chambers of the eye, the capsule of Tenon or tunica vaginalis oculi, the labyrinth of the ear, the pleura, the pericardium, the peritoneum, and tunica vaginalis testis, are all, therefore, lymph-sacs. Hence their great absorbing power, which it is especially important to recognize in laparotomy and other operations involving them.]

The finest visible lymphatic vessels form a plexiform network in the subcutaneous and submucous tissues, and this is properly regarded as one method of their commencement. But the lymphatics have also other modes of origin, for the intestinal lacteals commence by closed extremities, though some observers believe that the closed extremity is continuous with a minute network contained in the substance of the villus, through which the lacteal is connected with the epithelial cells covering it. Again, it seems now to be conclusively proved that the serous membranes present stomata or openings between the endothelial cells (Figs. 12 and 66), by which there is an open communication with the lymphatic system, and through which the lymph is thought to be pumped by the ultimate dilatation and contraction of the serous surface due to the movements of respiration and circulation.[1] Von Recklinghausen was the first to observe the passage of milk and other colored fluids through these stomata on the peritoneal surface of the central tendon of the diaphragm. Again, in most glandular structures the lymphatic capillaries have a lacunar origin. Here they begin in irregular clefts or spaces in the tissue of the part; and closely corresponding to or identical with this is their origin in connective tissue, where the lymphatic vessels are apparently continuous with spaces in the connective tissue; and Klein has described and figured a direct communication between these spaces and the lymphatic vessel.[1]

---

[1] The resemblance between lymph and serum led Hewson long ago to regard the serous cavities as sacs into which the lymphatics open. Recent microscopic discoveries confirm this opinion in a very interesting manner.

Lymphatic Glands (Fig. 69) are small oval or bean-shaped bodies situated in the course of lymphatic and lacteal vessels, so that the lymph and chyle pass through them on their way to the blood. They generally present on one side a slight depression—the *hilum*—through which the blood-vessels enter and leave the interior. The efferent lymphatic vessel also emerges from the gland at this spot, while the afferent vessels enter the organ at different parts of the periphery. On section, a lymphatic gland displays two different structures: an external, of lighter color—the *cortical;* and an internal, darker—the *medullary.* The cortical structure does not form a complete investment, but is deficient at the hilum, where the medullary portion reaches the surface of the gland; so that the efferent vessel is derived directly from the medullary structure, while the afferent vessels empty themselves into the cortical substance.

FIG. 69.

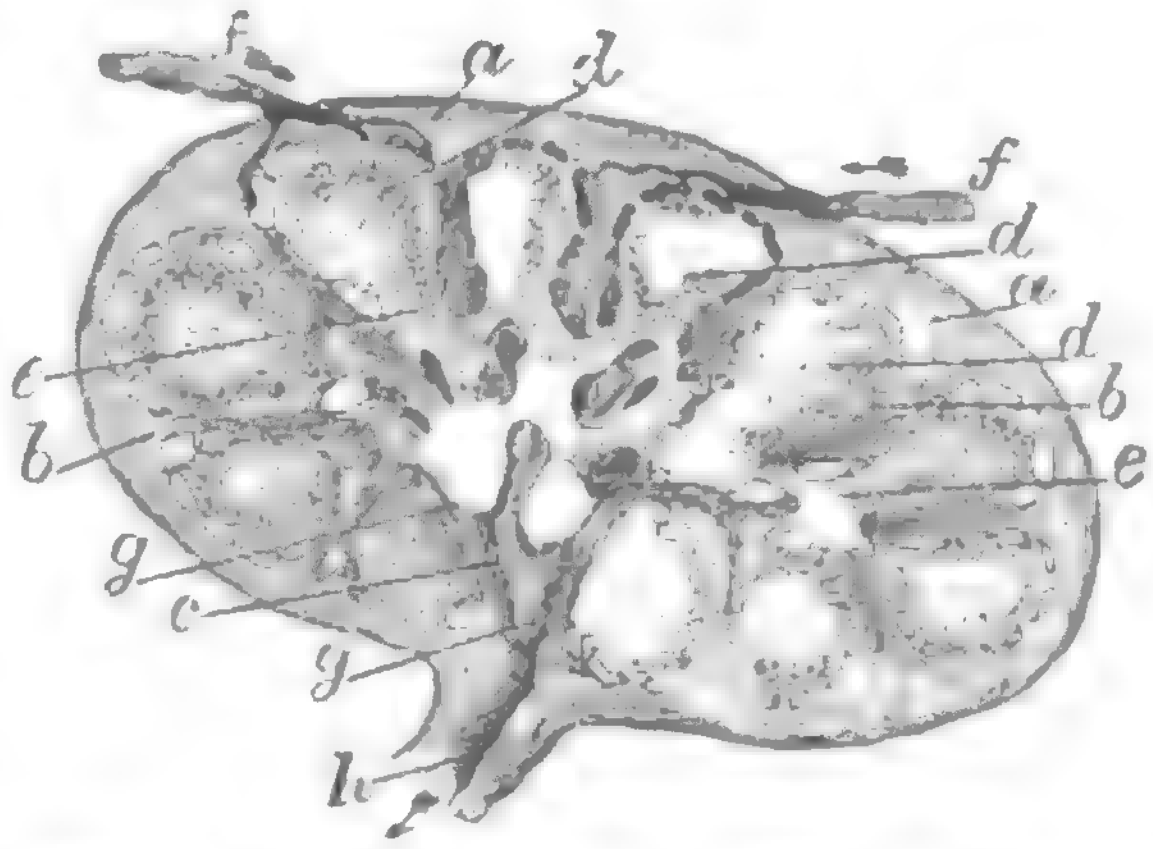

Section of Small Lymphatic Gland, half-diagrammatically given, with the course of the lymph: *a*, the envelope; *b*, septa between the follicles or alveoli of the cortical part; *c*, system of septa of the medullary portion, down to the hilum; *d*, the follicles; *e*, lymph-tubes of the medullary mass; *f*, different lymphatic streams which surround the follicles and flow through the interstices of the medullary portion; *g*, confluence of these passing through the efferent vessel, *h*, at the hilum.

Lymphatic glands consist of (1) a fibrous envelope, or *capsule*, from which a framework of processes (*trabeculæ*) proceed inward, dividing the gland into open spaces (*alveoli*) freely communicating with each other; (2) a quantity of adenoid tissue occupying these spaces without completely filling them; (3) a free supply of blood-vessels, which are supported on the trabeculæ; and (4) the *afferent* and *efferent* vessels. Little is known of the nerves, though Kölliker describes some fine nervous filaments passing into the hilum.

The *capsule* is composed of a layer of connective tissue, and from its internal surface are given off a number of membranous septa or lamellæ which pass inward, radiating toward the centre of the gland, for a certain distance; that is to say, for about one-third or one-fourth of the space between the circumference and the centre of the gland. They thus divide the outer part of its interior into a number of oval compartments or *alveoli* (Fig. 69). This is the cortical portion of the gland. After having penetrated into the gland for some distance, these septa break up into a number of smaller trabeculæ, which form flattened bands or cords interlacing with each other in all directions, forming in the central part of the organ a number of intercommunicating spaces, also called *alveoli.* This is the medullary portion of the gland, and the spaces or alveoli in it not only freely communicate with each other, but also with the alveoli of the cortical portion. In these alveoli or spaces (Fig. 70) is contained the proper gland-substance or lymphoid tissue. The gland-pulp does not, however, completely fill the alveolar spaces, but leaves, between its outer margin and the trabeculæ forming the alveoli, a channel or space of uniform width throughout. This is termed the *lymph-path* or *lymph-sinus* (Figs. 71 and 72). Running across it are a number of trabeculæ of retiform connective tissue, which appear to serve the purpose of maintaining the gland-pulp in the centre of the space in its proper position.

On account of the peculiar arrangement of the framework of the organ the gland-pulp in the cortical portion is disposed in the form of nodules, and in the medullary part in the form of rounded cords. It consists of ordinary lymphoid tissue, being made up of a delicate reticulum of retiform tissue, which is continuous with that in the lymph-paths, but marked off from it by a closer reticulation; in its meshes are closely-packed lymph-corpuscles, traversed by a dense plexus of capillary blood-vessels.

---

[1] *Atlas of Histology,* pl. viii. fig. xiv.

FIG. 70.

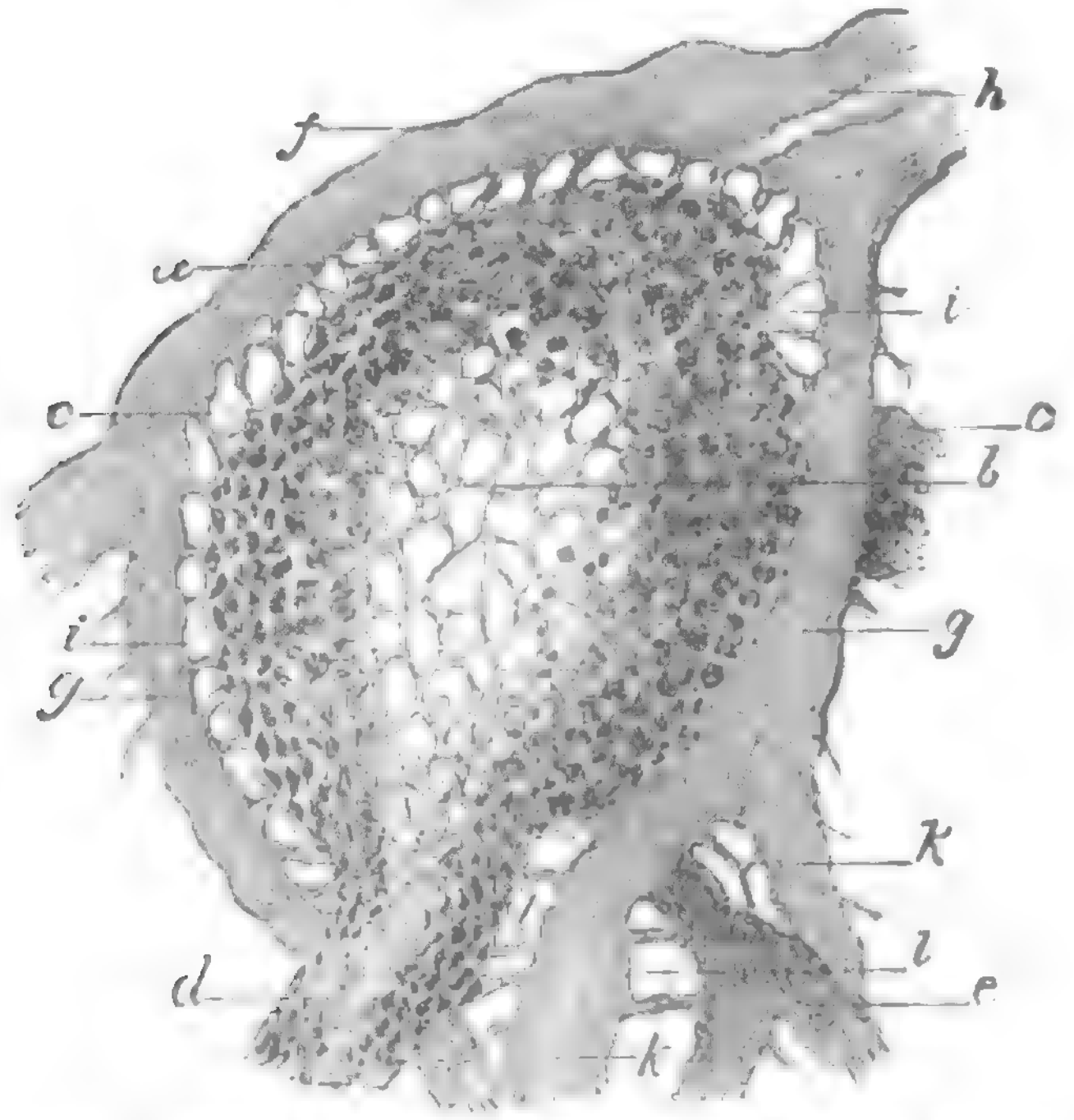

Follicle from a Lymphatic Gland of the Dog, in vertical section: *a*, reticular sustentacular substance of the more external portion; *b*, of the more internal, and *c*, of the most external and most finely webbed part on the surface of the follicle; *d*, origin of a large lymph-tube; *e*, of a smaller one; *f*, capsule; *g*, septa; *h*, vas afferens; *i*, investing space of the follicle, with its retinacula; *k*, one of the divisions of the septa; *l*, *l*, attachment of the lymph-tubes to the septa.

FIG. 71.

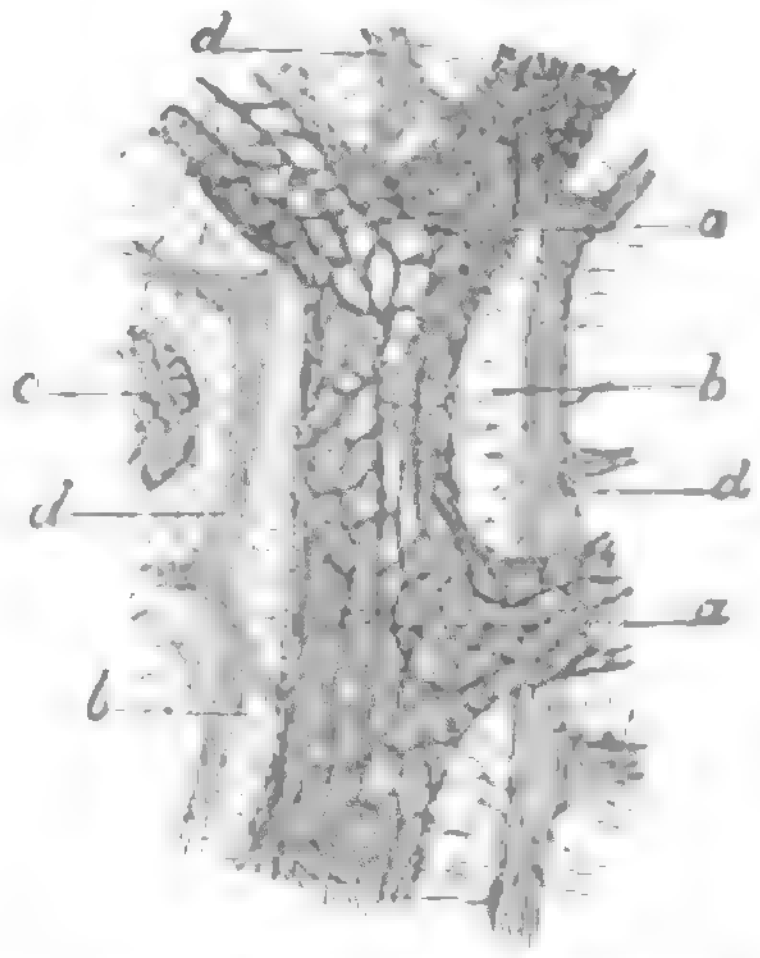

From the Medullary Substance of an Inguinal Gland of the Ox (after His): *a*, lymph-tube, with its complicated system of vessels; *b*, retinacula stretched between the tube and the septa; *c*, portion of another lymph-tube; *d*, septa.

The *afferent vessels*, as above stated, enter at all parts of the periphery of the gland, and, after branching and forming a dense plexus in the substance of the capsule, open into the lymph-sinuses of the cortical part. In doing this they lose all their coats except their endothelial lining, which is continuous with a layer of similar cells lining the lymph-paths. In like manner the efferent vessel commences from the lymph-sinuses of the medullary portion. The stream of lymph carried to the gland by the afferent vessel would thus pass through the plexus in the capsule to the lymph-paths of the cortical portion, where it would be exposed to the action of the gland-pulp; flowing through these, it would enter the paths or sinuses of the medullary portion, and finally emerge from the hilum by means of the efferent vessel. [This passage of the lymph-stream through the glands explains readily the glandular enlargement that follows chancre, vaccination, malignant tumors, etc.] The arteries of the gland enter at the hilum, and either pass at once to the gland-pulp to break

FIG. 72.

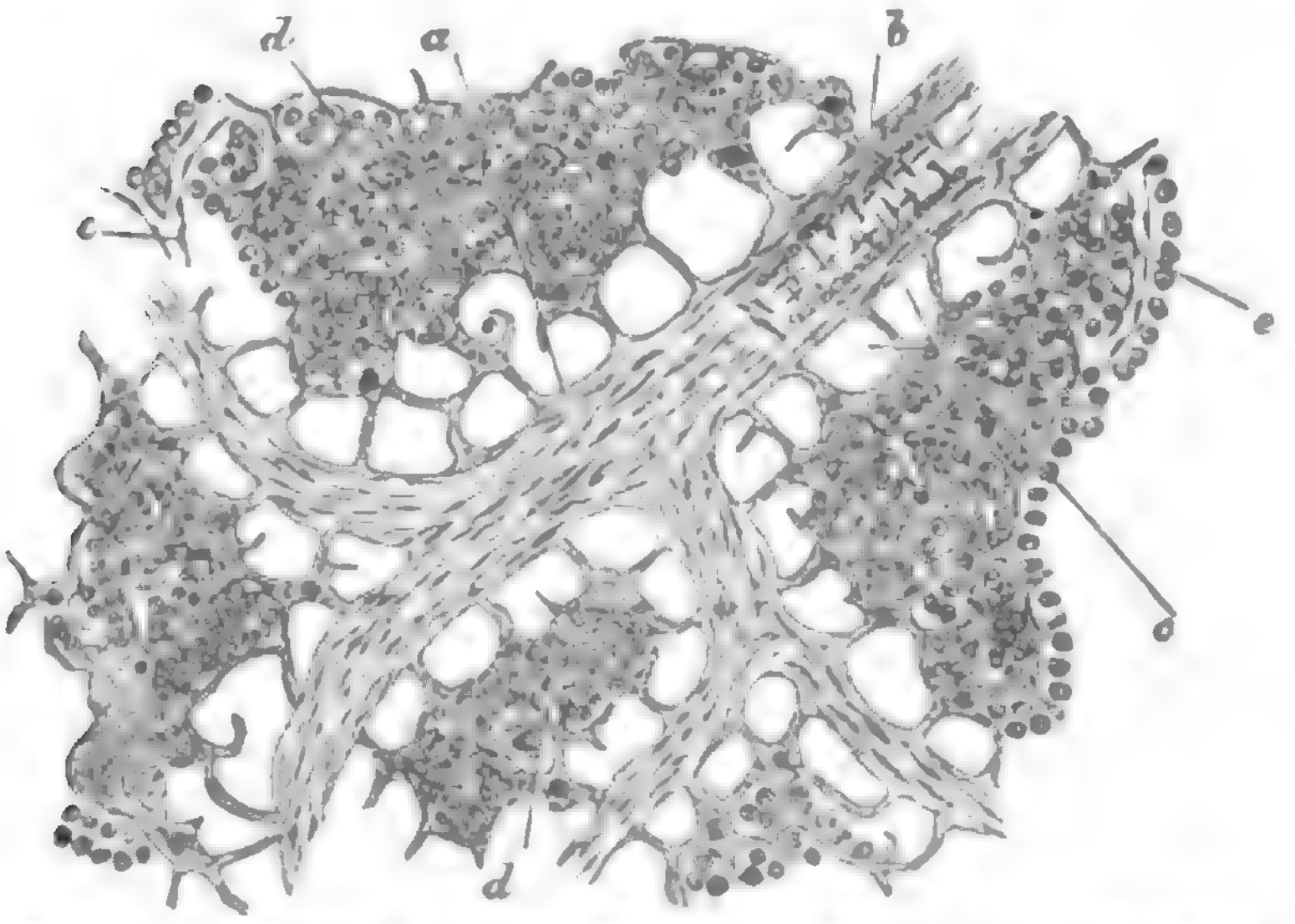

Section of Lymphatic Gland-tissue: *a*, trabeculæ; *b*, small artery in substance of same; *c*, lymph-paths; *d*, lymph-corpuscles; *e*, capillary plexus.

up into a capillary plexus, or else run along the trabeculæ, partly to supply them, and partly running across the lymph-paths to assist in forming the capillary plexus of the gland-pulp. From this plexus the veins commence, and emerge from the organ at the same place as that at which the artery enters.

THE SKIN AND ITS APPENDAGES.

FIG. 73.

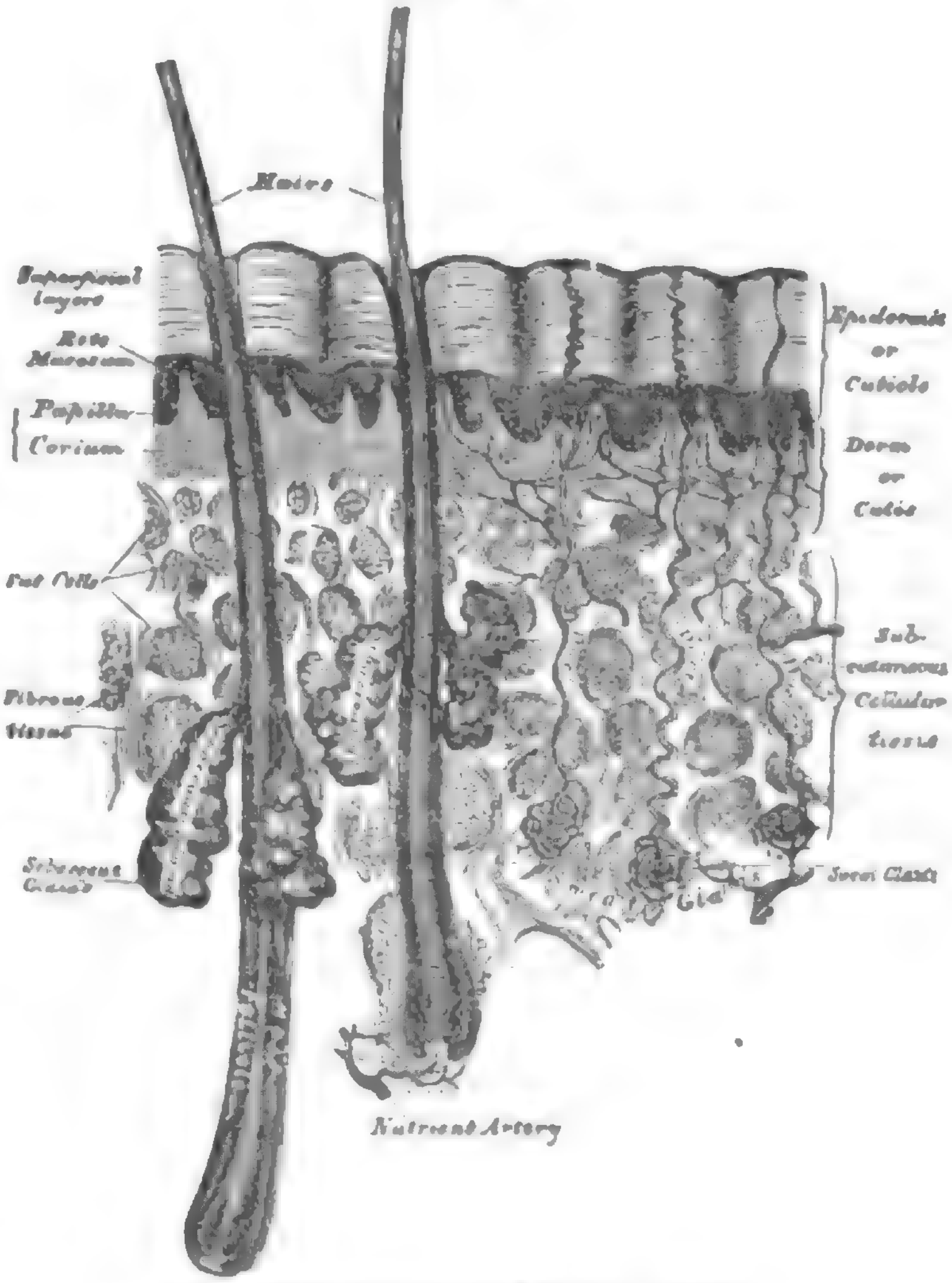

A Sectional View of the Skin (magnified).

The **Skin** (Fig. 73) is the principal seat of the sense of touch, and may be regarded as a covering for the protection of the deeper tissues; it is also an important excretory and absorbing organ. It consists principally of a layer of vascular tissue, named the *derma* or *cutis vera*, and an external covering of epithelium, termed the *epidermis* or *cuticle*. On the surface of the former layer are the sensitive *papillæ;* and within or imbedded beneath it are certain organs with special functions—namely, the *sweat-glands, hair-follicles*, and *sebaceous glands*.

The **Epidermis** or **Cuticle** (*scarf-skin*, Fig. 74) is an epithelial structure belonging to the class of stratified epithelia. It is accurately moulded on the papillary layer of the derma. It forms a defensive covering to the surface of the true skin and limits the evaporation of watery vapor from its free surface. It varies in thickness in different parts. In some situations, as in the palms of the hands and soles of the feet, it is thick, hard, and horny in texture. This may be partly due to the fact that these parts are exposed to intermittent pressure; but that this is not the sole cause is proved by the fact that the condition exists to a very considerable extent at birth. The more superficial layer of cells, called the *horny* layer (*stratum corneum*), may be separated by maceration from the deeper layers, which are called the *rete mucosum*, and which consist of several layers of differently-shaped cells. The free surface of the epidermis is marked by a network of linear furrows of variable size, marking out the surface into a number of spaces of polygonal or lozenge-shaped form. Some of these furrows are large, as opposite the flexures of the joints, and correspond to the folds in the derma produced by their movements. In other situations, as upon the back of the hand, they are exceedingly fine, and intersect one another at various angles; upon the palmar surface of the hand and fingers and upon the sole of the foot these lines are very distinct and are disposed in curves. They depend upon the large size and peculiar arrangement of the papillæ upon which the epidermis is placed. The deep surface of the epidermis is accurately moulded upon the papillary layer of the derma, each papilla being invested by its epidermic sheath; so that when this layer is removed by maceration it presents on its under surface a number of pits or depressions corresponding to the elevations in the papillæ, as well as the ridges left in the intervals between them. Fine tubular prolongations are continued from this layer into the ducts of the sudoriferous and sebaceous glands.

In *structure* the epidermis consists of several layers of epithelial cells agglutinated together and having a laminated arrangement. These several layers may be described as composed of four different strata: (1) The rete *Malpighii*, composed of several layers of epithelial cells, which are elongated in figure and placed perpendicularly on the surface of the corium. Of these the deepest layer is composed of columnar cells arranged perpendicularly, while the succeeding laminæ consist of cells of a more rounded or polyhedral form, the contents of which are soft, opaque, granular, and soluble in acetic acid. They are often marked on their surfaces with ridges and furrows, and are covered with numerous spines. (2) Immediately superficial to these is a single layer of flattened, spindle-shaped cells, the *granular layer*, which contain granules that become deeply stained in hæmatoxylin. They are supposed to be cells in a transitional stage between the protoplasmic cells of the rete Malpighii and the horny cells of the superficial layers. (3) Above this layer the cells become indistinct, and appear, in sections, to form a homogeneous or dimly-striated membrane composed of closely-packed scales, and hence called the *stratum lucidum*. (4) As these cells successively approach the surface by the development of fresh layers from beneath, they assume a flattened form from the evaporation of their fluid contents, and consist of many layers of horny epithelial scales, forming the *stratum corneum*. These cells apparently become changed in their chemical composition, as they are now unaffected by acetic acid. The deepest layer of the rete Malpighii is separated from the papillæ by an apparently homogeneous basement-membrane, which is most distinctly brought into view in specimens prepared with chloride of gold. This, according to Klein, is merely the deepest portion of the epithelium, and is "made up of the basis of the individual cells, which have undergone a chemical and morphological alteration." The black color of the skin in the negro, and the tawny color among some of the white races, are due to the presence of pigment in the cells of the cuticle. This pigment is more especially distinct in the cells of the deeper layer, or rete mucosum, and is similar to that found in the cells of the pigmentary layer of the retina. As the cells approach the surface and desiccate the color becomes partially lost.

FIG. 74.

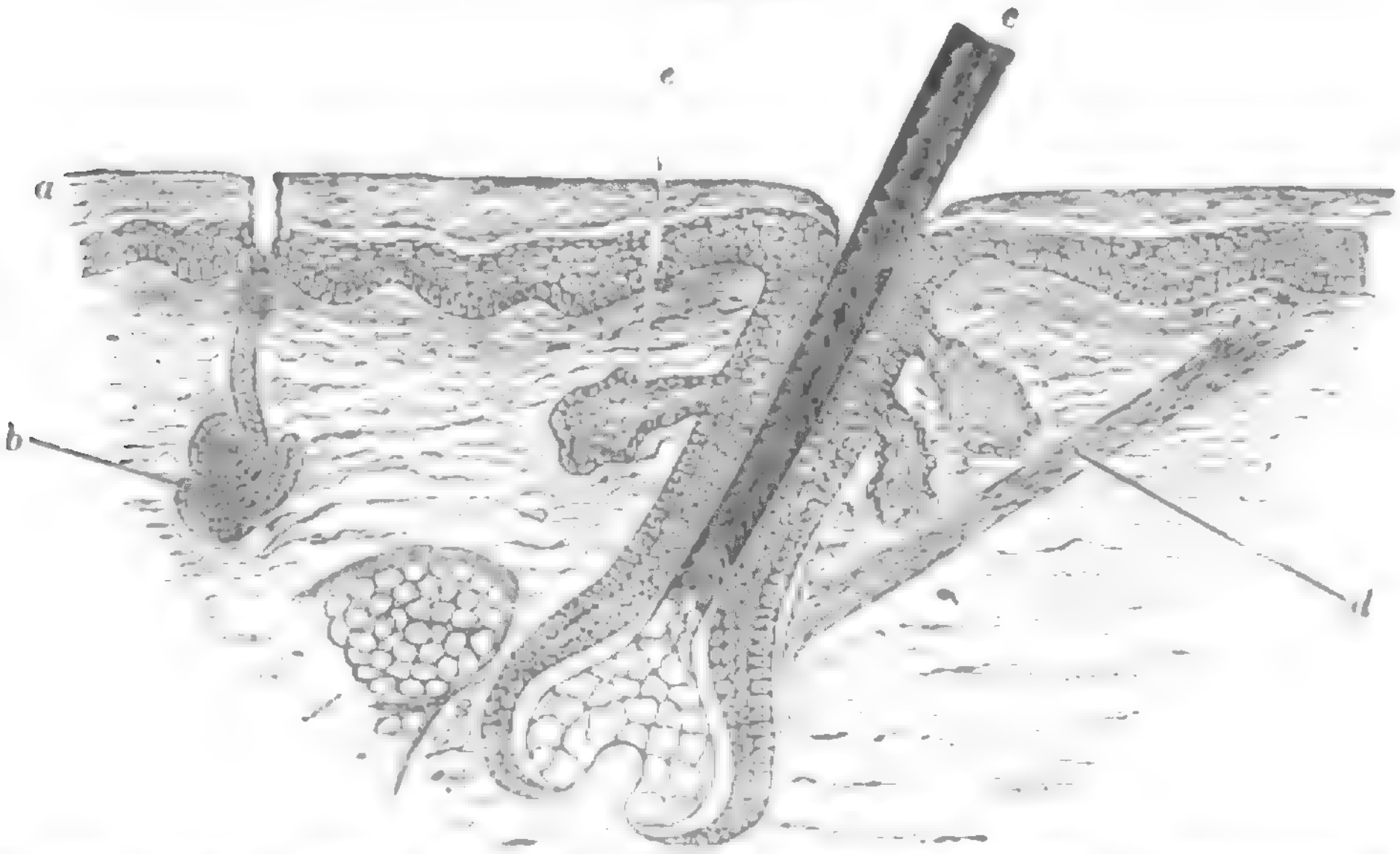

Microscopic Section of Skin, showing the epidermis (*a*) and derma (*b*); a hair (*c*) in its follicle; the erector pili muscle (*d*); sebaceous (*e*) and sudoriferous (*f*) glands.

The **Derma, Corium,** or **Cutis vera** is tough, flexible, and highly elastic, in order to defend the parts beneath from violence. It consists of fibrous connective tissue, with a large admixture of elastic fibres and numerous blood-vessels, lymphatics, and nerves. The corium varies in thickness from a quarter of a line to a line and a half in different parts of the body. Thus, it is very thick in the palms of the hands and soles of the feet; thicker on the posterior aspect of the body than the front, and on the outer than the inner side of the limbs. In the eyelids, scrotum, and penis it is exceedingly thin and delicate. The skin generally is thicker in the male than in the female, and in the adult than in the child. Unstriped muscular fibres are found in the superficial layers of the corium wherever hairs are found, and in the subcutaneous areolar tissue of the scrotum, penis, perineum, and areolæ of the nipples. In the latter situation the fibres are arranged in bands closely reticulated and disposed in superimposed laminæ. The fibro-areolar tissue forms the framework of the cutis, and is differently arranged in different parts, so that it is usual to describe it as consisting of two layers: the deeper or *reticular* layer, and the superficial or *papillary* layer.

The *reticular* layer consists of strong interlacing fibrous bands, composed chiefly of the white variety of fibrous tissue, but containing also some fibres of the yellow elastic tissue, which vary in amount in different parts, and connective-tissue corpuscles, which are often to be found flattened against the white fibrous-tissue bundles. Toward the attached surface the fasciculi are large and coarse, and the areolæ which are left by their interlacement are large and occupied by adipose tissue and sweat-glands. Below this the elements of the skin become gradually blended with the subcutaneous areolar tissue, which, except in a few situations, contains fat. Toward the free surface the fasciculi are much finer, and their mode of interlacing close and intricate.

[Fig. 75.



Epidermis detached from Derma by Maceration, and then turned upward (× 20). It shows on the under surface of the epidermis, in double lines, the hollows which receive the papillæ. The papillæ show on the surface of the derma. The concentric lines on the last phalanges of the fingers are caused by them. The ducts of the sweat-glands, some of which are broken, are well shown (Hirschfeldt).]

The *papillary layer* is situated upon the free surface of the reticular layer; it consists of numerous small, highly sensitive, and vascular eminences, the *papillæ* (Fig. 75), which rise perpendicularly from its surface and form the essential element of the organ of touch. The papillæ are conical-shaped eminences, having a round or blunted extremity, occasionally divided into two or more parts, and connected by a thin base with the free surface of the corium. Their average length is about $\frac{1}{100}$ of an inch, and they measure at their base $\frac{1}{250}$ of an inch in diameter. On the surface of the body, more especially in those parts which are endowed with slight sensibility, they are few in number, short, exceedingly minute, and irregularly scattered over the surface; but in other situations, as upon the palmar surface of the hands and fingers, upon the plantar surface of the feet and toes, and around the nipple, they are long, of large size, closely aggregated together, and arranged in parallel curved lines, forming the elevated ridges seen on the free surface of the epidermis. In these ridges the larger papillæ are arranged in a double row, with smaller papillæ between them; and these rows are subdivided into small square-shaped spaces by short transverse furrows, regularly disposed; in the centre of each of these spaces is the minute orifice of the duct of a sweat-gland. No papillæ exist in the grooves between the ridges. In structure the papillæ resemble the superficial layer of the cutis, consisting of very small and closely interlacing bundles of finely fibrillated tissue, with a few elastic fibres.

The *arteries* supplying the skin form a network in the subcutaneous tissue, from which branches are given off to supply the sweat-glands, the brain-follicles, and the fat. Other branches are given off which form a plexus immediately beneath the corium; from this fine capillary vessels pass into the papillæ, forming, in the smaller papillæ, a single capillary loop, but in the larger a more or less convoluted vessel.

The *nerves* of the skin terminate partly in the epidermis and partly in the cutis vera. The former form a dense plexus in the superficial layer of the corium, which extends horizontally and gives off numerous branches; these are prolonged into the epidermis and terminate between the cells, either in bulbous extremities or in a network. The latter terminate in end-bulbs, touch-corpuscles, or Pacinian bodies in the manner already described [p. 42]. There are numerous *lymphatics* supplied to the skin, which form two networks superficial and deep, communicating with each other and with those of the subcutaneous tissue by oblique branches.

The **Appendages of the Skin** are the nails, the hairs, the sudoriferous and sebaceous glands, and their ducts.

The nails and hairs are peculiar modifications of the epidermis, consisting essentially of the same cellular structure as that membrane.

The **Nails** are flattened, elastic structures of a horny texture placed upon the dorsal surface of the terminal phalanges of the fingers and toes. Each nail is convex on its outer surface, concave within, and is implanted by a portion, called the *root*, into a groove in the skin; the exposed portion is called the *body*, and the anterior extremity the *free edge*. The nail has a very firm adhesion to the cutis, being accurately moulded upon its surface, as the epidermis is in other parts. The part of the cutis beneath the body and root of the nail is called the *matrix*, because it is the part from which the nail is produced. Corresponding to the body of the nail, the matrix is thick, and covered with large, highly vascular papillæ arranged in longitudinal rows, the color of which is seen through the transparent tissue. Behind this, near the root of the nail, the papillæ are small, less vascular, and have no regular arrangement; and here the tissue of the nail is somewhat more opaque; hence this portion is of a whiter color, and is called the *lunula* on account of its shape.

The cuticle, as it passes forward on the dorsal surface of the finger or toe, is attached to the surface of the nail a little in advance of its root; at the extremity of the finger it is connected with the under surface of the nail a little behind its free edge. The cuticle and horny substance of the nail (both epidermic structures) are thus directly continuous with each other. The nails, in structure, consist of cells having a laminated arrangement, and these are essentially similar to those composing the epidermis. The deepest layer of cells, which lie in contact with the papillæ of the matrix, are of elongated form, arranged perpendicularly to the surface, and provided with nuclei; those which succeed them are of a rounded or polygonal form, the more superficial ones becoming broad, thin, and flattened, and so closely compacted as to make the limits of each cell very indistinct. It is by the successive growth of new cells at the root and under surface of the body of the nail that it advances forward and maintains a due thickness, whilst at the same time the growth of the nail in the proper direction is secured. As these cells in their turn become displaced by the growth of new cells, they assume a flattened form, lose their nuclei, and finally become closely compacted together into a firm, dense, horny texture. In *chemical composition* the nails resemble epidermis. According to Mulder, they contain a somewhat larger proportion of carbon and sulphur.

The **Hairs** are peculiar modifications of the epidermis, and consist essentially of the same structure as that membrane. They are found on nearly every part of the surface of the body, excepting the palms of the hands, soles of the feet, and the penis. They vary much in length, thickness, and color in different parts of the body and in different races of mankind. In some parts, as in the skin of the eyelids, they are so short as not to project beyond the follicles containing them; in other parts, as upon the scalp, they are of considerable length; again, in other parts, as the eyelashes, the hairs of the pubic region, and the male whiskers and beard, they are remarkable for their thickness. The hairs generally present a cylindrical or more or less flattened form, and a reniform outline upon transverse section.

A hair consists of a *root*, the part implanted in the skin; the *shaft* or *stem*, the portion projecting from its surface; and the *point*.

The *root of the hair* presents at its extremity a bulbous enlargement, which is whiter in color and softer in texture than the shaft, and is lodged in a follicular involution of the epidermis called the *hair-follicle.* When the hair is of considerable length the follicle extends into the subcutaneous cellular tissue. The hair-follicle commences on the surface of the skin with a funnel-shaped opening, and passes inward in an oblique direction, to become dilated at its deep extremity to correspond with the bulbous condition of the hair which it contains. It has opening into it, near its free extremity, the orifices of the ducts of one or more sebaceous glands (Fig. 74). At the bottom of each hair-follicle is a small conical vascular eminence or papilla similar in every respect to those found upon the surface of the skin; it is continuous with the dermic layer of the follicle, is highly vascular, and probably supplied with nervous fibrils: this is the part through which material is supplied for the production and constant growth of the hair. In structure the hair-follicle consists of two coats—an outer or *dermic,* and an inner or *cuticular.*

FIG. 76.

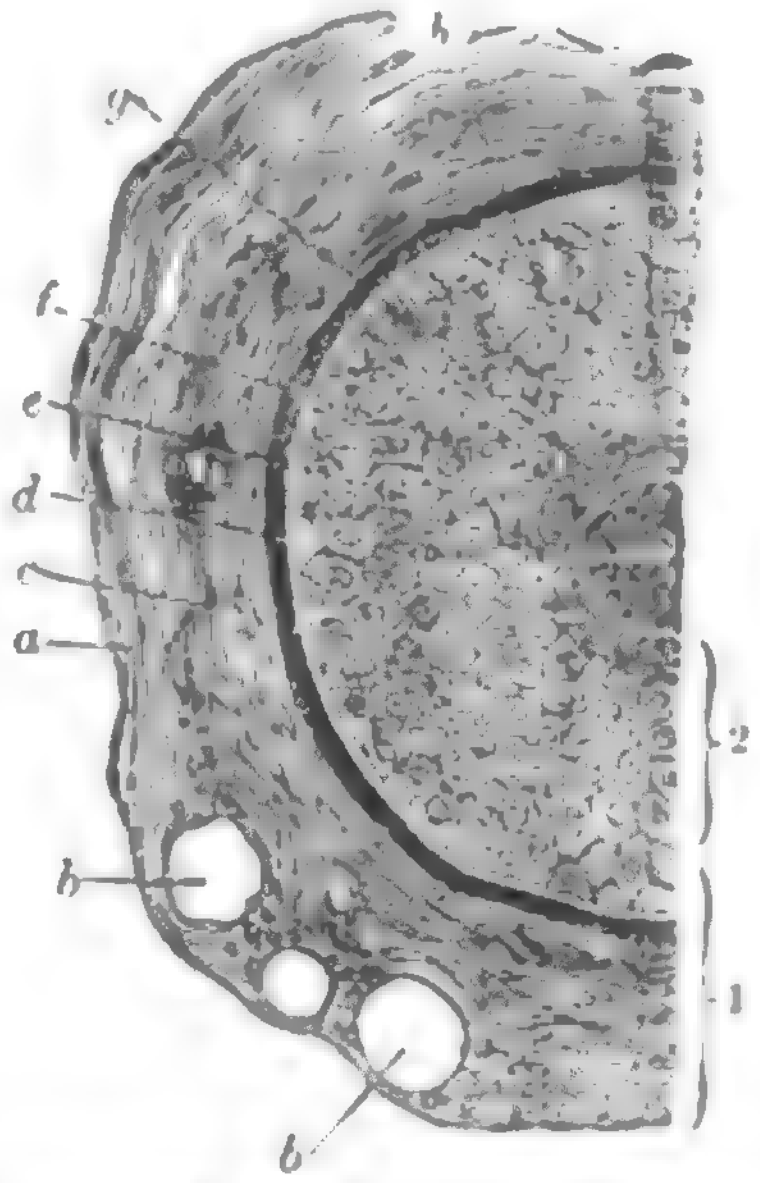

Transverse Section of Hair-follicle: 1. Dermic coat of follicle. 2. Epidermic coat or root-sheath: *a,* outer layer of dermic coat, with blood-vessels; *b, b,* cut across; *c,* middle layer; *d,* inner or hyaline layer; *e,* outer root-sheath, *f, g,* inner-root-sheath; *h,* cuticle of root-sheath; *i,* hair (from *Quain's Anatomy,* Biesiadecki).

The *outer* or *dermic* coat is formed mainly of fibrous tissue; it is continuous with the corium, is highly vascular, and supplied by numerous minute nervous filaments. It consists of three layers (Fig. 76). The most internal, next the cuticular lining of the follicle, consists of a hyaline basement-membrane having a glassy, transparent appearance, which is well marked in the larger hair-follicles, but is not very distinct in the follicles of minute hairs. It is continuous with the basement-membrane of the surface of the corium. External to this is a layer of spindle-shaped cells arranged in a circular manner around the follicle, but reaching only as high as the entrance of the ducts of the sebaceous glands. This is usually regarded as a muscular layer, the cells resembling unstriped-muscle cells. Externally is a thick layer of connective tissue, arranged in longitudinal bundles, in which are contained the blood-vessels and nerves.

The *inner* or *cuticular* layer is continuous with the epidermis, and at the bottom of the hair-follicle with the root of the hair; this cuticular lining resembles the epidermis in the peculiar rounded form and soft character of those cells which lie in contact with the outer coat of the hair-follicle, and the thin, dry, and scaly character of those which lie near the surface of the hair, to which they are closely adherent. When the hair is plucked from its follicle the cuticular lining most commonly adheres to it and forms what is called the *root-sheath.*

The hair-follicle contains the root of the hair, which terminates in a bulbous extremity, and is excavated so as to exactly fit the papilla from which it grows. The bulb is composed of polyhedral epithelial cells, which, as they pass upward into the root of the hair, become elongated and spindle-shaped, except some in the centre, which remain polyhedral. Some of these latter cells contain pigment-granules, which give rise to the color of the hair. It occasionally happens that these pigment-granules completely fill the cells in the centre of the bulb, which gives rise to the dark tract of pigment often found, of greater or less length, in the axis of the hair.

The shaft of the hair consists of a central pith or medulla, the fibrous part of the hair, and the cortex externally. The medulla occupies the centre of the shaft and ceases toward the point of the hair. It is usually wanting in the fine hairs covering the surface of the body, and commonly in those of the head. It is more opaque and deeper-colored than the fibrous part, and consists of cells containing pigment- or fat-granules. The fibrous portion of the hair constitutes the chief part of the shaft; its cells are elongated and unite to form flattened fusiform fibres. Between the fibres are found minute spaces which contain either pigment-granules in dark hair or minute air-bubbles in white hair. In addition to this there is also a diffused pigment contained in the fibres. The cells which form the cortex of the hair consist of a single layer which surrounds those of the fibrous part; they are converted into thin, flat scales having an imbricated arrangement.

Connected with the hair-follicles are minute bundles of involuntary muscular fibres termed the *erectores pili*. They arise from the superficial layer of the corium, and are inserted into the outer surface of the hair-follicle below the entrance of the duct of the sebaceous gland. They are placed on the side toward which the hair slopes, and by their action elevate the hair (Fig. 74).

The **Sebaceous Glands** are small, sacculated, glandular organs lodged in the substance of the corium. They are found in most parts of the skin, but are most abundant in the scalp and face; they are also very numerous around the apertures of the anus, nose, mouth, and external ear; but are wanting in the palms of the hands and soles of the feet. Each gland consists of a single duct, more or less capacious, which terminates in a cluster of small secreting pouches or saccules. The sacculi connected with each duct vary, as a rule, in numbers from two to five, but in some instances may be as many as twenty. They are composed of a transparent, colorless membrane enclosing a number of cells. Of these, the outer layer or marginal cells are small, polyhedral, epithelial cells, continuous with the lining cells of the duct. The remainder of the sac is filled with larger cells containing fat, except in the centre, where the cells have become broken up, leaving a cavity containing the débris of cells and a mass of fatty matter which constitutes the sebaceous secretion. The orifices of the ducts open most frequently into the hair-follicles, but occasionally upon the general surface. On the nose and face the glands are of large size, distinctly lobulated, and often become much enlarged from the accumulation of pent-up secretion. The largest sebaceous glands are those found in the eyelids—the Meibomian glands.

The **Sudoriferous** or **Sweat Glands** are the organs by which a large portion of the aqueous and gaseous materials is excreted by the skin. They are found in almost every part of this structure, and are situated in small pits in the deep parts of the corium, or more frequently in the subcutaneous areolar tissue, surrounded by a quantity of adipose tissue. They are small, lobular, reddish bodies, consisting of a single convoluted tube, from which the efferent duct proceeds upward through the corium and cuticle, becomes somewhat dilated at its extremity, and opens on the surface of the cuticle by an oblique valve-like aperture. The efferent duct, as it passes through the epidermis, presents a spiral arrangement, being twisted like a corkscrew in those parts where the epidermis is thick; where, however, it is thin the spiral arrangement does not exist. In the superficial layers of the corium the duct is straight, but in the deeper layers it is convoluted or even twisted. The spiral course of these ducts is especially distinct in the thick cuticle of the palm of the hand and sole of the foot. The size of the glands varies. They are especially large in those regions where the amount of perspiration is great, as in the axillæ, where they form a thin mammillated layer of a reddish color, which corresponds exactly to the situation of the hair in this region; they are large also in the groin. Their number varies. They are most numerous on the palm of the hand, presenting, according to Krause, 2800 orifices on a square inch of the integument, and are rather less numerous on the sole of the foot. In both of these situations the orifices of the ducts are exceedingly regular, and correspond to the small transverse grooves which intersect the ridges of papillæ. In other situations they are more irregularly scattered, but in nearly equal numbers, over parts including the same extent of surface. In the neck and back they are least numerous, their number amounting to 417 on the square inch (Krause). Their total number is estimated by the same writer at 2,381,248, and, supposing the aperture of each gland to represent a surface of $\frac{1}{56}$ of a line in diameter, he calculates that the whole of these glands would present an evaporating surface of about eight square inches. Each gland consists of a single tube intricately convoluted, terminating at one end by a blind extremity, and opening at the other end upon the surface of the skin. In the larger glands this single duct usually divides and subdivides dichotomously, the smaller ducts ultimately terminating in short cæcal pouches, rarely anastomosing. The wall of the duct is thick, the width of the canal rarely exceeding one-third of its diameter. The tube, both in the gland and where it forms the excretory duct, consists of two layers—an outer, formed by fine areolar tissue, and an inner layer of epithelium. The external or fibro-cellular coat is thin, continuous with the superficial layer of the corium, and extends only as high as the surface of the true skin. The epithelial lining in the gland proper consists of a single layer of cubical epithelium, and beneath it, between the epithelium and the fibro-cellular coat, a layer of plain muscular fibres arranged longitudinally. In the duct there are two or more layers of epithelial cells, but no muscular fibres. The epithelium is continuous with the epidermis, and alone forms the spiral portion of the tube. When the cuticle is carefully removed from the surface of the cutis these convoluted tubes of epithelium may be drawn out, and form short, thread-like processes on its under surface. [See Fig. 75.]

The contents of the smaller sweat-glands are quite fluid, but in the larger glands the contents are semifluid and opaque, and contain a number of colored granules and cells which appear analogous to epithelial cells.

SEROUS MEMBRANES.

The **Serous Membranes** form shut sacs, of which one portion is applied to the walls of the cavity which it lines—the *parietal* portion; the other is reflected over the surface of the organ or organs contained in the cavity—the *visceral* portion. Sometimes the sac is arranged quite simply, as the tunica vaginalis testis; at others with numerous involutions or recesses, as the peritoneum, in which, nevertheless, the membrane can always be traced continuously around the whole circumference. The sac is completely closed, so that no communication exists between the serous cavity and the parts in its neighborhood. An apparent exception exists in the peritoneum of the female; for the Fallopian tube opens freely into the peritoneal cavity in the dead subject, so that a bristle can be passed from the one into the other. But this communication is closed during life, except at the moment of the passage of the ovum out of the ovary into the tube, as is proved by the fact that no interchange of fluids ever takes place between the two cavities in dropsy of the peritoneum or in accumulation of fluid in the Fallopian tubes.[1] A serous membrane is often supported by a firm, fibrous layer, as is the case with the pericardium, and such membranes are sometimes spoken of as "fibro-serous."

The various serous membranes are the peritoneum, lining the cavity of the abdomen; the two pleuræ and the pericardium, lining the lungs and heart respectively; and the tunica vaginalis, surrounding each testicle in the scrotum.[2] Serous membranes are thin, transparent, glistening structures, lined on their inner surface by a single layer of polygonal or pavement-endothelial cells, supported on a matrix of fibrous connective tissue, with networks of fine elastic fibres, in which are contained numerous capillaries and lymphatics. On the surface of the endothelium between the cells numerous apertures or interruptions are to be seen. Some of these are stomata, surrounded by a ring of cubical endothelium (see Fig. 12) and communicate with a lymphatic capillary (see p. 51); others (*pseudo-stomata*) are mere interruptions in the epithelial layer, and are occupied by processes of the branched connective-tissue corpuscles of the subjacent tissue or by accumulations of the intercellular cement-substance. [The serous membranes, together with the arachnoid, are *lymph-*

---

[1] The communication between the uterine cavity and the peritoneal sac is not only apparent in the dead subject, but is an anatomical fact which is established by the continuity of its epithelium with that covering the uterus, Fallopian tubes, and fimbriæ.

[2] The arachnoid membrane lining the brain and spinal cord was formerly regarded as a serous membrane, but is now no longer classed with them, as it differs from them in structure, and does not form a shut sac, as do the other serous membranes.

sacs, from which lymphatics arise by the stomata. Hence the great danger of septic inflammation in them in consequence of the large surface and rapid absorption.]

The secretion of these membranes is, in most cases, only sufficient in quantity to moisten the surface, but not to furnish any appreciable quantity of fluid. When a small quantity can be collected, it appears to resemble in many respects the lymph, and like that fluid coagulates spontaneously; but when secreted in large quantities, as in dropsy, it is a watery fluid, which gives a precipitate of albumen on boiling.

SYNOVIAL MEMBRANES.

Synovial Membranes, like serous membranes, are connective-tissue membranes placed between two movable tissues, so as to diminish friction, as between the two articular ends of the bones forming a movable joint; between a tendon and a bone, where the former glides over the latter; and between the skin and various subcutaneous bony prominences.

The synovial membranes are composed essentially of connective tissue, with the cells and fibres of that structure, containing numerous vessels and nerves. It was formerly supposed that these membranes were analogous in structure to the serous membranes, and consisted of a layer of flattened cells on a basement-membrane. No such cells, however, exist, and the only ones found on the surface are irregularly-branched connective-tissue corpuscles, similar to those found throughout the tissue. Here and there these cells are collected in patches and present the appearance of endothelium, but do not possess the true characters of an endothelial layer. They are surrounded and held together by an albuminous ground-substance. A further description of the synovial membranes will be found in the Descriptive Anatomy of the Joints.

MUCOUS MEMBRANES.

Mucous Membranes line all those passages by which the internal parts communicate with the exterior, and are continuous with the skin at the various orifices of the surface of the body. They are soft and velvety and very vascular, and their surface is coated over by their secretion, *mucus*, which is of a tenacious consistence, and serves to protect them from the foreign substances introduced into the body with which they are brought in contact.

They are described as lining the two tracts—the gastro-pulmonary and the genito-urinary; and all or almost all mucous membranes may be classed as belonging to and continuous with the one or the other of these tracts.

The external surfaces of these membranes are attached to the parts which they line by means of connective tissue, which is sometimes very abundant, forming a loose and lax bed, so as to allow considerable movement of the opposed surfaces on each other. It is then termed the *submucous tissue*. At other times it is exceedingly scanty, and the membrane is closely connected to the tissue beneath—sometimes, for example, to muscle, as in the tongue; sometimes to cartilage, as in the larynx; and sometimes to bone, as in the nasal fossæ and sinuses of the skull.

In structure a mucous membrane is composed of *corium* and *epithelium*. The epithelium is of various forms, including the squamous, columnar, and ciliated, and is often arranged in several layers. (See Fig. 11.) This epithelial layer is supported by the corium, which is analogous to the derma of the skin, and consists of connective tissue, either simply areolar or containing a greater or less quantity of lymphoid tissue. This tissue is usually covered on its external surface by a transparent structureless basement-membrane, and internally merges into the submucous areolar tissue. It is only in some situations that the basement-membrane can be demonstrated. The corium is an exceedingly vascular membrane, containing a dense network of capillaries, which lie immediately beneath the epithelium and are derived from small arteries in the submucous tissue.

The fibro-vascular layer of the corium contains, besides the areolar tissue and vessels, unstriped muscle-cells, which form in many situations a definite layer, called the *muscularis mucosæ*. [See the description of the Small Intestine.] This is situated in the deepest part of the membrane, and is plentifully supplied with nerves. In addition to these nerves, others pass to the epithelium and terminate between the cells. Lymphatic vessels are found in great abundance, commencing either by cæcal extremities or in networks, and communicating with plexuses in the submucous tissue.

Imbedded in the mucous membrane are found numerous glands, and, projecting from it, are processes (villi and papillæ) analogous to the papillæ of the skin. These glands and processes, however, exist only at certain parts; and it will be more convenient to refer for their description to the sequel, where the parts are described as they occur.

SECRETING GLANDS.

The **Secreting Glands** are organs in which the blood, circulating in capillary vessels, is brought into contact with epithelial cells, whereby certain elements are separated ("secreted") out of the blood. The essential parts, therefore, of a secreting gland are *cells*, which have the power of extracting from the blood certain matters, and in some cases converting them into new chemical compounds; and *blood-vessels*, by which the blood is brought into close relationship with these cells. The general arrangement in all secreting structures—that is to say, not only in secreting glands, but also in secreting membranes—is for the cells to be arranged on one surface of an extra-vascular basement-membrane, which supports them, and for a minute plexus of capillary vessels to ramify on the other surface of the membrane. The cells then extract from the blood certain constituents which pass through the membrane into the cells, where they are prepared and elaborated. The basement-membrane does not, however, always exist, and any free surface would appear to answer the same purpose in some cases.

By the various modifications of this secreting surface the different glands are formed. This is generally effected by an involution of the membrane in various different ways, the object being to increase the extent of secreting surface within a given bulk.

In the simplest form a single involution takes place, constituting a *simple gland;* this may be either in the form of an open tube (Fig. 77, A) or the walls of the tube may be dilated so as to form a saccule (Fig. 77, B). These are named the *simple tubular* or *saccular* glands. Or, instead of a short tube, the involution may be lengthened to a considerable extent, and then coiled up to occupy less space. This constitutes the *simple convoluted tubular* gland, an example of which may be seen in the sweat-glands of the skin (Fig. 77, C).

If, instead of a single involution, secondary involutions take place from the primary one, as in Fig. 77, D and E, the gland is then termed a compound one. These secondary involutions may assume either a saccular or tubular form, and so constitute the two subdivisions—the *compound saccular* or *racemose* gland, and the *compound tubular*. The racemose gland in its simplest form consists of a primary involution which forms a sort of duct, upon the extremity of which are found a number of secondary involutions, called saccules or alveoli, as in Brunner's glands (Fig. 77, D). But, again, in other instances the duct, instead of being simple, may divide into branches, and these again into other branches, and so on, each ultimate ramification terminating in a dilated cluster of saccules; and thus we may have the secreting surface almost indefinitely extended, as in the salivary glands (Fig. 77, E). In the *compound tubular* glands the division of the primary duct takes place in the same way as in the racemose glands, but the branches retain their tubular form, and do not terminate in saccular recesses, but become greatly lengthened out (Fig. 77, F). The best examples of this form of gland are to be found in the kidney and testicle. All these varieties of glands are produced by a more or less complicated involution of a secreting membrane, and they are all identical in structure; that is to say, the saccules or tubes, as the case may be, are lined with cells, generally spheroidal or columnar in figure, and on their outer surface is an intimate plexus of capillary vessels. The secretion, whatever it may be, is eliminated by the cells from the blood, and is poured into the saccule or tube, and so finds its way out through the primary involution on to the free surface of the secreting membrane. In addition, however, to these glands which are formed by an *involution* of the secreting membrane, there are some few others which are formed by a *protrusion* of the same structure, as in the vascular fringes of synovial membranes. This form of secreting structure is not nearly so frequently met with.

Fig. 77.

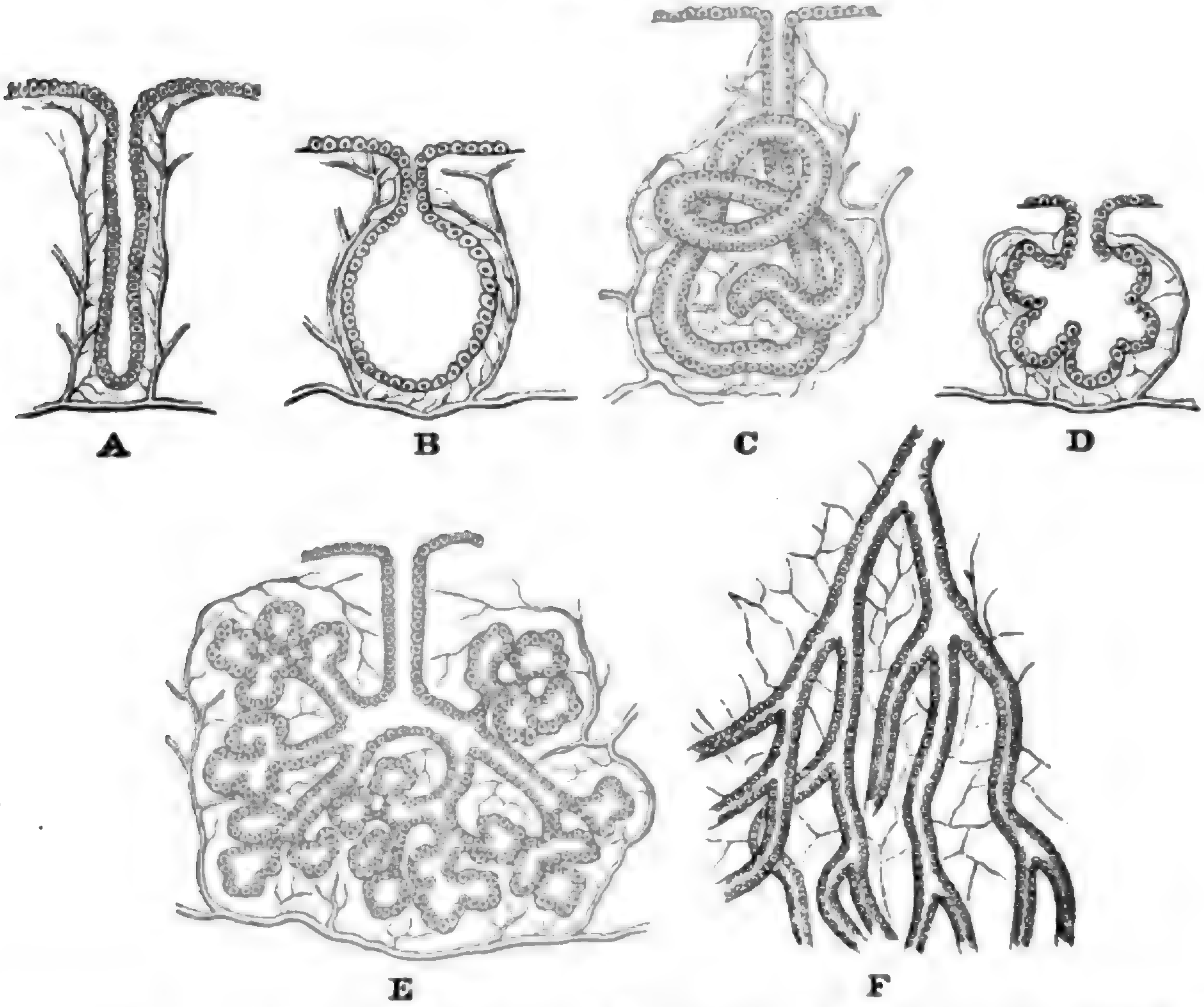

Diagrammatic Plan of Varieties of Secreting Glands: A, simple gland; B, sacculated simple gland; C, simple convoluted tubular gland; D, E, racemose gland; F, compound tubular gland.

Origin and Development of the Body.

THE whole body is developed out of the **ovum** (Fig. 78) when fertilized by the spermatozoa. The ovum is merely a simple nucleated cell or collection of protoplasm, and the spermatozoa disappear when they have accomplished their mysterious function. All the complicated changes by which the various intricate organs of the whole body are formed from one simple cell may be reduced to two general processes—viz. the *segmentation* or *cleavage* of cells, and their *differentiation*. The former process consists in the splitting of the nucleus and its investing cell-wall, whereby the original cell is represented by two. The differentiation of cells is a term used to describe that unknown power or tendency impressed on cells—which, to all methods of examination now known, seem absolutely identical—whereby they grow into different forms; so that (to take the first instance which occurs in the growth of the embryo) the indifferent cells of the vascular area are differentiated, some of them into blood-globules, others into the solid tissue which forms the blood-vessels. The extreme complexity of the process of development renders it at all times difficult to describe it intelligibly, and still more so in a work like this, where adequate space and illustration can hardly be afforded, having respect to the main purpose of the work. I can only hope to render the leading features of the process tolerably plain, and must refer the reader who wishes to follow the various changes more minutely to the special works on the subject, and especially to the work of Foster and Balfour. Many of the statements which are accepted in human embryology are made only on the strength of experiments on the lower animals, direct observation on the human subject being impossible.

FIG. 78.

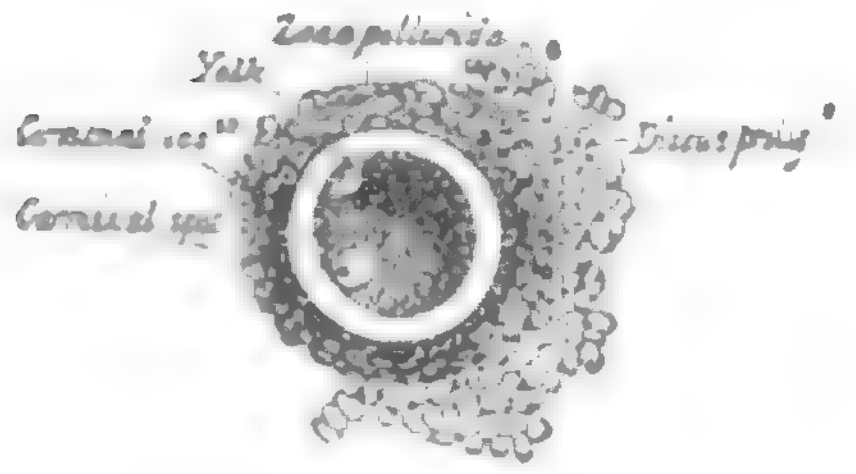

Ovum of the Sow.

FIG. 79.

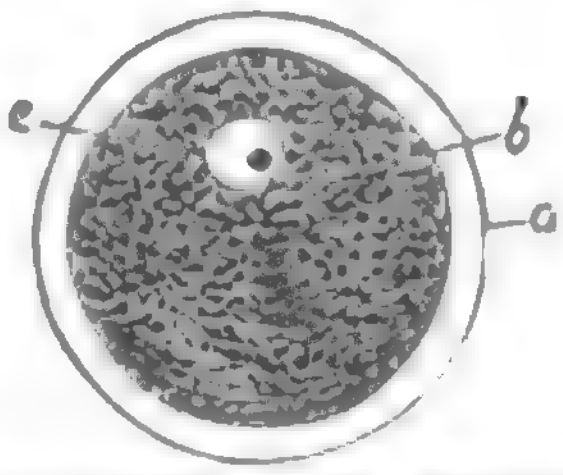

Human Ovum from a Middle-sized Follicle (magnified 250 times): *a*, vitelline membrane or *zona pellucida*; *b*, external border of the yolk and internal border of the vitelline membrane; *c*, germinal vesicle and germinal spot.

The **ovum** is a small spheroidal body situated, in immature Graafian vesicles, near their centre, but in the mature ones in contact with the membrana granulosa,[1] at that part of the vesicle which projects from the surface of the ovary. The cells of the membrana granulosa are accumulated round the ovum in greater number than at any other part of the vesicle, forming a kind of granular zone, the *discus proligerus*.

The **human ovum** (Fig. 79) is extremely minute, measuring $\frac{1}{125}$ of an inch in diameter. It is a cell consisting externally of a transparent envelope, the *zona pellucida*, or *vitelline* membrane. Within this, and in close contact with it, is the *yolk* or *vitellus*, imbedded in the substance of which is a small vesicular body, the *germinal vesicle* (*vesicle of Purkinje*), the nucleus of the cell; and this contains as its nucleus a small spot, the *macula germinativa*, or the spot of Wagner.

The **zona pellucida, or vitelline membrane,** is a thick, colorless, transparent membrane which appears under the microscope as a bright ring, bounded externally and internally by a dark outline. It disappears, and is replaced by the chorion of the impregnated ovum.

---

[1] See the description of the Ovary.

The **yolk** consists of granular protoplasm—*i. e.* of granules or globules of various sizes—imbedded in a more or less viscid fluid. The smaller granules are very minute; the larger granules, which are in the greatest number at the periphery of the yolk, resemble fat-globules. In the human ovum the number of granules is comparatively small.

The **germinal vesicle** consists of a fine, transparent, structureless membrane containing a watery fluid, in which are occasionally found a few granules. It is $\frac{1}{500}$ to $\frac{1}{625}$ of an inch in diameter, and in immature ova lies nearly in the centre of the yolk; but as the ovum becomes developed it approaches the surface, and enlarges much less rapidly than the ovum itself.

The **germinal spot** occupies that part of the periphery of the germinal vesicle which is nearest to the periphery of the yolk. It is opaque, of a yellow color, and finely granular in structure, measuring from $\frac{1}{3600}$ to $\frac{1}{5000}$ of an inch.

The phenomena attending the discharge of the ova from the Graafian vesicles, since they belong as much or more to the ordinary function of the ovary than to the general subject of the growth of the body, are described with the anatomy of the ovaries in the body of the work.

It has long been known that the germinal vesicle disappears in the mature ovarian ovum; but it has only recently been discovered that this disappearance is intimately connected with the formation of one or more peculiar bodies, the *polar globules* of Robin, the origin of which has not been known, and also with the formation of another body, which appears to take a remarkable part in fecundation, and is named the *female pronucleus.* The order of the formation of these bodies from the germinal vesicle is briefly as follows: Usually before the rupture of the Graafian follicle, but after the ovum has become mature or ripe, a portion of the germinal vesicle is protruded outside the yolk, but still remains within the vitelline membrane; this forms a small globular mass and constitutes the first polar globule. After a time, generally not till the ovum has entered the tube, a second protrusion of a portion of the germinal vesicle takes place, and forms a second polar globule. We have thus about two-thirds of the germinal vesicle extruded from the yolk, and about one-third remaining behind; and upon the ejection of each of these bodies a visible shrinking of the yolk takes place. The portion of the germinal vesicle which remains behind recedes from the surface toward the centre of the yolk and assumes a spherical form, and is now termed the *female pronucleus.* All these changes, it must be understood, occur at each expulsion of an ovum, and are quite independent of fecundation.

Fig. 80.

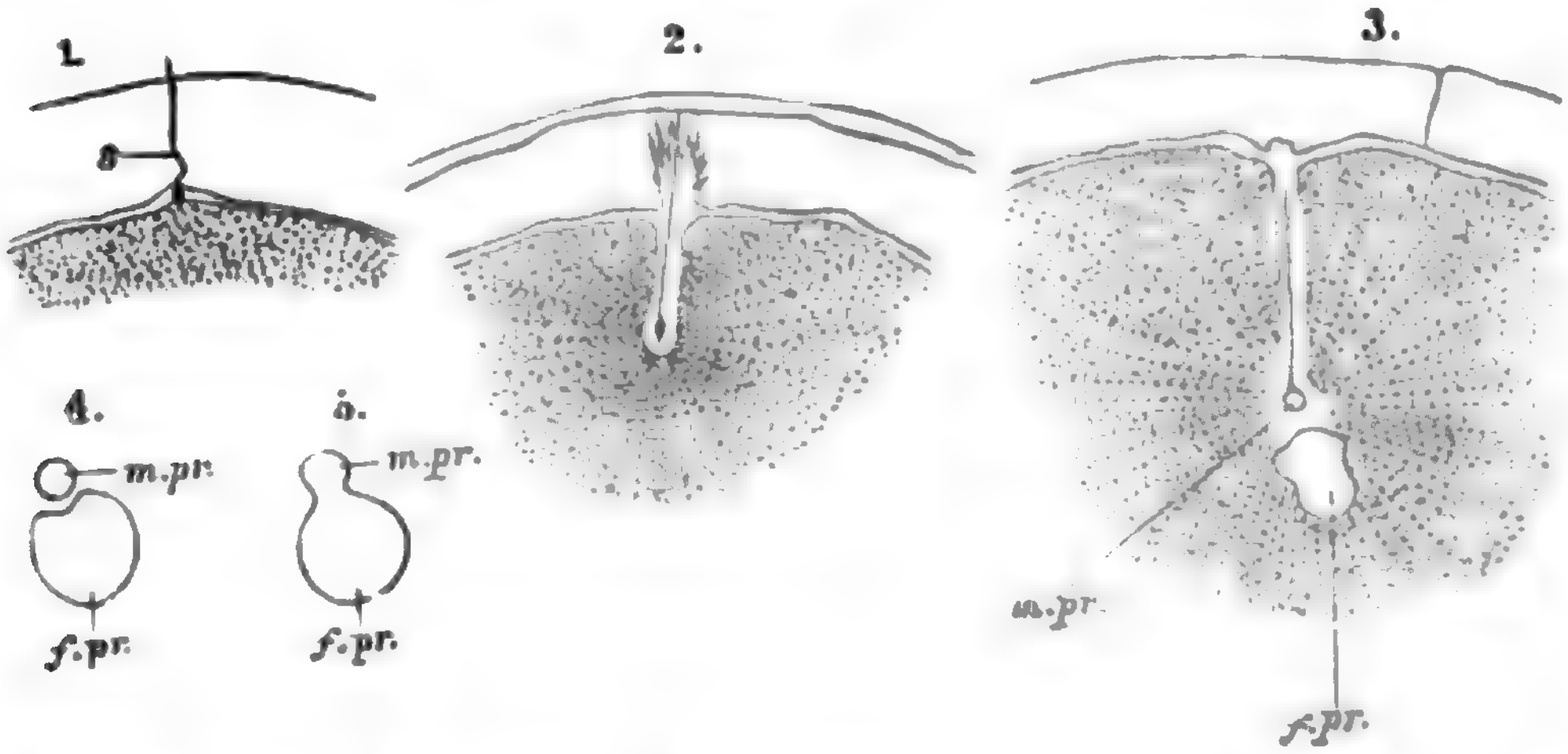

Fertilization of the Ovum of an Echinoderm: *s*, spermatozoon; *m. pr.*, male pronucleus; *f. pr.*, female pronucleus; 1, accession of a spermatozoon to the periphery of the vitellus; 2, its penetration; 3, transformation of the head of the spermatozoon into the male pronucleus; 4, 5, blending of the male and female pronuclei (from *Quain's Anatomy*, Selenka).

The first changes in the ovum which take place at the time of conception appear to be as follows: One or more spermatozoa penetrate the ovum, and come into contact with the yolk and with the portion of the germinal vesicle remaining in the yolk. It seems as if this normally occurs in the Fallopian tube,[1] but abnormally it may even take place in the peritoneal cavity. One spermatozoon, in advance of all the rest, becomes buried in the yolk, the tail disappears, and the head, a sort of nuclear body, constitutes the *male pronucleus.* This gradually approaches the female pronucleus, which by this time is situated in the centre of the yolk. As soon as they come into contact they fuse into one, and thus fecundation is effected (Fig. 80). It is believed by most physiologists that one spermatozoon is sufficient for fecundation; but in all probability several spermatozoa, as a rule, penetrate the yolk and undergo the same process of conversion into male nuclei, reach the female pronucleus, and fuse with it.[2] [This last is probably not the case.]

The first result of the fertilization of the ovum is a cleavage or fission of its substance, which is first cleft into two masses, then into four, and so on, until at length a mulberry-like agglomeration of nucleated cells results (Fig. 81). These cells are sometimes termed *vitelline spheres.*

FIG. 81.

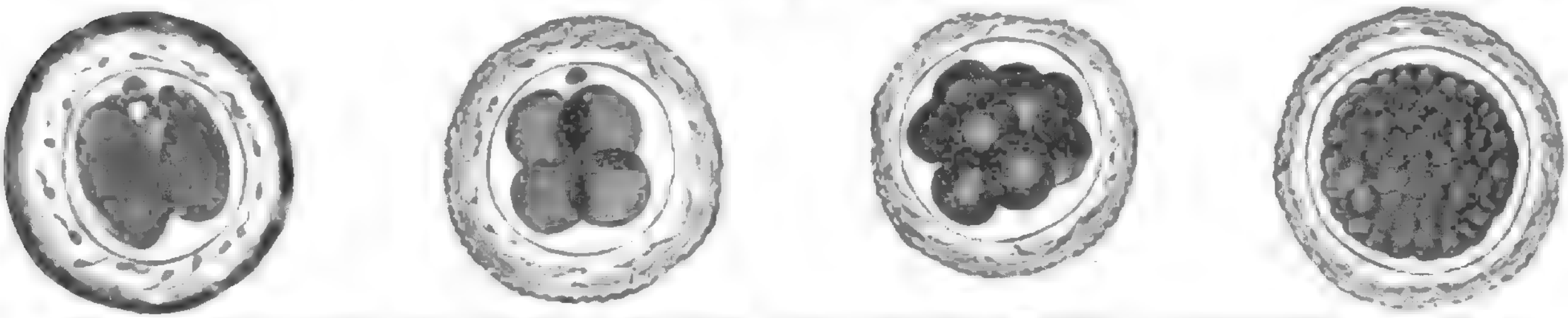

Four Diagrams to show the Division of the Yolk. The ovum is surrounded by spermatozoa. The clear corpuscles (polar globules of Robin) are seen in the first two.

The manner in which segmentation occurs is somewhat peculiar. The two spheres resulting from the first cleavage are of unequal size. One, which for the sake of distinction we will call the *upper* or *epiblastic cell,* is larger than the other, the *lower* or *hypoblastic cell,* and after they have divided three or four times, the rate of cleavage in the spheres derived from the upper or epiblastic segment becomes more rapid than in those derived from the lower or hypoblastic segment. In addition to this, the spheres derived from the upper segment have a tendency to spread out over and enclose those from the lower segment; so that by about the ninth or tenth division there is an external layer of spheres derived from the primary upper or epiblastic segment surrounding and almost enclosing a mass of spheres, which in consequence of their diminished rate of cleavage are fewer in number and larger in size, derived from the primary lower or hypoblastic segment (Fig. 82, A). Fluid collects between the two sets of spheres, except at one part, where they remain in contact, and the ovum is converted into a sac formed by a layer of spheres derived from the upper primary segment, and containing at one part another mass of spheres derived from the lower primary segment (Fig. 82, B). The inner cells are rather more granular than the outer, beneath which they gradually spread, becoming applied over a part of their inner surface in a single layer; so that the cavity is afterward enclosed more or less completely in a double layer of cells.

The ultimate destination of the outermost complete layer of spheres is at present doubtful. By some they are believed to be transitory, and gradually to disappear in the course of the formation of the various layers of the blastodermic membrane; by others it is thought that they form the outer layer (epiblast) of this membrane.

---

[1] Many physiologists, as Bischoff and Dr. M. Barry, taught that the ovum is fecundated in the ovary, but the reasoning of Dr. Allen Thomson appears very cogent in proving that the usual spot at which the spermatozoa meet the ovum is in the tube, down which it slowly travels to the uterus, in its course becoming surrounded by an albuminous envelope derived from the walls of the tube.

[2] If the student refers to the development of the generative organs, he will find that the ovum of the female and the spermatozoon of the male are derived from fundamentally the same structures, and therefore their fusion is the union of two elements of very similar morphological value.

Adopting the latter and more general view, the ovum would consist of a cavity surrounded by (1) a layer of cells completely lining the interior of the vitelline membrane, and (2) by a second layer internal to these and partially lining the interior of the outer layer, both sets of cells derived from the segmentation of the ovum. The double layer of cells is called the "*blastodermic membrane*," the outer layer being termed the "*epiblast*," and the inner the "*hypoblast*."

FIG. 82.

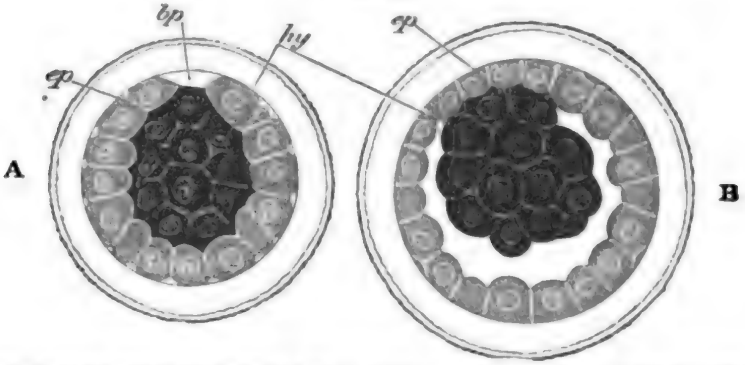

Ovum of the Rabbit at the End of the Process of Segmentation: *ep*, epiblast; *hy*, primitive hypoblast; *bp*, place where the epiblast has not yet grown over the hypoblast (from Balfour, after Ed. van Beneden).

At first the area of the blastodermic membrane, which consists of both the inner and outer layers of cells, is a small disk in which the first traces of the embryo are seen; hence it is called the *germinal disk* or *area germinativa* (Fig. 83). The first trace of the embryo appears as a faint streak [at the posterior end of the area germinativa], called the *primitive trace*. After the formation of the primitive trace, but previous to the appearance of the next parts of the embryo presently to be described—viz. the laminæ dorsales and the notochord—the blastodermic membrane consists of only two layers, the epiblast and hypoblast, but during the formation of these structures a third layer has made its appearance. This is the *mesoblast*, and is situated between the other two (Fig. 84). As to the precise origin of this third layer considerable difference of opinion exists. According to some embryologists, it is formed entirely by proliferation of cells belonging to the epiblastic layer; according to others, it is formed by a splitting of the hypoblast, or, at all events, a differentiation into a central layer of mesoblastic cells and a lower layer of hypoblastic cells. But in whichever way this third stratum may be formed, the blastodermic membrane eventually consists of three layers—the external, which used to be called the serous layer, but is now more commonly termed the *epiblast*; the internal, the mucous layer or *hypoblast*; and the middle, believed by most writers to be originally developed by cleavage from the *hypoblast*, which is now usually called the *mesoblast*, but which was formerly named the "vascular layer."

[FIG. 83.

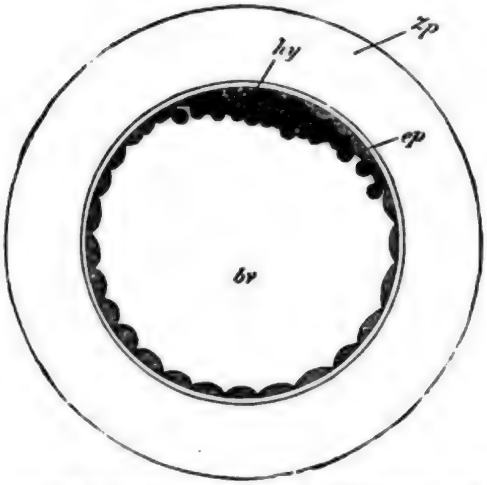

Rabbit's Ovum between seventy and ninety hours after impregnation: *bv*, cavity of blastodermic vesicle; *ep*, epiblast; *hy*, primitive hypoblast; *zp*, zona pellucida (Foster and Balfour).]

The *epiblast* is mainly concerned in the formation of the external cuticle and of the nervous centres. The epidermis of the body and all the involutions of the epidermis in the ducts of [superficial] glands, as the mammæ, as well as the brain, the spinal cord, and part of the eye, which is directly formed from the brain, and portions of the nose and ear, are developed from it. The external layer of the amnion is also formed from the epiblast, and also a portion of the chorion.

Fig. 84.

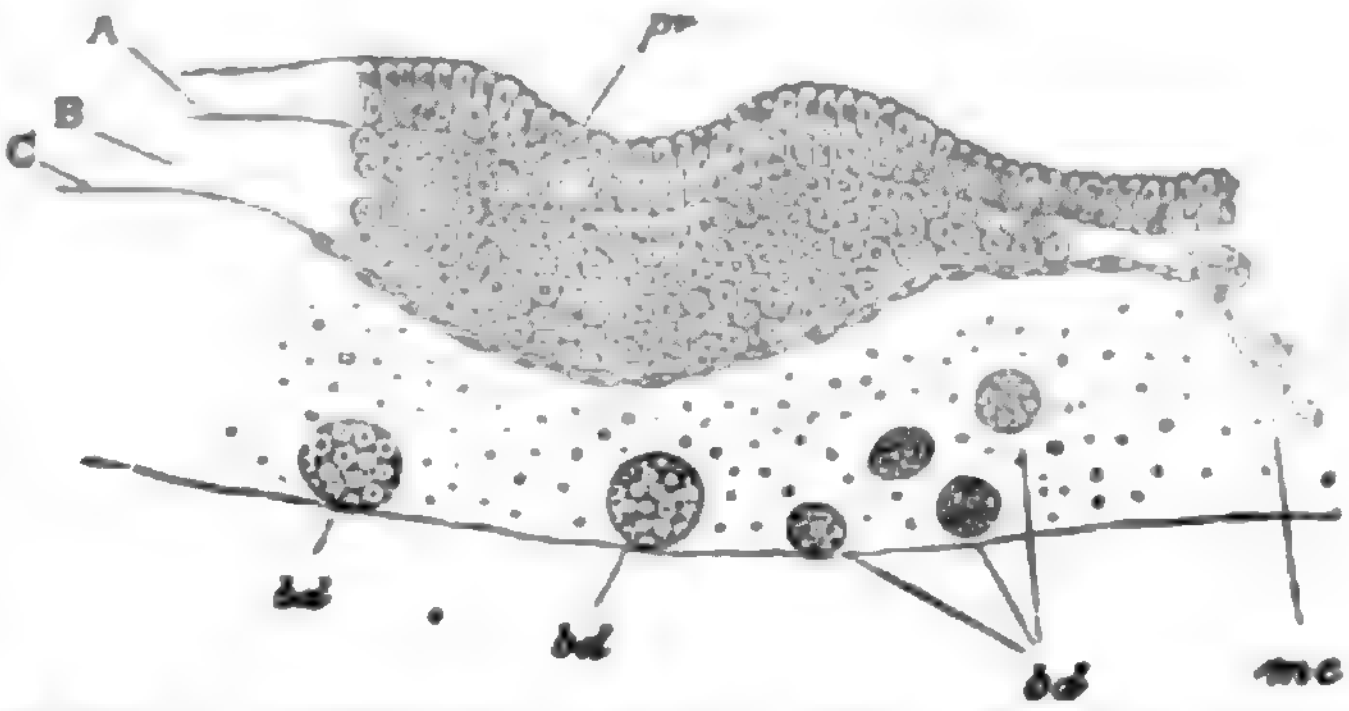

Section of a Blastoderm, at right angles to the long axis of the embryo, near its middle, after eight hours' incubation (from Foster and Balfour): A, epiblast formed of two layers of cells; B, mesoblast thickened below the primitive groove; C, hypoblast formed of one layer of flattened cells; *pr*, primitive groove; *mc*, mesoblast cell; *bd*, formative cells in the so-called segmentation or subgerminal cavity. (The line of separation between the epiblast and mesoblast below the primitive groove is too strongly marked in the figure.)

The *hypoblast* is mainly concerned in forming the internal epithelium—viz. that of the whole alimentary passages except the mouth and a small portion of the rectum near the anus (which are formed by an involution of the integument [epiblast]); that of the respiratory tract, which is originally an offset from the alimentary canal; and the epithelium of all the glandular organs which open into the intestinal tract. The hypoblast forms also the deeper layer of the umbilical vesicle and allantois.

All the rest of the embryo is formed from the mesoblast—viz. all the vascular and locomotive system, the cutis, all the connective tissues, the nerves[1] and the genito-urinary organs, through the Wolffian bodies and other temporary fœtal structures. The vascular system of the fœtus extends to the yolk and the maternal parts along the umbilical vesicle and allantois, so that the greater part of these bodies and the outer layer of the amnion are also formed out of the mesoblast. The fœtal portion of the placenta, being essentially a vascular structure, is also developed from the mesoblast.

First Rudiments of the Embryo (Figs. 85 and 86).—The *primitive trace*, alluded to above as appearing in the *area germinativa*, is a very transitory structure, which marks the direction of the embryonic axis, and is gradually lost in consequence of its place becoming occupied by the rudimentary spinal column [and embryonic axis].

The first real approach toward a definite form in the embryo is made (1) by the development of the rudimentary spinal column; (2) by the cleavage of the middle layer of the blastodermic membrane from which a part of that column is derived; and (3) by the incurvation of the column at its cephalic end to form the brain and brain-case.

First, a growth and heaping up of the cells of the epiblast or outer layer take place. This commences in the anterior part of the area germinativa and extends in the same direction as the primitive trace, gradually occupying its position until this latter is lost at the caudal extremity of the embryo (Fig. 87). This heaping up of the epiblast gives rise to a longitudinal groove down its centre, in consequence of the manner in which the cells of the epiblast are heaped up into two [longitudinal] ridges, with a furrow between them, so that the sides and base of the groove are formed of epiblastic cells (Fig. 88, A). The groove becomes deeper and deeper in consequence of the further heaping up of the cells to form the ridge on either side. In this way the ridges eventually become two plates, the *laminæ dorsales* or *medullary plates*, which finally coalesce, and thus form a closed tube, the *neural canal*, lined by epiblast and having a covering of the same membrane (Fig. 88). This coalescence first takes place in the middle of the embryo, then toward the cephalic end, and lastly at the caudal extremity. The lining of this tube is developed into the nervous centres, the covering into the epidermis of the back and head. The

---

[1] In the spinal nerves the part in connection with the cord, including the ganglion, is formed from mesoblast, according to the most recent observation. [The spinal nerves do not arise as here stated, but are developed as outgrowths from the spinal cord. They are therefore of epiblastic, rather than of mesoblastic, origin.]

Fig. 85.[1]

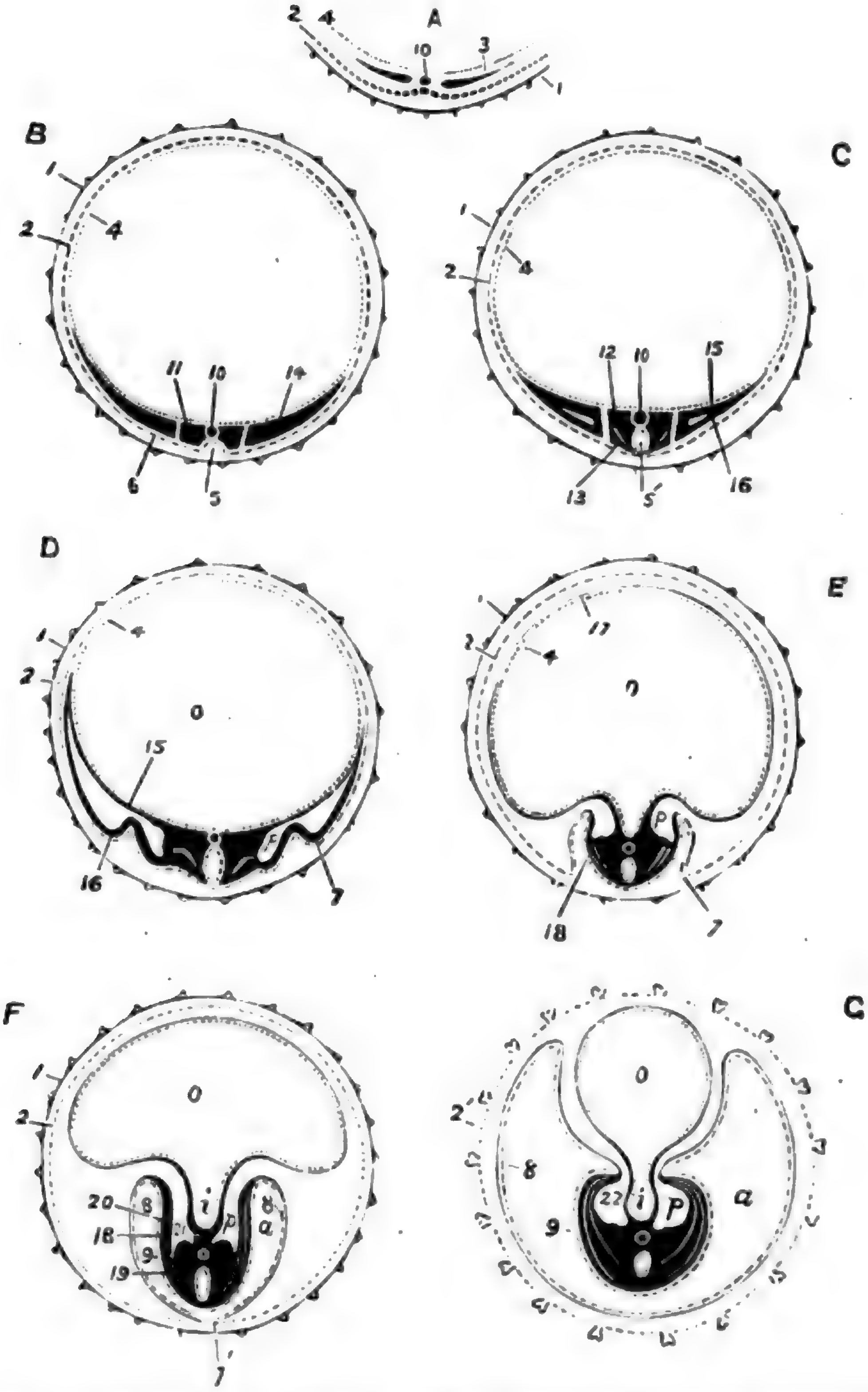

Diagrams to show the Development of the Three Layers of the Blastodermic [vesicle or] Membrane in transverse sections: *A*, portion of the ovum with the zona pellucida and the germinal area. *B, C, D, E, F, G*, different stages of development: *o*, umbilical vesicle; *a*, amnion; *i*, intestine; *p*, peritoneal cavity, bounded by the splanchno-pleural and somato-pleural layers of mesoblast; 1, vitelline membrane; 2, external blastodermic layer [epiblast]; 3, middle layer [mesoblast]; 4, internal layer [hypoblast]; 5, medullary laminæ and groove; 5′, medullary canal; 6, epidermic laminæ; 7, lateral flexures of the amnion; 7′, the same almost in contact; 8, internal epithelial layer of the amnion; 9, epidermis of the embryo; 10, chorda dorsalis; 11, vertebral laminæ; 12, protovertebræ proper; 13, muscular laminæ; 14, lateral laminæ; 15, fibro-intestinal laminæ; 16, cutaneous laminæ; 17, internal fibrous layer of the umbilical vesicle; 18, muscular laminæ extending to meet the cutaneous; 19, external layer of the cutaneous laminæ; 20, internal layer of the same; 21, mesentery; 22, fibrous layer of the intestine.

---

[1] The dotted lines indicate the parts belonging to the internal blastodermic layer; the plain lines those belonging to the middle; the interrupted lines those belonging to the external. The embryo has been represented, in this and the following diagram, lying on its back. The natural position is generally assumed to be the reverse.

FIG. 86.[1]

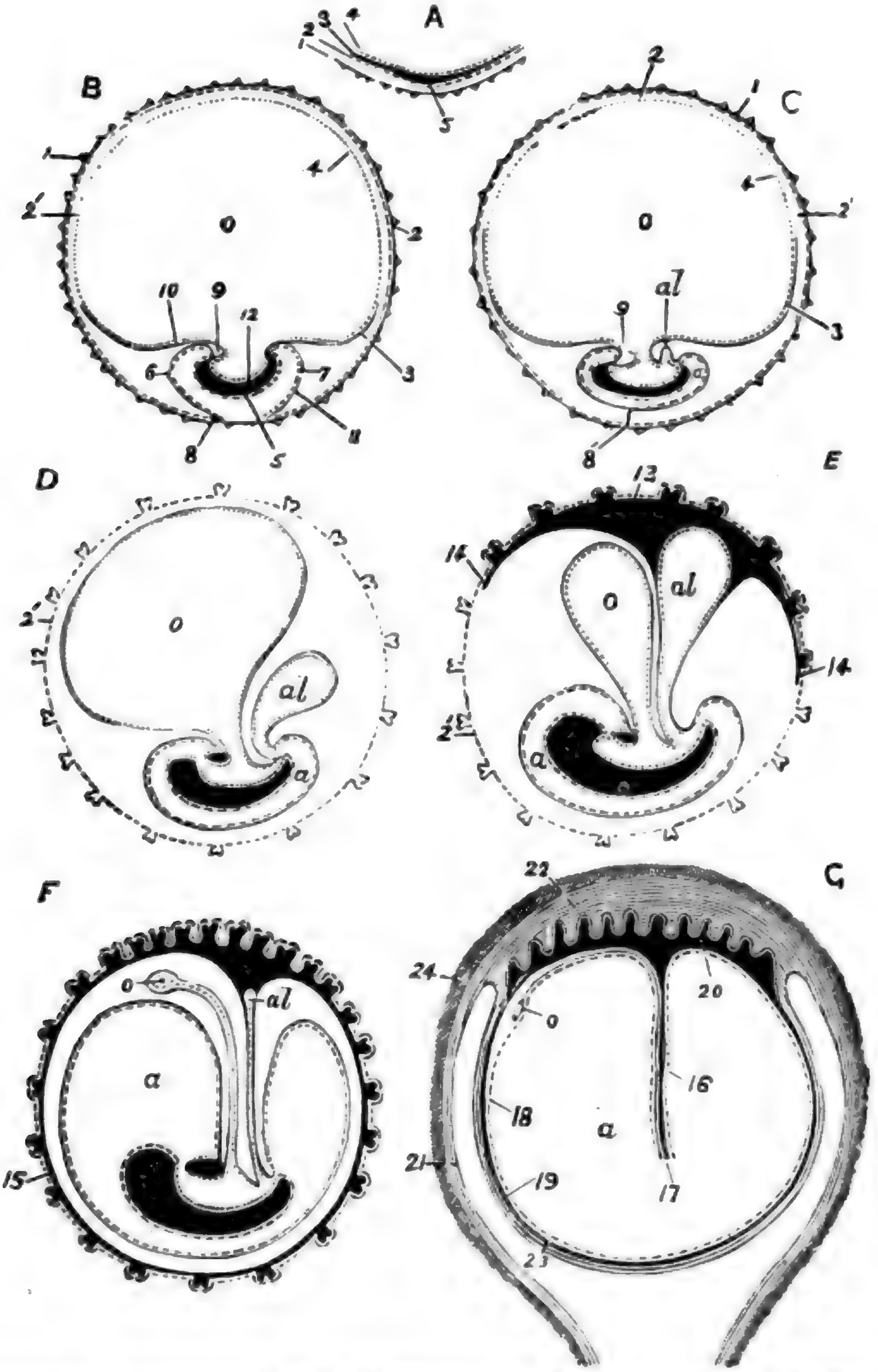

Diagrams to show the Development of the Three Blastodermic Layers in antero-posterior sections: *A*, portion of ovum with the vitelline membrane and germinal area. *B, C, D, E, F*, various stages of development. *G*, ovum in the uterus and formation of decidua; 1, vitelline membrane; 2, external blastodermic layer [epiblast]; 2′, vesicula serosa; 3, middle blastodermic layer [mesoblast]; 4, internal layer [hypoblast]; 5, the future embryo; 6, cephalic flexure of the amnion; 7, caudal flexure; 8, spot where the amnion and vesicula serosa are continuous; 8′, posterior umbilicus; 9, cardiac cavity; 10, external fibrous layer of the umbilical vesicle; 11, external fibrous layer of the amnion; 12, internal layer of the blastoderm forming the intestine; 13, 14, external layer of the allantois, extending to the inner surface of the vesicula serosa; 15, the same now completely applied to the inner surface of the vesicula serosa; 16, umbilical cord; 17, umbilical vessels; 18, amnion; 19, chorion; 20, fœtal placenta; 21, mucous membrane of uterus · 22, maternal placenta; 23, decidua reflexa; 24, muscular wall of uterus.

---

[1] The same note applies to this as to the preceding diagram.

cephalic extremity of the neural canal is soon seen to be more dilated than the rest, and to present constrictions dividing it imperfectly into three chambers: the brain is developed from this dilated portion; the spinal cord takes its origin from the remainder of the tube. Below the neural canal the mesoblast lies, and from this are developed (1) a continuous rod-shaped body lying below the primitive groove, called the *notochord* or *chorda dorsalis*;[1] (2) on either side a row of well-defined, dark, square segments or masses, separated by clear, transverse intervals, called the *protovertebræ* or *protovertebral somites*. These first make their appearance in the region which afterward becomes the neck, then farther forward toward the head, and afterward extend along the body. They are developed from mesoblastic cells which form a thick longitudinal column on either side of the notochord, and [which become] separated from the rest of the mesoblastic layer. The remainder of the mesoblast forms a flattened layer of cells between the epi- and hypoblast, and, as will presently be seen, divides into two plates, leaving an interval between them. The longitudinal column, on the other hand, undergoes a series of transverse segmentations, and so becomes converted into the quadrilateral protovertebræ. These bodies, as will be explained hereafter, are not the same as the permanent vertebræ, but they are differentiated, partly into the vertebræ and partly into the muscles and true skin. Just outside the two series of protovertebræ the mesoblast splits into two layers: the upper, or that covered by epiblast, is called the *somatopleure*, and the lower, lined by hypoblast, the *splanchnopleure* (Fig. 88 B, 5–5′). From the former the skeleton, muscles, and true skin of the external parts of the body are derived; from the latter, the muscular and other mesoblastic portions of the viscera. The space between

FIG. 87.

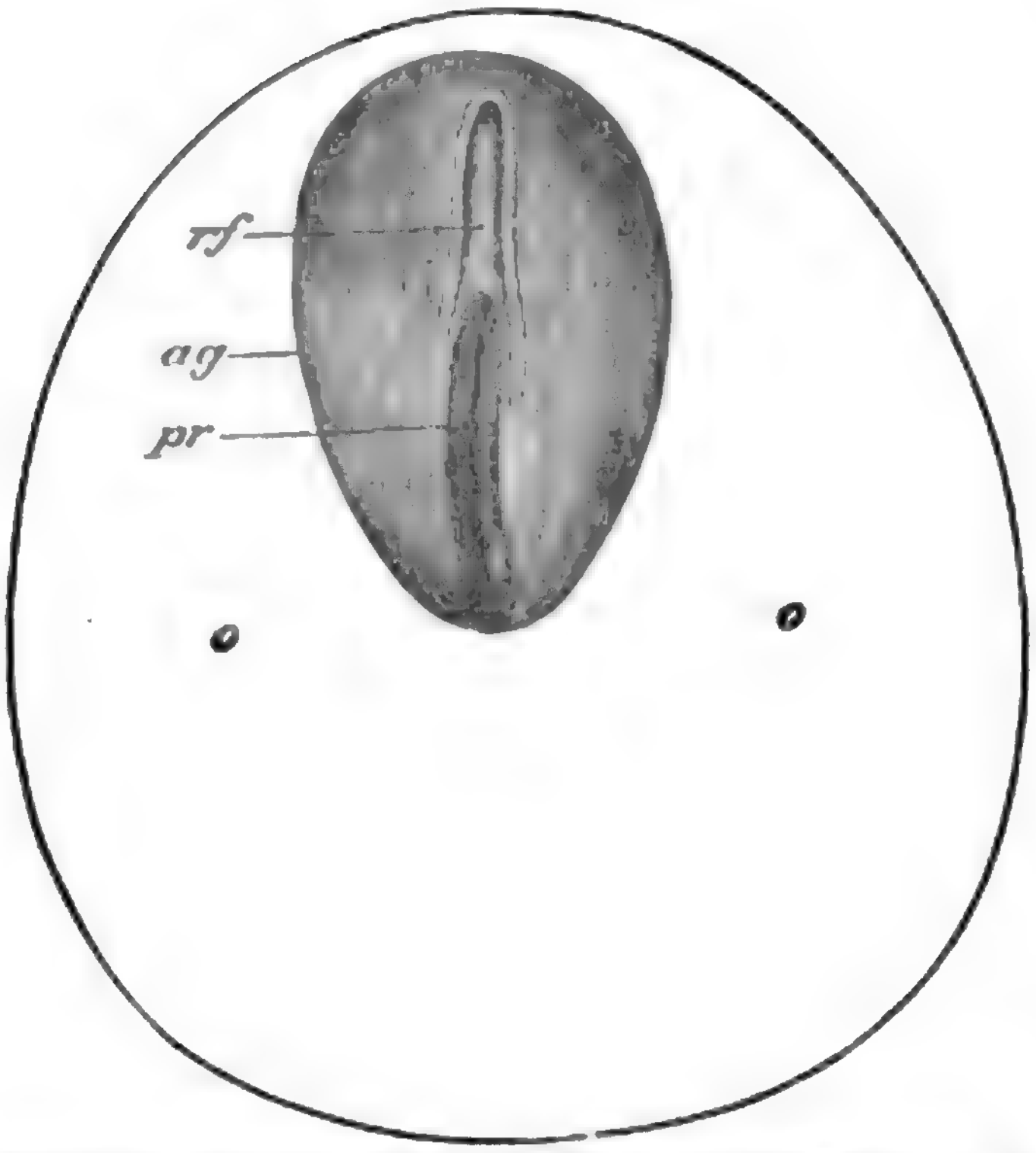

Embryonic Area of the Ovum of a Rabbit at the Seventh Day: *ag*, embryonic area; *o*, *o*, region of the blastodermic vesicle immediately surrounding the embryonic area; *pr*, primitive streak; *rf*, medullary groove (from Kölliker).

FIG. 88.

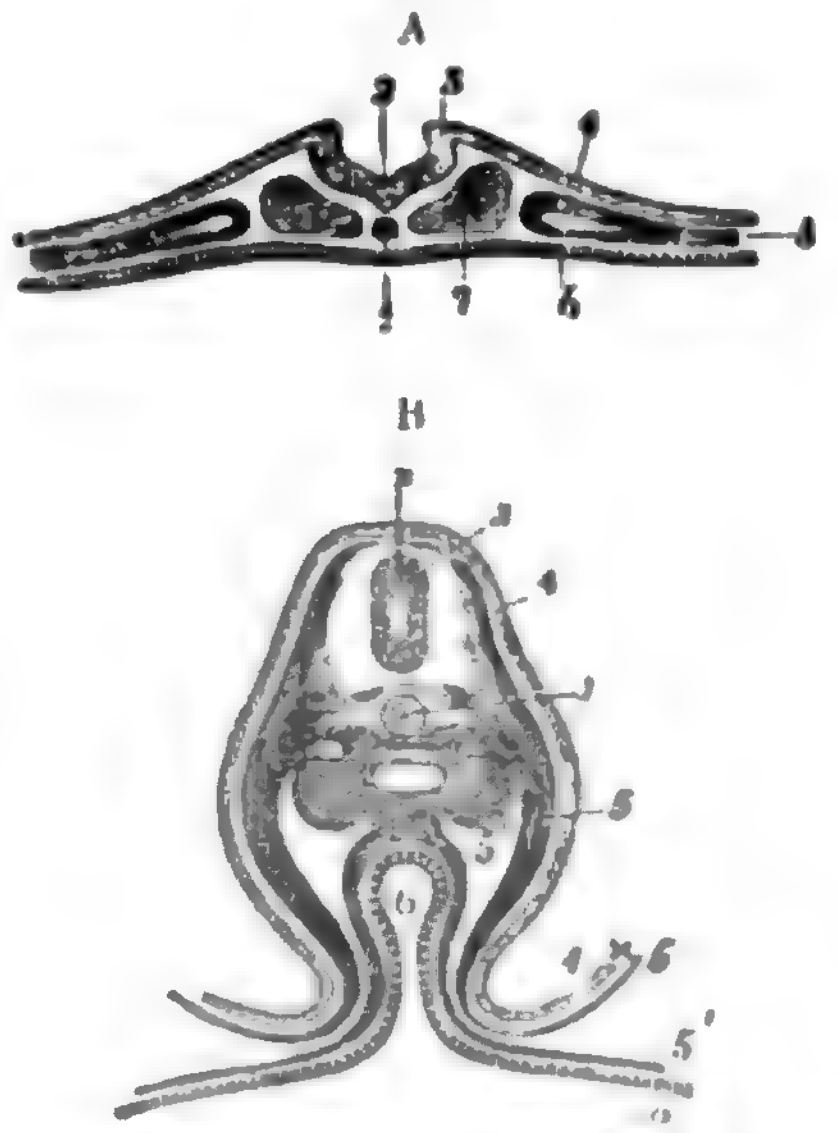

Transverse Sections through the Embryo Chick, before and some time after the closure of the medullary canal, to show the upward and downward inflections of the blastoderm (after Remak). A, at the end of the first day: 1, notochord; 2, primitive groove in the medullary canal; 3, edge of the dorsal lamina; 4, corneous layer or epiblast; 5, mesoblast divided in its inner part; 6, hypoblast or epithelial layer; 7, section of protovertebral segment.
B, on the third day in the lumbar region: 1, notochord in its sheath; 2, medullary canal, now closed in; 3, section of the medullary substance of the spinal cord; 4, corneous layer; 5, somatopleure of the mesoblast; 5, splanchnopleure (one figure is placed in the pleuro-peritoneal cavity); 6, layers of hypoblast in the intestines, spreading also over the yolk; 4 × 5, part of the fold of the amnion formed by epiblast and somatopleure.

---

[1] Some doubt appears to exist as to whether the notochord is not developed from the hypoblast (Balfour). [It is now generally admitted that the notochord arises from the hypoblast.]

them is the common pleuro-peritoneal cavity. Whilst the parietes of the body are still unclosed, this common pleuro-peritoneal cavity is continuous with the space between the amnion and chorion, as seen in Fig. 85, F. The embryo, which at first seems to be a mere streak, extends longitudinally and laterally. As it grows forward the cephalic end becomes remarkably curved on itself (cephalic flexure), and a smaller but distinct flexure takes place at its hinder end (caudal flexure). At the same time the sides of the embryo grow and curve toward each other; so that the embryo is aptly compared to a canoe turned over (Fig. 89). In consequence of this incurving of the embryo, both in an antero-posterior and a lateral direction, the original ovum, with the three layers derived from its cleavage to form the vesicular blastodermic membrane, is converted into an hourglass shape with two unequal globes. The smaller globe is formed by the part of the blastodermic membrane (area germinativa), which has already undergone certain changes in the formation of the embryo, and constitutes the part which has been compared to a canoe. The larger globe is called the *yolk-sac* or *umbilical vesicle*, and is formed by the rest of the blastodermic membrane—*i. e.* that part which is not concerned in the formation of the area germinativa. The two freely communicate through the constriction which is the site of the future umbilicus, and through

FIG. 89.

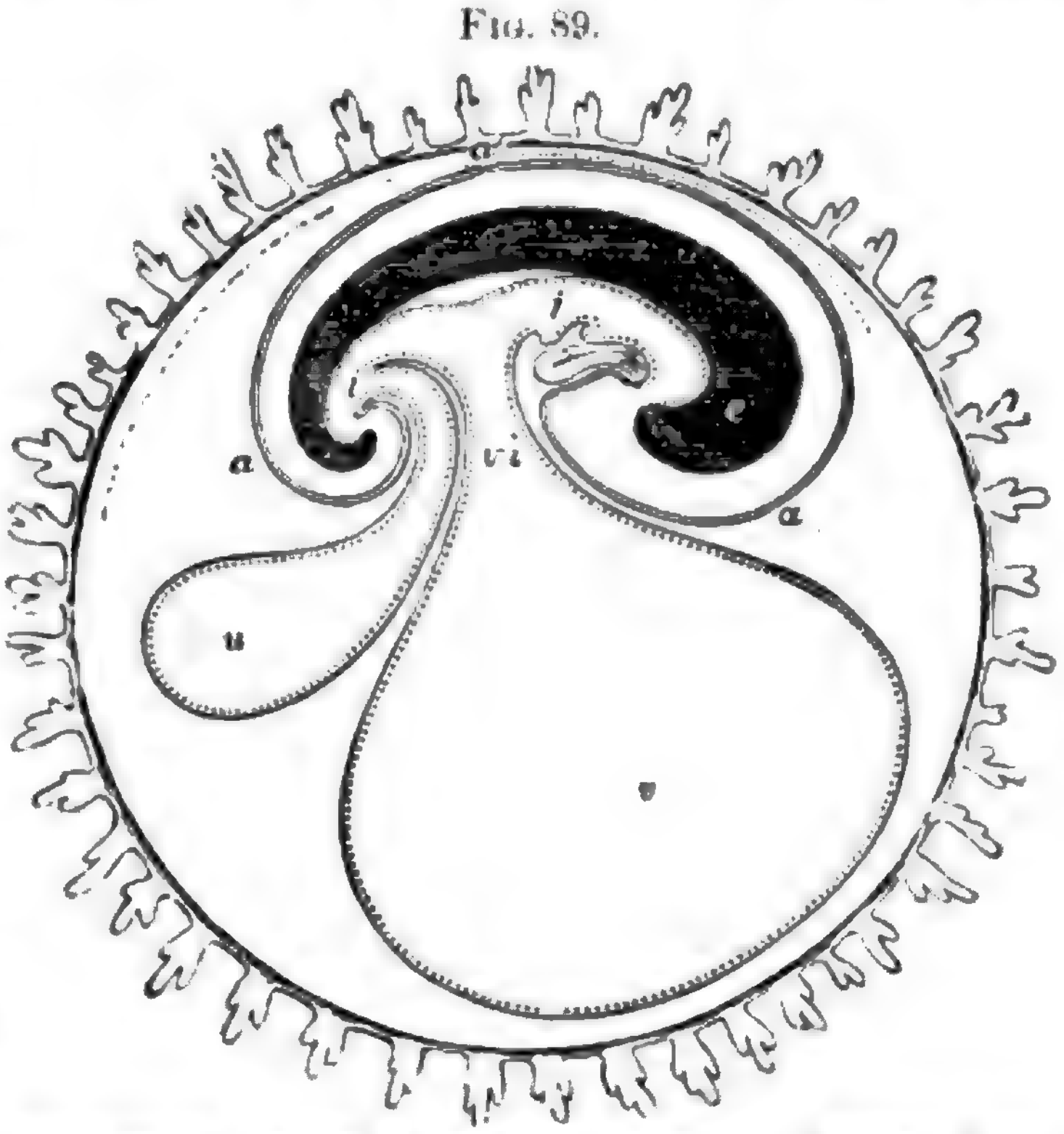

Diagrammatic Section through the Ovum of a Mammal in the Long Axis of the Embryo: *e*, the cranio-vertebral axis: *i*, *i*, the cephalic and caudal portions of the primitive alimentary canal; *a*, the amnion; *a'*, the point of reflection into the false amnion; *v*, yolk-sac, communicating with the middle part of the intestine by *vi*, the vitello-intestinal duct; *u*, the allantois. The ovum is surrounded externally by the villous chorion.

FIG. 90.

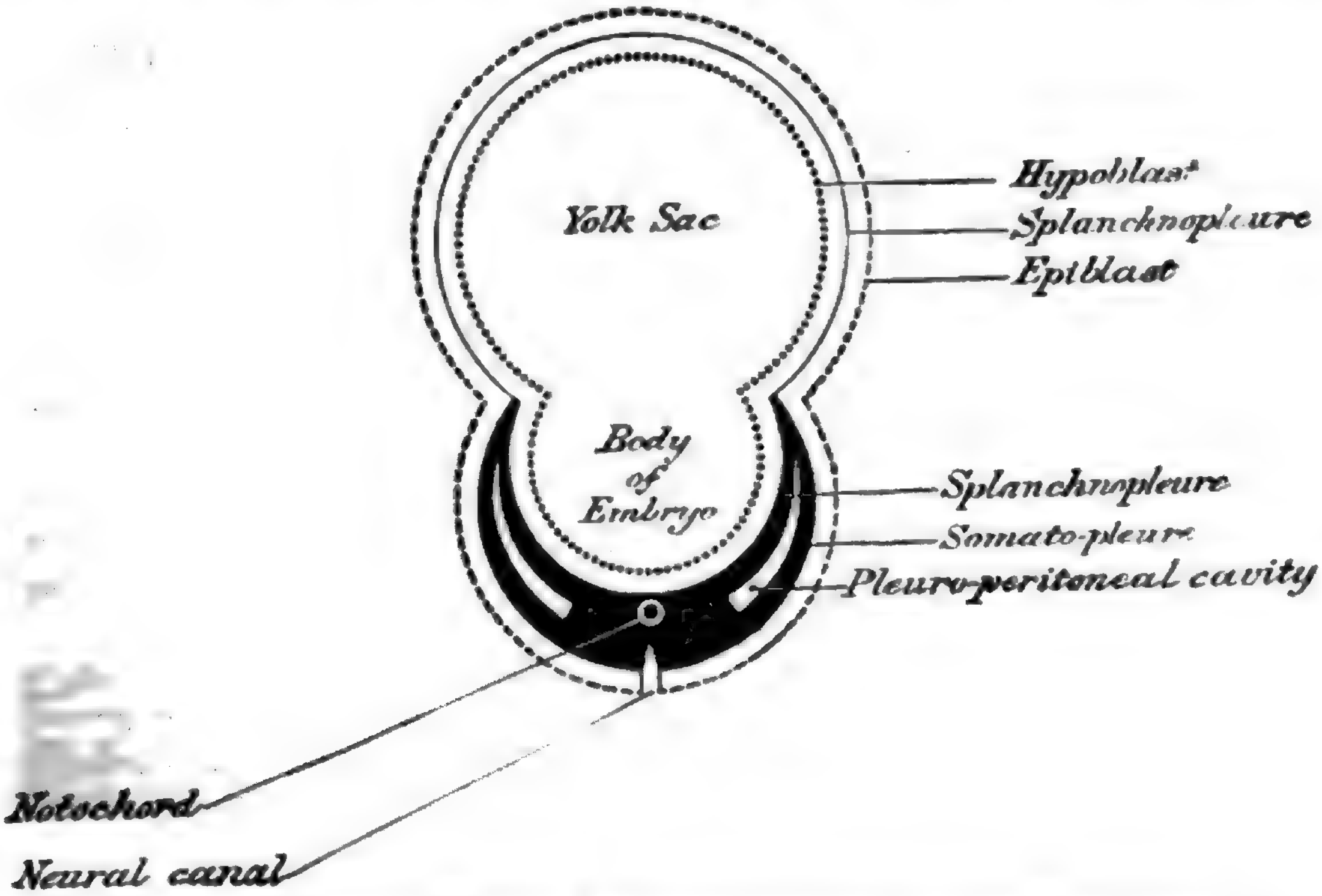

Diagrammatic Section of Embryo, showing the formation of the umbilical vesicle.

this constriction the internal layer of the blastodermic membrane (the hypoblast) and the innermost of the two layers into which, as has been already stated, the mesoblast divides—viz. the splanchnopleure—pass out, the incurving have only involved the somato-pleural layer of the mesoblast and the epiblast (Fig. 90). The umbilical vesicle is, therefore, at first a mere part of the general cavity of the blastodermic vesicle, partly enclosed by the embryo; but as the latter grows round on all sides toward the umbilical aperture, the umbilical vesicle becomes distinguished into two portions. One lies inside the embryo, and eventually forms a part of the intestinal cavity (out of which also, as will hereafter be seen, the bladder is developed). The other lies external to the embryo, and remains, therefore, [for a time] a part of what is, in a more restricted sense, the ovum. The two parts are almost separated from each other by the meeting of the abdominal walls of the embryo at the umbilicus, through which they still communicate by a passage, the *omphalo-mesenteric duct*, the destination of which will be pointed out presently. The extra-embryonic portion is of small importance and very temporary duration in the human subject. It is for the purpose of supplying nutrition to the embryo during the very earliest period, before it can obtain it from the uterine sinuses of the mother. In the oviparous animals, however, where no supply of nutrition can be obtained from the mother, since the egg is entirely separated from her, the yolk-sac is large and of great importance, as it supplies nutrition to the chick during the whole of fœtation. Vessels developed in the middle blastodermic layer soon cover the umbilical vesicle, forming the *vascular area*, the chief vessels of which are the *omphalo-mesenteric*, two in number (Fig. 91). The vessels of this area appear to

Fig. 91.

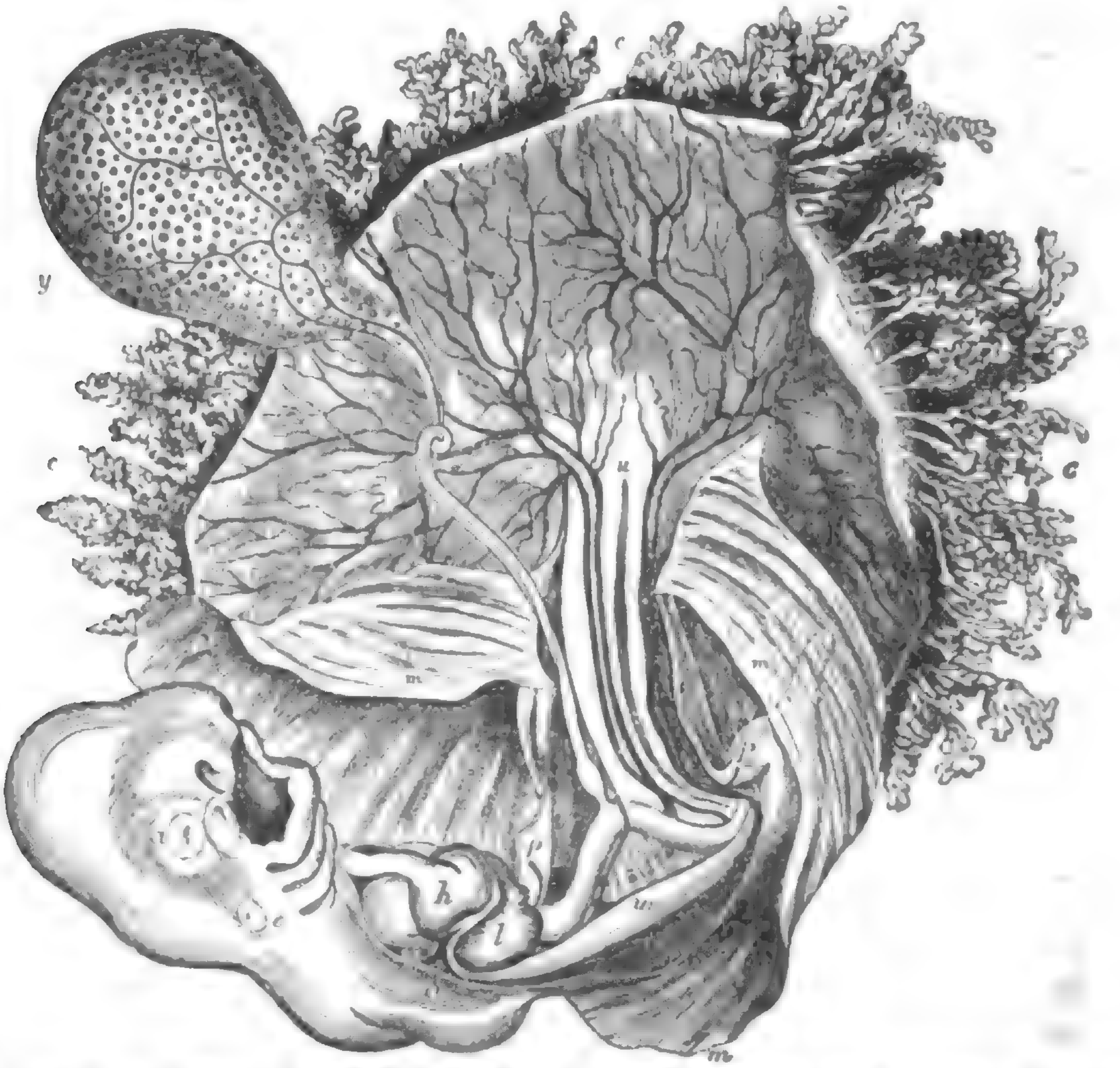

Magnified View of the Human Embryo of Four Weeks, with the membranes opened (from Leishman, after Coste): *y*, the umbilical vesicle with the omphalo-mesenteric vessels, *v*, and its long tubular attachment to the intestine; *c*, the villi of the chorion; *m*, the amnion opened; *u*, cul-de-sac of the allantois, and on each side of this the umbilical vessels passing out to the chorion; *a*, in the embryo, the eye; *e*, the ear-vesicle; *h*, the heart; *l*, the liver; *o*, the upper, *p*, the lower limb; *w*, Wolffian body, by the side of which are the mesentery and intestine. The Wolffian duct and tubes are not represented.

absorb the fluid of the umbilical vesicle, which as the fluid is absorbed dries up and has no further function. The activity of the umbilical vesicle ceases about the fifth or sixth week, at the same time that the allantois, which is the great bond of vascular connection between the embryo and the uterine tissues, is formed. In fact, the umbilical vesicle provides for the nutrition of the fœtus from the ovum itself, while the allantois is the channel whereby it is nourished from the uterine tissues. The umbilical vesicle, containing fluid, remains visible, however, up to the fourth or fifth month, with its pedicle and the omphalo-mesenteric vessels. The latter vessels become atrophied as the functional activity of the body with which they are connected ceases.

So far we have traced (1) the segmentation or cleavage of the yolk into a number of nucleated cells—"vitelline spheres;" (2) the accumulation of fluid within the ovum, and the arrangement of the vitelline spheres around the fluid on the internal surface of the vitelline membrane, forming a second membrane, the "blastodermic membrane;" (3) the separation of the blastodermic membrane into three layers, named, from within outward, the "hypoblast," the "mesoblast," and the "epiblast;" (4) the formation of an elongated, oval-shaped disk called the "area germinativa;" (5) the appearance in the centre of the area germinativa of a delicate line or furrow, running longitudinally and called the "primitive trace;" (6) the formation of a distinct groove in the situation of this primitive trace, caused by the heaping-up of the cells on either side of it, so as to form two longitudinal ridges called the "laminæ dorsales;" (7) the increase and incurvation of these laminæ dorsales until they meet behind, enclosing a canal lined by epiblast: the canal is the neural canal, and from the epiblast which lines it the nervous centres are developed; (8) the formation, in the mesoblast immediately under this canal, of a continuous rod-shaped body, the "chorda dorsalis" or "notochord;" (9) the formation, also from the mesoblast, on either side of the notochord, of a longitudinal column divided into a number of square segments, the "*protovertebræ;*" (10) the splitting of the mesoblast, external to the protovertebræ, into two layers—the outer, called the "somatopleure," lined externally by the epiblast; the inner, called the "splanchnopleure," lined internally by the hypoblast, a space being left between the two, which forms the "pleuro-peritoneal cavity;" (11) the curving of the embryo on itself, both longitudinally and laterally, so as to be comparable to a canoe, the walls being formed of all three layers of the blastodermic membrane and the well of the canoe—that is, the body-cavity of the embryo opening into the cavity of the yolk-sac; (12) a portion of the yolk-sac now lying in the body-cavity of the embryo, and a portion outside it, the two communicating by a duct, the "omphalo-mesenteric" duct. The portion of the yolk-sac external to the body-cavity is now termed the umbilical vesicle, and provides nutrition to the embryo until such time as the allantois is formed, vessels developed from the middle blastodermic layer ramifying over it and gradually absorbing its contents.[1]

The next step toward a clear understanding of the development of the embryo is to have a proper conception of the manner in which the membranes enveloping the fœtus are formed.

The **membranes** investing the fœtus are the amnion, the chorion, and the decidua. The two former are developed from fœtal structures, and are proper to the fœtus; the latter is formed in the uterus, and is derived from the maternal structures.

The Amnion.—The amnion is the membrane which immediately surrounds the embryo. It is of small size at first, but increases considerably toward the middle of pregnancy, as the fœtus acquires the power of independent movement. It exists only in reptiles, birds, and mammals, which are hence called "Amniota," but is absent in amphibia and fishes. It is formed thus: At or near the extremities of the incurved fœtus—that is to say, at the point of constriction of the blastodermic membrane, where the portion which has undergone changes to form the body of the

---

[[1] It is very doubtful if any considerable amount of nutriment is supplied to the embryo from the yolk sac at any time.]

embryo joins the part devoted to the formation of the umbilical vesicle—an inflection of the epiblast and outer layer of the mesoblast, which have become separated from the inner layer of the mesoblast and hypoblast by the formation of the pleuro-peritoneal cavity, takes place (Fig. 85, D 7). These inflections or backward folds commence first at the cephalic extremity, and subsequently at the caudal end and sides, and deepen more and more by growing up over the back of the embryo, until they, gradually approaching, meet one another (Fig. 85, E 7). After they come in contact they fuse together, and the septum between them disappears; so that the inner layer of the cephalic fold becomes continuous with the inner layer of the caudal fold, and the outer with the outer (Fig. 85, F 7′). Thus we have two membranes, one formed by the inner layer of the fold—the *true amnion*—which encloses a space over the back of the embryo—the *amniotic cavity* (Fig. 85, F and G, *a*)—containing a clear fluid, the *liquor amnii.*[1] The other, the outer layer of the fold—the *false amnion*—lines the internal surface of the original vitelline membrane. Between the two is an interval, which of course communicates with the pleuro-peritoneal cavity (Fig. 89). The true amnion—or, as it is usually called, the amnion—is formed of two layers, derived respectively from the epiblast and from the parietal layer of the mesoblast. The one from the epiblast consists of nucleated cells; the other, from the mesoblast, has a fibrous and, according to some embryologists, a muscular structure; at all events, it possesses the power of rhythmic contraction during life. In some animals this layer is vascular.

The amnion is at first in close contact with the surface of the body of the embryo, but about the fourth or fifth week fluid begins to accumulate, and thus separates the two. The quantity steadily increases up to about the sixth month of pregnancy, after which it diminishes somewhat. The use of the liquor amnii is believed to be chiefly to allow of the movements of the fœtus in the later stages of pregnancy, though it no doubt serves other purposes also. It contains about 1 per cent. of solid matter, chiefly albumen, with traces of urea, the latter probably derived from the urinary secretion of the fœtus.

The Chorion.—The chorion is rather a complex membrane, made up essentially of two parts: first, of the membranes of the ovum external to the pleuro-peritoneal cavity—that is to say, of the vitelline membrane and false amnion; and, secondly, of a diverticulum of the splanchnopleure [and hypoblast pushed out into] the pleuro-peritoneal cavity. This diverticulum is called the *allantois.*

1. *The portion of the chorion which is formed from the membranes of the ovum external to the pleuro-peritoneal cavity.* We have seen that in the formation of the amnion we had two layers formed out of a reduplication of the epiblast and outer layer of the mesoblast: one—the *true* amnion—which surrounds the embryo and encloses a cavity between it and the embryo—the *amniotic cavity;* and secondly, the *false* amnion, which lies in apposition with the internal surface of the vitelline membrane, and is continuous at its periphery with the original epiblast and somatopleural layer of the mesoblast which did not enter into the formation of the area germinativa; and that between these two layers there is a space (which must not be confounded with the amniotic cavity) which communicates with the pleuro-peritoneal space, and, according to Dalton, contains a semifluid, gelatinous material. The external part of the chorion is formed out of the vitelline membrane with the false amnion, and its peripheral continuation with the external layers of the blastoderm; but the exact share which the three layers take in its formation is at present uncertain. By some embryologists it is believed that the vitelline membrane during the rapid growth of the ovum becomes attenuated, and finally lost; by others it is thought that it combines with the other layers to form the chorion. But, whichever is true, at a very early period of gestation cellular processes or fringes grow outward

---

[1] The student should be careful not to confound this cavity with that formed between the true and false amnion, which communicates with the pleuro-peritoneal cavity of the embryo. This latter space ought with more propriety to be called the "amniotic cavity," since it is contained between the layers of the amnion; whereas the so-called amniotic cavity is not really between the layers of the amnion at all, but between the inner layer of the amnion and the body of the embryo.

from the external surface of the vitelline membrane, or, if this has disappeared, from the outer layer of the blastoderm, which have been likened by Dalton to tufts of sea-weed. They are at first destitute of vessels and are of simple cellular structure. These fringes, or villi as they subsequently become, cover at first the whole surface of the chorion; but as development progresses and the placenta by which the extent of the attachment of the ovum to the uterine walls is to be limited is about to be formed, the villi are not further developed over the rest of the chorion, but are confined to that part only which is to form the fœtal portion of the placenta. They may, however, be recognized all over the chorion as abortive processes during the whole of fœtal gestation.

2. **The Allantois.**—This structure is derived from the layers of the blastodermic membrane which are internal to the pleuro-peritoneal space, being formed by the projection of a hollow bud of that part of the hypoblast and splanchnopleure which is contained in the body-cavity of the embryo, and which, as we have before stated, is intended for the formation of the intestinal canal (Fig. 89, *u*).[1] It extends into and through the pleuro-peritoneal space, into the cavity between the true and false amnion, until it meets the latter, over the internal surface of which it spreads. In this diverticulum two arteries and two veins (the allantoic vessels) are developed. The arteries are in the first instance branches of the two primary divisions of the abdominal aorta, but subsequently, when the two aortas coalesce, they become branches of the hypogastric arteries. The veins join the veins of the yolk-sac and form the umbilical veins. When the allantois meets the chorion, branches from these allantoic vessels permeate the cellular tufts or fringes previously described as growing from the outer surface of the false amnion, and convert them into vascular villi, which eventually form the fœtal portion of the placenta[2] (Fig. 91, *c*). The allantois is the chief agent of the early circulation—*i. e.* the duct or tract along which the vessels extend which convey the blood of the embryo to the fœtal chorion, where it is exposed to the influence of the maternal blood circulating in the decidua or uterine portion of the placenta, from which it imbibes the materials of nutrition, and to which it gives up effete materials, the removal of which is necessary for its purification. In some animals the allantois is a hollow projection, and is usually styled the *allantoic vesicle*; but in most mammals, and especially in man, the external or mesoblastic element undergoes great development, while the internal or hypoblastic element undergoes little increase beyond the body of the embryo, so that it is very doubtful whether any cavity exists in the allantois beyond the limits of the umbilicus, or whether it does not rather consist of a solid mass of material derived from the mesoblastic tissue.[3] A portion of the allantoic vesicle *within* the body-cavity is eventually destined to form the bladder, while the remainder forms an impervious cord, the *urachus*, stretching from the summit of the bladder to the umbilicus. The part external to the fœtus forms the umbilical cord, by which the fœtus is connected with the villi of the chorion, which eventually form the fœtal portion of the placenta.

The Decidua.—The growth of the chorion and placenta can only be understood by tracing the formation of the decidua.

The decidua (Figs. 86, 92) is formed from the mucous membrane of the uterus. Even before the arrival of the fecundated ovum in the uterus the mucous membrane of the latter is vascular and tumid, and when the ovum has reached the uterus it becomes imbedded in the folds of the mucous membrane, which grow up around it, and finally completely encircle it, so as to cover it in entirely and exclude it from the uterine cavity. Thus two portions of the uterine mucous membrane (decidua) are formed—viz. that which coats the muscular wall of the uterus, *decidua vera*, and that which is reflected over the ovum, *decidua reflexa*. The decidua vera at the os internum and at the openings of the Fallopian tubes is continuous with the lining membrane of these canals, the thickening of the original mucous membrane of the uterus which converts it into decidua abruptly ceasing at these points. The neck of the uterus after conception is closed by a plug of mucus. The decidua vera is perforated by the openings formed by the enlarged uterine glands, which become much hypertrophied and developed into tortuous tubes. It contains at a later period numerous arteries and venous channels continuous with the uterine sinuses, and it is from it that the uterine part of the placenta is developed. The portion of the decidua vera which takes part in the formation of the placenta is called the *decidua serotina* (Fig. 92, *ds*).

---

[1] [I would prefer to state this as follows: This structure is developed as a hollow ventral outgrowth of the hinder portion of the primitive intestine of the embryo; its walls consist of the hypoblastic and splanchno-pleural layers (Fig. 89, *u*).]

[2] In some animals, some of the vessels of the villi of the chorion are derived from the yolk-sac; that is, the omphalo-mesenteric vessels.

[3] Indeed, it would appear, from the researches of His, that in the human embryo not only is the allantois formed unusually early, as is admitted by all, but in an altogether exceptional manner, not consisting of an outgrowth from the portion of the splanchnopleure engaged in the formation of the alimentary canal, but being present from a very early period as a stalk connecting the posterior extremity of the embryo with the chorion.

[Fig. 92.

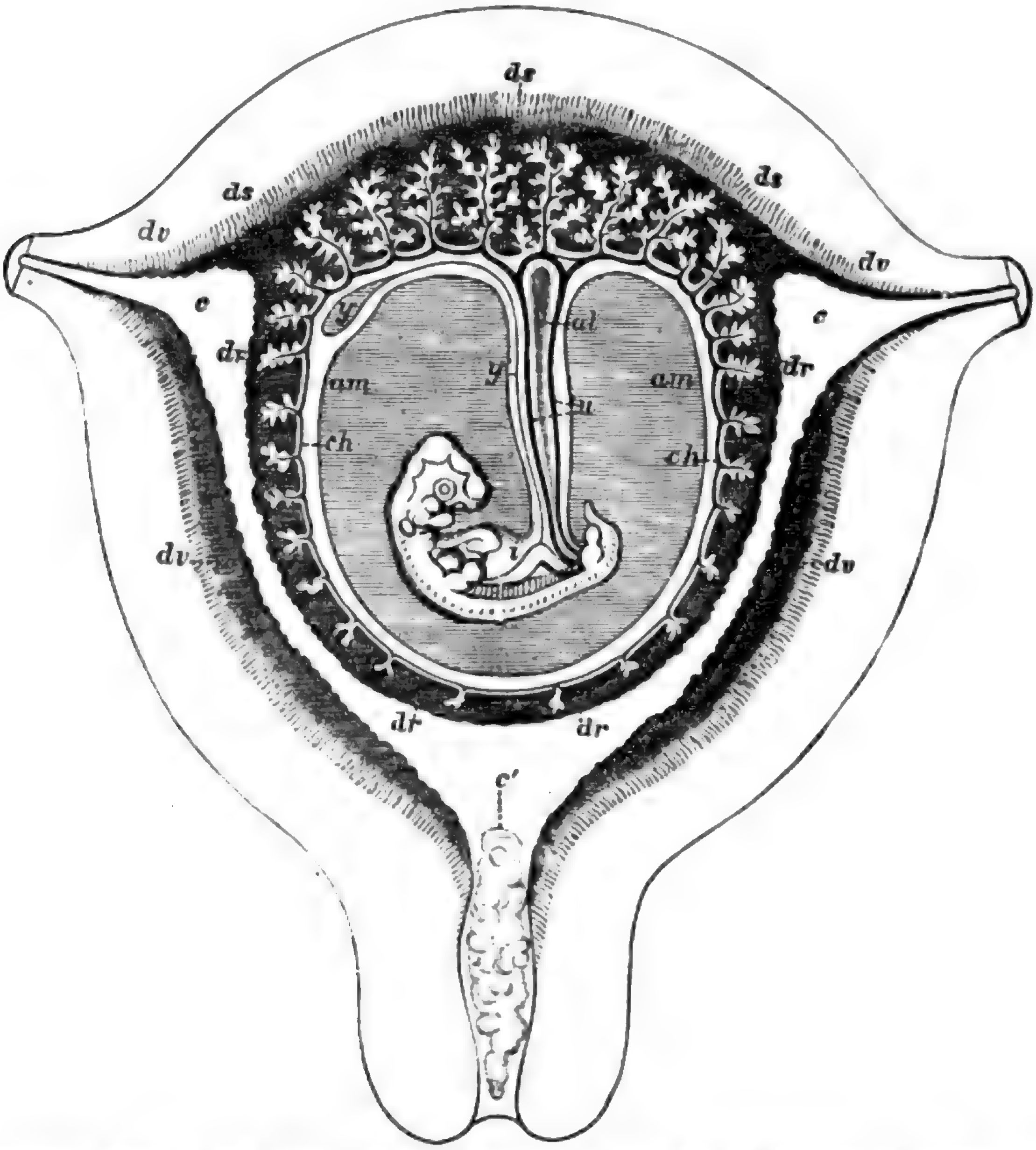

Diagrammatic Section of the Human Uterus, with Embryo *in situ*, showing Relations of Placenta, etc.: *al*, allantoic stalk; *am*, true amnion: the part shaded horizontally, between the amnion and the embryo, is the amnionic cavity; *c*, cavity of uterus; *c'*, plug of mucus in cervix uteri; *ch*, chorion; *dr*, decidua reflexa; *ds*, decidua serotina; *dv*, decidua vera; *i*, intestine of embryo; *u*, umbilical or allantoic arteries; *y*, yolk-sac; *y'*, yolk-stalk (Longet).]

The decidua reflexa (Fig. 92, *dr*) is shaggy on its outer aspect, but smooth within. The vessels which it contains at first disappear after about the third month. About the fifth or sixth month the space between the two layers of the decidua disappears, and toward the end of pregnancy the decidua reflexa is transformed into a thin yellowish membrane which constitutes the external envelope of the ovum.

Much additional interest has been given to the physiology of the decidua by the fact, which seems to be now established by the researches of Dr. John Williams, that every discharge of an ovum, whether impregnated or not, is, as a rule, accompanied by the formation of a decidua, and that the essence of menstruation consists in the separation of a decidual layer of the mucous membrane from the uterus; while in the case of pregnancy there is no exfoliation of the membrane, but, on the contrary, it undergoes further development in the manner described above.

The **Placenta** is the organ by which the connection between the fœtus and mother is maintained. It therefore subserves the purposes both of circulation and respiration. It is formed of two parts, as already shown—viz. the maternal portion, which is developed out of the decidua vera (serotina), and the fœtal portion, formed out of the villi of the chorion. Its shape in the human subject is that of a disk, one side of which adheres to the uterine wall, while the other is covered by the amnion. The villi of the chorion (or uterine placenta) gradually enlarge, forming large projections—*cotyledons*—which each contain the ramifications of vessels communicating with the umbilical (allantoic) arteries and veins of the fœtus. These vascular tufts are covered with epithelium, and project into corresponding depressions in the mucous membrane (decidua vera) of the uterine wall. The maternal portion of the placenta consists of a large number of sinuses formed by an enlargement of the vessels of the uterine wall. These bring the uterine blood into close proximity with the villi of the fœtal placenta, which dip into the sinuses. The interchange of fluids necessary for the growth of the fœtus and for the depuration of the blood takes place through the walls of the villi, but there is no direct continuity between the maternal and fœtal vessels. The fœtal vessels form tufts of capillaries, the blood from which is returned by small veins which end in tributaries of the umbilical vein. The maternal arteries open into spaces somewhat after the manner of the arteries of the erectile tissues. These spaces communicate with a plexus of veins which anastomose freely with one another and give rise, at the edge of the placenta, to a venous channel which runs around its whole circumference—the *placental sinus*.

The **Umbilical Cord** appears about the end of the fifth month after pregnancy. It consists of the coils of two arteries (*umbilical*, originally *allantoic*) and a single vein, united together by a gelatinous tissue (jelly of Wharton). There are originally two umbilical veins, but one of these vessels becomes obliterated, as do also the two omphalo-mesenteric arteries and veins and the duct of the umbilical vesicle, all of which are originally contained in the rudimentary cord. The permanent structures of the cord are therefore furnished by the allantois.

In this manner the human embryo eventually becomes surrounded with three membranes: (1) the *amnion*, derived from the outer layer of the mesoblast and the epiblast; (2) the *chorion*, formed most probably by three layers—the allantois (which is derived from the inner layer of the mesoblast and hypoblast), the false amnion, and perhaps the vitelline membrane; and (3) the *decidua*, derived from the mucous membrane of the uterus.

Development of the Embryo Proper.—The further development of the embryo will, perhaps, be better understood if we follow, as briefly as possible, the principal facts relating to the chief parts of which the body consists—viz. the spine, the cranium, the pharyngeal cavity, mouth, etc., the nervous centres, the organs of the senses, the circulatory system, the alimentary canal and its appendages, the organs of respiration, and the genito-urinary organs.[1] The reader is also referred to the chronological table of the development of the fœtus at the end of this section.

Development of the Spine.—We have already traced the first steps in the formation of the spine: (1) The heaping up of two longitudinal ridges from the cells of the epiblast on either side of the primitive streak, so as to form a groove, and the gradual growing together of these ridges (*laminæ dorsales*), so as to convert the

---

[1] The scope of this work only permits the briefest possible reference to these subjects. Those who wish to study the subject of embryology in more detail are referred to Kölliker's *Entwickelungsgeschichte*, to the chapters on the development of the various organs in the ninth edition of *Quain's Anatomy*, or to the works of Prof. Dalton and of Foster and Balfour.

groove into a canal, which is lined by epiblast, and out of which the spinal cord is developed. (2) The formation in front of this groove of a continuous cellular cord enclosed in a structureless sheath, the *notochord* or *chorda dorsalis* (Fig. 93). The notochord extends from the cephalic to the caudal extremity of the embryo, and lies in the place which is afterward occupied by the bodies of the vertebræ. It is probably derived from the mesoblast, but possibly from the hypoblast (Balfour). (3) On either side of the notochord a portion of the mesoblastic layer is divided longitudinally from the rest of the mesoblast, so as to form a thick column, which extends from the cephalic to the caudal extremity of the embryo on either side of the spinal canal and notochord (Fig. 88, A 7); this is the *protovertebral column.* From the greater part of it is derived the vertebral column, a small portion at the upper and outer part being differentiated from it and eventually forming the muscles of the back. (4) This column undergoes a process of transverse segmentation and becomes converted into a number of quadrilateral blocks, the *protovertebral somites* (Fig. 94). The process of segmentation commences in the cervical region, and proceeds successively through the other regions of the spine until a number of segments are formed, which correspond very closely to the number of the permanent vertebræ. (5) These protovertebral somites extend laterally; they grow forward and inward until they meet in front of the notochord in the middle line, which they thus enclose; and backward and inward around the spinal canal, which they also enclose. The notochord and the spinal canal are thus surrounded by a cellular mass derived from the mesoblastic layer, which constitutes the *membranous matrix* of the vertebræ. This structure is covered on its internal surface by hypoblast, and on its outer by epiblast, and presents the transverse segmentation already described (p. 106). (6) The next step is the conversion of this primitive membranous matrix into cartilage. This takes place probably about the fourth or fifth week in the human embryo (Kölliker).

FIG. 93.

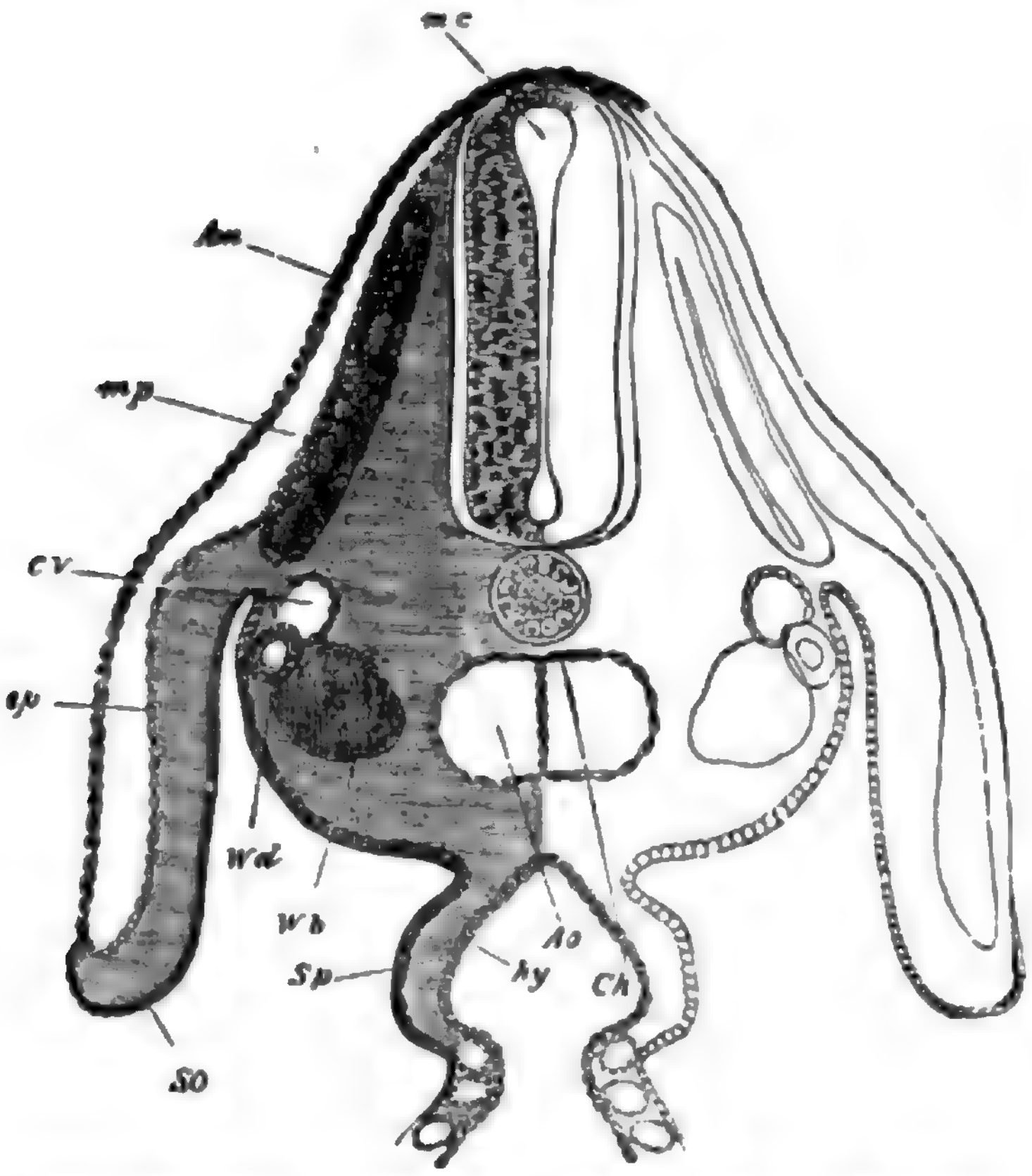

Transverse Section through the Dorsal Region of an Embryo Chick, end of third day (from Foster and Balfour): *Am*, amnion; *mp*, muscle-plate; *cv*, cardinal vein; *Ao*, dorsal aorta at the point where its two roots begin to join; *Ch*, notochord; *Wd*, Wolffian duct; *Wb*, commencement of formation of Wolffian body; *ep*, epiblast; *so*, somatopleure; *hy*, hypoblast: the section passes through the place where the alimentary canal (*hy*) communicates with the yolk-sac.

FIG. 94.

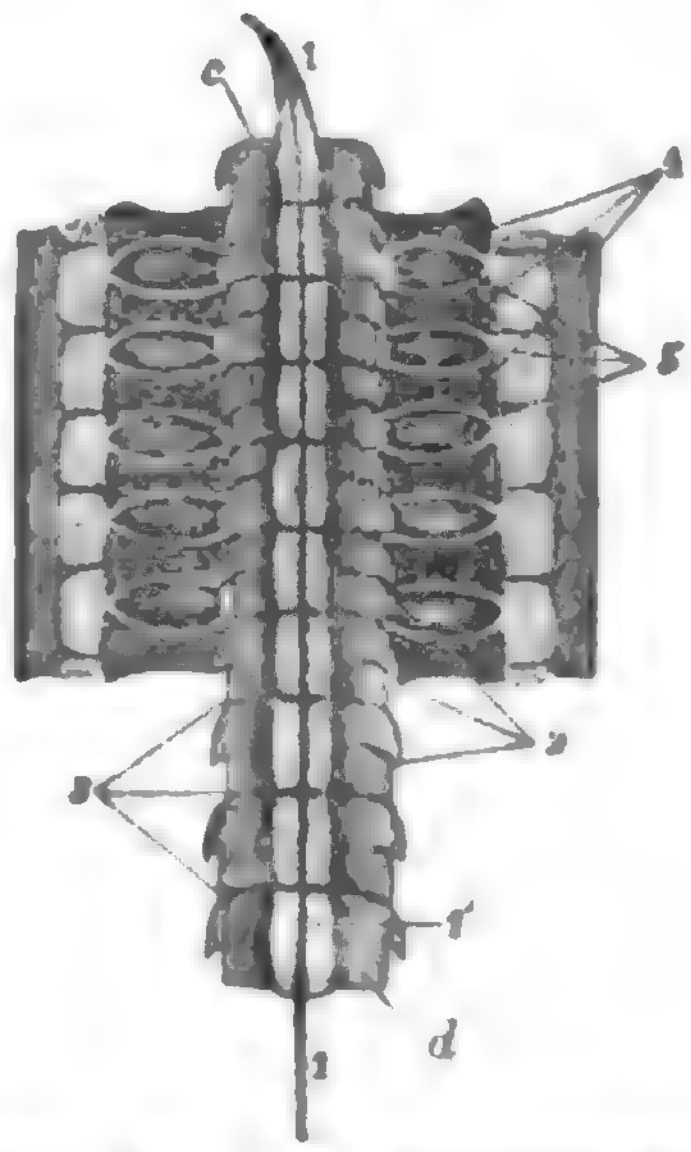

Cervical Part of the Primitive Vertebral Column and adjacent parts of an embryo of the sixth day, showing the division of the primitive vertebral segments (from Kölliker, after Remak): 1, 1, chorda dorsalis in its sheath, pointed at its upper end; 2 points by three lines to the original intervals of the primitive vertebræ; 3, in a similar manner, indicates the places of new division into permanent bodies of vertebræ; *c* indicates the body of the first cervical vertebra: in this and the next the primitive division has disappeared, as also in the two lowest represented—viz. *d* and the one above; in these intermediate the line of division is shown; 4 points in three places to the vertebral arches; and 5, similarly, to three commencing ganglia of the spinal nerves: the dotted segments outside these parts are the muscular plates.

The part of the protovertebral somites which has extended backward to enclose the spinal foramen, and which eventually forms the arches of the vertebræ, simply undergoes a process of chondrification, so that the permanent arches correspond to the primary segments of the protovertebral somites, spaces being left between them for the spinal nerves and ganglia to grow out from the spinal cord. But a somewhat more complex change goes on in the portion of the protovertebral somites which encloses the notochord, and which is destined to form the bodies of the vertebræ. Here each one of the protovertebral segments undergoes a second transverse division through its centre, and in the interval which is left between these secondary segmentations the fibrous structure of the intervertebral disks is formed. The half-segment of the original protovertebral somites on either side of this secondary segmentation joins with the segment above and below and undergoes chondrification, and thus forms the basis of the future body of a vertebra. Each cartilaginous body of a vertebra is formed therefore out of half an original protovertebral plate joined to the half of another plate above or below it, as the case may be. (7) The notochord contained in the centre of this chondrifying mass does not continue to grow, but becomes in the human subject relatively smaller, so as, at last, to form a mere slender thread, except opposite the secondary segmentations; that is to say, corresponding to the intervals between the bodies of the permanent vertebræ. Here it presents thickenings which are supposed by some to form the central pulp of the intervertebral disks.

The further development of the vertebræ and the ossification of this cartilaginous structure are described in the body of the work.

Development of the Cranium in General, and the Face.—We have seen that the first trace of the embryo consists in the formation of a longitudinal fold of the epiblast on either side of a median groove, and that these folds or ridges grow backward and meet in the median line, thus forming a canal. This canal, at the cephalic extremity of the embryo, is dilated and forms a bulbous enlargement. The bulbous enlargement soon expands into three vesicular dilatations, which are known as the three *primary cerebral vesicles*, from which all the different parts of the encephalon are presently to be developed. The most anterior of the three forms the optic thalamus, whilst a hollow projection from it forms the corpus striatum and the cerebral hemispheres; the middle one forms the tubercula quadrigemina; the posterior, the medulla oblongata. The primary cerebral vesicles are at this time, of course, hollow, and their cavities freely communicate with each other at the points of constriction. As the embryo grows the cerebral vesicles become twice bent forward on their own axis (Fig. 95, and Fig. 96, A and B). The upper or posterior curvature is called the cerebral; the lower or anterior, the frontal protuberance.

FIG. 95.

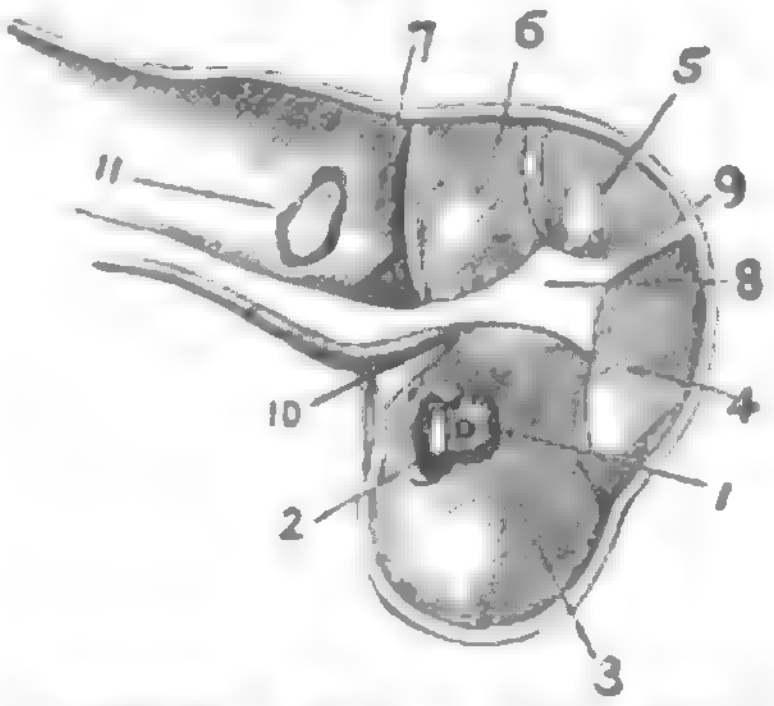

Longitudinal Section of the Head of an Embryo four weeks old, seen from the inside: 1, ocular vesicle; 2, optic nerve flattened out; 3, fore brain; 4, intermediary brain; 5, middle brain; 6, hinder brain; 7, after brain; 8, anterior portion of the tentorium cerebelli; 9, its lateral portion intervening between Nos. 4 and 5; 10, the pharyngeal curve, bent into a cul-de-sac; 11, the auditory vesicle.

Thus, we have a triple cavity (see Fig. 96, A, where the three cavities are marked *c*, *mc*, and *mo*), lined by epiblast and covered by the same structure. Between these two layers of epiblast a layer of mesoblast, derived from the protovertebral plates of the trunk, is prolonged and spreads over the whole surface of the cerebral vesicles. From these structures the cranium and its contents are developed. The external layer of the epiblast forms the superficial epithelium of the scalp. The mesoblastic layer forms the true skin, the blood-vessels, muscles, connective tissue, bones of the skull, and membranes of the brain. The layer of epiblast lining the cavity forms the nervous substance of the encephalon, while the cavity itself constitutes the ventricles.

The upper end of the notochord terminates at its cephalic end in a pointed extremity, which extends as far forward as the situation of the future body of the sphenoid bone, and is there imbedded in a mass of tissue, the "investing mass of

Rathke." This mass, derived from mesoblastic tissue, becomes cartilaginous, and from it is developed the basi-occipital and basi-sphenoid bones; and by lateral expansions from it the occipitals, the greater wings of the sphenoid, and the periotic mass of cartilage surrounding the primary auditory vesicles. From the front of the investing mass of Rathke, which corresponds in position to the future dorsum sellæ, two lateral bars are directed forward, enclosing a space which forms the pituitary fossa, in which the pituitary body is eventually developed. These bars are named the trabeculæ cranii, and extend as far forward as the anterior extremity of the head, where they coalesce with each other. From them the presphenoid and lateral masses of the ethmoid are developed; and from their coalescence a process is prolonged downward to form a portion of the framework of the face, hereafter to be described. From the presphenoids, which are developed from these trabeculæ, a lateral expansion takes place, which forms the orbito-sphenoid or lesser wings of the sphenoid, enclosing the optic foramen.

The portions of the base of the skull above enumerated are formed from cartilage; the remaining parts, comprising the vault of the skull, are of membranous formation.

FIG. 96.

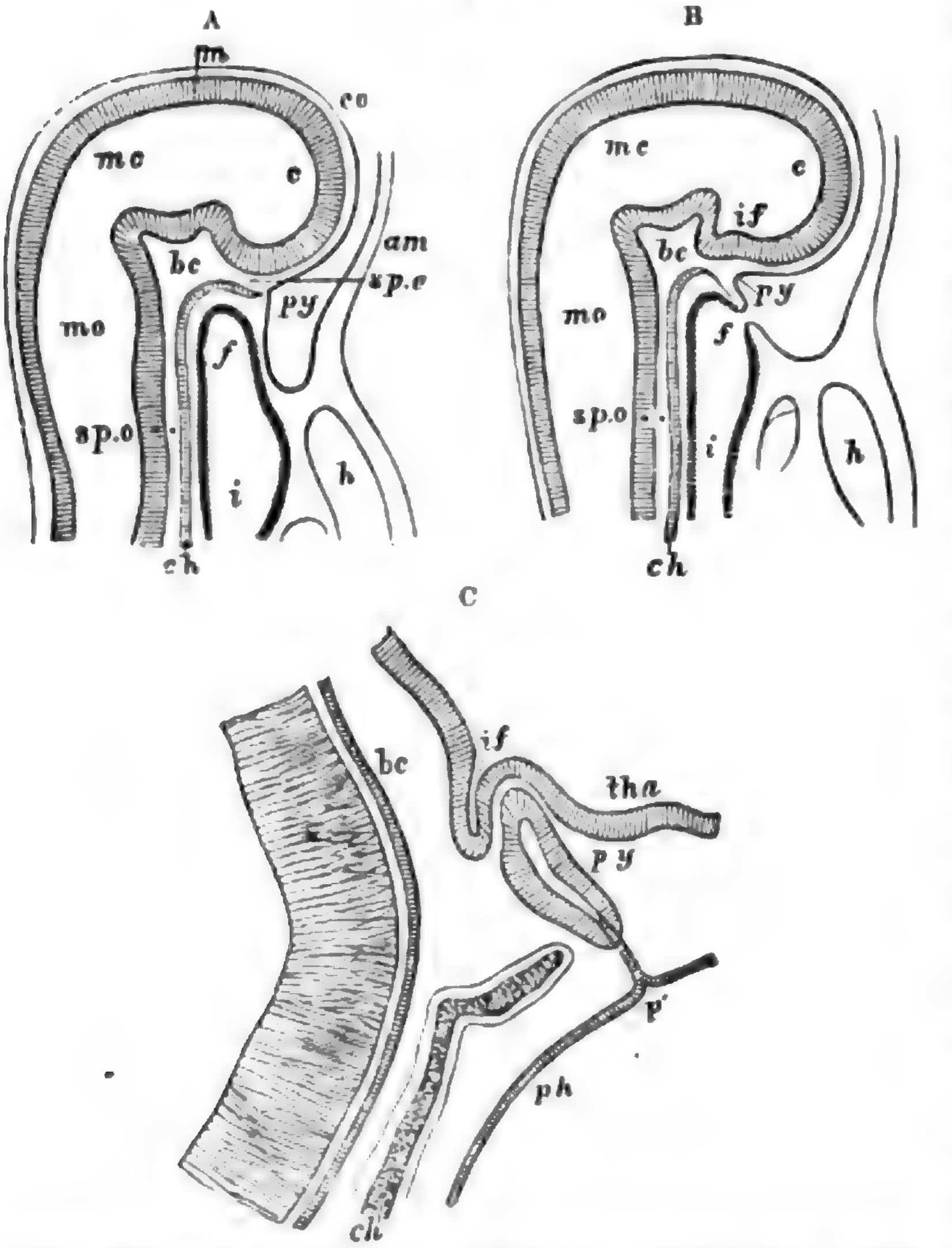

Vertical Section of the Head in Early Embryos of the Rabbit (magnified from Mihalkovics): A, from an embryo of five millimeters long; B, from an embryo of six millimeters long; C, vertical section of the anterior end of the notochord and pituitary body, etc., from an embryo sixteen millimeters long. In A the faucial opening is still closed; in B, it is formed: *c*, anterior cerebral vesicle; *mc*, meso-cerebrum; *mo*, medulla oblongata; *co*, corneous layer; *m*, medullary layer; *if*, infundibulum; *am*, amnion; *spe*, spheno-ethmoidal; *bc*, central (dorsum sellæ), and *spo*, spheno-occipital parts of the basis cranii; *h*, heart; *f*, anterior extremity of primitive alimentary canal and opening (later) of the fauces; *i*, cephalic portion of primitive intestine; *tha*, thalamus; *p'*, closed opening or the involuted part of the pituitary body (*py*); *ch*, notochord; *ph*, pharynx.

The head at first consists simply of a cranial cavity, the face being subsequently developed, in the manner now to be described, by a series of arches with clefts between them (Fig. 97). It is usual in our textbooks to describe the arches as a series of processes which jut out and grow downward, inclining toward each other until they meet in the middle line and thus form a series of inverted arches, whilst the clefts are the spaces left between these pairs of processes. This, however, is scarcely the true description, and leads rather to the false impression that the arches are formed by processes budding out from the embryo, much in the same way as the extremities do, and, like them, are free on every side. What would appear rather to be the case is that the clefts are first formed, and that the arches consist of a thickening of the tissue on either side of the cleft. The arches thus formed may be divided into two sets, according as they are placed in front or behind the buccal cavity or mouth, the former being known as the *præ-oral*, and the latter as the *post-*

oral or *visceral* arches. Four clefts on each side appear laterally in the undifferentiated somato-splanchno-pleural wall of the fore-gut, and between them thickenings occur which ultimately meet and fuse in the middle line, and above are connected with the investing mass. These are the so-called post-oral visceral arches. Differentiation of tissue occurs from above downward, and cartilage is formed in them in connection with the investing mass. The first post-oral arch has no cleft in front of it, but forms a rim in front of the fore-gut. The præ-oral arches are formed in much the same way by local thickening, in which differentiation of tissue and formation of cartilage proceed in a direction forward and downward from the investing mass.

The *præ-oral* or *maxillary arch* unites with the *fronto-nasal* process. The latter consists of three plates, a central single one and two lateral ones. The *central* is called the "mid-frontal" process. It is prolonged downward and forward from the middle of the base of the skull, from the point of coalescence of the two trabeculæ cranii, and from it the septum of the nose is developed. It is free in front and below, but behind it is united with the coalesced portion of the trabeculæ, which therefore probably assists in the formation of the septum nasi, and, in addition, of the prominent part of the future nose. The *lateral* plates of the fronto-nasal process are separated from the central one by a depression or furrow on either side; these furrows form the primary nasal pits or fossæ. The lateral plates project downward parallel to the mid-process for a certain distance, and then, curving inward, unite with it, thus shutting off the nasal fossæ from the rest of the face. The lateral masses of the ethmoid and lachrymal bones are developed in the lateral plates, and by their union with the mid-frontal process they form the intermaxillary bone and the *lunula*, or central part of the upper lip.

Fig. 97.

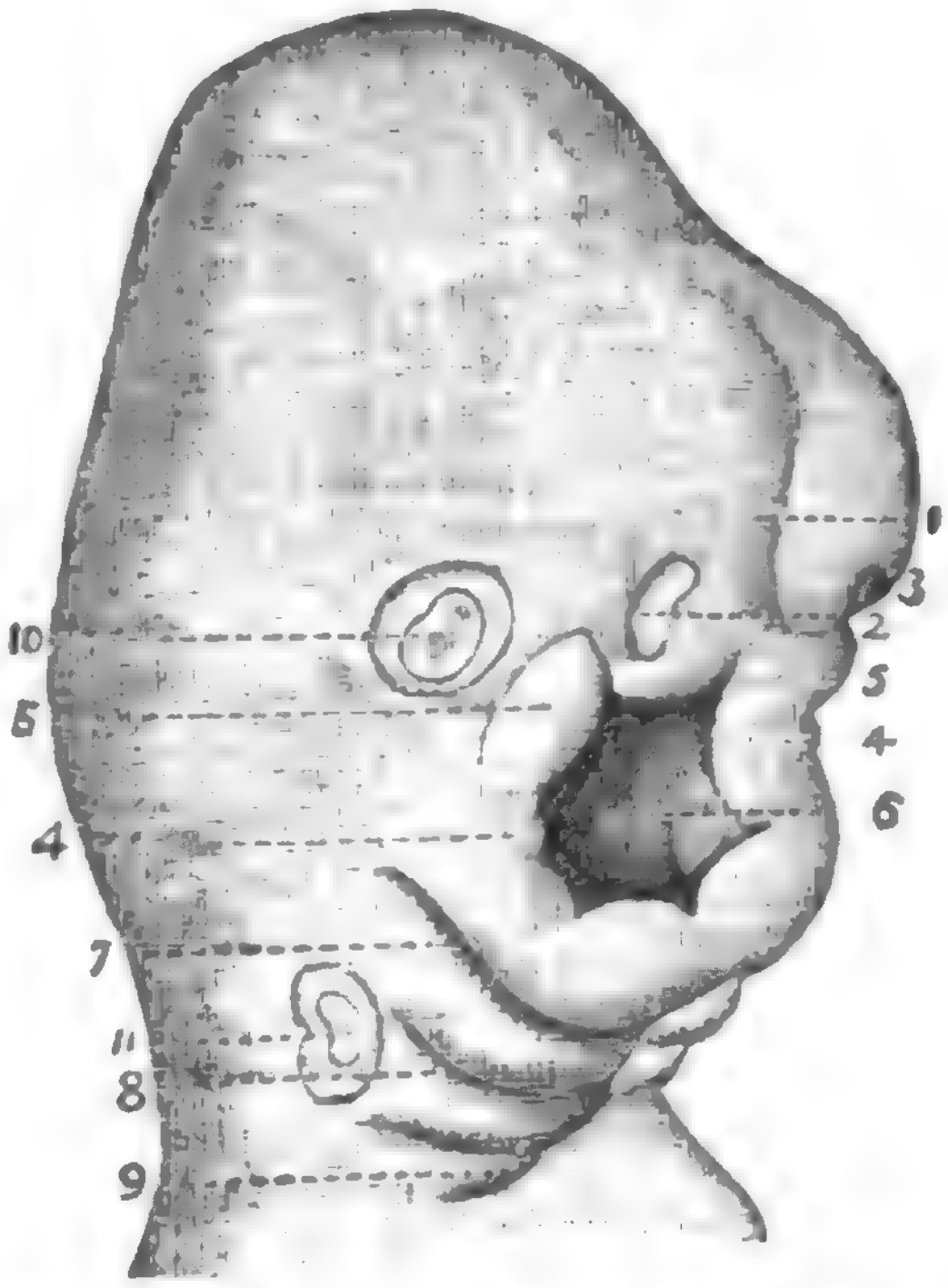

Face of an Embryo of twenty-five to twenty-eight days (magnified 15 times): 1, frontal prominence; 2, 3, right and left olfactory fossæ; 4, inferior maxillary tubercles, united in the middle line; 5, superior maxillary tubercles; 6, mouth or fauces; 7, second pharyngeal arch; 8, third; 9, fourth; 10, primitive ocular vesicle; 11, primitive auditory vesicle.

The *maxillary* processes spring from the base of the skull farther back than the fronto-nasal, and at their origin are closely connected with the first post-oral or visceral arch. They descend for a short distance, forming the outer wall of the orbit, in which the malar bone is developed; they then incline inward, and, meeting the lateral plate of the fronto-nasal process, form the floor of the orbit and shut it off from the rest of the face; then, continuing their course downward and inward, they join the mid-frontal process, and with it complete the alveolar arch and the superior maxillary bone. Finally, palatal processes are formed by an extension of the inner sides of this arch; these coalesce with each other in the median line, thus separating the cavity of the mouth from the nasal fossæ, and completing the palate. In front, however, the palatal processes do not join with the mid-frontal process, but a cleft is left which constitutes the naso-palatine canal.

The *post-oral* arches are five in number in the Amniota, and of these the first only is concerned in the formation of the face proper, for the lower jaw or mandible is developed from it, and hence it is called the *mandibular* arch. The second forms the upper part of the hyoid bone, and is therefore named the *hyoid* arch. The third, in which the remainder of the hyoid bone is formed, and the remaining two, correspond to the arches which in aquatic animals form the gills, but which in the Amniota never do so. They are appropriately named *branchial*, a name which was primarily given to the whole series by Rathke, who first described them.

The deeper part of the first or mandibular arch contains a transitory cartilaginous rod which has long been known as the "cartilage of Meckel," from the posterior end of which the malleus is formed, while its middle portion is converted into the internal lateral ligament of the lower jaw, and its distal end enters into the formation of the symphysis and perhaps of the body of the bone.

Between the mandibular arch and the præ-oral arch the buccal cavity or mouth is formed; this, therefore, is bounded by the præ-oral and post-oral arches, and its walls consist of mesoblastic tissue lined by epiblast. It is at first quite distinct from the upper part of the alimentary canal, which, as we shall hereafter see, is formed by the inner or splanchno-pleural layer of the mesoblast and the hypoblast, the two cavities being separated by all the layers of the blastodermic membrane. A communication between the two is, however, gradually effected by the fusion of the anterior end of the primitive alimentary cavity [with the hinder portion of the epiblastic involution from which the mouth is formed].

The second post-oral arch (*hyoid*) is closely united with the first at its origin. It forms the incus, the stylo-hyoid ligament, and the lesser cornua of the hyoid bone.

The third arch (*thyro-hyoid*) forms the greater cornua and body of the hyoid bone, and supports the rudiment of the thyroid cartilage and the rest of the larynx.

The fourth and fifth arches enter merely into the formation of the soft parts of the neck, and do not give rise to any special organs.

Between each of these visceral arches are clefts, four in number, which run through the tissues of the neck to the cavity of the pharynx: the first persists, though only in a portion of its extent, forming the Eustachian tube, the meatus auditorius, and the tympanic cavity. The other fissures are wholly closed by the sixth week.[1]

Development of the Nervous Centres and the Nerves.—The medullary groove above described (p. 105) presents, about the third week, three dilatations at its upper end, separated by two constrictions, and at its posterior part another dilatation, called the *rhomboidal sinus*. Soon afterward the groove becomes a closed canal (*medullary canal*) and a soft blastema lines it, exhibiting corresponding dilatations. This is the rudiment of the cerebro-spinal axis. As the embryo grows, its cephalic part becomes more curved, and the three dilatations at the anterior end of the primitive cerebro-spinal axis become vesicles distinctly separated from each other (Fig. 95). These are the cerebral vesicles—anterior, middle, and posterior. The anterior cerebral vesicle (situated, at this period, quite below the middle vesicle) is the rudiment of the third ventricle and of the parts surrounding it—viz. the optic thalami and all the parts which form the floor of the third ventricle. The middle vesicle represents the aqueduct of Sylvius, with the corpora quadrigemina. The posterior vesicle is developed into the fourth ventricle, and its walls form the pons Varolii, medulla oblongata, and the parts in the floor of the fourth ventricle.

At an early period in the development of this primitive brain a protrusion takes place from the anterior vesicle, which is at first simple, but soon becomes divided into two parts by an antero-posterior fissure. These expand laterally, and the cerebral hemispheres and corpora striata are developed from them. From the fore part of the posterior cerebral vesicle a similar protrusion takes place, forming the rudiment of the cerebellum. In consequence of these protrusions or outgrowths taking place, the three primary cerebral vesicles are now converted into six permanent rudiments of the brain and medulla oblongata. The anterior part of the original anterior cerebral vesicle (fore-brain, Prosencephalon), now divided into two, constitutes the cerebral hemispheres, corpus callosum, corpora striata, fornix, lateral ventricles, and olfactory bulbs. These parts lie at first quite covered and concealed by those formed from the middle primary vesicle and by the optic thalami, which, with the optic nerves, the third ventricle, and the parts in its floor, are furnished by the posterior portion of the anterior vesicle (inter-brain, Thalamencephalon). By the third month, however, the hemispheres have risen above the optic thalami, and by the sixth month above the cerebellum. Fissures are seen on the surface of the hemispheres at the third month, but all except one disappear. This one persists, and forms the fissure of Sylvius. The permanent fissures for the convolutions do not form till about the seventh or eighth month. The middle cerebral vesicle (mid-brain, Mesencephalon) is at first situated at the summit of the angle shown on Fig. 95. Its smooth surface is soon divided by a median and transverse groove into four tubercles (tubercula quadrigemina), which are gradually covered in by the growth of the cerebral hemispheres. Its cavity diminishes as its walls thicken, and contracts to form the aqueduct of Sylvius. The crura cerebri are also formed from this vesicle. The third primary cerebral vesicle at an early period (between the ninth and twelfth week) consists of the hind-brain, or Epencephalon, forming the cerebellum, pons Varolii, and anterior part of the fourth ventricle; and of the after-brain, or Metencephalon, which forms the medulla oblongata with the rest of the fourth ventricle.

---

[1] The relations of these pharyngeal arches to the cranial nerves are of the greatest interest in a morphological point of view, but are hardly yet quite settled. Prof. Parker has lately described the ossification of the skull as proceeding from five arches—a præ-oral and four pharyngeal or post-oral, the post-oral being the mandibular or inferior maxillary; the hyoid; the thyro-hyoid; and the fourth, which, as above stated, has no remnant in the skeleton. The fifth cranial nerve, the facial, and the glosso-pharyngeal have definite relations to these arches, each dividing so that its anterior and posterior divisions embrace the cleft, or are distributed on the "bars," as Professor Parker calls them, which bound the cleft. Thus the front division of the trigeminus is distributed in front of the buccal cleft on the præ-oral arch, and its posterior division on the first pharyngeal or mandibular; the facial sends its anterior division—represented in the mature condition by the chorda tympani—in front of the Eustachian fissure (the remains of the first cleft) to the mandibular arch, while its descending branches go to the hyoid arch; the glosso-pharyngeal sends its lingual portion to the hyoid arch, while its pharyngeal part is distributed to the thyro-hyoid.

These relations are exceedingly suggestive, and the method of inquiry most fruitful in promise for the higher anatomy, which aims at uniting into one plan all the various forms of ova and the animals developed from them; but as yet these relations are hardly sufficiently established in fact to be made a necessary part of scholastic teaching.

FIG. 98.

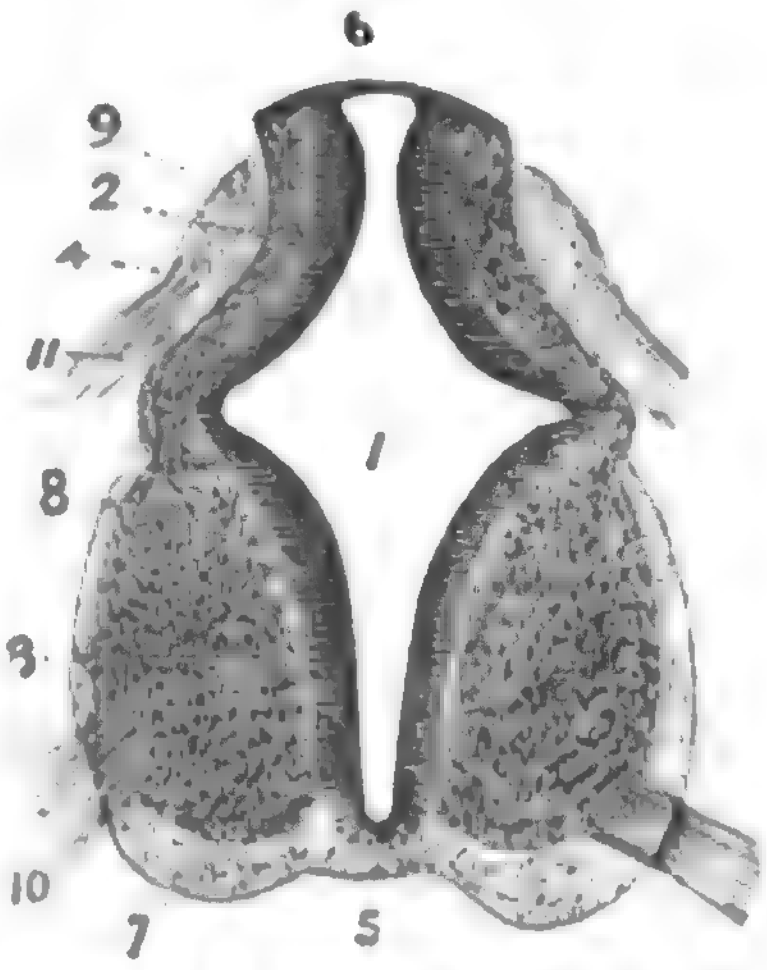

Section of the Medulla in the Cervical Region, at six weeks (magnified 50 diameters): 1, central canal; 2, its epithelium; 3, anterior gray matter; 4, posterior gray matter; 5, anterior commissure; 6, posterior portion of the canal, closed by the epithelium only; 7, anterior column; 8, lateral column; 9, posterior column; 10, anterior roots; 11, posterior roots.

The development of the pituitary body has of late received much attention, and important questions of morphology are connected with it. The description which is now accepted regards the pituitary body as the place of meeting of the epiblast, hypoblast, and mesoblast at the extremity of the notochord; it contains rudiments from each of these sources, or at least from the epiblast and hypoblast, for the mesoblastic elements derived from the chorda dorsalis are now said early to become displaced and to disappear. At the point where the notochord terminates anteriorly the medullary layer of the epiblast, or that from which the central nervous system is developed, is reflected downward to form a little pouch (Fig. 96, c, *if*)—the *infundibulum*. At the same time the hypoblast passes upward from the pharynx, or upper end of the primitive intestine, to form, along with the common layer of the epiblast, a similar pouch, which becomes closed and converted into a glandular body, the anterior part of the pituitary body or *hypophysis* (Fig. 96, c, *py*). The end of the notochord lies at first between the infundibulum and the hypophysis; but it is believed that, as the hypophysis becomes closed off and separated from the pharynx, the two parts of the pituitary body are carried backward and upward from off the end of the notochord, so as to leave the latter stranded, as it were, below the pituitary fossa. Others refer the hypophysal part of the pituitary body to epiblastic elements derived from the buccal part of the epiblast only, and so connect its development, not with the pharynx, but with the mouth and the anterior portion of the skull. The question is an obscure one, but its main interest is to remind the reader that this peculiar appendage to the brain forms, in an early condition of the fœtus, the meeting-point of the portions of the ovum from which the nervous centres, the alimentary canal, the mouth, and the base of the skull are developed; and that its development has some connection, as yet imperfectly understood, with that of these or some of these great sections of the body.[1]

When the medullary groove is first closed the fœtal spinal marrow occupies the whole of it, and presents a large central canal, which gradually contracts in consequence of the thickening and rapid growth of the epiblast around it. This increase in thickness takes place principally at the sides, so that eventually the central canal acquires on section the appearance of a slit. Eventually, the two sides join in the middle, and the original canal is divided into two—an *anterior*, which becomes the central permanent canal, which in after-life is no longer perceptible to the eye, though it is still visible on microscopic section; and a *posterior*, which becomes filled about the ninth week with a septum of connective tissue from the pia mater, and forms the posterior fissure of the cord.

About the fourth month the spinal column begins to grow in length more rapidly than the medulla spinalis, so that the latter no longer occupies the whole canal. The cord is composed at first entirely of uniform-looking cells, which soon separate into two layers, the inner of which forms the epithelium of the central canal, while the outer forms the central gray substance of the cord. The white columns are formed later; their rudiments can be detected about the fourth week, and some embryologists believe that they are developed from the mesoblast.

The cerebral and spinal membranes are, according to Kölliker, a production from the protovertebral disks, and are recognizable about the sixth week. As the fissures separating the segments of the cerebro-spinal axis appear, the membranes extend through them and the pia mater passes into the cerebral ventricles. Bischoff, however, describes the pia mater and arachnoid as developed from the cerebral vesicles, so that they are, according to him, formed in the position which they permanently occupy.

The Nerves.—The nerves are developed as secondary growths in the mesoblast. The spinal nerves are developed as follows: Along either side of the rudimentary spinal cord, close to the point of involution of the epiblast in the median line, a series of cellular swellings, constituting the *neural crest*, appear, corresponding in number to the number of the spinal nerves. They are the rudiments of the posterior roots of the spinal nerves. In some animals the swellings are connected with each other by longitudinal fibres. They at first consist entirely of cells, and, growing, become differentiated into a narrow part or root, a thickened portion, the ganglion, and beyond this a second narrowed portion, which joins the anterior root to form the nerve itself. The root gradually changes its place, and, instead of arising from the spinal cord close to the median line, gradually shifts its position toward the lateral wall more anteriorly. The anterior roots are also outgrowths from the spinal cord. They appear later than the posterior roots, and arise from the lateral wall in the first instance, and therefore do not shift their position. The two roots gradually converge and unite, and from the point of union the nerve grows toward its peripheral termination. The cellular structure of which it is composed disappears, and fibres first make their appearance in the anterior roots. Most of the cranial nerves are developed in the same manner as the posterior roots of the spinal nerves. The first, third, fifth, the facial, the auditory, the glosso-pharyngeal, and the pneumogastric arise from a series of dorso-lateral swellings on the cephalic portion of the embryonic cerebro-spinal nervous system. As in the spinal nerves, the swelling, which shows some traces of differentiation into root, ganglion, and peripheral portion, gradually changes its point of origin, so as eventually to become attached at a much lower level. With regard to the mode of origin of the fourth, sixth, spinal accessory, and hypoglossal we possess no exact knowledge. It must be mentioned, however, that Marshall believes that the abducens and the hypoglossal arise as anterior or motor roots to two of the other cranial nerves, though they do not join with them, as in the spinal nerves, to form a compound nerve.

---

[1] [I would prefer to state this as follows: The epiblast of the back part of the roof of the oral invagination, where a hollow, saccular portion of the oral epiblast is constricted off and fuses with the median infundibular process of the floor of the brain (Fig. 96, c, *if*), is developed into the pituitary body or hypophysis. The fusion of the infundibulum with the involution from the epiblast of the upper and posterior part of the oral cavity leads to the formation of the pituitary body or hypophysis. This, therefore, is entirely of epiblastic origin, and its relations indicate that at one time the oral cavity and the brain may have been more intimately connected than at present.]

The optic nerve arises in a manner entirely different from any of the other cranial nerves.

The sympathetic nerves are developed in connection with the gangliated roots of the spinal and cranial nerves.

Development of the Eye.—The nervous elements and non-vascular parts of the eye are formed from the epiblast, and the vascular portions from the mesoblast; but the method of development is somewhat complicated. The essential portion of the eye—*i. e.* the retina and the parts immediately connected with it—is an outgrowth from the rudimentary brain (primitive ocular vesicle); and this outgrowth is met by an ingrowth from the common epidermic or corneous layer of the epiblast, out of which the lens and the conjunctival and corneal epithelium are developed.

The first appearance of the eye consists in the protrusion or evolution from the medullary wall of the thalamencephalon or inter-brain of a vesicle called the *primitive ocular vesicle.* This is at first an open cavity communicating by a hollow stalk with the general cavity of the cerebral vesicle. As development advances the hollow stalk becomes solid and thus the optic nerve is formed, receiving, however, in a way to be presently explained, mesoblastic elements for the formation of its central artery and connective tissue. As the primitive ocular vesicle is prolonged forward, it meets the epidermic layer of the epiblast, which at the point of contact becomes thickened, and then forms a depression which gradually encroaches on the most prominent part of the primitive ocular vesicle, which in its turn appears to recede before it, so as to become at first depressed and then inverted in the manner indicated by the annexed figure (Fig. 99, A), so that the cavity is finally almost obliterated by the folding back of its anterior half, and the original sac converted into a cup-shaped cavity—the *ocular cup*—in which the involuted epiblastic layer, the rudiment of the lens, is received (Fig. 99, B). This cup-shaped cavity consists therefore of two layers: one, the outer, originally the posterior half of the primitive ocular vesicle, is thin, and eventually forms the pigmental layer of the retina;[1] the other layer, the inner, originally the anterior or more prominent half, which has become folded back and is much thicker, is converted into the nervous layers of the retina. Between the two are the remains of the cavity of the original primary vesicle, which finally becomes obliterated by the union of its two layers. As development proceeds the cup-shaped cavity or ocular cup increases in size, and thus a space is formed between it and the rudimentary lens which it contains; this is the *secondary ocular vesicle*, and in it the vitreous humor is developed (Fig. 99, C). The folding in of the primary optic vesicle to produce the optic cup proceeds from above downward, and gradually surrounds the lens, but leaves an aperture or fissure below—the *choroidal fissure* or *ocular cleft*—through which vascular elements, within the vesicle and derived from the mesoblast, retain their connection with the rest of the mesoblast. The lens is at first a thickening of the epiblast; then a depression or involution takes place, thus forming an open follicle, the margins of which gradually approach each other and coalesce, forming an enclosed cavity of epiblastic cells (Fig. 99). At the point of involution the external layer of epiblast separates from the ball of the lens and passes freely over the surface, so that the lens becomes disconnected from the epiblastic layer from which it was developed, and recedes into the ocular cup, while the cuticular layer covering it is developed into the corneal epithelium. The cells forming the posterior or inner wall of the cavity, which is to form the lens, rapidly increase in size, becoming elongated and developed into fibres, and, filling up the cavity, convert it into a solid body. The cells on the anterior wall undergo no change and retain their cellular character. The secondary ocular vesicle, or space between the lens and the hollow of the ocular cup (Fig. 99, C, 7, and Fig. 100) contains a quantity of mesoblastic tissue continuous through the ocular cleft with the rest of

---

[1] This layer forms functionally part of the choroid, and was formerly described as belonging to this membrane; it is now described as part of the retina, on account of its method of development.

Digitized

the mesoblast, and into this blood-vessels project themselves through the ocular cleft. The iris and ciliary processes are formed from this vascular tissue, and the choroid is developed in the mesoblast surrounding the ocular vesicle; and at the same time a process of the mesoblast is believed to extend down the stalk of the primitive ocular vesicle to form the arteria centralis retinæ with the sheath and connective tissue of the optic nerve. A portion of this tissue also becomes converted into the vitreous humor, and surrounds the lens with a vascular membrane—the *vascular capsule of the lens*—which is connected with the termination of the temporary artery (hyaloid) that forms the continuation of the central artery of the retina through the vitreous chamber. This vascular capsule of the crystalline lens forms the membrana pupillaris (described on a subsequent page), and also attaches the borders of the iris to the capsule of the lens. It disappears about the seventh month.

FIG. 99.

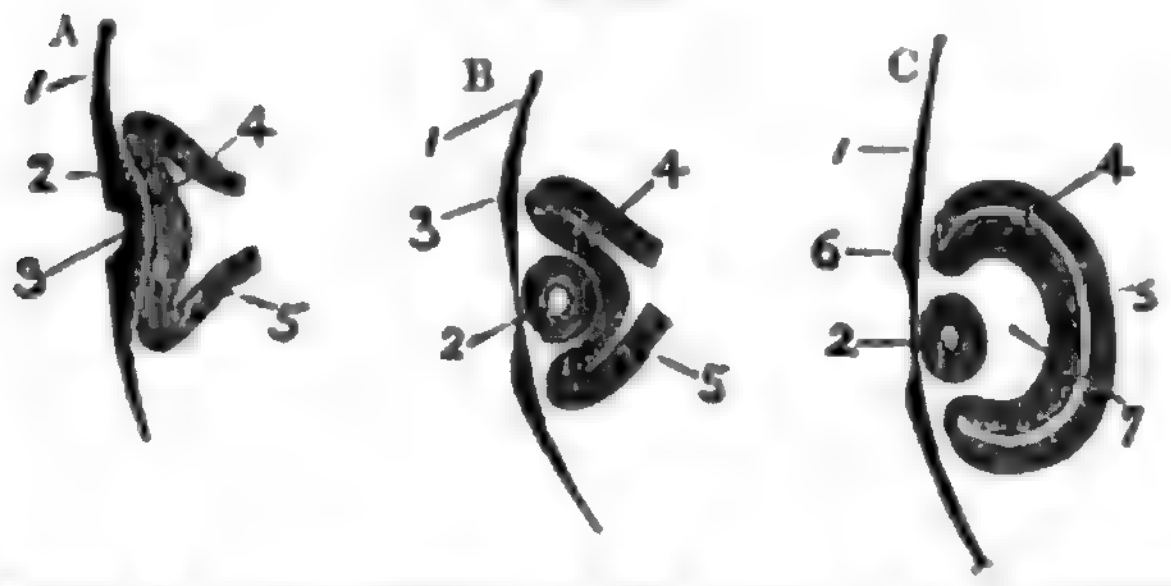

Diagram of Development of the Lens: A, B, C, different stages of development: 1, epidermic layer; 2, thickening of this layer; 3, crystalline depression; 4, primitive ocular vesicle, its anterior part pushed back by the crystalline depression; 5, posterior part of the primitive ocular vesicle, forming the external layer of the secondary ocular vesicle; 6, point of separation between the lens and the epidermic layer; 7, cavity of the secondary ocular vesicle, occupied by the vitreous.

FIG. 100.

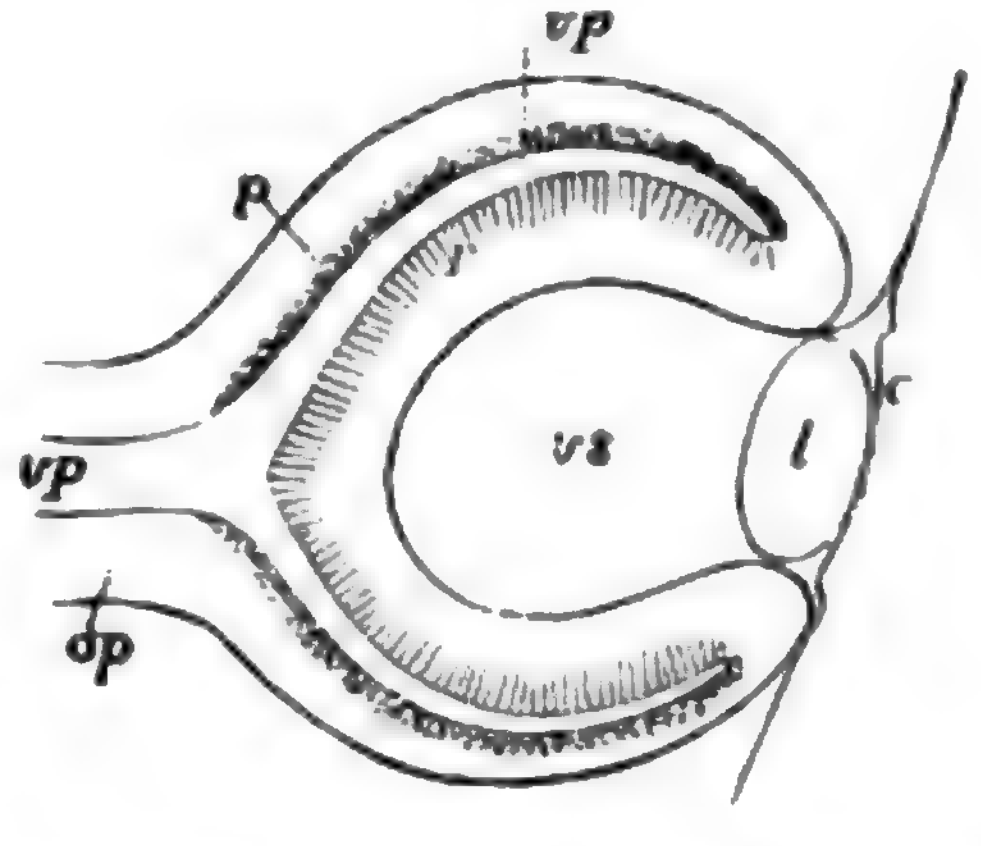

Diagrammatic Sketch of a Vertical Longitudinal Section through the Eyeball of a Human Fœtus of four weeks (after Kolliker—magnified 100 diameters). The section is a little to the side, so as to avoid passing through the ocular cleft: *c*, the cuticle, where it becomes later the cornea; *l*, the lens; *op*, optic nerve formed by the pedicle of the primary optic vesicle; *vp*, primary medullary cavity of the optic vesicle; *p*, the pigment-layer of the outer wall; *r*, the inner wall forming the retina; *vs*, secondary optic vesicle containing the rudiment of the vitreous humor.

The eyelids are formed at the end of the third month as small cutaneous folds, which come together in front of the globe and cornea. This union is broken up and the eyelids separate before the end of fœtal life.

The lachrymal canal appears to result from the non-closure of a fissure which exists between the lateral plates of the fronto-nasal and maxillary processes (p. 117).

Development of the Ear.—The first rudiment of the ear appears shortly after that of the eye, in the form of a thickening of the epiblast on the outside of that part of the third primary cerebral vesicle which eventually forms the medulla oblongata, opposite the dorsal end of the second pharyngeal arch. The thickening is then followed by an involution of the epiblast, which becomes deeper and deeper, sinking toward the base of the skull, and a flask-shaped cavity is formed; by the narrowing of the external aperture the neck of the flask constitutes the *recessus labyrinthi.* The mouth of the flask then becomes closed, and thus a shut sac is formed, the *primitive auditory* or *otic vesicle*, which by its sinking inward comes to be placed between the alisphenoid and basi-occipital matrices. From it the internal ear is formed. The middle ear and the Eustachian tube are developed from the remains of the first branchial cleft, while the pinna and external meatus are developed from outgrowths surrounding the posterior margin of the same cleft. The primary otic vesicle becomes imbedded in a mass of mesoblastic tissue, which rapidly undergoes chondrification and ossification. It, as before stated, is at first flask- or pear-shaped; the neck of the flask, or *recessus labyrinthi*, prolonged backward, forms the aquæductus vestibuli. From it are given off certain prolongations or diverticula from which the various parts of the labyrinth are formed. One from the anterior end gradually elongates, and, forming a tube, bends on itself from left to right and becomes the cochlea. Three others, which appear on the surface of the vesicle, form the semicircular canals. Of these, the one which is to constitute the external semicircular canal does not appear at such an early date as the other two. Subsequently, a constriction takes place in the original vesicle, which, gradually increasing, divides it into two, and from these are formed the utricle and saccule. Finally, the auditory nerve, which has been developed from the "neural crest" in the manner above described (p. 120), pierces the auditory capsule in two main divisions—one for the vestibule, the other for the cochlea. The middle ear and Eustachian tube are the remains of the first pharyngeal or branchial cleft (hyo-mandibular), and are, from an early period, closed by the formation of the membrana tympani, which consists of a layer of epiblast externally, a layer of hypoblast internally, and, between the two, of mesoblastic tissue constituting its fibrous and vascular layer. Projecting into the cleft are the ossicles of the middle ear, the *malleus* being developed from the proximal end of the mandibular (Meckel's) cartilage, the *incus* from the proximal end of the hyoidean cartilage, and the *stapes* as a deposit of cartilaginous cells around the fenestra ovalis.

The external auditory meatus is developed, liked the pinna, from the soft parts on the posterior margin of the first visceral cleft by an outgrowth of the tissues in this situation.

Development of the Nose.—The olfactory fossæ, like the primary auditory vesicles, are formed in the first instance by a thickening and involution of the epiblast which take place at a point below and in front of the ocular vesicle (Fig. 97, 2, 3). The thickening appears at a very early period, about the fourth week. The borders of the involuted portion very soon become prominent in consequence of the development of the mid-frontal and lateral naso-frontal plates above spoken of (p. 117), which are formed on either side of the rudimentary fossæ. As these processes increase, the fossæ deepen and become converted into a deep channel, which eventually forms the upper part of the nasal fossæ—that is, the two superior meatuses, the part to which the olfactory nerves are distributed. At this time they are continuous with the buccal cavity, a portion of which forms the lower part or inferior meatus of the nasal fossæ. For, as the palatine septum is formed, the buccal cavity is divided into two parts, the upper of which forms the lower part of the nasal fossæ, while the remainder forms the permanent mouth.

The soft parts of the nose are formed from the coverings of the frontal projections and of the olfactory fossæ. The nose is perceptible about the end of the second month. The nostrils are at first closed by epithelium, but this disappears about the fifth month.

The olfactory nerve, as above pointed out, is formed from the anterior cerebral vesicle as a secondary vesicle on its under surface, and it lies upon the involuted epiblast, which subsequently forms the nasal fossæ.

Development of the Skin, Glands, and Soft Parts.—The epidermis is produced from the external, the true skin from the middle, blastodermic layer (Fig. 85, 19, 20). About the fifth week the epidermis presents two layers, the deeper one corresponding to the rete mucosum. The subcutaneous fat forms about the fourth month, and the papillæ of the true skin about the sixth. A considerable desquamation of epidermis takes place during fœtal life, and this desquamated epidermis, mixed with a sebaceous secretion, constitutes the *vernix caseosa* with which the skin is smeared during the last three months of fœtal life. The nails are formed at the third month, and begin to project from the epidermis about the sixth. The hairs appear between the third and fourth months in the form of depressions of the deeper layer of the epithelium, which then become inverted by a projection from the papillary layer of the skin. The papillæ grow into the interior of the epithelial layer; and finally, about the fifth month, the fœtal hairs (*lanugo*) appear first on the head and then on the other parts. These hairs drop off after birth and give place to the permanent hairs. The cellular structure of the sudoriferous and sebaceous glands is formed from the epithelial layer, while the connective tissue and blood-vessels are derived from the mesoblast about the fifth or sixth month. The mammary gland is also formed partly from mesoblast—its blood-vessels and connective tissue; and partly from epiblast—its cellular elements. Its first rudiment is seen about the third month, in the form of a small projection inward of epithelial elements, which invade the mesoblast; from this similar tracts of cellular elements radiate; these subsequently give rise to the glandular follicles and ducts. The development of the former, however, remains imperfect, except in the adult female, and especially after pregnancy.

Development of the Limbs.—The upper and lower limbs begin to project, as buds, from the anterior and posterior part of the embryo about the fourth week. These buds are formed as short lateral, longitudinal folds of epiblast, into which mesoblast proliferates, opposite or just external to the point where the mesoblast splits into its parietal and visceral layers, and external to the vertebral somites, of which they may be regarded as lateral extensions. The division of the terminal portion of the bud into fingers and toes is early indicated, and soon a notch or constriction marks the future separation of the hand or foot from the forearm. Next, a similar groove appears at the site of the elbow or knee. The indifferent tissue or blastema, of which the whole projection is at first composed, is differentiated into muscle and cartilage before the appearance of any internal cleft for the joints between the chief bones.

The **muscles** become visible about the seventh or eighth week. The source of their development is the mesoblast. The vertebral muscles are developed from the muscle-plates or protovertebral somites of the embryo (p. 106; see Fig. 85, c, 13), and the muscles of the neck and jaws, as well as those which enclose the cavities of the thorax and abdomen, are also formed from the same source. They do not meet in the middle line of the body till about the fourth month. The cutaneous muscles are developed from the cutaneous portion of the middle blastodermic layer.

Development of the Blood-vascular System.—There are three distinct stages in the development of the circulatory system before it arrives at its complete or adult condition, in accordance with the manner in which nourishment is provided for at different periods of its existence. In the first stage there is the *vitelline circulation*, during which nutriment is extracted from the yolk or contents of the vitelline membrane. In the second stage there is the *placental circulation*, which commences after the formation of the placenta, and during which nutrition is obtained by means of this organ from the blood of the mother. In the third stage there is the complete circulation of the adult, commencing at birth, and during which nutrition is provided for by the organs of the individual itself.

1. The **vitelline circulation** is carried on partly within the body of the embryo, and partly external to it in the vascular area of the umbilical vesicle. It consists of a median tubular heart, from which two vessels (arteries) project anteriorly. These carry the blood to a plexus of capillaries spread over the area vasculosa, and also, though to a less extent, in the body of the embryo. From this plexus the blood is returned by two vessels (veins) which enter the heart posteriorly, and thus a complete circulation is formed.

In these vessels and the heart a fluid (*blood*) is contained, in which rudimentary corpuscles are found. The mode of formation of these elementary parts will have first to be considered.

In Mammalia the heart is formed by a hollowing out or vacuolation of a longitudinal group of mesoblastic cells on either side of the median line in front of the anterior extremity of the rudimentary pharynx, at about the level of the posterior primary cerebral vesicle. This vacuolation takes place in the visceral layer of the mesoblast, and round the cavity thus formed the layer becomes folded or reduplicated, and presents two distinct strata of cells: the inner and thinner layer forms the endocardium, the outer and thicker the muscular wall of the heart. In its very earliest and primitive condition the heart consists, therefore, of a pair of tubes, one on either side of the body. These, however, soon coalesce in the median line, and, fusing together, form a single central tube.[1] Each of the two primary tubes receives posteriorly a large vessel (a vein), and is prolonged anteriorly into a second vessel (an artery). So that after fusion of the heart-tubes has taken place there is, in the primitive vitelline circulation, as above mentioned, a single tubular heart, with two arteries proceeding from it and two veins emptying themselves into it. The earliest *vessels* are also formed in the visceral layer of the mesoblast. The indifferent cells of which this layer is composed become "vacuolated;" *i. e.* they become enlarged, and spaces are formed within them. The nuclei of these enlarged cells multiply; some few of the proliferated nuclei remain imbedded in the walls of the cell, but the greater number of them are free and are converted into blood-corpuscles. The vacuolated cells fuse together, forming cavities, and also give off processes which unite with processes of other cells: these in their turn become also vacuolated, and, communicating with the cavities in the original cells, a network of tubes is produced (Fig. 101). The tubes or primary vessels consist in the first instance of the original protoplasm of the cell, with here and there nuclei derived from the original divided nucleus imbedded in it. Then differentiation of the protoplasm into flattened cells around these nuclei takes place, and constitutes the wall of the capillary or the lining membrane of the larger vessel. In these latter other cells, derived from the mesoblast, apply themselves externally and form the other coats of the vessel at a later period.

---

[1] In most fishes and in amphibia the heart originates as a single median tube.

FIG. 101.

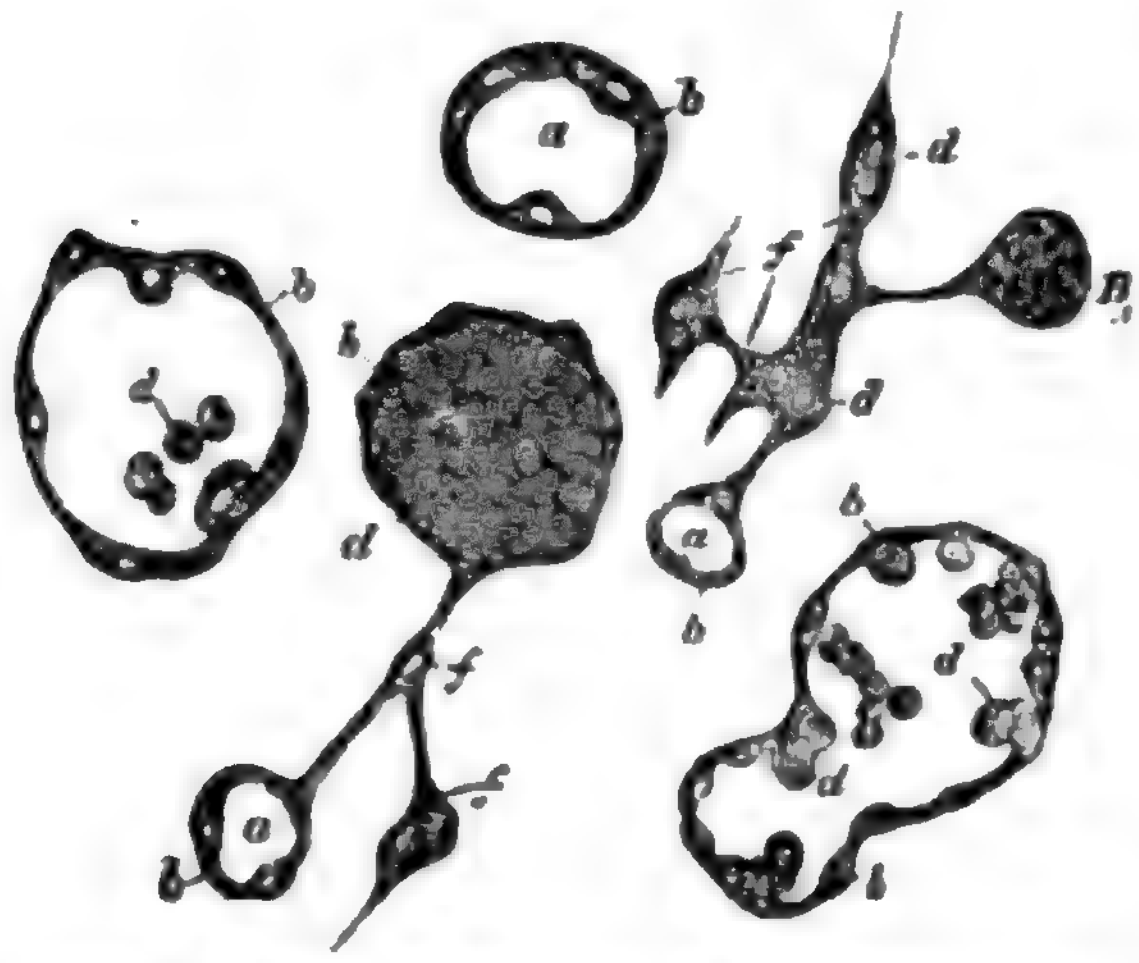

Various Forms of Mother-cells undergoing Development into Blood-vessels, from the middle layer of the chick's blastoderm (Klein): *a*, large mother-cell vacuolated, forming the rudimentary vessel; *b*, the wall of this cell formed of protoplasm, with nuclei imbedded, and in some cases more or less detached and projecting; *c*, processes connected with neighboring cells, formed of the common cellular substance of the germinal area; *d*, blood-corpuscles; *f*, small mother-cells, vacuolation commencing; *B*, mother-cell, in which only obscure granular matter is found.

The *blood-disks* are formed from the original divided nucleus of the vacuolated mesoblastic cells. They are free, and accumulate, each one around itself, a small quantity of the protoplasm of the cell, which rapidly acquires a tinge of color. The earliest blood-corpuscles are therefore at first nucleated, and in this and other respects resemble the white corpuscles. As soon, however, as the liver is formed, true white corpuscles make their appearance; and it seems that the chief source from which they are derived is the embryonic liver, though later on the spleen and lymphatic glands take up this function and continue it after birth. The nucleated condition of the red globules ceases before birth. The precise mode in which the nucleated white corpuscle is converted into the non-nucleated red blood-globule, whether by a change in the whole cell or by the disappearance of the cell and persistence of its nucleus, is not yet ascertained. The vitelline circulation commences about the fifteenth day and lasts till the fifth week. When fully established it is carried on as follows: Proceeding from the tubular heart are two arteries, the first aortic arteries (Fig. 102), which unite at some distance from the heart into a single artery. This runs down in front of the primitive vertebræ and in the walls of the intestinal cavity, and again divides into two *primitive aortæ* or *vertebral* arteries, and these give off five or six *omphalo-mesenteric* arteries, which ramify in the germinal area, forming with their parent trunks a close network, terminating in veins which radiate toward an annular venous trunk—the *terminal sinus*. This vessel surrounds the vascular portion of the germinal area, but does not extend up to the anterior end of the embryo. It terminates on either side in a vein called the

FIG. 102.

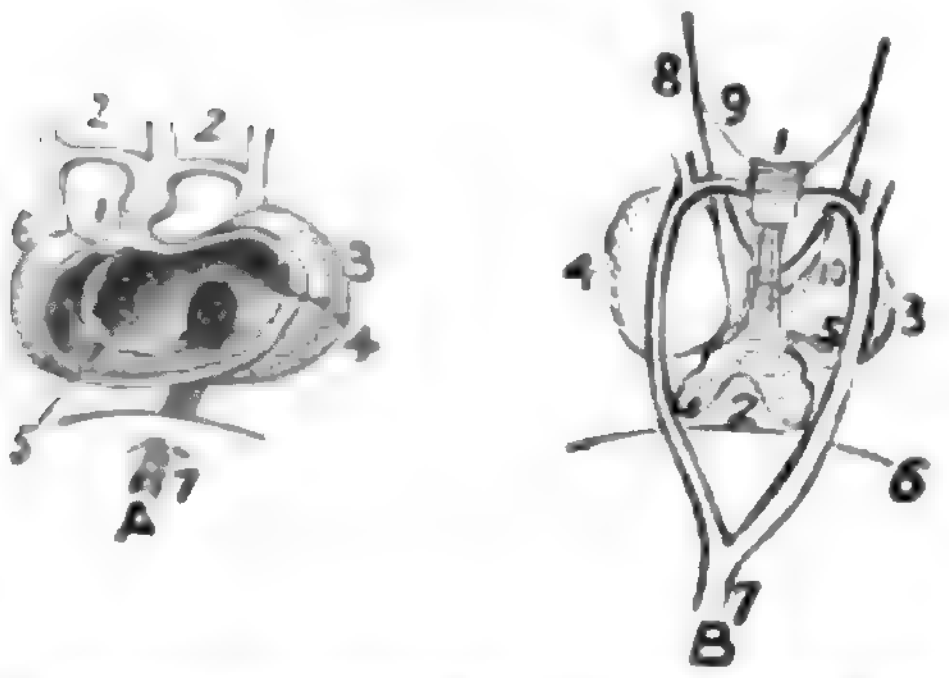

Heart at the Fifth Week: A, opened from the abdominal aspect: 1, arterial sinus: 2, aortic arches uniting behind to form the descending aorta: 3, auricle: 4, auriculo-ventricular orifice: 5, commencing septum ventriculorum: 6, ventricle: 7, inferior vena cava.
B, Posterior View of the same: 1, trachea: 2, lungs; 3, ventricles: 4, 5, auricles: 6, diaphragm: 7, descending aorta: 8, 9, 10, pneumogastric nerves and their branches.

omphalo-mesenteric. The two omphalo-mesenteric veins open into the opposite extremity of the heart to that from which the arteries proceeded. This primitive circulation extends gradually from the germinal area over the whole of the umbilical vesicle, and the vessels external to the embryo disappear as the umbilical vesicle becomes atrophied.

2. **The Placental Circulation.**—As the umbilical vesicle diminishes, the allantois, which is formed by a protrusion from the lower part of the intestine, enlarges and becomes converted into a vascular chorion, a part of which forms the placenta. When the umbilical vesicle disappears, this becomes the only source of nutrition for the embryo. The allantois carries with it two arteries, derived from branches of the primitive aorta, and two veins; these vessels become much enlarged as the placental circulation is established, but subsequently one of the veins disappears, and in the later stages of uterine life the circulation is carried on between the fœtus and the placenta by two arteries and one vein (*umbilical*).

During the occurrence of these changes great alterations take place in the primitive heart and blood-vessels, above alluded to, which will now require description.

Further Development of the Heart.—The simple median tube formed by the coalescence of the pair of tubes of which the primitive heart consists becomes elongated and bent on itself, so as to form a U-shaped tube, the middle portion being protruded forward and to the right side, and at the same time twisted on itself, so that the extremity from which the arteries are prolonged is situated in front and to the right, and that into which the veins enter behind and to the left. The bent tube then becomes divided by two transverse constrictions into three parts. One, the posterior, becomes the auricles, the middle one forms the two ventricular cavities, while the anterior forms the aortic bulb, from which the commencement of the aorta and pulmonary artery is developed. A division of each of these cavities now takes place, so as to convert them into right and left ventricle, right and left auricle, and aorta and pulmonary artery respectively. This division first takes place in the middle portion of the tubular heart, the rudimentary ventricular cavities (Fig. 102, A, 5). A partition rises up from the lower part of the right wall of this cavity, and gradually grows up until it reaches the constrictions which separate it from the other two, and thus the interventricular septum is completed. At the same time a cleft appears on the outside, a little to the right of the most prominent point, which ultimately becomes the apex of the heart. This cleft becomes less marked as development progresses, but remains, to some extent, persistent throughout life as the interventricular groove.

The first appearance of a division in the posterior or auricular portion of the tubular heart makes its appearance at a very early period of development in the shape of two projecting pouches, one on either side; these are the rudiments of the auricular appendages, but the actual division of the cavity by a septum does not occur until some time after the appearance of the ventricular septum. This is formed by the growth of a partition from the anterior wall of the auricular cavity, which grows backward, and partially separates the cavity into two. The partition, however, is not completed until after birth, a part remaining undeveloped, and thus permitting of a communication (*foramen ovale*) between the two auricles during the whole of fœtal life. In like manner, the aortic bulb is divided into two by the growth of a septum downward from the distal end of the bulb, dividing this cavity into two, the permanent aorta and pulmonary artery. Very soon a superficial furrow appears on the external surface of this portion of the heart, corresponding to the septum internally, and, becoming deeper, the two vessels are gradually separated from each other through the septum, in the immediate neighborhood of the ventricular portion of the heart, whilst beyond this they still remain joined together, and give origin to the fourth and fifth aortic arches, presently to be described.

Further Development of the Arteries.—In the vitelline circulation two arteries were described as coming off from the primitive heart and running down in front of the developing vertebræ. The first change consists in the fusion of these arteries into one at some distance from the heart, thus forming the descending thoracic and abdominal aorta. In consequence of the heart falling backward to the lower part of the neck, and then into the thorax, as the head is developed, the two original arteries, proceeding from the heart to the point of fusion in the common descending aorta, become elongated and assume an arched form, curving backward on each side from the front of the body toward the vertebral column (Fig. 103, A). These are the first or primitive aortic arches. As the heart recedes into the thorax, and these arches, which correspond in position to the first pharyngeal or mandibular arch, become elongated, four pairs of arches are formed behind them around the pharynx (Fig. 103). The arches, five in number, remain permanent in fishes, giving off from their convex borders the branchial arteries to supply the gills. In Mammalia the five pairs do not exist together, for the first two have disappeared before the others are formed. Only some of the arches in this class of animals remain as permanent structures; other arches, or portions of them, become obliterated or disappear. The first two arches entirely disappear. The third remains as a part of the internal carotid artery, the remainder being formed by the upper part of the posterior aortic root—*i. e.* the descending part of the original vessel which proceeded from the rudimentary tubular heart. The common and external carotid are formed from the anterior aortic root; that is, the ascending portion of the same primitive vessel. The fourth arch on the left side becomes developed into the permanent arch of the aorta in mammals, but in birds it is the fourth arch on the right side which forms the aortic arch, while in reptiles the fourth arch on both sides persists, as there is a permanent double aortic arch. The fourth arch on the right side forms the subclavian artery, and by the junction of its commencement with the anterior aortic root, from which the common carotid is developed, it forms the innominate artery.[1] The fifth arch on the left side forms the pulmonary artery and the ductus arteriosus; that on the right side becomes atrophied and disappears. The first part of the fifth left arch remains connected with that part of the *bulbus aortæ* which is separated as the pulmonary stem, and with it forms the common pulmonary artery. From about the middle of this arch two branches are given off, which form the right and left pulmonary arteries respectively, and the remaining portion—*i. e.* the part beyond the origin of the branches communicating with the left fourth arch; that is, the descending part of the arch of the aorta—constitutes the ductus arteriosus. This duct remains pervious during the whole of fœtal life, and after birth becomes obliterated.

FIG. 103.

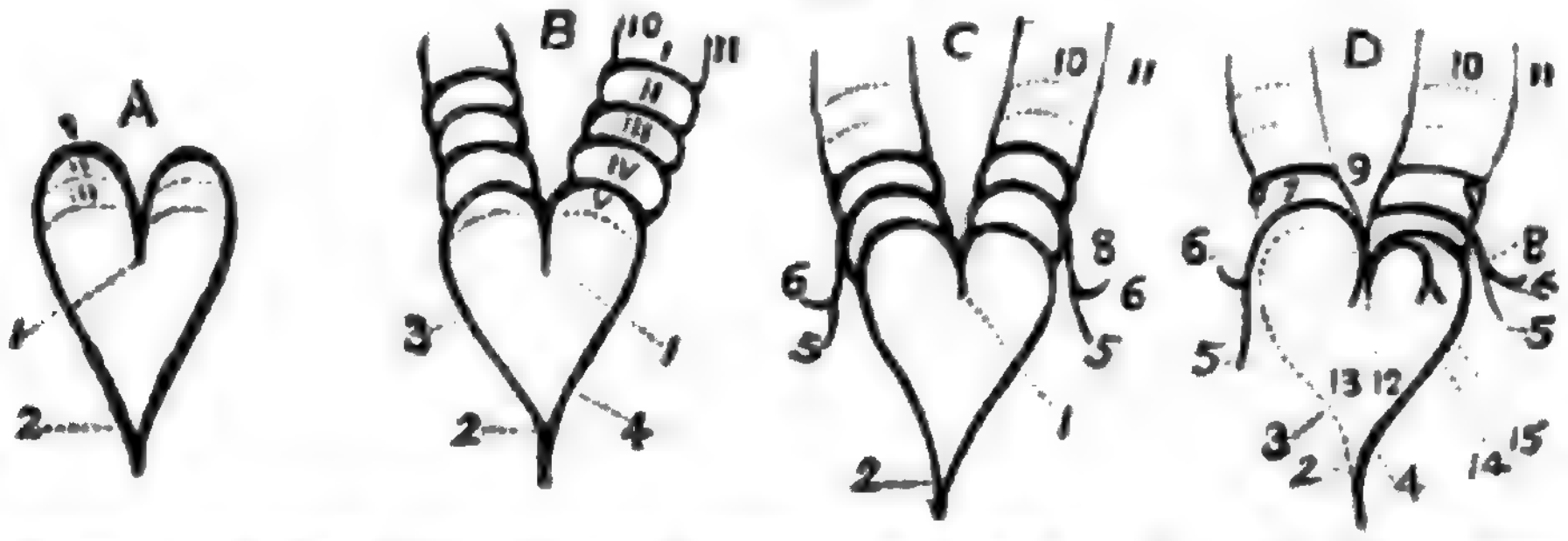

Diagram of the Formation of the Aortic Arches and the Large Arteries: I, II, III, IV, V, first, second, third, fourth, and fifth aortic arches; A, common trunk from which the first pair spring; the place where the succeeding pairs are formed is indicated by dotted lines; B, common trunk, with four arches and a trace of the fifth; C, common trunk, with the three last pairs, the first two having been obliterated; D, the persistent arteries, those which have disappeared being indicated by dotted lines; 1, common arterial trunk; 2, thoracic aorta; 3, right branch of the common trunk, which is only temporary; 4, left branch, permanent; 5, axillary artery; 6, vertebral; 7, 8, subclavian; 9, common carotid; 10, external, and 11, internal carotid; 12, aorta; 13, pulmonary artery; 14, 15, right and left pulmonary arteries.

The development of the arteries in the lower part of the body is going on during the same time. We have seen that originally there were two primitive arteries coming off from the primary tubular heart, and that these two vessels at some distance from the heart became fused together to form a single median artery, which coursed down in front of the vertebræ to the bottom of the spinal column, forming the permanent aorta. From the extremity of this the two vitelline arteries, which were originally parts of the primitive main trunks, pass to the area vasculosa. As the umbilical vesicle dwindles and the allantois grows, two large branches are formed as lateral offshoots of the median aorta. These are the two *umbilical* or *hypogastric* arteries, and are concerned in the placental circulation. The portion of the median aorta beyond this point becomes much diminished in size, and eventually forms the sacra-media artery, and thus the two umbilical branches become in appearance bifurcating branches of the main aorta. The common and internal iliac arteries are developed from the proximal end of these umbilical arteries; the middle portion of the vessel after birth becomes partially atrophied, but in part remains pervious as the superior vesical artery; the distal portion becomes obliterated, constituting part of the superior ligament of the bladder. The external iliac and femoral arteries are developed from two small branches given off from the umbilical arteries near their origin, and are at first of comparatively small size.

---

[1] This is interesting in connection with the position of the recurrent laryngeal nerve, which is thus seen to hook round the *same* primitive fœtal structure, which becomes on the right side the subclavian artery, on the left the arch of the aorta.

Development of the Veins.—The formation of the great veins of the embryo may be best considered under two groups, visceral and parietal.

The *visceral* are derived from the vitelline and umbilical veins. In the earliest period of the circulation of the embryo we have seen that there were two veins (vitelline or omphalo-mesenteric) returning the blood from the vitelline membrane. These unite together to form a single vitelline vein. As soon as the placenta begins to be formed two umbilical veins appear, and, uniting together, join the vitelline vein. We have thus a single trunk formed by four veins, two returning the blood from the area vasculosa, and two from the placenta. Soon, however, the right vitelline and right umbilical veins disappear. The trunk now receives only the left vitelline and umbilical veins in its passage to the heart, and it traverses the rudimentary liver. Whilst doing so it gives off two sets of vessels: those nearer the heart (the *venæ hepaticæ revehentes*) eventually become the hepatic veins, while those more remote (the *venæ hepaticæ advehentes*) are the radicles of the right and left portal veins. These vessels communicate by a capillary plexus in the substance of the liver, so that a portion of the blood passing to the heart through the united left vitelline and umbilical veins traverses the substance of the developing liver, passing to its capillaries by the

FIG. 104.

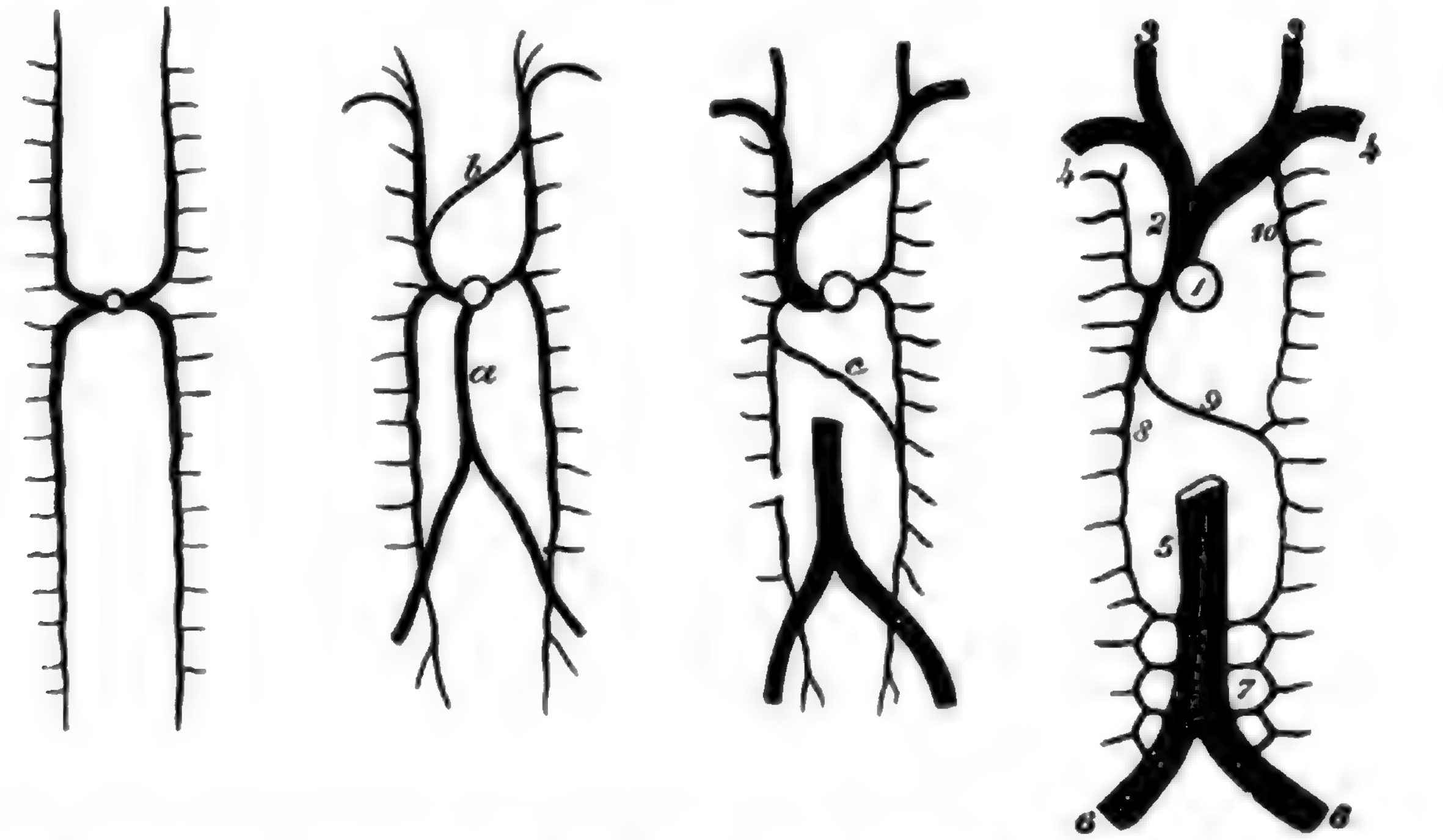

Diagrams illustrating the Development of the Great Veins. The first figure shows the vertebral veins emptying into the heart by two lateral trunks, "the ducts of Cuvier." The second figure shows the formation of the iliac and subclavian veins: *a*, inferior vena cava; *b*, left innominate vein. The third figure shows the vertebral veins much diminished in size and the duct of Cuvier on the left side, gradually disappearing: *c*, vena azygos minor. The fourth figure shows the adult condition of the venous system: 1, right auricle of heart; 2, vena cava superior; 3, jugular veins; 4, subclavian veins; 5, vena cava inferior; 6, iliac veins; 7, lumbar veins; 8, vena azygos major; 9, vena azygos minor; 10, superior intercostal vein (after Dalton).

venæ advehentes (rudimentary portal veins), and being returned by the venæ revehentes (rudimentary hepatic veins). That portion of the common trunk of the united vitelline and umbilical veins which lies between these two sets of vessels becomes the ductus venosus, and that portion which lies between the junction with it of the venæ revehentes and the heart becomes the upper part of the inferior vena cava. The distal part of the vitelline vein, receiving the veins from the mesentery, becomes the superior mesenteric vein, and is joined by the splenic, after which junction it becomes the trunk of the portal vein.

The Parietal Veins.—The first appearance of a parietal system consists in the appearance of two short transverse veins (the *ducts of Cuvier*) which open on either side of the auricular portion of the heart. Each of these ducts is formed by an ascending and descending vein. The ascending veins return the blood from the parietes of the trunk and the Wolffian bodies, and are called *cardinal* veins. The two descending ones return the blood (Fig. 104) from the head, and are called *primitive jugular* veins. As the kidneys are developed, the veins conveying the blood from them unite together to form a single trunk, which passes up the abdomen behind the intestines, and, joining the common trunk formed as above described by the junction of the left vitelline and left umbilical vein above the point of entrance of the venæ revehentes, constitutes the inferior vena cava. Two small veins receiving branches from the lower extremity unite to form the lower part of the inferior vena cava below the point of entrance of the veins from the kidneys. These are the primitive iliac veins, and in their course upward they cross the cardinal veins and communicate with them. The part of the iliac vein between this point of communication and their junction with one another constitutes the common iliac vein, while the distal portion forms the external iliac vein. The internal iliac vein is formed from that part of the cardinal vein which lies below the point of communication. The greater part of the remainder of the cardinal vein—that is to say, of that portion above the iliac veins—becomes obliterated; a small part, however, at the upper extremity remains persistent, and becomes continuous with two new veins which are formed, one on either side of the vertebral column. These veins receive the intercostal and lumbar veins, and eventually form the azygos veins. They become joined by an oblique communicating branch, which crosses the middle line and constitutes the junction of the vena azygos minor with the vena azygos major. These veins are termed the *posterior vertebral veins* of Rathke. The upper part of the left one, with its continuation, the cardinal vein, forms the superior intercostal of the left side.

FIG. 105.

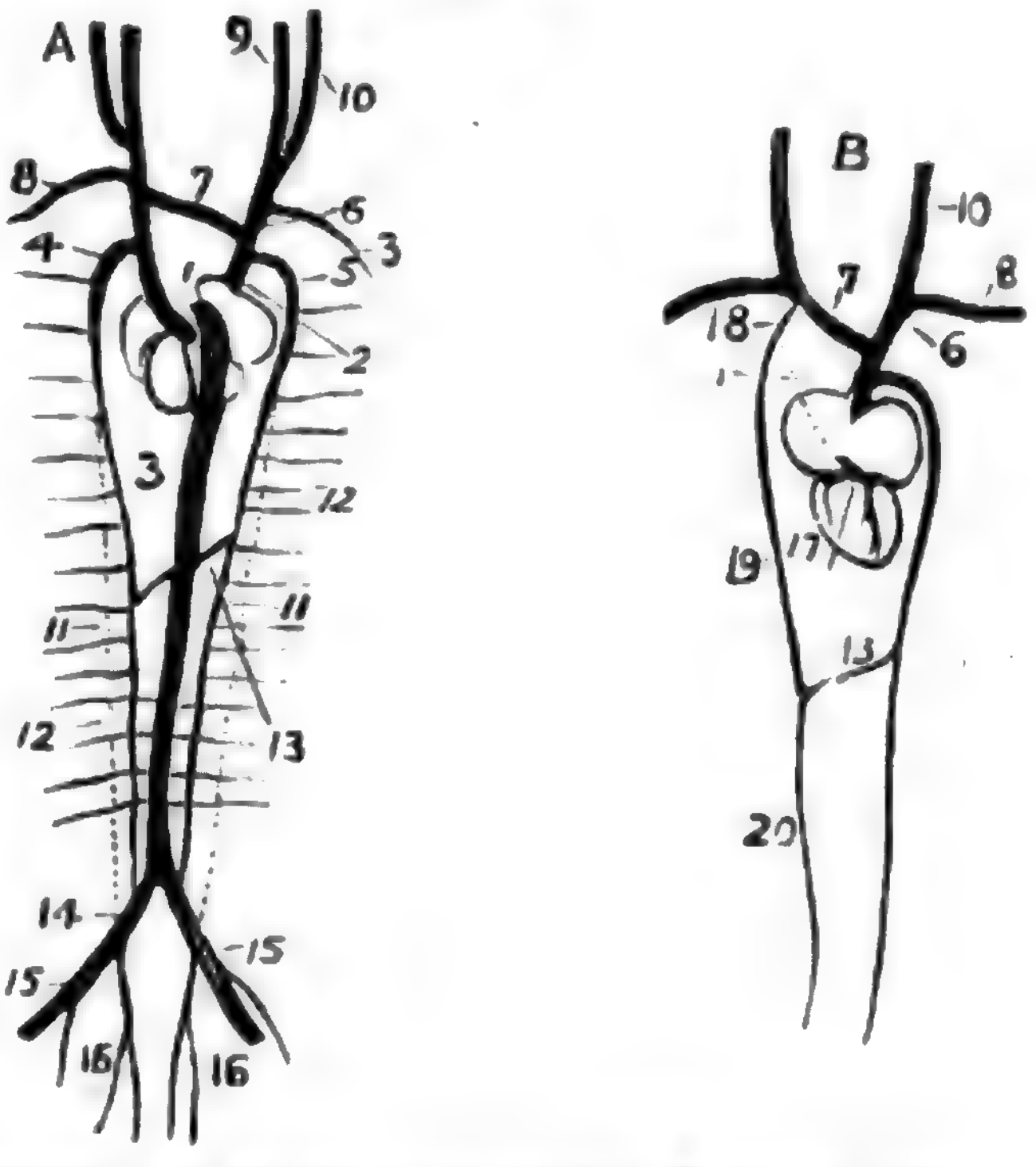

Diagram of the Formation of the Main Systemic Veins: A, heart and venous system at the period when there are two venæ cavæ superiores, posterior view: 1, left superior cava; 2, right superior cava; 3, inferior cava; 4, left inferior cardinal; 5, right inferior cardinal; 6, right jugular; 7, anastomosing branch between the jugulars (left innominata); 8, subclavian; 9, internal jugular; 10, external jugular; 11, middle obliterated portion of the posterior cardinal veins; 12, newly-formed posterior vertebral veins; 13, anastomosis between the two vertebrals—trunk of small azygos; 14, iliac veins, proceeding from anastomosis between the inferior cava and posterior cardinals; 15, crural; 16, hypogastric—originally the distal ends of the cardinals.

B, heart and permanent veins, posterior view: 1, obliterated left superior cava; 6, right innominate; 7, left innominate; 8, subclavian; 10, jugular; 13, trunk of the small azygos; 17, coronary sinus receiving the coronary vein; 18, superior intercostal; 19, superior small azygos; 20, inferior small azygos.

The veins first formed in the upper part of the trunk are, as above stated, the *primitive jugular* veins. Shortly, two small branches may be noticed opening into them near their termination; these form the subclavian and internal jugular veins.

From the point of junction of these veins on the left side a communicating branch makes its appearance, running obliquely across the neck downward and to the right, to open into the primitive jugular vein of the right side below the point of entrance of the subclavian vein. At the same time, in consequence of the alteration in the position of the heart and its descent into the thorax, the direction of the ducts of Cuvier becomes altered, and they assume an almost vertical position. From the portion of the primitive jugular veins above the branch of communication the internal jugulars are formed, except that part of the right one which lies between the point of entrance of the subclavian of this side and the termination of the communicating branch, which becomes the right innominate vein. The communicating branch becomes the left innominate vein. The primitive jugular of the right side, below the communicating vein and the right duct of Cuvier, becomes the vena cava superior, into which the right cardinal (vena azygos major) enters. The lower part of the left primitive jugular and the left duct of Cuvier become almost entirely obliterated, except at the lower end, which remains as a fibrous band, or sometimes a small vein, and runs obliquely over the posterior surface of the left auricle. The termination of the left duct of Cuvier remains persistent, and forms the coronary sinus (Fig. 105). The fœtal circulation will be described on a future page.

Development of the Alimentary Canal.—The development of the intestinal cavity is, as shown on page 108, one of the earliest phenomena of embryonic life. The original intestine consists of an inflection of the hypoblast extending from one end of the embryo to the other, and is situated just below the primitive vertebral column. At either extremity it forms a closed tube in consequence of the cephalic and caudal flexures (p. 107); and this manifestly divides it into three parts: a front part, enclosed in the cephalic fold, called the *fore-gut;* a posterior part, enclosed in the caudal fold, the *hind-gut;* and a central part, or *mid-gut*, which at this time freely communicates with the umbilical vesicle (Fig. 106). The ends of the fore- and hind-gut do not communicate with the surface of the body, the buccal and anal orifices being subsequently formed by involutions of the epiblast, which later on form communications with the gut. From the fore-gut, the pharynx, œsophagus, stomach, and duodenum; from the hind-gut, a part of the rectum; and from the middle division, the rest of the intestinal tube,—are developed (Fig. 107). The changes which take place in the fore-gut are as follows: The middle portion becomes dilated to form the stomach, and undergoes a rotation to the right, so that the posterior border, by which it is attached to the vertebral column by a mesentery, is now directed to the left, and the anterior border to the right. At this time it is straight, but it soon undergoes a lateral curve or bend to the right at its upper end. It thus assumes an oblique direction, and the left border (originally the posterior or attached border) becomes inferior and forms the great curvature. The mesentery by which it

FIG. 106.

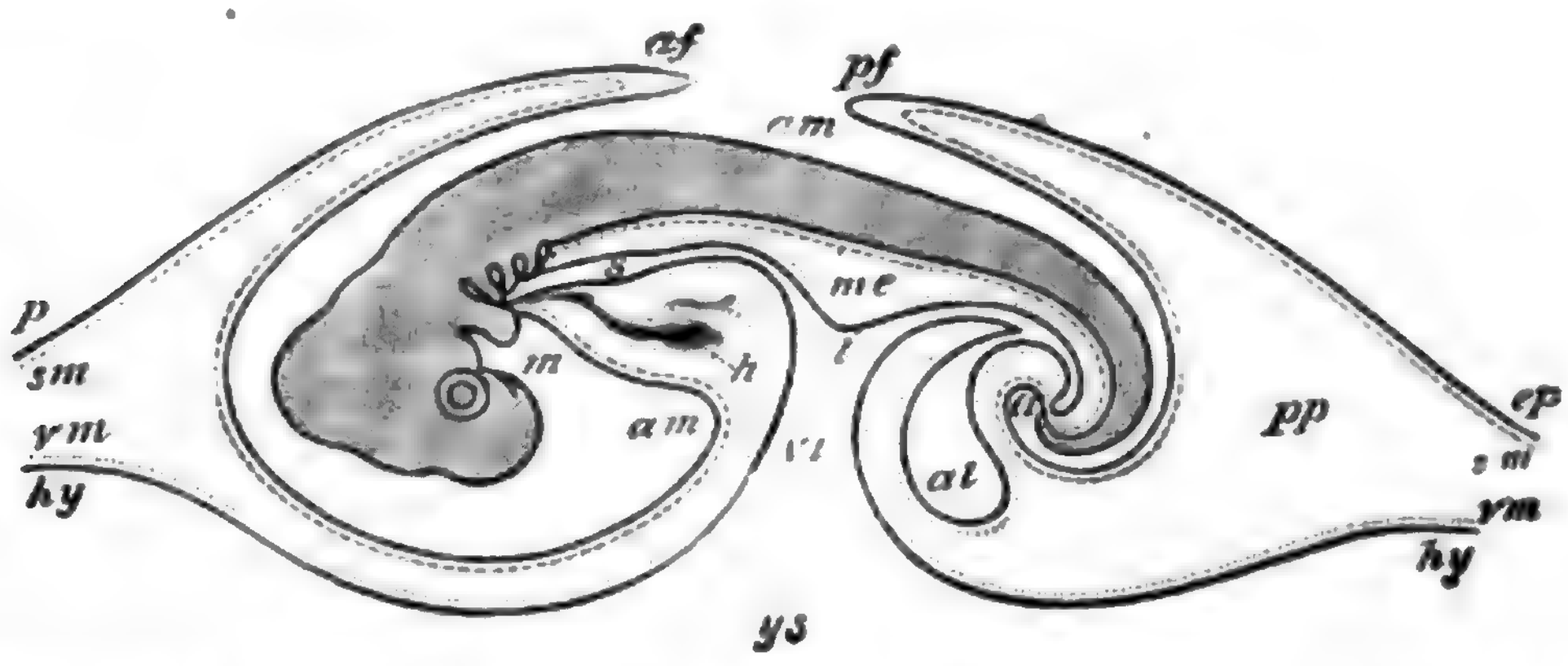

Diagrammatic Outline of a Longitudinal Vertical Section of the Chick on the fourth day: *ep*, epiblast; *sm*, somatic mesoblast; *hy*, hypoblast; *vm*, visceral mesoblast; *af*, cephalic [anterior amniotic] fold; *pf*, caudal [posterior amniotic] fold; *am*, cavity of true amnion; *ys*, yolk-sac; *i*, intestine; *s*, stomach and pharynx; *a*, future anus, still closed; *m*, the mouth; *me*, the mesentery; *al*, the allantoid vesicle; *pp*, space between inner and outer folds of amnion; [*vi*, vitello-intestinal duct] (from *Quain's Anatomy*, Allan Thompson).

was attached forms the great omentum. The portion of the fore-gut above this dilatation remains straight, forming the pharynx and œsophagus, and in consequence of the mesoblast being here undivided there is no serous investment to the dorsal part of the tube. Below this, division of the mesoblast has taken place, and the splanchnopleure forms the vascular and serous layers of the remainder of the intestinal canal, the space between this layer and the somatopleure constituting the pleuro-peritoneal cavity.

Fig. 107.

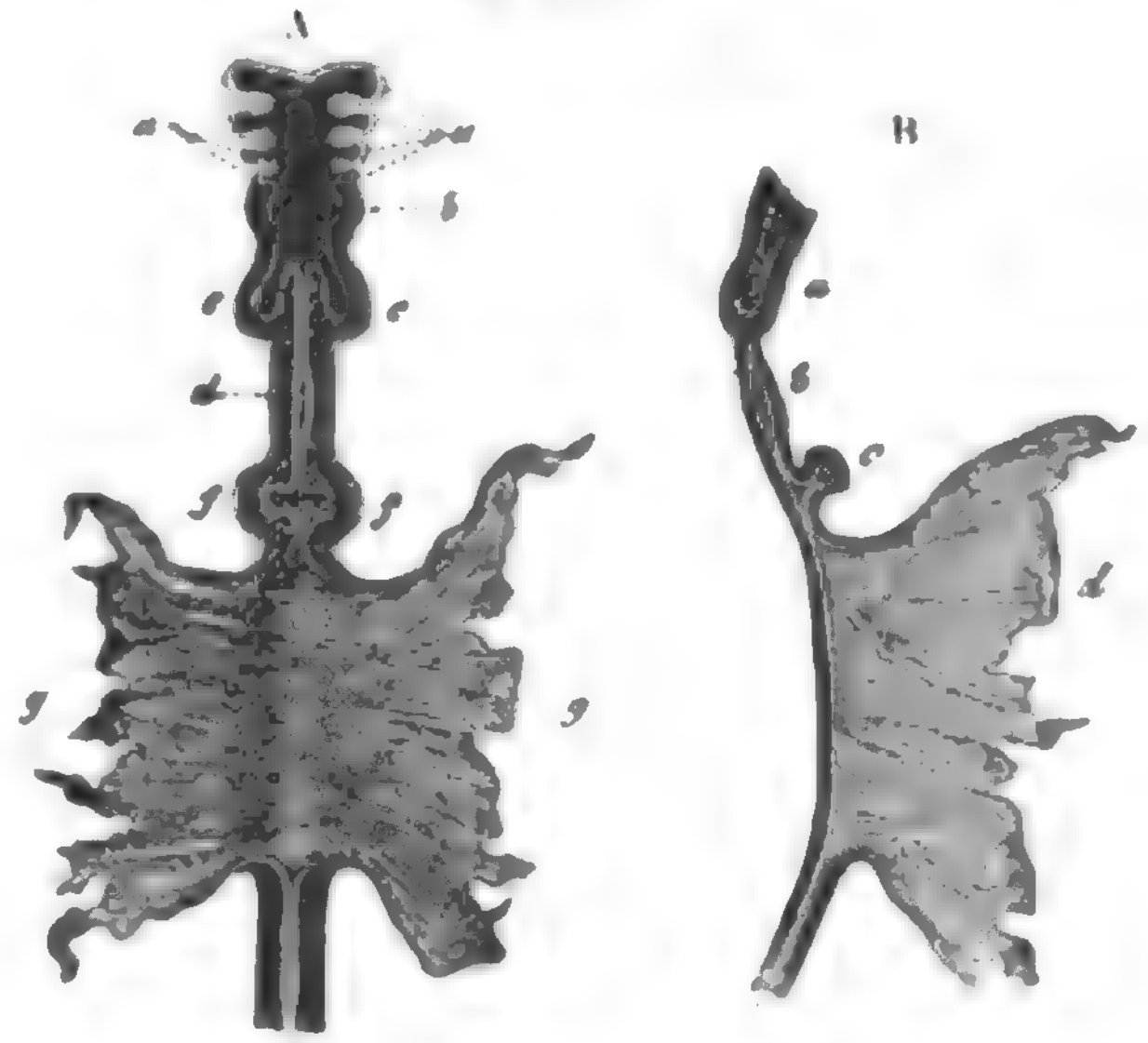

Early Form of the Alimentary Canal (from Kölliker, after Bischoff): In A a front view, and in B an antero-posterior section, are represented: *a*, four pharyngeal or visceral plates; *b*, the pharynx; *c*, *c*, the commencing lungs; *d*, the stomach; *f*, *f*, the diverticula connected with the formation of the liver; *g*, the yolk-sac [umbilical vesicle] into which the middle intestinal groove opens; *h*, the posterior part of the intestine.

The part of the fore-gut below the dilated stomach forms the duodenum, and in connection with this the liver and pancreas are developed.

The ***hind-gut*** is also a closed tube, and from it the middle third of the rectum is developed, as well as the allantois (p. 111), which will be again referred to in connection with the development of the bladder.

The ***mid-gut*** is at first an open cavity freely communicating with the umbilical vesicle. As the body-walls grow, this communication contracts very materially, though it still exists to a certain extent, and its open cavity becomes converted into a straight tube, still open where it communicates with the umbilical vesicle. This tube grows rapidly in length, and presents a primitive curve or loop downward and forward, and, in consequence of its growth exceeding that of the walls of the body-cavity, a portion of the loop protrudes into the stalk of the umbilical vesicle. At a subsequent period, however, the walls of the abdomen grow more rapidly than the intestine, which again recedes into the body-cavity. At a short distance below the most prominent point of this loop a diverticulum arises, which marks the separation between the large and small intestine. The lower part of this diverticulum forms the vermiform appendix; the proximal part, by its continued growth, constitutes the cæcum. After this the anterior or upper part of the gut, corresponding to the small intestine, rapidly increases in length, and about the eighth week becomes convoluted. The lower or posterior part, corresponding to the large intestine, is at first less in calibre than the upper part, and lies wholly to the left side of the convolutions of the small intestine; but later on the curve of the large intestine begins to form, and the first part (ascending colon) slowly crosses over to the right side, first lying in the middle line, just below the liver. It is not until the sixth month that the cæcum descends into the right iliac fossa, and so drags the ascending colon into its normal position in the right flank.

The *peritoneal* cavity is the space left between the visceral and parietal layers of the mesoblast, and the serous membrane is developed from these structures. The mesenteries are formed from mesoblastic tissue extending between the notochord and the gut which develops the vascular and connective-tissue elements of these parts.

The *buccal* cavity is formed by an involution of the external [epiblastic] layer of the blastodermic membrane, which passes inward and meets the pharynx or upper part of the fore-gut. The two cavities are, however, at first completely separated from each other by all the layers of the blastoderm; but at an early period of development a vertical slit appears between them; this gradually widens and becomes the opening by which the common cavity of the nose and mouth communicates with the pharynx. The common cavity is afterward divided into nose and mouth by the development of the palate in the manner spoken of above.

The *tongue* appears about the fifth week as a small elevation behind the inferior maxillary arch, to which another projection from the second pharyngeal arch is united. The epithelial layer is furnished by the epiblast. The tonsils appear about the fourth month.

The *anus* is also formed by an inflection of the epiblast, which extends inward to a slight extent, and approaches the termination of the hind-gut, and finally communicates with it by a solution of continuity in the septum between the two. The persistence of the fœtal septum at either the buccal or anal orifice constitutes a well-known deformity—imperforate œsophagus or imperforate rectum, as the case may be.

The *liver* appears after the Wolffian bodies, about the third week, in the form of a bifid mass of cells consisting of the hypoblastic and mesoblastic layers of the intestine. It projects from the intestine at that part which afterward forms the duodenum. This mass of cells becomes hollowed out into a cavity lined by hypoblast, the rudiment of the main duct of the liver, the cells on either side being developed into the right and left lobes. These grow very rapidly around the vein formed by the junction of the left umbilical and left allantoic veins, from which they receive the branches enumerated on p. 128. About the third month the liver almost fills the abdominal cavity. From this period the relative development of the liver is less active, more especially that of the left lobe, which now becomes smaller than the right; but the liver remains up to the end of fœtal life relatively larger than in the adult.

The *gall-bladder* appears about the second month as an extension of the cavity from which the main duct of the liver is developed, and bile is detected in the intestines by the third month.

The *pancreas* is also an early formation, being far advanced in the second month. It, as well as the salivary glands, which appear about the same period, originates in a projection from the epithelial layer, which afterward forms a cavity, and the lobules of the gland are developed from the ramifications of this cavity. It is generally admitted that the epithelial lining of the ducts is furnished by the hypoblast in the development of both the pancreas and the liver, and that the vessels owe their origin to the mesoblast. But authorities differ as to the mode of formation of the parenchyma—as to whether this is entirely of mesoblastic origin or whether the hypoblast shares in its development. The spleen, on the other hand, is apparently entirely of mesoblastic origin, for there is never any connection between the intestinal cavity and the substance of this organ. It originates from the mesenteric fold which connects the stomach to the vertebral column (mesogastrium).

Development of the Respiratory Organs.—The lungs appear somewhat later than the liver. They are developed from a small median cul-de-sac or diverticulum from the upper part of the fore-gut, immediately behind the fourth visceral cleft, as a projection from the epithelial and fibrous laminæ of the intestine. During the fourth week a pouch is formed on either side of the central diverticulum, and opens freely through it into the fore-gut (pharynx). From these, other secondary pouches are given off, so that by the eighth week the form of the lobes of the lungs may be made out. The two primary pouches have thus a common pedicle of communication with the pharynx. This is developed into the trachea (Fig. 102, B, 1), the cartilaginous rings of which are perceptible about the seventh week. The parts which afterward form the larynx are recognized as early as the sixth week—viz. a projection on either side of the pharyngeal opening, the rudiment of the arytenoid cartilage, and a transverse elevation from the third pharyngeal arch, which afterward becomes the epiglottis: the vocal cords and ventricles of the larynx are seen about the fourth month. Traces of the diaphragm appear in the form of a fine membrane, separating the lungs from the Wolffian bodies, the stomach, and the liver, whilst the heart is still near the head. As the diaphragm extends forward from the vertebral column it separates the common pleuro-peritoneal cavity into two parts, a thoracic and abdominal.

Development of the Urinary Organs.—The urinary organs appear to be entirely of mesoblastic origin, and are intimately connected with an embryonic glandular organ first discovered by Wolff, and hence called the Wolffian body. Recent researches have shown that the Wolffian bodies form a part of a set of organs which are found in all vertebrate and some invertebrate animals. These structures have been termed the *segmental organs*, and consist, in vertebrates, of branching tubes opening at one extremity into the body-cavity, and at the other by one or more main ducts into the cloaca or hind-gut.[1] The segmental organs of vertebrates are divided into three parts, each of which possesses an excretory duct. The anterior of the three, situated in the region of the rudimentary heart, is termed the *head-kidney* or *pronephros* (Lankester), and its duct is the Müllerian duct. The central part is the Wolffian body, the *mesonephros* (Lankester), and its duct is the Wolffian duct. The posterior segment is the rudiment of the permanent kidney, and is formed later than the other two. It is named the *metanephros* (Lankester), and its duct is the ureter.

The segmental duct is perceptible about the third week, forming an elongated ridge of cells situated on either side of the primitive vertebræ and extending from the heart to the lower end of the embryo. It makes its appearance below the heart and behind the common pleuro-peritoneal cavity, from the mesoblast at the point of separation of its two layers into somatopleure and splanchnopleure. As this ridge is situated in front of the epiblast (reflected from the medullary cavity) at the side of the protovertebræ and behind the common pleuro-peritoneal cavity, it has been named "the intermediate cell-mass." It is at first solid, but soon a tube is hollowed out in it by the formation of a lumen in its most prominent part; this is the segmental duct, the greater part of which forms the Wolffian duct. As the duct is formed it sinks downward and projects into the body-cavity. The remainder of the segmental organ—*i. e.* that part which is not concerned in the formation of the duct—becomes converted into tubes, which commence as branches from the duct and spread out at right angles with it. They are at first cæcal [*i. e.* blind or closed], but soon acquire openings at their inner extremities into the body-cavity, the lower end of the segmental duct at the same time forming an opening into the urogenital sinus. Thus a communication is established through these tubes and duct between the pleuro-peritoneal cavity and the cloaca or hinder part of the alimentary canal. The next step is the formation of a second duct in the neighborhood of the original duct, with which some of the tubules of the anterior part of the segmental body (pronephros) are connected. This is the Müllerian duct. The ureter, which is formed later, is an offshoot from the hinder part of the Wolffian duct.

The structure of the Wolffian body is in many respects analogous to that of the permanent kidney (Fig. 108). It is composed partly of an excretory canal or duct, into which open numerous "conduits," rectilinear at first, but afterward tortuous, and partly of a cellular or glandular structure, in which Malpighian tufts are found. It is fixed to the diaphragm by a superior ligament, and to the spinal column by an inferior or lumbar ligament. Its office is the same as that of the kidneys—viz. to secrete fluid containing urea which accumulates in the bladder. When the permanent kidneys are formed, the greater part of the Wolffian body disappears. The rest takes part in the formation of the organs of generation.

The functional activity of the Wolffian bodies is very transitory; they attain their highest development by the sixth week, after which time they begin to decrease in size, and have nearly disappeared by the end of the third month. The upper part of the segmental body, the pronephros, also undergoes atrophy and disappears. In the male the Wolffian duct persists, and becomes converted into the vas deferens; the Müllerian duct undergoes atrophy, a vestige of it, however, remaining as the sinus prostaticus; whereas, on the other hand, in the female the Müllerian duct remains and becomes converted into the whole length of the genital passages, while the Wolffian duct almost entirely disappears and remains only as a vestige. Prior to this, however, the Wolffian and Müllerian ducts (together with the ureter when formed) open into the common urogenital sinus or cloaca, which is the termination of the intestinal cavity, into which the allantois also opens in front (Fig. 109).

---

[1] In invertebrates the external openings are on the sides of the body.

As the allantois expands into the urinary bladder this common cavity is divided into two by a septum to form the bladder in front and the rectum behind. The Wolffian and Müllerian ducts are soon connected by cellular substance into a single mass—the *genital cord*—in which the Wolffian ducts lie side by side in front, and the ducts of Müller behind, at first separate, but later on uniting with each other.

It has been stated that the kidney is developed from the lower part (metanephros) of the segmental organ. With this the ureter becomes connected in the following manner: It commences as a tubular diverticulum from the lower part of the segmental duct close to the cloaca. It extends upward and becomes divided into a number of cæcal tubules, which represent the commencement of the several divisions of the pelvis of the kidney. These tubules are prolonged into the solid blastema of which the kidney at that time consists. The tubules then become convoluted, and masses of cells accumulate on their exterior, so as to give to the organ an appearance of lobulation. Between these cells vessels are developed, and the vascular glomeruli are gradually formed. The kidneys at first, therefore, consist of cortical substance only, but later on the proximal ends of the tubes become straight and arranged in bundles, and thus the pyramidal structure is developed. The lobulation of the kidney is perceptible for some time after birth.

FIG. 108.



Enlarged View from the Front of the Left Wolffian Body before the establishment of the distinction of sex (from Farre, after Kobelt): *a, a, b, d*, tubular structure of the Wolffian body; *e*, Wolffian duct; *f*, its upper extremity; *g*, its termination in *x*, the urogenital sinus; *h*, the duct of Müller; *i*, its upper, still closed, extremity; *k*, its lower end, terminating in the urogenital sinus; *l*, the mass of blastema for the reproductive organ, ovary or testicle.

FIG. 109.

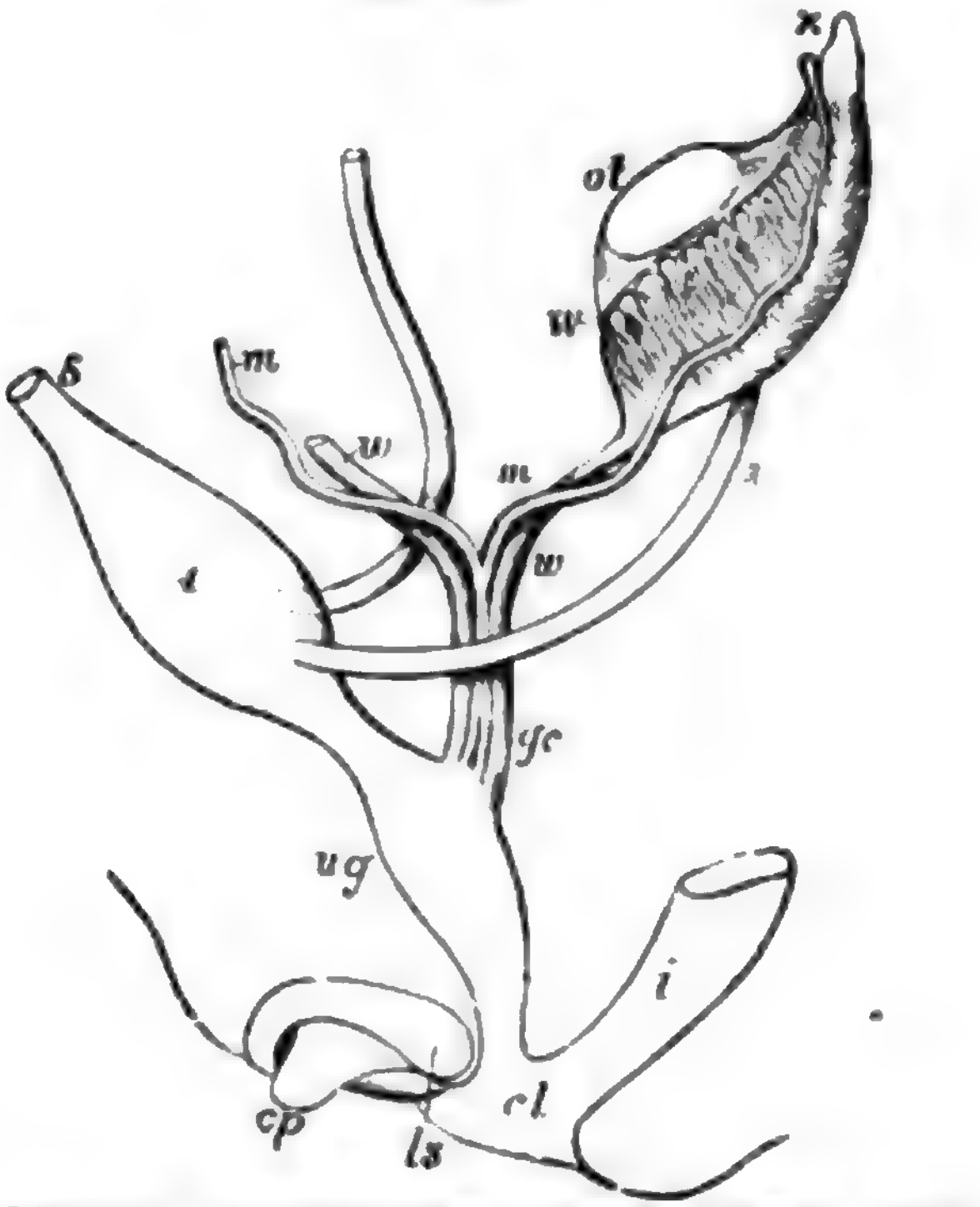

Diagram of the Primitive Urogenital Organs in the Embryo previous to sexual distinction. The parts are shown chiefly in profile, but the Müllerian and Wolffian ducts are seen from the front: 3, ureter; 4, urinary bladder; 5, urachus; *ol*, the mass of blastema from which ovary or testicle is afterward formed; *W*, left Wolffian body; *x*, part at the upper apex from which the coni vasculosi are afterward developed; *w, w*, right and left Wolffian ducts; *m, m*, right and left Müllerian ducts uniting together and with the Wolffian ducts in *gc*, the genital cord; *ug*, sinus urogenitalis; *i*, lower part of the intestine; *cl*, common opening of the intestine and urogenital sinus; *cp*, elevation which becomes clitoris or penis; *ls*, ridge from which the labia majora or scrotum is formed.

The *urinary bladder*, as before stated, is formed by a dilatation of the lower part of the stalk of the allantois. At the end of the second month this forms a spindle-shaped cavity, the bladder, which communicates with the lower part of the primitive intestine by a short canal, the first part of the urethra. The upper part of the stalk of the allantois, which is not dilated, forms the *urachus;* this extends up into the umbilical cord, and at an early period of embryonic existence forms a tube of communication with the allantois. It is obliterated before the termination of fœtal life, but the cord formed by its obliteration is perceptible throughout life, passing from the upper part of the bladder to the umbilicus, and it occasionally remains patent in the adult, constituting a well-known malformation.

The *suprarenal* bodies are developed from two different sources. The medullary part of the organ is of epiblastic origin, and is derived from the tissues forming the sympathetic ganglia of the abdomen, while the cortical portion is of mesoblastic origin, and originates in the mesoblast just above the kidneys. The two parts are at first quite distinct, but become combined in the process of development. The supra-renal capsules are at first larger than the kidney, but become equal in size about the tenth week, and from that time decrease relatively to the kidney, though they remain throughout fœtal life much larger in proportion than in the adult.

Development of the Generative Organs.—The first appearance of the reproductive organs is essentially the same in the two sexes, and consists in a thickening at one spot of the epithelial layer which lines the peritoneal or body-cavity, with a slight increase of the connective tissue beneath it, forming a low ridge. This is termed the *genital ridge*, and is situated on the mesial side of each Wolffian body, and from it the testicle in the one sex and the ovary in the other are developed. The ridge as the embryo grows gradually becomes pinched off from the Wolffian body, with which it is at first continuous, though it still remains connected to the remains of this body by a fold of peritoneum, the *mesorchium* or *mesovarium*. About the seventh week the distinction of sex begins to be perceptible. The epithelium on the genital ridge, which is called "germ-epithelium," in the female becomes distinctly columnar, multiplies rapidly, and begins to form *primitive ova* in a manner presently to be described; whereas in the male, though the germ-epithelium has a tendency to become columnar, the cells are on the whole flatter and smaller than in the female.

Development of Male Organs.—The tubuli seminiferi of the testicle appear at an early period. It is believed that they are formed by the extension of epithelial cells on the surface of the genital ridge into its blastema; rows of cells are thus developed which become the lining cells of the seminal ducts. In some animals (*e. g.* reptiles) the segmental tubes of the Wolffian body have been found to extend into the body of the testis and to form the tubes of this organ, which become lined with cells derived from the germ-epithelium; and it is probable that a similar process takes place in birds and mammals.

The Müllerian ducts disappear in the male sex, with the exception of their lower ends. These unite in the middle line, and open by a common orifice into the uro-genital sinus. This constitutes the *utriculus hominis* or *sinus prostaticus*. Occasionally, however, the upper end of the duct of Müller remains visible in the male, constituting the little pedunculated body called the hydatid of Morgagni, sometimes found in the neighborhood of the epididymis,[1] between the testes and globus major.

The head of the epididymis, its canal, the vas deferens, and the ejaculatory duct are formed from the canals and duct of the Wolffian body. One or more of the tubes of the Wolffian body form the vas aberrans and a structure described by Giraldès, and called, after him, "the organ of Giraldès," which bears a good deal of resemblance to the organ of Rosenmüller in the other sex. It consists of a number of convoluted tubules lying in the cellular tissue in front of the cord and close to the head of the epididymis.

The descent of the testis and the formation of the gubernaculum are described in the body of the work.

Development of Female Organs.—The ovary, as above stated, is formed from the genital ridge, which becomes pinched off from the remains of the Wolffian body, but is still attached by a mesovarium. It consists of a central part of connective tissue covered by a layer of germ-epithelium, from which the ova are developed. This epithelium undergoes repeated division, so that it rapidly increases in thickness and forms several layers. Next, certain of the cells become enlarged and spherical, and form what are called the *primitive ova*. Around these other epithelial cells have a tendency to arrange themselves so as to enclose the ovum in a follicle. The permanent ova, enclosed in their Graafian follicles, are thus formed.

The Fallopian tube is developed from that portion of the duct of Müller which lies above the lumbar ligament of the Wolffian body. This duct is at first completely closed at its upper extremity, and this closed extremity remains permanent, forming a small cystic body attached to the fimbriated end of the Fallopian tube, and called the "hydatid of Morgagni." Below this a cleft forms in the duct, and is developed into the fimbriated opening of the Fallopian tube.

---

[1] Mr. Osborn, in the *St. Thomas's Hospital Reports*, 1875, has written an interesting paper pointing out the probable connection between this fœtal structure and one form of hydrocele.

Fig. 110.

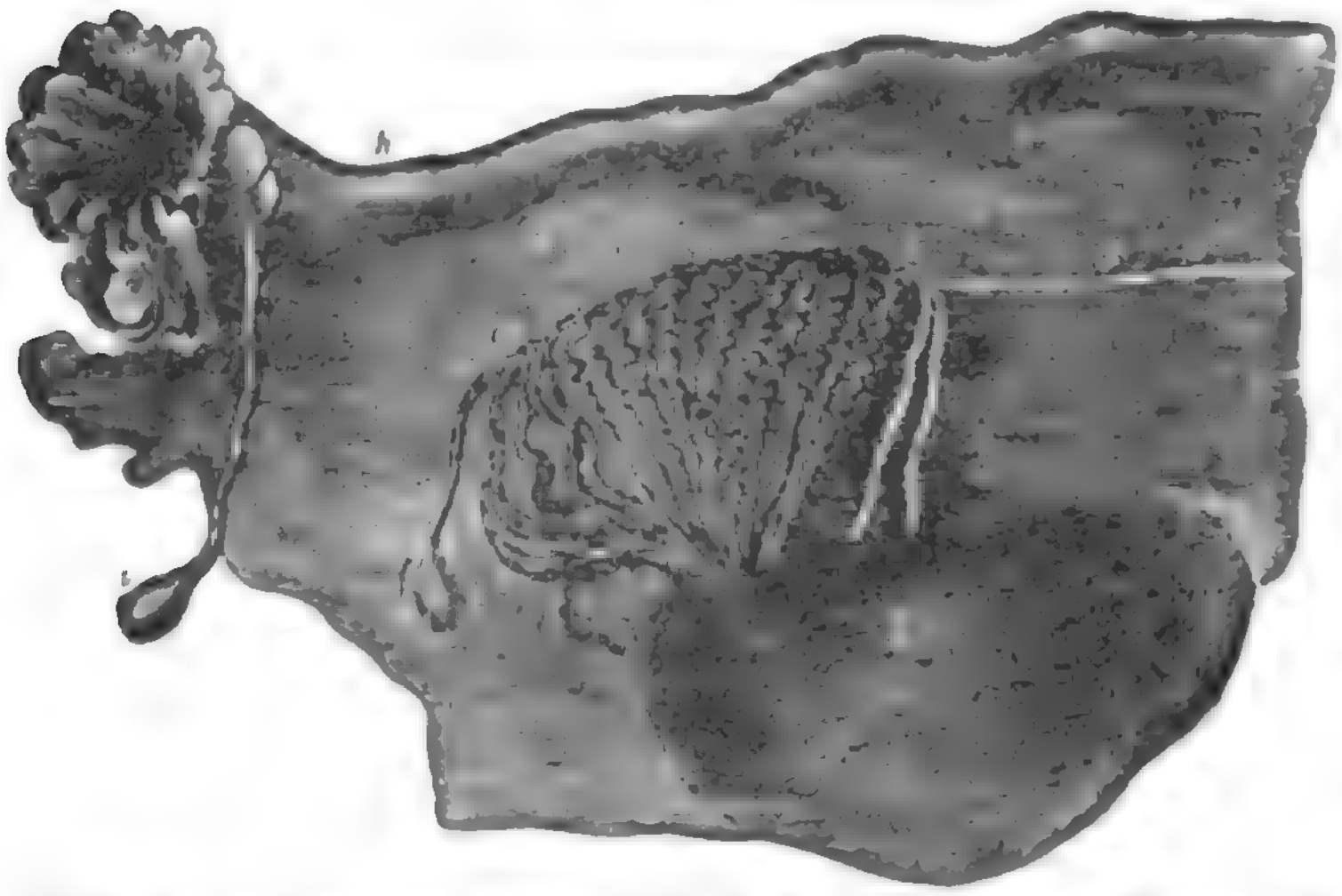

Adult Ovary, Parovarium, and Fallopian Tube (from Farre after Kobelt): *a, a*, epoöphoron (parovarium), formed from the upper part of the Wolffian body; *b*, remains of the uppermost tubes, sometimes forming hydatids; *c*, middle set of tubes; *d*, some lower atrophied tubes; *e*, atrophied remains of the Wolffian duct; *f*, the terminal bulb or hydatid; *h*, the Fallopian tube, originally the duct of Müller; *i*, hydatid attached to the extremity; *l*, the ovary.

Below this the duct of Müller and the ducts of the Wolffian bodies are united together in a structure called "the genital cord," in which the two Müllerian ducts approach each other, lying side by side, and finally coalesce to form the cavity of the vagina and uterus. This coalescence commences in the middle of the genital cord, and corresponds to the body of the uterus. The upper parts of the Müllerian ducts in the genital cord constitute the cornua of the uterus, little developed in the human species. The only remains of the Wolffian body in the complete condition of the female organs are two rudimentary or vestigial structures, which can be found, on careful search, in the round ligament near the ovary—the parovarium or organ of Rosenmüller and the epoöphoron (Fig. 110). The organ of Rosenmüller consists of a number of tubes which converge to a transverse portion (the epoöphoron), and this is sometimes prolonged into a distinct duct running transversely, the duct of Gartner, which is much more conspicuous and extends farther in some of the lower animals. This is the remains of the Wolffian duct. About the fifth month an annular constriction marks the position of the neck of the uterus, and after the sixth month the walls of the uterus begin to thicken. The round ligament is derived from the lumbar ligament of the Wolffian body; the peritoneum constitutes the broad ligament; the superior ligament of the Wolffian body disappears with that structure (Fig. 111).

Fig. 111.

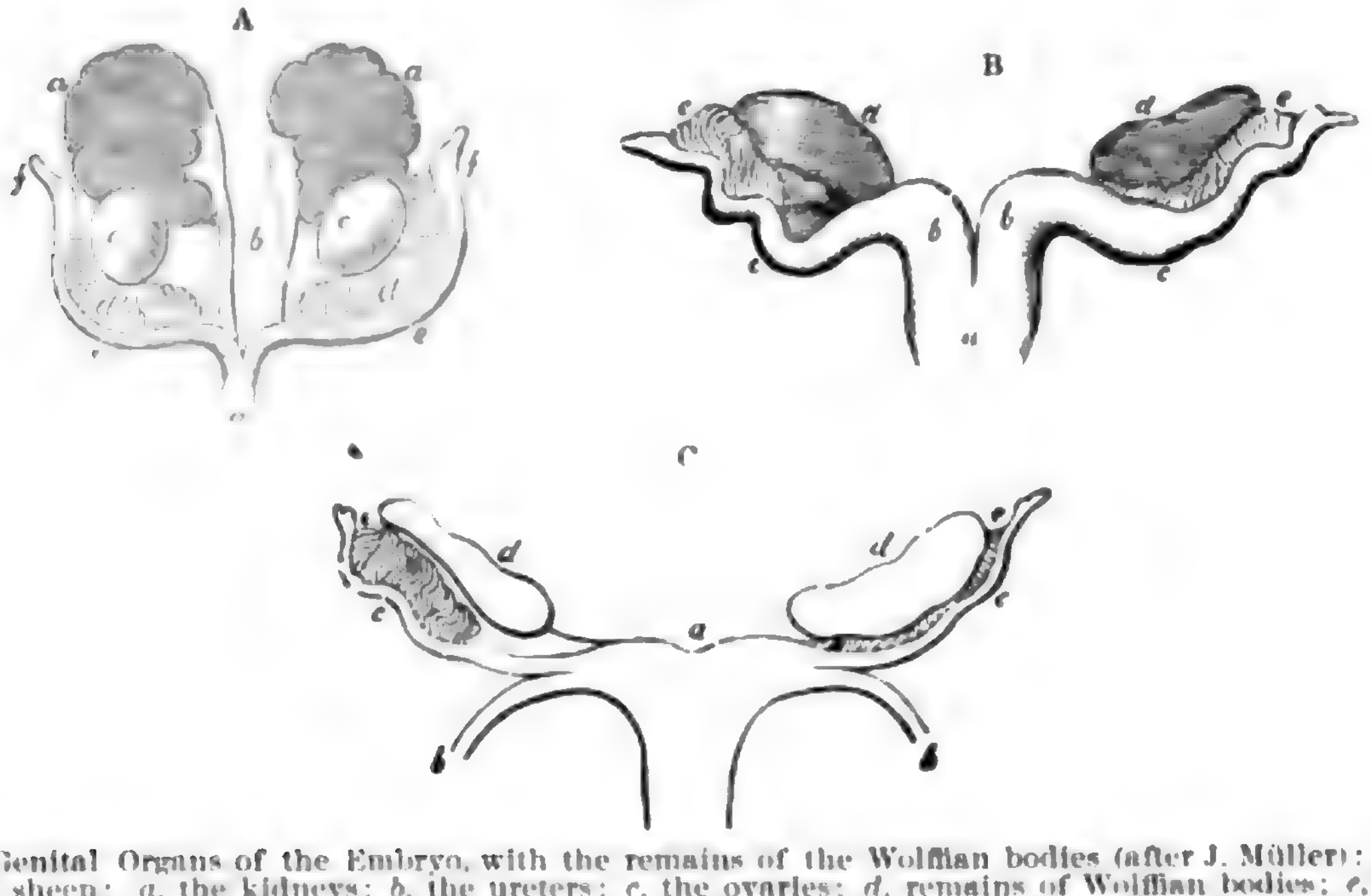

Female Genital Organs of the Embryo, with the remains of the Wolffian bodies (after J. Müller): A, from a fœtal sheep: *a*, the kidneys; *b*, the ureters; *c*, the ovaries; *d*, remains of Wolffian bodies; *e*, Fallopian tubes; *f*, their abdominal openings; *g*, their union in the body of the uterus. B, more advanced, from a fœtal deer: *a*, body of the uterus; *b*, cornua; *c*, tubes; *d*, ovaries; *e*, remains of Wolffian bodies. C, still more advanced, from the human fœtus of three months: *a*, the body of the uterus; *b*, the round ligament; *c*, the Fallopian tubes; *d*, the ovaries; *e*, remains of the Wolffian bodies.

The **external organs of generation,** like the internal, pass through a stage in which there is no distinction of sex (Fig. 112, II, III). We must therefore describe this stage, and then follow the development of the female and male organs respectively.

As stated above, the anal depression at an early period is formed by an involution of the external epithelium, and the intestine is still closed at its lower end. When the septum between the two opens, which is about the fourth week, the urachus in front and the intestine behind both communicate with the anal depression. This, which is now called the cloaca, is afterward divided by a vertical trans-

FIG. 112.

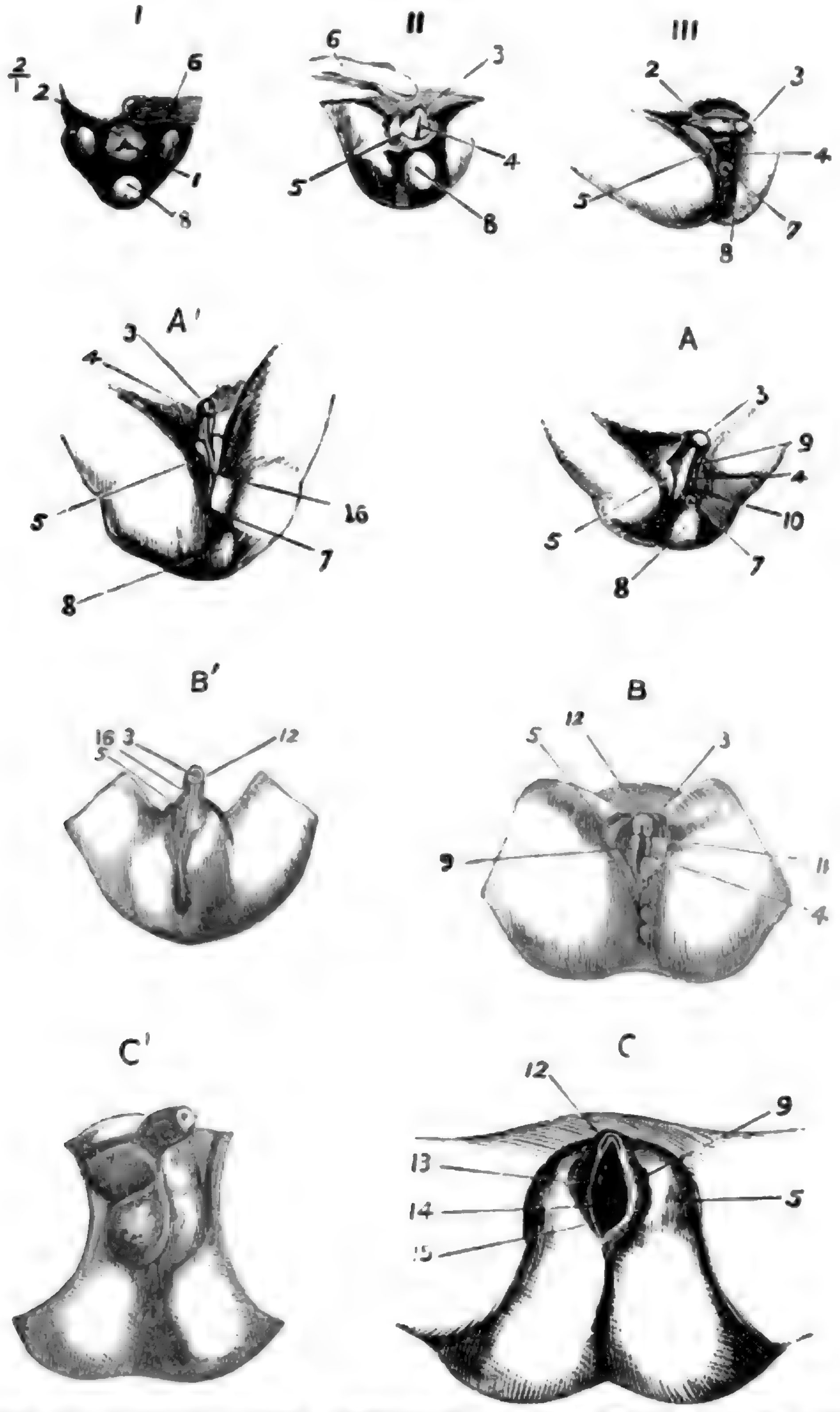

Development of the External Genital Organs. *Indifferent type*, I, II, III.—*Female:* A and B, at the middle of the fifth month; C, at the beginning of the sixth.—*Male:* A', at the beginning of the fourth month; B', at the middle of the fourth month; C', at the end of the fourth month. 1, cloaca; 2, genital tubercle; 3, glans penis or clitoris; 4, genital furrow; 5, external genital folds (labia majora or scrotum); 6, umbilical cord; 7, anus; 8, caudal extremity and coccygeal tubercle; 9, labia minora; 10, urogenital sinus; 11, frænum clitoridis; 12, preputium penis or clitoridis; 13, opening of the urethra; 14, opening of the vagina; 15, hymen; 16, scrotal raphé.

verse septum, the *perineum*, which appears about the second month. Two tubes are thus formed: the posterior becomes the lower part of the rectum, the anterior is the urogenital sinus. In the sixth week a tubercle, the *genital tubercle*, is formed in front of the cloaca, and this is soon surrounded by two folds of skin, the *genital folds*. Toward the end of the second month the tubercle presents, on its lower aspect, a groove, the *genital furrow*, turned toward the cloaca. All these parts are well developed by the second month, yet no distinction of sex is possible.

Female Organs (Fig. 112, A, B, C).—The female organs are developed by an easy transition from the above. The urogenital sinus persists as the vestibule of the vagina, and forms a single tube with the upper part of the vagina, which, as we have already seen, is developed from the united Müllerian ducts. The genital tubercle forms the clitoris, the genital folds the labia majora, and the lips of the genital furrow the labia minora, which remain open.

Male Organs.—In the male the changes are greater. The genital tubercle is developed into the penis, the glans appearing in the third month, the prepuce and corpora cavernosa in the fourth. The genital furrow closes, and thus forms a canal, the spongy portion of the urethra. The urogenital sinus becomes elongated, and forms the prostatic and membranous urethra. The genital folds unite in the middle line to form the scrotum, at about the same time as the genital furrow closes—viz. between the third and fourth months.

The following table is translated from the work of Beaunis and Bouchard, with some alterations, especially in the earlier weeks. It will serve to present a *résumé* of the above facts in an easily accessible form.[1]

---

[1] It will be noticed that the time assigned in this table for the appearance of the first rudiment of some of the bones varies in some cases from that assigned in the description of the various bones in the sequel. This is a point on which anatomists differ, and which probably varies in different cases.

CHRONOLOGICAL TABLE

OF

THE DEVELOPMENT OF THE FŒTUS.

(From Beaunis and Bouchard.)

First Week.—During this period the ovum is in the Fallopian tube. Having been fertilized in its upper part, it slowly passes down, undergoing segmentation, and reaches the uterus probably about the end of the first week. During this time it does not undergo much increase in size.

Second Week.—The ovum rapidly increases in size, and becomes imbedded in the decidua, so that it is completely enclosed in the decidua reflexa by the end of this period. An ovum believed to be of the thirteenth day after conception is described by Reichert. There was no appearance of any embryonic structure. The equatorial margins of the ovum were beset with villi, but the surface in contact with the uterine wall and the one opposite to it were bare. In another ovum, described by His, believed to be of about the fourteenth day, there was a distinct indication of an embryo. There was a medullary groove bounded by folds. In front of this a slightly prominent ridge, the rudimentary heart. The amnion was formed, and the embryo was attached by a stalk, the allantois, to the inner surface of the chorion. It may be said, therefore, that these parts, the amnion and the allantois, and the first rudiments of the embryo, the medullary groove and the heart, are formed at the end of the second week.

Third Week.—By the end of the third week the flexures of the embryo have taken place, so that it is strongly curved. The protovertebral disks, which begin to be formed early in the third week, present their full complement. In the nervous system the primary divisions of the brain are visible, and the primitive ocular and auditory vesicles are already formed. The primary circulation is established. The alimentary canal presents a straight tube communicating with the yolk-sac. The pharyngeal arches are formed. The limbs have appeared as short buds. The Wolffian bodies are visible.

Fourth Week.—The umbilical vesicle has attained its full development. Projection of the caudal extremity. Projection of the upper and lower limbs. Cloacal aperture. The heart separates into a right and left heart. Spinal ganglia and anterior roots. Olfactory fossæ. Lungs. Pancreas.

Fifth Week.—Vascularity of the allantois in its whole extent. First trace of hands and feet. The primitive aorta divides into primitive aorta and pulmonary artery. Conduit of Müller and genital gland. Ossification of clavicle and lower jaw. Cartilage of Meckel.

Sixth Week.—The activity of the umbilical vesicle ceases. The pharyngeal clefts disappear. The vertebral column, primitive cranium, and ribs assume the cartilaginous condition. Posterior roots of the nerves. Membranes of the nervous centres. Bladder. Kidneys. Tongue. Larynx. Thyroid gland. Germs of teeth. Genital tubercle and folds.

Seventh Week.—The muscles begin to be perceptible. Points of ossification of the ribs, scapula, shafts of humerus, femur, tibia, intermaxillary bone, palate, upper jaw (its first four points).

Eighth Week.—Distinction of arm and forearm and of thigh and leg. Appearance of the interdigital clefts. Capsule of the lens and pupillary membrane. Completion of the interventricular and commencement of the interauricular septum. Salivary glands. Spleen. Suprarenal capsules. The larynx begins to become cartilaginous. All the vertebral bodies are cartilaginous. Points of ossification for the ulna, radius, fibula, and ilium. The two halves of the bony palate unite. Sympathetic nerve.

Ninth Week.—Corpus striatum. Pericardium. Distinction between ovary and testicle. Formation of the genital furrow. Osseous nuclei of vertebral bodies and arches, frontal, vomer, malar bone, shafts of metacarpal bones, metatarsal bones, and phalanges. The union of the hard palate is completed. Gall-bladder.

Third Month.—Formation of the fœtal placenta. The projection of the caudal extremity disappears. It is possible to distinguish the male and female organs at the commencement of the third month. The cloacal aperture divided into two parts. The cartilaginous arches on the dorsal region of the spine close. Points of ossification for the occipital, sphenoid, os unguis, nasal bones, squamous portion of temporal and ischium. Orbital centre of superior maxillary bone. Commencement of formation of maxillary sinus. Pons Varolii. Fissure of Sylvius. Formation of eyelids and of hair and nails. Mammary gland. Epiglottis. Union of the testicle with the canals of the Wolffian body. Prostate.

Fourth Month.—The closure of the cartilaginous arches of the spine is complete. Osseous points for the first sacral vertebra and pubes. Ossification of the malleus and incus. Corpus callosum. Membranous lamina spiralis; cartilage of the Eustachian tube. Tympanic ring. Fat in subcutaneous cellular tissue. Tonsils. Closure of genital furrow and formation of scrotum and prepuce.

Fifth Month.—The two layers of decidua begin to coalesce. Osseous nuclei of axis and odontoid process. Lateral points of first sacral vertebra; median points of second. Osseous points of lateral masses of ethmoid. Ossification of stapes and petrous bone. Ossification of germs of teeth. Appearance of germs of permanent teeth. Organ of Corti. Eruption of hair on head. Sudoriferous glands. Glands of Brunner. Follicles of tonsils and base of tongue. Lymphatic glands. Commencement of limitation of uterus and vagina.

Sixth Month.—Points of ossification for the anterior root of the transverse process of the seventh cervical vertebra. Lateral points of second sacral vertebra; median points of third. The sacro-vertebral angle forms. Osseous points of the manubrium sterni and of the os calcis. The cerebral hemisphere covers the cerebellum. Papillæ of the skin. Sebaceous glands. The free border of the nail projects from the corium of the dermis. Peyer's patches. The walls of the uterus thicken.

Seventh Month.—Additional points of first sacral vertebra; lateral points of third; median point of fourth. First osseous point of body of sternum. Osseous point for astragalus. Disappearance of Meckel's cartilage. Cerebral convolutions. Insula of Reil. Separation of tubercula quadrigemina. Disappearance of pupillary membrane. The testicle passes into the vaginal process of the peritoneum.

Eighth Month.—Additional points for the second sacral vertebra; lateral points for the fourth; median points for the fifth.

Ninth Month.—Additional points for the third sacral vertebra; lateral points for the fifth. Osseous point for the middle turbinated bone; for the body and great cornu of the hyoid; for the second and third pieces of the body of the sternum; for the lower end of the femur. Ossification of the bony lamina spiralis and axis of the cochlea. Opening of the eyelids. The testicles are in the scrotum.

DESCRIPTIVE AND SURGICAL ANATOMY.

The Skeleton.

THE entire skeleton in the adult consists of two hundred distinct bones. These are—

The Spine or vertebral column (sacrum and coccyx included)	26
Cranium	8
Face	14
Os hyoides, sternum, and ribs	26
Upper extremities	64
Lower extremities	62
	200

In this enumeration the patellæ are included as separate bones, but the smaller sesamoid bones and the ossicula auditûs are not reckoned. The teeth belong to the tegumentary system.

These bones are divisible into four classes—*Long*, *Short*, *Flat*, and *Irregular*.

The **Long Bones** are found in the limbs, where they form a system of levers which have to sustain the weight of the trunk and to confer the power of locomotion. A long bone consists of a shaft and two extremities. The *shaft* [or *diaphysis*] is a hollow cylinder, contracted and narrow to afford greater space for the bellies of the muscles; the walls consist of dense, compact tissue of great thickness in the middle, which becomes thinner toward the extremities; the spongy tissue is scanty, and the bone is hollowed out in its interior to form the *medullary canal*. The *extremities* [or *epiphyses*] are generally somewhat expanded, for greater convenience of mutual connection, for the purposes of articulation, and to afford a broad surface for muscular attachment. Here the bone is made up of spongy tissue, with only a thin coating of compact substance. The long bones are not straight, but curved, the curve generally taking place in two directions, thus affording greater strength to the bone. The bones belonging to this class are the *humerus*, *radius*, *ulna*, *femur*, *tibia*, *fibula*, *metacarpal* and *metatarsal* bones, and the *phalanges*. The *clavicle* is also usually reckoned as a long bone.

Short Bones.—Where a part of the skeleton is intended for strength and compactness, and its motion is at the same time slight and limited, it is divided into a number of small pieces united together by ligaments, and the separate bones are short and compressed, such as the bones of the *carpus* and *tarsus*. These bones, in their structure, are spongy throughout, excepting at their surface, where there is a thin crust of compact substance. The *patellæ* also, together with the other sesamoid bones, are by some regarded as short bones.

Flat Bones.—Where the principal requirement is either extensive protection or the provision of broad surfaces for muscular attachment, we find the osseous structure expanded into broad flat plates, as is seen in the bones of the skull and the shoulder-blade. These bones are composed of two thin layers of compact tissue enclosing between them a variable quantity of cancellous tissue. In the cranial bones these layers of compact tissue are familiarly known as the *tables* of the skull: the outer one is thick and tough, the inner one thinner, denser, and more brittle, and hence termed the *vitreous table*.[1] The intervening cancellous tissue is called the *diploë*. The flat bones are the *occipital*, *parietal*, *frontal*, *nasal*, *lachrymal*, *vomer*, *scapula*, *os innominatum*, *sternum*, *ribs*, and *patella*.

The **Irregular** or **Mixed Bones** are such as, from their peculiar form, cannot be grouped under any of the preceding heads. The structure is similar to that of other bones, consisting of a layer of compact tissue externally and of spongy cancellous tissue within. The irregular bones are the *vertebræ*, *sacrum*, *coccyx*, *temporal*, *sphenoid*, *ethmoid*, *malar*, *superior maxillary*, *inferior maxillary*, *palate*, *inferior turbinated*, and *hyoid*.

Surfaces of Bones.—If the surface of any bone is examined, certain eminences and depressions are seen, to which descriptive anatomists have given the following names:

A prominent process projecting from the surface of a bone, which it has never been separate from or movable upon, is termed an *apophysis* (from ἀπόφυσις, an excrescence); but if such process is developed as a separate piece from the rest of the bone, to which it is afterward joined, it is termed an *epiphysis* (from ἐπίφυσις, an accretion).

These eminences and depressions are of two kinds—*articular* and *non-articular*. Well-marked examples of articular eminences are found in the heads of the humerus and femur, and of articular depressions in the glenoid cavity of the scapula and the acetabulum. Non-articular eminences are designated according to their form. Thus, a broad, rough, uneven elevation is called a *tuberosity;* a small, rough prominence, a *tubercle;* a sharp, slender, pointed eminence, a *spine;* a narrow, rough elevation running some way along the surface, a *ridge* or *line*.

The non-articular depressions are also of very variable form, and are described as *fossæ*, *grooves*, *furrows*, *fissures*, *notches*, etc. These non-articular eminences and depressions serve to increase the extent of surface for the attachment of ligaments and muscles, and are usually well marked in proportion to the muscularity of the subject.

THE SPINE.

The **Spine** is a flexuous and flexible column formed of a series of bones called *Vertebræ* (from *vertere*, to turn).

The **Vertebræ** are thirty-three in number, exclusive of those which form the skull, and have received the names *cervical*, *dorsal*, *lumbar*, *sacral*, and *coccygeal*, according to the position which they occupy; seven being found in the cervical region, twelve in the dorsal, five in the lumbar, five in the sacral, and four in the coccygeal. [The movable vertebræ can be readily distinguished as follows: Every *cervical* vertebra has a foramen in the transverse processes, every *dorsal* vertebra has a facet, or one or two half-facets, on each side of the body for the ribs; a *lumbar* vertebra has neither foramen nor facet.]

This number is sometimes increased by an additional vertebra in one region, or the number may be diminished in one region, the deficiency being supplied by an additional vertebra in another. These observations do not apply to the cervical portion of the spine, the number of bones forming which is seldom increased or diminished.

The vertebræ in the upper three regions of the spine are separate throughout the whole of life; but those found in the sacral and coccygeal regions are, in the adult, firmly united, so as to form two bones—five entering into the formation of the upper bone, or *sacrum*, and four into the terminal bone of the spine, or *coccyx*.

---

[1] Some authors have denied that the inner table is more brittle than the outer one. They state that the supposition has arisen from the fact that when the skull is fractured by a blow, or when a foreign body, such as a bullet, enters the skull, the inner table will often be found to be more splintered than the outer one. They affirm, however, that this is due to the direction in which the force is applied. If the force act in the opposite direction, then the condition of things would be reversed, and the outer table would be found to be more extensively fractured than the inner. (See some experiments by Mr. Teevan, *Path. Soc. Trans.*, vol. xvi. p. 217, 1865.)

GENERAL CHARACTERS OF A VERTEBRA.

Each **Vertebra** consists of two essential parts—an anterior solid segment, or *body*, and a posterior segment, or *arch*. The arch is formed of two *pedicles* and two *laminæ*, supporting seven *processes*—viz. four *articular*, two *transverse*, and one *spinous* process.

The Bodies of the vertebræ are piled one upon the other, forming a strong pillar for the support of the cranium and trunk, the arches forming a hollow cylinder behind for the protection of the spinal cord. The different vertebræ are connected together by means of the articular processes and the intervertebral cartilages, while the transverse and spinous processes serve as levers for the attachment of muscles which move the different parts of the spine. Lastly, between each pair of vertebræ apertures exist through which the spinal nerves pass from the cord. Each of these constituent parts must now be separately examined.

The **Body**, or *centrum*, is the largest and most solid part of a vertebra. Above and below it is flattened, presenting a rim around its circumference; and its upper and lower surfaces are rough, for the attachment of the intervertebral fibro-cartilages. In front it is convex from side to side, concave from above downward. Behind, it is flat from above downward, and slightly concave from side to side. Its anterior surface is perforated by a few small apertures for the passage of nutrient vessels, whilst on the posterior surface is a single large irregular aperture, or occasionally more than one, for the exit of veins from the body of the vertebra—the *venæ basis vertebræ*.

The **Pedicles** project backward, one on each side, from the upper part of the body of the vertebra, at the line of junction of its posterior and lateral surfaces. The concavities above and below the pedicles are the *intervertebral notches;* they are four in number, two on each side, the inferior ones being generally the deeper. When the vertebræ are articulated the notches of each contiguous pair of bones form the intervertebral foramina, which communicate with the spinal canal and transmit the spinal nerves and blood-vessels.

The **Laminæ** are two broad plates of bone which complete the vertebral arch behind, enclosing a foramen [the *spinal foramen*] which serves for the protection of the spinal cord; they are connected to the body by means of the pedicles. Their upper and lower borders are rough, for the attachment of the *ligamenta subflava.*

The **Articular Processes**, four in number, two on each side, spring from the junction of the pedicles with the laminæ. The two superior project upward, their articular surfaces being directed more or less backward; the two inferior project downward, their articular surfaces looking more or less forward.[1]

The **Spinous Process** projects backward from the junction of the two laminæ, and serves for the attachment of muscles.

The **Transverse Processes**, two in number, project one at each side from the point where the articular processes join the pedicle. They also serve for the attachment of muscles.

CHARACTER OF THE CERVICAL VERTEBRÆ (Fig. 113).

The **Body** is smaller than in any other region of the spine, and broader from side to side than from before backward. The anterior and posterior surfaces are flattened and of equal depth; the former is placed on a lower level than the latter, and its inferior border is prolonged downward, so as to overlap the upper and fore part of the vertebra below. Its upper surface is concave transversely, and presents a projecting lip on each side, its lower surface being convex from side to side, concave from before backward, and presenting laterally a shallow concavity, which receives the corresponding projecting lip of the adjacent vertebra. The *pedicles* are directed obliquely outward, and the superior intervertebral notches are deeper, but narrower, than the inferior. The *laminæ* are narrow, long, thinner above than below, and overlap each other, enclosing the spinal foramen, which is very large and of a triangular form. The *spinous processes* are short and bifid at the extremity, to afford greater extent of surface for the attachment of muscles, the two divisions being often of unequal size. They increase in length from the fourth to the seventh.

---

[1] It may, perhaps, be as well to remind the reader that the direction of a surface is determined by that of a line drawn at right angles to it.

Fig. 113.

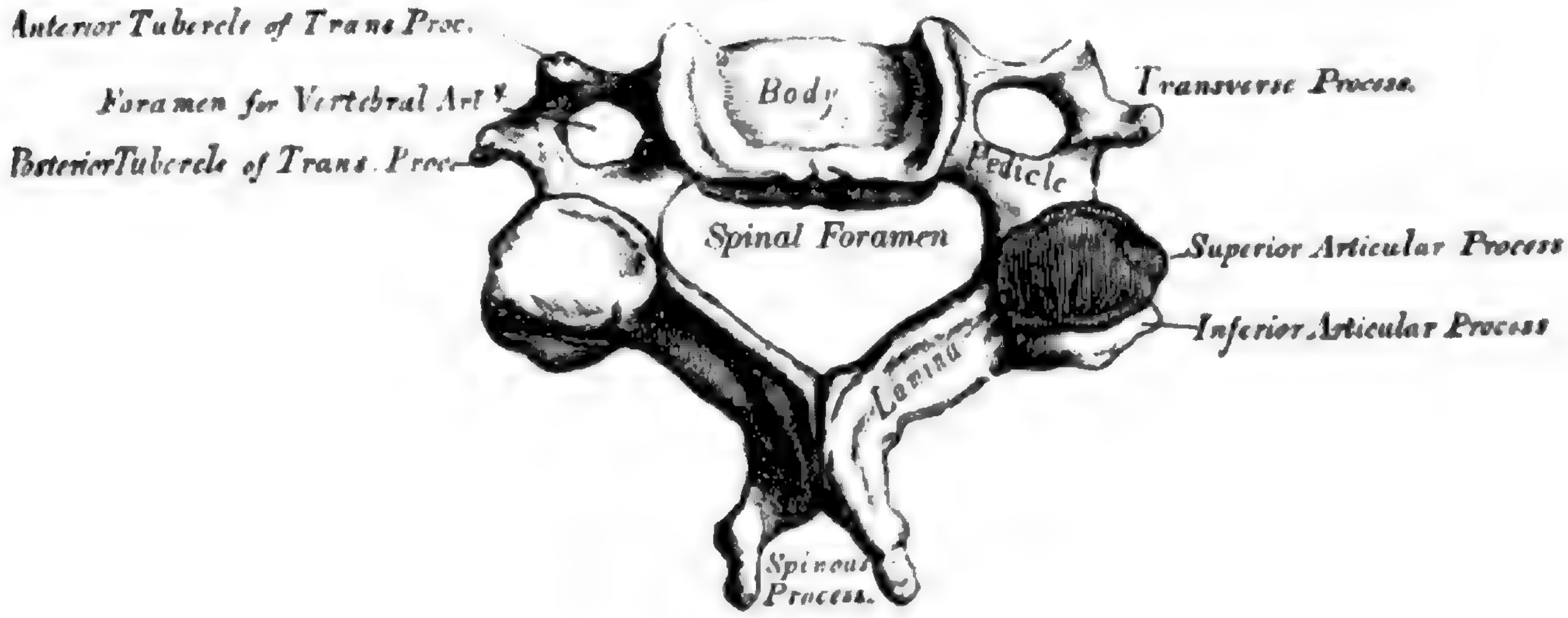
Anterior Tubercle of Trans Proc.
Foramen for Vertebral Art.y
PosteriorTubercle of Trans. Proc.
Body
Transverse Process.
Pedicle
Spinal Foramen
Superior Articular Process
Inferior Articular Process
Lamina
Spinous Process.

Cervical Vertebra.

The *transverse processes* are short, directed downward, outward, and forward, bifid at their extremity, and marked by a groove along their upper surface, which runs downward and outward from the superior intervertebral notch, and serves for the transmission of one of the cervical nerves. They are situated in front of the articular processes and on the outer side of the pedicles. The transverse processes are pierced at their base by a foramen, for the transmission of the vertebral artery, vein, and plexus of nerves. Each process is formed by two roots: the anterior root arises from the side of the body, and is the homologue of the rib in the dorsal region of the spine. The posterior root springs from the junction of the pedicle with the lamina, and corresponds with the transverse processes in the dorsal region. It is by the junction of the two that the foramen for the vertebral vessels is formed. The extremity of each of these roots forms the *anterior* and *posterior tubercles* of the transverse processes.[1] The *articular processes* are oblique: the superior are of an oval form, flattened and directed upward and backward, the inferior downward and forward.

The peculiar vertebræ in the cervical region are the first, or *Atlas;* the second, or *Axis;* and the seventh, or *Vertebra prominens.* The great modifications in the form of the atlas and axis are designed to admit of the nodding and rotatory movements of the head.

The **Atlas** (Fig. 114) is so named from supporting the globe of the head. The chief peculiarities of this bone are that it has neither body nor spinous process. The body is detached from the rest of the bone, and forms the odontoid process of the second vertebra, while the parts corresponding to the pedicles pass in front and join to form the anterior arch. The atlas consists of an anterior arch, a posterior arch, and two lateral masses. The *anterior* arch forms about one-fifth of the bone: its anterior surface is convex, and presents about its centre a *tubercle*, for the attachment of the Longus colli muscle; posteriorly it is concave, and marked by a smooth oval or circular facet, for articulation with the odontoid process of the axis. The upper and lower borders give attachment to ligaments which connect it with the occipital bone above and the axis below. The *posterior* arch forms about two-fifths of the circumference of the bone; it terminates behind in a *tubercle*, which is the rudiment of a spinous process and gives origin to the Rectus capitis posticus minor. The diminutive size of this process prevents any interference in the movements between it and the cranium. The posterior part of the arch presents above and behind a rounded edge for the attachment of a ligament, whilst in front, immediately behind each superior articular process, is a groove, sometimes converted into a foramen by a delicate bony spiculum which arches backward from the posterior extremity of the superior articular process. These grooves represent the superior intervertebral notches, and are peculiar from being situated behind the articular processes, instead of before them, as in the other vertebræ. They serve for the transmission of the vertebral artery, which, ascending through the foramen in the transverse process, winds round the lateral mass in a direction backward and inward.

---

[1] The anterior tubercle of the transverse process of the sixth cervical vertebra is of large size, and is sometimes known as "Chassaignac's, or the carotid tubercle." It is in close relation with the carotid artery, which lies in front and a little external to it; so that, as was first pointed out by Chassaignac, the vessel can with ease be compressed against it.

FIG. 114.

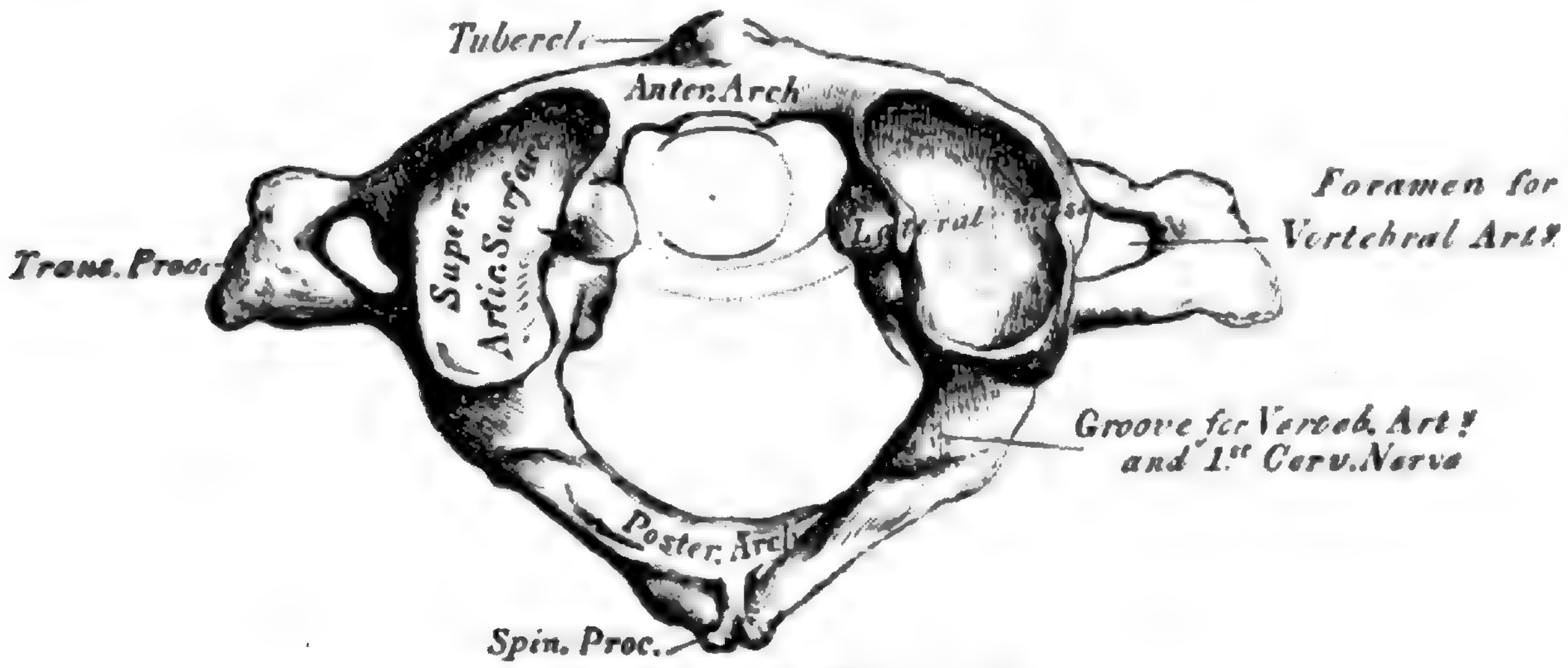

First Cervical Vertebra, or Atlas.

They also transmit the suboccipital nerves. On the under surface of the posterior arch, in the same situation, are two other grooves, placed behind the lateral masses and representing the inferior intervertebral notches of other vertebræ. They are much less marked than the superior. The lower border also gives attachment to a ligament, which connects it with the axis. The *lateral masses* are the most bulky and solid parts of the atlas, in order to support the weight of the head; they present two articulating processes above and two below. The two superior are of large size, oval, concave, and approach toward one another in front, but diverge behind; they are directed upward, inward, and a little backward, forming a kind of cup for the condyles of the occipital bone, and are admirably adapted to the nodding movements of the head. Not unfrequently they are partially subdivided by a more or less deep indentation which encroaches upon each lateral margin. The inferior articular processes are circular in form, flattened or slightly concave, and directed downward and inward, articulating with the axis and permitting the rotatory movements. Just below the inner margin of each superior articular surface is a small tubercle, for the attachment of a ligament which, stretching across the ring of the atlas, divides it into two unequal parts, the anterior or smaller segment receiving the odontoid process of the axis, the posterior allowing the transmission of the spinal cord and its membranes. This part of the spinal canal is of considerable size, to afford space for the spinal cord, and hence lateral displacement of the atlas may occur without compression of the spinal cord. The transverse processes are of large size, project directly outward from the lateral masses, and serve for the attachment of special muscles which assist in rotating the head. They are long, not bifid, and perforated at their base by a canal for the vertebral artery, which is directed from below, upward and backward.

The **Axis** (Fig. 115) is so named from forming the pivot upon which the head rotates. The most distinctive character of this bone is the strong prominent process, tooth-like in form (hence the name *odontoid*), which rises perpendicularly from the upper part of the body. The *body* is of a triangular form, deeper in front than behind, and prolonged downward anteriorly so as to overlap the upper and fore part of the adjacent vertebra. It presents in front a median longitudinal ridge, separating two lateral depressions for the attachment of the Longus colli muscle of either side. The *odontoid process* presents two articulating surfaces: one in front, of an oval form, for articulation with the atlas; another behind, for the transverse ligament, the latter frequently encroaching on the sides of the process. The apex is pointed; just below it the process is somewhat enlarged, and presents on either side a rough impression, for the attachment of the odontoid or check ligaments, which connect it to the occipital bone; the base of the process, where it is attached to the body, is constricted, so as to prevent displacement from the transverse ligament, which binds it in this situation to the anterior arch of the atlas. Sometimes, however, this process does become displaced, especially in children, in whom the ligaments are more relaxed: instant death is the result of this accident. The *pedicles* are broad and strong, especially their anterior extremities, which coalesce with the sides of the body and the root of the odontoid process. The *laminæ* are thick and strong, and the spinal foramen large, but smaller than that of the atlas. The *superior articular surfaces* are round, slightly convex, directed upward and outward, and are peculiar in being supported on the body, pedicles, and transverse processes. The *inferior articular surfaces* have the same direction as those of the other cervical vertebræ. The *superior intervertebral notches* are very shallow, and lie behind the articular processes; the *inferior* in front of them, as in the other cervical vertebræ. The *transverse processes* are very small, not bifid, and perforated by the vertebral foramen or foramen for the vertebral artery, which

FIG. 115.

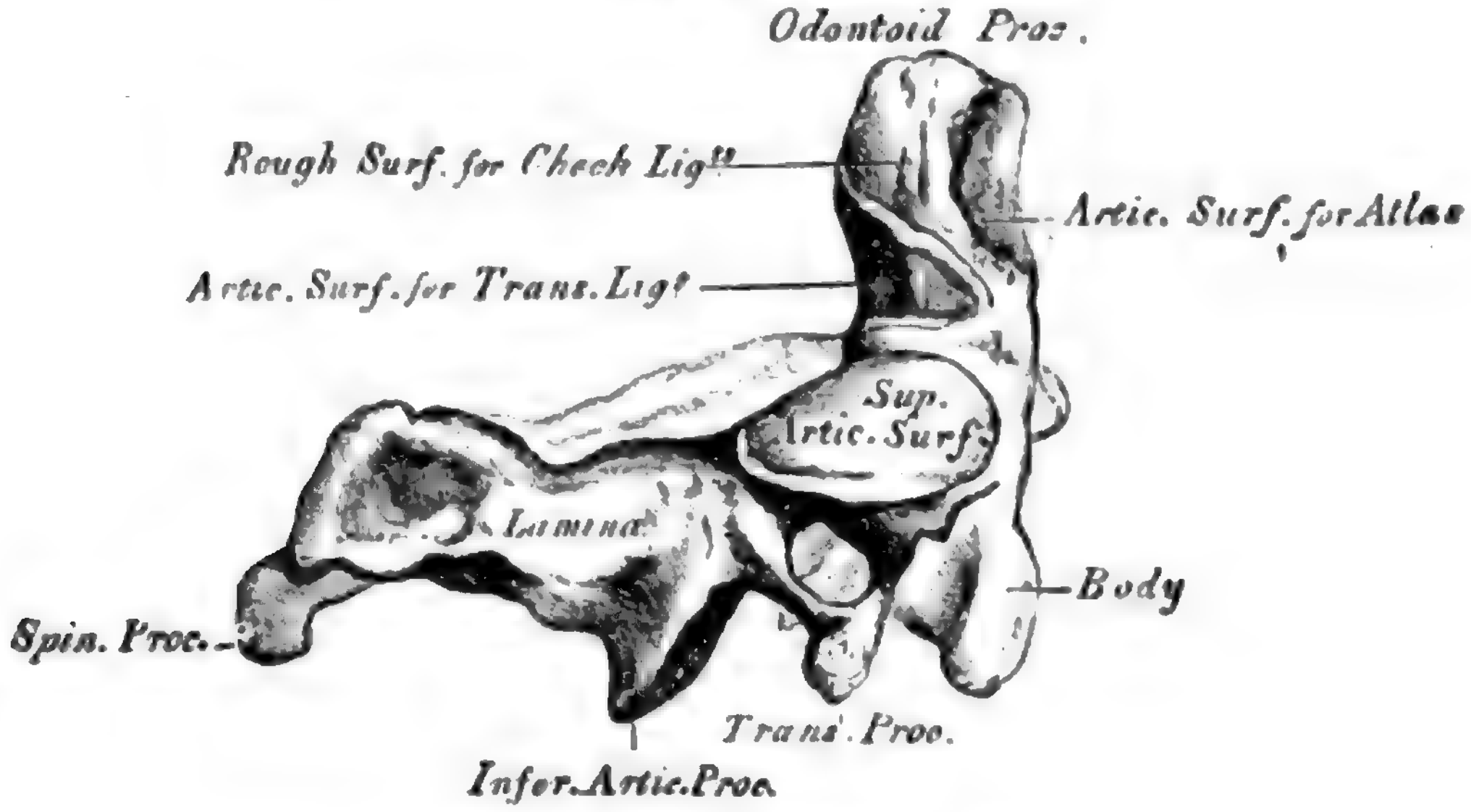

Second Cervical Vertebra, or Axis.

FIG. 116.

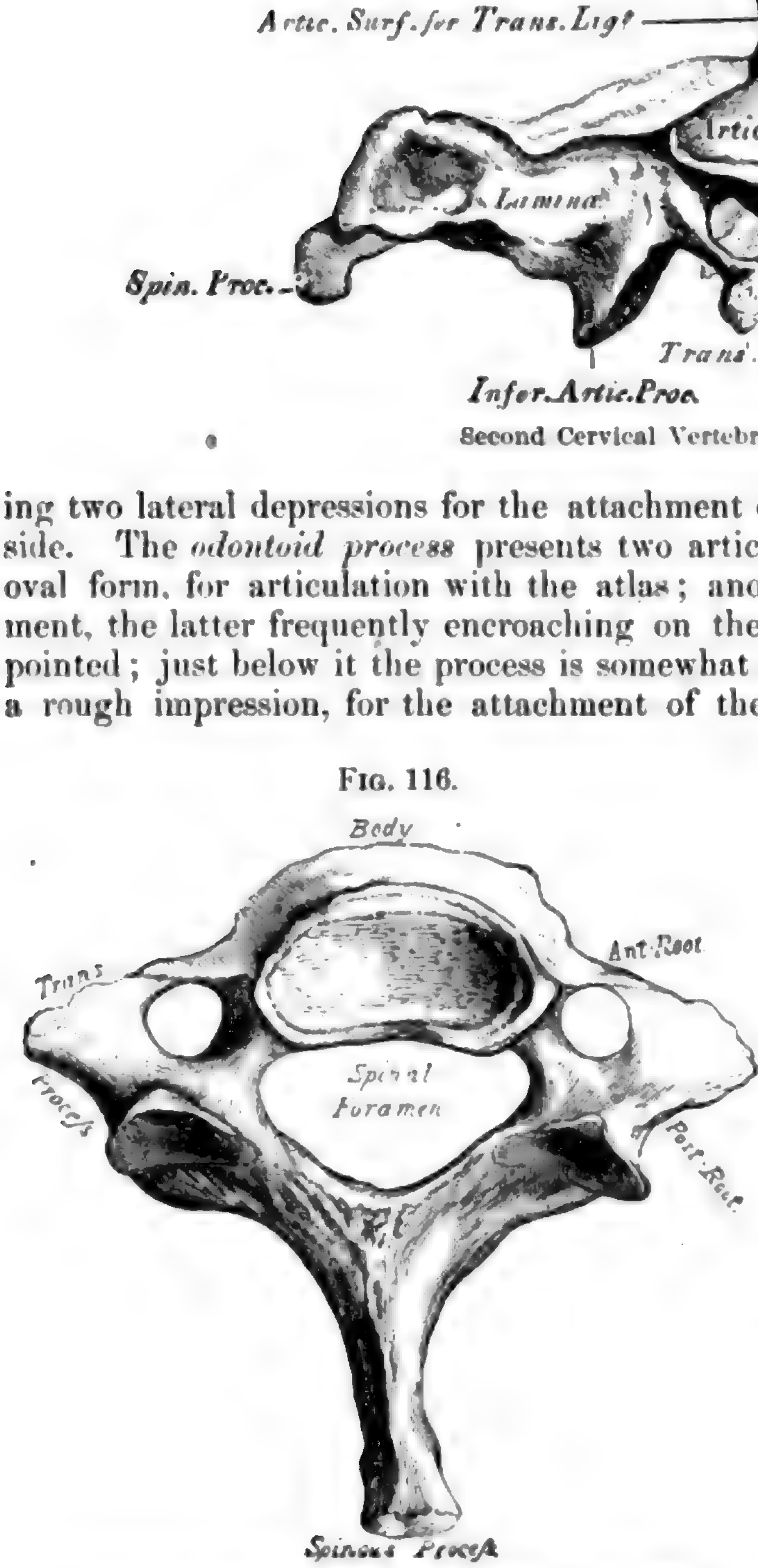

Seventh Cervical Vertebra, or Vertebra Prominens.

is directed obliquely upward and outward. *The spinous process* is of large size, very strong, deeply channelled on its under surface, and presents a bifid tubercular extremity for the attachment of muscles, which serve to rotate the head upon the spine.

Seventh Cervical (Fig. 116).—The most distinctive character of this vertebra is the existence of a very long and prominent spinous process; hence the name "vertebra prominens." This process is thick, nearly horizontal in direction, not bifurcated, and has attached to it the ligamentum nuchæ. [On flexion of the head and neck in the living model this spine, and sometimes those of the sixth cervical and first dorsal, become very prominent.] The *transverse process* is usually of large size, especially its posterior root; its upper surface has usually a shallow groove, and it seldom presents more than a trace of bifurcation at its extremity. [Occasionally the anterior part of the transverse process is developed into a cervical rib.] The vertebral foramen is sometimes as large as in the other cervical vertebræ, [but is] usually smaller on one or both sides, and sometimes wanting. On the left side it occasionally gives passage to the vertebral artery; more frequently the vertebral vein traverses it on both sides; but the usual arrangement is for both artery and vein to pass through the foramen in the transverse process of the sixth cervical. [Occasionally the vessels do not enter the vertebral foramina till they get to the fifth, or even the fourth, vertebra.]

CHARACTERS OF THE DORSAL VERTEBRÆ.

The *bodies* of the dorsal vertebræ resemble those in the cervical and lumbar regions at the respective ends of this portion of the spine; but in the middle of the dorsal region their form is very characteristic, being heart-shaped and as broad in the antero-posterior as in the lateral direction. They are thicker behind than in front, flat above and below, convex and prominent in front, deeply concave behind, slightly constricted in front and at the sides, and marked on each side, near the root of the pedicle, by two demi-facets, one above, the other below. These are covered with cartilage in the recent state, and when articulated with the adjoining vertebræ form, with the intervening fibro-cartilage, oval surfaces for the reception of the heads of the corresponding ribs. The *pedicles* are directed backward, and the

FIG. 117.

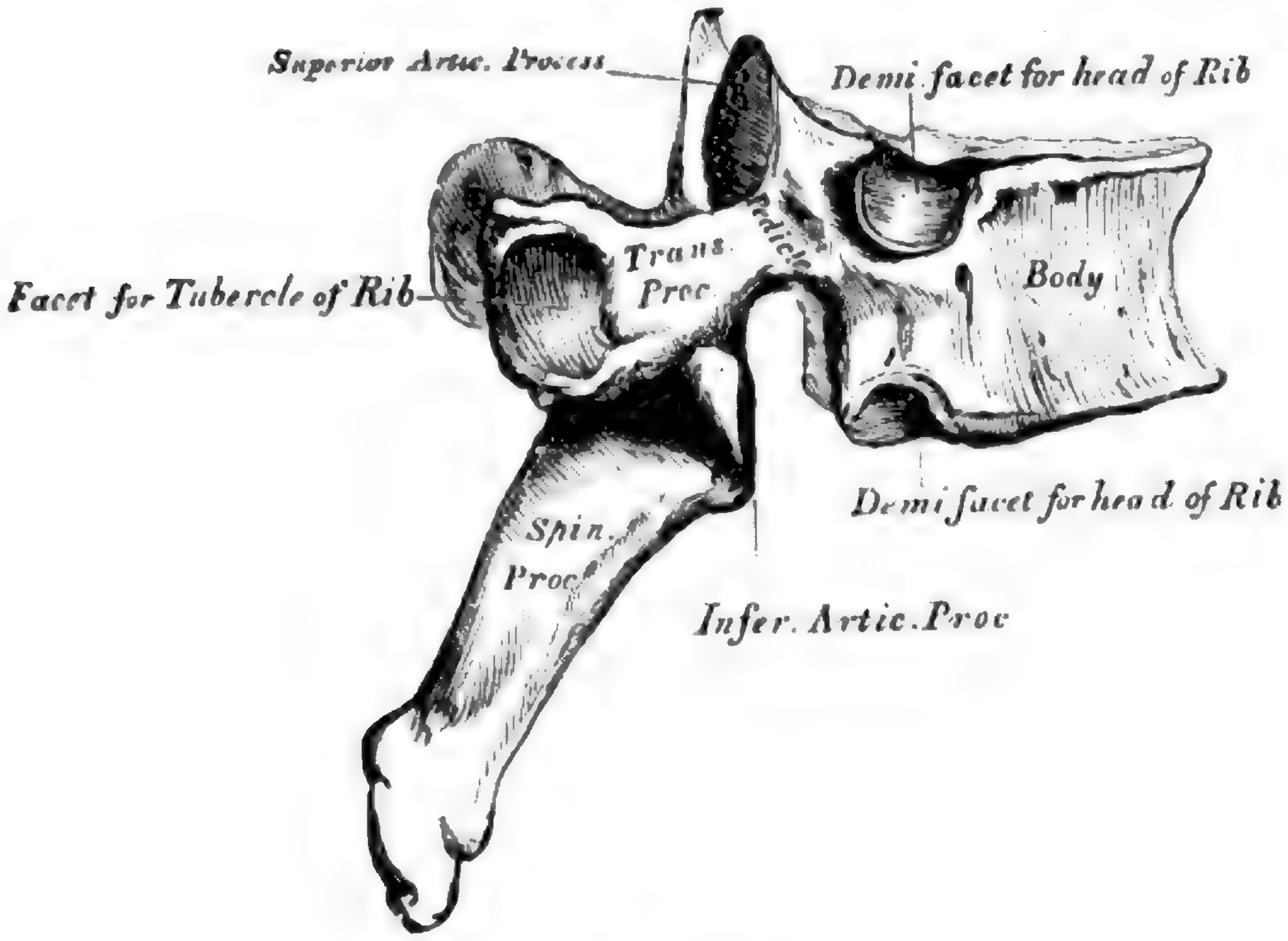
Superior Artic. Process
Demi facet for head of Rib
Facet for Tubercle of Rib
Trans. Proc.
Pedicle
Body
Demi facet for head of Rib
Spin. Proc.
Infer. Artic. Proc.

A Dorsal Vertebra.

inferior intervertebral notches are of large size and deeper than in any other region of the spine. The *laminæ* are broad, thick, and imbricated; that is to say, overlap one another like tiles on a roof. The spinal foramen is small and of a circular form. The *articular processes* are flat, nearly vertical in direction, and project from the upper and lower part of the pedicles, the superior being directed backward and a little outward and upward, the inferior forward and a little inward and downward. The *transverse processes* arise from the same parts of the arch as the posterior roots of the transverse processes in the neck, and are situated behind the articular processes and pedicles; they are thick, strong, and of great length, directed obliquely backward and outward, presenting a clubbed extremity, which is tipped on its anterior part by a small concave surface, for articulation with the tubercle of a rib. Besides the articular facet for the rib, two indistinct tubercles

Fig. 118.

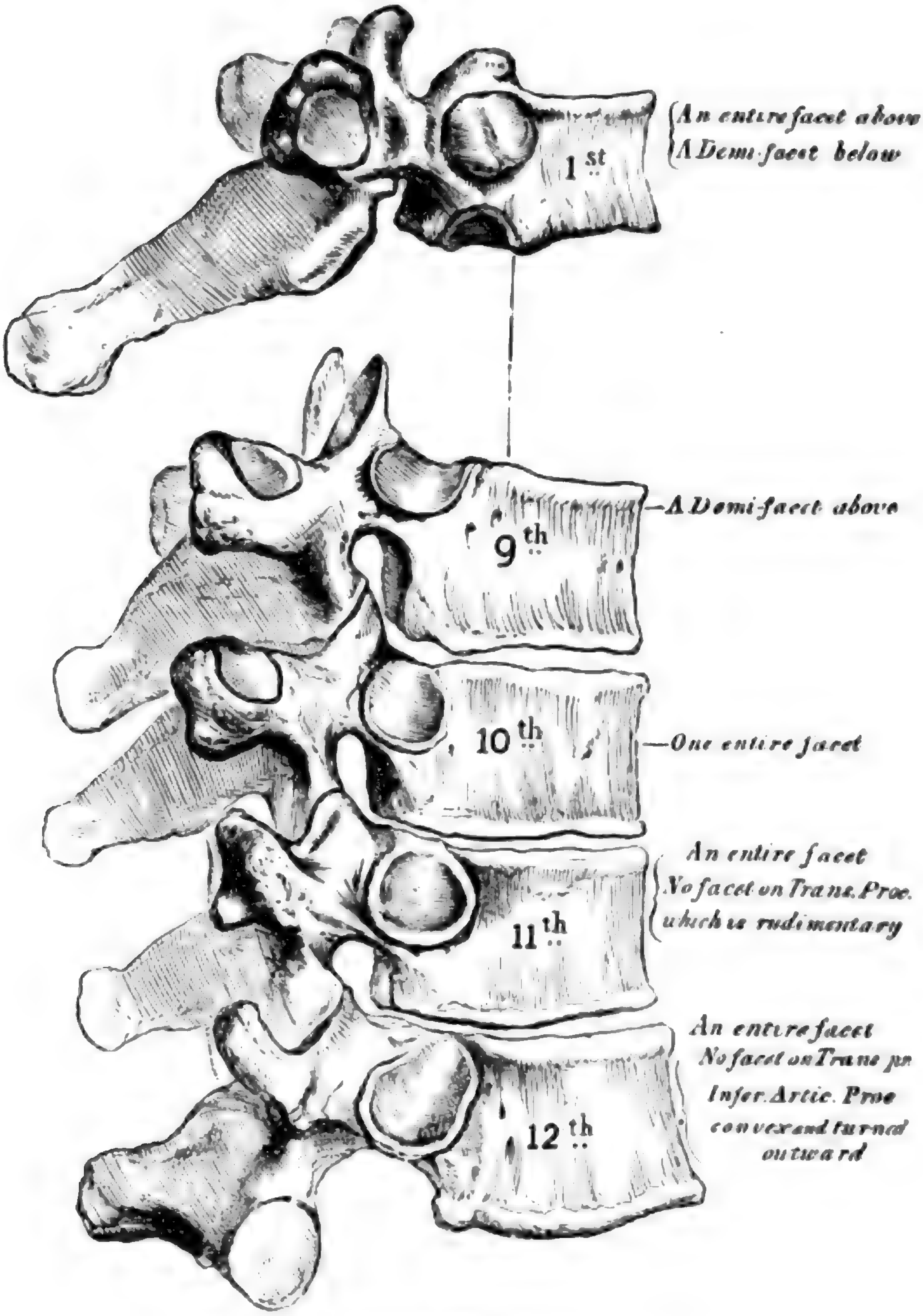
An entire facet above
A Demi-facet below
1st
9th
A Demi-facet above
10th
One entire facet
An entire facet
No facet on Trans. Proc. which is rudimentary
11th
An entire facet
No facet on Trans. pr.
Infer. Artic. Proc. convex and turned outward
12th

Peculiar Dorsal Vertebræ.

may be seen rising from the extremity of the transverse processes, one near the upper, the other near the lower border. In man they are comparatively of small size, and serve only for the attachment of muscles. But in some animals they attain considerable magnitude, either for the purpose of more closely connecting the segments of this portion of the spine or for muscular and ligamentous attachment. The *spinous processes* are long, triangular in form (bayonet-shaped), directed obliquely downward, and terminate in a tubercular extremity. They overlap one another from the fifth to the eighth, but are less oblique in direction above and below.

The peculiar dorsal vertebræ are the *first*, *ninth*, *tenth*, *eleventh*, and *twelfth* (Fig. 118).

The **First Dorsal Vertebra** presents, on each side of the *body*, a single entire articular facet for the head of the first rib, and a half-facet for the upper half of the second. The upper surface of the body is like that of a cervical vertebra, being broad, transversely concave, and lipped on each side. The *articular surfaces* are oblique, and the *spinous process* thick, long, and almost horizontal.

The **Ninth Dorsal** has no demi-facet below. In some subjects, however, the ninth has two demi-facets on each side; then the tenth has a demi-facet at the upper part, none below.

The **Tenth Dorsal** has (except in the cases just mentioned) an entire articular facet on each side above, which is partly placed on the outer surface of the pedicle. It has no demi-facet below.

In the **Eleventh Dorsal** the body approaches in its form and size to the lumbar. The articular facets for the heads of the ribs, one on each side, are of large size, and placed chiefly on the pedicles, which are thicker and stronger in this and the next vertebra than in any other part of the dorsal region. The *transverse* processes are very short, tubercular at their extremities, and have no articular facets for the tubercles of the ribs. The spinous process is short, nearly horizontal in direction, and presents a slight tendency to bifurcation at its extremity.

The **Twelfth Dorsal** has the same general characters as the eleventh, but may be distinguished from it by the inferior articular processes being convex and turned outward, like those of the lumbar vertebræ; by the general form of the body, laminæ, and spinous process, approaching to that of the lumbar vertebræ; and by the transverse processes being shorter, and marked by three elevations, the superior, inferior, and external tubercles, which correspond to the mammillary, accessory, and transverse processes of the lumbar vertebræ. Traces of similar elevations are usually to be found upon the other dorsal vertebræ. (*Vide antea.*)

CHARACTERS OF THE LUMBAR VERTEBRÆ.

The **Lumbar Vertebræ** (Fig. 119) are the largest segments of the vertebral column. The *body* is large, broader from side to side than from before backward, slightly thicker in front than behind, flattened or slightly concave above and below, concave behind, and deeply constricted in front and at the sides, presenting prominent margins, which afford a broad basis for the support of the superincumbent weight. The *pedicles* are very strong, directed backward from the upper part of the bodies; consequently the inferior intervertebral notches are of large size. The *laminæ* are short, but broad and strong, and the foramen triangular, larger than in the dorsal, smaller than in the cervical region. The *superior articular processes* are concave, and look almost directly inward; the *inferior*, convex, look outward and a little forward: the former are separated by a much wider interval than the latter, embracing the lower articulating processes of the vertebra above. The *transverse processes* are long, slender, directed transversely outward in the upper three lumbar vertebræ, slanting a little upward in the lower two. They are situated in front of the articular processes, instead of behind them, as in the dorsal vertebræ, and are by some anatomists considered homologous with the ribs. Of the two tubercles noticed in connection with the transverse processes in the dorsal region, the superior ones become connected in this region with the back part of the superior articular processes, and have received the name of *mammillary* processes; the inferior are represented by a small process pointing downward, situated at the back part of the base of the transverse process, and called the *accessory* processes. Although in man these are comparatively small, in some animals they attain considerable size, and serve to lock the vertebræ more closely together. The *spinous processes* are thick and broad, somewhat quadrilateral, horizontal in direction, thicker below than above, and terminate by a rough, uneven border.

Fig. 119.

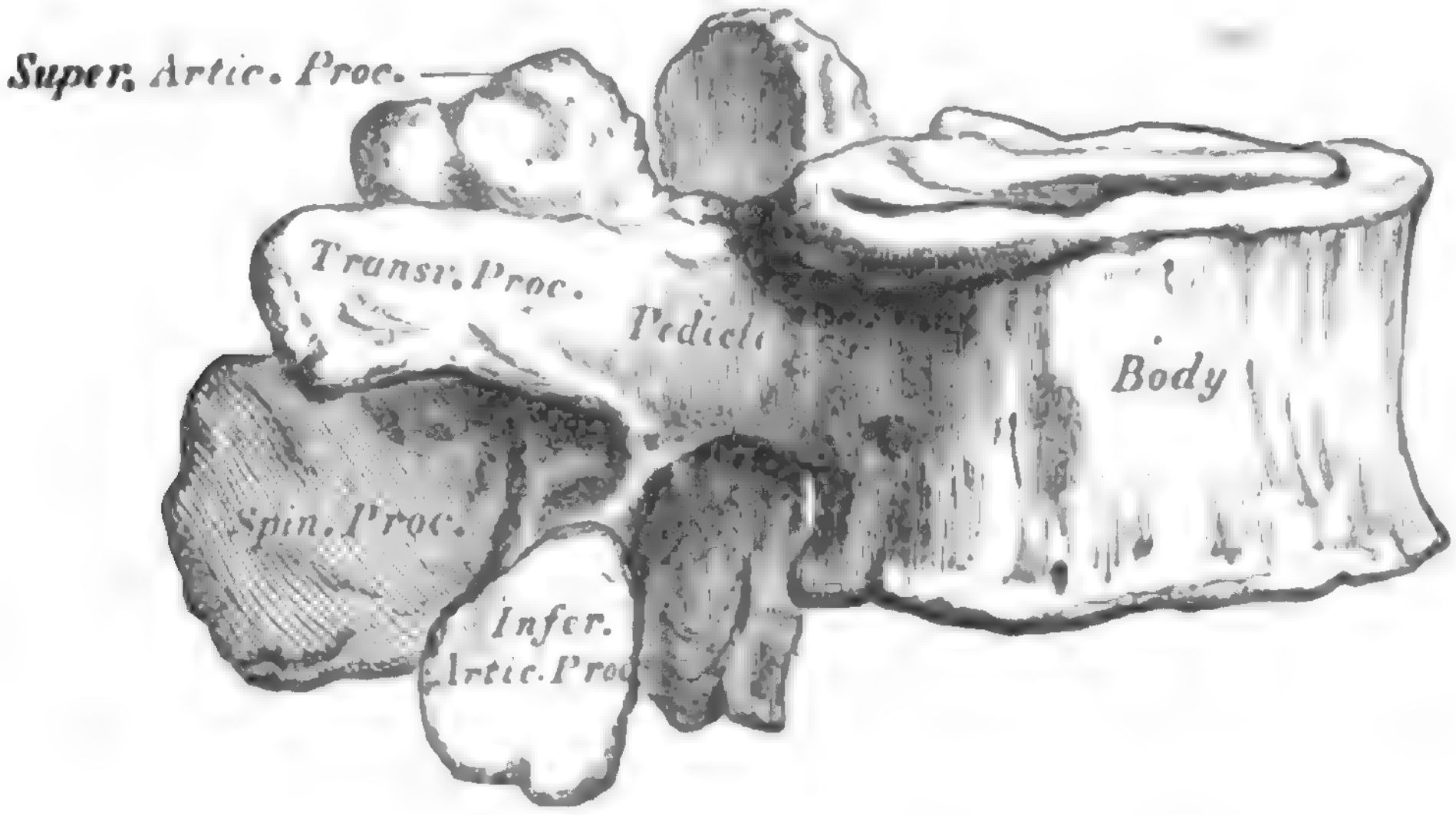

Lumbar Vertebra.

The **Fifth Lumbar Vertebra** is characterized by having the body much thicker in front than behind, which accords with the prominence of the sacro-vertebral articulation; by the smaller size of its spinous process; by the wide interval between the inferior articulating processes; and by the greater size and thickness of its transverse processes.

Structure of the Vertebræ.—The structure of a vertebra differs in different parts. The body is composed of light spongy cancellous tissue, having a thin coating of compact tissue on its external surface, perforated by numerous orifices, some of large size, for the passage of vessels; its interior is traversed by one or two large canals for the reception of veins, which converge toward a single large irregular aperture or several small apertures at the posterior part of the body of each bone. The arch and processes projecting from it have, on the contrary, an exceedingly thick covering of compact tissue.

Development.—Each vertebra is formed of three primary cartilaginous portions (Fig. 120)—one for each lamina and its processes, and one for the body. Ossification commences in the laminæ about the sixth week of fœtal life, in the situation where the transverse processes afterward project, the ossific granules shooting backward to the spine, forward to the body, and outward into the transverse and articular processes. Ossification in the body commences in the middle of the cartilage about the eighth week. According to some authors, ossification commences in the laminæ only in the upper vertebræ—*i. e.* in the cervical and upper dorsal. The first ossific point in the lower vertebræ is that which is to form the body, the osseous centres for the laminæ appearing at a subsequent period. At birth these three pieces are perfectly separate. During the first year the laminæ become united behind by a portion of cartilage in which the spinous process is ultimately formed, and thus the arch is completed. About the third year the body is joined to the arch on each side in such a manner that the body is formed from the three original centres of ossification, the amount contributed by the pedicles increasing in extent from below upward. Thus the bodies of the sacral vertebræ are formed almost entirely from the central nuclei; the bodies of the lumbar are formed laterally and behind by the pedicles: in the dorsal region the pedicles advance as far forward as the articular depressions for the head of the ribs, forming these cavities of reception, and in the neck the lateral portions of the bodies are formed entirely by the advance of the pedicles. Before puberty no other changes occur, excepting a gradual increase in the growth of these primary centres, the upper and under surfaces of the bodies and the ends of the transverse and spinous processes being tipped with cartilage, in which ossific granules are not as yet deposited. At sixteen years (Fig. 121) four secondary centres appear—one for the tip of each transverse process, and two (sometimes united into one) for the end of the spinous process. At twenty-one years (Fig. 122) a thin circular epiphysial plate of bone is formed in the layer of cartilage situated on the upper and under surfaces of the body, the former being the thicker of the two. All these become joined, and the bone is completely formed about the thirtieth year of life.

Fig. 120.

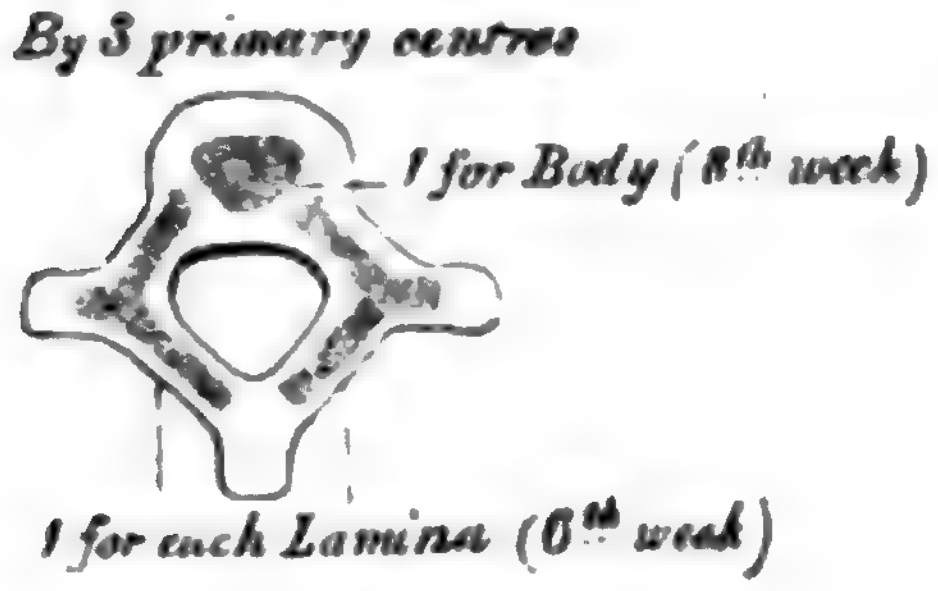
By 3 primary centres
1 for Body (8th week)
1 for each Lamina (6th week)

Fig. 121.

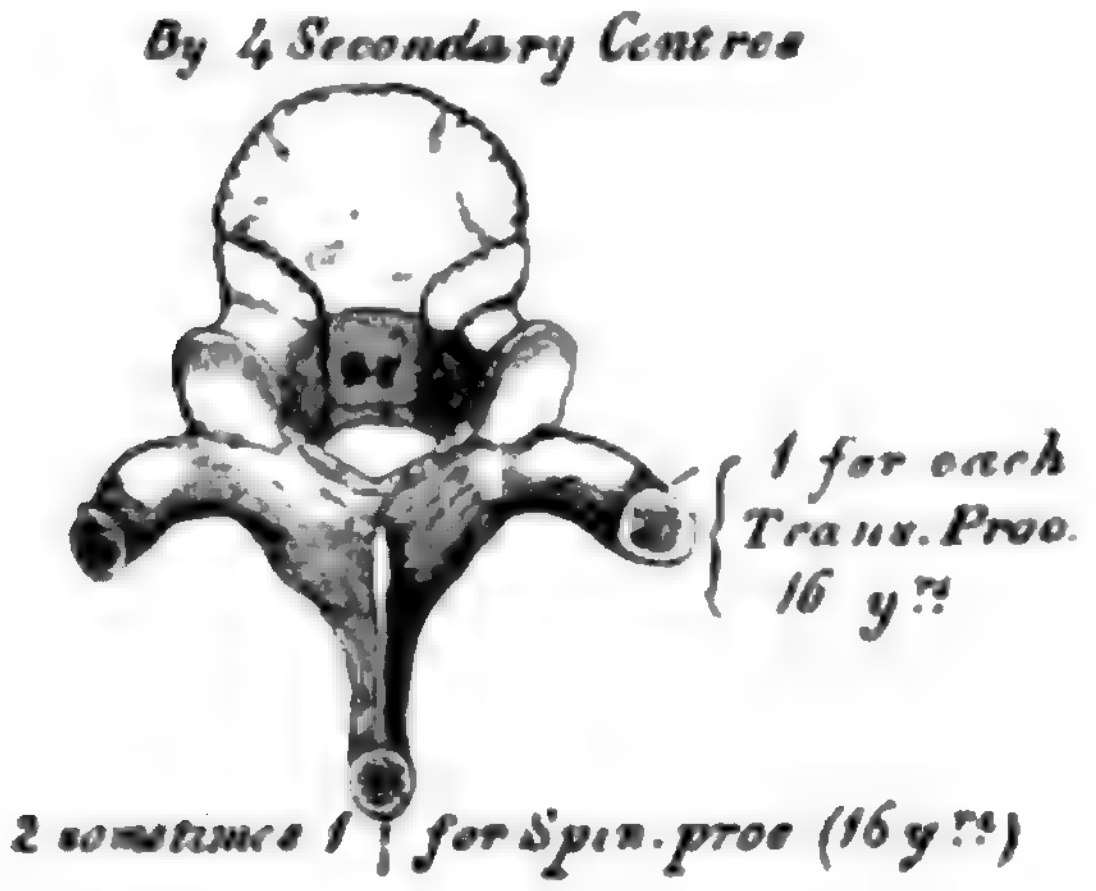
By 4 Secondary Centres
1 for each Trans. Proc. 16 yrs
2 sometimes 1 for Spin. proc (16 yrs)

Fig. 122.


By 2 additional plates
1 for upper surface of body
1 for under surface of body
21 yrs

Development of a Vertebra.

Fig. 123.

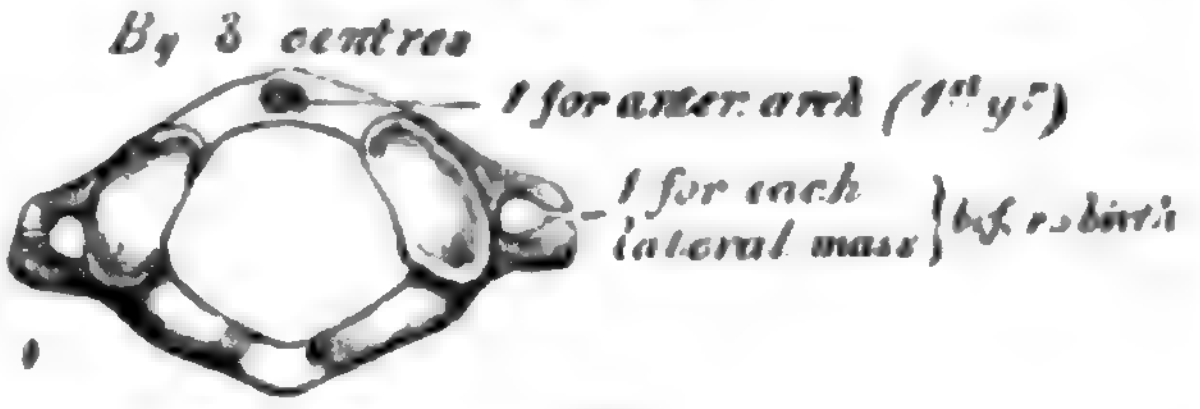
By 3 centres
1 for anter. arch (1st yr)
1 for each lateral mass } bef. birth

Atlas.

Fig. 124.

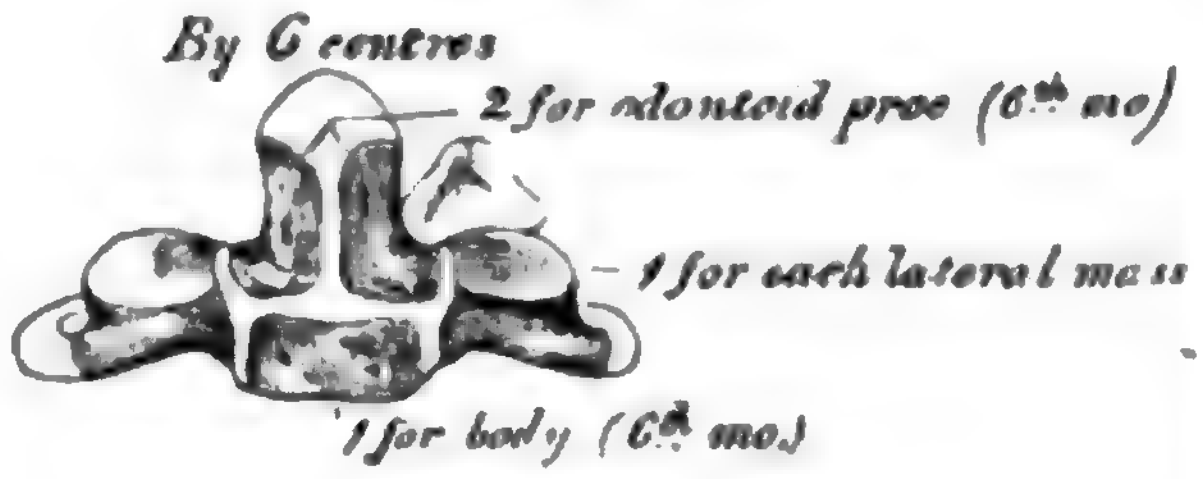
By 6 centres
2 for odontoid proc (6th mo)
1 for each lateral mass
1 for body (6th mo)

Axis.

Fig. 125.

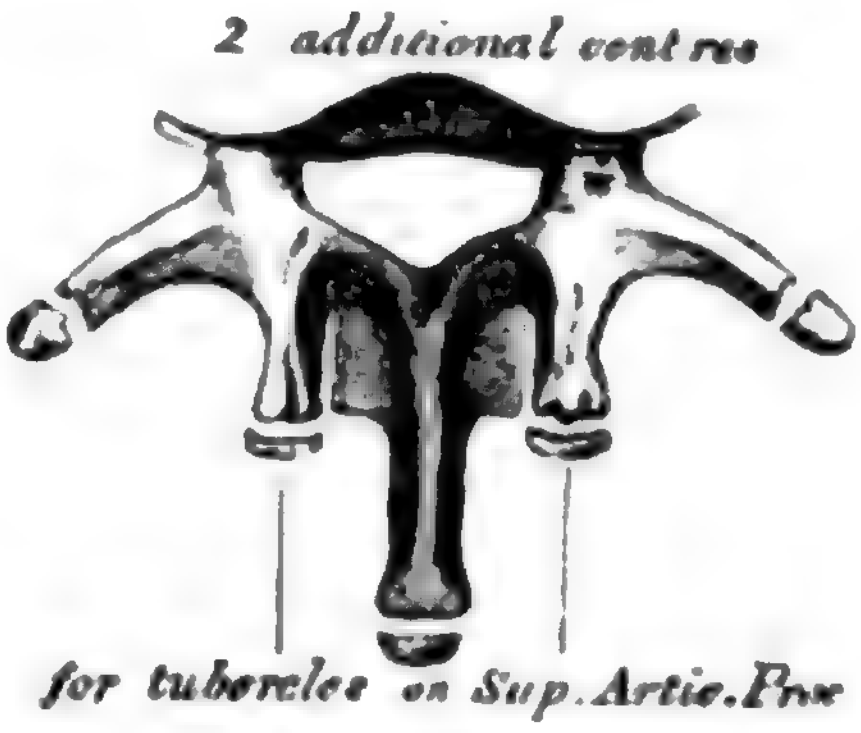
2 additional centres
for tubercles on Sup. Artic. Proc

Lumbar Vertebra.

Exceptional cases.

Exceptions to this mode of development occur in the first, second, and seventh cervical, and in the vertebræ of the lumbar region.

The **Atlas** (Fig. 123) is developed by *two* primary centres and by *one* or more epiphyses. The two primary centres are destined for the two lateral or neural masses, the ossification of which commences generally about the eighth week, near the articular processes, and extends backward: these portions of bone are separated from one another behind, at birth, by a narrow interval filled in with cartilage. Between the second and third years they unite, either directly or through the medium of an epiphysial centre developed in the cartilage near their point of junction. The anterior arch at birth is altogether cartilaginous, and this portion of the atlas is completed by the gradual extension forward and ultimate junction of the two neural processes. Occasionally, a separate nucleus, which appears about the end of the first year after birth, is developed in the anterior arch, which, extending laterally, joins the neural processes in front of the pedicles; or there are two nuclei developed in the anterior arch, one on either side of the median line, which join to form a single mass, afterward united to the lateral portions in front of the articulating processes.

The **Axis** (Fig. 124) is developed by *six* centres. The body and arch of this bone are formed in the same manner as the corresponding parts in the other vertebræ—one centre for the lower part of the body and one for each lamina. The odontoid process consists originally of an extension upward of the cartilaginous mass in which the lower part of the body is formed. At about the sixth month of fœtal life two osseous nuclei make their appearance in the base of this process: they are placed laterally, and join before birth to form a conical bilobed mass deeply cleft above: the interval between the cleft and the summit of the process is formed by a wedge-shaped piece of cartilage, the base of the process being separated from the body by a cartilaginous interval which gradually becomes ossified, sometimes by a separate epiphysial nucleus. Finally, as Dr. Humphry has demonstrated, the apex of the odontoid process has a separate nucleus.

The Seventh Cervical.—The anterior or costal part of the transverse process of the seventh cervical is developed from a separate osseous centre at about the sixth month of fœtal life, and joins the body and posterior division of the transverse process between the fifth and sixth years. Sometimes this process continues as a separate piece, and, becoming lengthened outward, constitutes what is known as a cervical rib.

The **Lumbar Vertebræ** (Fig. 125) have *two additional centres* (besides those peculiar to the vertebræ generally) for the mammillary tubercles, which project from the back part of the superior articular processes. The transverse process of the first lumbar is sometimes developed as a separate piece, which may remain permanently unconnected with the remaining portion of the bone, thus forming a lumbar rib—a peculiarity which is rarely met with.

Progress of Ossification of the Spine generally.—Ossification of the laminæ of the vertebræ commences at the upper part of the spine, and proceeds gradually downward; hence the frequent occurrence of spina bifida in the lower part of the spinal column [from non-union posteriorly of the two centres for the laminæ]. Ossification of the bodies, on the other hand, commences a little below the centre of the spinal column (about the ninth or tenth dorsal vertebra), and extends both upward and downward. Although, however, the ossific nuclei make their first appearance in the lower dorsal vertebræ, the lumbar and first sacral are those in which these nuclei are largest at birth.

Attachment of Muscles.—To the *Atlas* are attached nine pairs: the Longus colli, Rectus anticus minor, Rectus lateralis, Rectus posticus minor, Obliquus superior and inferior, Splenius colli, Levator anguli scapulæ, and First Intertransverse.

To the *Axis* are attached eleven pairs: the Longus colli, Obliquus inferior, Rectus posticus major, Semispinalis colli, Multifidus spinæ, Levator anguli scapulæ, Splenius colli, Scalenus medius, Transversalis colli, Intertransversales, Interspinales.

To the remaining vertebræ generally are attached thirty-five pairs and a single muscle: *anteriorly*, the Rectus anticus major, Longus colli, Scalenus anticus, medius, and posticus, Psoas magnus, Psoas parvus, Quadratus lumborum, Diaphragm, Obliquus internus, and Transversalis; *posteriorly*, the Trapezius, Latissimus dorsi, Levator anguli scapulæ, Rhomboideus major and minor, Serratus posticus superior and inferior, Splenius, Erector spinæ, Sacro-lumbalis, Longissimus dorsi, Spinalis dorsi, Cervicalis ascendens, Transversalis colli, Trachelo-mastoid, Complexus, Biventer cervicis, Semispinalis dorsi and colli, Multifidus spinæ, Rotatores spinæ, Interspinales, Supraspinales, Intertransversales, Levatores costarum.

SACRAL AND COCCYGEAL VERTEBRÆ.

The **Sacral** and **Coccygeal Vertebræ** consist, at an early period of life, of nine separate pieces, which are united in the adult so as to form two bones, five entering into the formation of the sacrum, four into that of the coccyx. Occasionally the coccyx consists of five bones.[1]

The **Sacrum** (*sacrus*, sacred) is a large triangular bone (Fig. 126) situated at the lower part of the vertebral column and at the upper and back part of the pelvic cavity, where it is inserted like a wedge between the two innominate bones, its upper part, or base, articulating with the last lumbar vertebra, its apex with the coccyx. The sacrum is curved upon itself, and placed very obliquely, its upper extremity projecting forward, and forming, with the last lumbar vertebra, a very prominent angle called the *promontory* or *sacro-vertebral angle*, whilst its central part is directed backward, so as to give increased capacity to the pelvic cavity. It presents for examination an anterior and posterior surface, two lateral surfaces, a base, an apex, and a central canal.

---

[1] Dr. Humphry describes this as the usual composition of the coccyx (*On the Skeleton*, p. 456).

FIG. 126

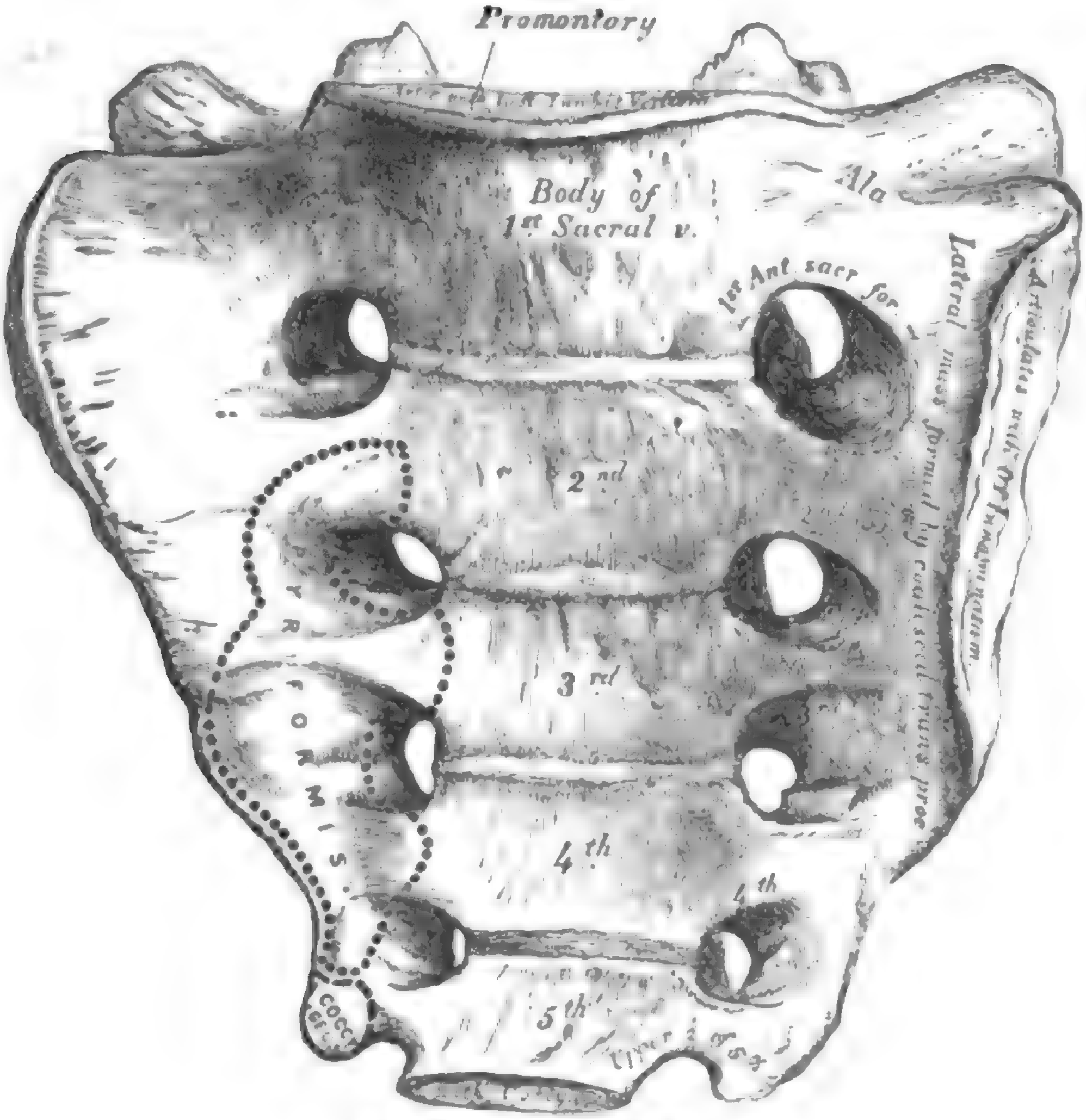

Sacrum, anterior surface.

The **anterior surface** is concave from above downward, and slightly so from side to side. In the middle are seen four transverse ridges, indicating the original division of the bone into five separate pieces. The portions of bone intervening between the ridges correspond to the bodies of the vertebræ. The body of the first segment is of large size, and in form resembles that of a lumbar vertebra; the succeeding ones diminish in size from above downward, are flattened from before backward, and are curved so as to accommodate themselves to the form of the sacrum, being concave in front, convex behind. At each end of the ridges above mentioned are seen the *anterior sacral foramina*, analogous to the intervertebral foramina, four in number on each side, somewhat rounded in form, diminishing in size from above downward, and directed outward and forward; they transmit the anterior branches of the sacral nerves. External to these foramina is the *lateral mass*, consisting, at an early period of life, of separate segments; these become blended in the adult with the bodies, with each other, and with the posterior transverse processes. Each lateral mass is traversed by four broad shallow grooves which lodge the anterior sacral nerves as they pass outward, the grooves being separated by prominent ridges of bone which give attachment to the slips of the Pyriformis muscle.

If a vertical section is made through the centre of the bone (Fig. 127), the bodies are seen to be united at their circumference by bone, a wide interval being left centrally, which, in the recent state, is filled by intervertebral substance. In some bones this union is more complete between the lower segments than between the upper ones.

Fig. 127.

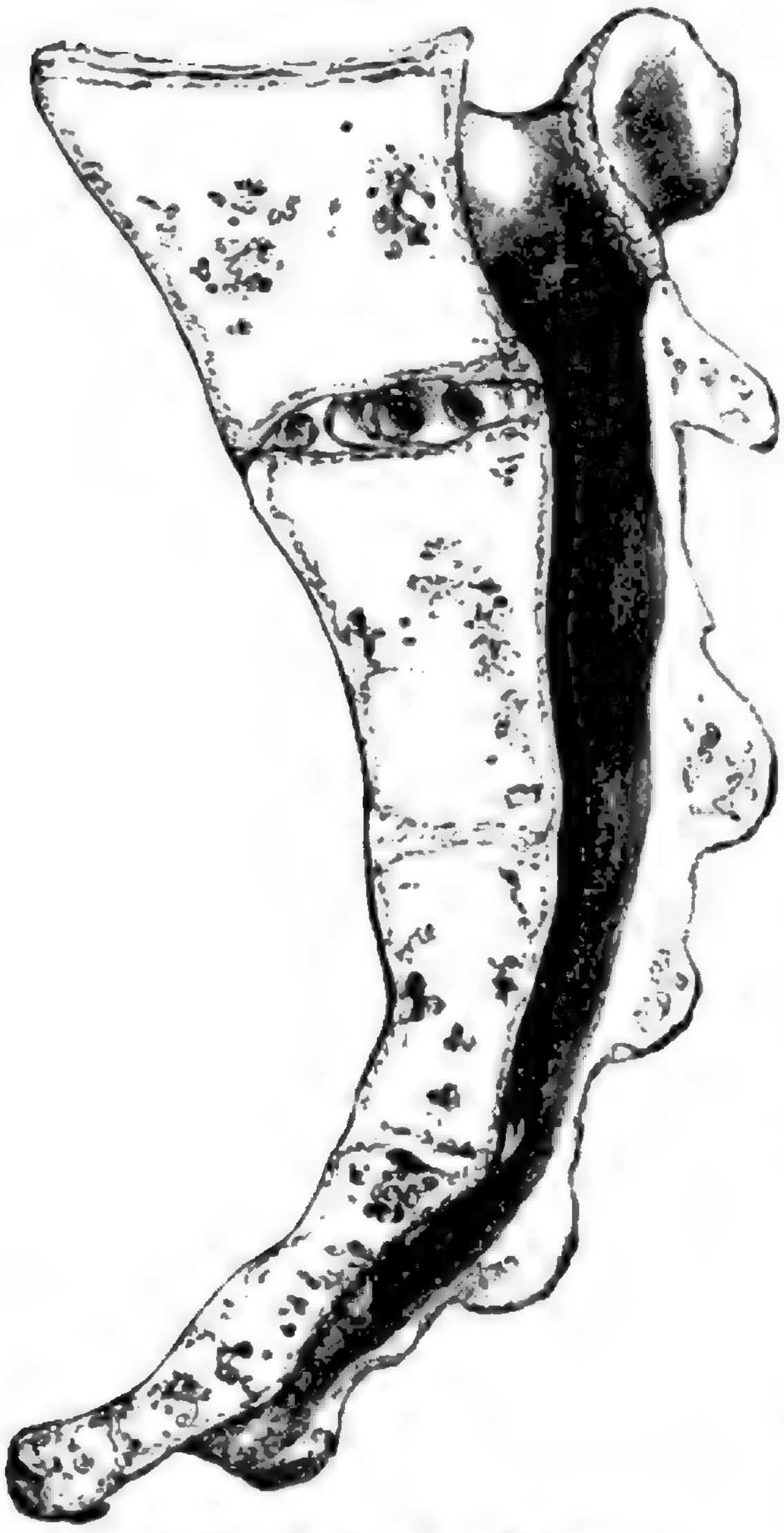

Vertical Section of the Sacrum.

The **posterior surface** (Fig. 128) is convex, and much narrower than the anterior. In the middle line are three or four tubercles, which represent the rudimentary spinous processes of the sacral vertebræ. Of these tubercles, the first is usually prominent and perfectly distinct from the rest; the second and third are either separate or united into a tubercular ridge, which diminishes in size from above downward; the fourth usually, and the fifth always, remaining undeveloped. External to the spinous processes on each side are the *laminæ*, broad and well marked in the first three pieces, sometimes the fourth, and generally the fifth, being undeveloped; in this situation the lower end of the sacral canal is exposed. [In severe bed-sores this canal is sometimes opened here by sloughing, and may be followed by spinal meningitis, etc.] External to the laminæ is a linear series of indistinct tubercles representing the *articular processes;* the upper pair are large, well-developed, and correspond in shape and direction to the superior articulating processes of a lumbar vertebra; the second and third are small; the fourth and fifth (usually blended together) are situated on each side of the sacral canal: they are called the *sacral cornua*, and articulate with the cornua of the coccyx. External to the articular processes are the four *posterior sacral foramina;* they are smaller in size and less regular in form than the anterior, and transmit the posterior branches of the sacral nerves. On the outer side of the posterior sacral foramina is a series of tubercles, the rudimentary *transverse processes* of the sacral vertebræ. The first pair of transverse tubercles are of large size, very distinct, and correspond with each superior angle of the bone; the second, small in size, enter into the formation of the sacro-iliac articulation; the third give attachment to the oblique fasciculi of the posterior sacro-iliac ligaments, and the fourth and fifth to the great sacro-sciatic ligaments. The interspace between the spinous and transverse processes on the back of the sacrum presents a wide shallow concavity called the *sacral groove:* it is continuous above with the vertebral groove, and lodges the origin of the Erector spinæ.

The **lateral surface,** broad above, becomes narrowed into a thin edge below. Its upper half presents in front a broad ear-shaped surface for articulation with the ilium. This is called the *auricular* surface, and in the fresh state is coated with fibro-cartilage. It is bounded posteriorly by deep and uneven impressions, for the attachment of the posterior sacro-iliac ligaments. The lower half is thin and sharp, and gives attachment to the greater and lesser sacro-sciatic ligaments, and to some fibres of the Gluteus maximus; below, it presents a deep notch, which is converted into a foramen by articulation with the transverse process of the upper piece of the coccyx, and transmits the anterior branch of the fifth sacral nerve.

The **base** of the sacrum, which is broad and expanded, is directed upward and forward. In the middle is seen an oval articular surface which corresponds with the under surface of the body of the last lumbar vertebra, bounded behind by the large triangular orifice of the sacral canal. This orifice is formed behind by the spinous process and laminæ of the first sacral vertebra, whilst projecting from it on each side are the superior articular processes: they are oval, concave, directed backward and inward, like the superior articular processes of a lumbar vertebra; and in front of each articular process is an intervertebral notch which forms the lower half of the last intervertebral foramen. Lastly, on each side of the oval articular surface is a broad and flat triangular surface of bone which extends outward, supports the Psoas magnus muscle and lumbo-sacral cord, and is continuous on each side with the iliac fossa. This is called the *ala* of the sacrum, and gives attachment to a few of the fibres of the Iliacus muscle.

FIG. 128.

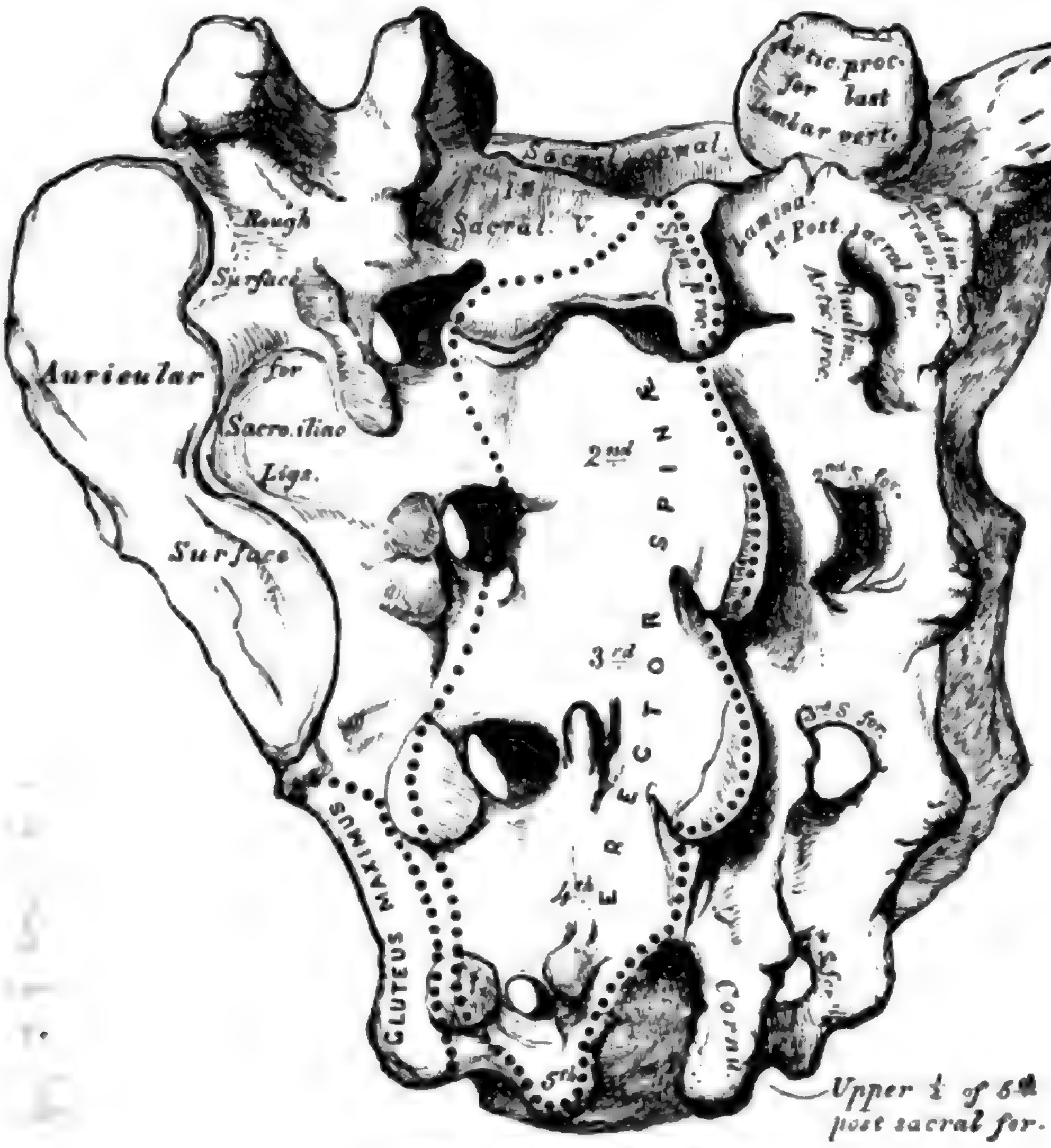
Artic. proc. for last lumbar vert.
Sacral canal.
1st Sacral V.
Rough Surface
Auricular for Sacro-iliac Ligs. Surface
Spinous proc.
Lamina 1st Post. sacral for.
Rudim. Transv. proc.
Rudim. Artic. proc.
2nd
3rd
4th
5th
2nd S. for.
3rd S. for.
4th S. for.
ERECTOR SPINÆ
GLUTEUS MAXIMUS
Cornu
Upper ½ of 5th post sacral for.

Sacrum, posterior surface.

The **apex**, directed downward and forward, presents a small oval concave surface for articulation with the coccyx.

The **Sacral** [*i. e.* **Spinal**] **Canal** runs throughout the greater part of the bone; it is large and triangular in form above, small and flattened from before backward below. In this situation its posterior wall is incomplete, from the non-development of the laminæ and spinous processes. It lodges the sacral nerves, and is perforated by the anterior and posterior sacral foramina, through which these pass out.

Structure.—It consists of much loose, spongy tissue within, invested externally by a thin layer of compact tissue.

Differences in the Sacrum of the Male and Female.—The sacrum in the female is usually wider than in the male, and it is much less curved, the upper half of the bone being nearly straight, the lower half presenting the greatest amount of curvature. The bone is also directed more obliquely backward, which increases the size of the pelvic cavity and forms a more prominent sacro-vertebral angle. In the male the curvature is more evenly distributed over the whole length of the bone, and is altogether greater than in the female.

Peculiarities of the Sacrum.—This bone, in some cases, consists of six pieces; occasionally, the number is reduced to four. Sometimes the bodies of the first and second segments are not joined, or the laminæ and spinous processes have not coalesced. Occasionally, the upper pair of transverse tubercles are not joined to the rest of the bone on one or both sides; and lastly, the sacral canal may be open for nearly the lower half of the bone, in consequence of the imperfect development of the laminæ and spinous processes. The sacrum also varies considerably with respect to its degree of curvature. From the examination of a large number of skeletons it would appear that in one set of cases the anterior surface of this bone was nearly straight, the curvature, which was very slight, affecting only its lower end. In another set of cases the bone was curved throughout its whole length, but especially toward its middle. In a third set the degree of curvature was less marked, and affected especially the lower third of the bone.

Fig. 129.

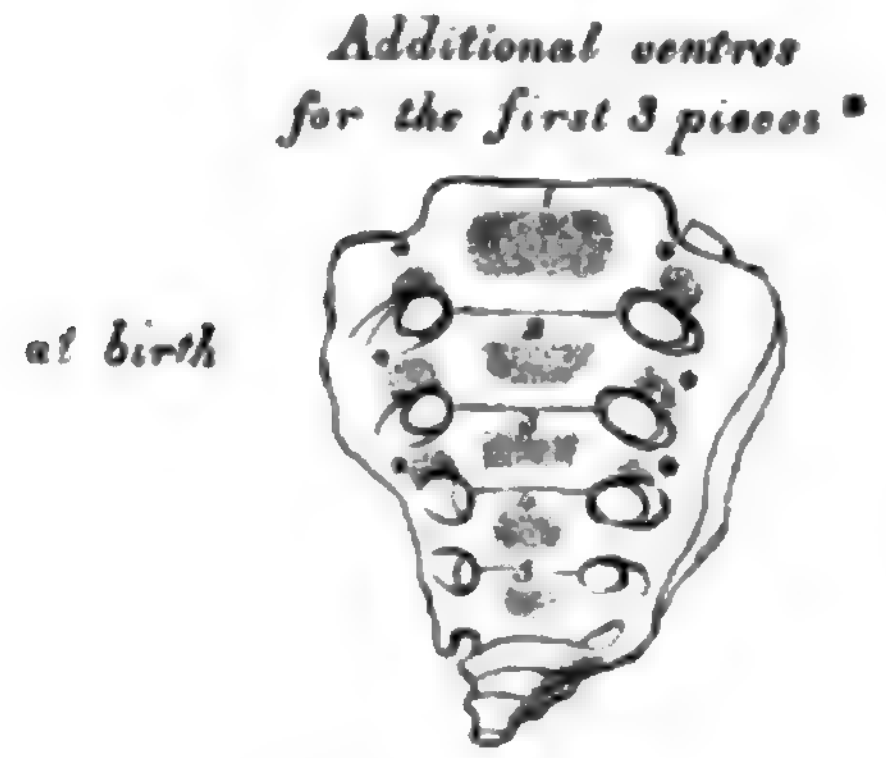

Fig. 130.

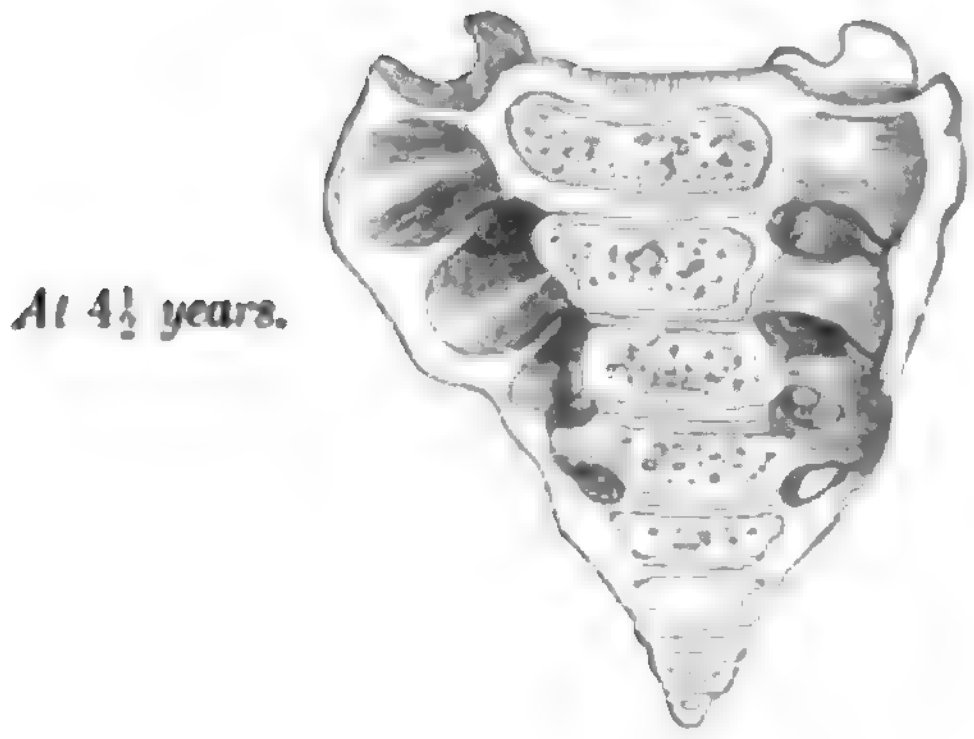

Fig. 131.

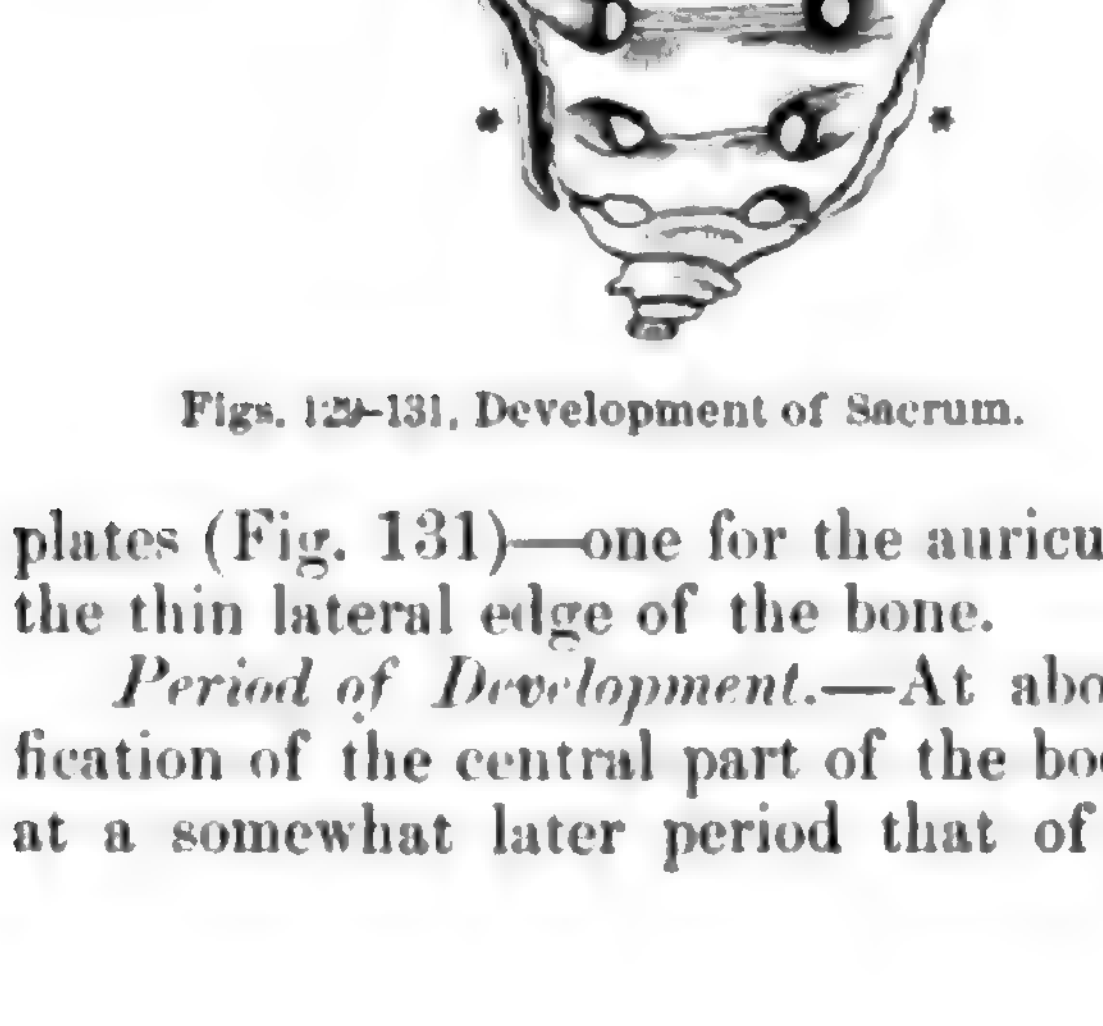

Figs. 129-131, Development of Sacrum.

Development (Fig. 129).—The sacrum, formed by the union of five vertebræ, has *thirty-five* centres of ossification.

The *bodies* of the sacral vertebræ have each three ossific centres—one for the central part, and one for the epiphysial plates on its upper and under surface.

The arch of each sacral vertebra is developed by two centres, one for each lamina. These unite with each other behind, and subsequently join the body.

The *lateral masses* have six additional centres, two for each of the first three vertebræ. These centres make their appearance above and to the outer side of the anterior sacral foramina (Fig. 129), and are developed into separate segments (Fig. 130); they are subsequently blended with each other and with the bodies and transverse processes to form the lateral mass.

Lastly, each *lateral surface* of the sacrum is developed by two epiphysial plates (Fig. 131)—one for the auricular surface, and one for the remaining part of the thin lateral edge of the bone.

Period of Development.—At about the eighth or ninth week of fœtal life ossification of the central part of the bodies of the first three vertebræ commences, and at a somewhat later period that of the last two. Between the sixth and eighth months ossification of the laminæ takes place, and at about the same period the characteristic osseous tubercles for the first three sacral vertebræ make their appearance. The period at which the arch becomes completed by the junction of the laminæ with the bodies in front and with each other behind varies in different segments. The junction takes place first in the lowermost vertebræ as early as the second year, but is not effected in the uppermost until the fifth or sixth year. About the sixteenth year the epiphyses for the upper and under surfaces of the bodies are formed, and between the eighteenth and twentieth years those for each lateral surface of the sacrum make their appearance. The bodies of the sacral vertebræ are, during early life, separated from each other by intervertebral disks. But about the eighteenth year the two lowest segments become joined together by ossification extending through the disk. This process gradually extends upward until all the segments become united, and the bone is completely formed from the twenty-fifth to the thirtieth year of life.

Articulations.—With four bones—the last lumbar vertebra, coccyx, and the two ossa innominata.

Attachment of Muscles.—To eight pairs: in front, the Pyriformis and Coccygeus, and a portion of the Iliacus to the base of the bone; behind, the Gluteus maximus, Latissimus dorsi, Multifidus spinæ and Erector spinæ, and sometimes the Extensor coccygis.

THE COCCYX.

The **Coccyx** (*κόκκυξ*, cuckoo), so called from having been compared to a cuckoo's beak (Fig. 132), is usually formed of four small segments of bone, the most rudimentary parts of the vertebral column. In each of the first three segments may be traced a rudimentary body, articular and transverse processes: the last piece (sometimes the third) is a mere nodule of bone, without distinct processes. All the segments are destitute of laminæ and spinous processes, and consequently of spinal canal and intervertebral foramina. The first segment is the largest; it resembles the lowermost sacral vertebra, and often exists as a separate piece: the last three, diminishing in size from above downward, are usually blended together so as to form a single bone. The gradual diminution in the size of the pieces gives this bone a triangular form, the base of the triangle joining the end of the sacrum. It presents for examination an anterior and a posterior surface, two borders, a base, and an apex. The *anterior surface* is slightly concave, and marked with three transverse grooves, indicating the points of junction of the different pieces. It has attached to it the anterior sacro-coccygeal ligament and Levator ani muscle, and supports the lower end of the rectum. The *posterior surface* is convex, marked by transverse grooves similar to those on the anterior surface, and presents on each side a lineal row of tubercles, the rudimentary articular processes of the coccygeal vertebræ. Of these, the superior pair are very large, and are called the *cornua of the coccyx:* they project upward and articulate with the cornua of the sacrum, the junction between these two bones completing the fifth posterior sacral foramen for the transmission of the posterior branch of the fifth sacral nerve. The *lateral borders* are thin, and present a series of small eminences which represent the transverse processes of the coccygeal vertebræ. Of these, the first on each side is of large size, flattened from before backward, and often ascends to join the lower part of the thin lateral edge of the

FIG. 132.

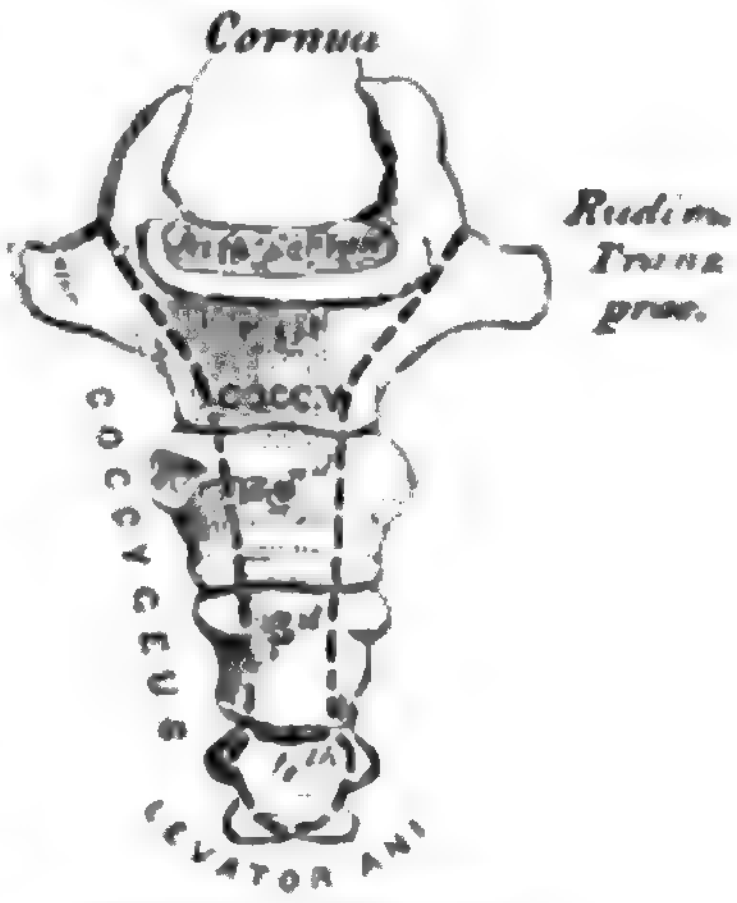

Anterior Surface

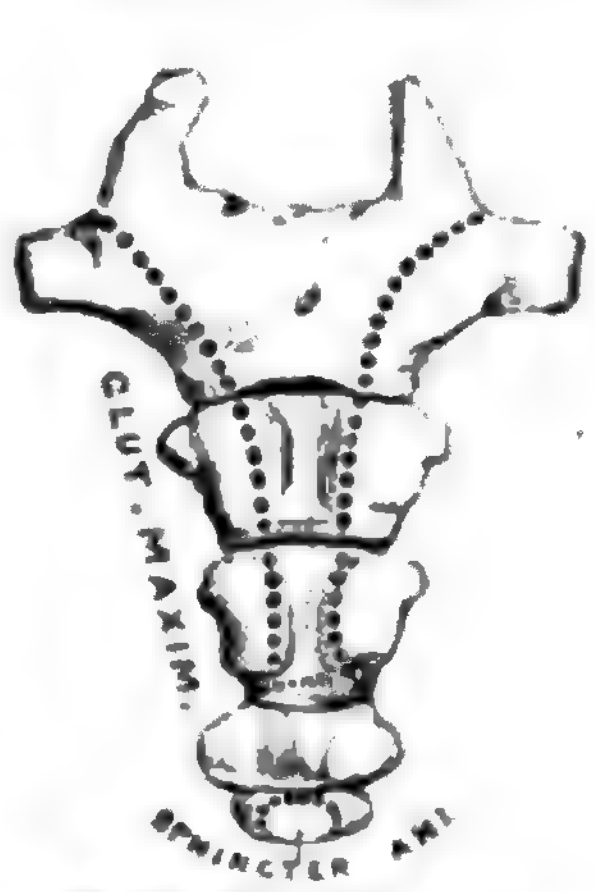

Posterior Surface

Coccyx.

sacrum, thus completing the fifth anterior sacral foramen for the transmission of the anterior division of the fifth sacral nerve; the others diminish in size from above downward, and are often wanting. The borders of the coccyx are narrow, and give attachment on each side to the sacro-sciatic ligaments and Coccygeus muscle. The *base* presents an oval surface for articulation with the sacrum. The *apex* is rounded, and has attached to it the tendon of the external Sphincter muscle. It is occasionally bifid, and sometimes deflected to one or the other side.

Development.—The coccyx is developed by *four* centres, one for each piece. Occasionally, one of the first three pieces of this bone is developed by two centres placed side by side. The ossific nuclei make their appearance in the following order: in the first segment, at birth; in the second piece, at from five to ten years; in the third, from ten to fifteen years; in the fourth, from fifteen to twenty years. As age advances these various segments become united in the following order: the first two pieces join; then the third and fourth; and lastly, the bone is completed by the union of the second and third. At a late period of life, especially in females, the coccyx often becomes joined to the end of the sacrum.

Articulation.—With the sacrum.

Attachment of Muscles.—To four pairs and one single muscle: on either side, the Coccygeus; behind, the Gluteus maximus and Extensor coccygis when present; at the apex, the Sphincter ani; and in front, the Levator ani.

FIG. 133.

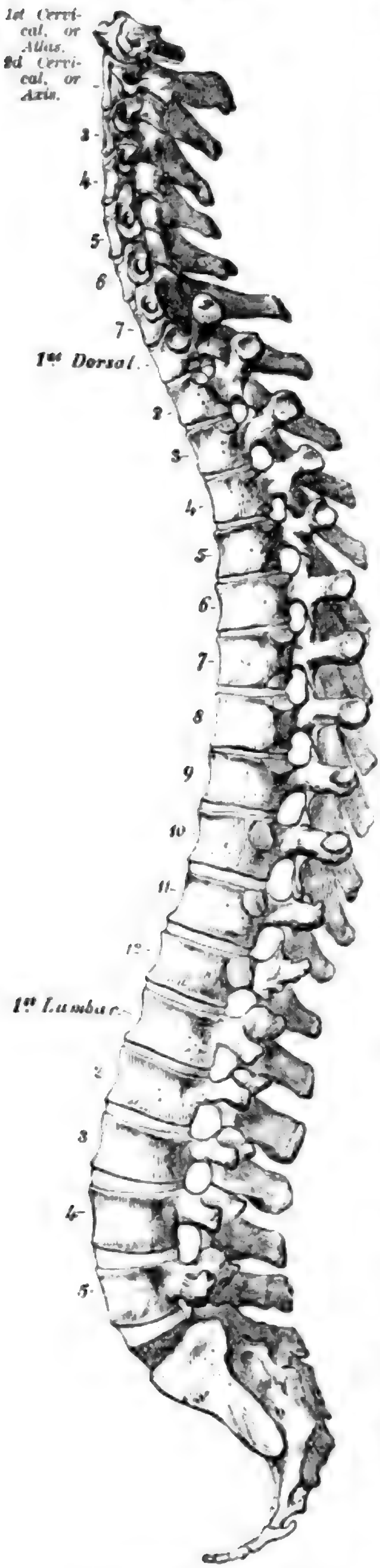

Lateral View of the Spine.

OF THE SPINE IN GENERAL.

The **Spinal Column,** formed by the junction of the vertebræ, is situated in the median line at the posterior part of the trunk: its average length is about two feet two or three inches, measured along the curved anterior surface of the column. Of this length, the cervical part measures about five, the dorsal about eleven, the lumbar about seven inches, and the sacrum and coccyx the remainder.

Viewed in front, it presents two pyramids joined together at their bases, the upper one being formed by all the vertebræ from the second cervical to the last lumbar; the lower one, by the sacrum and coccyx. When examined more closely the upper pyramid is seen to be formed of three smaller pyramids. The uppermost of these consists of the six lower cervical vertebræ, its apex being formed by the axis or second cervical, its base by the first dorsal. The second pyramid, which is inverted, is formed by the four upper dorsal vertebræ, the base being at the first dorsal, the smaller end at the fourth. The third pyramid commences at the fourth dorsal, and gradually increases in size to the fifth lumbar.

Viewed laterally (Fig. 133), the spinal column presents several curves, which correspond to the different regions of the column, and are called *cervical*, *dorsal*, *lumbar*, and *pelvic*. The *cervical* curve commences at the apex of the odontoid process, and terminates at the middle of the second dorsal vertebra; it is convex in front, and is the least marked of all the curves. The *dorsal* curve, which is concave forward, commences at the middle of the second, and terminates at the middle of the twelfth dorsal. Its most prominent point behind corresponds to the body of the seventh or eighth vertebra. The *lumbar* curve commences at the middle of the last dorsal vertebra, and terminates at the sacro-vertebral angle. It is convex anteriorly, the convexity of the lower three vertebræ being much greater than that of the upper ones. The *pelvic* curve commences at the sacro-vertebral articulation, and terminates at the point of the coccyx. It is concave anteriorly. These curves are partly due to the shape of the bodies of the vertebræ, and partly to the intervertebral substances, as will be explained in the *Articulations of the Spine*.[1]

The spine has also a slight lateral curvature, the convexity of which is directed toward the right side. This is most probably produced, as Bichat first explained, chiefly by muscular action, most persons using the right arm in preference to the left, especially in making long-continued efforts, when the body is curved to the right side. In support of this explanation it has been found by Béclard that in one or two individuals who were left-handed the lateral curvature was directed to the left side.

The spinal column presents for examination an anterior, a posterior, and two lateral surfaces, a base, summit, and vertebral canal.

The **anterior surface** presents the bodies of the vertebræ separated in the recent state by the intervertebral disks. The bodies are broad in the cervical region, narrow in the upper part of the dorsal, and broadest in the lumbar region. The whole of this surface is convex transversely, concave from above downward in the dorsal region, and convex in the same direction in the cervical and lumbar regions.

The **posterior surface** presents in the median line the spinous processes. These are short, horizontal, with bifid extremities in the cervical region. In the dorsal region they are directed obliquely above, assume almost a vertical direction in the middle, and are horizontal below, as are also the spines of the lumbar vertebræ. They are separated by considerable intervals in the loins, by narrower intervals in the neck, and are closely approximated in the middle of the dorsal region. Occasionally, one of these processes deviates a little from the median line—a fact to be remembered in practice, as irregularities of this sort are attendant also on fractures or displacements of the spine. [The study of the vertebral spines and of the groove between the lateral muscular masses is of great importance. If the model be made to flex and extend the trunk, and to make rotation and lateral flexion, the greatest possible variations are seen, especially on comparing the various regions of the spine.] On either side of the spinous processes, extending the whole length of the column, is the vertebral groove, formed by the laminæ in the cervical and lumbar regions, where it is shallow, and by the laminæ and transverse processes in the dorsal region, where it is deep and broad. In the recent state these grooves lodge the deep muscles of the back. External to the vertebral grooves are the articular processes, and still more externally the transverse processes. In the dorsal region the latter processes stand backward, on a plane considerably posterior to the same processes in the cervical and lumbar regions. In the cervical region the transverse processes are placed in front of the articular processes and between the intervertebral foramina. In the lumbar they are placed also in front of the articular processes, but behind the intervertebral foramina. In the dorsal region they are posterior both to the articular processes and foramina.

The **lateral surfaces** are separated from the posterior by the articular processes in the cervical and lumbar regions, and by the transverse processes in the dorsal. These surfaces present in front the sides of the bodies of the vertebræ, marked in the dorsal region by the facets for articulation with the heads of the ribs. More posteriorly are the intervertebral foramina, formed by the juxtaposition of the intervertebral notches, oval in shape, smallest in the cervical and upper part of the dorsal regions, and gradually increasing in size to the last lumbar. They are situated between the transverse processes in the neck, and in front of them in the back and loins, and transmit the spinal nerves. The *base* of the vertebral column [*i. e.* of the twenty-four movable vertebræ] is formed by the under surface of the body of the fifth lumbar vertebra, and the *summit* by the upper surface of the atlas. The *vertebral* or *spinal canal* follows the different curves of the spine: it is largest in those regions in which the spine enjoys the greatest freedom of movement, as in the neck and loins, where it is wide and triangular, and narrow and rounded in the back, where motion is more limited.

---

[1] Professor Humphry gives the measurement of these curves in an adult female. (See *The Human Skeleton*, p. 147.)

THE SKULL.

The **Skull**, or superior expansion of the vertebral column, has been described as if composed of four vertebræ, the elementary parts of which are specially modified in form and size, and almost immovably connected, for the reception of the brain and special organs of the senses. These vertebræ are the occipital, parietal, frontal, and nasal. Descriptive anatomists, however, divide the skull into two parts—the Cranium and the Face. The Cranium (κράνος, a helmet) is composed of *eight* bones—viz. the *occipital, two parietal, frontal, two temporal, sphenoid, and ethmoid.* The Face is composed of *fourteen* bones—viz. the *two nasal, two superior maxillary, two lachrymal, two malar, two palate, two inferior turbinated, vomer*, and *inferior maxillary*. The *ossicula auditûs*, the *teeth*, and *Wormian bones* are not included in this enumeration.

- *Skull, 22 bones.*
  - *Cranium, 8 bones:*
    - Occipital.
    - Two Parietal.
    - Frontal.
    - Two Temporal.
    - Sphenoid.
    - Ethmoid.
  - *Face, 14 bones:*
    - Two Nasal.
    - Two Superior Maxillary.
    - Two Lachrymal.
    - Two Malar.
    - Two Palate.
    - Two Inferior Turbinated.
    - Vomer.
    - Inferior Maxillary.

THE OCCIPITAL BONE.

The **Occipital Bone** (*ob, caput*, against the head) is situated at the back part and base of the cranium, is trapezoid in form (Fig. 134), curved upon itself, and presents for examination two surfaces, four borders, and four angles.

The **external surface** is convex. Midway between the summit of the bone and the posterior margin of the foramen magnum is a prominent tubercle, the *external occipital protuberance*, for the attachment of the Ligamentum nuchæ; and, descending from it as far as the foramen, a vertical ridge, the *external occipital crest*. This tubercle and crest vary in prominence in different skulls. Passing outward from the occipital protuberance is a semicircular ridge on each side, the *superior curved line*, and running parallel with these from the middle of the crest are two other ridges, the *inferior curved lines*. The surface of the bone above the superior curved lines is rough, and in the recent state is covered by the Occipito-frontalis muscle, whilst the ridges, as well as the surface of the bone between them, serve for the attachment of numerous muscles. The superior curved line gives attachment internally to the Trapezius, externally to the muscular origin of the Occipito-frontalis and to the Sterno-cleido-mastoid, to the extent shown in Fig. 134, the depressions between the curved lines to the Complexus internally, the Splenius capitis and Obliquus capitis superior externally. The inferior curved line and the depressions below it afford insertion to the Rectus capitis posticus, major and minor. The surface of bone above the superior curved line is rough and porous, and is covered by the aponeurosis of the Occipito-frontalis.

Fig. 134.

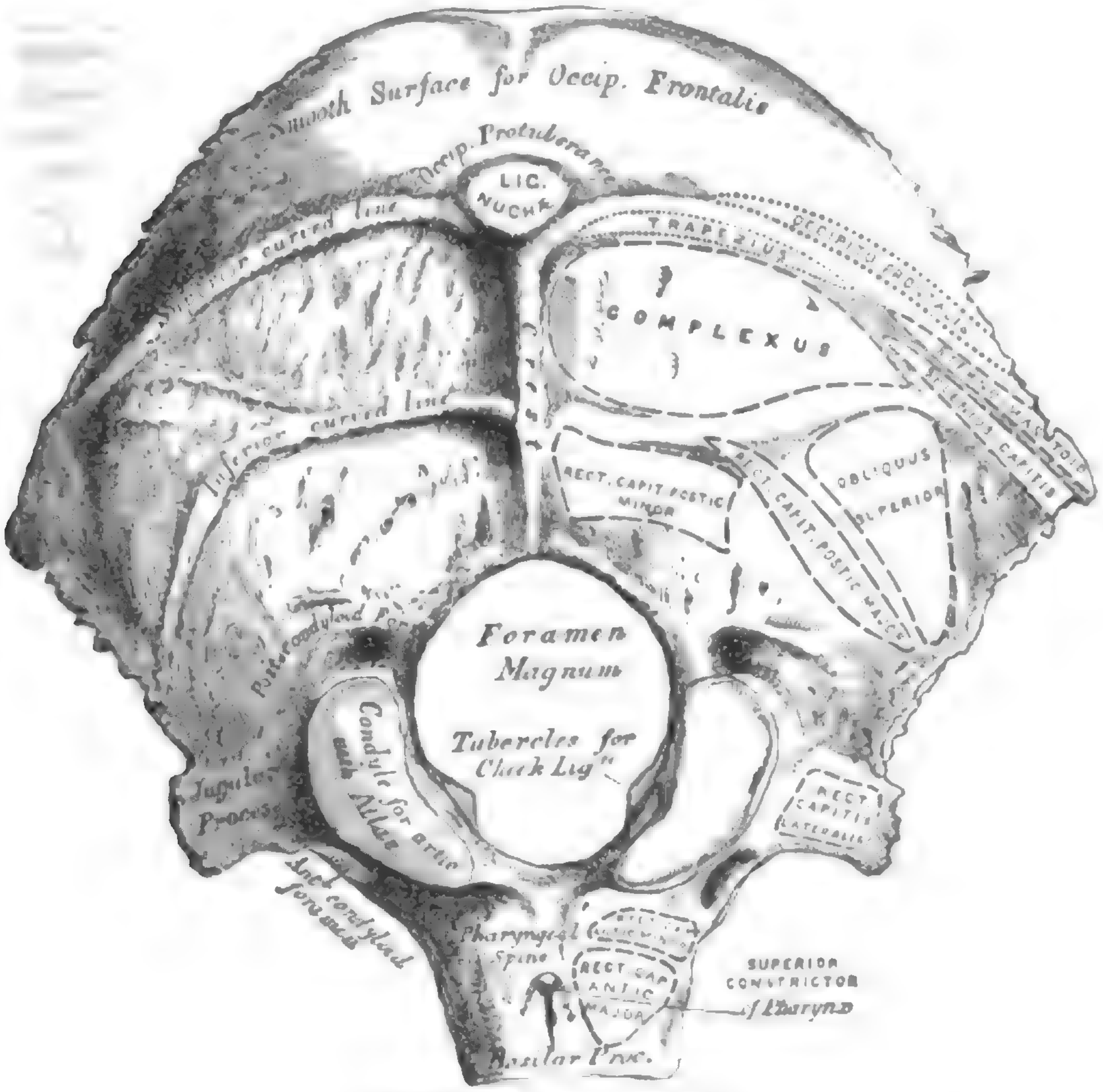
Smooth Surface for Occip. Frontalis
Occip. Protuberance
LIC. NUCHÆ
Superior curved line
TRAPEZIUS
OCCIPITO FRONTALIS
COMPLEXUS
STERNO MASTOID
SPLENIUS CAPITIS
Inferior curved line
RECT. CAPIT. POSTIC. MINOR
RECT. CAPIT. POSTIC. MAJOR
OBLIQUUS SUPERIOR
Posterior condyloid For.
Foramen Magnum
Tubercles for Check Ligᵗˢ
Condyle for artic. with Atlas
Jugular Process
RECT. CAPITIS LATERALIS
Ant. condyloid foramen
Pharyngeal Spine
RECT. CAP. ANTIC. MAJOR
SUPERIOR CONSTRICTOR of Pharynx
Basilar Proc.

Occipital Bone, outer surface.

The **Foramen Magnum** is a large oval aperture, its long diameter extending from before backward. It transmits the medulla oblongata and its membranes, the spinal accessory nerves, and the vertebral arteries. Its back part is wide for the transmission of the medulla, and the corresponding margin rough for the attachment of the dura mater enclosing it; the fore part is narrower, being encroached upon by the condyles; it has projecting toward it from below the odontoid process, and its margins are smooth and bevelled internally to support the medulla oblongata. On each side of the foramen magnum are the *condyles*, for articulation with the atlas: they are convex, oblong, or reniform in shape, and directed downward and outward; they converge in front, and encroach slightly upon the anterior segment of the foramen. On the inner border of each condyle is a rough tubercle for the attachment of the ligaments (*check*) which connect this bone with the odontoid process of the axis, whilst external to them is a rough tubercular prominence, the *transverse* or *jugular process* (the representative of the transverse process of a vertebra), channelled in front by a deep notch, which forms part of the jugular foramen or foramen lacerum posterius. The under surface of this process affords attachment to the Rectus capitis lateralis; its upper or cerebral surface presents a deep groove which lodges part of the lateral sinus, whilst its external surface is marked by a quadrilateral rough facet, covered with cartilage in the fresh state, and articulating with a similar surface on the petrous portion of the temporal bone. On the outer side of each condyle, near its fore part, is a foramen, the *anterior condyloid:* it is directed downward, outward, and forward, and transmits the hypoglossal nerve, and occasionally a meningeal branch of the ascending pharyngeal artery. This foramen is sometimes double. Behind each condyle is a fossa,[1] sometimes perforated at the bottom by a foramen, the *posterior condyloid*, for the transmission of a vein to the lateral sinus. In front of the foramen magnum is a strong quadrilateral plate of bone, the *basilar process*, wider behind than in front, its under surface, which is rough, presenting in the median line a tubercular ridge, the *pharyngeal spine*, for the attachment of the tendinous raphé and Superior constrictor of the pharynx, and on each side of it rough depressions for the attachment of the Rectus capitis anticus, major and minor.

FIG. 135.

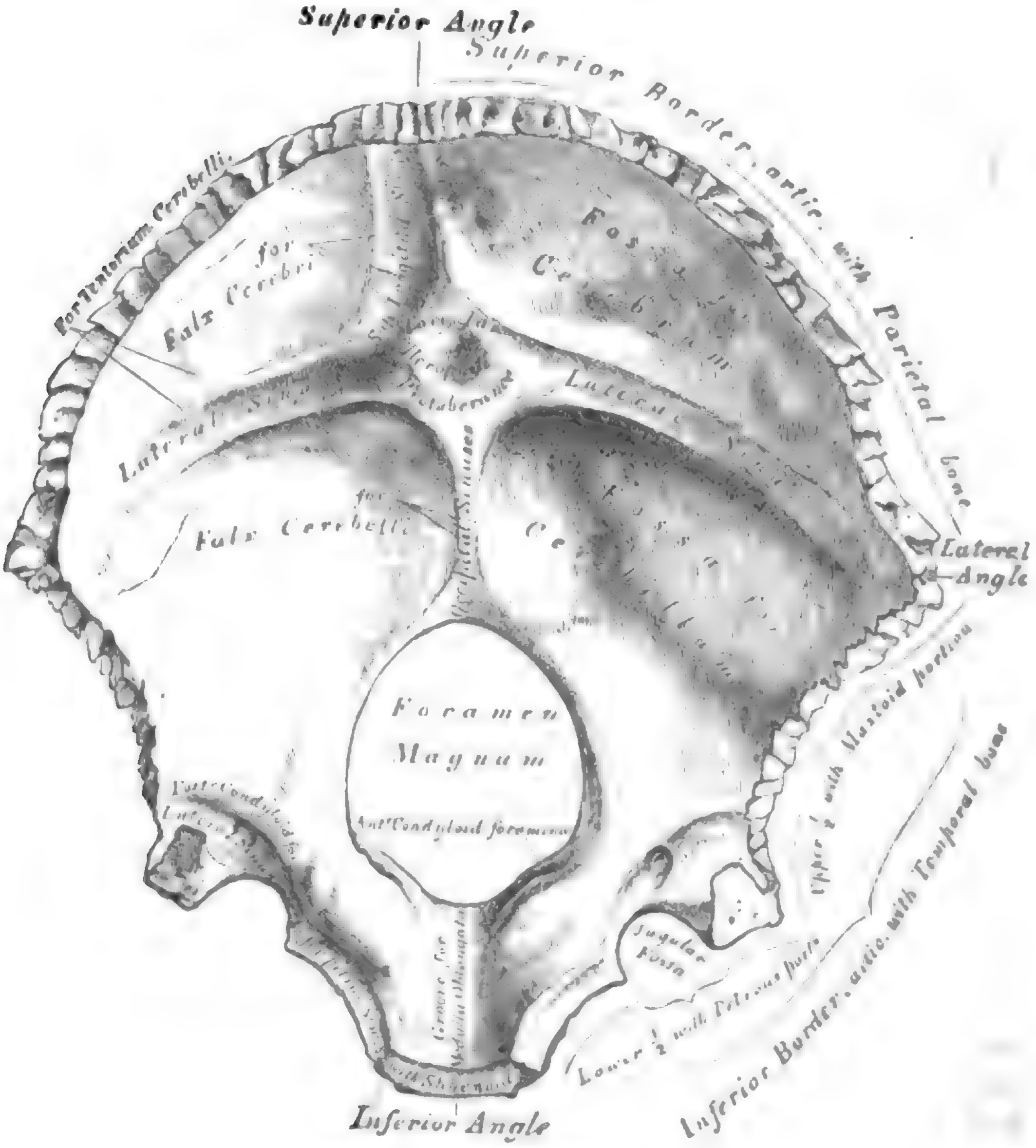
Superior Angle
Superior Border, artic. with Parietal bone
For Tentorium Cerebelli
for Falx Cerebri
Fossa Cerebrum
Sup. Longitud.
Occipital Protuberance
Lateral Sinus
Lateral
for Falx Cerebelli
Occipital Sinuses
Fossa Cerebella
Lateral Angle
Foramen Magnum
Ant. Condyloid foramen
Post. Condyloid for.
Jugular Fossa
Upper ½ with Mastoid portion
Lower ½ with Petrous part
Inferior Border, artic. with Temporal bone
Groove for Medulla Oblongata
with Sphenoid
Inferior Angle

Occipital Bone, inner surface.

The **internal or cerebral surface** (Fig. 135) is deeply concave. The posterior or occipital part is divided by a crucial ridge into four fossæ. The two superior fossæ receive the posterior lobes of the cerebrum, and present slight eminences and depressions corresponding to their convolutions. The two inferior, which receive the hemispheres of the cerebellum, are larger than the former and comparatively smooth; both are marked by slight grooves for the lodgment of arteries. At the point of meeting of the four divisions of the crucial ridge is an eminence, the *internal occipital protuberance*. It nearly corresponds to that on the outer surface, and is perforated by one or more large vascular foramina. From this eminence the superior division of the crucial ridge runs upward to the superior angle of the bone; it presents a deep groove for the superior longitudinal sinus, the margins of which give attachment to the falx cerebri. The inferior division, the *internal occipital crest*, runs to the posterior margin of the foramen magnum, on the edge of which it becomes gradually lost; this ridge, which is bifurcated below, serves for the attachment of the falx cerebelli. It is usually marked by a single groove, which commences at the back part of the foramen magnum and lodges the occipital sinus. Occasionally the groove is double where two sinuses exist. The transverse grooves pass outward to the lateral angles; they are deeply channelled, for the lodgment of the lateral sinuses, their prominent margins affording attachment to the tentorium cerebelli.[1] At the point of meeting of these grooves is a depression, the *torcular Herophili*,[2] placed a little to one or the other side of the internal occipital protuberance. More anteriorly is the foramen magnum, and on each side of it, but nearer its anterior than its posterior part, the internal openings of the anterior condyloid foramina; the internal openings of the posterior condyloid foramina are a little external and posterior to them, protected by a small arch of bone. At this part of the internal surface there is a very deep groove, in which the posterior condyloid foramen, when it exists, has its termination. This groove is continuous in the complete skull with the transverse groove on the posterior part of the bone, and lodges the end of the same sinus, the lateral. In front of the foramen magnum is the basilar process, presenting a shallow depression, the basilar groove, which slopes from behind upward and forward, and supports the medulla oblongata and part of the pons Varolii, and on each side of the basilar process is a narrow channel which, when united with a similar channel on the petrous portion of the temporal bone, forms a groove which lodges the inferior petrosal sinus.

---

[1] This fossa presents many variations in size. It is usually shallow and the foramen small, occasionally wanting on one or both sides. Sometimes both fossa and foramen are large, but confined to one side only; more rarely, the foramen and fossa are very large on both sides.

Angles.—The *superior* angle is received into the interval between the posterior superior angles of the two parietal bones: it corresponds with that part of the skull in the fœtus which is called the *posterior fontanelle*. The *inferior* angle is represented by the square-shaped surface of the basilar process. At an early period of life a layer of cartilage separates this part of the bone from the sphenoid, but in the adult the union between them is osseous. The *lateral angles* correspond to the outer ends of the transverse grooves, and are received into the interval between the posterior inferior angles of the parietal and the mastoid portion of the temporal.

Borders.—The *superior* extends on each side from the superior to the lateral angle, is deeply serrated for articulation with the parietal bone, and forms, by this union, the lambdoid suture. The *inferior* border extends from the lateral to the inferior angle; its upper half is rough, and articulates with the mastoid portion of the temporal, forming the masto-occipital suture; the inferior half articulates with the petrous portion of the temporal, forming the petro-occipital suture; these two portions are separated from each other by the jugular process. In front of this process is a deep notch, which, with a similar one on the petrous portion of the temporal, forms the *foramen lacerum posterius*, or *jugular foramen*. This notch is occasionally subdivided into two parts by a small process of bone, and it generally presents an aperture at its upper part, the internal opening of the posterior condyloid foramen.

---

[1] Usually one of the transverse grooves is deeper and broader than the other; occasionally, both grooves are of equal depth and breadth, or both equally indistinct. The broader of the two transverse grooves is nearly always continuous with the vertical groove for the superior longitudinal sinus, and occupies the corresponding side of the median line.

[2] The columns of blood coming in different directions were supposed to be *pressed* together at this point (*torcular*, a wine-press). [Herophilus, after whom this depression is named, and Erasistratus were the two earliest anatomists. They flourished about 300 years B. C.]

Structure.—The occipital bone consists of two compact laminæ, called the *outer* and *inner tables*, having between them the diploic tissue: this bone is especially thick at the ridges, protuberances, condyles, and internal part of the basilar process, whilst at the bottom of the fossæ, especially the inferior, it is thin, semi-transparent, and destitute of diploë.

Development (Fig. 136).—At birth the bone consists of four distinct parts: a *tabular* or expanded portion, which lies behind the foramen magnum; two *condylar* parts, which form the sides of the foramen; and a *basilar* part, which lies in front of the foramen. The number of nuclei for the tabular part vary. As a rule, there are four, but there may be only one (Blandin) or as many as eight (Meckel). They appear about the eighth week of fœtal life, and soon unite to form a single piece, which is, however, fissured in the direction indicated in the plate. This portion of the bone is developed from membrane. The basilar and two condyloid portions are each developed from a single nucleus, appearing a little later and formed in cartilage. At about the fourth year the occipital and the two condyloid pieces join, and at about the sixth year the bone consists of a single piece. At a later period, between the eighteenth and twenty-fifth years, the occipital and sphenoid become united, forming a single bone.

FIG. 136.

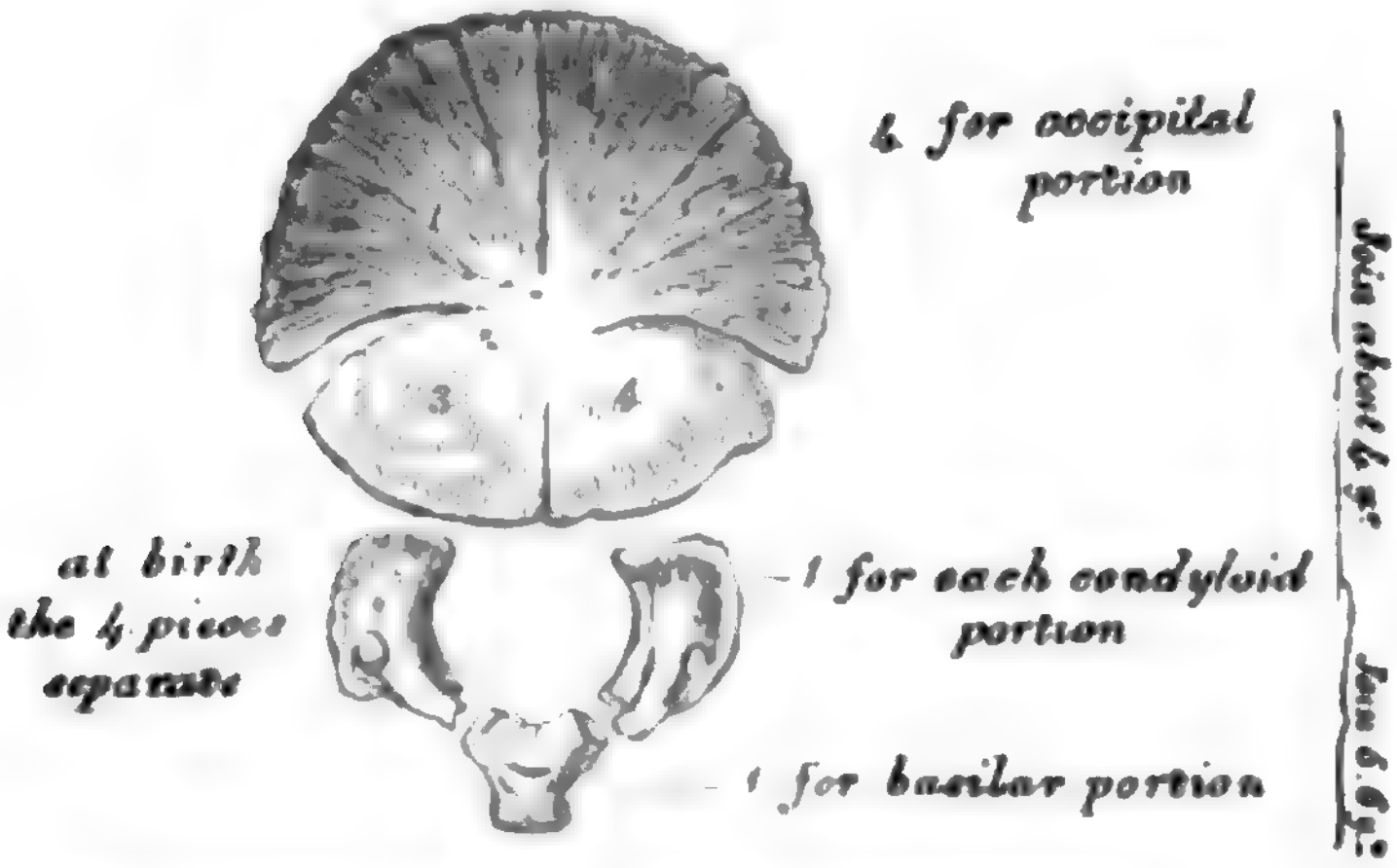

Development of Occipital Bone, by seven centres.

Articulations.—With six bones—two parietal, two temporal, sphenoid, and atlas.

Attachment of Muscles.—To twelve pairs: to the superior curved line are attached the Occipito-frontalis, Trapezius, and Sterno-cleido-mastoid; to the space between the curved lines, the Complexus,[1] Splenius capitis, and Obliquus superior; to the inferior curved line and the space between it and the foramen magnum, the Rectus capitis posticus, major and minor; to the transverse process, the Rectus lateralis; and to the basilar process, the Rectus capitis anticus, major and minor, and Superior Constrictor of the pharynx.

THE PARIETAL BONES.

The **Parietal Bones** (*paries*, a wall) form by their union the sides and roof of the skull. Each bone is of an irregular quadrilateral form, and presents for examination two surfaces, four borders, and four angles.

Surfaces.—The *external surface* (Fig. 137) is convex, smooth, and marked about its centre by an eminence, called the *parietal eminence*, which indicates the point where ossification commenced. Crossing the middle of the bone in an arched direction is a curved ridge, the *temporal ridge*, for the attachment of the temporal fascia. [About two-fifths of an inch below this ridge, at its middle, is a second less well-marked ridge marking the upper ridge of the Temporal muscle. See p. 684, and Fig. 464, p. 685.] Above this ridge the surface of the bone is rough and porous and covered by the aponeurosis of the Occipito-frontalis; below it the bone is smooth, forms part of the temporal fossa, and affords attachment to the Temporal muscle. At the back part of the superior border, close to the sagittal suture, is a small foramen, the *parietal foramen*, which transmits a vein to the superior longitudinal sinus, and sometimes a small branch of the occipital artery. Its existence is not constant and its size varies considerably.

---

[1] To these the Biventer cervicis should be added if it is regarded as a separate muscle.

The **internal surface** (Fig. 138), concave, presents eminences and depressions for lodging the convolutions of the cerebrum and numerous furrows for the ramifications of the meningeal arteries; the latter run upward and backward from the anterior inferior angle and from the central and posterior part of the lower border of the bone. Along the upper margin is part of a shallow groove which, when joined to the opposite parietal, forms a channel for the superior longitudinal sinus, the elevated edges of which afford attachment to the falx cerebri. Near the groove are seen several depressions, especially in the skulls of old persons; they lodge the Pacchionian bodies. The internal opening of the parietal foramen is also seen when that aperture exists.

Fig. 137.

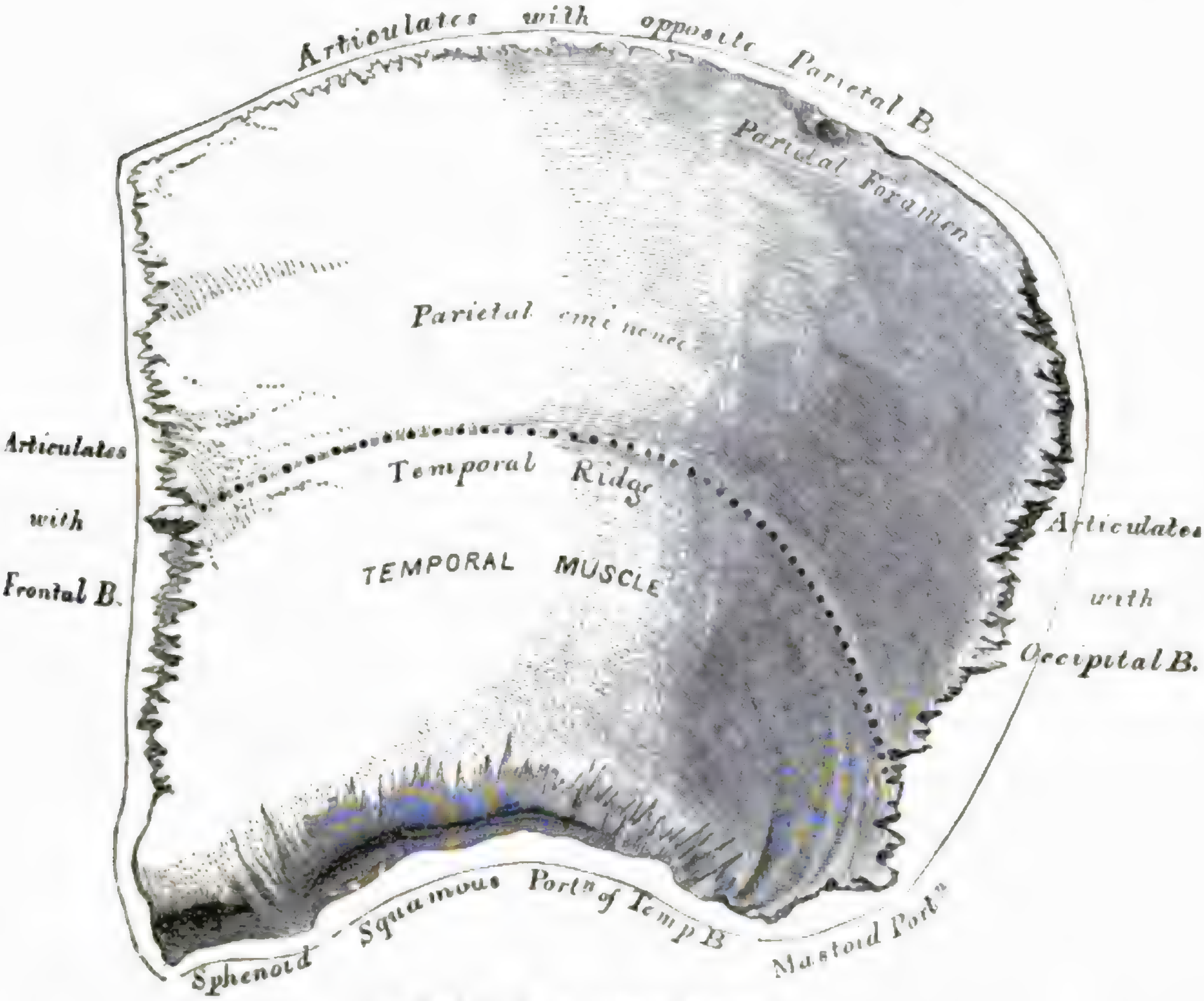

Left Parietal Bone, external surface.

Borders.—The *superior*, the longest and thickest, is dentated to articulate with its fellow of the opposite side, forming the sagittal suture. The *inferior* is divided into three parts: of these, the anterior is thin and pointed, bevelled at the expense of the outer surface, and overlapped by the tip of the great wing of the sphenoid: the middle portion is arched, bevelled at the expense of the outer surface, and overlapped by the squamous portion of the temporal; the posterior portion is thick, and serrated for articulation with the mastoid portion of the temporal. The *anterior border*, deeply serrated, is bevelled at the expense of the outer surface above and of the inner below; it articulates with the frontal bone, forming the *coronal suture*. The *posterior* border, deeply denticulated, articulates with the occipital, forming the *lambdoid suture*.

Angles.—The *anterior superior*, thin and pointed, corresponds with that portion of the skull which in the fœtus is membranous and is called the *anterior fontanelle*. The *anterior inferior angle* is thin and lengthened, being received in the interval between the great wing of the sphenoid and the frontal. This point will be found about one inch behind the upper and outer angle of the orbit. Its inner surface is marked by a deep groove, sometimes a canal, for the anterior branch of the middle meningeal artery. The *posterior superior angle* corresponds with the junction of the sagittal and lambdoid sutures. In the fœtus this part of the skull is membranous and is called the *posterior fontanelle*. The *posterior inferior angle* articulates with the mastoid portion of the temporal bone, and generally presents on its inner surface a broad shallow groove for lodging part of the lateral sinus.

FIG. 138.

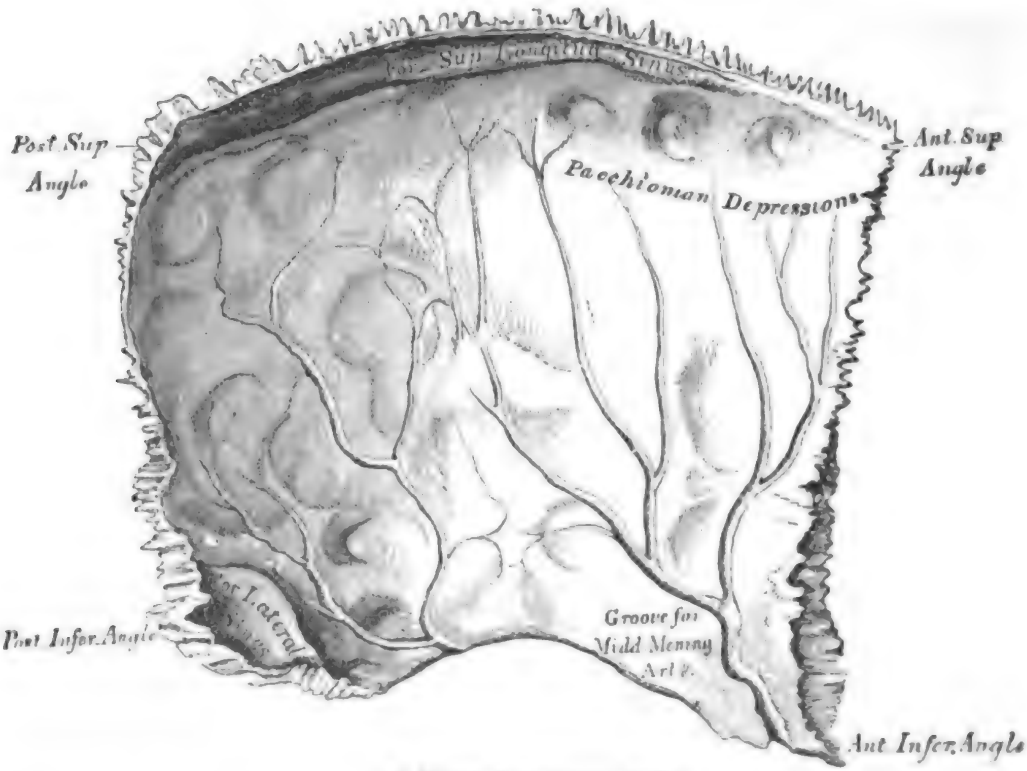

Left Parietal Bone, internal surface.

Development.—The parietal bone is formed in membrane, being developed by *one* centre, which corresponds with the parietal eminence, and makes its first appearance about the seventh or eighth week of fœtal life. Ossification gradually extends from the centre to the circumference of the bone: the angles are consequently the parts last formed, and it is in their situation that the fontanelles exist previous to the completion of the growth of the bone.

Articulations.—With five bones: the opposite parietal, the occipital, frontal, temporal, and sphenoid.

Attachment of Muscles.—One only, the Temporal.

THE FRONTAL BONE.

The **Frontal Bone** (*frons*, the forehead) resembles a cockle-shell in form, and consists of two portions—a *vertical* or *frontal* portion, situated at the anterior part of the cranium, forming the forehead; and a *horizontal* or *orbito-nasal* portion, which enters into the formation of the roof of the orbits and nasal fossæ.

Vertical Portion, external surface (Fig. 139).—In the median line, traversing the bone from the upper to the lower part, is occasionally seen a slightly elevated ridge, and in young subjects a suture, which represents the line of union of the two lateral halves of which the bone consists at an early period of life: in the adult this suture is usually obliterated and the bone forms one piece; traces of the obliterated suture are, however, generally perceptible at the lower part. On either side of this ridge, a little below the centre of the bone, is a rounded eminence, the *frontal eminence.* These eminences vary in size in different individuals, and are occasionally unsymmetrical in the same subject. They are especially prominent in cases of well-marked cerebral development. The whole surface of the bone above this part is smooth, and covered by the aponeurosis of the Occipito-frontalis muscle. Below the frontal eminence, and separated from it by a slight groove, is the *superciliary ridge*, broad internally where it is continuous with the nasal eminence, but less distinct as it arches outward. These ridges are caused by the projection outward of the frontal sinuses,[1] and give attachment to the Orbicularis palpebrarum and Corrugator supercilii. Beneath the superciliary ridge is the *supraorbital arch*, a curved and prominent margin which forms the upper boundary of the orbit and separates the vertical from the horizontal portion of the bone. The outer part of the arch is sharp and prominent, affording to the eye, in that situation, considerable protection from injury: the inner part is less prominent. At the junction of the internal and middle third of this arch is a notch, sometimes converted into a foramen by a bony process, and called the *supraorbital notch* or *foramen.* It transmits the supraorbital artery, vein, and nerve. A small aperture is seen in the upper part of the notch,

Fig. 139.

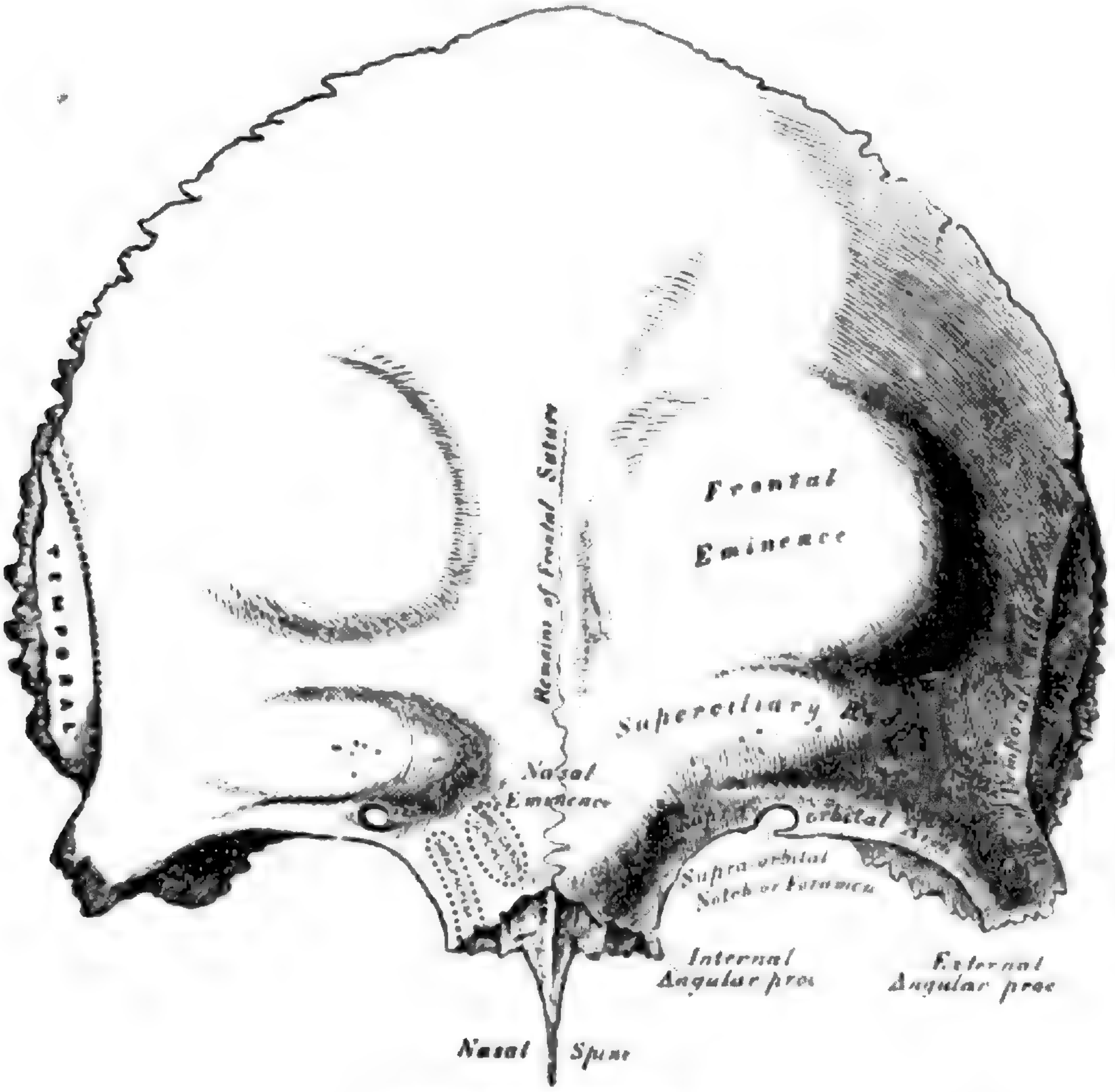

Frontal Bone, outer surface.

---

[1] Some confusion is occasioned to students commencing the study of anatomy by the name "sinuses" having been given to two perfectly different kinds of spaces connected with the skull. It may be as well, therefore, to state here, at the outset, that the "sinuses" on the interior of the cranium, marked by grooves on the inner surface of the bones, are venous channels along which the blood runs in its passage back from the brain, while the "sinuses" external to the cranial cavity (the frontal, ethmoidal, sphenoidal, and maxillary) are hollow spaces in the bones themselves which communicate with the nostrils and contain air.

which transmits a vein from the diploë to join the ophthalmic vein. The supraorbital arch terminates externally in the *external angular process*, and internally in the *internal angular process*. The external angular process is strong, prominent, and articulates with the malar bone; running upward and backward from it is a sharp curved crest, the *temporal ridge*, for the attachment of the temporal fascia; and beneath it a slight concavity, that forms the anterior part of the temporal fossa and gives origin to the Temporal muscle. The internal angular processes are less marked than the external, and articulate with the lachrymal bones. Between the internal angular processes is a rough, uneven interval, the *nasal notch*, which articulates in the middle line with the nasal bone and on either side with the nasal process of the superior maxillary bone. The notch is continuous below with a long pointed process, the *nasal spine*. Above the nasal notch and between the two superciliary ridges is a projection, the *nasal eminence* or *glabella*, which denotes the position of the frontal sinuses.

Internal Surface (Fig. 140).—Along the middle line is a vertical groove, the edges of which unite below to form a ridge, the *frontal crest;* the groove lodges the superior longitudinal sinus, whilst its margins afford attachment to the falx cerebri. The crest terminates below at a small notch which is converted into a foramen by articulation with the ethmoid. It is called the *foramen cæcum*, and varies in size in different subjects; it is sometimes partially or completely impervious, lodges a process of the falx cerebri, and, when open, transmits a vein from the lining membrane of the nose to the superior longitudinal sinus. On either side of the groove the bone is deeply concave, presenting eminences and depressions for the convolutions of the brain, and numerous small furrows for lodging the ramifications of the

FIG. 140.

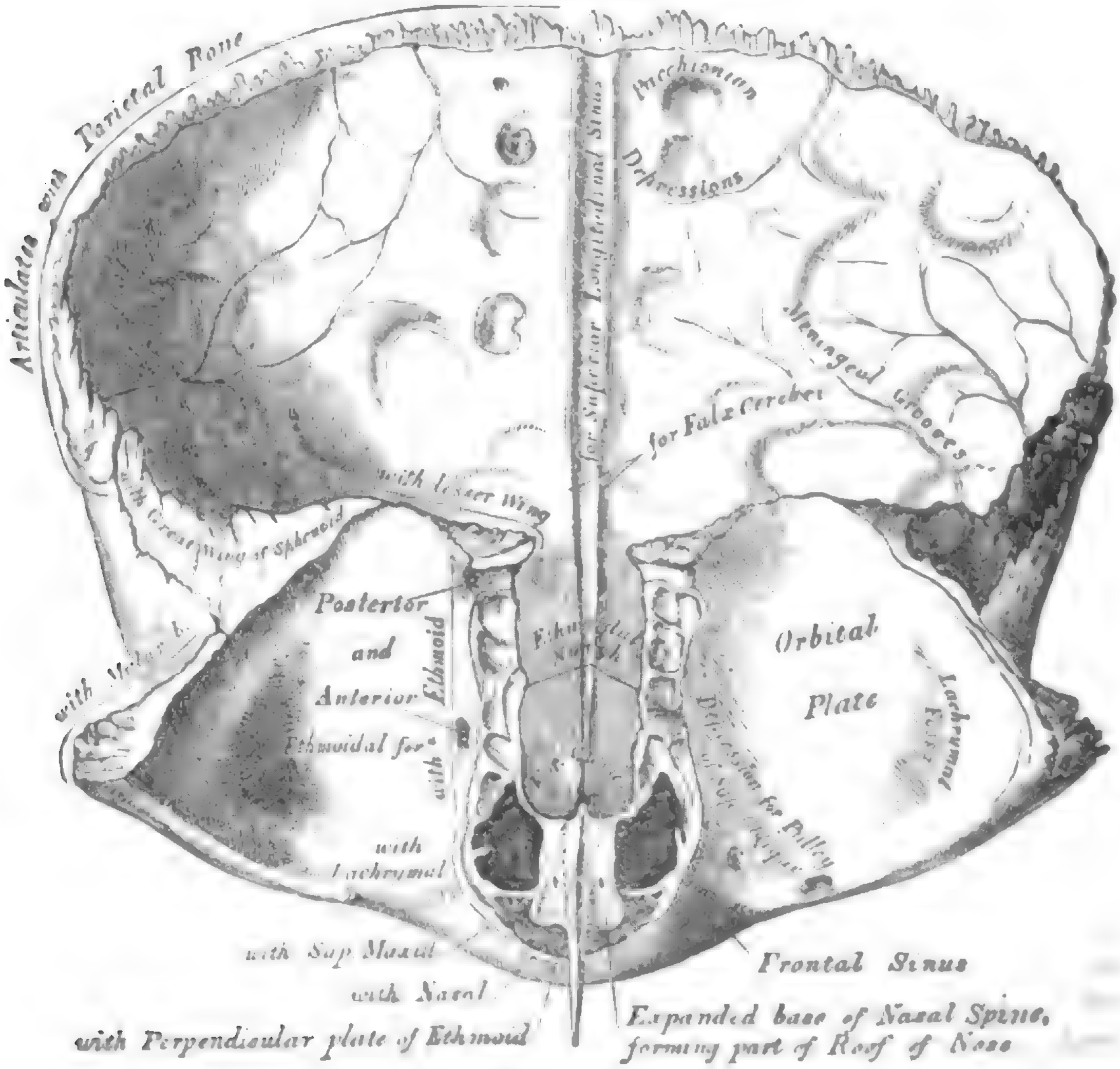
Articulates with Parietal Bone
for Superior Longitudinal Sinus
Pacchionian Depressions
Meningeal Grooves
for Falx Cerebri
with lesser Wing
with Greater Wing of Sphenoid
with Malar b.
Posterior and Anterior Ethmoidal for.
with Ethmoid
Ethmoidal Notch
Orbital Plate
Lachrymal Fossa
Depression for Pulley of Sup. Oblique
with Lachrymal
with Sup. Maxil.
with Nasal
with Perpendicular plate of Ethmoid
Frontal Sinus
Expanded base of Nasal Spine, forming part of Roof of Nose

Frontal Bone, inner surface.

anterior meningeal arteries. Several small irregular fossæ are also seen on either side of the groove, for the reception of the Pacchionian bodies.

Horizontal Portion, external surface.—This portion of the bone consists of two thin plates which form the vault of the orbit, separated from one another by the ethmoidal notch. Each orbital vault consists of a smooth, concave, triangular plate of bone, marked at its anterior and external part (immediately beneath the external angular process) by a shallow depression, the *lachrymal fossa*, for lodging the lachrymal gland; and at its anterior and internal part by a depression (sometimes a small tubercle [or a hook]), for the attachment of the fibro-cartilaginous pulley of the Superior oblique muscle. The ethmoidal notch separates the two orbital plates: it is quadrilateral, and filled up, when the bones are united, by the cribriform plate of the ethmoid. The margins of this notch present several half-cells, which, when united with corresponding half-cells on the upper surface of the ethmoid, complete the ethmoidal cells; two grooves are also seen crossing these edges transversely; they are converted into canals by articulation with the ethmoid, and are called the *anterior* and *posterior ethmoidal* canals: they open on the inner wall of the orbit. The anterior one transmits the nasal nerve and anterior ethmoidal vessels, the posterior one the posterior ethmoidal vessels. In front of the ethmoidal notch is the *nasal spine*, a sharp-pointed eminence which projects downward and forward, and articulates in front with the crest of the nasal bones; behind, it is marked by two grooves separated by a vertical ridge; the ridge articulates with the perpendicular lamellæ of the ethmoid; the grooves form part of the roof of the nasal fossæ. On either side of the base of the nasal spine are the openings of the frontal sinuses. These are two irregular cavities which extend upward and outward a variable distance between the two tables of the skull, and are separated from one another by a thin bony septum. They give rise to the prominences above the root of the nose called the *nasal eminence* and *superciliary ridges*. In the child they are generally absent, and they become gradually developed as age advances. These cavities vary in size in different persons, are larger in men than in women, and are frequently of unequal size on the two sides, the left being commonly the larger. Occasionally they are subdivided by incomplete bony laminæ. They are lined by mucous membrane, and communicate with the nose by the infundibulum, and occasionally with each other by apertures in their septum.

The **internal surface of the Horizontal Portion** presents the convex upper surfaces of the orbital plates, separated from each other in the middle line by the ethmoidal notch, and marked by eminences and depressions for the convolutions of the anterior lobes of the brain.

Borders.—The border of the vertical portion is thick, strongly serrated, bevelled at the expense of the internal table above, where it rests upon the parietal bones, and at the expense of the external table at each side, where it receives the lateral pressure of those bones; this border is continued below into a triangular rough surface which articulates with the great wing of the sphenoid. The border of the horizontal portion is thin, serrated, and articulates with the lesser wing of the sphenoid.

Structure.—The vertical portion and external angular processes are very thick, consisting of diploic tissue contained between two compact laminæ. The horizontal portion is thin, translucent, and composed entirely of compact tissue; hence the facility with which instruments can penetrate the cranium through this part of the orbit.

Fig. 141.

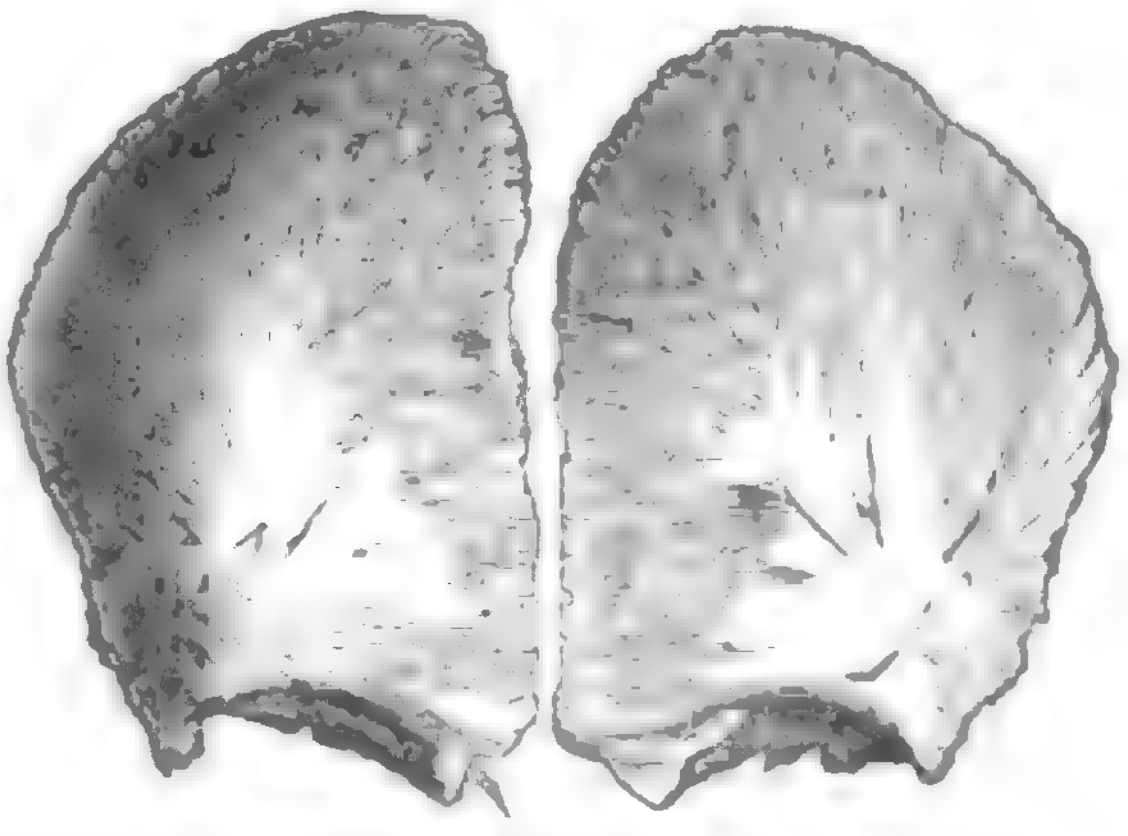

Frontal Bone at Birth, developed by two lateral halves.

Development (Fig. 141).—The frontal bone is formed in membrane, being developed by *two* centres, one for each lateral half, which make their appearance about the seventh or eighth week above the orbital arches. From this point ossification extends, in a radiating manner, upward into the forehead and backward over the orbit. At birth the bone consists of two pieces, which afterward become united, along the middle line, by a suture which runs from the vertex to the root of the nose. This suture usually becomes obliterated within a few years after birth, but it occasionally remains throughout life.

Articulations.—With twelve bones: two parietal, the sphenoid, the ethmoid, two nasal, two superior maxillary, two lachrymal, and two malar.

Attachment of Muscles.—To three pairs: the Corrugator supercilii, Orbicularis palpebrarum, and Temporal, on each side.

THE TEMPORAL BONES.

The Temporal Bones (*tempus*, time) are situated at the side and base of the skull, and present for examination a *squamous*, *mastoid*, and *petrous* portion.

The Squamous Portion (*squama*, a scale) (Fig. 142), the anterior and upper part of the bone, is scale-like in form and thin and translucent in texture. Its *outer surface* is smooth, convex, and grooved at its back part for the deep temporal arteries: it affords attachment to the Temporal muscle and forms part of the temporal fossa. At its back part may be seen a curved ridge, part of the *temporal ridge;* it serves for the attachment of the temporal fascia, limits the origin of the Temporal muscle, and marks the boundary between the squamous and mastoid portions of the bone. Projecting from the lower part of the squamous portion is a long arched process of bone, the *zygoma* [or *zygomatic process*. This process can always be felt, and often seen, as a marked elevation. In the Carnivora it is very strong, and projects enormously on account of their powerful muscles of mastication]. This

FIG. 142.

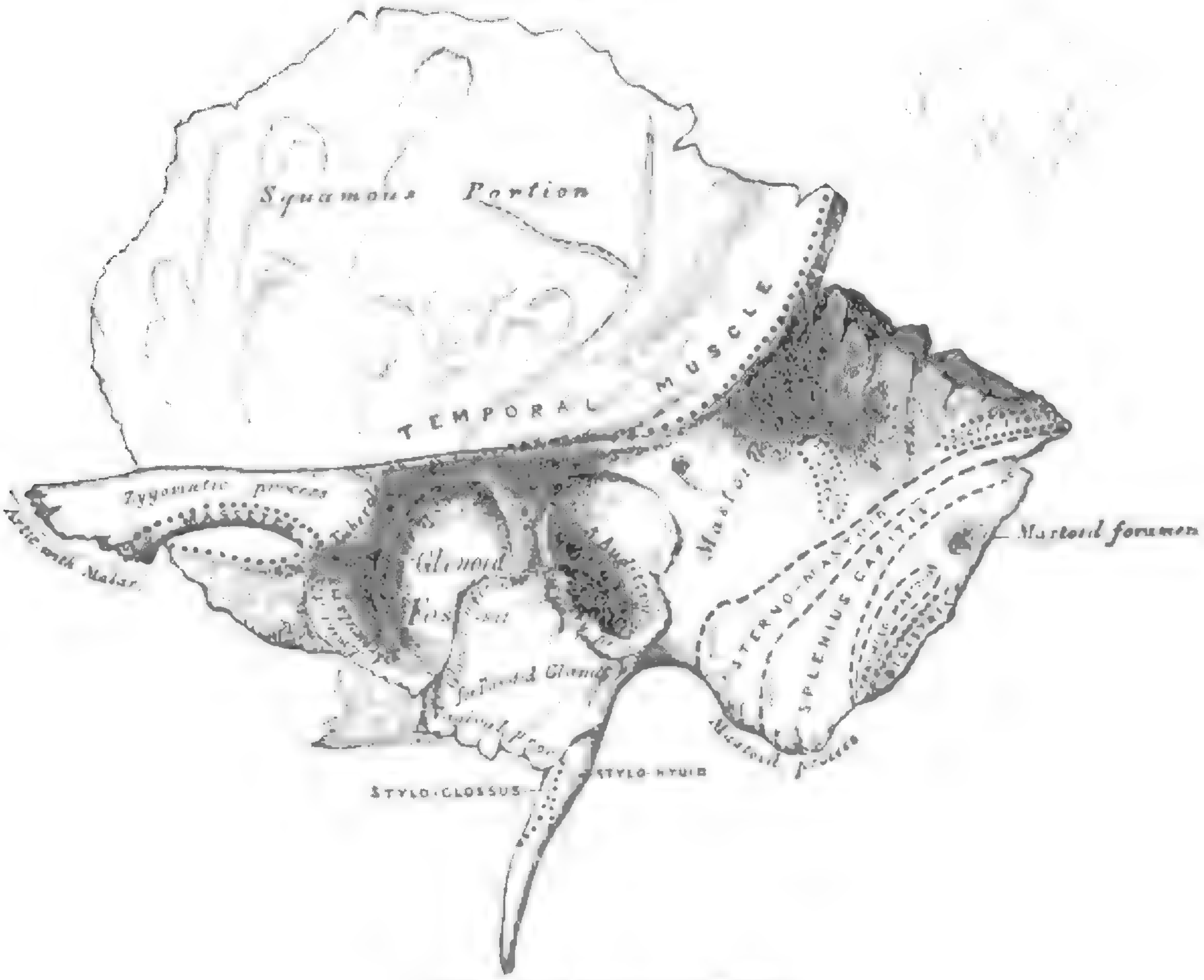
Squamous Portion
TEMPORAL MUSCLE
Zygomatic process
Artic. with Malar
Glenoid Fossa
Mastoid
Mastoid foramen
STERNO-MASTOID
SPLENIUS CAPITIS
for Parotid Gland
Vaginal Proc.
Mastoid process
STYLO-GLOSSUS
STYLO-HYOID

Left Temporal Bone, outer surface.

process is at first directed outward, its two surfaces looking upward and downward; it then appears as if twisted upon itself, and runs forward, its surfaces now looking inward and outward. The superior border of the process is long, thin, and sharp, and serves for the attachment of the temporal fascia. The inferior, short, thick, and arched, has attached to it some fibres of the Masseter muscle. Its outer surface is convex and subcutaneous; its inner is concave, and also affords attachment to the Masseter. The extremity, broad and deeply serrated, articulates with the malar bone. The zygomatic process is connected to the temporal bone by three divisions, called its *roots*—an anterior, middle, and posterior. The anterior, which is short but broad and strong, is directed inward, to terminate in a rounded eminence, the *eminentia articularis*. This eminence forms the front boundary of the glenoid fossa, and in a recent state is covered with cartilage. The middle root forms the outer margin of the glenoid cavity; running obliquely inward, it terminates at the commencement of a well-marked fissure, the *Glaserian fissure;* whilst the posterior root, which is strongly marked, runs from the upper border of the zygoma in an arched direction upward and backward, forming the posterior part of the temporal ridge. At the junction of the anterior root with the zygoma is a projection, called the *tubercle*, for the attachment of the external lateral ligament of the lower jaw; and between the anterior and middle roots is an oval depression, forming part of the *glenoid fossa* (γλήνη, a socket), for the reception of the condyle of the lower jaw. This fossa is bounded in front by the eminentia articularis; behind, by the vaginal process; and externally, by the auditory process and middle root of the zygoma; and is divided into two parts by a narrow slit, the *Glaserian fissure*. The anterior part, formed by the squamous portion of the bone, is smooth, covered in the recent state with cartilage, and articulates with the condyle of the lower jaw. This part of the glenoid fossa is separated from the auditory process by a small tubercle, the *post-glenoid process*, the representative of a prominent tubercle which, in some of the Mammalia, descends behind the condyle of the jaw and prevents its being displaced backward during mastication (Humphry). The posterior part of the glenoid fossa is formed chiefly by the *tympanic plate*, a lamina of bone which forms the anterior wall of the tympanum and external auditory meatus. This plate of bone terminates externally in the auditory process, above in the Glaserian fissure, and below forms a sharp edge, the *vaginal* process. It lodges a portion of the parotid gland, and gives origin to some of the fibres of the Tensor palati muscle. The Glaserian fissure, which leads into the tympanum, lodges the processus gracilis of the malleus and transmits the tympanic branch of the internal maxillary artery. The chorda tympani nerve passes through a separate canal, parallel to the Glaserian fissure (*canal of Huguier*), on the outer side of the Eustachian tube, in the retiring angle between the squamous and petrous portions of the temporal bone.[1]

The **internal surface** of the squamous portion (Fig. 144) is concave—presents numerous eminences and depressions for the convolutions of the cerebrum, and two well-marked grooves for the branches of the middle meningeal artery.

Borders.—The superior border is thin, bevelled at the expense of the internal surface, so as to overlap the lower border of the parietal bone, forming the squamous suture. The anterior inferior border is thick, serrated, and bevelled, alternately at the expense of the inner and outer surfaces, for articulation with the great wing of the sphenoid.

The **Mastoid Portion** (μαστός, a nipple or teat) is situated at the posterior part of the bone; its outer surface is rough and perforated by numerous foramina; one of these, of large size, situated at the posterior border of the bone, is termed the *mastoid foramen;* it transmits a vein to the lateral sinus and a small artery from the occipital, to supply the dura mater. The position and size of this foramen are very variable. It is not always present; sometimes it is situated in the occipital bone or in the suture between the temporal and the occipital. The mastoid portion is continued below into a conical projection, the *mastoid process*, the size and form of which vary somewhat. This process serves for the attachment of the Sterno-mastoid, Splenius capitis, and Trachelo-mastoid muscles. On the inner side of the mastoid process is a deep groove, the *digastric fossa*, for the attachment of the Digastric muscle, and running parallel with it, but more internal, the *occipital groove*, which lodges the occipital artery. The internal surface of the mastoid portion presents a deep curved groove, the *fossa Sigmoidea*, which lodges part of the lateral sinus, and into it may be seen opening the mastoid foramen. A section of the mastoid process shows it to be hollowed out into a number of cellular spaces communicating with each other, called the *mastoid cells;* they open by a single or double orifice into the back of the tympanum, are lined by a prolongation of its lining membrane, and probably form some secondary part of the organ of hearing. The mastoid cells, like the other sinuses of the cranium, are not developed until after puberty; hence the prominence of this process in the adult. [Fig. 143 shows their communication with the middle ear. By this route inflammation and suppuration may readily extend into these cells as a result of ear disease, producing "mastoid disease." Unless speedily relieved by trephining, this often produces death by involving the brain. The very thin bony septum which separates the mastoid cells and middle ear from the cranial cavity is also well shown in the figure.]

---

[1] This small fissure must not be confounded with the large canal which lies above the Eustachian tube and transmits the Tensor tympani muscle.

[Fig. 143.

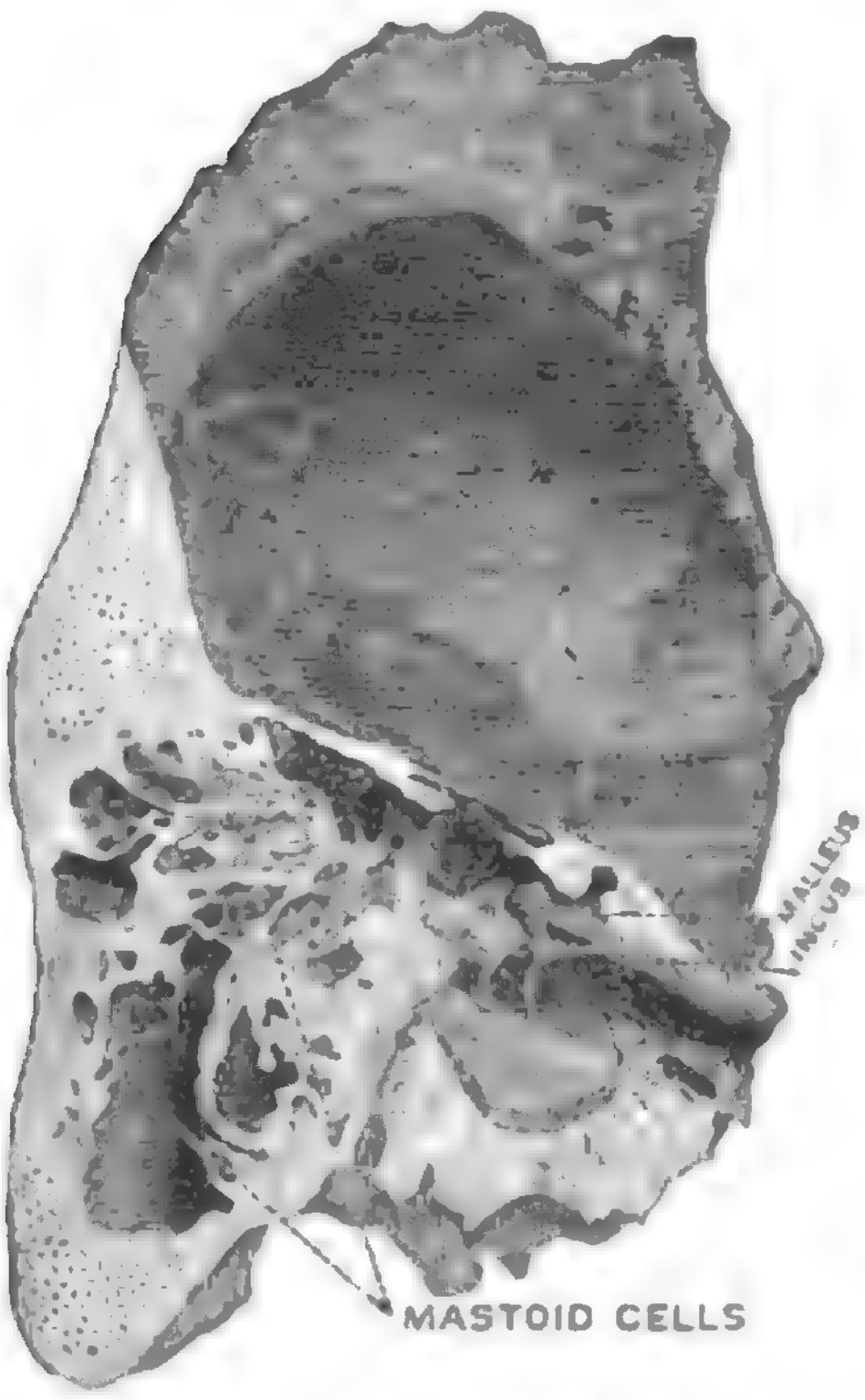
MALLEUS
INCUS
MASTOID CELLS

Section through the Mastoid Cells, showing their communication with the middle ear.—W. W. K.]

Fig. 144.

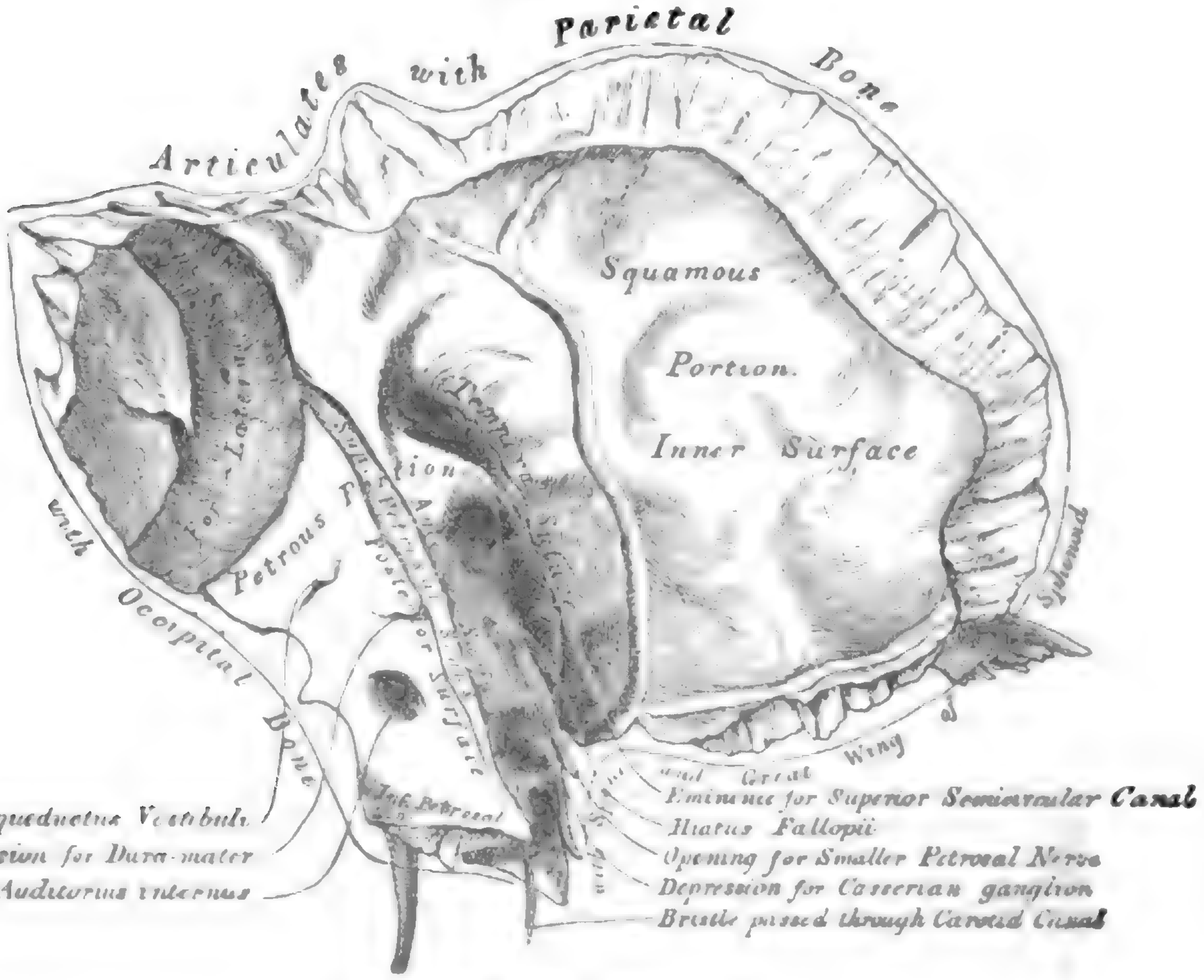
Articulates with Parietal Bone
Squamous
Portion.
Inner Surface
Petrous Portion
with Occipital Bone
Sphenoid
and Great Wing of
Inf. Petrosal
Aqueductus Vestibuli
Depression for Dura-mater
Meatus Auditorius internus
Eminence for Superior Semicircular Canal
Hiatus Fallopii
Opening for Smaller Petrosal Nerve
Depression for Casserian ganglion
Bristle passed through Carotid Canal

Left Temporal Bone, inner surface.

Borders.—The superior border of the mastoid portion is broad and rough, its serrated edge sloping outward, for articulation with the posterior inferior angle of the parietal bone. The posterior border, also uneven and serrated, articulates with the inferior border of the occipital bone between its lateral angle and jugular process.

The **Petrous Portion** (πέτρος, a stone), so named from its extreme density and hardness, is a pyramidal process of bone wedged in at the base of the skull between the sphenoid and occipital bones. Its direction from without is inward, forward, and a little downward. It presents for examination a base, an apex, three surfaces, and three borders, and contains in its interior the essential parts of the organ of hearing. The *base* is applied against the internal surface of the squamous and mastoid portions, its upper half being concealed; but its lower half is exposed by the divergence of those two portions of the bone, which brings into view the oval expanded orifice of a canal leading into the tympanum, the *meatus auditorius externus.* This canal is situated in front of the mastoid process and between the posterior and middle roots of the zygoma; its upper margin is smooth and rounded, but the greater part of its circumference is surrounded by a curved plate of bone, the *auditory process*, the free margin of which is thick and rough, for the attachment of the cartilage of the external ear.

The **apex** of the petrous portion, rough and uneven, is received into the angular interval between the posterior border of the greater wing of the sphenoid and the basilar process of the occipital; it presents the anterior or internal orifice of the carotid canal, and forms the posterior and external boundary of the foramen lacerum medium.

FIG. 145.

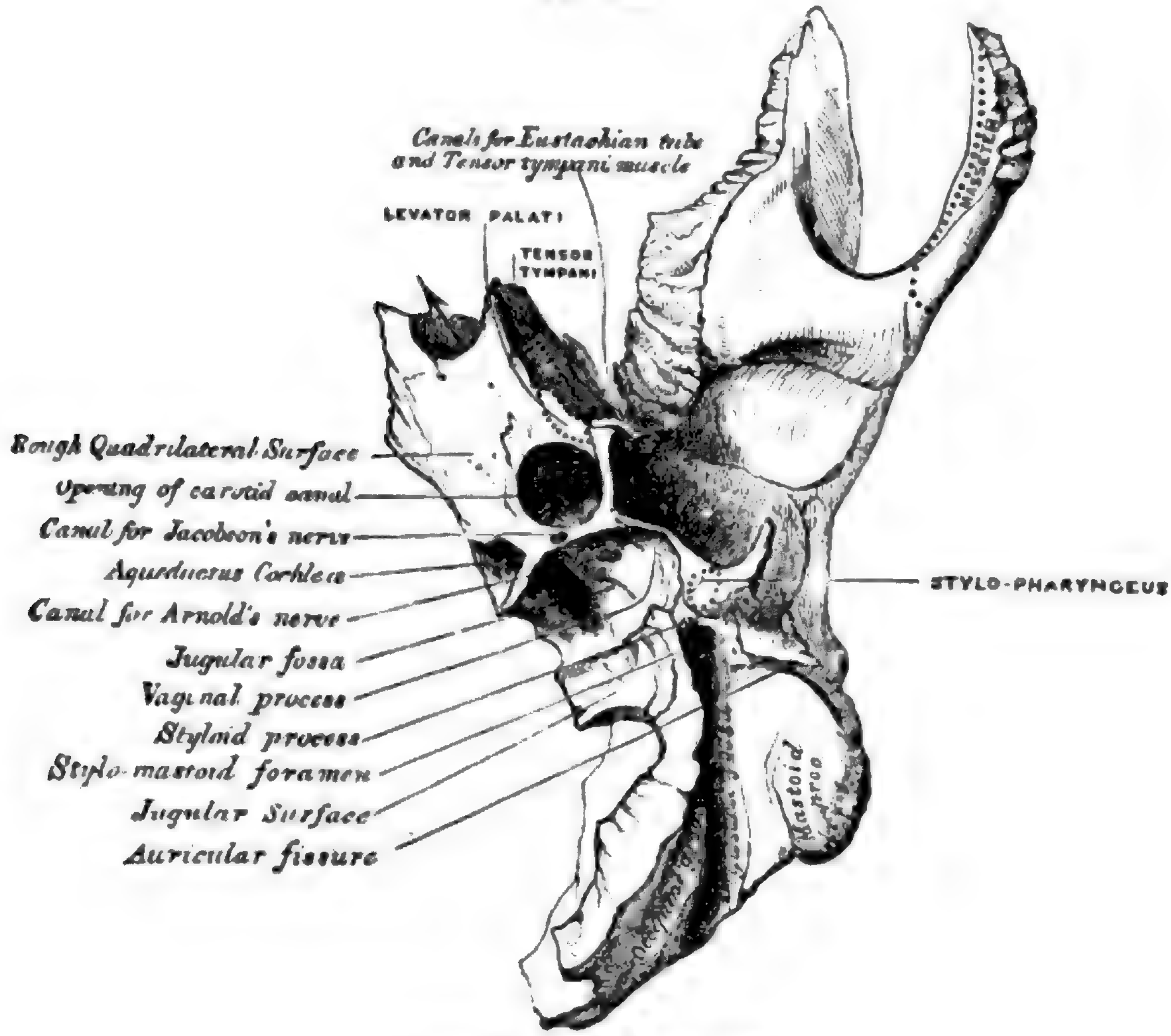
Canals for Eustachian tube and Tensor tympani muscle
LEVATOR PALATI
TENSOR TYMPANI
Rough Quadrilateral Surface
Opening of carotid canal
Canal for Jacobson's nerve
Aquæductus Cochleæ
Canal for Arnold's nerve
Jugular fossa
Vaginal process
Styloid process
Stylo-mastoid foramen
Jugular Surface
Auricular fissure
STYLO-PHARYNGEUS
Mastoid proc.

Petrous Portion, inferior surface.

The **anterior surface** of the petrous portion (Fig. 145) forms the posterior part of the middle fossa of the skull This surface is continuous with the squamous portion, to which it is united by a suture, the *temporal suture*, the remains of which are distinct even at a late period of life; it presents six points for examination: 1, An eminence near the centre, which indicates the situation of the superior semicircular canal; 2, on the outer side of this eminence a depression, indicating the position of the tympanum, the layer of bone which separates the tympanum from the cranial cavity being extremely thin; 3, a shallow groove, sometimes double, leading outward and backward to an oblique opening, the *hiatus Fallopii*, for the passage of the petrosal branch of the Vidian nerve and a branch of the middle meningeal artery; 4, a smaller opening, occasionally seen external to the latter, for the passage of the smaller petrosal nerve; 5, near the apex of the bone the termination of the carotid canal, the wall of which in this situation is deficient in front; 6, above this canal a shallow depression for the reception of the Gasserian ganglion.

The **posterior surface** forms the front part of the posterior fossa of the skull, and is continuous with the inner surface of the mastoid portion of the bone. It presents three points for examination: 1, About its centre a large orifice, the *meatus auditorius internus*, whose size varies considerably; its margins are smooth and rounded, and it leads into a short canal, about four lines in length, which runs directly outward and is closed by a vertical plate, the *lamina cribrosa*, which is divided by a horizontal crest into two unequal portions, the lower presenting several small apertures for the transmission of the filaments of the auditory nerve and the auditory artery, a branch of the basilar, the upper having one larger opening, the commencement of the aquæductus Fallopii, for the passage of the facial nerve; 2, behind the meatus auditorius a small slit, almost hidden by a thin plate of bone, leading to a canal, the *aquæductus vestibuli*, which transmits a small artery and vein and lodges a process of the dura mater; 3, in the interval between these two openings, but above them, an angular depression which lodges a process of the dura mater and transmits a small vein into the cancellous tissue of the bone.

The **inferior** or **basilar surface** (Fig. 145) is rough and irregular, and forms part of the base of the skull. Passing from the apex to the base, this surface presents eleven points for examination: 1, A rough surface, quadrilateral in form, which serves partly for the attachment of the Levator palati and Tensor tympani muscles; 2, the large circular aperture of the carotid canal, which ascends at first vertically, and then, making a bend, runs horizontally forward and inward: it transmits the internal carotid artery and the carotid plexus; 3, the *aquæductus cochleæ*, a small triangular opening lying on the inner side of the latter, close to the posterior border of the petrous portion: it transmits a vein from the cochlea which joins the internal jugular; 4, behind these openings a deep depression, the *jugular fossa*, which varies in depth and size in different skulls: it lodges the lateral sinus, and, with a similar depression on the margin of the jugular process of the occipital bone, forms the foramen lacerum posterius [or jugular foramen]; 5, a small foramen for the passage of Jacobson's nerve (the tympanic branch of the glosso-pharyngeal): this foramen is seen in front of the bony ridge dividing the carotid canal from the jugular fossa; 6, a small foramen on the outer wall of the jugular fossa, for the entrance of the auricular branch of the pneumogastric (Arnold's) nerve; 7, behind the jugular fossa a smooth, square-shaped facet, the *jugular surface*: it is covered with cartilage in the recent state, and articulates with the jugular process of the occipital bone; 8, the *vaginal process*, a very broad, sheath-like plate of bone which extends from the carotid canal to the mastoid process: it divides behind into two laminæ, receiving between them the ninth point for examination, the *styloid process*, a long sharp spine about an inch in length: it is directed downward, forward, and inward, varies in size and shape, and sometimes consists of several pieces united by cartilage: it affords attachment to three muscles, the Stylo-pharyngeus, Stylo-hyoideus, and Stylo-glossus, and two ligaments, the stylo-hyoid and stylo-maxillary; 10, the *stylomastoid foramen*, a rather large orifice, placed between the styloid and mastoid processes: it is the termination of the aquæductus Fallopii, and transmits the facial nerve and stylo-mastoid artery; 11, the *auricular fissure*, situated between the vaginal and mastoid processes, for the exit of the auricular branch of the pneumogastric nerve.

Borders.—The *superior*, the longest, is grooved for the superior petrosal sinus, and has attached to it the tentorium cerebelli; at its inner extremity is a semilunar notch, upon which the fifth nerve lies. The *posterior* border is intermediate in length between the superior and the anterior. Its inner half is marked by a groove which, when completed by its articulation with the occipital, forms the channel for the inferior petrosal sinus. Its outer half presents a deep excavation—the *jugular fossa*—which, with a similar notch on the occipital, forms the foramen lacerum posterius. A projecting eminence of bone occasionally stands out from the centre of the notch and divides the foramen into two parts. The *anterior* border is divided into two parts—an outer, joined to the squamous portion by a suture, the remains of which are distinct; an inner, free, articulating with the spinous process of the sphenoid. At the angle of junction of the petrous and squamous portions are seen two canals, separated from one another by a thin plate of bone, the *processus cochleariformis:* they both lead into the tympanum, the upper one transmitting the Tensor tympani muscle, the lower one the Eustachian tube.

Structure.—The squamous portion is like that of the other cranial bones, the mastoid portion cellular, and the petrous portion dense and hard.

Development (Fig. 146).—The temporal bone is developed by *ten* centres, exclusive of those for the internal ear and the ossicula—viz. one for the squamous portion, including the zygoma, one for the auditory process (tympanic ring), six for the petrous and mastoid parts, and two for the styloid process. Just before the close of fœtal life the temporal bone consists of four parts: 1. The *squamo-zygomatic*, which is ossified in membrane from a single nucleus which appears at its lower part about the second month. 2. The *auditory process*, an imperfect ring which encloses the tympanic membrane. This is also ossified from a single centre, which appears rather later than that for the squamous portion. 3. The *petro-mastoid*, which is developed from six centres, which appear about the fifth or sixth month. Four of these are for the petrous portion, and are placed around the labyrinth, and two for the mastoid (Vrolik). According to Huxley, the centres are more numerous and are disposed so as to form three portions: (1) Including most of the labyrinth, with a part of the petrous and mastoid, he has named *proötic;* (2) the rest of the petrous, the *opisthotic;* and (3) the remainder of the mastoid, the *epiotic*. The petro-mastoid is ossified in cartilage. 4. The *styloid process* is also ossified in cartilage from two centres—one for the base, which appears before birth and is termed the *tympano-hyal;* the other, comprising the rest of the process, is named the *stylo-hyal*, and does not appear until after birth. Shortly before birth the auditory process joins with the squamous. The petrous and mastoid join with the squamous during the first year, and the tympano-hyal portion of the styloid process about the same time. The stylo-hyal does not join the rest of the bone until after puberty, and in some skulls never becomes united. The subsequent changes in this bone are, that the auditory process extends outward, so as to form the meatus auditorius; the glenoid fossa becomes deeper; and the mastoid part, which at an early

FIG. 146.

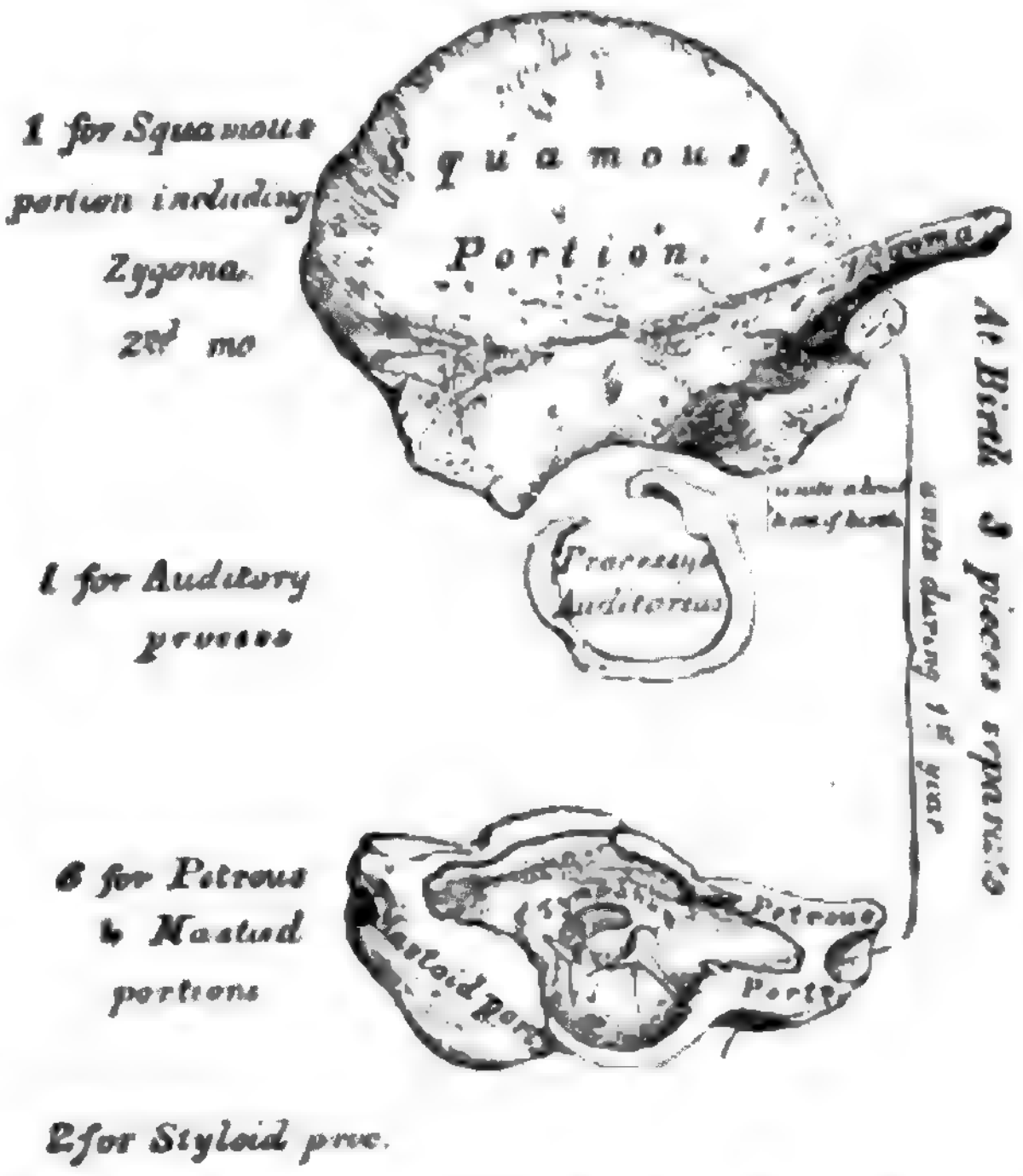

Development of the Temporal Bone, by ten centres.

period of life is quite flat, enlarges from the development of the cellular cavities in its interior.

Articulations.—With five bones—occipital, parietal, sphenoid, inferior maxillary, and malar.

Attachment of Muscles.—To fifteen: to the squamous portion, the Temporal; to the zygoma, the Masseter; to the mastoid portion, the Occipito-frontalis, Sterno-mastoid, Splenius capitis, Trachelo-mastoid, Digastricus, and Retrahens aurem; to the styloid process, the Stylo-pharyngeus, Stylo-hyoideus, and Stylo-glossus; and to the petrous portion, the Levator palati, Tensor tympani, Tensor palati, and Stapedius.

THE SPHENOID BONE.

The **Sphenoid Bone** (σφήν, a wedge) is situated at the anterior part of the base of the skull, articulating with all the other cranial bones, which it binds firmly and solidly together. In its form it somewhat resembles a bat with its wings extended, and is divided into a central portion or body, two greater and two lesser wings extending outward on each side of the body; and two processes—the pterygoid processes—which project from it below.

The **Body** is of large size, cuboid in form, and hollowed out in its interior so as to form a mere shell of bone. It presents for examination *four* surfaces—a superior, an inferior, an anterior, and a posterior.

The Superior Surface (Fig. 147).—In front is seen a prominent spine, the *ethmoidal spine*, for articulation with the cribriform plate of the ethmoid; behind this, a smooth surface presenting, in the median line, a slight longitudinal eminence, with a depression on each side, for lodging the olfactory nerves. A narrow transverse groove, the *optic groove*, bounds the above-mentioned surface behind; it lodges the optic commissure, and terminates on either side in the *optic foramen*, for the passage of the optic nerve and ophthalmic artery. Behind the optic groove is a small eminence, olive-like in shape, the *olivary process;* and still more posteriorly, a deep depression, the *pituitary fossa*, or *sella Turcica*, which lodges the pituitary body. This fossa is perforated by numerous foramina for the transmission of nutrient vessels into the substance of the bone. It is bounded in front by two small eminences, one on either side, called the *middle clinoid processes* (κλίνη, a bed), and behind by a square-shaped plate of bone, the *dorsum ephippii* or *dorsum sellæ*, ter-

FIG. 147.

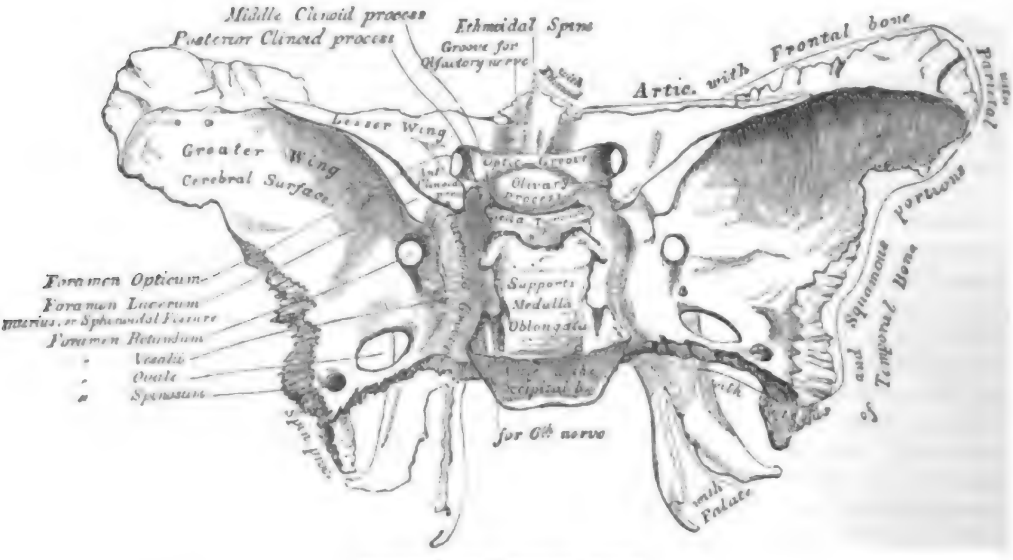
Middle Clinoid process
Posterior Clinoid process
Ethmoidal Spine
Groove for Olfactory nerve
Artic. with Frontal bone
with Parietal
Lesser Wing
Greater Wing
Cerebral Surface
Optic Groove
Olivary Process
Supports Medulla Oblongata
Foramen Opticum
Foramen Lacerum
...terius, or Sphenoidal Fissure
Foramen Rotundum
Vesalii
Ovale
Spinosum
for 6th nerve
with Occipital bo
Spin proc.
with Palate
with
and Squamous portions of Temporal Bone

Sphenoid Bone, superior surface.

minating at each superior angle in a tubercle, the *posterior clinoid processes*, the size and form of which vary considerably in different individuals. These processes deepen the pituitary fossa, and serve for the attachment of prolongations from the tentorium cerebelli. The sides of the dorsum ephippii are notched for the passage of the sixth pair of nerves, and behind this plate of bone presents a shallow depression, which slopes obliquely backward and is continuous with the basilar groove of the occipital bone; it is called the *clivus Blumenbachii*, and supports the upper part of the pons Varolii. On either side of the body is a broad groove, curved something like the italic letter *f*; it lodges the internal carotid artery and the cavernous sinus, and is called the *carotid* or *cavernous groove*. Along the outer margin of this groove, at its posterior part, is a ridge of bone called the *lingula*. The **posterior surface**, quadrilateral in form, is joined to the basilar process of the occipital bone. During childhood these bones are separated by a layer of cartilage, but in after-life (between the eighteenth and twenty-fifth years) this becomes ossified, ossification commencing above and extending downward, and the two bones then form one piece. The **anterior surface** (Fig. 148) presents, in the middle line, a vertical lamella of bone, the *ethmoidal crest*, which articulates in front with the perpendicular plate of the ethmoid, forming part of the septum of the nose. On either side of it are the irregular openings leading into the *sphenoidal cells* or *sinuses*. [See Fig. 181.]

FIG. 148.

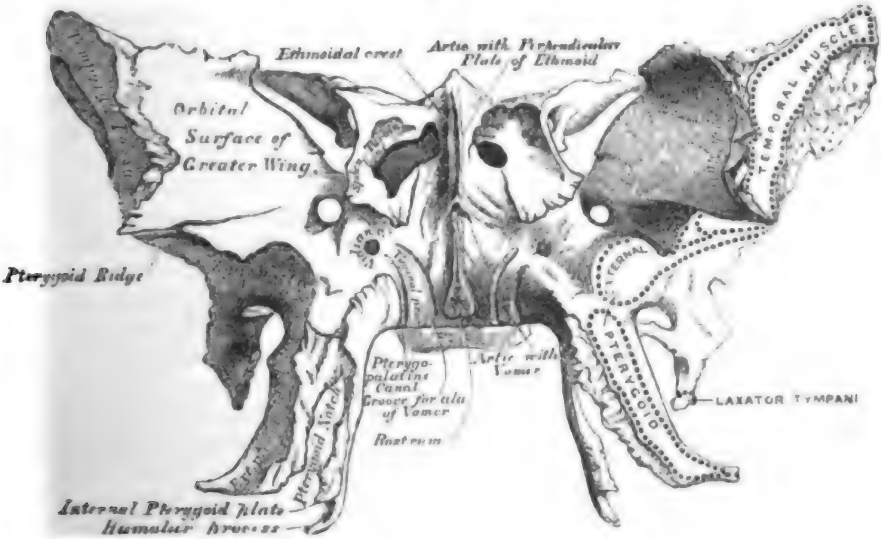
Ethmoidal crest
Artic. with Perpendicular Plate of Ethmoid
TEMPORAL MUSCLE
Orbital Surface of Greater Wing.
Pterygoid Ridge
EXTERNAL
Pterygo-palatine Canal
Artic. with Vomer
Groove for ala of Vomer
Rostrum
PTERYGOID
LAXATOR TYMPANI
Pterygoid Notch
Internal Pterygoid plate
Hamular process

Sphenoid Bone, anterior surface.[1]

These are two large irregular cavities hollowed out of the interior of the body of the sphenoid bone, and separated from one another by a more or less complete perpendicular bony septum. Their form and size vary considerably; they are seldom symmetrical, and are often partially subdivided by irregular osseous laminæ. Occasionally they extend into the basilar process of the occipital nearly as far as the foramen magnum. The septum is seldom quite vertical, being commonly bent to one or the other side. These sinuses do not exist in children, but they increase in size as age advances. They are partially closed, in front and below, by two thin curved plates of bone, the *sphenoidal turbinated* bones, leaving a round opening at their upper parts, by which they communicate with the upper and back part of the nose, and occasionally with the posterior ethmoidal cells or sinuses. The lateral margins of this surface present a serrated edge which articulates with the os planum of the ethmoid, completing the posterior ethmoidal cells; the lower margin, also rough and serrated, articulates with the orbital process of the palate bone, and the upper margin with the orbital plate of the frontal bone. The **inferior surface** presents, in the middle line, a triangular spine, the *rostrum*, which is continuous with the vertical plate on the anterior surface, and is received into a deep fissure between the alæ of the vomer. On each side may be seen a projecting lamina of bone which runs horizontally inward from near the base of the pterygoid process: these plates, termed the *vaginal processes*, articulate with the edges of the vomer. Close to the root of the pterygoid process is a groove, formed into a complete canal when articulated with the sphenoidal process of the palate bone; it is called the *pterygo-palatine canal*, and transmits the pterygo-palatine vessels and pharyngeal nerve.

---

[1] In this figure both the anterior and inferior surfaces of the body of the sphenoid bone are shown, the bone being held with the pterygoid processes almost horizontal.

The **Greater Wings** are two strong processes of bone which arise from the sides of the body, and are curved in a direction upward, outward, and backward, being prolonged behind into a sharp-pointed extremity, the *spinous process* of the sphenoid. Each wing presents three surfaces and a circumference. The *superior* or *cerebral* surface (Fig. 147) forms part of the middle fossa of the skull; it is deeply concave, and presents eminences and depressions for the convolutions of the brain. At its anterior and internal part is seen a circular aperture, the *foramen rotundum*, for the transmission of the second division of the fifth nerve. Behind and external to this is a large oval foramen, the *foramen ovale*, for the transmission of the third division of the fifth nerve, the small meningeal artery, and sometimes the small petrosal nerve.[1] At the inner side of the foramen ovale a small aperture may occasionally be seen opposite the root of the pterygoid process; it is the *foramen Vesalii*, transmitting a small vein. Lastly, in the posterior angle, near to the spine of the sphenoid, is a short canal, sometimes double, the *foramen spinosum*; it transmits the middle meningeal artery. The *external* surface (Fig. 148) is convex, and divided by a transverse ridge, the *pterygoid ridge*, into two portions. The superior or larger, convex from above downward, concave from before backward, enters into the formation of the temporal fossa and gives attachment to part of the Temporal muscle. The inferior portion, smaller in size and concave, enters into the formation of the zygomatic fossa and affords attachment to the External pterygoid muscle. It presents, at its posterior part, a sharp-pointed eminence of bone, the *spinous process*, to which are connected the internal lateral ligament of the lower jaw and the Tensor palati muscle. The pterygoid ridge, dividing the temporal and zygomatic portions, gives attachment to part of the External pterygoid muscle. At its inner and anterior extremity is a triangular spine of bone which serves to increase the extent of origin of this muscle. The *anterior* or *orbital* surface, smooth and quadrilateral in form, assists in forming the outer wall of the orbit. It is bounded above by a serrated edge, for articulation with the frontal bone; below, by a rounded border which enters into the formation of the spheno-maxillary fissure; internally, it presents a sharp border which forms the lower boundary of the sphenoidal fissure, and has projecting from about its centre a little tubercle of bone, which gives origin to one head of the external rectus muscle of the eye, and at its upper part is a notch for the transmission of a branch of the ophthalmic artery; externally it presents a serrated margin for articulation with the malar bone. One or two small foramina may occasionally be seen for the passage of branches of the deep temporal arteries; they are called the *external orbital foramina*. *Circumference of the great wing* (Fig. 147): commencing from behind, from the body of the sphenoid to the spine, the outer half of this margin is serrated, for articulation with the petrous portion of the temporal bone, whilst the inner half forms the anterior boundary of the foramen lacerum medium and presents the posterior aperture of the Vidian canal. In front of the spine the circumference of the great wing presents a serrated edge, bevelled at the expense of the inner table below and of the external above, which articulates with the squamous portion of the temporal bone. At the tip of the great wing a triangular portion is seen, bevelled at the expense of the internal surface, for articulation with the anterior inferior angle of the parietal bone. Internal to this is a broad serrated surface, for articulation with the frontal bone: this surface is continuous internally with the sharp inner edge of the orbital plate, which assists in the formation of the sphenoidal fissure.

---

[1] The small petrosal nerve sometimes passes through a special foramen between the foramen ovale and foramen spinosum.

The **Lesser Wings** (*processes of Ingrassias*) are two thin triangular plates of bone which arise from the upper and lateral parts of the body of the sphenoid, and, projecting transversely outward, terminate in a sharp point (Fig. 147). The superior surface of each is smooth, flat, broader internally than externally, and supports the anterior lobe of the brain. The inferior surface forms the back part of the roof of the orbit and the upper boundary of the sphenoidal fissure or foramen lacerum anterius. This fissure is of a triangular form, and leads from the cavity of the cranium into the orbit; it is bounded internally by the body of the sphenoid—above by the lesser wing, below by the internal margin of the orbital surface of the great wing—and is converted into a foramen by the articulation of this bone with the frontal. It transmits the third, the fourth, the ophthalmic division of the fifth, and [the] sixth cranial nerves, some filaments from the cavernous plexus of the sympathetic, the orbital branch of the middle meningeal artery, a recurrent branch from the lachrymal artery to the dura mater, and the ophthalmic vein. The anterior border of the lesser wing is serrated for articulation with the frontal bone; the posterior, smooth and rounded, is received into the fissure of Sylvius of the brain. The inner extremity of this border forms the *anterior clinoid process*. The lesser wing is connected to the side of the body by two roots, the upper thin and flat, the lower thicker, obliquely directed, and presenting on its outer side, near its junction with the body, a small tubercle, for the attachment of the common tendon of three of the muscles of the eye. Between the two roots is the *optic foramen*, for the transmission of the optic nerve and ophthalmic artery.

The **Pterygoid Processes** (πτέρυξ, a wing; εἶδος, likeness) (Fig. 149), one on each side, descend perpendicularly from the point where the body and greater wing unite. Each process consists of an external and an internal plate, separated behind by an intervening notch, the *pterygoid fossa*, but joined partially in front. The *external pterygoid plate* is broad and thin, turned a little outward, and forms part of the inner wall of the zygomatic fossa. It gives attachment, by its outer surface, to the External pterygoid; its inner surface forms part of the pterygoid fossa, and gives attachment to the Internal pterygoid. The *internal pterygoid plate* is much narrower and longer, curving outward at its extremity into a hook-like process of bone, the *hamular process*, around which turns the tendon of the Tensor palati muscle. At the base of this plate is a small, oval, shallow depression, the *scaphoid fossa*, from which arises the Tensor palati, and above which is seen the posterior orifice of the Vidian canal. The outer surface of this plate forms part of the pterygoid fossa, the inner surface forming the outer boundary of the posterior aperture of the nares. The Superior constrictor of the pharynx is attached to its posterior edge. The two pterygoid plates are separated below by an angular interval, in which the pterygoid process or tuberosity of the palate bone is received. The anterior surface of the pterygoid process is very broad at its base, and forms the posterior wall of the spheno-maxillary fossa. It

Fig. 149.

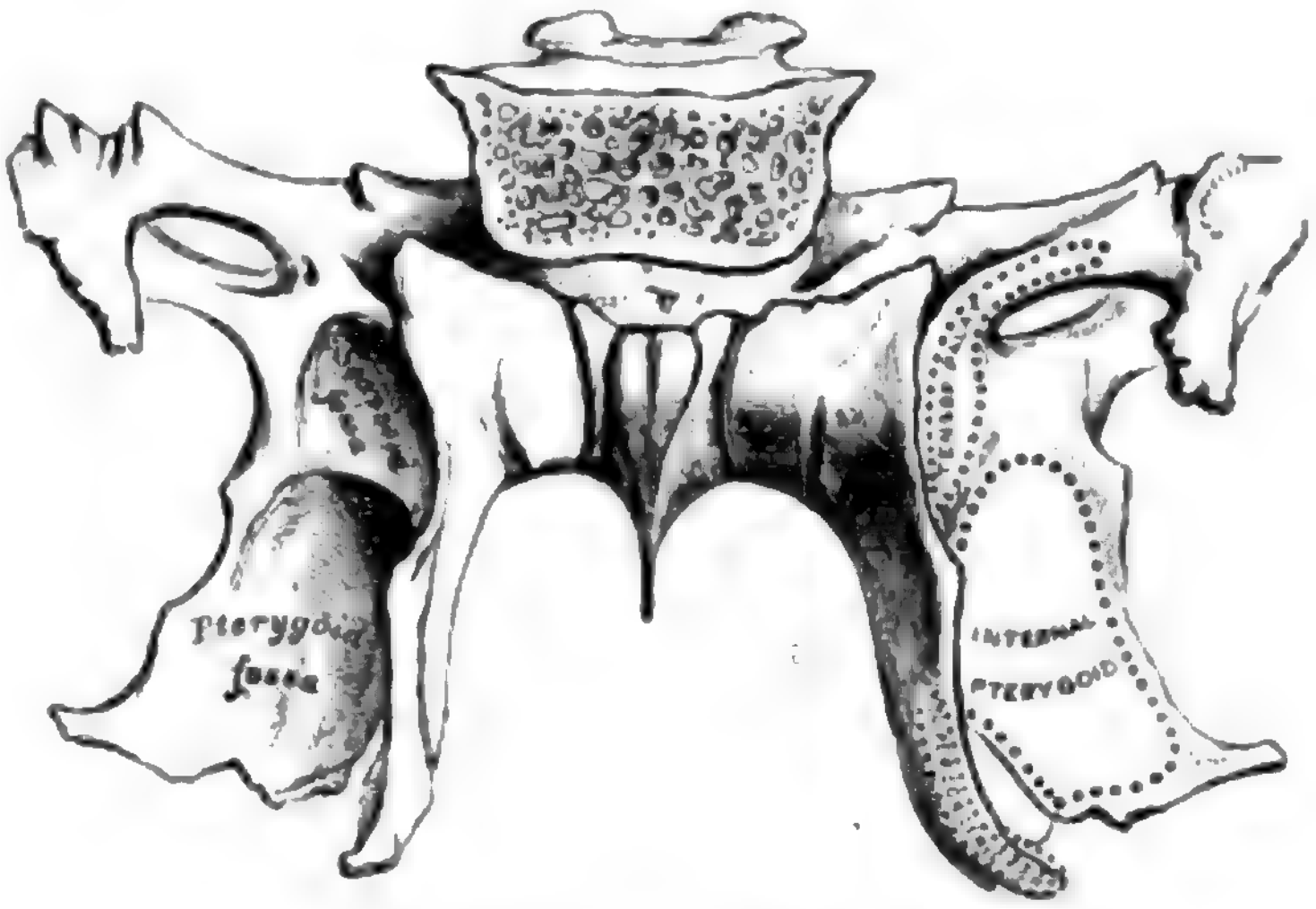

Sphenoid Bone, posterior surface.

supports Meckel's ganglion. It presents above the anterior orifice of the Vidian canal, and below a rough margin which articulates with the perpendicular plate of the palate bone.

The **Sphenoidal Turbinated** or **Sphenoidal Spongy Bones** [Fig. 148] are two thin curved plates of bone, which exist as separate pieces until puberty, and occasionally are not joined to the sphenoid in the adult. They are situated at the anterior and inferior part of the body of the sphenoid, an aperture of variable size being left in their anterior wall, through which the sphenoidal sinuses open into the nasal fossæ. They are irregular in form, and taper to a point behind, being broader and thinner in front. Their inner surface, which looks toward the cavity of the sinus, is concave; their outer surface, convex. Each bone articulates in front with the ethmoid, externally with the palate; its pointed posterior extremity is placed above the vomer, and is received between the root of the pterygoid process on the outer side and the rostrum of the sphenoid on the inner.[1]

Development.—Up to about the eighth month of fœtal life the sphenoid bone consists of two distinct parts: a posterior or *postsphenoid* part, which comprises the pituitary fossa, the greater wings, and the pterygoid processes; and an anterior or *presphenoid* part, to which the anterior part of the body and lesser wings belong. It is developed by fourteen centres—eight for the posterior sphenoid division, and six for the anterior sphenoid. The eight centres for the posterior sphenoid are—one for each greater wing and external pterygoid plate, one for each internal pterygoid plate, two for the posterior part of the body, and one on either side for the lingula. The six for the anterior sphenoid are—one for each lesser wing, two for the anterior part of the body, and one for each sphenoidal turbinated bone.

FIG. 150.

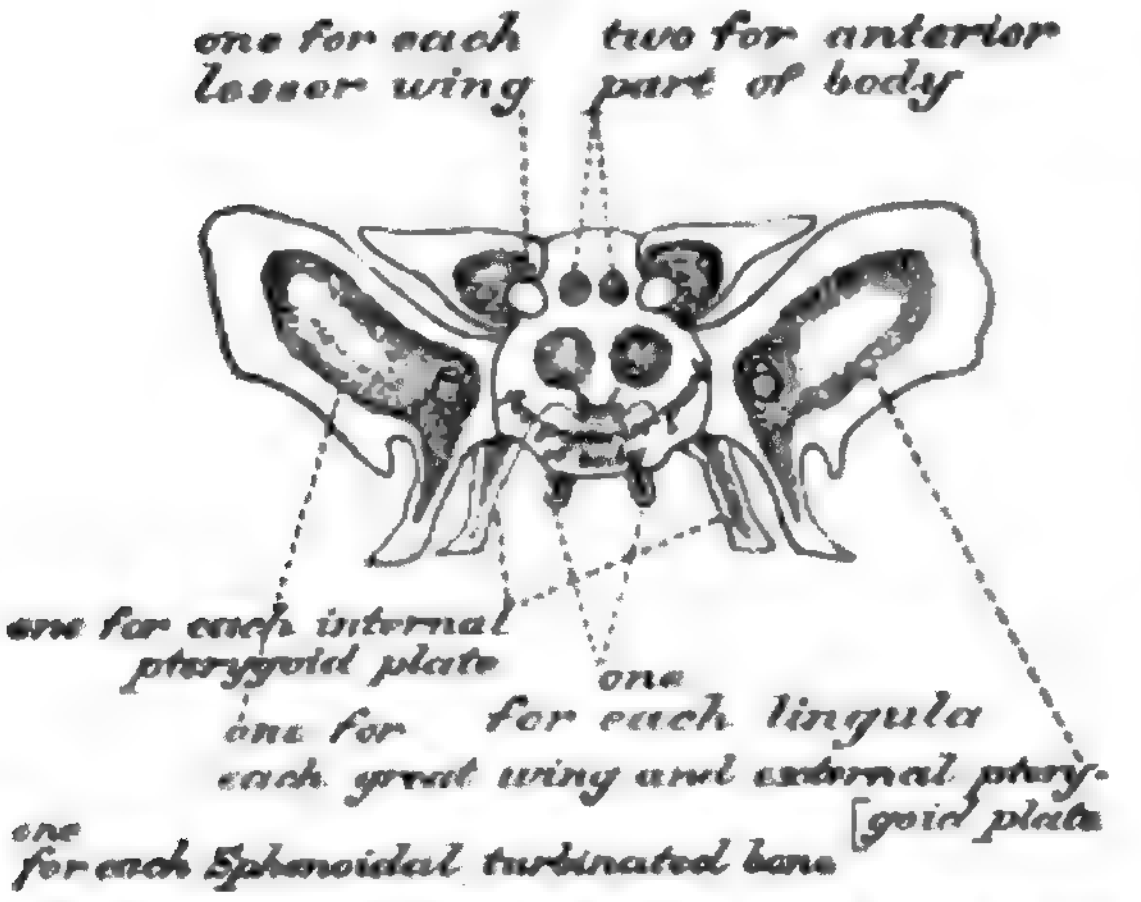
one for each lesser wing
two for anterior part of body
one for each internal pterygoid plate
one for each lingula
one for each great wing and external pterygoid plate
one for each Sphenoidal turbinated bone

Plan of the Development of Sphenoid, by fourteen centres.

Postsphenoid Division.—The first nuclei to appear are those for the greater wings. They make their appearance between the foramen rotundum and foramen ovale about the eighth week, and from them the external pterygoid plates are also formed. Soon after the nuclei for the posterior part of the body appear, one on either side of the sella Turcica, and become blended together about the middle of fœtal life. About the fourth month the remaining four centres appear, those for the internal pterygoid plates being ossified in membrane and becoming joined to the external pterygoid plate about the sixth month. The centres for the lingulæ speedily become joined to the rest of the bone.

Presphenoid Division.—The first nuclei to appear are those for the lesser wings. They make their appearance about the ninth week at the outer borders of the optic foramina. A second pair of nuclei appear on the inner side of the foramina shortly after, and, becoming united, form the front part of the body of the bone. The remaining two centres for the sphenoidal turbinated bones do not make their appearance until the end of the third year, and become joined to the body of the bone after puberty.

The presphenoid is united to the body of the postsphenoid about the eighth month, so that at birth the bone consists of three pieces—viz. the body in the centre, and on each side the great wings with the pterygoid processes. At the first year after birth the greater wings and body are united. From the tenth to the twelfth year the spongy bones are partially united to the sphenoid, their junction being complete by the twentieth year. Lastly, the sphenoid joins the occipital from the eighteenth to the twenty-fifth year.

---

[1] A small portion of the sphenoidal turbinated bone sometimes enters into the formation of the inner wall of the orbit, between the os planum of the ethmoid in front, the orbital plate of the palate below, and the frontal above (Cleland, *Roy. Soc. Trans.*, 1862).

Articulations.—The sphenoid articulates with *all* the bones of the cranium and five of the face—the two malar, two palate, and vomer: the exact extent of articulation with each bone is shown in the accompanying figures.[1]

Attachment of Muscles.—To twelve pairs: the Temporal, External pterygoid, Internal pterygoid, Superior constrictor, Tensor palati, Laxator tympani, Levator palpebræ, Obliquus superior, Superior rectus, Internal rectus, Inferior rectus, External rectus.

The Ethmoid Bone.

The **Ethmoid** (ἠθμός, a sieve) is an exceedingly light, spongy bone, of a cubical form, situated at the anterior part of the base of the cranium, between the two orbits, at the root of the nose, and contributing to form each of these cavities. It consists of three parts: a horizontal plate, which forms part of the base of the cranium; a perpendicular plate, which forms part of the septum nasi; and two lateral masses of cells.

Fig. 151.

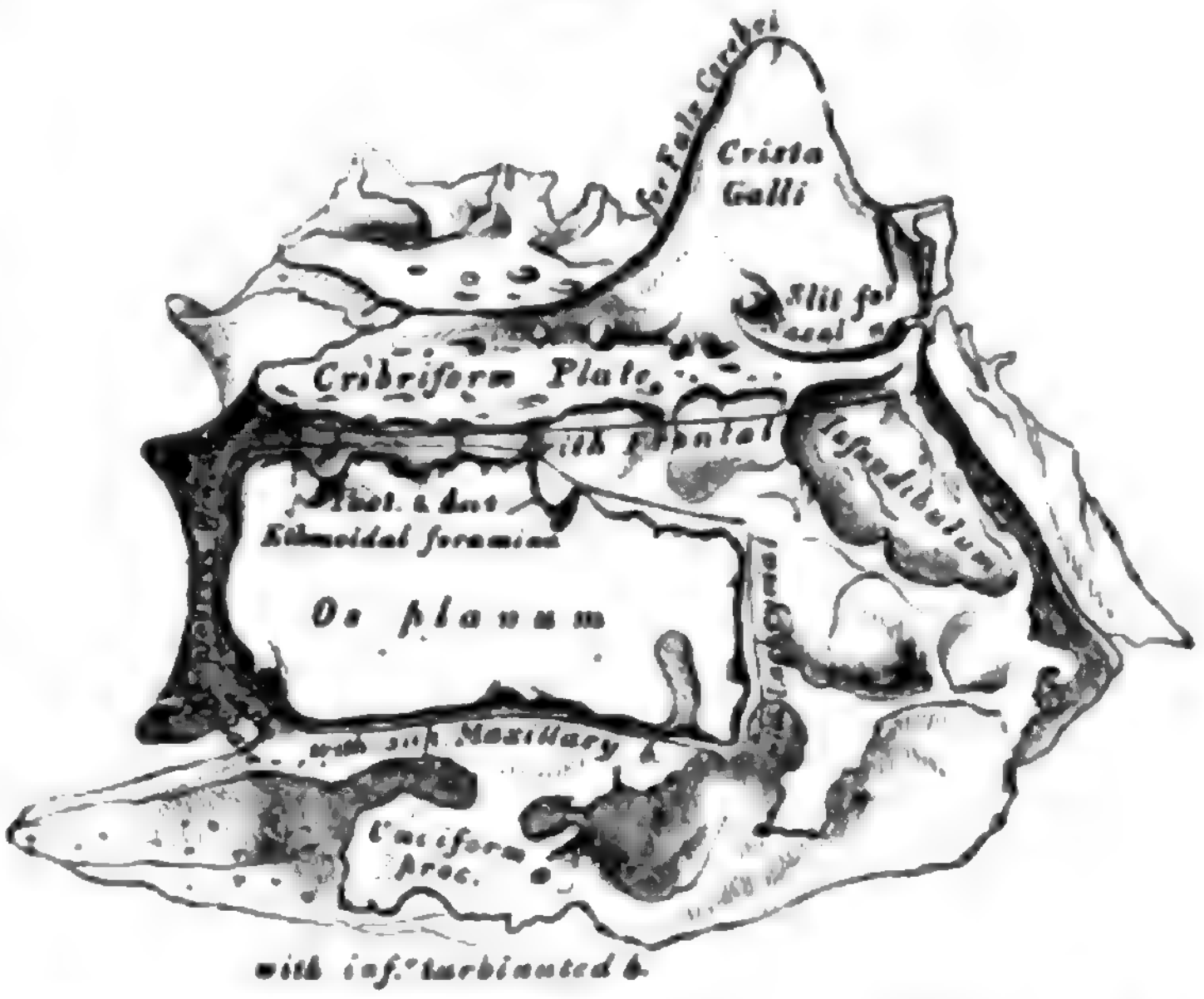

Ethmoid Bone: outer surface of right lateral mass (enlarged).

The **Horizontal** or **Cribriform Plate** (Fig. 151) forms part of the anterior fossa of the base of the skull, and is received into the ethmoid notch of the frontal bone between the two orbital plates. Projecting upward from the middle line of this plate is a thick, smooth, triangular process of bone, the *crista galli*, so called from its resemblance to a cock's comb. Its base joins the cribriform plate. Its posterior border, long, thin, and slightly curved, serves for the attachment of the falx cerebri. Its anterior border, short and thick, articulates with the frontal bone, and presents two small projecting alæ, which are received into corresponding depressions in the frontal, completing the foramen cæcum behind. Its sides are smooth, and sometimes bulging, in which case it is found to enclose a small sinus.[2] On each side of the crista galli the cribriform plate is narrow and deeply grooved, to support the bulb of the olfactory nerve, and perforated by foramina for the passage of its filaments. These foramina are arranged in three rows: the innermost, which are the largest and least numerous, are lost in grooves on the upper part of the septum; the foramina of the outer row are continued on to the surface of the upper spongy bone. The foramina of the middle row are the smallest; they perforate the bone and transmit nerves to the roof of the nose. At the front part of the cribriform plate, on each side of the crista galli, is a small fissure which transmits the nasal branch of the ophthalmic nerve, and at its posterior part a triangular notch which receives the ethmoidal spine of the sphenoid.

The **Perpendicular Plate** (Fig. 152) is a thin, flattened lamella of bone which descends from the under surface of the cribriform plate and assists in forming the septum of the nose. It is much thinner in the middle than at the circumference, and is generally deflected a little to one side. Its anterior border articulates with the nasal spine of the frontal bone and crest of the nasal bones. Its posterior, divided into two parts, is connected by its upper half with the rostrum of the sphenoid—by its lower half with the vomer. The inferior border serves for the attachment of the triangular cartilage of the nose. On each side of the perpendicular plate numerous grooves and canals are seen leading from foramina on the cribriform plate; they lodge filaments of the olfactory nerves.

---

[1] It also sometimes articulates with the superior maxilla. (See p. 152.)

[2] Dr. Humphry states that the crista galli is commonly inclined to one side, usually the opposite to that toward which the lower part of the perpendicular plate is bent (*The Human Skeleton*, 1858, p. 277).

FIG. 152.

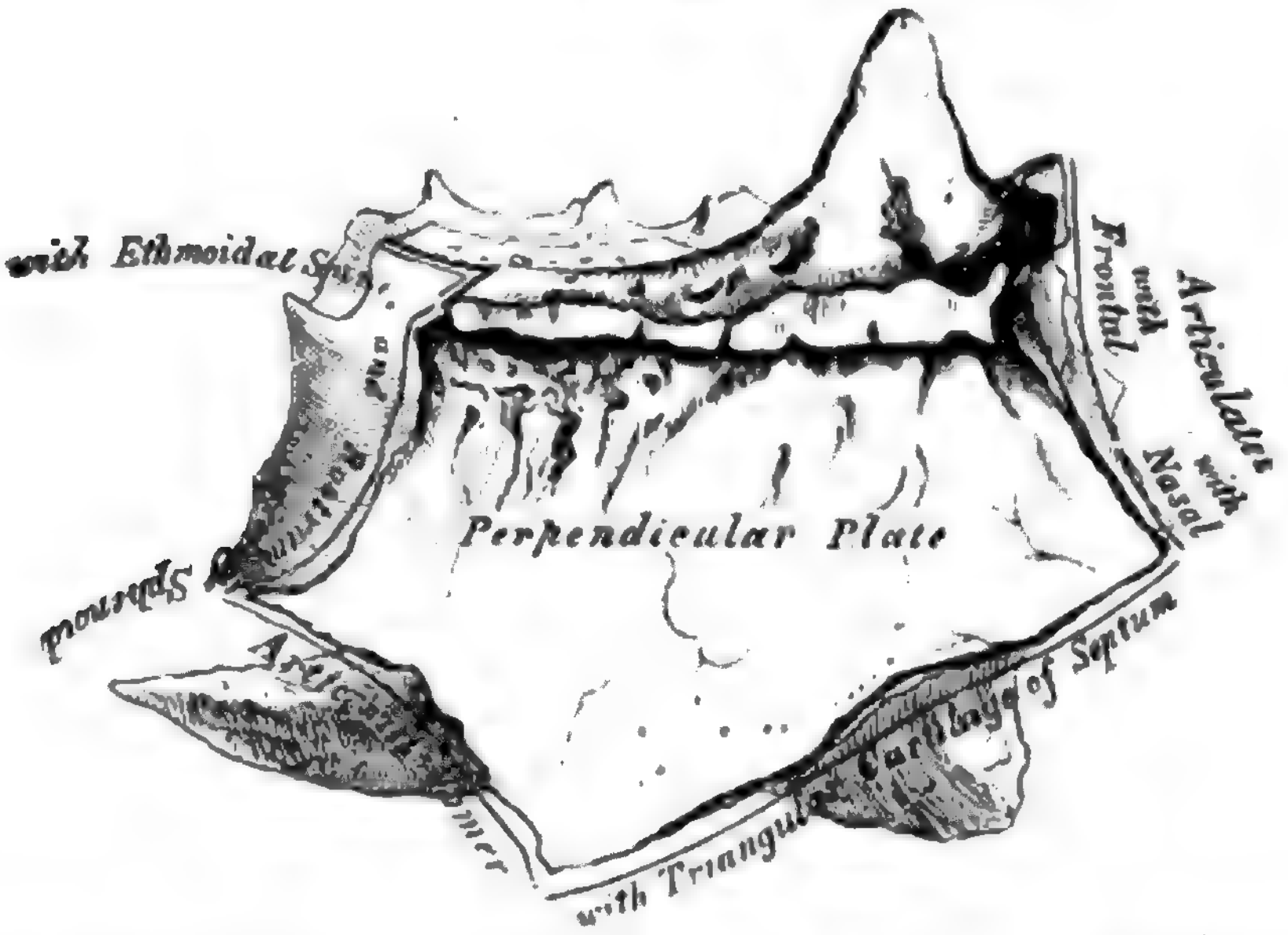

Perpendicular Plate of Ethmoid (enlarged), shown by removing the right lateral mass.

The **Lateral Masses** of the ethmoid consist of a number of thin-walled cellular cavities, the *ethmoidal cells*, interposed between two vertical plates of bone, the outer one of which forms part of the orbit, and the inner one part of the nasal fossa of the corresponding side. In the disarticulated bone many of these cells appear to be broken, but when the bones are articulated they are closed in at every part. The upper surface of each lateral mass presents a number of apparently half-broken cellular spaces; these are closed in when articulated by the edges of the ethmoidal notch of the frontal bone. Crossing this surface are two grooves on each side, converted into canals by articulation with the frontal; they are the *anterior* and *posterior ethmoidal* foramina, and open on the inner wall of the orbit. The posterior surface also presents large irregular cellular cavities, which are closed in by articulation with the sphenoidal turbinated bones and orbital process of the palate. The cells at the anterior surface are completed by the lachrymal bone and nasal process of the superior maxillary, and those below also by the superior maxillary. The outer surface of each lateral mass is formed of a thin, smooth square plate of bone called the *os planum:* it forms part of the inner wall of the orbit, and articulates above with the orbital plate of the frontal; below with the superior maxillary and orbital process of the palate; in front with the lachrymal; and behind with the sphenoid.

From the inferior part of each lateral mass, immediately beneath the os planum, there projects downward and backward an irregular lamina of bone called the *unciform process*, from its hook-like form: it serves to close in the upper part of the orifice of the antrum, and articulates with the ethmoidal process of the inferior turbinated bone. It is often broken in disarticulating the bones.

The inner surface of each lateral mass forms part of the outer wall of the nasal fossa of the corresponding side. It is formed of a thin lamella of bone which descends from the under surface of the cribriform plate, and terminates below in a free convoluted margin, the *middle turbinated* bone. The whole of this surface is rough, and marked above by numerous grooves, which run nearly vertically downward from the cribriform plate; they lodge branches of the olfactory nerve, which are distributed on the mucous membrane covering the bone. The back part of this surface is subdivided by a narrow oblique fissure, the *superior meatus* of the nose, bounded above by a thin curved plate of bone—the *superior turbinated* bone. By means of an orifice at the upper part of this fissure the posterior ethmoidal cells open into the nose. Below, and in front of the superior meatus, is seen the convex surface of the *middle turbinated* bone. It extends along the whole length of the inner surface of each lateral mass; its lower margin is free and thick, and its concavity, directed outward, assists in forming the middle meatus. It is by a large orifice at the upper and front part of the middle meatus that the anterior ethmoidal cells, and through them the frontal sinuses, communicate with the nose by means of a funnel-shaped canal, the *infundibulum*. The cellular cavities of each lateral mass, thus walled in by the os planum on the outer side and by the other bones already mentioned, are divided by a thin transverse bony partition into two sets, which do not communicate with each other; they are termed the *anterior* and *posterior ethmoidal cells* or *sinuses*. The former, more numerous, communicate with the frontal sinuses above and the middle meatus below by means of a long flexuous cellular canal, the *infundibulum;* the posterior, less numerous, open into the superior meatus, and communicate (occasionally) with the sphenoidal sinuses.

Fig. 153.

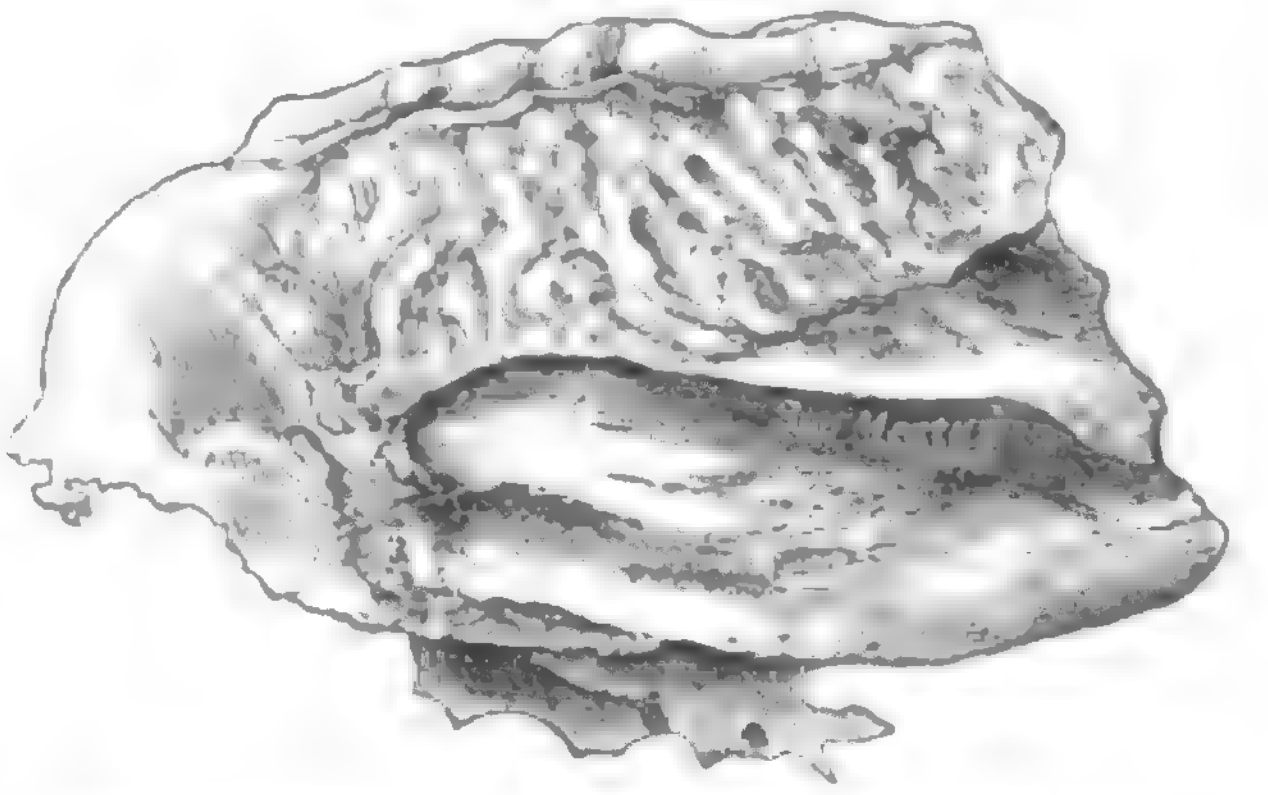

Ethmoid Bone, inner surface of right lateral mass (enlarged).

Development.—By *three* centres—one for the perpendicular lamella and one for each lateral mass.

The lateral masses are first developed, ossific granules making their first appearance in the os planum between the fourth and fifth months of fœtal life, and extending into the spongy bones. At birth the bone consists of the two lateral masses, which are small and ill developed. During the first year after birth the perpendicular and horizontal plates begin to ossify from a single nucleus, and become joined to the lateral masses about the beginning of the second year. The formation of the ethmoidal cells, which completes the bone, does not commence until about the fourth or fifth year.

Articulations.—With fifteen bones: the sphenoid, two sphenoidal turbinated, the frontal, and eleven of the face—the two nasal, two superior maxillary, two lachrymal, two palate, two inferior turbinated, and the vomer. No muscles are attached to this bone.

DEVELOPMENT OF THE CRANIUM.

The early stages of the development of the cranium have already been described (see p. 115). We have seen that it is formed from a layer of mesoblast, derived from the protovertebral plates of the trunk, which is spread over the whole surface of the rudimentary brain. That portion of this layer from which the bones of the skull are to be developed consists of a thin membranous capsule.

Ossification commences in this, in the first place, in the roof, and is preceded by the deposition of a membranous blastema upon the surface of the cerebral capsule, in which the ossifying process extends, the primitive membranous capsule becoming the internal periosteum and being ultimately blended with the dura mater. Although the bones of the vertex of the skull appear before those at the base, and make considerable progress in their growth, at birth ossification is more advanced in the base, this portion of the skull forming a solid, immovable groundwork.

THE FONTANELLES (Figs. 154, 155).

Before birth the bones at the vertex and side of the skull are separated from each other by membranous intervals in which bone is deficient. These intervals are principally found at the four angles of the parietal bones. In consequence of the wave of ossification being circular and the bones quadrilateral, the ossific matter first meets at the margins of the bones at the points nearest to their centres of ossification, and vacuities or spaces are left at the angles, which are called *fontanelles*, so named from the pulsations of the brain, which are perceptible at the anterior fontanelle, and were likened to the rising of water in a fountain. The anterior fontanelle is the largest, and corresponds to the junction of the sagittal and coronal sutures; the posterior fontanelle, of smaller size, is situated at the junction of the sagittal and lambdoid sutures; the remaining ones are situated at the inferior angles of the parietal bone. The latter are closed soon after birth; the two at the superior angles remain open longer, the posterior being closed in a few months after birth, the anterior remaining open until the first or second year. These spaces are gradually filled in by an extension of the ossifying process or by the development of a Wormian bone. Sometimes the anterior fontanelle remains open beyond two years, and is occasionally persistent throughout life. [Its persistence and enlargement are generally indicative of hydrocephalus.]

FIG. 154.

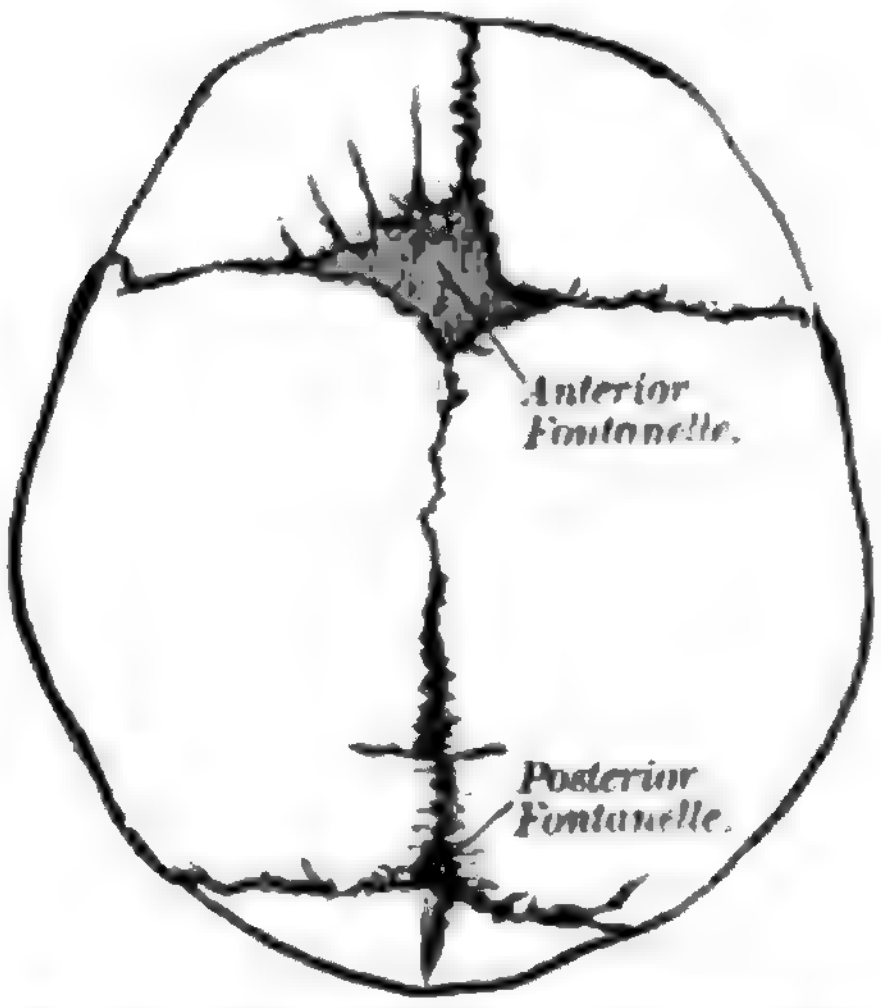

Skull at Birth, showing the anterior and posterior fontanelles.

FIG. 155.

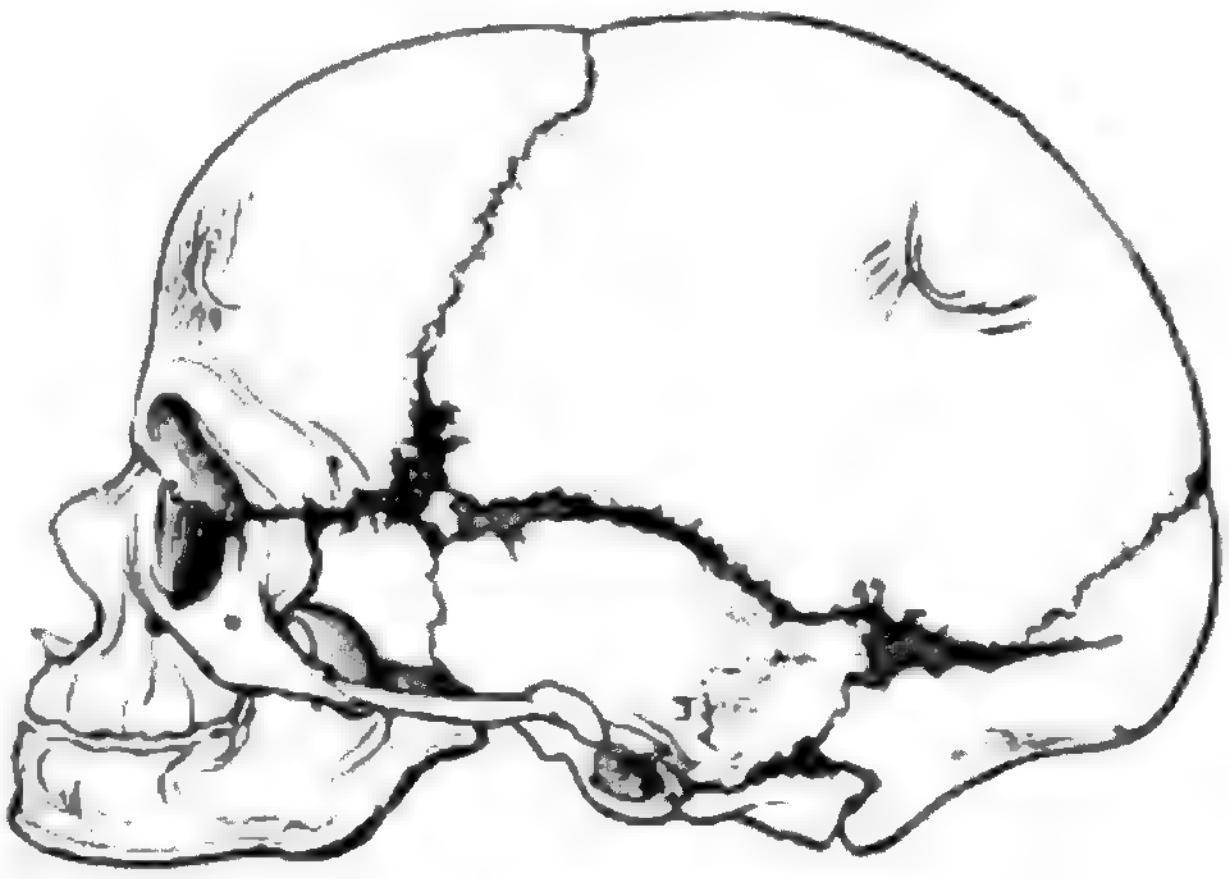

The Lateral Fontanelles.

SUPERNUMERARY OR WORMIAN[1] BONES.

In addition to the constant centres of ossification of the skull, additional ones are occasionally found in the course of the sutures. These form irregular, isolated bones interposed between the cranial bones, and have been termed *Wormian bones* or *ossa triquetra* [*i. e.* triangular]. They are most frequently found in the course of the lambdoid suture, but occasionally also occupy the situation of the fontanelles, especially the posterior, and, more rarely, the anterior. Frequently one is found between the anterior inferior angle of the parietal bone and the greater wing of the sphenoid (the *epipteric bone*, Fig. 155). They have a great tendency to be symmetrical on the two sides of the skull, and they vary much in size, being in some cases not larger than a pin's head, and confined to the outer table; in other cases so large that one pair of these bones may form the whole of the occipital bone above the superior curved lines, as described by Béclard and Ward. Their number is generally limited to two or three, but more than a hundred have been found in the skull of an adult hydrocephalic skeleton. In their development, structure, and mode of articulation they resemble the other cranial bones.

CONGENITAL FISSURES AND GAPS.

An arrest in the ossifying process may give rise to deficiencies or gaps, or to fissures, which are of importance in a medico-legal point of view, as they are liable to be mistaken for fractures. The fissures generally extend from the margins toward the centre of the bone, but the gaps may be found in the middle as well as at the edges. In course of time they may become covered with a thin lamina of bone.

---

[1] Wormius, a physician in Copenhagen, is said to have given the first detailed description of these bones.

BONES OF THE FACE.

The facial bones are fourteen in number—viz. the

Two Nasal,
Two Superior Maxillary,
Two Lachrymal,
Two Malar,
Two Palate,
Two Inferior Turbinated,
Vomer,
Inferior Maxillary.

[Of these, the upper and lower jaws are the fundamental bones for mastication, and the others are accessories; for the chief function of the facial bones is to provide an apparatus for mastication, while subsidiary functions are to provide for the sense-organs (eye, nose, tongue) and a vestibule to the respiratory and vocal organs. Hence the variations in the shape of the face in man and the lower animals depend chiefly on the question of the character of their food and their mode of obtaining it.]

NASAL BONE.

The **Nasal** (*nasus*, the nose) are two small oblong bones, varying in size and form in different individuals; they are placed side by side at the middle and upper part of the face, forming, by their junction, "the bridge" of the nose. Each bone presents for examination two surfaces and four borders. The *outer* surface is concave from above downward, convex from side to side; it is covered by the Pyramidalis and Compressor nasi muscles, marked by numerous small arterial furrows, and perforated about its centre by a foramen, sometimes double, for the transmission of a small vein. Sometimes this foramen is absent on one or both sides, and occasionally the foramen cæcum opens on its surface. The *inner* surface is concave from side to side, convex from above downward, in which direction it is traversed by a longitudinal groove (sometimes a canal) for the passage of a branch of the nasal nerve. The *superior* border is narrow, thick, and serrated for articulation with the nasal notch of the frontal bone. The *inferior* border is broad, thin, sharp, directed obliquely downward, outward, and backward, and serves for the attachment of the lateral cartilage of the nose. This border presents, about its middle, a notch through which passes the branch of the nasal nerve above referred to, and is prolonged at its inner extremity into a sharp spine, which, when articulated with the opposite bone, forms the *nasal angle*. The *external* border is serrated, bevelled, at the expense of the internal surface above and of the external below, to articulate with the nasal process of the superior maxillary. The *internal* border, thicker above than below, articulates with its fellow of the opposite side, and is prolonged behind into a vertical crest, which forms part of the septum of the nose: this crest articulates with the nasal spine of the frontal above and the perpendicular plate of the ethmoid below.

FIG. 156.

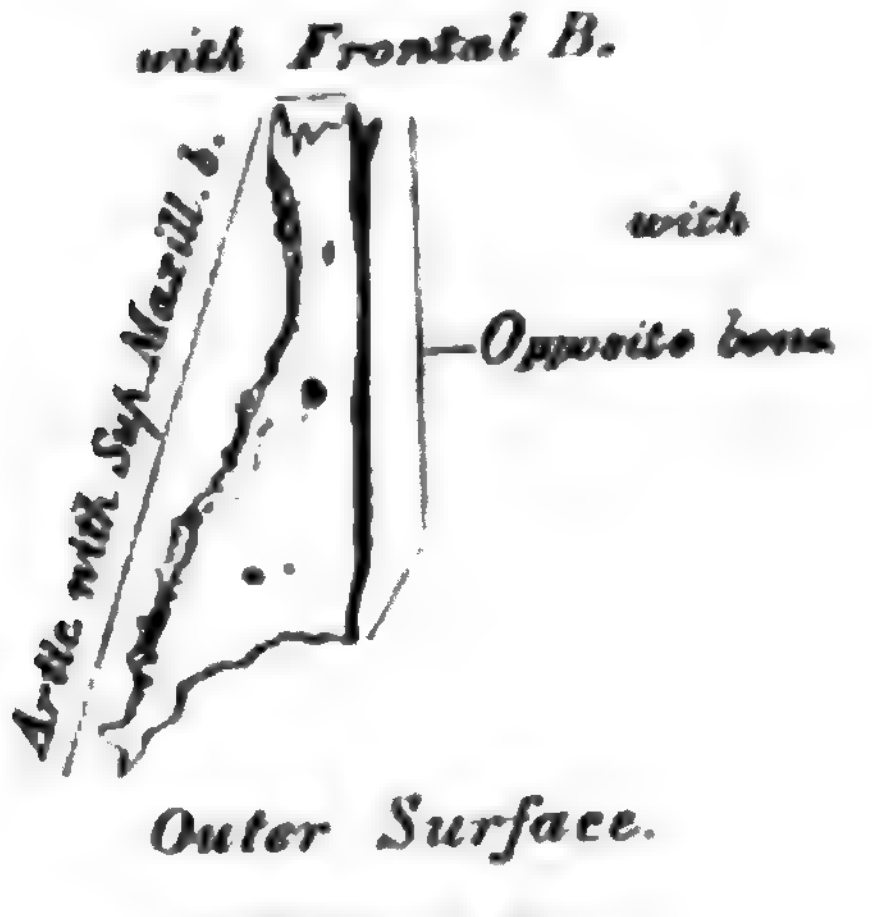

Right Nasal Bone.

FIG. 157.

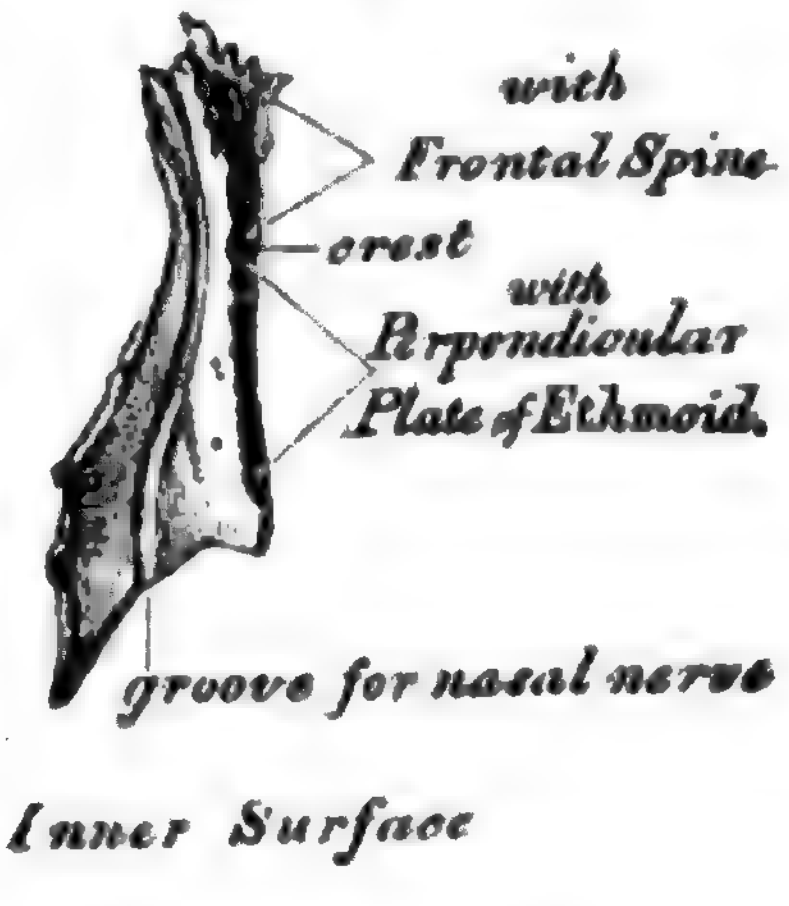

Left Nasal Bone.

Development.—By *one* centre for each bone, which appears about the same period as in the vertebræ.

Articulations.—With four bones: two of the cranium, the frontal and ethmoid, and two of the face, the opposite nasal and the superior maxillary.

No muscles are directly attached to this bone.

SUPERIOR MAXILLARY BONE.

The **Superior Maxillary** (*maxilla*, the jaw-bone) is one of the most important bones of the face in a surgical point of view, on account of the number of diseases to which some of its parts are liable. Its minute examination becomes, therefore, a matter of considerable interest. It is the largest bone of the face, excepting the lower jaw, and forms, by its union with its fellow of the opposite side, the whole of the upper jaw. Each bone assists in the formation of three cavities—the roof of the mouth, the floor and outer wall of the nasal fossæ, and the floor of the orbit—and also enters into the formation of two fossæ, the zygomatic and spheno-maxillary, and two fissures, the spheno-maxillary and pterygo-maxillary.

The bone presents for examination a body and four processes—malar, nasal, alveolar, and palatine.

The **body** is somewhat cuboid, and is hollowed out in its interior to form a large cavity, the *antrum of Highmore*. Its surfaces are four—an external or facial, a posterior or zygomatic, a superior or orbital, and an internal.

The **external** or **facial surface** (Fig. 158) is directed forward and outward. Just above the incisor teeth is a depression, the *incisive* or *myrtiform fossa*, which gives origin to the Depressor alæ nasi, and below it, to the alveolar border, is attached a slip of the Orbicularis oris. Above and a little external to it the Compressor nasi arises. More external is another depression, the *canine fossa*, larger and deeper than the incisive fossa, from which it is separated by a vertical ridge, the *canine eminence*, corresponding to the socket of the canine tooth. The canine fossa gives origin to the Levator anguli oris. Above the canine fossa is the *infraorbital fora-*

FIG. 158.

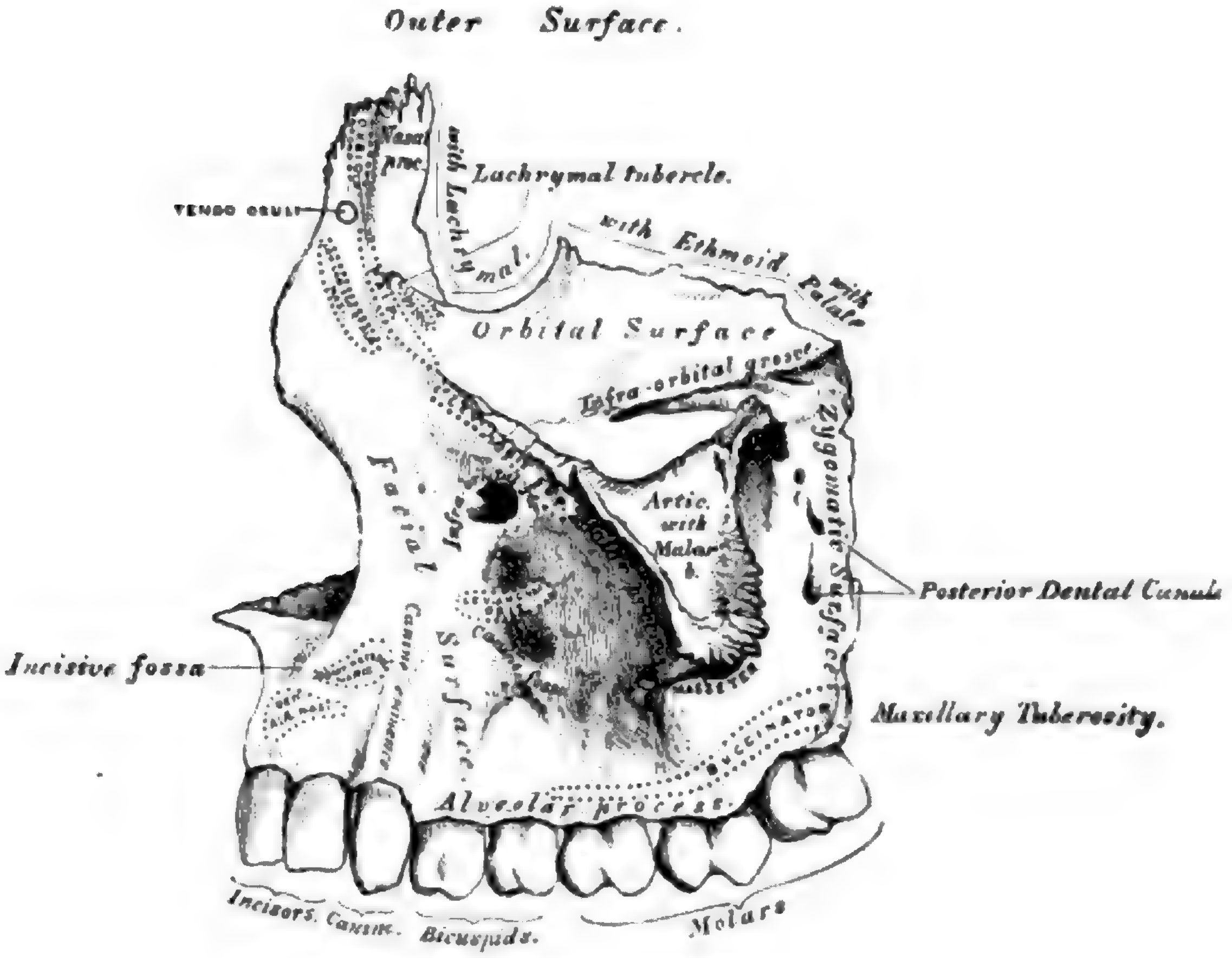
Outer Surface.
Nasal proc.
with Lachrymal
Lachrymal tubercle.
TENDO OCULI
with Ethmoid
with Palate
Orbital Surface
Infra-orbital groove
Zygomatic Surface
Facial Surface
Artic. with Malar b.
Posterior Dental Canals
Incisive fossa
Canine eminence
Maxillary Tuberosity.
BUCCINATOR
Alveolar process
Incisors. Canine. Bicuspids. Molars

Left Superior Maxillary Bone, outer surface.

men, the termination of the infraorbital canal; it transmits the infraorbital nerve and artery. Above the infraorbital foramen is the margin of the orbit, which affords partial attachment to the Levator labii superioris proprius. To the sharp margin of bone which bounds this surface in front and separates it from the internal surface is attached the Dilator naris posterior.

The **posterior** or **zygomatic surface** is convex, directed backward and outward, and forms part of the zygomatic fossa. It presents about its centre several apertures leading to canals in the substance of the bone; they are termed the *posterior dental canals*, and transmit the posterior dental vessels and nerves. At the lower part of this surface is a rounded eminence, the *maxillary tuberosity*, especially prominent after the growth of the wisdom tooth, rough on its inner side for articulation with the tuberosity of the palate bone, and sometimes with the external pterygoid plate. It gives attachment to a few fibres of origin of the internal pterygoid muscle. Immediately above the rough surface is a groove, which, running obliquely down on the inner surface of the bone, is converted into a canal by articulation with the palate bone, forming the *posterior palatine* canal.

The **superior** or **orbital surface** is thin, smooth, triangular, and forms part of the floor of the orbit. It is bounded internally by an irregular margin which articulates, in front, with the lachrymal; in the middle, with the os planum of the ethmoid; behind, with the orbital process of the palate bone; bounded externally by a smooth rounded edge which enters into the formation of the spheno-maxillary fissure, and which sometimes articulates at its anterior extremity with the orbital plate of the sphenoid; bounded in front by part of the circumference of the orbit, which is continuous on the inner side with the nasal, on the outer side with the malar, process. Along the middle line of the orbital surface is a deep groove, the *infraorbital*, for the passage of the infraorbital nerve and artery. This groove commences at the middle of the outer border of the surface, and, passing forward, terminates in a canal which subdivides into two branches; one of the canals, the infraorbital, opens just below the margin of the orbit; the other, which is smaller, runs into the substance of the anterior wall of the antrum; it is called the *anterior dental* canal, transmitting the anterior dental vessels and nerve to the front teeth of the upper jaw. At the inner and fore part of the orbital surface, just external to the lachrymal canal, is a minute depression which gives origin to the Inferior oblique muscle of the eye.

The **internal surface** (Fig. 159) is unequally divided into two parts by a horizontal projection of bone, the *palate process;* the portion above the palate process forms part of the outer wall of the nasal fossæ; that below it forms part of the cavity of the mouth. The superior division of this surface presents a large irregular opening leading into the *antrum of Highmore*. At the upper border of this aperture are numerous broken cellular cavities which, in the articulated skull, are closed in by the ethmoid and lachrymal bones. Below the aperture is a smooth concavity which forms part of the inferior meatus of the nasal fossæ, and behind it is a rough surface which articulates with the perpendicular plate of the palate bone, traversed by a groove which, commencing near the middle of the posterior border, runs obliquely downward and forward, and forms, when completed by its articulation with the palate bone, the *posterior palatine canal*. In front of the opening of the antrum is a deep groove, converted into a canal by the lachrymal and inferior turbinated bones, which is coated with mucous membrane and called the *lachrymal* or *nasal duct*. More anteriorly is a well-marked rough ridge, the *inferior turbinated crest*, for articulation with the inferior turbinated bone. The concavity above this ridge forms part of the middle meatus of the nose, whilst that below it forms part of the inferior meatus. The portion of this surface below the palate process is concave, rough, and uneven, and perforated by numerous small foramina for the passage of nutrient vessels. It enters into the formation of the roof of the mouth.

The **Antrum of Highmore**, or Maxillary Sinus, is a large triangular-shaped cavity hollowed out of the body of the maxillary bone; its apex, directed outward, is formed by the malar process; its base, by the outer wall of the nose. Its walls are everywhere exceedingly thin, its roof being formed by the orbital plate, its floor by the alveolar process, its anterior wall by the facial, and its posterior by the zygomatic surface. Its inner wall, or base, presents, in the disarticulated bone, a large irregular aperture which communicates with the nasal fossa. The margins of this aperture are thin and ragged, and the aperture itself is much contracted by its articulation with the ethmoid above, the inferior turbinated below, and the palate bone behind.[1] In the articulated skull this cavity communicates with the middle meatus of the nasal fossæ, generally by two small apertures left between the above-mentioned bones. In the recent state usually only one small opening exists, near the upper part of the cavity, sufficiently large to admit the end of a probe, the other being closed by the lining membrane of the sinus.

Fig. 159.

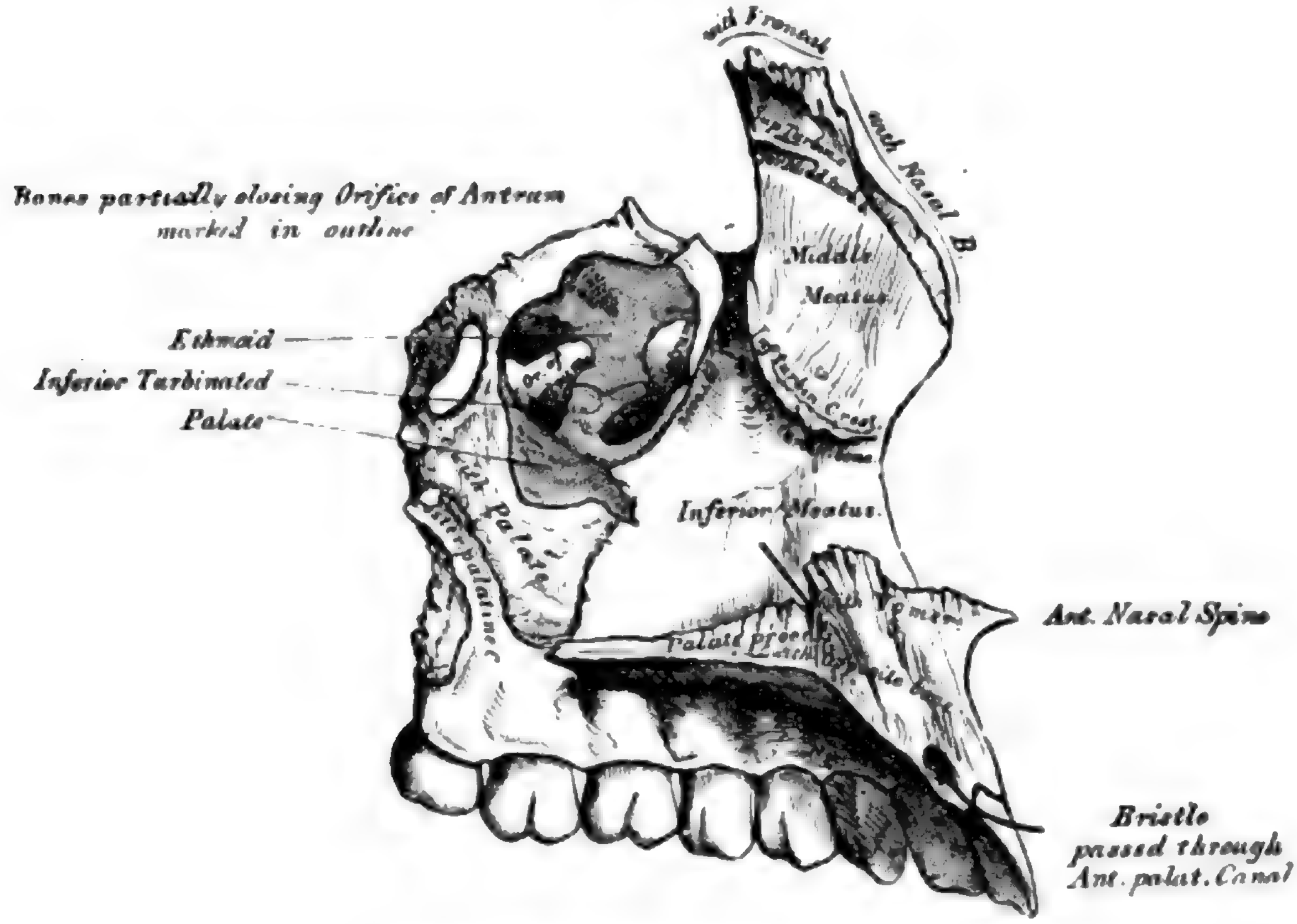
with Frontal
Sup. Turbinated
Middle Turbinated
with Nasal B.
Bones partially closing Orifice of Antrum marked in outline
Middle Meatus
Ethmoid
Inferior Turbinated
Palate
Inferior Turb. Crest
with Palate
Inferior Meatus
Posterior palatine C.
Ant. Nasal Spine
with Vomer
Palate process
Bristle passed through Ant. palat. Canal

Left Superior Maxillary Bone, inner surface.

Crossing the cavity of the antrum are often seen several projecting laminæ of bone similar to those seen in the sinuses of the cranium; and on its posterior wall are the *posterior dental canals*, transmitting the posterior dental vessels and nerves to the teeth. Projecting into the floor are several conical processes, corresponding to the roots of the first and second molar teeth;[2] in some cases the floor is perforated by the teeth in this situation. It is from the extreme thinness of the walls of this cavity that we are enabled to explain how a tumor growing from the antrum encroaches upon the adjacent parts, pushing up the floor of the orbit and displacing the eyeball, projecting inward into the nose, protruding forward on to the cheek, and making its way backward into the zygomatic fossa and downward into the mouth. [The cavity of the antrum is so large that percussion will often give important information as to whether the antrum be empty or full. It can be perforated either through the anterior wall on either side of the first or second molar, or, if a suitable tooth be carious, through its socket after its removal.[1]]

---

[1] In some cases, at any rate, the lachrymal bone encroaches slightly on the anterior superior portion of the opening, and assists in forming the inner wall of the antrum.

[2] The number of teeth whose fangs are in relation with the floor of the antrum is variable. The antrum "may extend so as to be in relation to all the teeth of the true maxilla, from the canine to the *dens sapientiæ*." (See Mr. Salter on "Abscess of the Antrum," in a *System of Surgery*, edited by T. Holmes, 2d ed., vol. iv. p. 356.)

The **Malar Process** is a rough triangular eminence situated at the angle of separation of the facial from the zygomatic surface. In front it is concave, forming part of the facial surface; behind, it is also concave, and forms part of the zygomatic fossa; above, it is rough and serrated for articulation with the malar bone, whilst below a prominent ridge marks the division between the facial and zygomatic surfaces. A small part of the Masseter muscle arises from this process.

The **Nasal Process** is a thick triangular plate of bone which projects upward, inward, and backward by the side of the nose, forming part of its lateral boundary. Its *external* surface is concave, smooth, perforated by numerous foramina, and gives attachment to the Levator labii superioris alæque nasi, the Orbicularis palpebrarum, and the Tendo oculi. Its *internal* surface forms part of the outer wall of the nose; it articulates above with the frontal, and presents a rough, uneven surface which articulates with the ethmoid bone, closing in the anterior ethmoidal cells; below this is a transverse ridge, the *superior turbinated crest*, for articulation with the middle turbinated bone of the ethmoid, bounded below by a smooth concavity which forms part of the middle meatus; below this, again, is the inferior turbinated crest (already described), for articulation with the inferior turbinated bone; and, still more inferiorly, the concavity which forms part of the inferior meatus. The *anterior* border of the nasal process is thin, directed obliquely downward and forward, and presents a serrated edge, for articulation with the nasal bone; its *posterior* border is thick, and hollowed into a groove for the lachrymal duct: of the two margins of this groove, the inner one articulates with the lachrymal bone, the outer one forms part of the circumference of the orbit. Just where the latter joins the orbital surface is a small tubercle, the *lachrymal tubercle;* this used to be taken as a guide in the performance of the operation for fistula lachrymalis. The lachrymal groove in the articulated skull is converted into a canal by the lachrymal bone and lachrymal process of the inferior turbinated; it is directed downward and a little backward and outward, is about the diameter of a goose-quill, slightly narrower in the middle than at either extremity, and terminates below in the inferior meatus. It lodges the lachrymal duct.

The **Alveolar Process** is the thickest and most spongy part of the bone, broader behind than in front, and excavated into deep cavities for the reception of the teeth. These cavities are eight in number, and vary in size and depth according to the teeth they contain. That for the canine tooth is the deepest; those for the molars are the widest, and subdivided into minor cavities; those for the incisors are single, but deep and narrow. The Buccinator muscle arises from the outer surface of this process as far forward as the first molar tooth. [After the loss of the permanent teeth at any time, but especially in old age, the alveolar process of the upper jaw (Fig. 176, p. 202), like that of the lower, is absorbed. In old age also the entire bone thins greatly, and often the palate process and other parts become a mere shell—a point to be remembered in operations on old people.]

The **Palate Process**, thick and strong, projects horizontally inward from the inner surface of the bone. It is much thicker in front than behind, and forms a considerable part of the floor of the nostril and the roof of the mouth.

Its *inferior* surface (Fig. 160) is concave, rough, and uneven, and forms part of the roof of the mouth. This surface is perforated by numerous foramina for the passage of the nutrient vessels, channelled at the back part of its alveolar border by a longitudinal groove, sometimes a canal, for the transmission of the posterior palatine vessels and the anterior and external palatine nerves from Meckel's ganglion, and presents little depressions for the lodgment of the palatine glands. When the two superior maxillary bones are articulated together, a large orifice may be seen in the middle line immediately behind the incisor teeth. This is the *anterior palatine canal* or *fossa*. This canal, as it passes through the thickness of the palate process, is divided into four compartments; that is to say, two canals branch off laterally to the right and left nasal fossæ, and two canals, one in front and one behind, lie in the middle line. The former pair of these canals are named the *foramina of Stenson*, and through them pass the anterior or terminal branch of the descending or posterior palatine arteries which ascends from the mouth to the nasal fossæ. The remaining pair of canals are termed the *foramina of Scarpa*, and transmit the naso-palatine nerves, the left passing through the anterior and the right through the posterior canal. On the palatal surface of the process a delicate linear suture may sometimes be seen extending from the anterior palatine fossa to the interval between the lateral incisor and the canine tooth. This marks out the *intermaxillary* or *incisive bone*, which in some animals exists permanently as a separate piece. It includes the whole thickness of the alveolus, the corresponding part of the floor of the nose, and the anterior nasal spine, and contains the sockets of the incisor teeth. The *upper* surface is concave from side to side, smooth, and forms part of the floor of the nose. It presents the upper orifices of the foramina of Stenson and Scarpa, the former being on each side of the middle line, the latter being situated in the intermaxillary suture, and therefore not visible unless the two bones are placed in apposition. The *outer* border of the palate process is incorporated with the rest of the bone. The *inner* border is thicker in front than behind, and is raised above into a ridge, which, with the corresponding ridge in the opposite bone, forms a groove for the reception of the vomer. The *anterior* margin is bounded by the thin concave border of the opening of the nose, prolonged forward internally into a sharp process, forming, with a similar process of the opposite bone, the *anterior nasal spine*. The *posterior* border is serrated for articulation with the horizontal plate of the palate-bone.

---

[1] See a paper by the American Editor on "Percussion of the Frontal and Maxillary Sinuses," in the *Medical News* for Aug. 16, 1884.

Fig. 160.

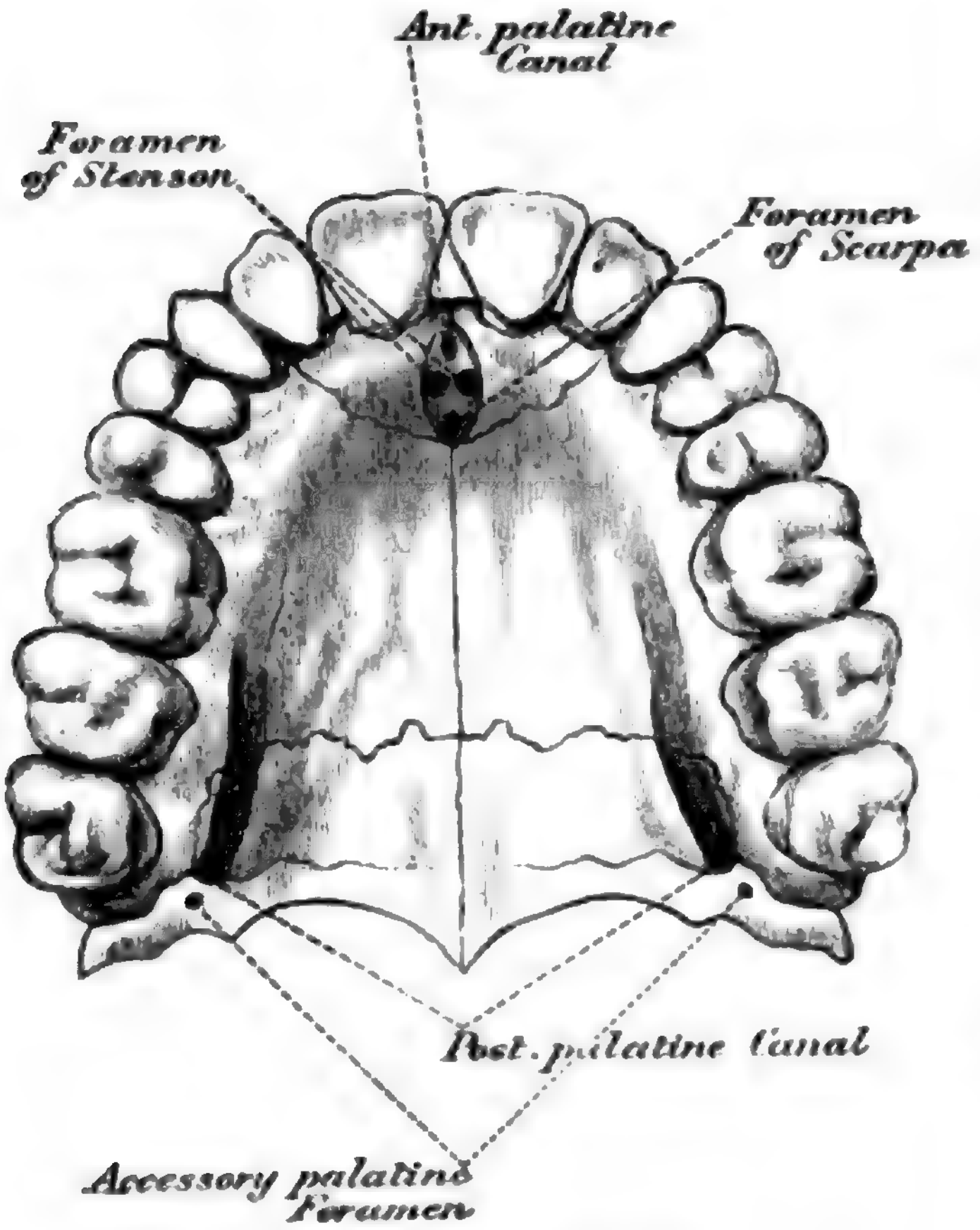

The Palate and Alveolar Arch.

Fig. 161.

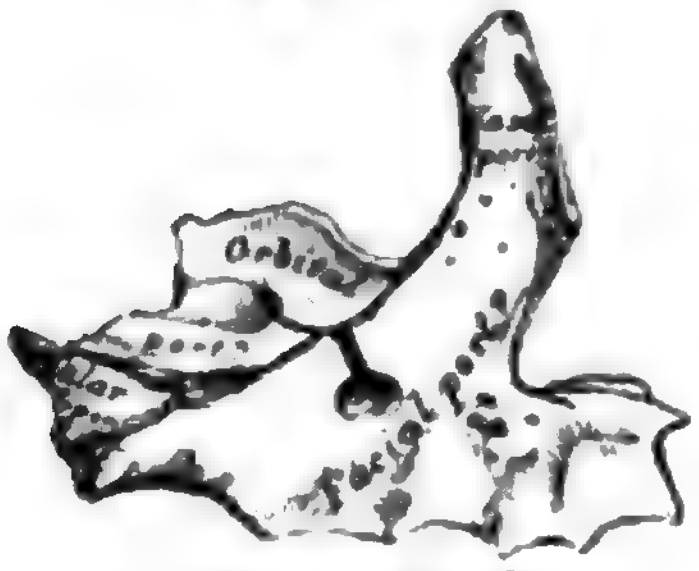

Anterior Surface.

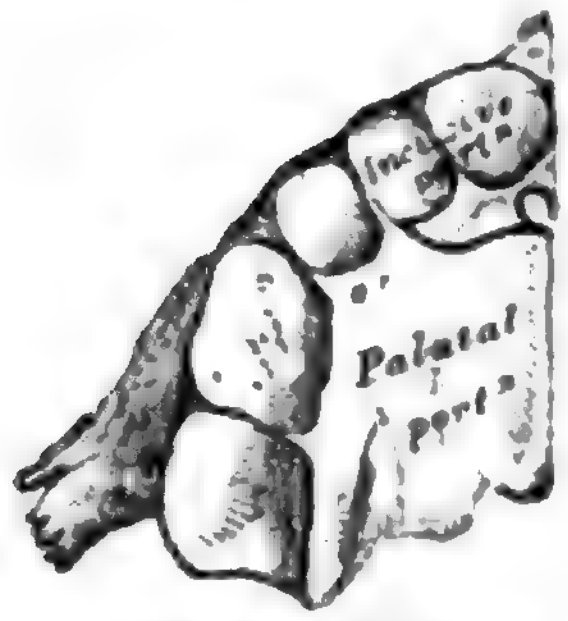

Inferior Surface.

Development of Superior Maxillary Bone at Birth.

Development.—This bone is formed at such an early period, and ossification proceeds in it with such rapidity, that it has been found impracticable hitherto to determine with accuracy its number of centres. It appears, however, probable that it has four centres of development—viz. (1) the *premaxilla*, in which the incisive portion of the alveolar arch is formed: this part is of cartilaginous origin, and is developed in the anterior extremity of the ethmo-vomerine plate; (2) the *prepalatine* portion, comprising the palate plate and a considerable portion of the inner wall of the antrum; (3) the *maxillary* portion, including all the facial and orbital parts of the bone internal to the infraorbital canal; (4) the *malar* portion, which comprises that portion of the bone external to the infraorbital canal. The premaxillary portion is indicated in young bones by a fissure which marks off a small segment of the palate, including the two incisor teeth. In some animals this remains permanently as a separate piece, constituting the premaxillary bone; and in the human subject where the jaw is malformed, as in cleft palate, this segment may be separated from the maxillary bone by a deep fissure extending backward between the two into the palate. If the fissure be on both sides, both segments are quite isolated from the maxillary bones, and hang from the end of the vomer; they are not unfrequently much displaced, and the deformity is often accompanied by congenital fissure of the upper lip either on one or both sides of the median line. The maxillary sinus [antrum] appears at an earlier period than any of the other nasal sinuses, its development commencing about the fourth month of fœtal life. The sockets for the teeth are formed by the growing downward of two plates from the dental groove, which subsequently becomes divided by partitions jutting across from the one to the other.

Articulations.—With *nine* bones: two of the cranium—the frontal and ethmoid; and seven of the face—viz. the nasal, malar, lachrymal, inferior turbinated, palate, vomer, and its fellow of the opposite side. Sometimes it articulates with the orbital plate of the sphenoid.

Attachment of Muscles.—To twelve: the Orbicularis palpebrarum, Obliquus inferior oculi, Levator labii superioris alæque nasi, Levator labii superioris proprius, Levator anguli oris, Compressor nasi, Depressor alæ nasi, Dilatator naris posterior, Masseter, Buccinator, Internal pterygoid, and Orbicularis oris.

THE LACHRYMAL BONE.

Fig. 162.

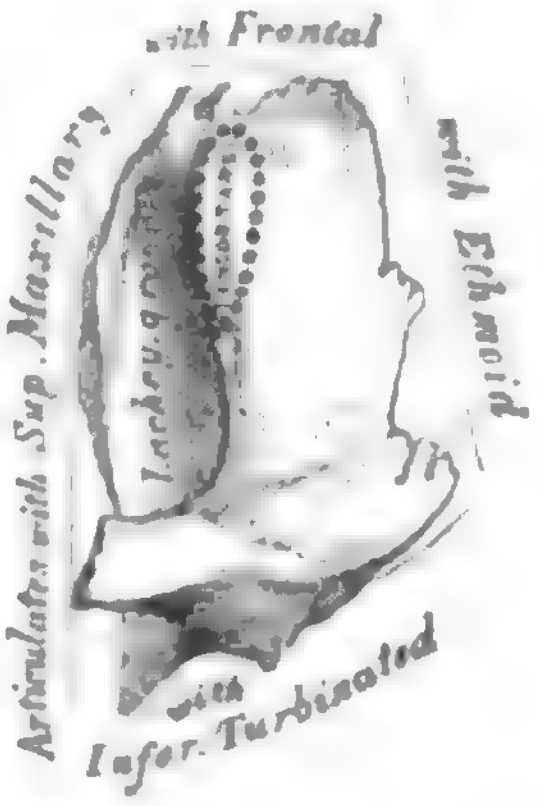

Left Lachrymal Bone, external surface (slightly enlarged).

The **Lachrymal** (*lachryma*, a tear) are the smallest and most fragile bones of the face. They are situated at the front part of the inner wall of the orbit, and resemble somewhat in form, thinness, and size a finger-nail; hence they are termed the *ossa unguis*. Each bone presents for examination two surfaces and four borders. The *external* or *orbital* surface (Fig. 162) is divided by a vertical ridge, the *lachrymal crest*, into two parts. The portion of bone in front of this ridge presents a smooth, concave, longitudinal groove, the free margin of which unites with the nasal process of the superior maxillary bone, completing the lachrymal groove. The upper part of this groove lodges the lachrymal sac; the lower part assists in the formation of the lachrymal canal and lodges the nasal duct. The portion of bone behind the ridge is smooth, slightly concave, and forms part of the inner wall of the orbit. The ridge, with a part of the orbital surface immediately behind it, affords attachment to the Tensor tarsi: the ridge terminates below in a small hook-like process, which articulates with the lachrymal tubercle of the superior maxillary bone and completes the upper orifice of the lachrymal canal. It sometimes exists as a separate piece, which is then called the *lesser lachrymal bone*. The *internal* or *nasal* surface presents a depressed furrow, corresponding to the ridge on its outer surface. The surface of bone in front of this forms part of the middle meatus, and that behind it articulates with the ethmoid bone, filling in the anterior ethmoidal cells. Of the *four borders*, the *anterior* is the longest and articulates with the nasal process of the superior maxillary bone. The *posterior*, thin and uneven, articulates with the os planum of the ethmoid. The *superior*, the shortest and thickest, articulates with the internal angular process of the frontal bone. The *inferior* is divided by the lower edge of the vertical crest into two parts; the posterior part articulates with the orbital plate of the superior maxillary bone; the anterior portion is prolonged downward into a pointed process which articulates with the lachrymal process of the inferior turbinated bone and assists in the formation of the lachrymal canal.

Development.—By a single centre, which makes its appearance soon after ossification of the vertebræ has commenced.

Articulations.—With four bones: two of the cranium, the frontal and ethmoid, and two of the face, the superior maxillary and the inferior turbinated.

Attachment of Muscles.—To one muscle, the Tensor tarsi.

THE MALAR BONE.

The **Malar** (*mala*, the cheek) are two small quadrangular bones situated at the upper and outer part of the face: they form the prominence of the cheek, part of the outer wall and floor of the orbit, and part of the temporal and zygomatic fossæ. Each bone presents for examination an external and an internal surface; four processes, the frontal, orbital, maxillary, and zygomatic; and four borders.

The **external surface** (Fig. 163) is smooth, convex, perforated near its centre by one or two small apertures, the *malar foramina*, for the passage of nerves and vessels, covered by the Orbicularis palpebrarum muscle, and affords attachment to the Zygomaticus major and minor muscles.

FIG. 163.

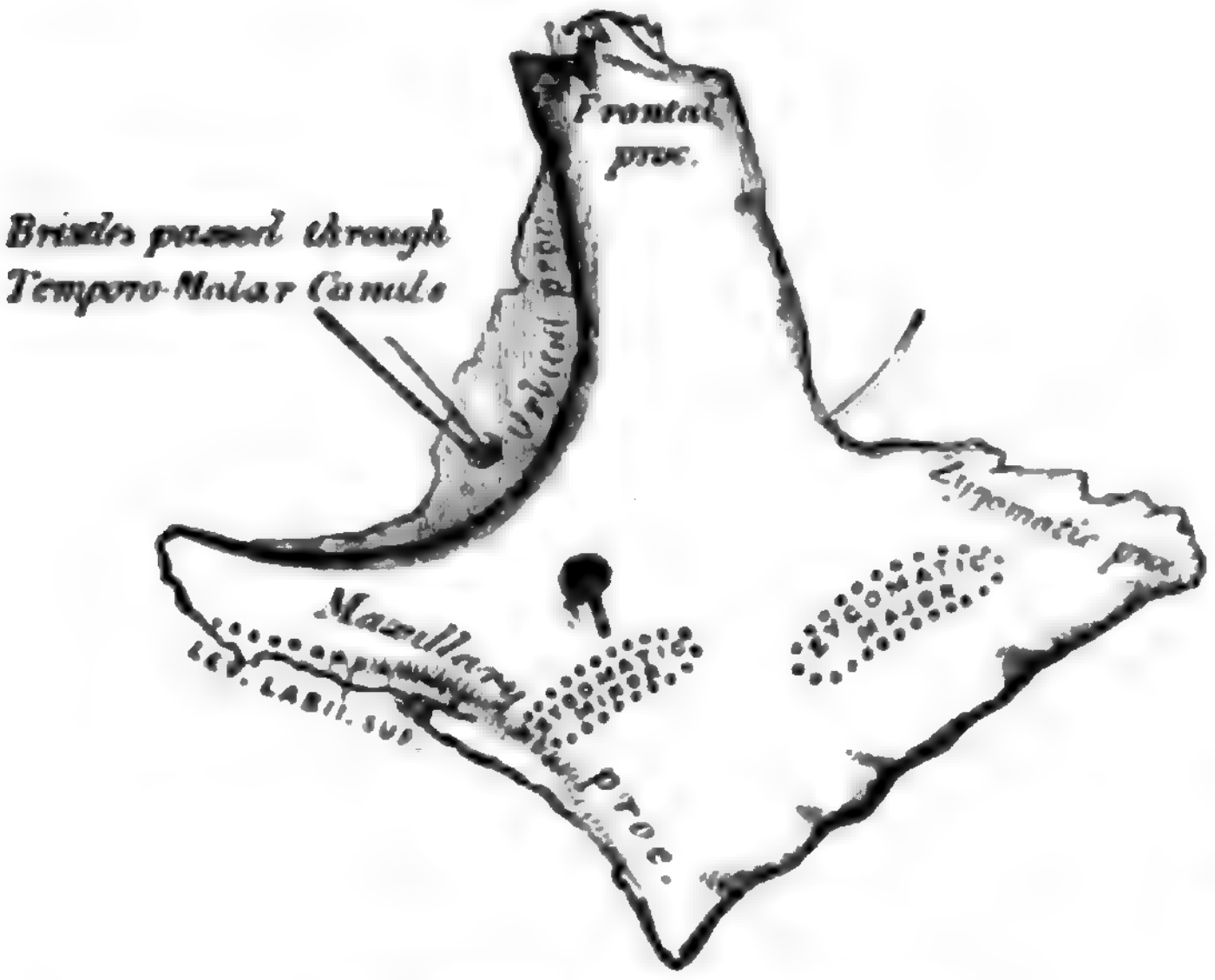

Left Malar Bone, outer surface.

FIG. 164.

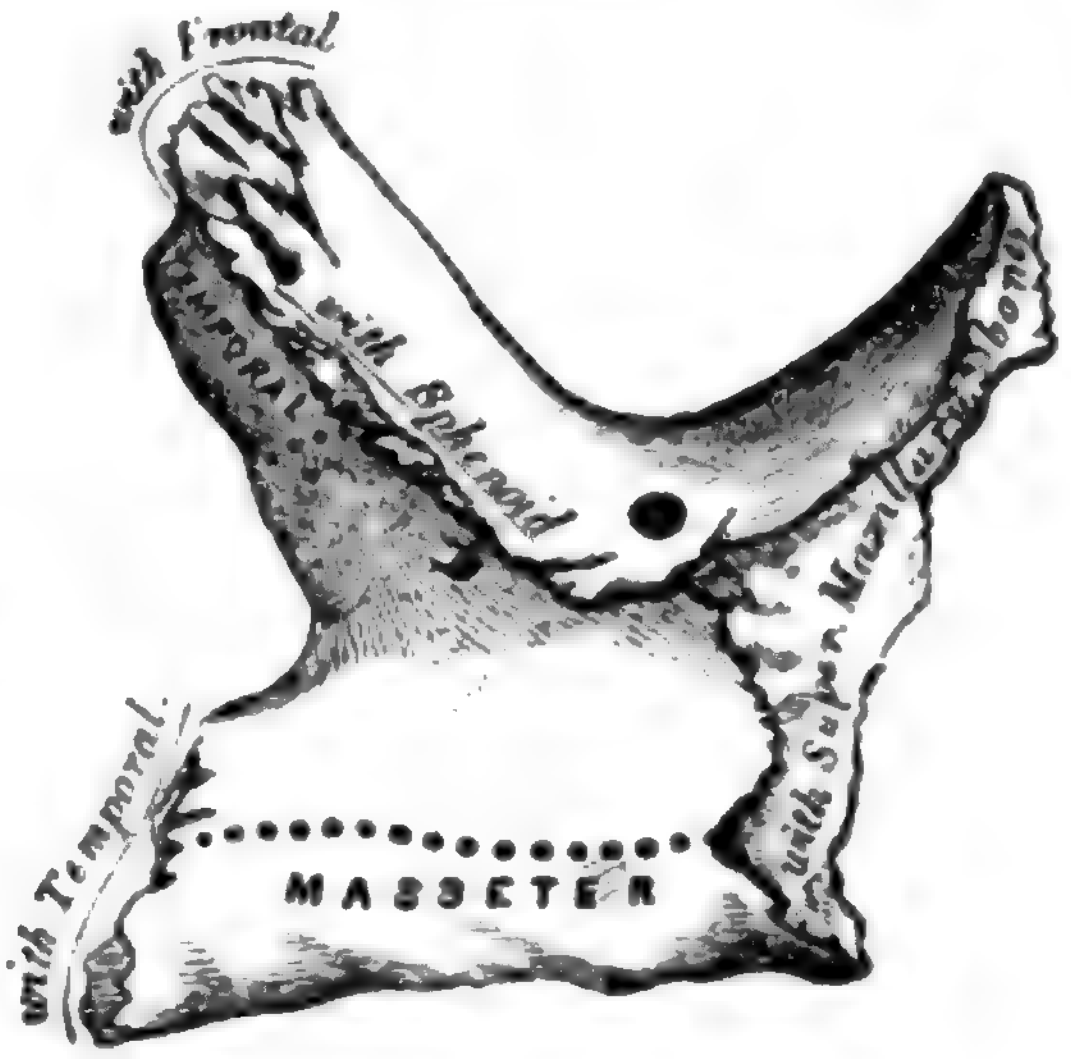

Left Malar Bone, inner surface.

The **internal surface** (Fig. 164), directed backward and inward, is concave, presenting internally a rough triangular surface for articulation with the superior maxillary bone; and externally a smooth concave surface which forms the anterior boundary of the temporal fossa above, and below, where it is wider, forms part of the zygomatic fossa. This surface presents, a little above its centre, the aperture of one or two malar canals, and affords attachment to part of two muscles, the Temporal above and the Masseter below. Of the four processes, the **frontal** is thick and serrated, and articulates with the external angular process of the frontal bone. The **orbital** process is a thick and strong plate which projects backward from the orbital margin of the bone. Its *upper* surface, smooth and concave, forms, by its junction with the great ala of the sphenoid, the outer wall of the orbit. Its *under* surface, smooth and convex, forms part of the temporal fossa. Its *anterior* margin is smooth and rounded, forming part of the circumference of the orbit. Its *superior* margin, rough and directed horizontally, articulates with the frontal bone behind the external angular process. Its *posterior* margin is rough and serrated, for articulation with the sphenoid; *internally* it is also serrated, for articulation with the orbital surface of the superior maxillary. At the angle of junction of the sphenoidal and maxillary portions a short rounded non-articular margin is generally seen; this forms the anterior boundary of the spheno-maxillary fissure; occasionally no such non-articular margin exists, the fissure being completed by the direct junction of the maxillary and sphenoid bones or by the interposition of a small Wormian bone in the angular interval between them. On the *upper* surface of the orbital process are seen the orifices of one or two temporo-malar canals; one of these usually opens on the posterior surface, the other (occasionally two) on the facial surface: they transmit filaments (temporo-malar) of the orbital branch of the superior maxillary nerve. The **maxillary** process is a rough triangular surface which articulates with the superior maxillary bone. The **zygomatic** process, long, narrow, and serrated, articulates with the zygomatic process of the temporal bone. Of the **four borders,** the *antero-superior* or *orbital* is smooth, arched, and forms a considerable part of the circumference of the orbit. The *antero-inferior* or *maxillary* border is rough, and bevelled at the expense of its inner table to articulate with the superior maxillary bone, affording attachment by its outer margin to the Levator labii superioris proprius just at its point of junction with the superior maxillary. The *postero-superior* or *temporal* border, curved like an italic letter *f*, is continuous above with the commencement of the temporal ridge; below, with the upper border of the zygomatic arch: it affords attachment to the temporal fascia. The *postero-inferior*, or *zygomatic*, is continuous with the lower border of the zygomatic arch, affording attachment by its rough edge to the Masseter muscle.

Development.—By a single centre of ossification, which appears at about the same period when ossification of the vertebræ commences.[1]

Articulations.—With four bones: three of the cranium, frontal, sphenoid, and temporal; and one of the face, the superior maxillary.

Attachment of Muscles.—To five: the Levator labii superioris proprius, Zygomaticus major and minor, Masseter, and Temporal.

THE PALATE BONE.

The **Palate Bones** (*palatum*, the palate) are situated at the back part of the nasal fossæ: they are wedged in between the superior maxillary and the pterygoid process of the sphenoid. Each bone assists in the formation of three cavities—the floor and outer wall of the nose, the roof of the mouth, and the floor of the orbit—and enters into the formation of two fossæ, the spheno-maxillary and pterygoid; and one fissure, the spheno-maxillary. In form the palate bone somewhat resembles the letter L, and may be divided into an inferior or horizontal plate and a superior or vertical plate.

The **Horizontal Plate** is thick, of a quadrilateral form, and presents two surfaces and four borders. The *superior* surface, concave from side to side, forms the back part of the floor of the nostril. The *inferior* surface, slightly concave and rough, forms the back part of the hard palate. At its posterior part may be seen a transverse ridge, more or less marked, for the attachment of the aponeurosis of the Tensor palati muscle. At the outer extremity of this ridge is a deep groove converted into a canal by its articulation with the tuberosity of the superior maxillary bone, and forming the *posterior palatine canal.* Near this groove the orifices of one or two small canals, *accessory posterior palatine*, may frequently be seen. The *anterior* border is serrated, bevelled at the expense of its inferior surface, and articulates with the palate process of the superior maxillary bone. The *posterior* border is concave, free, and serves for the attachment of the soft palate. Its inner extremity is sharp and pointed, and, when united with the opposite bone, forms a projecting process, the *posterior nasal spine*, for the attachment of the Azygos uvulæ. The *external* border is united with the lower part of the perpendicular plate almost at right angles. The *internal* border, the thickest, is serrated for articulation with its fellow of the opposite side; its superior edge is raised into a ridge which, united with the opposite bone, forms a crest in which the vomer is received.

---

[1] In some Quadrumana the malar bone consists of two parts, an orbital and a malar, and is ossified by two centres. In the embryo these parts have been observed to be separated, and even after birth the malar bone is sometimes divided by a horizontal suture into an upper and larger division and a lower and smaller. It is possible, therefore, that this bone is ossified sometimes by two centres, one for the orbital and the other for the malar portion.

The **Vertical Plate** (Fig. 165) is thin, of an oblong form, and directed upward and a little inward. It presents two surfaces, an external and an internal, and four borders.

The **internal surface** presents at its lower part a broad, shallow depression which forms part of the inferior meatus of the nose. Immediately above this is a well-marked horizontal ridge, the *inferior turbinated crest*, for articulation with the inferior turbinated bone; above this, a second broad shallow depression, which forms part of the middle meatus, surmounted above by a horizonal ridge less prominent than the inferior, the *superior turbinated crest*, for articulation with the middle turbinated bone. Above the superior turbinated crest is a narrow horizontal groove which forms part of the superior meatus.

FIG. 165.

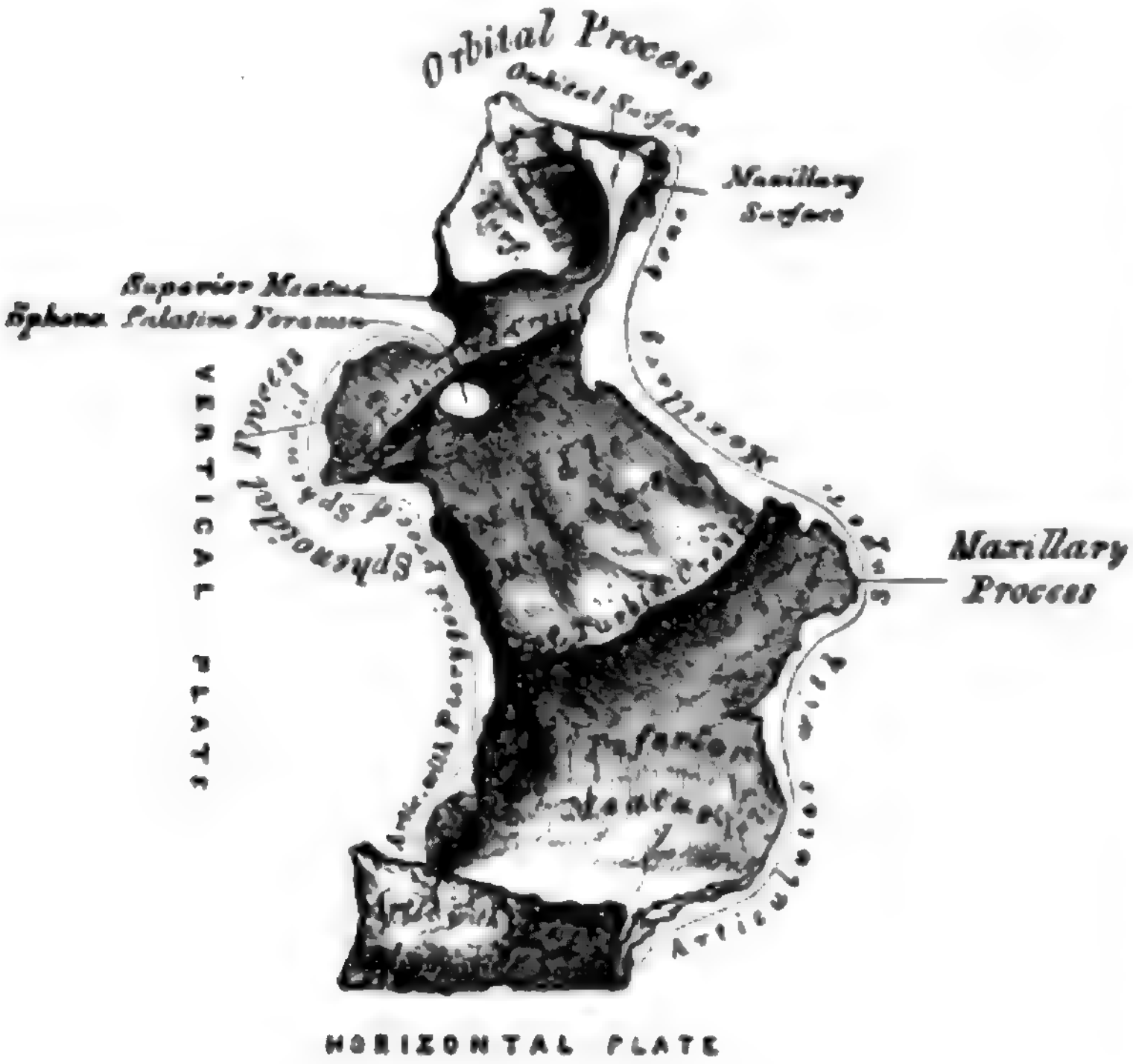
Orbital Process
Orbital Surface
Maxillary Surface
Superior Meatus
Spheno Palatine Foramen
Sphenoidal Process
VERTICAL PLATE
Maxillary Process
Inferior Meatus
HORIZONTAL PLATE

Left Palate Bone, internal view (enlarged).

The **external surface** is rough and irregular throughout the greater part of its extent, for articulation with the inner surface of the superior maxillary bone, its upper and back part being smooth where it enters into the formation of the spheno-maxillary fossa; it is also smooth in front, where it covers the orifice of the antrum. Toward the back part of this surface is a deep groove, converted into a canal, the *posterior palatine*, by its articulation with the superior maxillary bone. It transmits the posterior or descending palatine vessels, and two of the descending palatine branches from Meckel's ganglion.

FIG. 166.

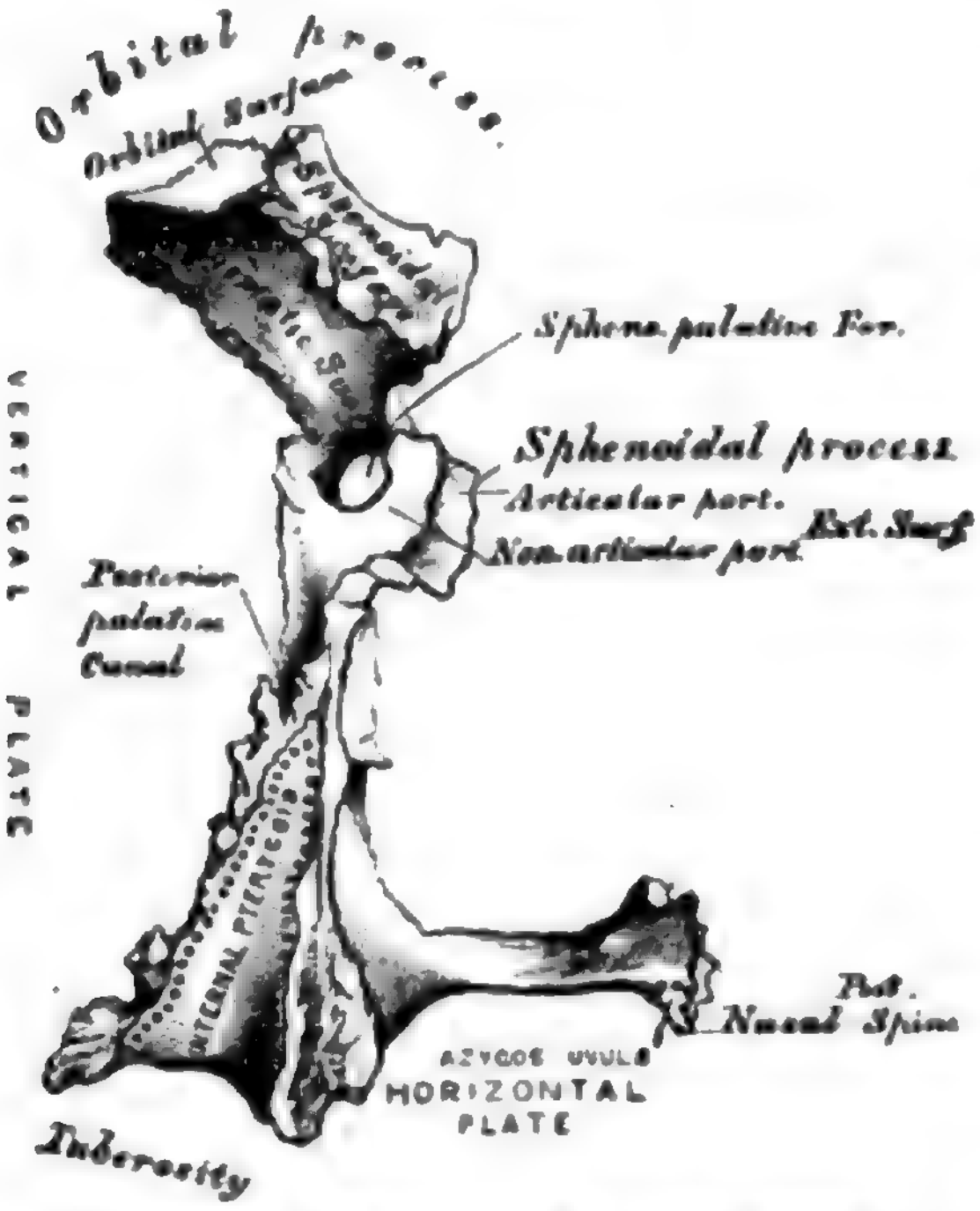
Orbital process
Orbital Surface
Spheno-palatine For.
Sphenoidal process
Articular port.
Non-articular port.
Ext. Surf.
Posterior palatine Canal
VERTICAL PLATE
INTERNAL PTERYGOID
AZYGOS UVULÆ
HORIZONTAL PLATE
Post. Nasal Spine
Tuberosity

Left Palate Bone, posterior view (enlarged).

The *anterior* border is thin, irregular, and presents opposite the inferior turbinated crest a pointed projecting lamina, the *maxillary process*, which is directed forward and closes in the lower and back part of the opening of the antrum. The *posterior* border (Fig. 166) presents a deep groove, the edges of which are serrated for articulation with the pterygoid process of the sphenoid. At the lower part of this border is seen a pyramidal process of bone, the *pterygoid process*, or tuberosity of the palate, which is received into the angular interval between the two pterygoid plates of the sphenoid at their inferior extremity. This process presents at its back part three grooves, a median and two lateral ones. The former is smooth, and forms part of the pterygoid fossa, affording attachment to the Internal pterygoid muscle; whilst the lateral grooves are rough and uneven, for articulation with the anterior border of each pterygoid plate. A few fibres of the

Superior constrictor also arise from the tuberosity of the palate bone. The base of this process, continuous with the horizontal portion of the bone, presents the apertures of the *accessory descending palatine canals*, through which passes the posterior of the three descending branches of Meckel's ganglion, whilst its outer surface is rough, for articulation with the inner surface of the body of the superior maxillary bone.

The *superior* border of the vertical plate presents two well-marked processes separated by an intervening notch or foramen. The anterior, or larger, is called the *orbital process;* the posterior, the *sphenoidal.*

The **Orbital Process**, directed upward and outward, is placed on a higher level than the sphenoidal. It presents five surfaces, which enclose a hollow cellular cavity, and is connected to the perpendicular plate by a narrow constricted neck. Of these five surfaces, three are articular, two non-articular or free surfaces. The three articular are as follows: The *anterior* or *maxillary* surface, which is directed forward, outward, and downward, is of an oblong form, and rough for articulation with the superior maxillary bone. The *posterior* or *sphenoidal* surface is directed backward, upward, and inward. It ordinarily presents a small open cell, which communicates with the sphenoidal sinus, and the margins of which are serrated for articulation with the vertical part of the sphenoidal turbinated bone. The *internal* or *ethmoidal* surface is directed inward, upward, and forward, and articulates with the lateral mass of the ethmoid bone. In some cases the cellular cavity above mentioned opens on this surface of the bone; it then communicates with the posterior ethmoidal cells. More rarely it opens on both surfaces, and then communicates both with the posterior ethmoidal cells and the sphenoidal sinus. The non-articular or free surfaces are the *superior* or *orbital*, directed upward and outward, of triangular form, concave, smooth, and forming the back part of the floor of the orbit; and the *external* or *zygomatic* surface, directed outward, backward, and downward, of an oblong form, smooth, lying in the spheno-maxillary fossa, and looking into the zygomatic fossa. The latter surface is separated from the orbital by a smooth rounded border which enters into the formation of the spheno-maxillary fissure.

The **Sphenoidal Process** of the palate bone is a thin compressed plate, much smaller than the orbital, and directed upward and inward. It presents three surfaces and two borders. The *superior* surface, the smallest of the three, articulates with the horizontal part of the sphenoidal turbinated bone; it presents a groove which contributes to the formation of the pterygo-palatine canal. The *internal* surface is concave, and forms part of the outer wall of the nasal fossa. The *external* surface is divided into an articular and a non-articular portion; the former is rough, for articulation with the inner surface of the pterygoid process of the sphenoid; the latter is smooth, and forms part of the spheno-maxillary fossa. The *anterior* border forms the posterior boundary of the spheno-palatine foramen. The *posterior* border, serrated at the expense of the outer table, articulates with the inner surface of the pterygoid process.

The orbital and sphenoidal processes are separated from each other by a deep notch, which is converted into a foramen, the *spheno-palatine*, by articulation with the sphenoidal turbinated bone. Sometimes the two processes are united above, and form between them a complete foramina, or the notch is crossed by one or more spiculæ of bone, so as to form two or more foramina. In the articulated skull this foramen opens into the back part of the outer wall of the superior meatus, and transmits the spheno-palatine vessels and the superior nasal and naso-palatine nerves.

Development.—From a single centre, which makes its appearance about the second month at the angle of junction of the two plates of the bone. From this point ossification spreads inward to the horizontal plate, downward into the tuberosity, and upward into the vertical plate. In the fœtus the horizontal plate is much longer than the vertical, and even after it is fully ossified the whole bone is at first remarkable for its shortness.

Articulations.—With six bones: the sphenoid, ethmoid, superior maxillary, inferior turbinated, vomer, and opposite palate.

Attachment of Muscles.—To five: the Tensor palati, Azygos uvulæ, Internal and External pterygoid, and Superior constrictor of the pharynx.

THE INFERIOR TURBINATED BONES.

The **Inferior Turbinated Bones** (*turbo*, a whirl) are situated one on each side of the outer wall of the nasal fossæ. Each consists of a layer of thin spongy bone curled upon itself like a scroll, hence its name "turbinated," and extends horizontally along the outer wall of the nasal fossa immediately below the orifice of the antrum. Each bone presents two surfaces, two borders, and two extremities.

The **internal surface** (Fig. 167) is convex, perforated by numerous apertures, and traversed by longitudinal grooves and canals for the lodgment of arteries and veins. In the recent state it is covered by the lining membrane of the nose.

FIG. 167.

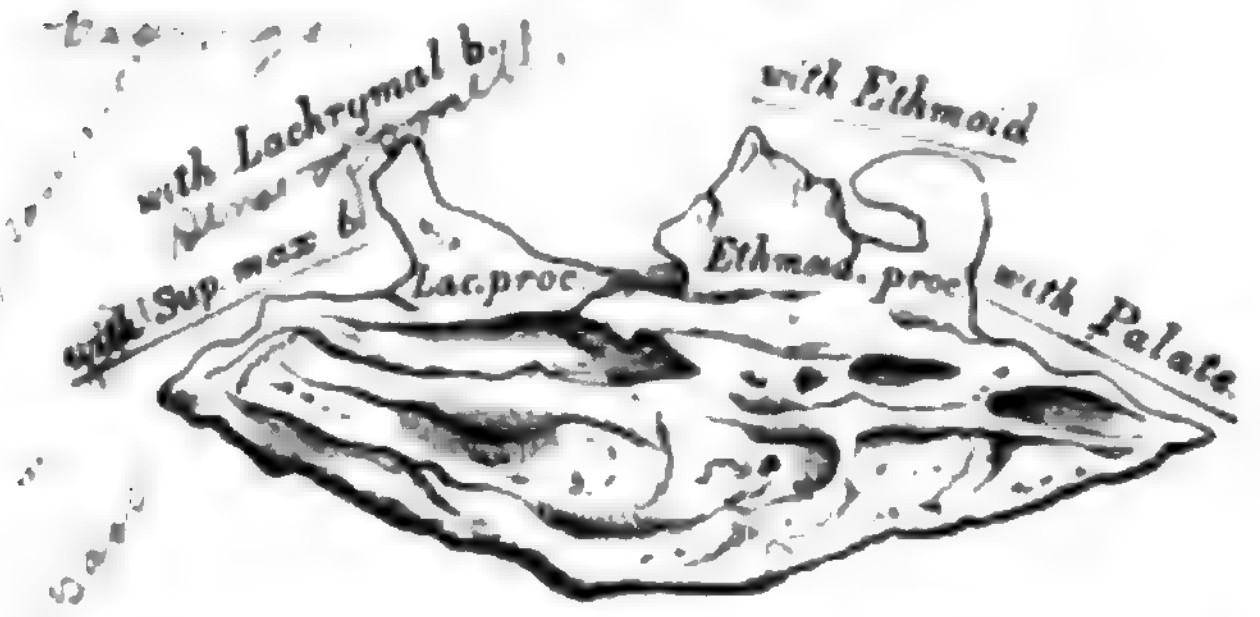

Right Inferior Turbinated Bone, internal surface.

FIG. 168.

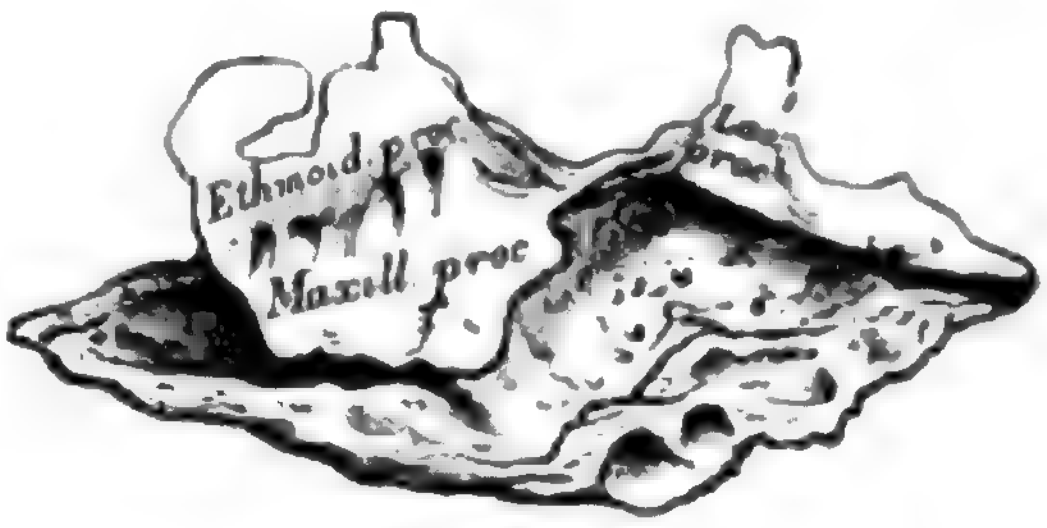

Right Inferior Turbinated Bone, outer surface.

The **external surface** is concave (Fig. 168), and forms part of the inferior meatus. Its *upper border* is thin, irregular, and connected to various bones along the outer wall of the nose. It may be divided into three portions: of these, the anterior articulates with the inferior turbinated crest of the superior maxillary bone; the posterior, with the inferior turbinated crest of the palate bone; the middle portion of the superior border presents three well-marked processes, which vary much in their size and form. Of these, the anterior and smallest is situated at the junction of the anterior fourth with the posterior three-fourths of the bone; it is small and pointed, and is called the *lachrymal process*, for it articulates with the anterior inferior angle of the lachrymal bone, and by its margins with the groove on the back of the nasal process of the superior maxillary, and thus assists in forming the lachrymal canal. At the junction of the two middle fourths of the bone, but encroaching on its posterior fourth, a broad thin plate, the *ethmoidal process*, ascends to join the unciform process of the ethmoid: from the lower border of this process a thin lamina of bone curves downward and outward, hooking over the lower edge of the orifice of the antrum, which it narrows below: it is called the *maxillary process*, and fixes the bone firmly on to the outer wall of the nasal fossa. The *inferior border* is free, thick, and cellular in structure, more especially in the middle of the bone. Both *extremities* are more or less narrow and pointed. If the bone is held so that its outer concave surface is directed backward (*i. e.* toward the holder), and its superior border, from which the lachrymal and ethmoidal processes project, upward, the lachrymal process will be directed to the side to which the bone belongs.[1]

Development.—By a single centre, which makes its appearance about the middle of fœtal life.

Articulations.—With four bones: one of the cranium, the ethmoid; and three of the face, the superior maxillary, lachrymal, and palate.

No muscles are attached to this bone.

---

[1] If the lachrymal process is broken off, as is often the case, the side to which the bone belongs may be known by recollecting that the maxillary process is nearer the back than the front of the bone.

THE VOMER.

The **Vomer** (*vomer*, a ploughshare) is a single bone situated vertically at the back part of the nasal fossæ, forming part of the septum of the nose. It is thin, somewhat like a ploughshare in form; but it varies in different individuals, being frequently bent to one or the other side; it presents for examination two surfaces and four borders. The *lateral surfaces* are smooth, marked by small furrows for the lodgment of blood-vessels, and by a groove on each side, sometimes a canal, the *naso-palatine*, which runs obliquely downward and forward to the intermaxillary suture [foramina of Scarpa in the anterior palatine fossa]; it transmits the naso-palatine nerve. The *superior border*, the thickest, presents a deep groove, bounded on each side by a horizontal projecting ala of bone; the groove receives the rostrum of the sphenoid, whilst the alæ are overlapped and retained by laminæ (the *vaginal processes*) which project from the under surface of the body of the sphenoid at the base of the pterygoid processes. At the front of the groove a fissure is left for the transmission of blood-vessels to the substance of the bone. The *inferior border*, the longest, is broad and uneven in front, where it articulates with the two superior maxillary bones; thin and sharp behind, where it joins with the palate bones. The upper half of the *anterior border* usually consists of two laminæ of bone, between which is received the perpendicular plate of the ethmoid, the lower half consisting of a single rough edge, also occasionally channelled, which is united to the triangular cartilage of the nose. The *posterior border* is free, concave, and separates the nasal fossæ behind. It is thick and bifid above, thin below.

Fig. 169.

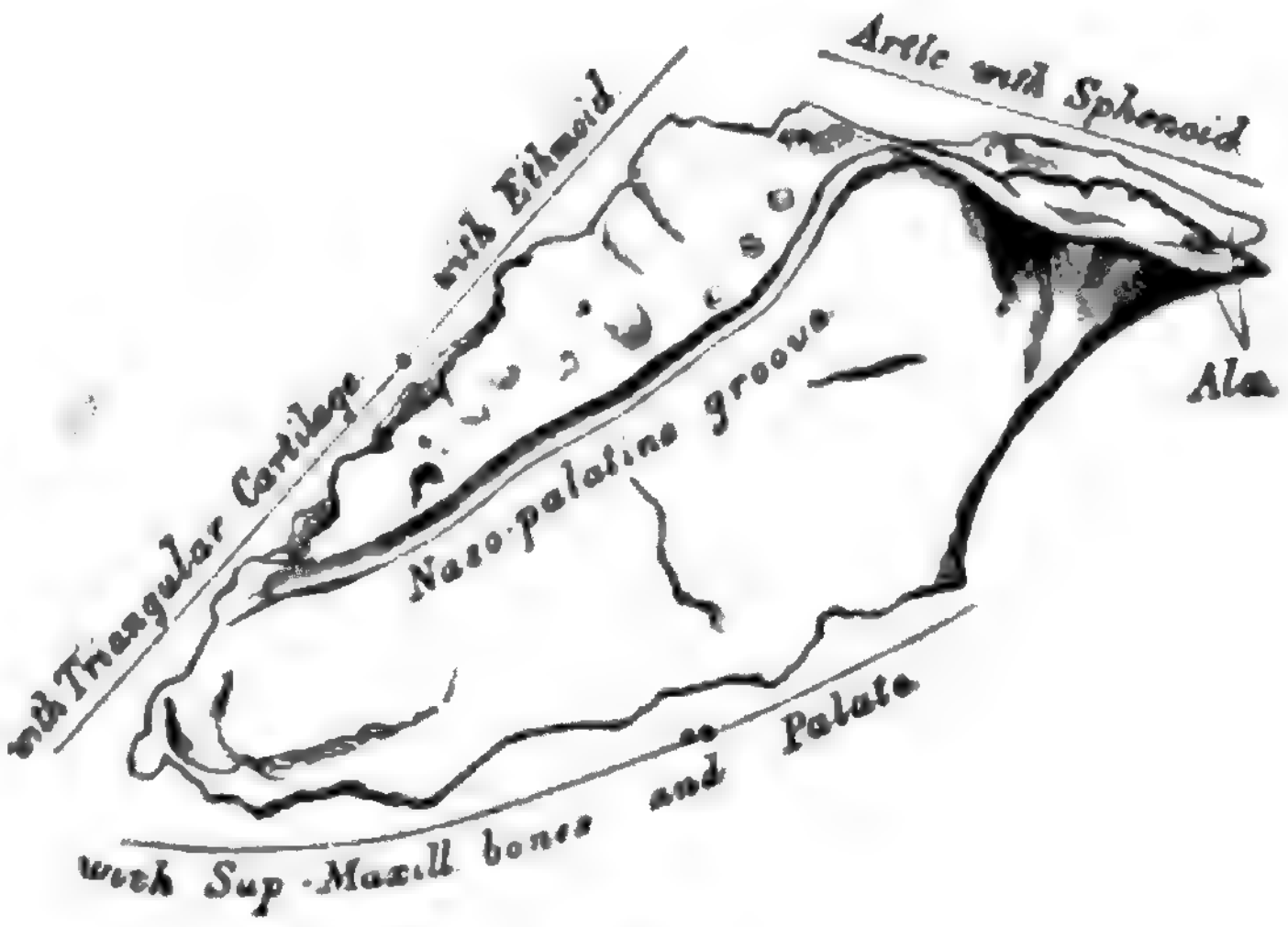

Vomer.

Development.—The vomer at an early period consists of two laminæ separated by a very considerable interval, and enclosing between them a plate of cartilage which is prolonged forward to form the remainder of the septum. Ossification commences in it by a single centre about the eighth week. From this nucleus the two laminæ are formed. They begin to coalesce at the hinder part, but their union is not complete until after puberty.

Articulations.—With six bones: two of the cranium, the sphenoid and ethmoid; and four of the face, the two superior maxillary and the two palate bones; and with the cartilage of the septum.

The vomer has no muscles attached to it.

THE INFERIOR MAXILLARY BONE.

The **Inferior Maxillary Bone**, the largest and strongest bone of the face, serves for the reception of the lower teeth. It consists of a curved horizontal portion, the *body*, and two perpendicular portions, the *rami*, which join the back part of the body nearly at right angles.

The **Horizontal Portion, or body** (Fig. 170), is convex in its general outline, and curved somewhat like a horseshoe. It presents for examination two surfaces and two borders. The **external surface** is convex from side to side, concave from above downward. In the median line is a vertical ridge, the *symphysis*, which extends from the upper to the lower border of the bone, and indicates the point of junction of the two pieces of which the bone is composed at an early period of life. The lower part of the ridge terminates in a prominent triangular eminence, the *mental process* [from *mentum*, the chin, not *mens*, the mind. The large development of the chin is very distinctive of man. The lower animals lack a chin, properly so called]. On either side of the symphysis, just below the cavities for the incisor teeth, is a depression, the *incisive fossa*, for the attachment of the Levator menti (or Levator labii inferioris); and, still more externally, a foramen, the *mental foramen*, for the passage of the mental nerve and artery. This foramen is placed just below the root of the second bicuspid tooth. Running outward from the base

FIG. 170.

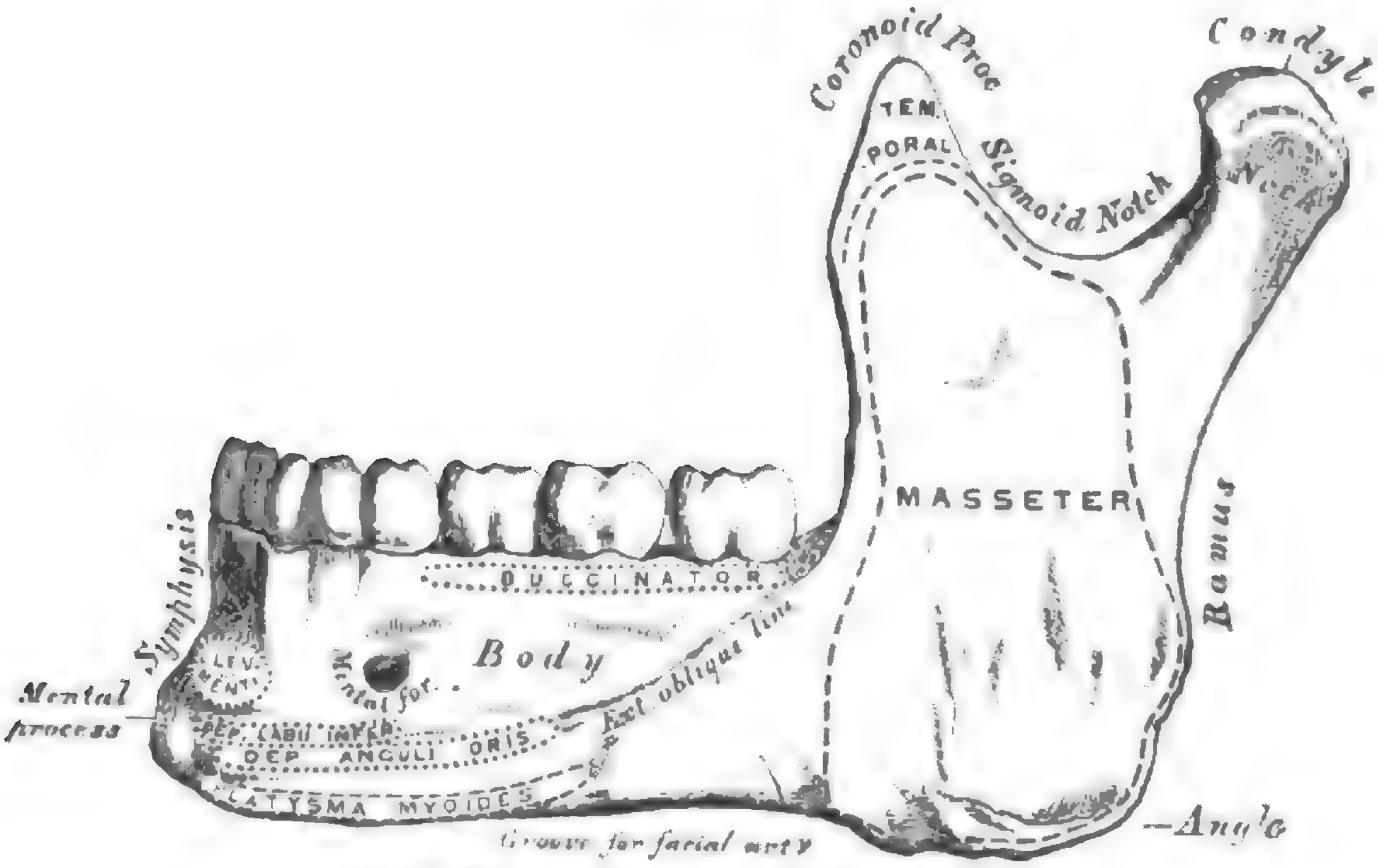
Coronoid Proc
Condyle
TEMPORAL
Sigmoid Notch
Neck
MASSETER
Ramus
Symphysis
BUCCINATOR
LEV. MENTI
Body
Mental for.
Ext. oblique line
Mental process
DEP. LABII INFER.
DEP. ANGULI ORIS
PLATYSMA MYOIDES
Groove for facial artery
Angle

Inferior Maxillary Bone, outer surface, side view.

FIG. 171.

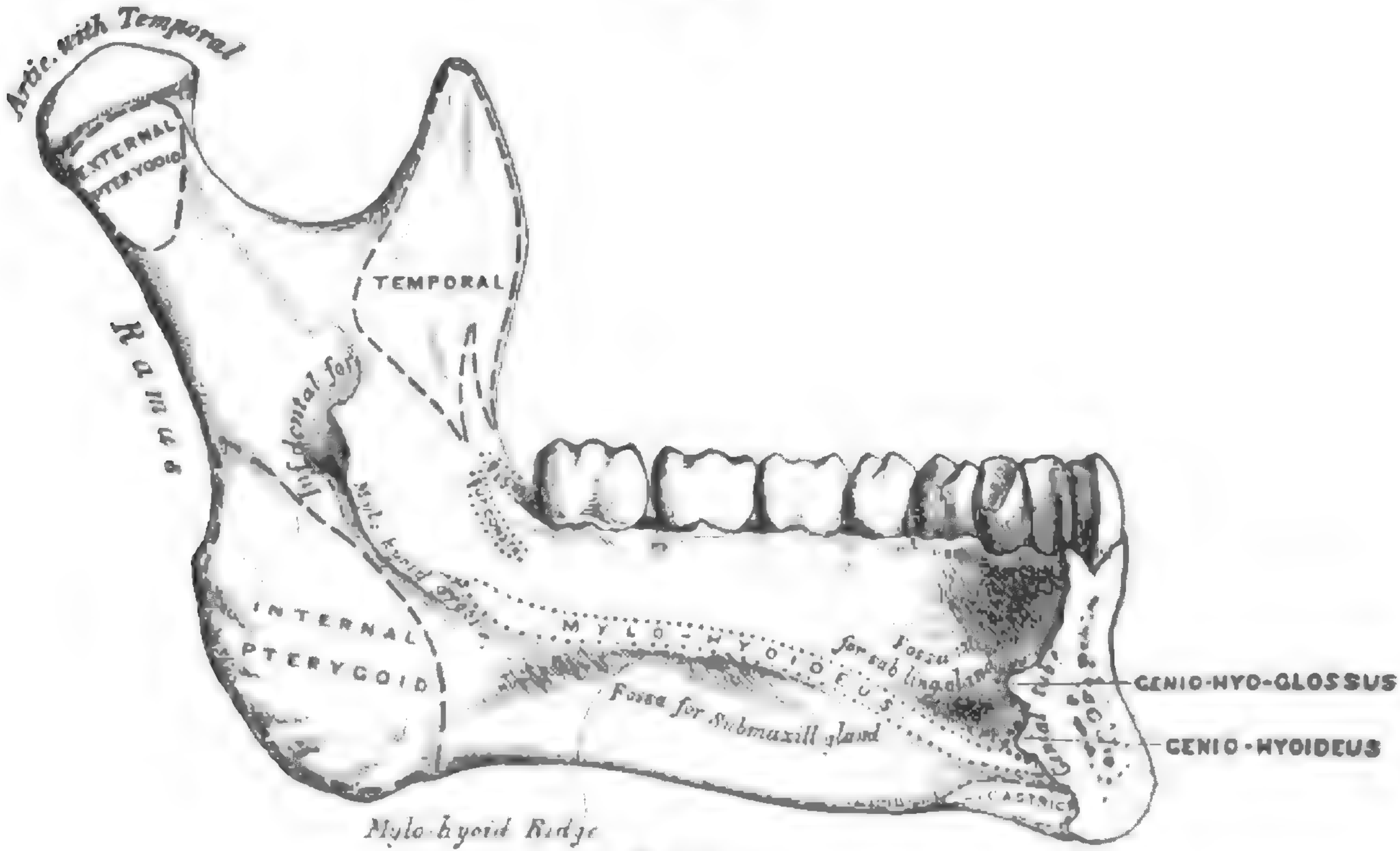
Artic. with Temporal
EXTERNAL PTERYGOID
TEMPORAL
Ramus
Inf. dental for.
Mylo-hyoid groove
INTERNAL PTERYGOID
MYLO-HYOIDEUS
Fossa for sub lingual gland
Fossa for Submaxill gland
GENIO-HYO-GLOSSUS
GENIO-HYOIDEUS
GASTRIC
Mylo-hyoid Ridge
Body

Inferior Maxillary Bone, inner surface, side view.

of the mental process on each side is a well-marked ridge, the *external oblique* line. The ridge is at first nearly horizontal, but afterward inclines upward and backward, and is continuous with the anterior border of the ramus; it affords attachment to the Depressor labii inferioris and Depressor anguli oris; below it the Platysma myoides is attached.

The **internal surface** (Fig. 171) is concave from side to side, convex from above downward. In the middle line is an indistinct linear depression corresponding to the symphysis externally; on either side of this depression, just below its centre, are four prominent tubercles, placed in pairs, two above and two below; they are called the *genial tubercles* [γενειον, the chin] and afford attachment, the upper pair to the Genio-hyo-glossi muscles, the lower pair to the Genio-hyoidei muscles. Sometimes the tubercles on each side are blended into one; at others they all unite into an irregular eminence; or, again, nothing but an irregularity may be seen on the surface of the bone at this part. On either side of the genial tubercles is an oval depression, the *sublingual fossa*, for lodging the sublingual gland; and beneath the fossa a rough depression on each side which gives attachment to the anterior belly of the Digastric muscle. At the back part of the sublingual fossa the *internal oblique line* (*mylo-hyoidean*) commences; it is at first faintly marked, but becomes more distinct as it passes upward and outward, and is especially prominent opposite the last two molar teeth; it affords attachment throughout its whole extent to the Mylo-hyoid muscle, the Superior constrictor of the pharynx with the pterygo-maxillary ligament being attached above its posterior extremity, nearer the alveolar margin. The portion of bone above this ridge is smooth, and covered by the mucous membrane of the mouth; the portion below presents an oblong depression, the *submaxillary fossa*, wider behind than in front, for the lodgment of the submaxillary gland. The external oblique line and the internal or mylo-hyoidean line divide the body of the bone into a superior or alveolar and an inferior or basilar portion.

The **superior or alveolar** border is wider and its margins thicker behind than in front. It is hollowed into numerous cavities for the reception of the teeth: these cavities are sixteen in number, and vary in depth and size according to the teeth which they contain. To its outer side the Buccinator muscle is attached as far forward as the first molar tooth. The *inferior border* is rounded, longer than the superior, and thicker in front than behind; it presents a shallow groove just where the body joins the ramus, over which the facial artery turns.

The **Perpendicular Portions,** or **Rami,** are of a quadrilateral form. Each presents for examination two surfaces, four borders, and two processes. The *external surface* is flat, marked with ridges, and gives attachment throughout nearly the whole of its extent to the Masseter muscle. The *internal surface* presents about its centre the oblique aperture of the inferior dental canal, for the passage of the inferior dental vessels and nerve. The margin of this opening is irregular; it presents in front a prominent ridge, surmounted by a sharp spine, which gives attachment to the internal lateral ligament of the lower jaw, and at its lower and back part a notch leading to a groove, the *mylo-hyoidean*, which runs obliquely downward to the back part of the submaxillary fossa, and lodges the mylo-hyoid vessels and nerve: behind the groove is a rough surface, for the insertion of the Internal pterygoid muscle. The inferior dental canal runs obliquely downward and forward in the substance of the ramus, and then horizontally forward in the body; it is here placed under the alveoli, with which it communicates by small openings. On arriving at the incisor teeth it turns back to communicate with the mental foramen, giving off two small canals, which run forward, to be lost in the cancellous tissue of the bone beneath the incisor teeth. This canal, in the posterior two-thirds of the bone, is situated nearer the internal surface of the jaw, and in the anterior third nearer its external surface. Its walls are composed of compact tissue at either extremity and of cancellous in the centre. It contains the inferior dental vessels and nerve, from which branches are distributed to the teeth through small apertures at the bases of the alveoli. The *upper border* of the ramus is thin, and presents two processes separated by a deep concavity, the *sigmoid notch*. Of these processes, the anterior is the *coronoid*, the posterior the *condyloid*.

The **Coronoid Process** is a thin, flattened, triangular eminence of bone which varies in shape and size in different subjects, and serves chiefly for the attachment of the Temporal muscle. Its *external surface* is smooth, and affords attachment to the Masseter and Temporal muscles. Its *internal surface* gives attachment to the Temporal muscle, and presents the commencement of a longitudinal ridge which is continued to the posterior part of the alveolar process. On the outer side of this ridge is a deep groove continued below on the outer side of the alveolar process; this ridge and part of the groove afford attachment, above, to the Temporal; below, to the Buccinator muscle.

The **Condyloid Process**, shorter but thicker than the coronoid, consists of two portions—the *condyle*, and the constricted portion which supports the condyle, the *neck*. The *condyle* is of an oblong form, its long axis being transverse and set obliquely on the neck in such a manner that its outer end is a little more forward and a little higher than its inner. It is convex from before backward and from side to side, the articular surface extending farther on the posterior than on the anterior surface. The *neck* of the condyle is flattened from before backward, and strengthened by ridges which descend from the fore part and sides of the condyle. Its lateral margins are narrow, and present externally a tubercle for the external lateral ligament. Its posterior surface is convex; its anterior is hollowed out on its inner side by a depression (the *pterygoid fossa*) for the attachment of the External pterygoid.

The *lower border* of the ramus is thick, straight, and continuous with the body of the bone. At its junction with the posterior border is the *angle of the jaw*, which is either inverted or everted, and marked by rough oblique ridges on each side, for the attachment of the Masseter externally and the Internal pterygoid internally; the stylo-maxillary ligament is attached to the bone between these muscles. The *anterior border* is thin above, thicker below, and continuous with the external oblique line. The *posterior border* is thick, smooth, rounded, and covered by the parotid gland.

The **Sigmoid Notch**, separating the two processes, is a deep semilunar depression crossed by the masseteric artery and nerve.

Development.—The lower jaw is developed principally from membrane, but partly from cartilage. The bone is formed at such an early period of life—before, indeed, any other bone except the clavicle—that it has been found impossible at present to determine its earliest condition. It is generally believed, however, that each half is developed by several centres, which speedily unite. The greater part is formed from the fibrous tissue investing Meckel's cartilage (p. 118), but a small portion near the symphysis is developed from the anterior extremity of the cartilage itself; while the condyle and a part of the ramus are developed from another mass of cartilage. According to Callender, a separate ossific plate forms the floor of the dental groove. At birth the bone consists of two halves, united by a fibrous symphysis in which ossification takes place during the first year.

CHANGES PRODUCED IN THE LOWER JAW BY AGE.

The changes which the lower jaw undergoes after birth relate—1, to the alterations effected in the body of the bone by the first and second dentitions, the loss of the teeth in the aged, and the subsequent absorption of the alveoli; 2, to the size and situation of the dental canal; and 3, to the angle at which the ramus joins with the body.

At birth (Fig. 172) the bone consists of two lateral halves, united by fibro-cartilaginous tissue, in which one or two osseous nuclei are generally found. The body is a mere shell of bone, containing the sockets of the two incisor, the canine, and the two temporary molar teeth, imperfectly partitioned from one another. The dental canal is of large size, and runs near the lower border of the bone, the mental foramen opening beneath the socket of the first molar. The angle is obtuse, and the condyloid portion nearly in the same horizontal line with the ramus; the neck of the condyle is short and bent backward. The coronoid process is of comparatively large size and situated at right angles with the rest of the bone.

After birth (Fig. 173) the two segments of the bone become joined at the symphysis, from below upward, in the first year; but a trace of separation may be visible in the beginning of

Side View of the Lower Jaw at Different Periods of Life.

FIG. 172. At Birth.



FIG. 173. At Puberty.

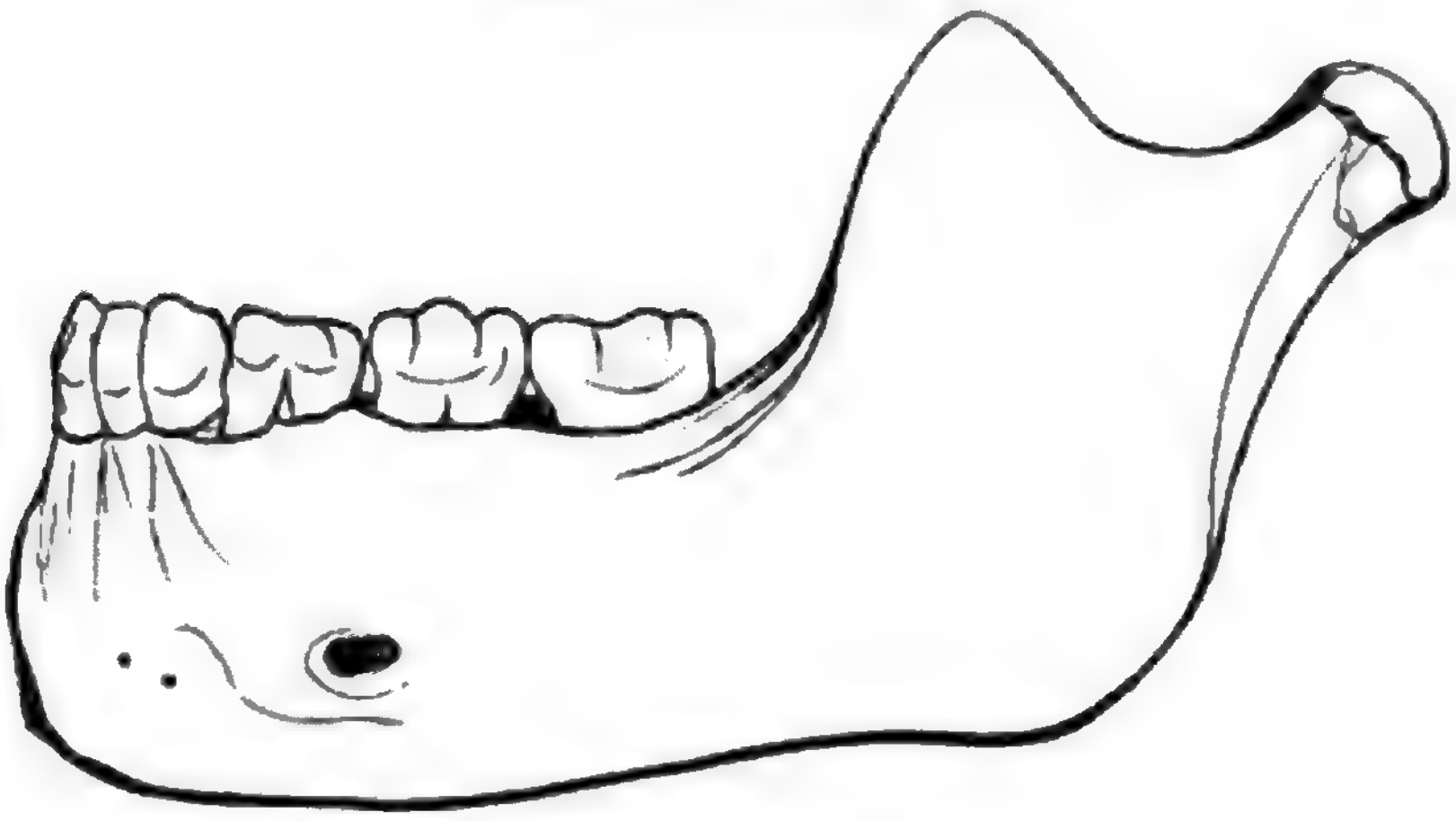

FIG. 174. In the Adult.

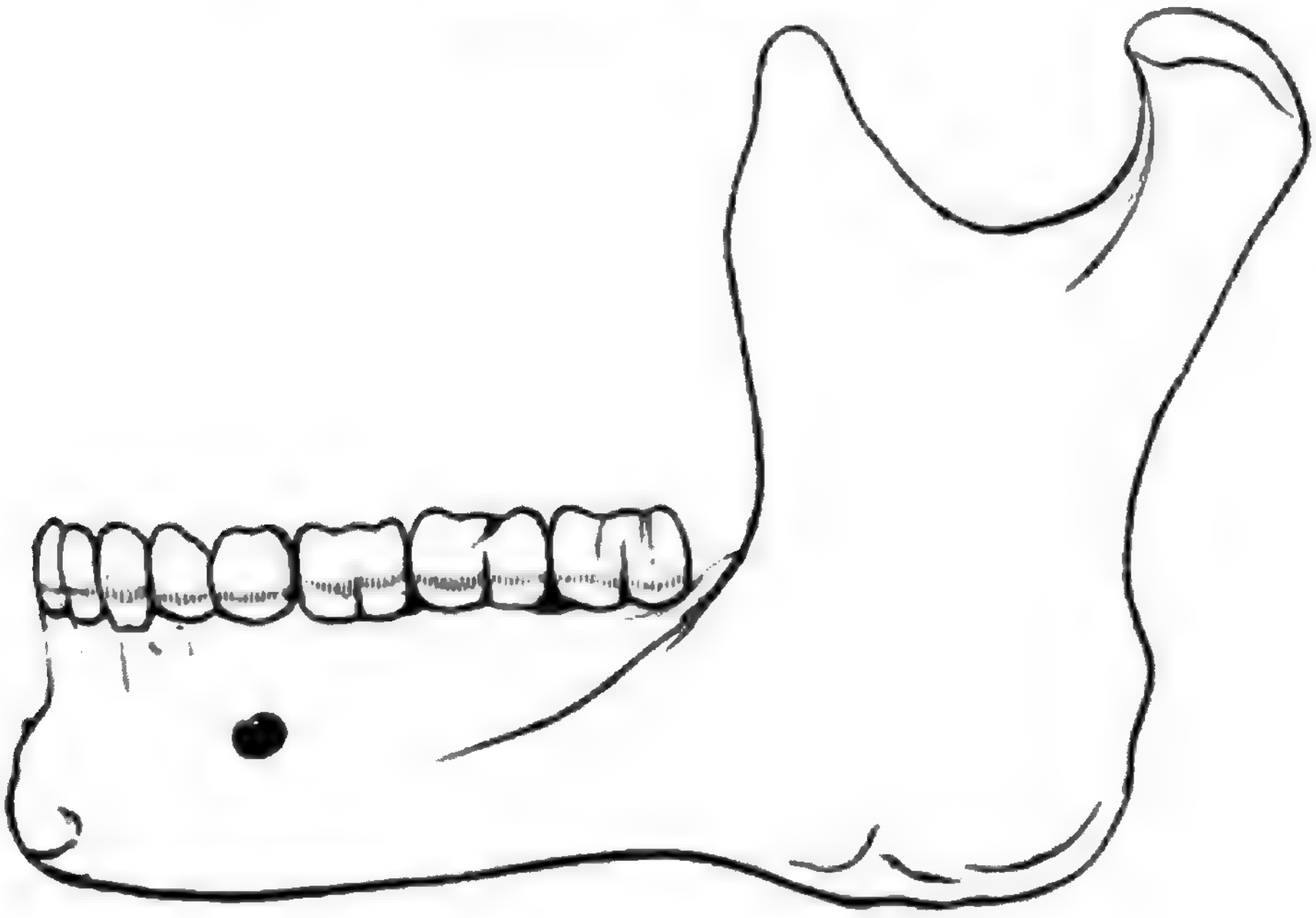

FIG. 175. In Old Age.

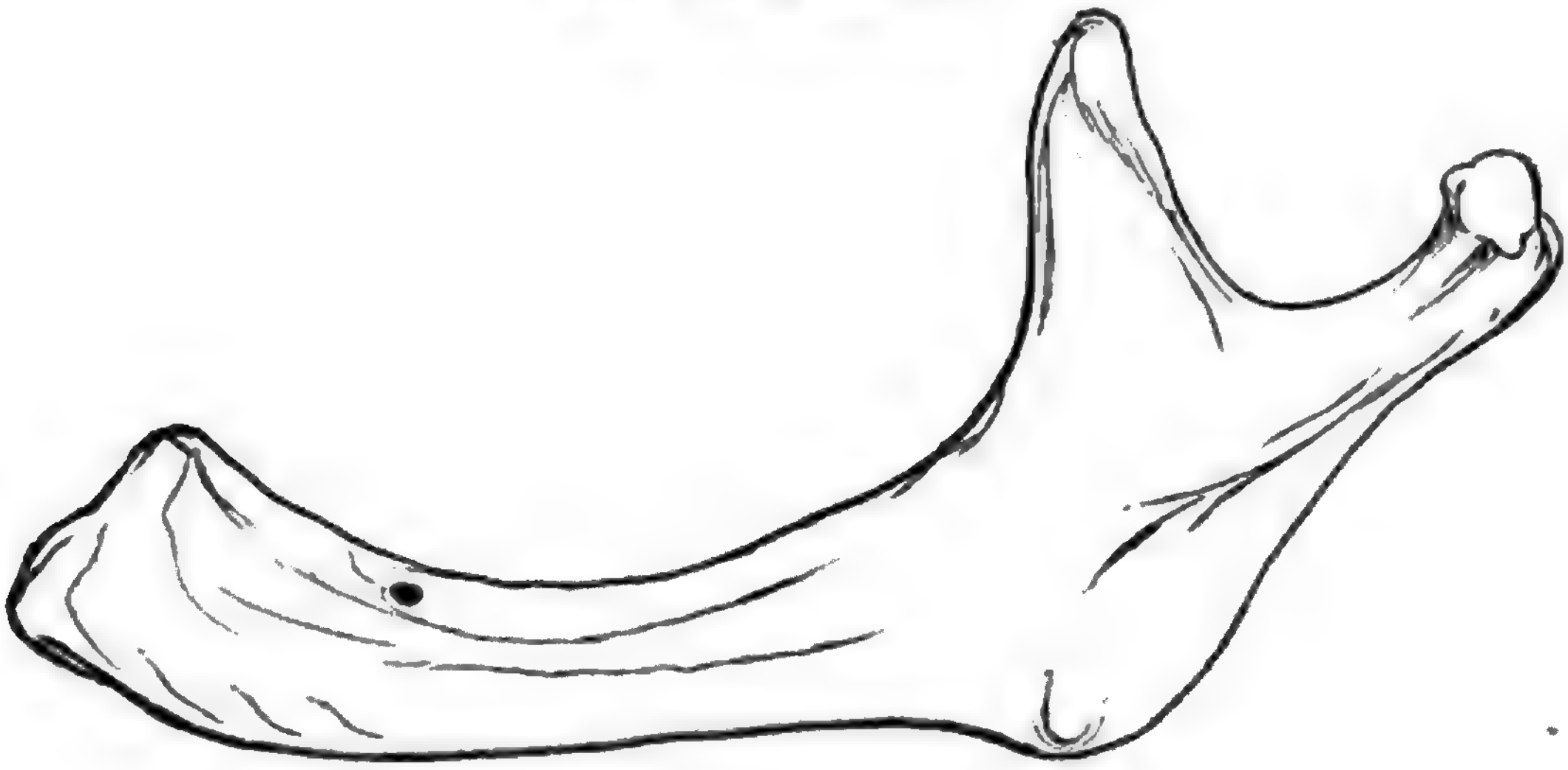

the second year near the alveolar margin. The body becomes elongated in its whole length, but more especially behind the mental foramen, to provide space for the three additional teeth developed in this part. The depth of the body becomes greater, owing to increased growth of the alveolar part, to afford room for the fangs of the teeth, and by thickening of the subdental portion, which enables the jaw to withstand the powerful action of the masticatory muscles; but the alveolar portion is the deeper of the two, and, consequently, the chief part of the body lies above the oblique line. The dental canal, after the second dentition, is situated just above the level of the mylo-hyoid ridge, and the mental foramen occupies the position usual to it in the adult. The angle becomes less obtuse, owing to the separation of the jaws by the teeth.

In the adult (Fig. 174) the alveolar and basilar portions of the body are usually of equal depth. The mental foramen opens midway between the upper and lower borders of the bone, and the dental canal runs nearly parallel with the mylo-hyoid line. The ramus is almost vertical in direction, and joins the body nearly at right angles.

In old age (Figs. 175 and 176) the bone becomes greatly reduced in size; for with the loss of the teeth the alveolar process is absorbed, and the basilar part of the bone alone remains; consequently, the chief part of the bone is *below* the oblique line. The dental canal, with the mental foramen opening from it, is close to the alveolar border. The rami are oblique in direction, the angle obtuse, and the neck of the condyle more or less bent backward.

[Fig. 176.

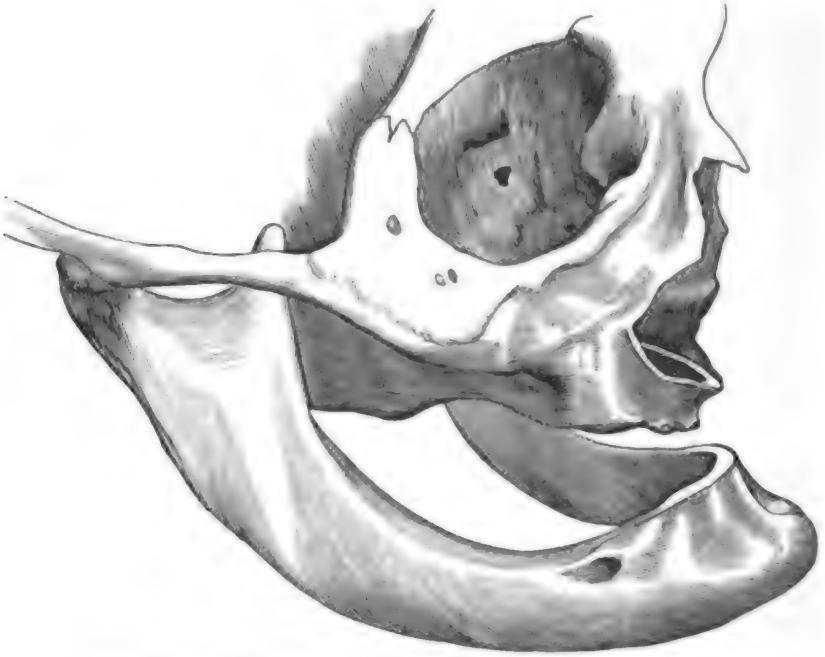

Absorption of the Alveolar Processes of both Jaws, after loss of the teeth (Litch).]

Articulation.—With the glenoid fossæ of the two temporal bones.

Attachment of Muscles.—To fifteen pairs—to its external surface, commencing at the symphysis and proceeding backward: Levator menti, Depressor labii inferioris, Depressor anguli oris, Platysma myoides, Buccinator, Masseter; a portion of the Orbicularis oris (Accessorii orbicularis inferiores) is also attached to this surface. To its internal surface, commencing at the same point: Genio-hyo-glossus, Genio-hyoideus, Mylo-hyoideus, Digastric, Superior constrictor, Temporal, Internal pterygoid, External pterygoid.

THE SUTURES.

The bones of the cranium and face are connected to each other by means of *Sutures* [Fig. 178, p. 209]. The sutures are rows of dentated processes of bone projecting from the edge of either bone, and locking into one another; the dentations, however, are confined to the external table, the edges of the internal table lying merely in apposition. The *Cranial Sutures* may be divided into three sets: 1, Those at the vertex of the skull; 2, those at the side of the skull; 3, those at the base.

The sutures at the vertex of the skull are three: the *sagittal*, *coronal*, and *lambdoid*.

The **Sagittal Suture** (*interparietal*) is formed by the junction of the two parietal bones, and extends from the middle of the frontal bone backward to the superior angle of the occipital. In childhood, and occasionally in the adult when the two halves of the frontal bone are not united, it is continued forward to the root of the nose. This suture sometimes presents, near its posterior extremity, the parietal foramen on each side; and in front, where it joins the coronal suture, a space is occasionally left which encloses a large Wormian bone.

The **Coronal Suture** (*fronto-parietal*) extends transversely across the vertex of the skull and connects the frontal with the parietal bones. It commences at the extremity of the greater wing of the sphenoid on one side, and terminates at the same point on the opposite side. The dentations of this suture are more marked at the sides than at the summit, and are so constructed that the frontal rests on the parietal above, whilst laterally the frontal supports the parietal.

The **Lambdoid Suture** (*occipito-parietal*), so called from its resemblance to the Greek letter Λ, connects the occipital with the parietal bones. It commences on each side at the mastoid portion of the temporal bone, and inclines upward to the end of the sagittal suture. The dentations of this suture are very deep and distinct, and are often interrupted by several small Wormian bones.

The sutures at the side of the skull are also three in number: the *spheno-parietal*, *squamo-parietal*, and *masto-parietal*. They are subdivisions of a single suture formed between the lower border of the parietal and the sphenoid and temporal bones, and which extends from the lower end of the coronal suture in front to the lower end of the lambdoid suture behind.

The **Spheno-parietal** is very short; it is formed by the tip of the great wing of the sphenoid, which overlaps the anterior inferior angle of the parietal bone.

The **Squamo-parietal** or **Squamous Suture** is arched. It is formed by the squamous portion of the temporal bone overlapping the middle division of the lower border of the parietal.

The **Masto-parietal** is a short suture, deeply dentated, formed by the posterior inferior angle of the parietal and the superior border of the mastoid portion of the temporal.

The sutures at the base of the skull are—the *basilar* in the centre, and on each side the *petro-occipital*, the *masto-occipital*, the *petro-sphenoidal*, and the *squamo-sphenoidal*.

The **Basilar Suture** is formed by the junction of the basilar surface of the occipital bone with the posterior surface of the body of the sphenoid. At an early period of life a thin plate of cartilage exists between these bones, but in the adult they become fused into one. Between the outer extremity of the basilar suture and the termination of the lambdoid an irregular suture exists which is subdivided into two portions. The inner portion, formed by the union of the petrous part of the temporal with the occipital bone, is termed the *petro-occipital*. The outer portion, formed by the junction of the mastoid part of the temporal with the occipital, is called the *masto-occipital*. Between the bones forming the petro-occipital suture a thin plate of cartilage exists; in the masto-occipital is occasionally found the opening of the mastoid foramen. Between the outer extremity of the basilar suture and the spheno-parietal an irregular suture may be seen, formed by the union of the sphenoid with the temporal bone. The inner and smaller portion of this suture is termed the *petro-sphenoidal;* it is formed between the petrous portion of the temporal and the great wing of the sphenoid; the outer portion, of greater length and arched, is formed between the squamous portion of the temporal and the great wing of the sphenoid: it is called the *squamo-sphenoidal.*

The cranial bones are connected with those of the face, and the facial bones with each other, by numerous sutures, which, though distinctly marked, have received no special names. The only remaining suture deserving especial consideration is the *transverse.* This extends across the upper part of the face, and is formed by the junction of the frontal with the facial bones: it extends from the external angular process of one side to the same point on the opposite side, and connects the frontal with the malar, the sphenoid, the ethmoid, the lachrymal, the superior maxillary, and the nasal bones on each side.

The sutures remain separate for a considerable period after the complete formation of the skull. It is probable that they serve the purpose of permitting the growth of the bones at their margins, while their peculiar formation, together with the interposition of the sutural ligament between the bones forming them, prevents the dispersion of blows or jars received upon the skull. Dr. Humphry remarks "that, as a general rule, the sutures are first obliterated at the parts in which the ossification of the skull was last completed—viz. in the neighborhood of the fontanelles; and the cranial bones seem in this respect to observe a similar law to that which regulates the union of the epiphyses to the shafts of the long bones." The same author remarks that the time of their disappearance is extremely variable: they are sometimes found well marked in skulls edentulous with age, while in others which have only just reached maturity they can hardly be traced.

THE SKULL.

The Skull, formed by the union of the several cranial and facial bones already described, when considered as a whole, is divisible into five regions—a superior region or vertex, an inferior region or base, two lateral regions, and an anterior region, the face.

VERTEX OF THE SKULL.

The **Superior Region,** or **Vertex,** presents two surfaces, an external and an internal.

The **external surface** is bounded in front by the nasal eminence and supraorbital ridges; behind, by the occipital protuberance and superior curved lines of the occipital bone; laterally, by an imaginary line extending from the outer end of the superior curved line, along the temporal ridge, to the external angular process of the frontal. This surface includes the vertical portion of the frontal, the greater part of the parietal, and the superior third of the occipital bone; it is smooth, convex, of an elongated oval form, crossed transversely by the coronal suture, and from before backward by the sagittal, which terminates behind in the lambdoid. From before backward may be seen the frontal eminences and remains of the suture connecting the two lateral halves of the frontal bone; on each side of the sagittal suture are the parietal foramen and parietal eminence, and still more posteriorly the convex surface of the occipital bone.

The **internal surface** is concave, presents eminences and depressions for the convolutions of the cerebrum, and numerous furrows for the lodgment of branches of the meningeal arteries. Along the middle line of this surface is a longitudinal groove, narrow in front, where it terminates in the frontal crest, but broader behind, where it lodges the superior longitudinal sinus and by its margin affords attachment to the falx cerebri. On either side of it are several depressions for the Pacchionian bodies, and at its back part the internal openings of the parietal foramina. This surface is crossed in front by the coronal suture; from before backward, by the sagittal; behind, by the lambdoid.

BASE OF THE SKULL.

The **Inferior Region**, or **Base of the Skull**, presents two surfaces—an internal or cerebral, and an external or basilar.

The **internal** or **cerebral surface** (Fig. 177) presents three fossæ, called the *anterior*, *middle*, and *posterior* fossæ of the cranium.

FIG. 177.

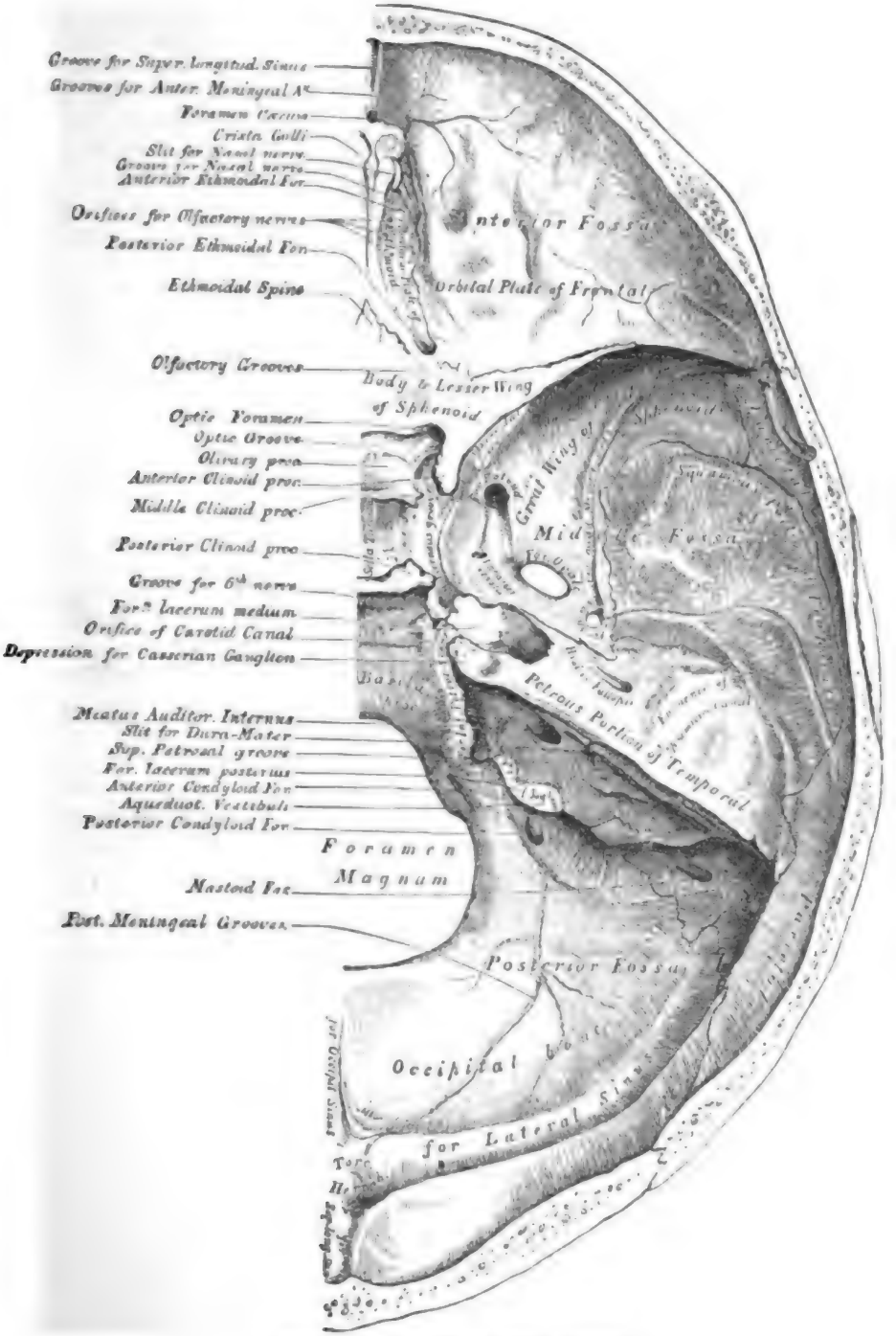
Groove for Super. longitud. Sinus
Grooves for Anter. Meningeal Ar.
Foramen Cæcum
Crista Galli
Slit for Nasal nerve
Groove for Nasal nerve
Anterior Ethmoidal For.
Orifices for Olfactory nerves
Posterior Ethmoidal For.
Ethmoidal Spine
Olfactory Grooves
Optic Foramen
Optic Groove
Olivary proc.
Anterior Clinoid proc.
Middle Clinoid proc.
Posterior Clinoid proc.
Groove for 6th nerve
For.n lacerum medium
Orifice of Carotid Canal
Depression for Casserian Ganglion
Meatus Auditor. Internus
Slit for Dura-Mater
Sup. Petrosal groove
For. lacerum posterius
Anterior Condyloid For.
Aquæduct. Vestibuli
Posterior Condyloid For.
Mastoid For.
Post. Meningeal Grooves
Anterior Fossa
Orbital Plate of Frontal
Body & Lesser Wing of Sphenoid
Great Wing of Sphenoid
Middle Fossa
For. Ovale
Sella Turcica
Basilar Process
Petrous Portion of Temporal
Foramen Magnum
Posterior Fossa
Occipital bone
for Lateral Sinus
Torc. Heroph.

Base of the Skull, inner or cerebral surface.

The **Anterior Fossa** is formed by the orbital plate of the frontal, the cribriform plate of the ethmoid, the ethmoidal spine, and the lesser wing of the sphenoid. It is the most elevated of the three fossæ, convex externally where it corresponds to the roof of the orbit, concave in the median line in the situation of the cribriform plate of the ethmoid. It is traversed by three sutures—the *ethmo-frontal, ethmo-sphenoidal*, and *fronto-sphenoidal*—and lodges the anterior lobe of the cerebrum. It presents, in the median line, from before backward, the commencement of the groove for the superior longitudinal sinus and the crest for the attachment of the falx cerebri; the *foramen cæcum*, an aperture formed by the frontal bone and the crista galli of the ethmoid, which, if pervious, transmits a small vein from the nose to the superior longitudinal sinus; behind the foramen cæcum, the *crista galli*, the posterior margin of which affords attachment to the falx cerebri; on either side of the crista galli, the *olfactory groove*, which supports the bulb of the olfactory nerve, and presents three rows of foramina for its filaments, and in front a slit-like opening for the nasal branch of the ophthalmic [division of the fifth] nerve. On the outer side of each olfactory groove are the internal openings of the *anterior* and *posterior ethmoidal foramina;* the former, situated about the middle of the outer margin of the olfactory groove, transmits the anterior ethmoidal artery and the nasal nerve, which runs in a depression along the surface of the ethmoid to the slit-like opening above mentioned; whilst the posterior ethmoidal foramen opens at the back part of this margin under cover of the projecting lamina of the sphenoid, and transmits the posterior ethmoidal artery and vein to the posterior ethmoidal cells. Farther back in the middle line is the *ethmoidal spine*, bounded behind by an elevated ridge separating two longitudinal grooves which support the olfactory nerves. The anterior fossa presents, laterally, eminences and depressions for the convolutions of the brain and grooves for the lodgment of the anterior meningeal arteries.

The **Middle Fossa,** somewhat deeper than the preceding, is narrow in the middle line, but becomes wider at the side of the skull. It is bounded in front by the posterior margin of the lesser wing of the sphenoid, the anterior clinoid process, and the anterior margin of the optic groove; behind, by the superior border of the petrous portion of the temporal and the dorsum ephippii; externally, by the squamous portion of the temporal, anterior inferior angle of the parietal bone, and greater wing of the sphenoid. It is traversed by four sutures—the squamo-parietal, spheno-parietal, spheno-temporal, and petro-sphenoidal.

In the middle line, from before backward, is the *optic groove*, which supports the optic commissure, and terminates on each side in the optic foramen, for the passage of the optic nerve and ophthalmic artery; behind the optic groove is the *olivary process;* and laterally, the *anterior clinoid processes*, to which are attached processes of the tentorium cerebelli. Farther back is the *sella Turcica*, a deep depression which lodges the pituitary gland, bounded in front by a small eminence on either side, the *middle clinoid process*, and behind by a broad square plate of bone, the *dorsum ephippii*, surmounted at each superior angle by a tubercle, the *posterior clinoid process;* beneath the latter process is a groove, for the sixth nerve. On each side of the sella Turcica is the *cavernous* groove; it is broad, shallow, and curved somewhat like the italic letter *f;* it commences behind the foramen lacerum medium, and terminates on the inner side of the anterior clinoid process, and presents along its outer margin a ridge of bone, the *lingula*. This groove lodges the cavernous sinus, the internal carotid artery, and the nerves of the orbit. The sides of the middle fossa are of considerable depth; they present eminences and depressions for the middle lobes of the brain, and grooves for the branches of the middle meningeal artery: the latter commence on the outer side of the foramen spinosum, and consist of two large branches, an anterior and a posterior, the former passing upward and forward to the anterior inferior angle of the parietal bone, the latter passing upward and backward. The following foramina may also be seen from before backward: Most anteriorly is the *foramen lacerum anterius*, or *sphenoidal fissure*, formed above by the lesser wing of the sphenoid;

below, by the greater wing; internally, by the body of the sphenoid; and completed externally by the orbital plate of the frontal bone. It transmits the third, fourth, the three branches of the ophthalmic division of the fifth, the sixth nerve, some filaments of the sympathetic, the orbital branch of the middle meningeal artery, a recurrent branch from the lachrymal artery, and the ophthalmic vein. Behind the inner extremity of the sphenoidal fissure is the *foramen rotundum*, for the passage of the second division of the fifth or superior maxillary nerve; still more posteriorly is seen a small orifice, the *foramen Vesalii*, an opening situated between the foramen rotundum and ovale, a little internal to both: it varies in size in different individuals, and is often absent; when present, it transmits a small vein. It opens below into the pterygoid fossa, just at the outer side of the scaphoid depression. Behind and external to the latter opening is the *foramen ovale*, which transmits the third division of the fifth or inferior maxillary nerve, the small meningeal artery, and the small petrosal nerve.[1] On the outer side of the foramen ovale is the *foramen spinosum*, for the passage of the middle meningeal artery; and on the inner side of the foramen ovale, the *foramen lacerum medium*. The lower part of this aperture is filled up with cartilage in the recent state. The Vidian nerve pierces this cartilage. On the anterior surface of the petrous portion of the temporal bone is seen, from without inward, the eminence caused by the projection of the superior semicircular canal; outside this, a depression corresponding to the roof of the tympanum, the groove leading to the hiatus Fallopii, for the transmission of the petrosal branch of the Vidian nerve and the petrosal branch of the middle meningeal artery; beneath it, the smaller groove, for the passage of the lesser petrosal nerve; and near the apex of the bone, the depression for the Gasserian ganglion, and the orifice of the carotid canal, for the passage of the internal carotid artery and carotid plexus of nerves.

The **Posterior Fossa**, deeply concave, is the largest of the three, and situated on a lower level than either of the preceding. It is formed by the occipital, the petrous and mastoid portions of the temporal, and the posterior inferior angle of the parietal bone; is crossed by three sutures, the petro-occipital, masto-occipital, the masto-parietal; and lodges the cerebellum, pons Varolii, and medulla oblongata. It is separated from the middle fossa in the median line by the dorsum ephippii, and on each side by the superior border of the petrous portion of the temporal bone. This border serves for the attachment of the tentorium cerebelli, is grooved externally for the superior petrosal sinus, and at its inner extremity presents a notch upon which rests the fifth nerve. The circumference of the fossa is bounded posteriorly by the grooves for the lateral sinuses. In the centre of this fossa is the *foramen magnum*, bounded on either side by a rough tubercle which gives attachment to the odontoid ligaments; and a litle above these are seen the internal openings of the *anterior condyloid foramina*. In front of the foramen magnum is the *basilar process*, grooved for the support of the medulla oblongata and pons Varolii, and articulating on each side with the petrous portion of the temporal bone, forming the petro-occipital suture, the anterior half of which is grooved for the inferior petrosal sinus, the posterior half being encroached upon by the *foramen lacerum posterius*, or *jugular foramen*. This foramen presents three compartments: through the anterior the inferior petrosal sinus passes; through the posterior, the lateral sinus and some meningeal arteries; and through the middle, the ninth, tenth, and eleventh pairs of nerves.[2] Above the jugular foramen is the *internal auditory meatus*, for the facial and auditory nerves and auditory artery; behind and external to this is the slit-like opening leading into the aquæductus vestibuli; whilst between the two latter, and near the superior border of the petrous portion, is a small triangular depression which lodges a process of the dura mater, and occasionally transmits a small vein into the substance of the bone. Behind the foramen magnum are the *inferior occipital fossæ*, which lodge the hemispheres of the cerebellum, separated from one another by the *internal occipital crest*, which serves for the attachment of the falx cerebelli and lodges the occipital sinus. The posterior fossæ are surmounted above by the deep transverse grooves for the lodgment of the *lateral sinuses*. These channels, in their passage outward, groove the occipital bone, the posterior inferior angle of the parietal, the mastoid portion of the temporal, and the occipital just behind the jugular foramen, at the back part of which they terminate. Where this sinus grooves the mastoid part of the temporal bone the orifice of the *mastoid foramen* may be seen, and just previous to its termination it has opening into it the *posterior condyloid foramen*. Neither foramen is constant.

---

[1] See foot-note, p. 178.

[2] [In Fig. 177, in the jugular foramen, the "8th pr" means the eighth pair of nerves in the enumeration of Willis, and consists of the ninth, tenth, and eleventh of Sömmerring.]

The **external surface** of the base of the skull (Fig. 178) is extremely irregular. It is bounded in front by the incisor teeth in the upper jaws; behind, by the superior curved lines of the occipital bone; and laterally, by the alveolar arch, the lower border of the malar bone, the zygoma, and an imaginary line extending from the zygoma to the mastoid process and extremity of the superior curved line of the occiput. It is formed by the palate processes of the superior maxillary and palate bones, the vomer, the pterygoid processes, under surface of the great wing, spinous processes, and part of the body of the sphenoid, the under surface of the squamous, mastoid, and petrous portions of the temporal, and the under surface of the occipital bone. The anterior part of the base of the skull is raised above the level of the rest of this surface (when the skull is turned over for the purpose of examination), surrounded by the alveolar process, which is thicker behind than in front, and excavated by sixteen depressions for lodging the teeth of the upper jaw, the cavities varying in depth and size according to the teeth they contain. Immediately behind the incisor teeth is the *anterior palatine fossa*. At the bottom of this fossa may usually be seen four apertures: two placed laterally—the *foramina of Stenson*, which open above, one in the floor of each nostril, and transmit the anterior branch of the posterior palatine vessels; and two in the median line in the intermaxillary suture—the *foramina of Scarpa*, one in front of the other, the anterior transmitting the left, and the posterior (the larger) the right, naso-palatine nerve. These two latter canals are sometimes wanting, or they may join to form a single one, or one of them may open into one of the lateral canals above referred to. The palatine vault is concave, uneven, perforated by numerous foramina, marked by depressions for the palatine glands, and crossed by a crucial suture formed by the junction of the four bones of which it is composed. One or two small foramina in the alveolar margin behind the incisor teeth, occasionally seen in the adult, almost constant in young subjects, are called the *incisive foramina;* they transmit nerves and vessels to the incisor teeth. At each posterior angle of the hard palate is the *posterior palatine foramen*, for the transmission of the posterior palatine vessels and descending palatine nerves, and running forward and inward from it a groove for the posterior palatine vessels and anterior palatine nerve. Behind the posterior palatine foramen is the *tuberosity of the palate bone*, perforated by one or more accessory posterior palatine canals, and marked by the commencement of a ridge which runs transversely inward and serves for the attachment of the tendinous expansion of the Tensor palati muscle. Projecting backward from the centre of the posterior border of the hard palate is the *posterior nasal spine*, for the attachment of the Azygos uvulæ. Behind and above the hard palate is the posterior aperture of the nares, divided into two parts by the vomer, bounded above by the body of the sphenoid, below by the horizontal plate of the palate bone, and laterally by the pterygoid processes of the sphenoid. Each aperture measures about an inch in the vertical and half an inch in the transverse direction. At the base of the vomer may be seen the expanded alæ of this bone, receiving between them the rostrum of the sphenoid. Near the lateral margins of the vomer, at the root of the pterygoid processes, are the *pterygo-palatine canals*. The pterygoid process, which bounds the posterior nares on each side, presents near its base the *pterygoid* or *Vidian canal*, for the Vidian nerve and artery. Each process consists of two plates, which bifurcate at the extremity to receive the tuberosity of the palate bone, and are separated behind by the pterygoid fossa, which lodges the Internal pterygoid muscle.

FIG. 178.

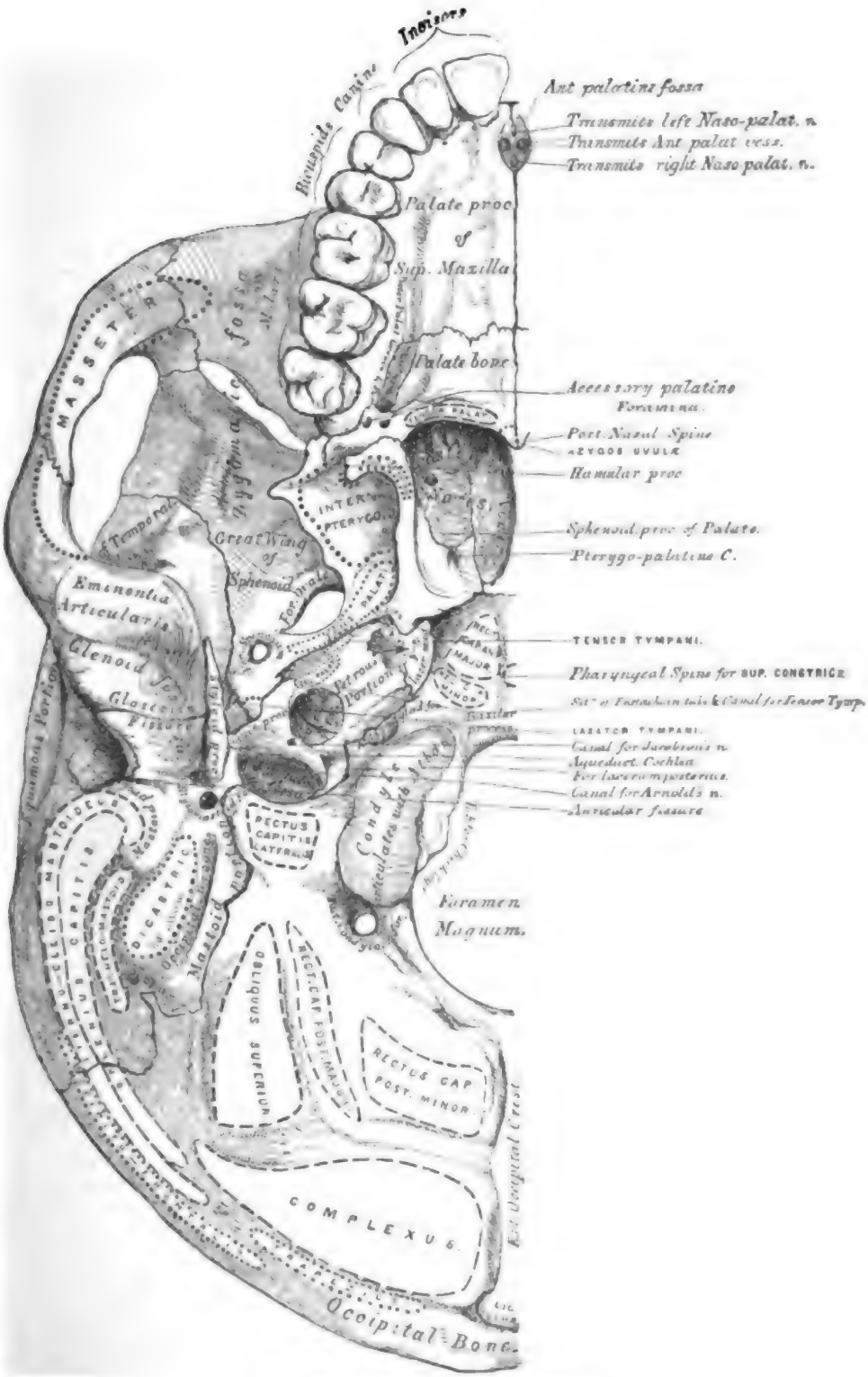
Incisors
Canine
Bicuspids
Ant palatine fossa
Transmits left Naso-palat. n.
Transmits Ant palat vess.
Transmits right Naso-palat. n.
Palate proc of Sup. Maxilla
Palate bone
MASSETER
fossa
Malar
Zygoma
Accessory palatine Foramina.
Post. Nasal Spine
AZYGOS UVULÆ
Hamular proc
Sphenoid. proc. of Palate.
Pterygo-palatine C.
Temporal
Great Wing of Sphenoid
INTERN. PTERYGOID
Nares
Eminentia Articularis
Glenoid fossa
Glaserian Fissure
For. ovale
Petrous Portion
Basilar process
TENSOR TYMPANI.
Pharyngeal Spine for SUP. CONSTRICT.
Sit. of Eustachian tube & Canal for Tensor Tymp.
LEVATOR TYMPANI.
Canal for Jacobson's n.
Aqueduct. Cochlea
For lacerum posterius.
Canal for Arnold's n.
Auricular fissure
Squamous Portion
RECTUS CAPITIS LATERALIS
Condyle
DIGASTRIC
Mastoid
Occipital
TRACHELO-MASTOID
STERNO-CLEIDO-MASTOID
SPLENIUS CAPITIS
Foramen Magnum.
OBLIQUUS SUPERIOR
RECT. CAP. POST. MAJOR
RECTUS CAP. POST. MINOR
COMPLEXUS
Ext. Occipital Crest
Occipital Bone.

Base of the Skull, external surface.

The internal plate is long and narrow, presenting on the outer side of its base the *scaphoid fossa*, for the origin of the Tensor palati muscle, and at its extremity the *hamular process*, around which the tendon of this muscle turns. The external pterygoid plate is broad, forms the inner boundary of the zygomatic fossa, and affords attachment by its outer surface to the External pterygoid muscle.

Behind the nasal fossæ in the middle line is the basilar surface of the occipital bone, presenting in its centre the *pharyngeal spine*, for the attachment of the Superior constrictor muscle of the pharynx, with depressions on each side for the insertion of the Rectus capitis anticus, major and minor. At the base of the external pterygoid plate is the *foramen ovale;* behind this, the *foramen spinosum* and the prominent spinous process of the sphenoid, which gives attachment to the internal lateral ligament of the lower jaw and the Laxator tympani and Tensor palati muscles. External to the spinous process is the *glenoid fossa*, divided into two parts by the Glaserian fissure (p. 171), the anterior portion concave, smooth, bounded in front by the eminentia articularis, and serving for the articulation of the condyle of the lower jaw; the posterior portion rough, bounded behind by the vaginal process, and serving for the reception of part of the parotid gland. Emerging from between the laminæ of the vaginal process is the *styloid process*, and at the base of this process is the *stylo-mastoid foramen*, for the exit of the facial nerve and entrance of the stylo-mastoid artery. External to the stylo-mastoid foramen is the *auricular fissure*, for the auricular branch of the pneumogastric, bounded behind by the mastoid process. Upon the inner side of the mastoid process is a deep groove, the *digastric fossa*, and a little more internally the *occipital groove*, for the occipital artery. At the base of the internal pterygoid plate is a large and somewhat triangular aperture, the *foramen lacerum medium*, bounded in front by the great wing of the sphenoid, behind by the apex of the petrous portion of the temporal bone, and internally by the body of the sphenoid and basilar process of the occipital bone: it presents in front the posterior orifice of the Vidian canal; behind, the aperture of the carotid canal. The basilar surface of this opening is filled up in the recent state by a fibro-cartilaginous substance; across its upper or cerebral aspect pass the internal carotid artery and Vidian nerve. External to this aperture the *petro-sphenoidal suture* is observed, at the outer termination of which are seen the orifice of the canal for the Eustachian tube and that for the Tensor tympani muscle. Behind this suture is seen the under surface of the petrous portion of the temporal bone, presenting, from within outward, the quadrilateral rough surface, part of which affords attachment to the Levator palati and Tensor tympani muscles; external to this surface the orifices of the carotid canal and the aquæductus cochleæ, the former transmitting the internal carotid artery and the ascending branches of the superior cervical ganglion of the sympathetic, the latter serving for the passage of a small artery and vein to the cochlea. Behind the carotid canal is a large aperture, the *jugular fossa*, formed in front by the petrous portion of the temporal, and behind by the occipital; it is generally larger on the right than on the left side, and is divided into three compartments by processes of dura mater. The anterior is for the passage of the inferior petrosal sinus; the posterior for the lateral sinus and some meningeal branches from the occipital and ascending pharyngeal arteries; the central one for the ninth, tenth, and eleventh cranial nerves. On the ridge of bone dividing the carotid canal from the jugular fossa is the small foramen for the transmission of Jacobson's nerve; and on the outer wall of the jugular foramen, near the root of the styloid process, is the small aperture for the transmission of Arnold's nerve. Behind the basilar surface of the occipital bone is the *foramen magnum*, bounded on each side by the condyles, rough internally for the attachment of the check ligaments, and presenting externally a rough surface, the jugular process, which serves for the attachment of the Rectus lateralis. On either side of each condyle anteriorly is the *anterior condyloid fossa*, perforated by the anterior condyloid foramen, for the passage of the hypoglossal nerve and a meningeal artery. Behind each condyle are the *posterior condyloid* fossæ, perforated on one or both sides by the posterior condyloid foramina, for the transmission of a vein to the lateral sinus. Behind the foramen magnum is the *external occipital crest*, terminating above at the *external occipital protuberance*, whilst on each side are seen the *superior and inferior curved lines:* these, as well as the surfaces of bone between them, are rough, for the attachment of the muscles, which are enumerated on p. 164.

Lateral Region of the Skull.

The **Lateral Region** of the skull is of a somewhat triangular form, the base of the triangle being formed by a line extending from the external angular process of the frontal bone, along the temporal ridge, backward to the outer extremity of the superior curved line of the occiput; and the sides by two lines, the one drawn downward and backward from the external angular process of the frontal bone to the angle of the lower jaw, the other from the angle of the jaw upward and backward to the extremity of the superior curved line. This region is divisible into three portions—temporal, mastoid, and zygomatic.

Fig. 179.

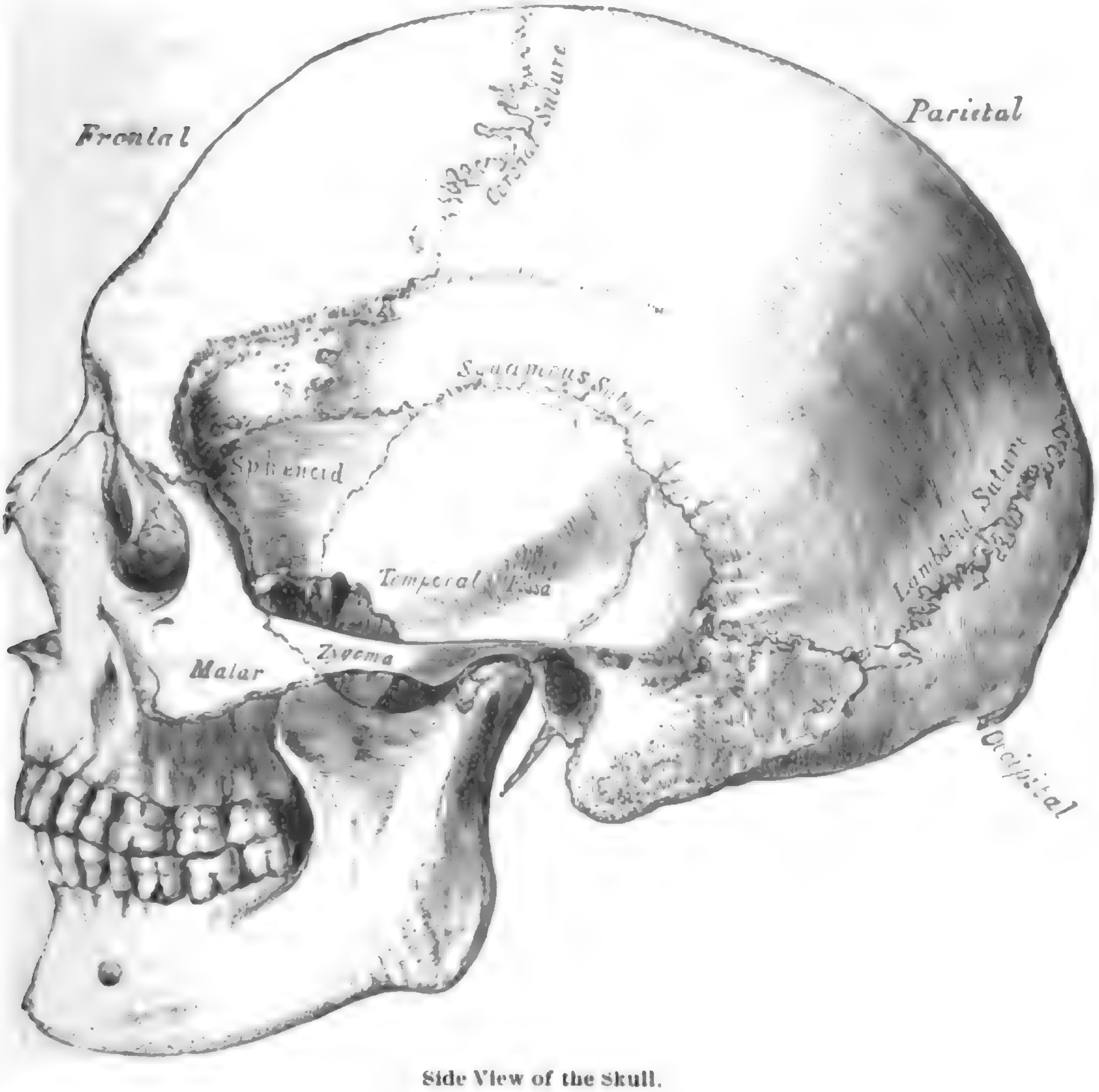

Side View of the Skull.

The Temporal Fossa.

The **Temporal** fossa is bounded above and behind by the temporal ridge, which extends from the external angular process of the frontal upward and backward across the frontal and parietal bones, curving downward behind to terminate in the posterior root of the zygomatic process. In front it is bounded by the frontal, malar, and great wing of the sphenoid; externally, by the zygomatic arch, formed conjointly by the malar and temporal bones; below, it is separated from the zygomatic fossa by the pterygoid ridge, seen on the outer surface of the great wing of the sphenoid. This fossa is formed by five bones—part of the frontal, great wing of the sphenoid, parietal, squamous portion of the temporal, and malar bones; and is traversed by six sutures—the transverse facial, spheno-malar, coronal, spheno-parietal, squamo-parietal, and squamo-sphenoidal. It is deeply concave in front, convex behind, traversed by grooves which lodge branches of the deep temporal arteries, and filled by the Temporal muscles.

The **Mastoid Portion** of the side of the skull is bounded in front by the anterior root of the zygoma; above, by a line which runs from the posterior root of the zygoma to the end of the masto-parietal suture; behind and below, by the masto-occipital suture. It is formed by the mastoid and part of the squamous and petrous portions of the temporal bone; its surface is convex and rough for the attachment of muscles, and presents, from behind forward, the mastoid foramen, the mastoid process, the external auditory meatus, surrounded by the auditory process; and, most anteriorly, the glenoid fossa, bounded in front by the eminentia articularis, behind by the vaginal process.

THE ZYGOMATIC FOSSA.

The **Zygomatic** fossa is an irregularly-shaped cavity situated below and on the inner side of the zygoma, bounded in front by the tuberosity of the superior maxillary bone and the ridge which descends from its malar process; behind, by the posterior border of the pterygoid process and the eminentia articularis; above, by the pterygoid ridge on the outer surface of the great wing of the sphenoid and squamous portion of the temporal; below, by the alveolar border of the superior maxilla; internally, by the external pterygoid plate; and externally, by the zygomatic arch and ramus of the lower jaw. It contains the lower part of the Temporal, the External, and Internal pterygoid muscles, the internal maxillary artery and inferior maxillary nerve, and their branches. At its upper and inner part may be observed two fissures, the spheno-maxillary and pterygo-maxillary.

The **Spheno-maxillary** fissure, horizontal in direction, opens into the outer and back part of the orbit. It is formed above by the lower border of the orbital surface of the great wing of the sphenoid; below, by the external border of the orbital surface of the superior maxilla and a small part of the palate bone; externally, by a small part of the malar bone;[1] internally it joins at right angles with the pterygo-maxillary fissure. This fissure opens a communication from the orbit into three fossæ—the temporal, zygomatic, and spheno-maxillary; it transmits the superior maxillary nerve and its orbital branch, the infraorbital artery, and ascending branches from Meckel's ganglion.

The **Pterygo-maxillary** fissure is vertical, and descends at right angles from the inner extremity of the preceding; it is an elongated interval formed by the divergence of the superior maxillary bone from the pterygoid process of the sphenoid. It serves to connect the spheno-maxillary fossa with the zygomatic, and transmits branches of the internal maxillary artery. It forms the entrance from the zygomatic fossa to

THE SPHENO-MAXILLARY FOSSA.

The **Spheno-maxillary** fossa is a small triangular space situated at the angle of junction of the spheno-maxillary and pterygo-maxillary fissures, and placed beneath the apex of the orbit. It is formed above by the under surface of the body of the sphenoid and by the orbital plate of the palate bone; in front by the superior maxillary bone; behind, by the anterior surface of the base of the pterygoid process of the sphenoid; internally, by the vertical plate of the palate. This fossa has three fissures terminating in it—the *sphenoidal*, *spheno-maxillary*, and *pterygo-maxillary*; it communicates with three fossæ—the *orbital*, *nasal*, and *zygomatic*—and with the cavity of the cranium, and has opening into it five foramina. Of these there are three on the posterior wall: the *foramen rotundum* above; below, and internal to this, the *Vidian*; and, still more inferior and internal, the *pterygo-palatine*. On the inner wall is the *spheno-palatine foramen*, by which the spheno-maxillary communicates with the nasal fossa, and below is the superior orifice of the *posterior palatine canal*, besides occasionally the orifices of two or three *accessory posterior palatine* canals. The fossa contains the superior maxillary nerve and Meckel's ganglion and the termination of the internal maxillary artery.

---

[1] Occasionally the superior maxillary bone and the sphenoid articulate with each other at the anterior extremity of this fissure; the malar is then excluded from entering into its formation.

ANTERIOR REGION OF THE SKULL.

The **Anterior Region** of the skull, which forms the face, is of an oval form, presents an irregular surface, and is excavated for the reception of the two principal organs of sense, the eye and the nose. It is bounded above by the nasal eminence and margins of the orbit; below, by the prominence of the chin; on each side, by the malar bone and anterior margin of the ramus of the jaw. In the median line is seen, from above downward, the *nasal eminence*, which indicates the situation of the frontal sinuses, and diverging from which are the *superciliary ridges*, which support the eyebrows. Beneath the nasal eminence is the arch of the nose, formed by the nasal bones and the nasal processes of the superior maxillary. The nasal arch is convex from side to side, concave from above downward, presenting in the median line the internasal suture formed between the nasal bones; laterally the naso-maxillary suture formed between the nasal bone and the nasal process of the superior maxillary bone, both these sutures terminating above in that part of the transverse suture which connects the nasal bones and nasal processes of the superior maxillary with the frontal. Below the nose is seen the opening of the anterior nares, which is heart-shaped, with the narrow end upward, and presents laterally the thin sharp margins serving for the attachment of the lateral cartilages of the nose; and in the middle line, below a prominent process, the *anterior nasal spine*, bounded by two deep notches. Below this is the *intermaxillary suture*, and on each side of it the *incisive fossa*. Beneath this fossa is the alveolar process of the upper and lower jaw, containing the incisor teeth, and at the lower part of the median line the *symphysis of the chin*, the *mental eminence*, and the *incisive fossa* of the lower jaw.

On each side, proceeding from above downward, is the *supraorbital ridge*, terminating externally in the external angular process at its junction with the malar, and internally in the internal angular process; toward the inner third of this ridge is the *supraorbital notch* or *foramen*, for the passage of the supraorbital vessels and nerve, and at its inner side a slight depression, for the attachment of the pulley of the Superior oblique muscle. Beneath the supraorbital ridge is the opening of the orbit, bounded externally by the orbital ridge of the malar bone; below, by the orbital ridge formed by the malar, superior maxillary, and lachrymal bones; internally, by the nasal process of the superior maxillary and the internal angular process of the frontal bone. On the outer side of the orbit is the quadrilateral anterior surface of the malar bone, perforated by one or two small malar foramina. Below the inferior margin of the orbit is the *infraorbital foramen*, the termination of the infraorbital canal; and beneath this the *canine fossa*, which gives attachment to the Levator anguli oris, bounded below by the alveolar processes, containing the teeth of the upper and lower jaw. Beneath the alveolar arch of the lower jaw is the *mental foramen* for the passage of the mental nerve and artery, the *external oblique line*; and at the lower border of the bone, at the point of junction of the body with the ramus, a shallow groove for the passage of the facial artery.

THE ORBITS.

The **Orbits** (Fig. 180) are two quadrilateral pyramidal cavities situated at the upper and anterior part of the face, their bases being directed forward and outward, and their apices backward and inward, so that the axes of the two, if continued backward, would meet over the body of the sphenoid bone. Each orbit is formed of *seven* bones—the frontal, sphenoid, ethmoid, superior maxillary, malar, lachrymal, and palate; but three of these, the frontal, ethmoid, and sphenoid, enter into the formation of *both* orbits, so that the two cavities are formed of *eleven* bones only. Each cavity presents for examination a roof, a floor, an inner and an outer wall, four angles, a circumference or base, and an apex. The **roof** is concave, directed downward and forward, and formed in front by the orbital plate of the frontal, behind by the lesser wing of the sphenoid. This surface presents internally the depression for the fibro-cartilaginous pulley of the Superior oblique muscle; externally, the depression for the lachrymal gland; and posteriorly, the suture connecting the frontal and lesser wing of the sphenoid.

FIG. 180.

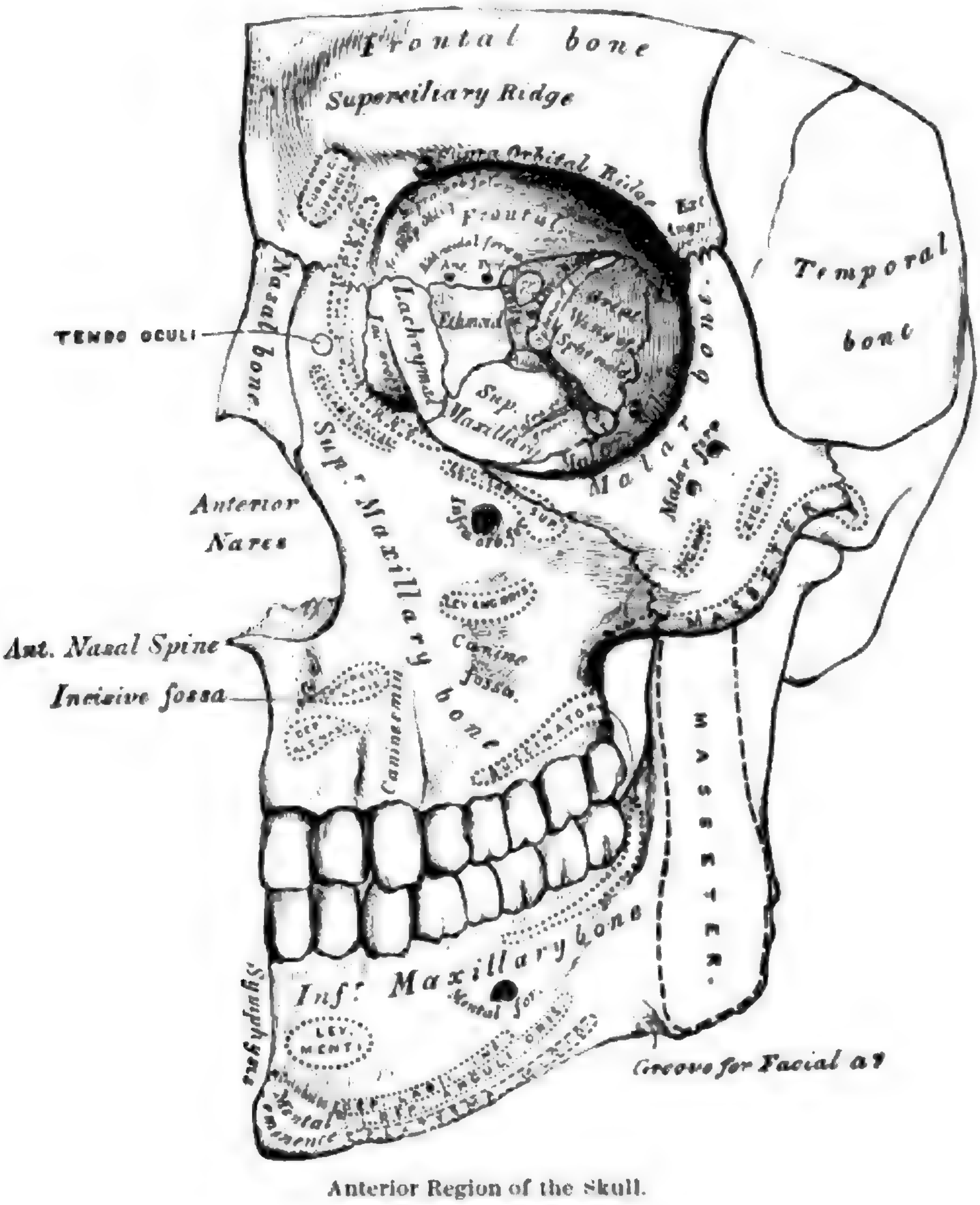
Frontal bone
Superciliary Ridge
Supra Orbital Ridge
Ext Angul
Temporal bone
Nasal bone
TENDO OCULI
Frontal
Lachrymal
Ethmoid
Sphenoid
Sup. Maxillary
Malar bone
Malar for.
Anterior Nares
Sup. Maxillary bone
Infraorb.
Canine fossa
Ant. Nasal Spine
Incisive fossa
MASSETER.
Inf. Maxillary bone
Mental for.
LEV. MENTI
Symphysis
Mental eminence
Groove for Facial a.t.

Anterior Region of the Skull.

The **floor** is nearly flat, and of less extent than the roof; it is formed chiefly by the orbital process of the superior maxillary; in front, to a small extent, by the orbital process of the malar, and behind by the orbital surface of the palate. This surface presents at its anterior and internal part, just external to the lachrymal canal, a depression for the attachment of the Inferior oblique muscle; externally, the suture between the malar and superior maxillary bones; near its middle, the infraorbital groove; and posteriorly, the suture between the maxillary and palate bones.

The **inner wall** is flattened, and formed from before backward by the nasal process of the superior maxillary, the lachrymal, os planum of the ethmoid, and a small part of the body of the sphenoid. This surface presents the lachrymal groove and crest of the lachrymal bone, and the sutures connecting the ethmoid with the lachrymal bone in front and the sphenoid behind.

The **outer wall** is formed in front by the orbital process of the malar bone; behind, by the orbital plate of the sphenoid. On it are seen the orifices of one or two malar canals and the suture connecting the sphenoid and malar bones.

Angles.—The *superior external angle* is formed by the junction of the upper and outer walls; it presents, from before backward, the suture connecting the frontal with the malar in front, and with the orbital plate of the greater wing of the sphenoid behind; quite posteriorly is the foramen lacerum anterius, or sphenoidal fissure, which transmits the third, fourth, the ophthalmic division of the fifth, and the sixth nerves, some filaments from the cavernous plexus of the sympathetic, the orbital branch of the middle meningeal artery, a recurrent branch from the lachrymal artery, and the ophthalmic vein. The *superior internal angle* is formed by the junction of the upper and inner wall, and presents the suture connecting the frontal bone with the lachrymal in front and with the ethmoid behind. This suture is perforated by two foramina, the anterior and posterior ethmoidal, the former transmitting the anterior ethmoidal vessels and nasal nerve, the latter the posterior ethmoidal artery and vein. The *inferior external angle*, formed by the junction of the outer wall and floor, presents the spheno-maxillary fissure, which transmits the infraorbital vessels and superior maxillary nerve, the ascending branches from the sphenopalatine ganglion, and the orbital branch of the superior maxillary nerve. The *inferior internal angle* is formed by the union of the lachrymal and os planum of the ethmoid with the superior maxillary and palate bones. The *circumference* or base of the orbit, quadrilateral in form, is bounded above by the supraorbital arch; below, by the anterior border of the orbital plate of the malar, superior maxillary, and lachrymal bones; externally, by the external angular process of the frontal and the malar bones; internally, by the internal angular process of the frontal and the nasal process of the superior maxillary. The circumference is marked by three sutures—the fronto-maxillary internally, the fronto-malar externally, and the malo-maxillary below; it contributes to the formation of the lachrymal groove, and presents, above, the supraorbital notch (or foramen), for the passage of the supraorbital artery, veins, and nerve. The *apex*, situated at the back of the orbit, corresponds to the optic foramen, a short circular canal which transmits the optic nerve and ophthalmic artery. It will thus be seen that there are *nine* openings communicating with each orbit—viz. the optic foramen, foramen lacerum anterius, spheno-maxillary fissure, supraorbital foramen, infraorbital canal, anterior and posterior ethmoidal foramina, malar foramina, and lachrymal canal.

THE NASAL FOSSÆ.

The **Nasal Fossæ** are two large irregular cavities situated on either side of the middle line of the face, extending from the base of the cranium to the roof of the mouth, and separated from each other by a thin vertical septum. They communicate by two large apertures, the *anterior nares*, with the front of the face, and with the pharynx behind by the two *posterior nares*. These fossæ are much narrower above than below, and in the middle than at the anterior or posterior openings: their depth, which is considerable, is much greater in the middle than at either extremity. Each nasal fossa communicates with four sinuses—the frontal above, the sphenoidal behind, and the maxillary and ethmoidal on either side. Each fossa also communicates with four cavities: with the orbit by the lachrymal canal, with the mouth by the anterior palatine canal, with the cranium by the olfactory foramina, and with the spheno-maxillary fossa by the spheno-palatine foramen; and they occasionally communicate with each other by an aperture in the septum. The bones entering into their formation are fourteen in number: three of the cranium, the frontal, sphenoid, and ethmoid, and all the bones of the face, excepting the malar and lower jaw. Each cavity is bounded by a roof, a floor, an inner and an outer wall.

The **upper wall,** or **roof** (Fig. 181), is long, narrow, and concave from before backward; it is formed in front by the nasal bones and nasal spine of the frontal, which are directed downward and forward; in the middle, by the cribriform lamella of the ethmoid, which is horizontal; and behind, by the under surface of the body of the sphenoid and sphenoidal turbinated bones, which are directed downward and backward. This surface presents, from before backward, the internal aspect of the nasal bones; on their outer side, the suture formed between the nasal bone and the nasal process of the superior maxillary; on their inner side, the elevated crest which receives the nasal spine of the frontal and the perpendicular plate of the ethmoid, and articulates with its fellow of the opposite side; whilst the surface of the bones is perforated by a few small vascular apertures and presents the longitudinal groove for the nasal nerve: farther back is the transverse suture, connecting the frontal with the nasal in front and the ethmoid behind, the olfactory foramina and nasal slit on the under surface of the cribriform plate, and the suture between it and the sphenoid behind: quite posteriorly are seen the sphenoidal turbinated bones, the orifices of the sphenoidal sinuses, and the articulation of the alæ of the vomer with the under surface of the body of the sphenoid.

FIG. 181.

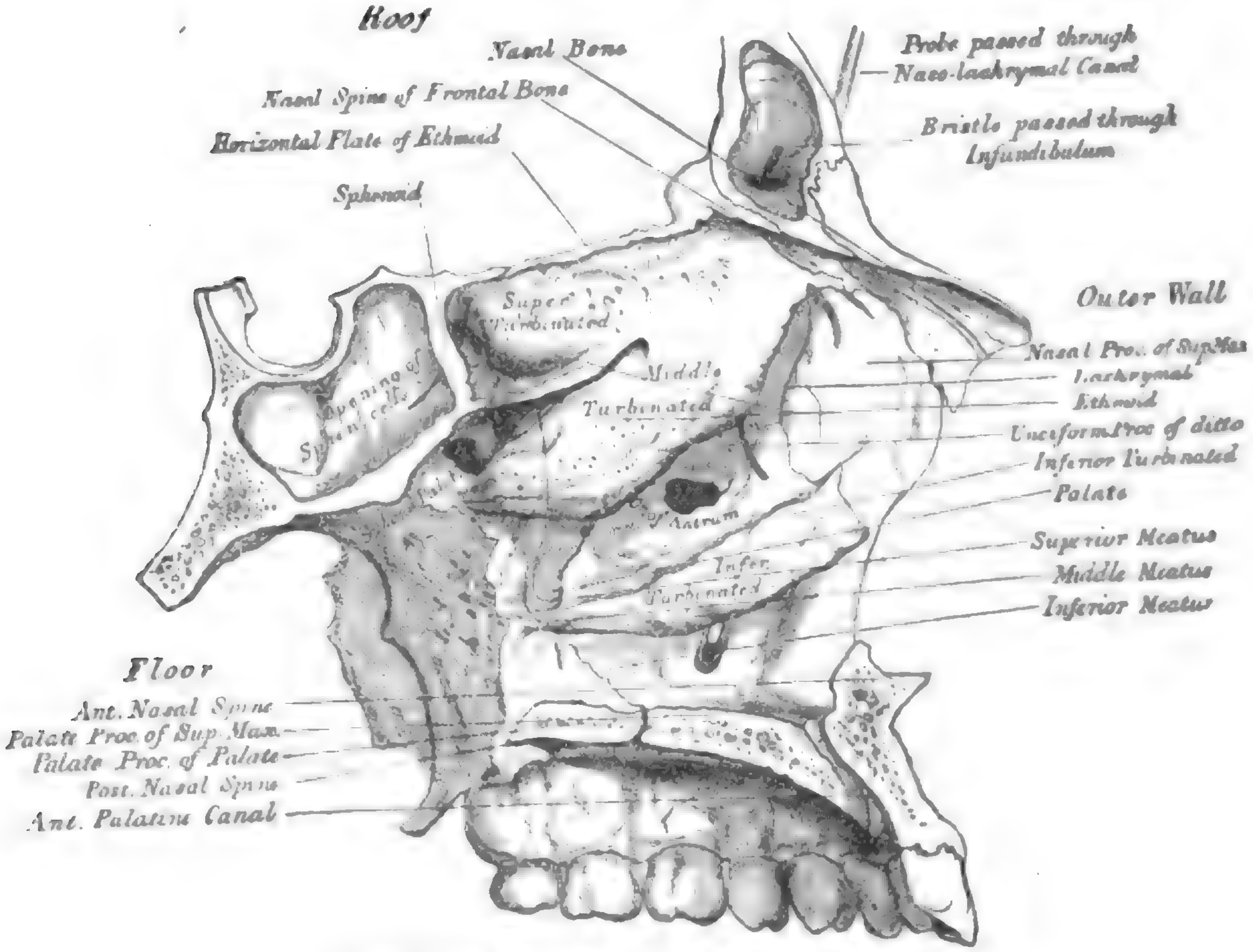
Roof
Nasal Bone
Nasal Spine of Frontal Bone
Horizontal Plate of Ethmoid
Sphenoid
Probe passed through
Naso-lachrymal Canal
Bristle passed through
Infundibulum
Outer Wall
Nasal Proc. of Sup. Max.
Lachrymal
Ethmoid
Unciform Proc. of ditto
Inferior Turbinated
Palate
Superior Meatus
Middle Meatus
Inferior Meatus
Super. Turbinated
Middle Turbinated
Opening of Sphen. cells
of Antrum
Infer. Turbinated
Floor
Ant. Nasal Spine
Palate Proc. of Sup. Max.
Palate Proc. of Palate
Post. Nasal Spine
Ant. Palatine Canal

Roof, Floor, and Outer Wall of Left Nasal Fossa.

The **floor** is flattened from before backward, concave from side to side, and wider in the middle than at either extremity. It is formed in front by the palate process of the superior maxillary; behind, by the palate process of the palate bone. The surface presents, from before backward, the anterior nasal spine; behind this, the upper orifices of the anterior palatine canal; internally, the elevated crest which articulates with the vomer; and behind, the suture between the palate and superior maxillary bones and the posterior nasal spine.

The **inner wall, or septum** (Fig. 182), is a thin vertical partition which separates the nasal fossæ from one another; it is occasionally perforated, so that the fossæ communicate, and it is frequently deflected considerably to one side.[1] It is formed in front by the crest of the nasal bones and nasal spine of the frontal; in the middle, by the perpendicular lamella of the ethmoid; behind, by the vomer and rostrum of the sphenoid; below, by the crest of the superior maxillary and palate bones. It presents in front a large triangular notch which receives the triangular cartilage of the nose; above, the lower orifices of the olfactory canals; and behind, the guttural edge of the vomer. Its surface is marked by numerous vascular and nervous canals and the groove for the naso-palatine nerve, and is traversed by sutures connecting the bones of which it is formed.

FIG. 182.

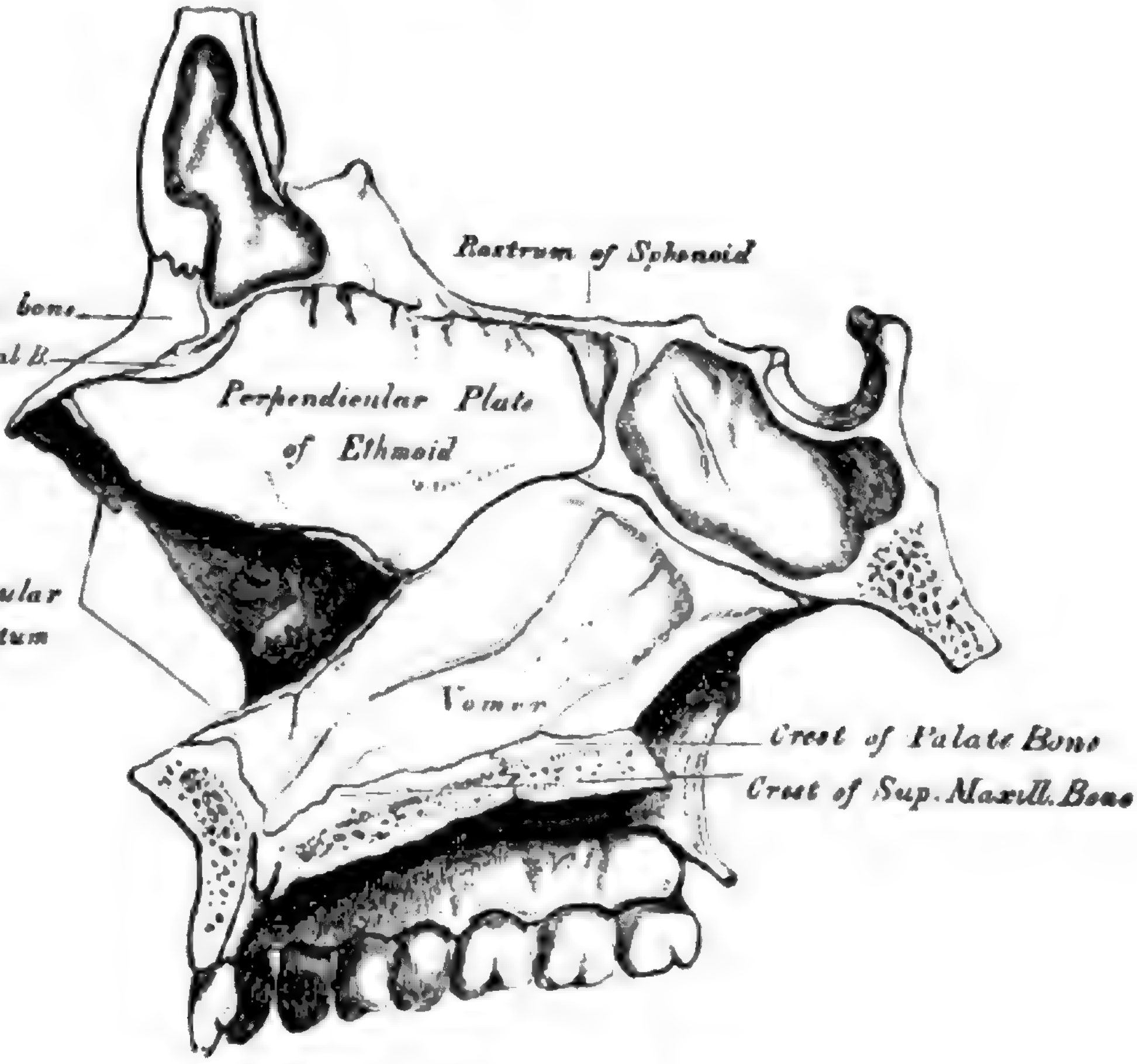
Rostrum of Sphenoid
Crest of Nasal bone
Nasal Spine of Frontal B.
Perpendicular Plate of Ethmoid
Space for Triangular Cartilage of Septum
Vomer
Crest of Palate Bone
Crest of Sup. Maxill. Bone

Inner Wall of Nasal Fossæ, or Septum of Nose.

The **outer wall** (Fig. 181) is formed in front by the nasal process of the superior maxillary and lachrymal bones; in the middle, by the ethmoid and inner surface of the superior maxillary and inferior turbinated bones; behind, by the vertical plate of the palate bone and the internal pterygoid plate of the sphenoid. This surface presents three irregular longitudinal passages, or *meatuses* [Figs. 181 and 183], formed between three horizontal plates of bone that spring from it; they are termed the superior, middle, and inferior meatuses of the nose. The *superior meatus*, the smallest of the three, is situated at the upper and back part of each nasal fossa, occupying the posterior third of the outer wall. It is situated between the superior and middle turbinated bones, and has opening into it two foramina—the *spheno-palatine* at the back of its outer wall, and the *posterior ethmoidal cells* at the front part of the upper wall. The opening of the sphenoidal sinuses is usually at the upper and back part of the nasal fossæ immediately behind the superior turbinated bone. The *middle meatus* is situated between the middle and inferior turbinated bones, and occupies the posterior two-thirds of the outer wall of the nasal fossa. It presents two apertures. In front is the orifice of the *infundibulum*, by which the middle meatus communicates with the anterior ethmoidal cells, and through these with the frontal sinuses. At the centre of the outer wall is the *orifice of the antrum*, which varies somewhat as to its exact position in different skulls. The *inferior meatus*, the largest of the three, is the space between the inferior turbinated bone and the floor of the nasal fossa. It extends along the entire length of the outer wall of the nose, is broader in front than behind, and presents anteriorly the lower *orifice of the lachrymal canal*.

---

[1] See foot note, p. 181.

[Fig. 183.

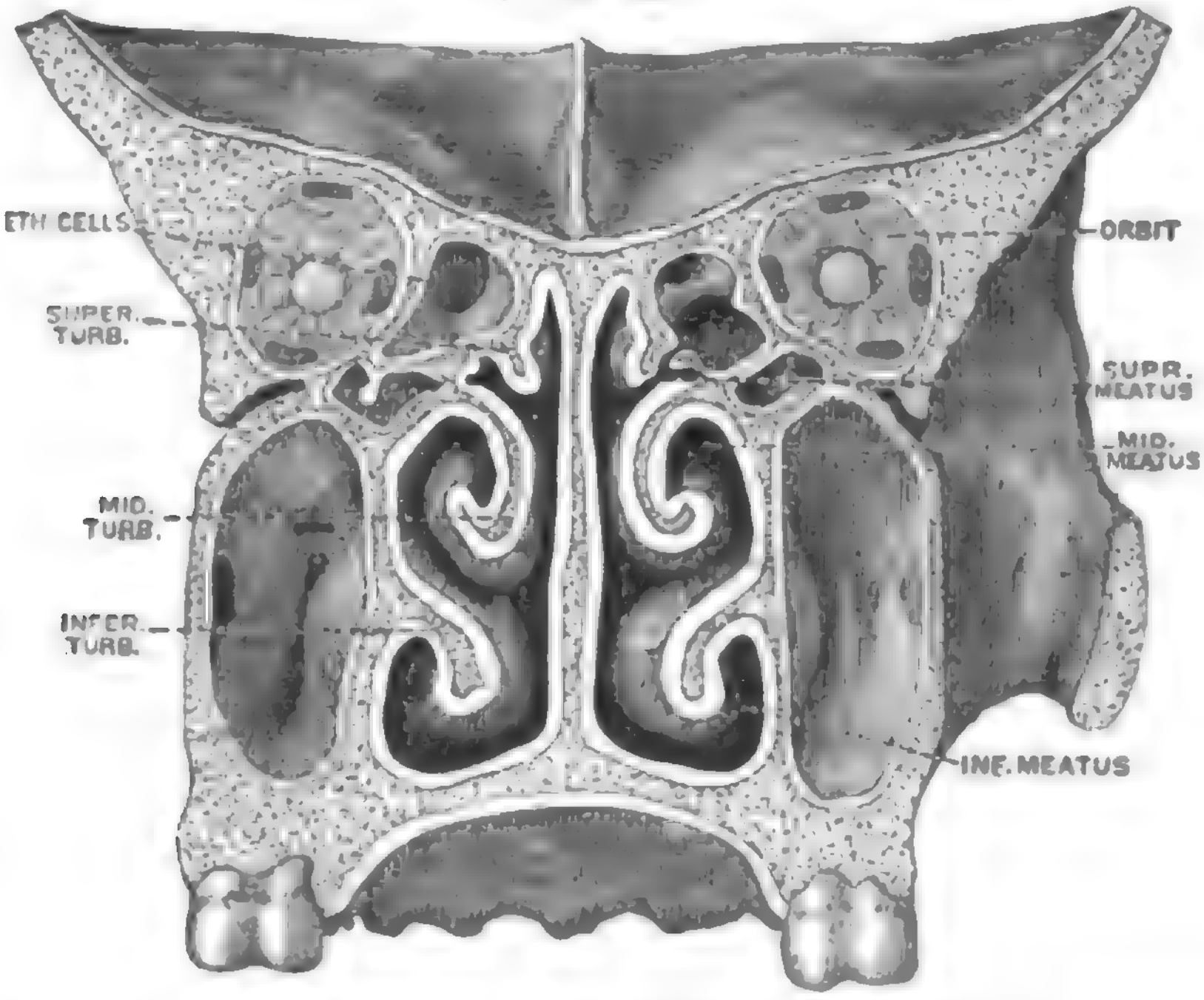

Transverse Vertical (*i.e.* coronal) **Section of the Nasal Fossæ at the plane of the second molar teeth, seen from behind** (Hirschfeldt).]

[Fig. 184.

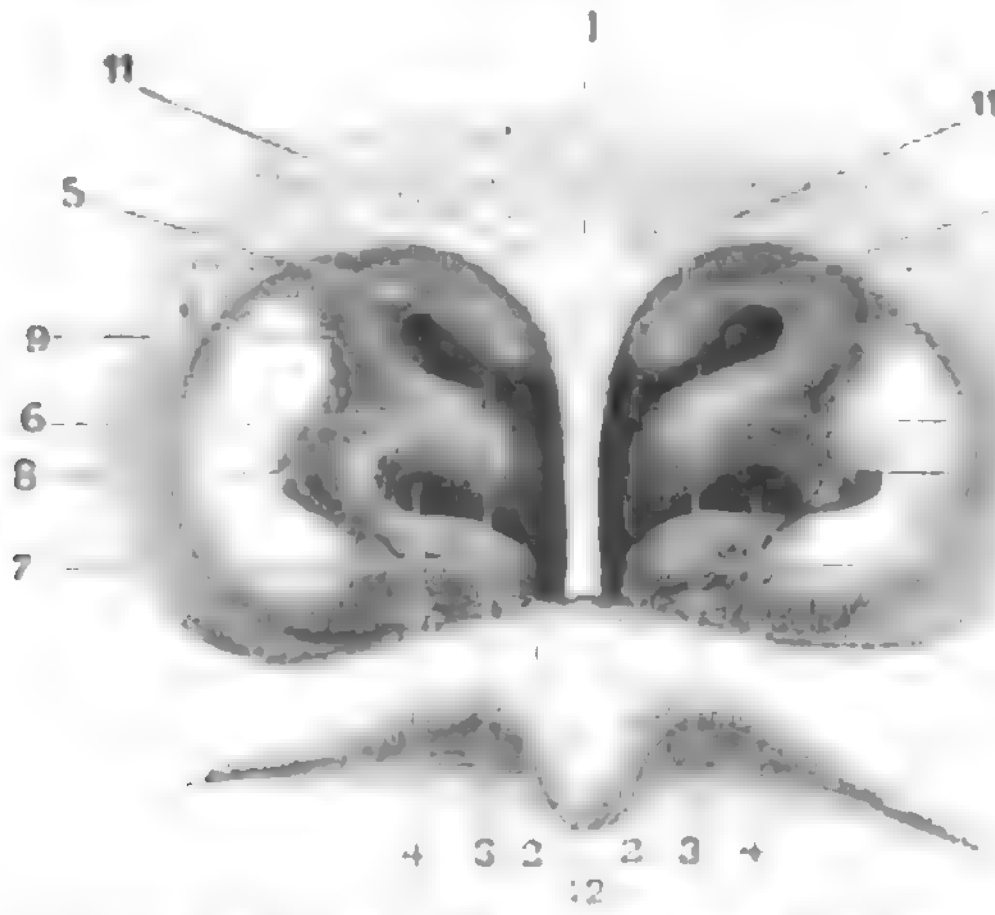

Rhinoscopic Image: 1, Vomer, or nasal septum; 2, floor of nose; 3, superior meatus; 4, middle meatus; 5, superior turbinated bone; 6, middle turbinated bone; 7, inferior turbinated bone; 8, pharyngeal orifice of Eustachian tube; 9, upper portion of Rosenmüller's groove; 11, Glandular tissue at the anterior portion of vault of pharynx; 12, uvula and posterior surface of velum (Seiler).]

[The *anterior nares* are the two pear-shaped openings of the nose on the face. By lifting the tip of the nose and dilating the opening, we can get a good view of the septum and the inferior turbinated bone. The anterior extremity of the middle turbinated can also be seen. Both of these are covered by the mucous membrane, which often becomes hypertrophied in nasal catarrh.

The *posterior nares* are the two oval openings of the nose posteriorly into the naso-pharynx. They are much smaller in the body than in the skull, since the mucous membrane narrows them. Fig. 184 shows them, together with the adjacent parts, as they are best examined in the living by the rhinoscopic mirror. Notice in this view of the posterior nares the opening of the Eustachian tube (8) and the parts about it. The picture is somewhat more distinct and extensive than we usually see it.

The posterior nares sometimes require to be plugged in hemorrhage from the nose by passing a string by means of a curved instrument, such as Bellocq's canula or a male catheter, through the inferior meatus, behind the soft palate and out through the mouth. A pledget of cotton is then attached to the end of the string passing through the mouth, and can be drawn into the posterior nares by the end through the nose.]

HYOID BONE.

The **Hyoid** bone is named from its resemblance to the Greek *upsilon;* it is also called the *lingual bone*, because it supports the tongue and gives attachment to its numerous muscles. It is a bony arch shaped like a horseshoe, and consisting of five segments—a body, two greater cornua, and two lesser cornua. It is suspended from the tip of the styloid processes of the temporal bones by ligamentous bands, the *stylo-hyoid* ligaments.

The **body** (*basihyal*) forms the central part of the bone, and is of a quadrilateral form: its *anterior surface* (Fig. 185), convex, directed forward and upward, is divided into two parts by a vertical ridge which descends along the median line and is crossed at right angles by a horizontal ridge, so that this surface is divided into four muscular depressions. At the point of meeting of these two lines is a prominent elevation, the *tubercle*. The portion above the horizontal ridge is directed upward, and is sometimes described as the superior border. The anterior surface gives attachment to the Genio-hyoid in the greater part of its extent; above, to the Genio-hyo-glossus; below, to the Mylo-hyoid, Stylo-hyoid, and aponeurosis of the Digastric (suprahyoid aponeurosis); and between these to part of the Hyo-glossus. The *posterior surface* is smooth, concave, directed backward and downward, and separated from the epiglottis by the thyro-hyoid membrane and by a quantity of loose areolar tissue. The *superior border* is rounded, and gives attachment to the thyro-hyoid membrane and part of the Genio-hyo-glossi muscles. The *inferior border* gives attachment, in front, to the Sterno-hyoid; behind, to part of the Thyro-hyoid; and to the Omo-hyoid at its junction with the great cornu. The *lateral surfaces* are small, oval, convex facets, covered with cartilage for articulation with the greater cornua.

FIG. 185.

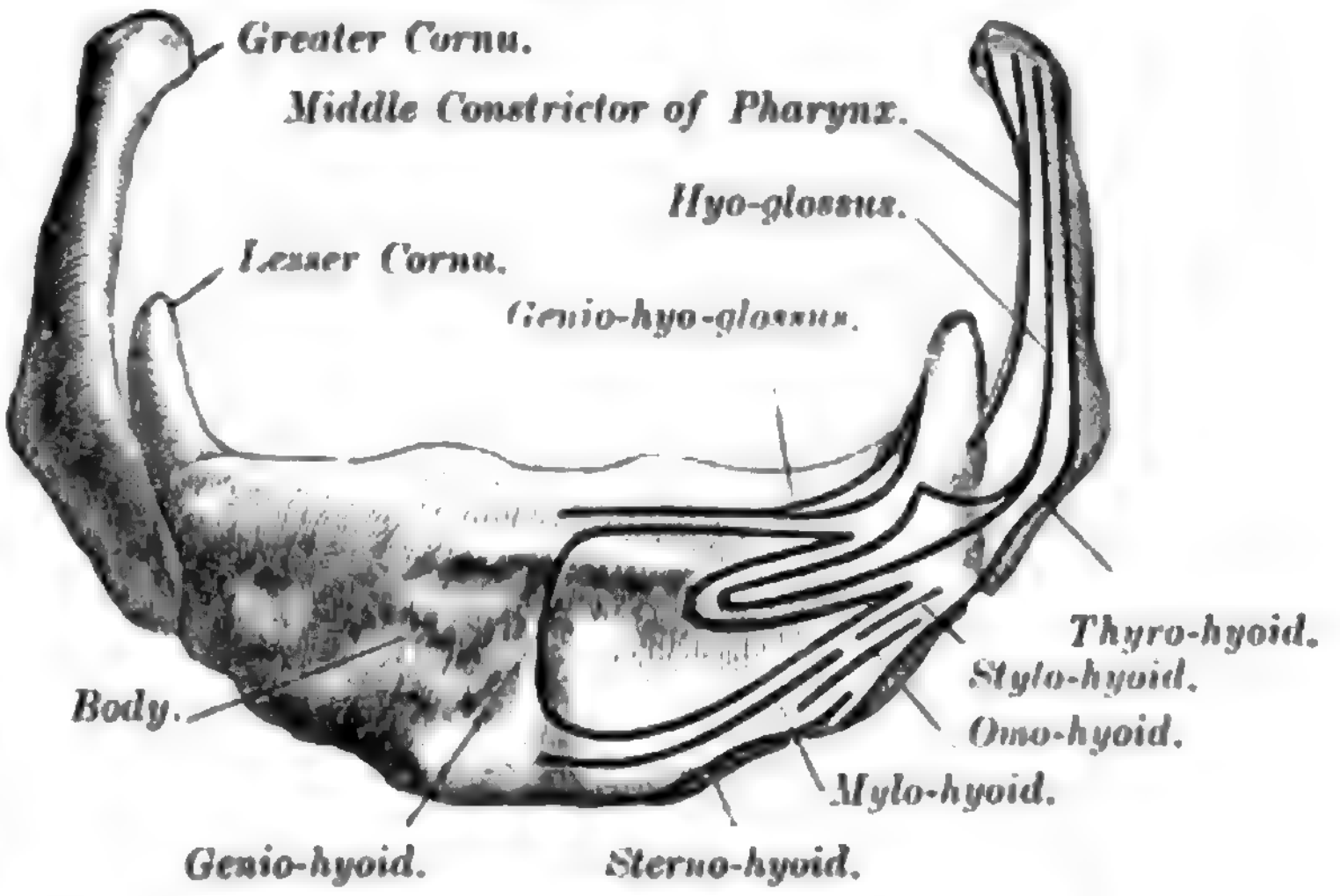

Hyoid Bone, anterior surface (enlarged).

The **Greater Cornua** (*thyro-hyals*) project backward from the lateral surfaces of the body; they are flattened from above downward, diminish in size from before backward, and terminate posteriorly in a tubercle for the attachment of the thyro-hyoid ligament. Their outer surface gives attachment to the Hyo-glossus; their upper border, to the Middle constrictor of the pharynx; their lower border, to part of the Thyro-hyoid muscle.

The **Lesser Cornua** (*cerato-hyals*) are two small conical-shaped eminences attached by their bases to the angles of junction between the body and greater cornua, and giving attachment by their apices to the stylo-hyoid ligaments.[1] In youth the great cornua are connected to the body by cartilaginous surfaces and held together by ligaments; in middle life they usually become joined. The smaller cornua are connected to the body of the bone by a distinct diarthrodial joint, which usually persists throughout life, but occasionally becomes ankylosed.

Development.—By *five* centres: one for the body and one for each cornu. Ossification commences in the body and greater cornua toward the end of fœtal life, those of the cornua first appearing. Ossification at the lesser cornua commences some months after birth.

Attachment of Muscles.—Sterno-hyoid, Thyro-hyoid, Omo-hyoid, aponeurosis of the Digastricus, Stylo-hyoid, Mylo-hyoid, Genio-hyoid, Genio-hyo-glossus, Hyoglossus, Middle constrictor of the pharynx, and occasionally a few fibres of the Lingualis. It also gives attachment to the thyro-hyoidean membrane and the stylo-hyoid, thyro-hyoid, and hyo-epiglottic ligaments.

THE THORAX.

The **Thorax, or Chest,** is an osseo-cartilaginous cage intended to contain and protect the principal organs of respiration and circulation. It is conical in shape, flattened from before backward, and longer behind than in front. It is constructed in all vertebrate animals on the same type, consisting of a sternum in front, a part of the vertebral column behind, and the ribs on either side. All these parts are not, however, invariably present, and in man the anterior parts of the ribs are replaced by the costal cartilages. In the human thorax the transverse diameter exceeds the antero-posterior one, the cavity being spread out laterally, but in the lower orders of mammals the converse is the case, the antero-posterior exceeding the lateral diameter. The *posterior* surface of the thorax is formed by the twelve dorsal vertebræ and the posterior part of the ribs. It is convex from above downward, and presents on either side of the middle line a deep groove in consequence of the direction forward and inward which the ribs take from their angles to their vertebral extremities. The *anterior* surface is flattened, slightly convex, and inclined forward from above downward. It is formed by the sternum and costal cartilages. The *lateral* surfaces are convex; they are formed by the ribs, separated from one another by spaces, the *intercostal spaces*. These are eleven in number, and are occupied by the intercostal muscles. The *upper opening* of the thorax is reniform in shape, formed by the first dorsal vertebra behind, the upper margin of the sternum in front, and the first rib on either side. It slopes downward and forward, so that the anterior part of the ring is on a lower level than the posterior. It also differs in the two sexes: the upper margin of the sternum in the male is on a level with the lower part of the body of the second dorsal vertebra, whereas in the female it is on a level with the lower part of the body of the third. The *lower* opening is formed by the twelfth dorsal vertebra behind, by the twelfth rib at the sides, and in front by the cartilages of the tenth, ninth, eighth, and seventh ribs, which ascend on either side and form an angle, the *subcostal angle*, from the centre of which the ensiform cartilage projects.

THE STERNUM.

The **Sternum** (*στέρνον*, the chest) (Figs. 186, 187) is a flat, narrow bone situated in the median line of the front of the chest, and consisting, in the adult, of three portions. It has been likened to an ancient sword: the upper piece, representing the handle, is termed the *manubrium;* the middle and largest piece, which represents the chief part of the blade, is termed the *gladiolus;* and the inferior

---

[1] These ligaments in many animals are distinct bones, and in man are occasionally ossified to a certain extent.

FIG. 186. Sternum and Costal Cartilages.

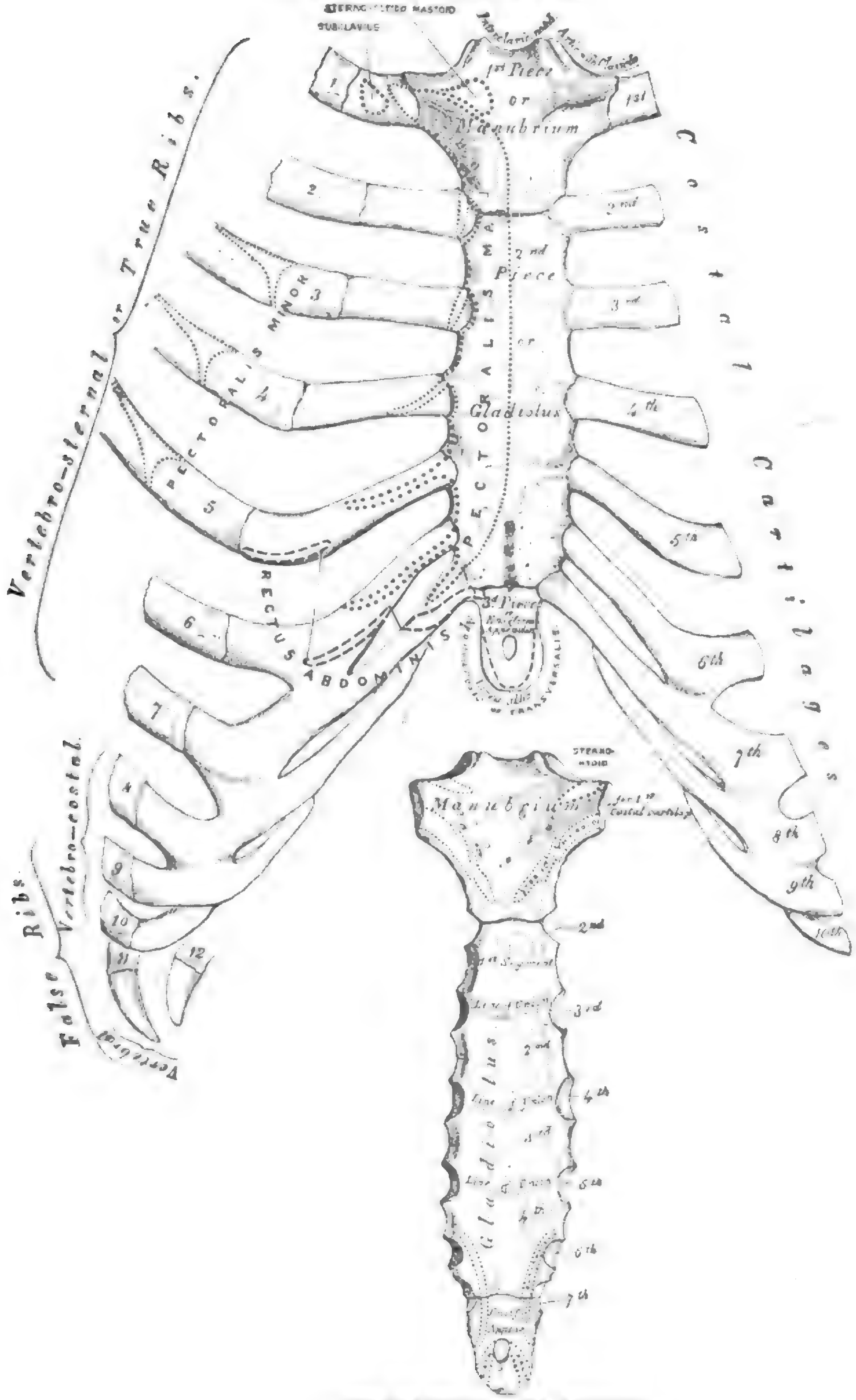
STERNO-CLEIDO MASTOID
SUBCLAVIUS
Interclavicular
1st Piece or Manubrium
1st
2nd
3rd
4th
5th
6th
7th
8th
9th
10th
2nd Piece or Gladiolus
3d Piece
Costal Cartilages
Vertebro-sternal or True Ribs
False Ribs
Vertebro-costal
Vertebral
PECTORALIS MINOR
PECTORALIS
PECTORALIS MAJOR
RECTUS ABDOMINIS
TRANSVERSALIS
1
2
3
4
5
6
7
8
9
10
11
12
STERNO-HYOID
Manubrium
Gladiolus
2nd
3rd
4th
5th
6th
7th

FIG. 187. Posterior Surface of Sternum.

piece, which is likened to the point of the sword, is termed the *ensiform* or *xiphoid appendix*. In its natural position its inclination is oblique from above downward and forward. It is flattened in front, concave behind, broad above, becoming narrowed at the point where the first and second pieces are connected; after which it again widens a little, and is pointed at its extremity. Its average length in the adult is six inches, being rather longer in the male than in the female. [Its three pieces form three planes, forming obtuse angles at their junctions. The line of junction of the first and second portions is always readily seen and felt, and is a guide to the cartilages of the second ribs.]

The **First Piece** of the sternum, or **Manubrium** (*presternum*), is of a somewhat triangular form, broad and thick above, narrow below at its junction with the middle piece. Its *anterior surface*, convex from side to side, concave from above downward, is smooth, and affords attachment on each side to the Pectoralis major and sternal origin of the Sterno-cleido-mastoid muscle. In well-marked bones the ridges limiting the attachment of these muscles are very distinct. Its *posterior surface*, concave and smooth, affords attachment on each side to the Sterno-hyoid and Sterno-thyroid muscles. The *superior border*, the thickest, presents at its centre the *interclavicular notch*, and on each side an oval articular surface, directed upward, backward, and outward, for articulation with the sternal end of the clavicle. The *inferior border* presents an oval rough surface, covered in the recent state with a thin layer of cartilage, for articulation with the second portion of the bone. The *lateral borders* are marked above by an articular depression for the first costal cartilage, and below by a small facet, which, with a similar facet on the upper angle of the middle portion of the bone, forms a notch for the reception of the costal cartilage of the second rib. These articular surfaces are separated by a narrow curved edge which slopes from above downward and inward. [The interclavicular notch and the sternal ends of the clavicles will well repay study in the living model.]

The **Second Piece** of the sternum, or **Gladiolus** (*mesosternum*), considerably longer, narrower, and thinner than the first piece, is broader below than above. Its *anterior surface* is nearly flat, directed upward and forward, and marked by three transverse lines which cross the bone opposite the third, fourth, and fifth articular depressions. These lines are produced by the union of the four separate pieces, of which this part of the bone consists at an early period of life. At the junction of the third and fourth pieces is occasionally seen an orifice, the *sternal foramen*; it varies in size and form in different individuals, and pierces the bone from before backward. This surface affords attachment on each side to the sternal origin of the Pectoralis major. The *posterior surface*, slightly concave, is also marked by three transverse lines, but they are less distinct than those in front: this surface affords attachment below, on each side, to the Triangularis sterni muscle, and occasionally presents the posterior opening of the sternal foramen. The *superior border* presents an oval surface for articulation with the manubrium. The *inferior border* is narrow and articulates with the ensiform appendix. Each *lateral border* presents at each superior angle a small facet, which, with a similar facet on the manubrium, forms a cavity for the cartilage of the second rib; the four succeeding angular depressions receive the cartilages of the third, fourth, fifth, and sixth ribs, while each inferior angle presents a small facet, which, with a corresponding one on the ensiform appendix, forms a notch for the cartilage of the seventh rib. These articular depressions are separated by a series of curved interarticular intervals, which diminish in length from above downward, and correspond to the intercostal spaces. Most of the cartilages belonging to the true ribs, as will be seen from the foregoing description, articulate with the sternum at the line of junction of two of its primitive component segments. This is well seen in many of the lower animals, where the separate parts of the bone remain ununited longer than in man. In this respect a striking analogy exists between the mode of connection of the ribs with the vertebral column and the connection of their cartilages with the sternal column.

The **Third Piece** of the sternum, the **Ensiform** or **Xiphoid Appendix** (*meta-*

sternum), is the smallest of the three; it is thin and elongated in form, cartilaginous in structure in youth, but more or less ossified at its upper part in the adult. Its *anterior surface* affords attachment to the costo-xiphoid ligament; its *posterior surface*, to some of the fibres of the Diaphragm and Triangularis sterni muscles; its *lateral borders*, to the aponeurosis of the abdominal muscles. Above, it is continuous with the lower end of the gladiolus; below, by its pointed extremity, it gives attachment to the linea alba, and at each superior angle presents a facet for the lower half of the cartilage of the seventh rib. This portion of the sternum is very various in appearance, being sometimes pointed, broad and thin, sometimes bifid or perforated by a round hole, occasionally curved or deflected considerably to one or the other side.

Structure.—The bone is composed of delicate cancellated texture, covered by a thin layer of compact tissue, which is thickest in the manubrium, between the articular facets for the clavicles.

Development.—The sternum, including the ensiform appendix, is developed by *six* centres; one for the first piece, or manubrium, four for the second piece, or gladiolus, and one for the ensiform appendix. Up to the middle of fœtal life the sternum is entirely cartilaginous, and when ossification takes place the ossific granules are deposited in the middle of the intervals between the articular depressions for the costal cartilages, in the following order (Fig. 186): In the first piece, between the fifth and sixth months; in the second and third, between the sixth and seventh months; in the

Fig. 188.

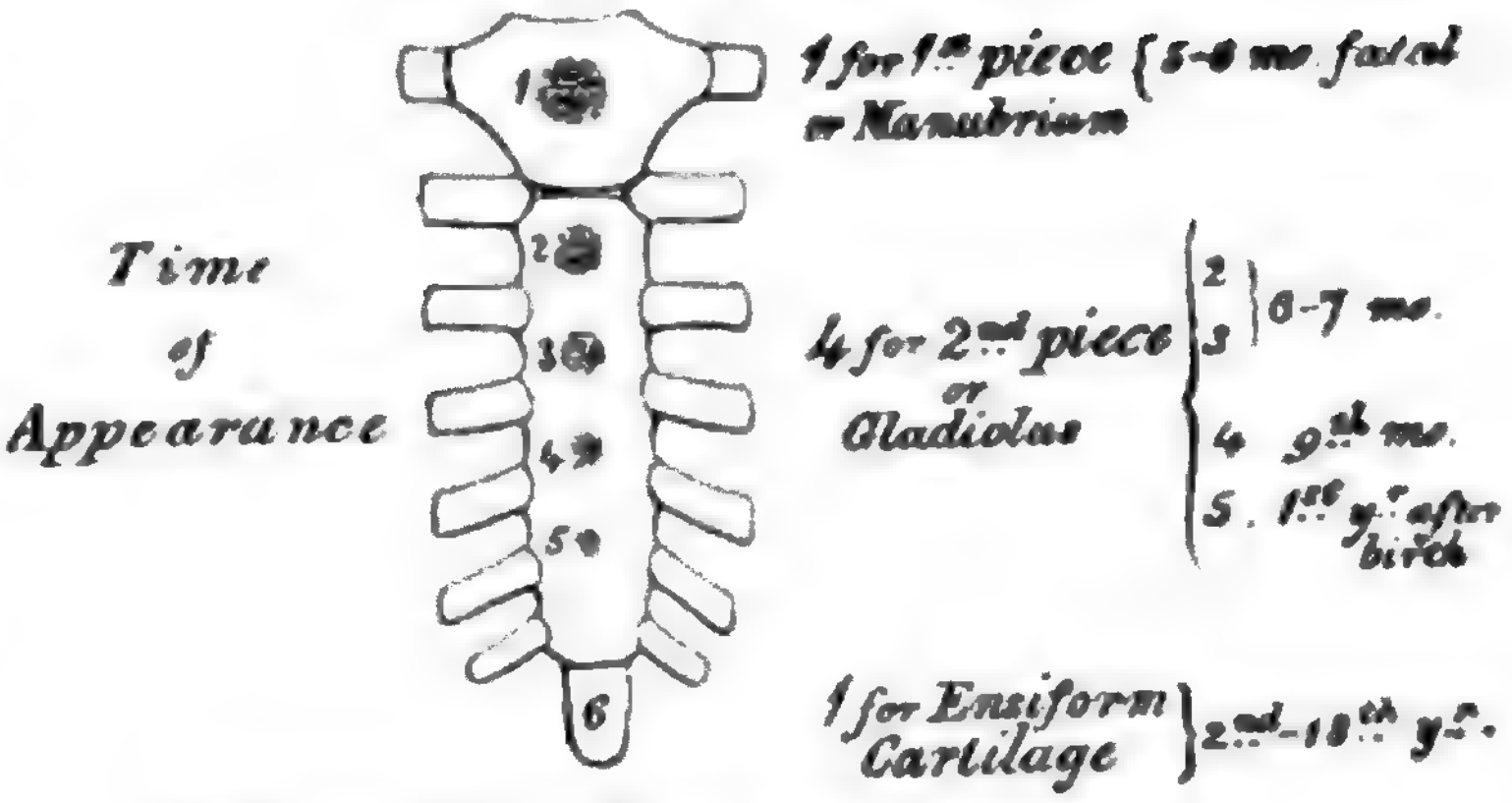
1 for 1st piece { 5-6 mo. fœtal
or Manubrium
Time of Appearance
1
2
3
4
5
6
4 for 2nd piece or Gladiolus
2
3 } 6-7 mo.
4 9th mo.
5. 1st yr. after birth
1 for Ensiform Cartilage } 2nd-18th yr.

Development of the Sternum, by six centres.

Fig. 189.

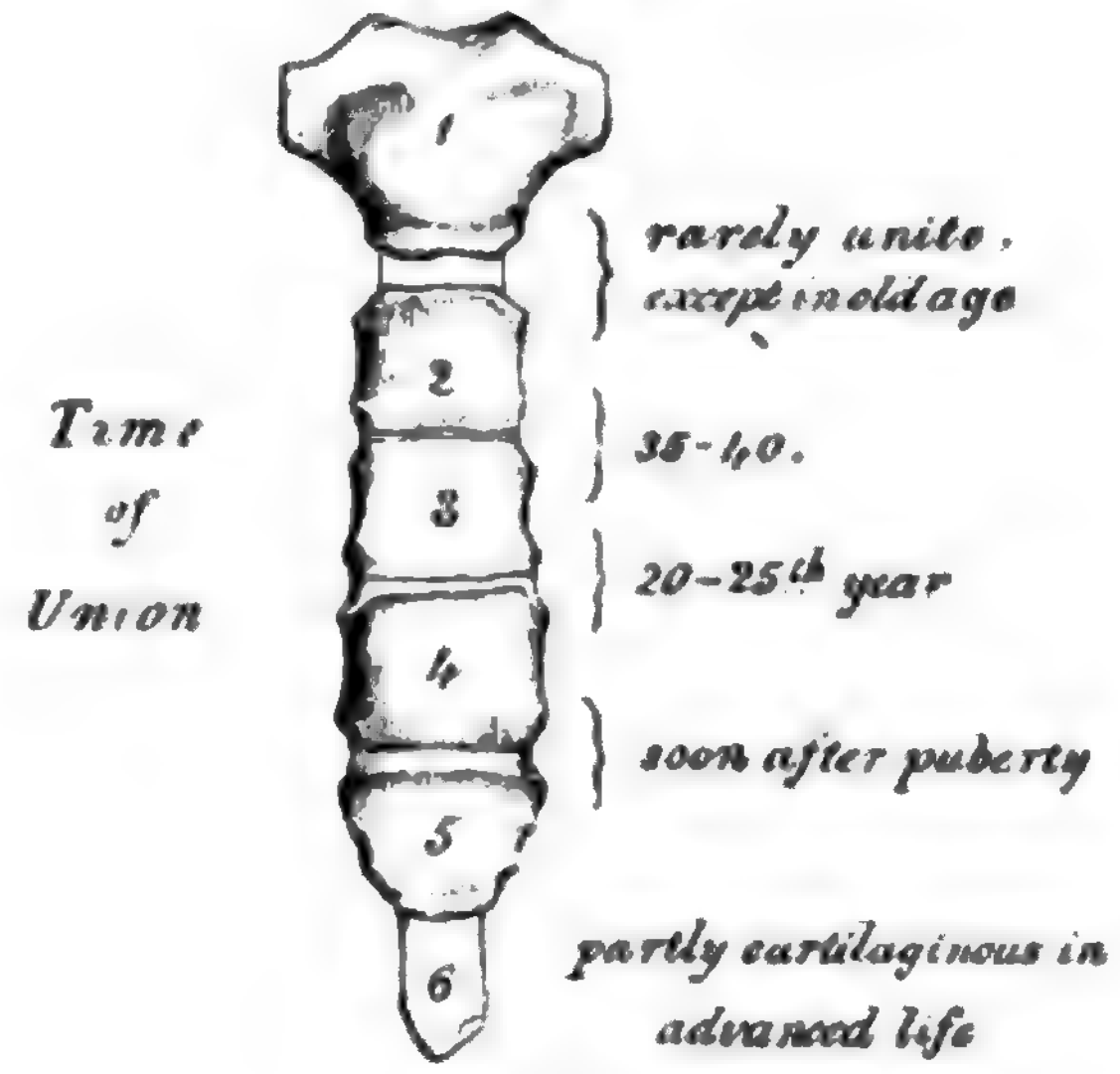
1
2
3
4
5
6
rarely unite, except in old age
Time of Union
35-40.
20-25th year
soon after puberty
partly cartilaginous in advanced life

Fig. 190.

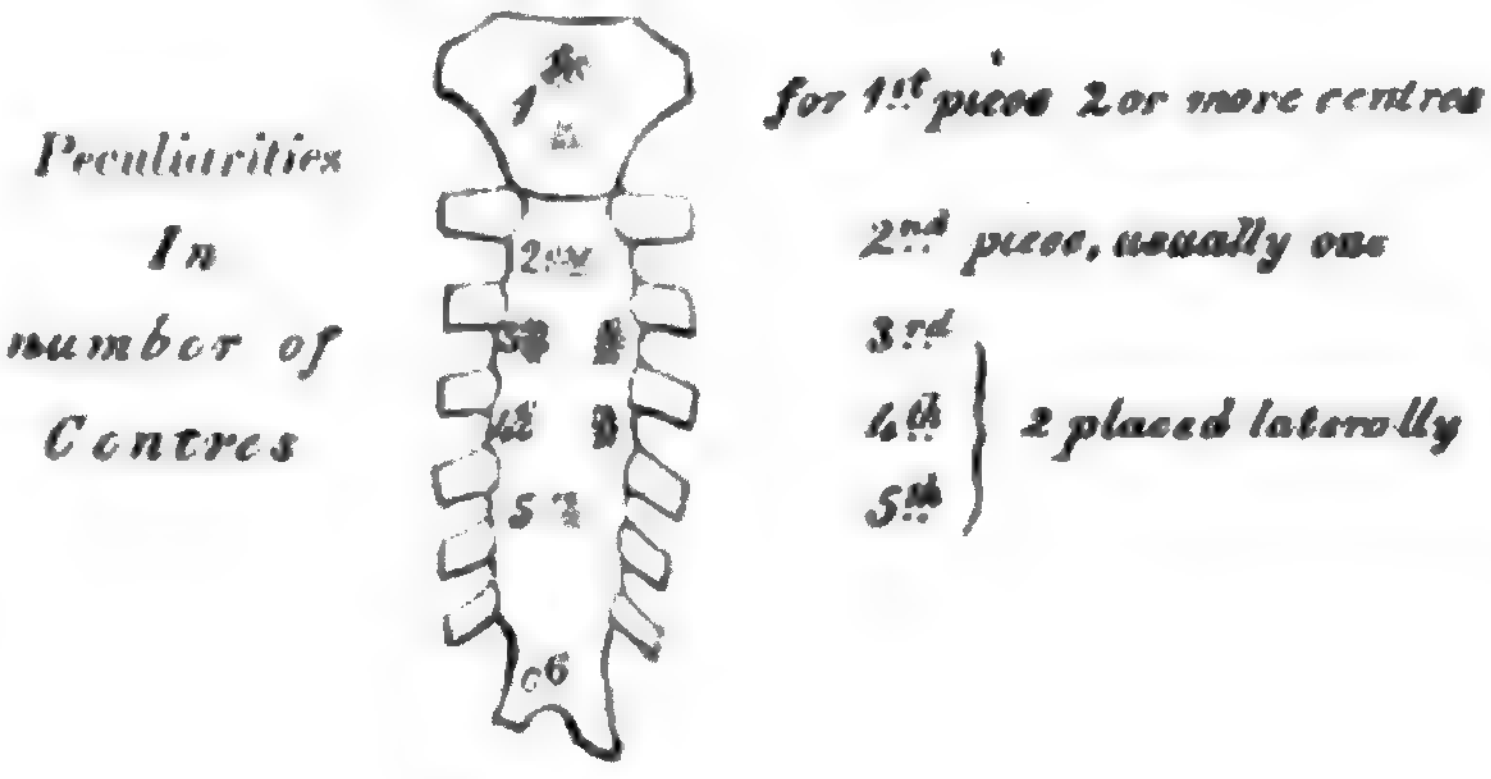
for 1st piece 2 or more centres
Peculiarities In number of Centres
2nd piece, usually one
3rd
4th
5th
2 placed laterally
1
2
3
4
5
6

Fig. 191.

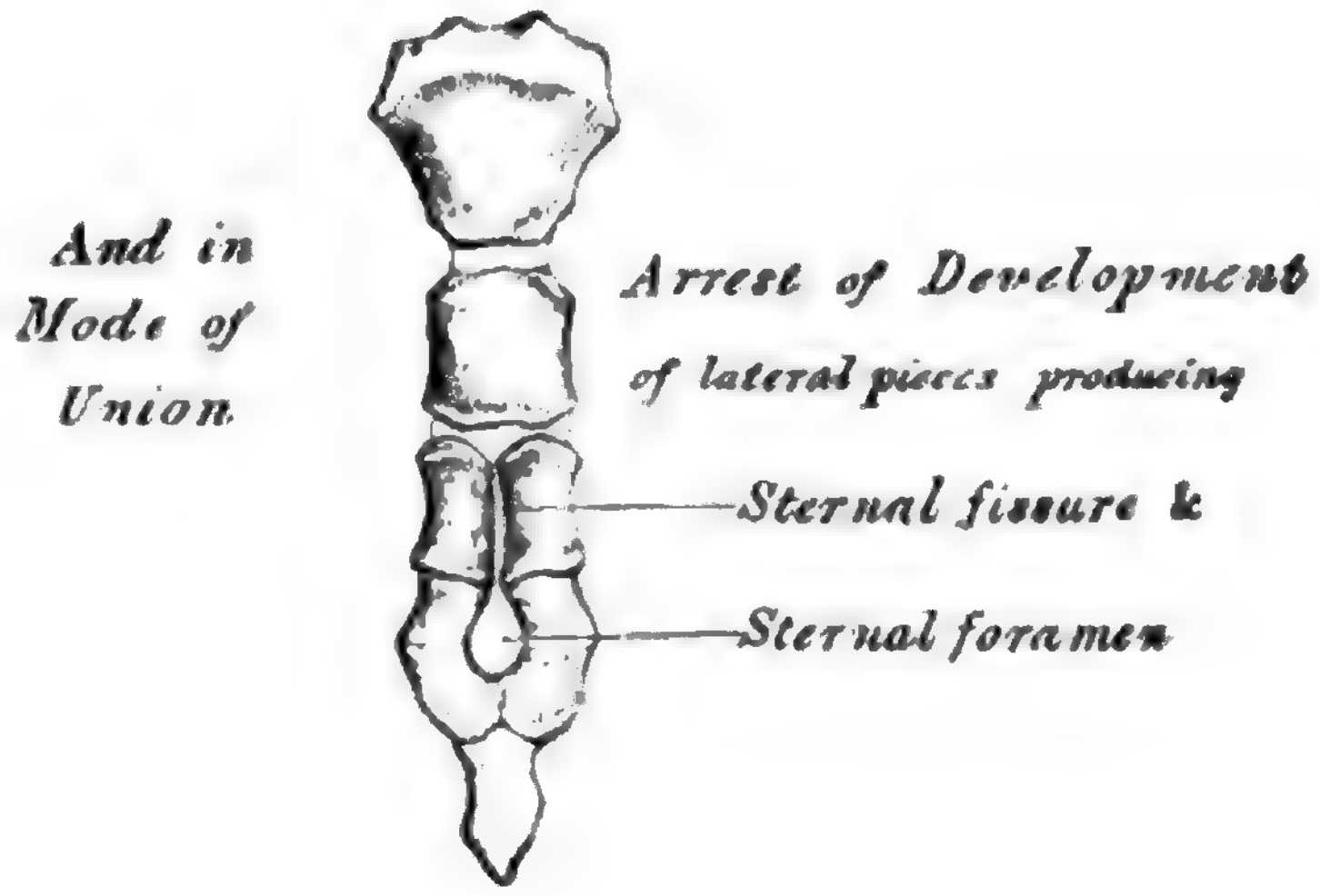
And in Mode of Union
Arrest of Development
of lateral pieces producing
Sternal fissure &
Sternal foramen

FIG. 192.



A Central Rib of Right Side, inner surface.

fourth piece, at the ninth month; in the fifth, within the first year, or between the first and second years after birth; and in the ensiform appendix, between the second and the seventeenth or eighteenth years by a single centre which makes its appearance at the upper part and proceeds gradually downward. To these may be added the occasional existence, as described by Breschet, of two small episternal centres, which make their appearance one on each side of the interclavicular notch. These are regarded by him as the anterior rudiments of a rib, of which the posterior rudiment is the anterior lamina of the transverse process of the seventh cervical vertebra. It occasionally happens that some of the segments are formed from more than one centre, the number and position of which vary (Fig. 190). Thus the first piece may have two, three, or even six centres. When two are present, they are generally situated one above the other, the upper one being the larger;[1] the second piece has seldom more than one; the third, fourth, and fifth pieces are often formed from two centres placed laterally, the irregular union of which will serve to explain the occasional occurrence of the sternal foramen (Fig. 191), or of the vertical fissure which occasionally intersects this part of the bone. Union of the various centres commences from below and proceeds upward, taking place in the following order (Fig. 189): The fifth piece is joined to the fourth soon after puberty; the fourth to the third, between the twentieth and twenty-fifth years; the third to the second, between the thirty-fifth and fortieth years; the second is occasionally joined to the first, especially at an advanced age.

Articulations.—With the clavicles and seven costal cartilages on each side.

Attachment of Muscles.—To nine pairs and one single muscle: the Pectoralis major, Sterno-cleido-mastoid, Sterno-hyoid, Sterno-thyroid, Triangularis sterni, aponeuroses of the Obliquus externus, Obliquus internus, and Transversalis muscles, Rectus, and Diaphragm.

THE RIBS.

The **Ribs** are elastic arches of bone which form the chief part of the thoracic walls. They are twelve in number on each side, but this number may be increased by the development of a cervical or lumbar rib, or may be diminished to eleven. The first seven are connected behind with the spine, and in front with the sternum, through the intervention of the costal cartilages; they are called *vertebro-sternal*, or true ribs. The remaining five are false ribs: of these the first three, being connected behind with the spine, and in front with the costal cartilages, are usually called the *vertebro-costal*, but would be better named the *vertebro-chondral* ribs; the last two are connected with the vertebræ only, being free at their anterior extremities; they are termed *vertebral* or *floating ribs.* The ribs vary in their direction, the upper ones being placed nearly at right angles with the spine, the lower ones obliquely, so that the anterior extremity is lower than the posterior. The extent of obliquity reaches its maximum at the ninth rib, and gradually decreases from that rib to the twelfth. The ribs are situated one below the other in such a manner that spaces are left between them, which are called *intercostal spaces.* Their length corresponds to the length of the ribs; their breadth is more considerable in front than behind, and between the upper than between the lower ribs. The ribs increase in length from the first to the seventh, when they again diminish to the twelfth. In breadth they decrease from above downward; in the upper ten the greatest breadth is at the sternal extremity.

---

[1] Professor Humphry states that this is "probably the more complete condition."

Common Characters of the Ribs (Fig. 192).—A rib from the middle of the series should be taken in order to study the common characters of the ribs.

Each rib presents two extremities, a posterior or vertebral, an anterior or sternal, and an intervening portion—the body or shaft. The **posterior or vertebral extremity** presents for examination a head, neck, and tuberosity. The **head** (Fig. 193) is marked by a kidney-shaped articular surface, divided by a horizontal ridge into two facets for articulation with the costal cavity formed by the junction of the bodies of two contiguous dorsal vertebræ; the upper facet is small, the inferior one of large size; the ridge separating them serves for the attachment of the interarticular ligament.

FIG. 193.

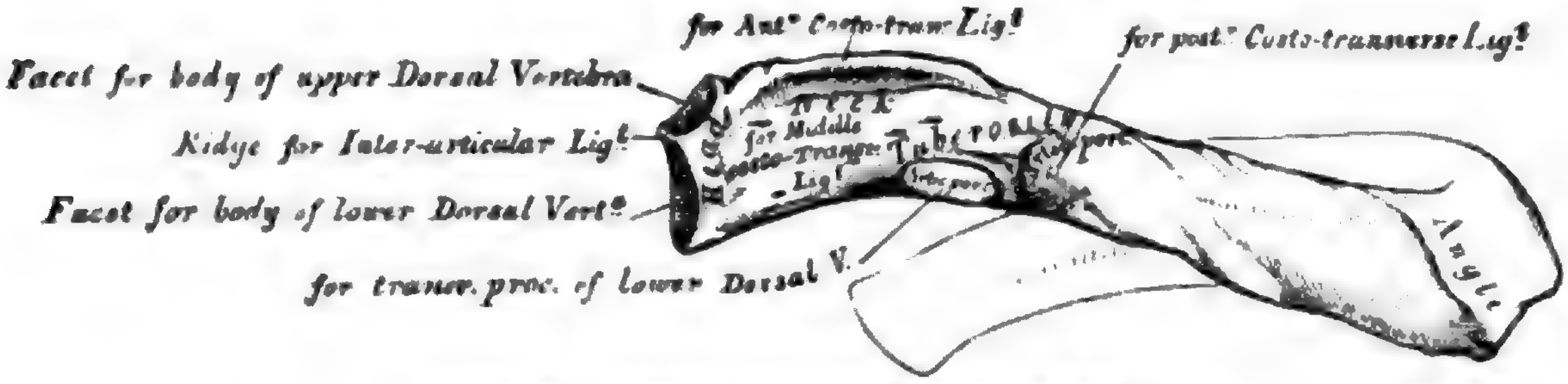
for Antʳ Costo-transᵉ Ligᵗ
for postʳ Costo-transverse Ligᵗ
Facet for body of upper Dorsal Vertebra
Ridge for Inter-articular Ligᵗ
Facet for body of lower Dorsal Vertᵃ
for transv. proc. of lower Dorsal V.
Head
Neck
for Middle Costo-Transv. Ligᵗ
Tuberosity
Angle

Vertebral Extremity of a Rib, external surface.

The **neck** is that flattened portion of the rib which extends outward from the head; it is about an inch long, and rests upon the transverse process of the lower of the two vertebræ with which the head articulates. Its *anterior surface* is flat and smooth, its *posterior* rough, for the attachment of the middle costo-transverse ligament, and perforated by numerous foramina, the direction of which is less constant than those found on the inner surface of the shaft. Of its two borders, the *superior* presents a rough crest, for the attachment of the anterior costo-transverse ligament; its *inferior border* is rounded. On the posterior surface of the neck, just where it joins the shaft, and nearer the lower than the upper border, is an eminence—the **tuberosity,** or **tubercle**; it consists of an articular and a non-articular portion. The *articular portion,* the more internal and inferior of the two, presents a small oval surface, for articulation with the extremity of the transverse process of the lower of the two vertebræ to which the head is connected. The *non-articular portion* is a rough elevation which affords attachment to the posterior costo-transverse ligament. The tubercle is much more prominent in the upper than in the lower ribs.

The **shaft** is thin and flat, so as to present two surfaces, an external and an internal; and two borders, a superior and an inferior. The *external surface* is convex, smooth, and marked at its back part, a little in front of the tuberosity, by a prominent line directed obliquely from above downward and outward; this gives attachment to a tendon of the Sacro-lumbalis muscle or of one of its accessory portions, and is called the *angle.* At this point the rib is bent in two directions. If the rib is laid upon its lower border, it will be seen that the anterior portion of the shaft, as far as the angle, rests upon this margin, while the vertebral end of the bone, beyond the angle, is bent inward and at the same time tilted upward. The interval between the angle and the tuberosity increases gradually from the second to the tenth rib. The portion of the bone between these two parts is rounded, rough, and irregular, and serves for the attachment of the Longissimus dorsi. The portion of bone between the tubercle and sternal extremity is also slightly twisted upon its own axis, the external surface looking downward behind the angle, a little upward in front of it. This surface presents, toward its sternal extremity, an oblique line, the *anterior angle*. The *internal surface* is concave, smooth, directed a little upward behind the angle, a little downward in front of it. This surface is marked by a ridge which commences at the lower extremity of the head; it is strongly marked as far as the inner side of the angle, and gradually becomes lost at the junction of the anterior with the middle third of the bone. The interval between it and the inferior border is deeply grooved, to lodge the intercostal vessels and nerve. At the back part of the bone this groove belongs to the inferior border, but just in front of the angle, where it is deepest and broadest, it corresponds to the internal surface. The superior edge of the groove is rounded; it serves for the attachment of the Internal intercostal muscle. The inferior edge corresponds to the lower margin of the rib, and gives attachment to the External intercostal. Within the groove are seen the orifices of numerous small foramina which traverse the wall of the shaft obliquely from before backward. The *superior border*, thick and rounded, is marked by an external and an internal lip, more distinct behind than in front; they serve for the attachment of the External and Internal intercostal muscles. The *inferior border*, thin and sharp, has attached the External intercostal muscle. The **anterior** or **sternal extremity** is flattened, and presents a porous, oval, concave depression into which the costal cartilage is received.

[Most of the ribs can readily be studied in the living model by his raising his arms and then breathing deeply. In great exertion the ribs are elevated and fixed in inspiration, to give a firm *point d'appui* to the muscles of the arms, as Bell has well illustrated in the *Anatomy of Expression*, Essay viii.]

PECULIAR RIBS.

The ribs which require especial consideration are five in number—viz. the first, second, tenth, eleventh, and twelfth.

The **first rib** (Fig. 194) is one of the shortest and the most curved of all the ribs; it is broad, flat, and placed horizontally at the upper part of the thorax, its surfaces looking upward and downward, and its borders inward and outward. The *head* is of small size, rounded, and presents only a single articular facet for articulation with the body of the first dorsal vertebra. The *neck* is narrow and rounded. The *tuberosity*, thick and prominent, rests on the outer border. There is no angle, but in this situation the rib is slightly bent, with the convexity of the bend upward, so that the head of the bone is directed downward. The upper surface of the shaft is marked by two shallow depressions, separated from one another by a ridge, which becomes more prominent toward the internal border, where it terminates in a tubercle: this tubercle and ridge serve for the attachment of the Scalenus anticus muscle, the groove in front of it transmitting the subclavian vein; that behind it, the subclavian artery. Between the groove for the subclavian artery and the tuberosity is a depression, for the attachment of the Scalenus medius muscle. The *under surface* is smooth, and destitute of the groove observed on the other ribs. The *outer border* is convex, thick, and rounded, and at its posterior part gives attachment to the first serration of the Serratus magnus; the *inner*, concave, thin, and sharp, and marked about its centre by the tubercle before mentioned. The *interior extremity* is larger and thicker than any of the other ribs.

The **second rib** (Fig. 195) is much longer than the first, but bears a very considerable resemblance to it in the direction of its curvature. The non-articular portion of the tuberosity is occasionally only slightly marked. The *angle* is slight, and situated close to the tuberosity, and the shaft is not twisted, so that both ends touch any plane surface upon which it may be laid; but there is a similar though slighter bend, with its convexity upward, to that found in the first rib. The shaft is not horizontal, like that of the first rib, its *outer surface*, which is convex, looking upward and a little outward. It presents, near the middle, a rough eminence, for the attachment of the second and third digitations of the Serratus magnus, behind and above which is attached the Scalenus posticus. The *inner surface*, smooth and concave, is directed downward and a little inward: it presents a short groove toward its posterior part.

Figs. 194–198.

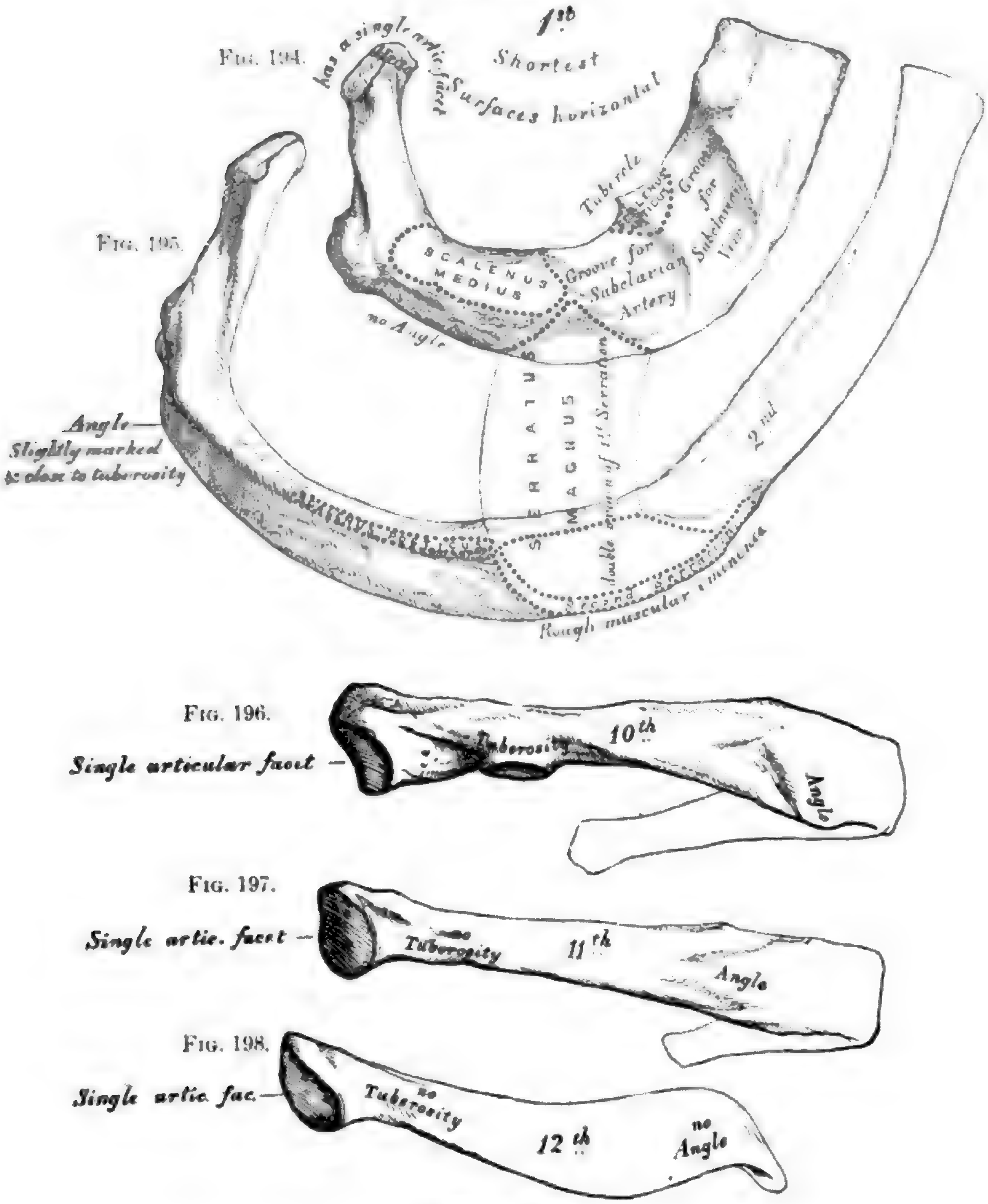
Fig. 194.
has a single artic. facet
Head
1st
Shortest
Surfaces horizontal
Tubercle
Groove for Subclavian Vein
Scalenus Anticus
Scalenus Medius
Groove for Subclavian Artery
no Angle
Fig. 195.
Angle — Slightly marked & close to tuberosity
Serratus Magnus
double origin of 1st Serratus
2nd
Second Serratus
Rough muscular eminence
Fig. 196.
Single articular facet
Tuberosity
10th
Angle
Fig. 197.
Single artic. facet
no Tuberosity
11th
Angle
Fig. 198.
Single artic. fac.
no Tuberosity
12th
no Angle

Peculiar Ribs.

The **tenth rib** (Fig. 196) has only a single articular facet on its head.

The **eleventh** and **twelfth ribs** (Figs. 197 and 198) have each a single articular facet on the head, which is of rather large size; they have no neck or tuberosity, and are pointed at the extremity. The eleventh has a slight angle and a shallow groove on the lower border. The twelfth has neither, and is much shorter than the eleventh, and the head has a slight inclination downward.

Structure.—The ribs consist of cancellous tissue enclosed in a thin compact layer.

Development.—Each rib, with the exception of the last two, is developed by *three* centres: one for the shaft, one for the head, and one for the tubercle. The last two have only *two* centres, that for the tubercle being wanting. Ossification commences in the body of the ribs at a very early period, before its appearance in the vertebræ. The epiphysis of the head, which is of a slightly angular shape, and that for the tubercle, of a lenticular form, make their appearance between the sixteenth and twentieth years, and are not united to the rest of the bone until about the twenty-fifth year.

Attachment of Muscles.—To twenty: the Internal and External Intercostals, Scalenus anticus, Scalenus medius, Scalenus posticus, Pectoralis minor, Serratus magnus, Obliquus externus, Transversalis, Quadratus lumborum, Diaphragm, Latissimus dorsi, Serratus posticus superior, Serratus posticus inferior, Sacro-lumbalis, Musculus accessorius ad sacro-lumbalem, Longissimus dorsi, Cervicalis ascendens, Levatores costarum, and Infracostales.

THE COSTAL CARTILAGES.

The **Costal Cartilages** (Fig. 186, p. 221) are white elastic structures, which serve to prolong the ribs forward to the front of the chest and contribute very materially to the elasticity of its walls. The first seven are connected with the sternum; the next three with the lower border of the cartilage of the preceding rib. The cartilages of the last two ribs, which have proper extremities, float freely in the walls of the abdomen. Like the ribs, the costal cartilages vary in their length, breadth, and direction. They increase in length from the first to the seventh, then gradually diminish to the last. They diminish in breadth, as well as the intervals between them, from the first to the last. They are broad at their attachment to the ribs, and taper toward their sternal extremities, excepting the first two, which are of the same breadth throughout, and the sixth, seventh, and eighth, which are enlarged where their margins are in contact. In direction they also vary: the first descends a little, the second is horizontal, the third ascends slightly, whilst all the rest follow the course of the ribs for a short extent, and then ascend to the sternum or preceding cartilage. Each costal cartilage presents two surfaces, two borders, and two extremities. The *anterior surface* is convex, and looks forward and upward; that of the first gives attachment to the costo-clavicular ligament and the Subclavius muscle; that of the second, third, fourth, fifth, and sixth, at their sternal ends, to the Pectoralis major.[1] The others are covered by, and give partial attachment to, some of the great flat muscles of the abdomen. The *posterior surface* is concave and directed backward and downward, the first giving attachment to the Sterno-thyroid, and the six or seven inferior ones affording attachment to the Transversalis muscle and the Diaphragm. Of the two borders, the *superior* is concave, the *inferior* convex: they afford attachment to the Intercostal muscles, the upper border of the sixth giving attachment to the Pectoralis major muscle. The contiguous borders of the sixth, seventh, and eighth costal cartilages, and sometimes the ninth and tenth, present smooth, oblong surfaces at the points where they articulate. Of the two extremities, the *outer* one is continuous with the osseous tissue of the rib to which it belongs. The *inner* extremity of the first is continuous with the sternum; the six succeeding ones have rounded extremities, which are received into shallow concavities on the lateral margins of the sternum. The inner extremities of the eighth, ninth, and tenth costal cartilages are pointed, and are connected with the cartilage above. Those of the eleventh and twelfth are free and pointed.

The costal cartilages are most elastic in youth, those of the false ribs being more so than the true. In old age they become of a deep yellow color. Under certain diseased conditions they are prone to ossify. Dr. Humphry's observations on this subject have led him to regard the ossification of the costal cartilages as a sign of disease rather than of age: "The ossification takes place in the first cartilage sooner than in the others; and in men more frequently, and at an earlier period of life, than in women."

---

[1] The first and seventh also occasionally give origin to the same muscle.

Attachment of Muscles.—To nine: the Subclavius, Sterno-thyroid, Pectoralis major, Internal oblique, Transversalis, Rectus, Diaphragm, Triangularis sterni, and Internal Intercostals.

OF THE EXTREMITIES.

The extremities, or limbs, are those long, jointed appendages of the body which are connected to the trunk by one end and free in the rest of their extent. They are *four* in number: an *upper* or *thoracic pair*, connected with the thorax through the intervention of the shoulder, and subservient mainly to prehension; and a *lower pair*, connected with the pelvis, intended for support and locomotion. Both pairs of limbs are constructed after one common type, so that they present numerous analogies, while at the same time certain differences are observed in each, dependent on the peculiar offices they have to perform.

OF THE UPPER EXTREMITY.

The upper extremity consists of the arm, the forearm, and the hand. Its continuity with the trunk is established by means of the shoulder, which is homologous with the innominate or haunch-bone in the lower limb. [For a comparison of the shoulder girdle with the pelvic girdle, see p. 259.]

OF THE SHOULDER.

The Shoulder is placed upon the upper part and side of the chest, connecting the upper extremity to the trunk; it consists of two bones—the clavicle and the scapula. [The inner end of the clavicle is the only point at which the upper extremity has any bony connection whatever with the trunk, the scapula being attached to the trunk wholly by muscles. It is accordingly the pivot on which the upper extremity, as a whole, moves. The range of motion of the clavicle, especially in the vertical direction, is very large, and is well shown on the model by comparing the two clavicles while he shrugs one shoulder. The frequent fracture of the clavicle by indirect violence, as by falls on the hand, etc., is also due to its being the only bony means of uniting the upper extremity to the trunk.]

THE CLAVICLE.

The **Clavicle** (*clavis*, a key), or collar-bone, forms the anterior portion of the shoulder-girdle. It is a long bone, curved somewhat like the italic letter *f*, and placed nearly horizontally at the upper and anterior part of the thorax, immediately above the first rib. It articulates by its inner extremity with the upper border of the sternum, and by its outer extremity with the acromion process of the scapula, serving to sustain the upper extremity in the various positions which it assumes, whilst at the same time it allows of great latitude of motion in the arm.[1] In women the clavicle is almost if not quite horizontal; but in men it inclines [slightly] downward to the sternum. It presents a double curvature when looked at in front, the convexity being forward at the sternal end, and the concavity at the scapular end.

---

[1] The clavicle acts especially as a fulcrum to enable the muscles to give lateral motion to the arm. It is accordingly absent in those animals whose fore limbs are used only for progression, but is present for the most part in those animals whose anterior extremities are clawed and used for prehension, though in some of them—as, for instance, in a large number of the Carnivora—it is merely a rudimentary bone suspended among the muscles, and not articulating either with the scapula or sternum.

Its outer third is flattened from above downward, and extends, in the natural position of the bone, from a point opposite the coracoid process to the acromion. Its inner two-thirds are of a cylindrical form, and extend from the sternum to a point opposite the coracoid process of the scapula.

External or Flattened Portion.—The *outer third* is flattened from above downward, so as to present two surfaces, an upper and a lower; and two borders, an anterior and a posterior. The *upper surface* is flattened, rough, marked by impressions for the attachment of the Deltoid in front and the Trapezius behind: between these two impressions, externally, a small portion of the bone is subcutaneous. The *under surface* is flattened. At its posterior border, where the prismatic joins with the flattened portion, is a rough eminence, the *conoid tubercle;* this in the natural position of the bone surmounts the coracoid process of the scapula and gives attachment to the conoid ligament. From this tubercle an oblique line, occasionally a depression, passes forward and outward to near the outer end of the anterior border; it is called the *oblique line*, and affords attachment to the trapezoid ligament. The *anterior border* is concave, thin, and rough; it limits the attachment of the Deltoid, and occasionally presents, near the centre, a tubercle, the *deltoid tubercle*, which is sometimes distinct in the living subject. The *posterior border* is convex, rough, broader than the anterior, and gives attachment to the Trapezius.

Internal or Cylindrical Portion.—The cylindrical portion forms the *inner two-thirds* of the bone. It is curved, so as to be convex in front, concave behind, and is marked by three borders separating three surfaces. The *anterior border* is continuous with the anterior margin of the flat portion. At its commencement it is smooth, and corresponds to the interval between the attachment of the Pectoralis major and Deltoid muscles; at the inner half of the clavicle it forms the lower boundary of an elliptical space for the attachment of the clavicular portion of the Pectoralis major, and approaches the posterior border of the bone. The *superior border* is continuous with the posterior margin of the flat portion, and separates the anterior from the posterior surface. At its commencement it is smooth and rounded, becomes rough toward the inner third for the attachment of the Sterno-mastoid muscle, and terminates at the upper angle of the sternal extremity. The *posterior* or *subclavian border* separates the posterior from the inferior surface, and extends from the conoid tubercle to the rhomboid impression. It forms the posterior boundary of the groove for the Subclavius muscle, and gives attachment to the fascia which encloses that muscle. The *anterior surface* is included between the superior and anterior borders. It is directed forward and a little upward at the sternal end, outward and still more upward at the acromial extremity, where it becomes continuous with the upper surface of the flat portion. Externally, it is smooth, convex, nearly subcutaneous, being covered only by the Platysma; but, corresponding to the inner half of the bone, it is divided by a more or less prominent line into two parts—a lower portion, elliptical in form, rough, and slightly convex, for the attachment of the Pectoralis major; and an upper part, which is rough behind, for the attachment of the Sterno-cleido-mastoid. Between the two muscular impressions is a small subcutaneous interval. The *posterior* or *cervical surface* is smooth, flat, directed vertically, and looks backward toward the root of the neck. It is limited above by the superior border; below, by the subclavian border; internally, by the margin of the sternal extremity; externally, it is continuous with the posterior border of the flat portion. It is concave from within outward, and is in relation, by its lower part, with the suprascapular vessels. This surface, at about the junction of the inner and outer curves, is also in close relation with the brachial plexus and subclavian vessels, which may be injured in fracture of the bone at this part. It gives attachment, near the sternal extremity, to part of the Sterno-hyoid muscle; and presents, at or near the middle, a foramen, directed obliquely outward, which transmits the chief nutrient artery of the bone. Sometimes there are two foramina on the posterior surface, or one on the posterior, the other on the inferior surface. The *inferior* or *subclavian surface* is bounded in front by the anterior border; behind, by the subclavian border. It is narrow internally, but gradually increases in width externally, and is continuous with the under surface of the flat portion. Commencing at the sternal extremity may be seen a small facet for articulation with the cartilage of the first rib. This is continuous with the articular surface at the sternal end of the bone. External to this is a broad rough impression, the *rhomboid*, rather more than an inch in length, for the attachment of the costo-clavicular (rhomboid) ligament. The remaining part of this surface is occupied by a longitudinal groove, the *subclavian groove*, broad and smooth externally, narrow and more uneven internally; it gives attachment to the Subclavius muscle, and by its anterior margin to the strong aponeurosis which encloses it. Not unfrequently this groove is subdivided into two parts by a longitudinal line, which gives attachment to the intermuscular septum of the Subclavius muscle.

The **internal** or **sternal** end of the clavicle is triangular in form, directed inward and a little downward and forward, and presents an articular facet, concave from before backward, convex from above downward, which articulates with the sternum through the intervention of an interarticular fibro-cartilage; the circumference of the articular surface is rough, for the attachment of numerous ligaments. The posterior border of this surface is prolonged backward, so as to increase the size of the articular facet; the upper border gives attachment to the interarticular fibro-cartilage, and the lower border is continuous with the costal facet on the inner end of the inferior or subclavian surface, which articulates with the cartilage of the first rib.

FIG. 199.

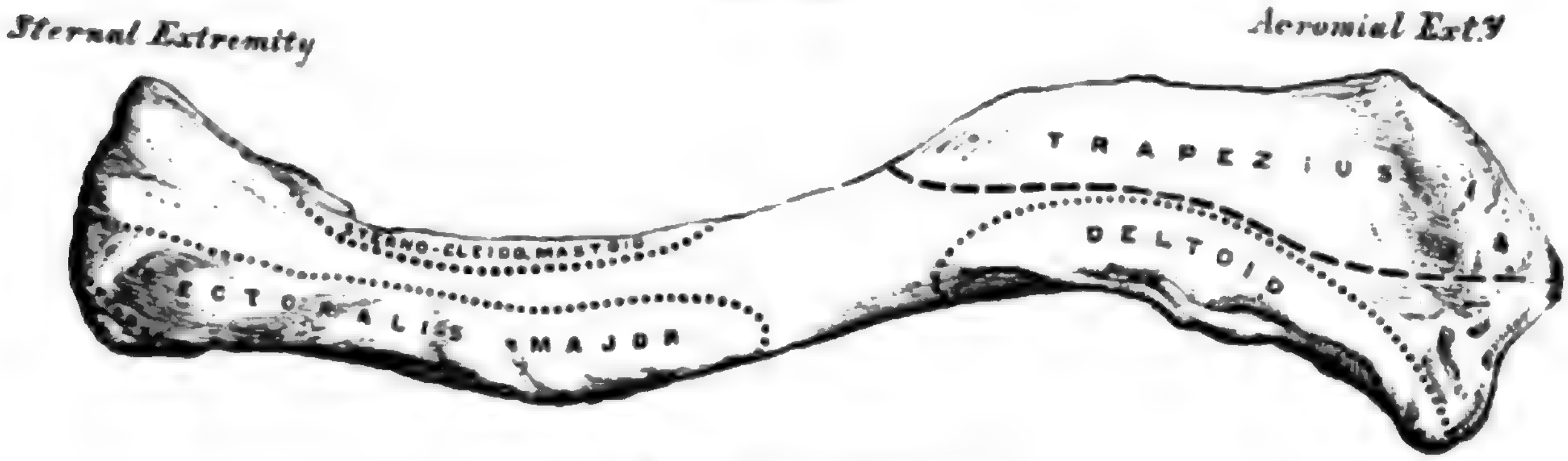
Sternal Extremity
Acromial Ext.y
TRAPEZIUS
DELTOID
STERNO-CLEIDO-MASTOID
PECTORALIS MAJOR

Left Clavicle, anterior surface.

FIG. 200.

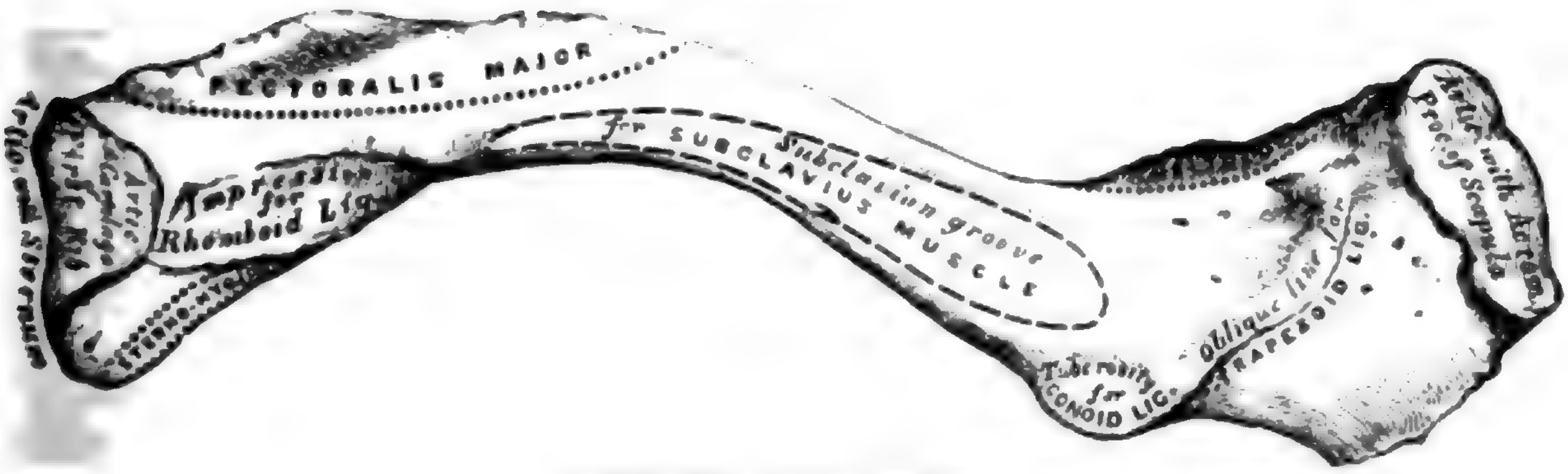
PECTORALIS MAJOR
Artic. with Sternum
Artic. with Cartilage of 1st Rib
Impression for Rhomboid Lig.
STERNO-HYOID
for SUBCLAVIUS MUSCLE
Subclavian groove
Artic. with Acrom. Proc. of Scapula
Oblique line for TRAPEZOID LIG.
Tuberosity for CONOID LIG.

Left Clavicle, inferior surface.

The **outer** or **acromial extremity,** directed outward and forward, presents a small, flattened, oval facet which looks obliquely downward, for articulation with the acromion process of the scapula. The direction of this surface serves to explain the greater frequency of dislocation upward rather than downward beneath the acromion process. The circumference of the articular facet is rough, especially above, for the attachment of the acromio-clavicular ligaments.

Peculiarities of the Bone in the Sexes and in Individuals.—In the female the clavicle is generally less curved, smoother, and more slender than in the male. It is also somewhat shorter. In those persons who perform considerable manual labor, which brings into constant action the muscles connected with this bone, it acquires considerable bulk, becomes thicker, more curved, its ridges for muscular attachment become prominently marked, and its sternal end of a prismatic form. The right clavicle is generally heavier, thicker, and rougher, and often shorter, than the left.

Structure.—The shaft, as well as the extremities, consists of cancellous tissue, invested in a compact layer much thicker in the middle than at either end. The clavicle is highly elastic, by reason of its curves. From the experiments of Mr. Ward it has been shown that it possesses sufficient longitudinal elastic force to project its own weight nearly two feet on a level surface when a smart blow is struck on it, and sufficient transverse elastic force, opposite the centre of its anterior convexity, to throw its own weight about a foot. This extent of elastic power must serve to moderate very considerably the effect of concussions received upon the point of the shoulder.

Fig. 201.

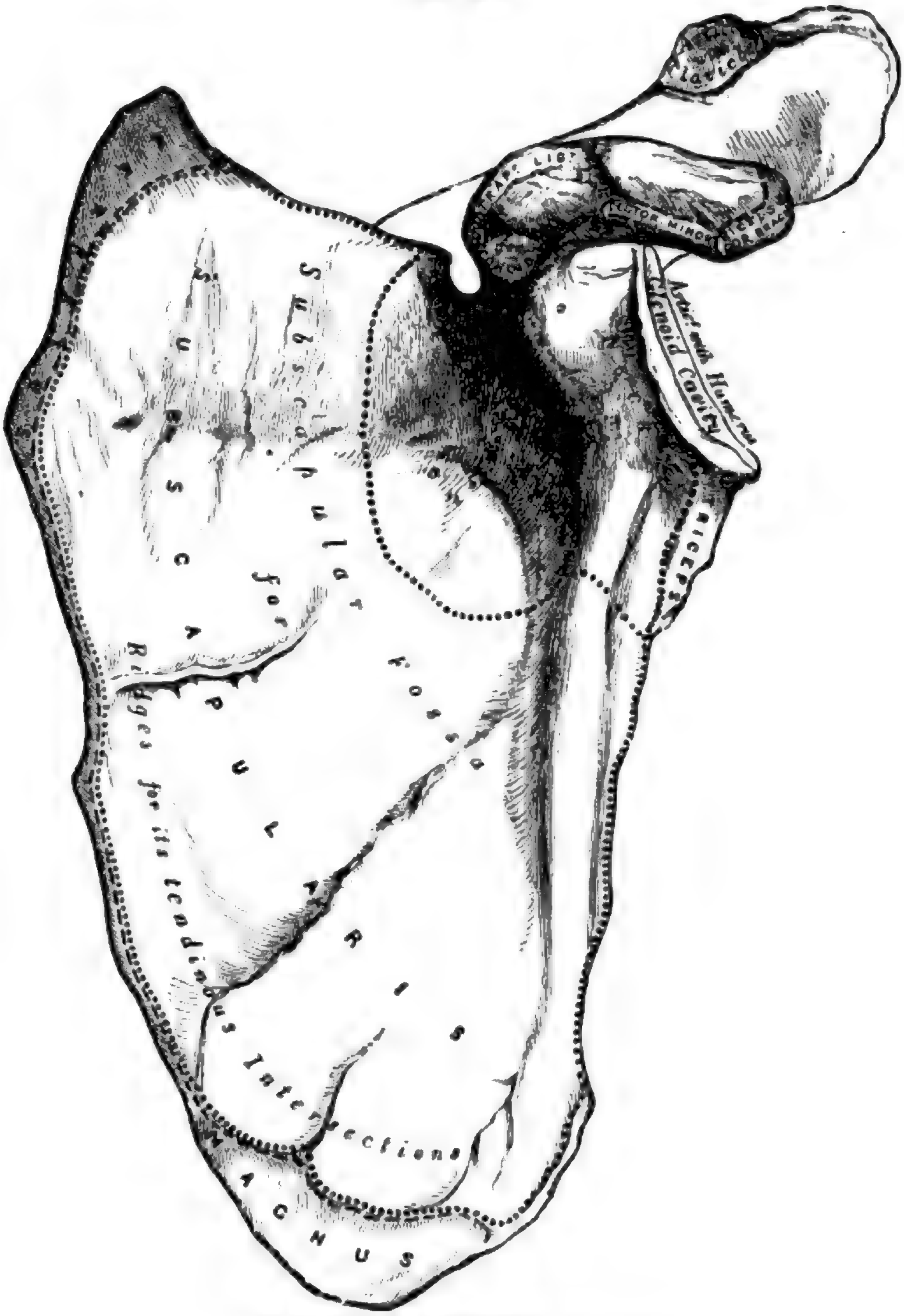
Clavicle
Trapez. Lig.
Pector Minor
Pector Brach.
Artic. with Humerus
Glenoid Cavity
Biceps
Subscapular fossa
Subscapularis
Ridges for its tendinous Intersections
Magnus

Left Scapula, anterior surface, or venter.

Development.—By *two* centres: one for the shaft, and one for the sternal extremity. The centre for the shaft appears very early, before any other bone; according to Béclard, as early as the thirtieth day. The centre for the sternal end makes its appearance about the eighteenth or twentieth year, and unites with the rest of the bone about the twenty-fifth year.

Articulations.—With the sternum, scapula, and cartilage of the first rib.

Attachment of Muscles.—To seven: the Sterno-cleido-mastoid, Trapezius, Pectoralis major, Deltoid, Subclavius, Sterno-hyoid, and Platysma.

The Scapula.

The **Scapula** (*σκαπάνη*, a spade) forms the back part of the shoulder. It is a large flat bone, triangular in shape, situated at the posterior aspect and side of the thorax, between the first and eighth ribs, its posterior border or base being about an inch from, and nearly parallel with, the spinous process of the vertebræ. [For the study of its movements, see the Shoulder-joint.] It presents for examination two surfaces, three borders, and three angles.

The **anterior surface** or **venter** (Fig. 201) presents a broad concavity, the *subscapular fossa.* It is marked in the posterior two-thirds by several oblique ridges, which pass from behind obliquely outward and upward, the anterior third being smooth. The oblique ridges give attachment to the tendinous intersections, and the surfaces between them to the fleshy fibres, of the Subscapularis muscle. The anterior third of the fossa, which is smooth, is covered by, but does not afford attachment to, the fibres of this muscle. This surface is separated from the posterior border by a smooth triangular margin at the superior and inferior angles, and in the interval between these by a narrow edge which is often deficient. This marginal surface affords attachment throughout its entire extent to the Serratus magnus muscle. The subscapular fossa presents a transverse depression at its upper part, where the bone appears to be bent on itself, forming a considerable angle, called the *subscapular angle,* thus giving greater strength to the body of the bone from its arched form, while the summit of the arch serves to support the spine and acromion process. It is in this situation that the fossa is deepest, so that the thickest part of the Subscapularis muscle lies in a line perpendicular to the plane of the glenoid cavity, and must consequently operate most effectively on the head of the humerus, which is contained in that cavity.

The **posterior surface,** or **dorsum** (Fig. 202), is arched from above downward, alternately concave and convex from side to side. It is subdivided unequally into two parts by the *spine:* the portion above the spine is called the *supraspinous fossa,* and that below it the *infraspinous fossa.*

The **supraspinous fossa,** the smaller of the two, is concave, smooth, and broader at the vertebral than at the humeral extremity. It affords attachment by its inner two-thirds to the Supraspinatus muscle.

The **infraspinous fossa** is much larger than the preceding; toward its vertebral margin a shallow concavity is seen at its upper part; its centre presents a prominent convexity, whilst toward the axillary border is a deep groove which runs from the upper toward the lower part. The inner two-thirds of this surface afford attachment to the Infraspinatus muscle; the outer third is only covered by it, without giving origin to its fibres. This surface is separated from the axillary border by an elevated ridge, which runs from the lower part of the glenoid cavity downward and backward to the posterior border, about an inch above the inferior angle. The ridge serves for the attachment of a strong aponeurosis which separates the Infraspinatus from the two Teres muscles. The surface of bone between this line and the axillary border is narrow in the upper two-thirds of its extent, and traversed near its centre by a groove for the passage of the dorsalis scapulæ vessels; it affords attachment to the Teres minor. Its lower third presents a broader, somewhat triangular surface, which gives origin to the Teres major, and over which the Latissimus dorsi glides; sometimes the latter muscle takes origin by a few fibres from this part. The broad and narrow portions of bone above alluded to are separated by an oblique line which runs from the axillary border downward and backward: to it is attached the aponeurosis separating the two Teres muscles from each other.

The **Spine** is a prominent plate of bone which crosses obliquely the inner four-fifths of the dorsum of the scapula at its upper part, and separates the supra- from the infra-spinous fossa. [It is always easily felt directly under the skin, and in muscular models is a linear depression between the attachments of the Trapezius and the Deltoid.] It commences at the vertebral border by a smooth triangular surface, over which the Trapezius glides, separated from the bone by a bursa; [in the living model, when the muscles are called into action, this triangle is marked by a deep fossa], and gradually becoming more elevated as it passes forward, terminates in the acromion process, which overhangs the shoulder-joint. The spine is triangular and flattened from above downward, its apex corresponding to the posterior border; its base, which is directed outward, to the neck of the scapula. It

FIG. 202.

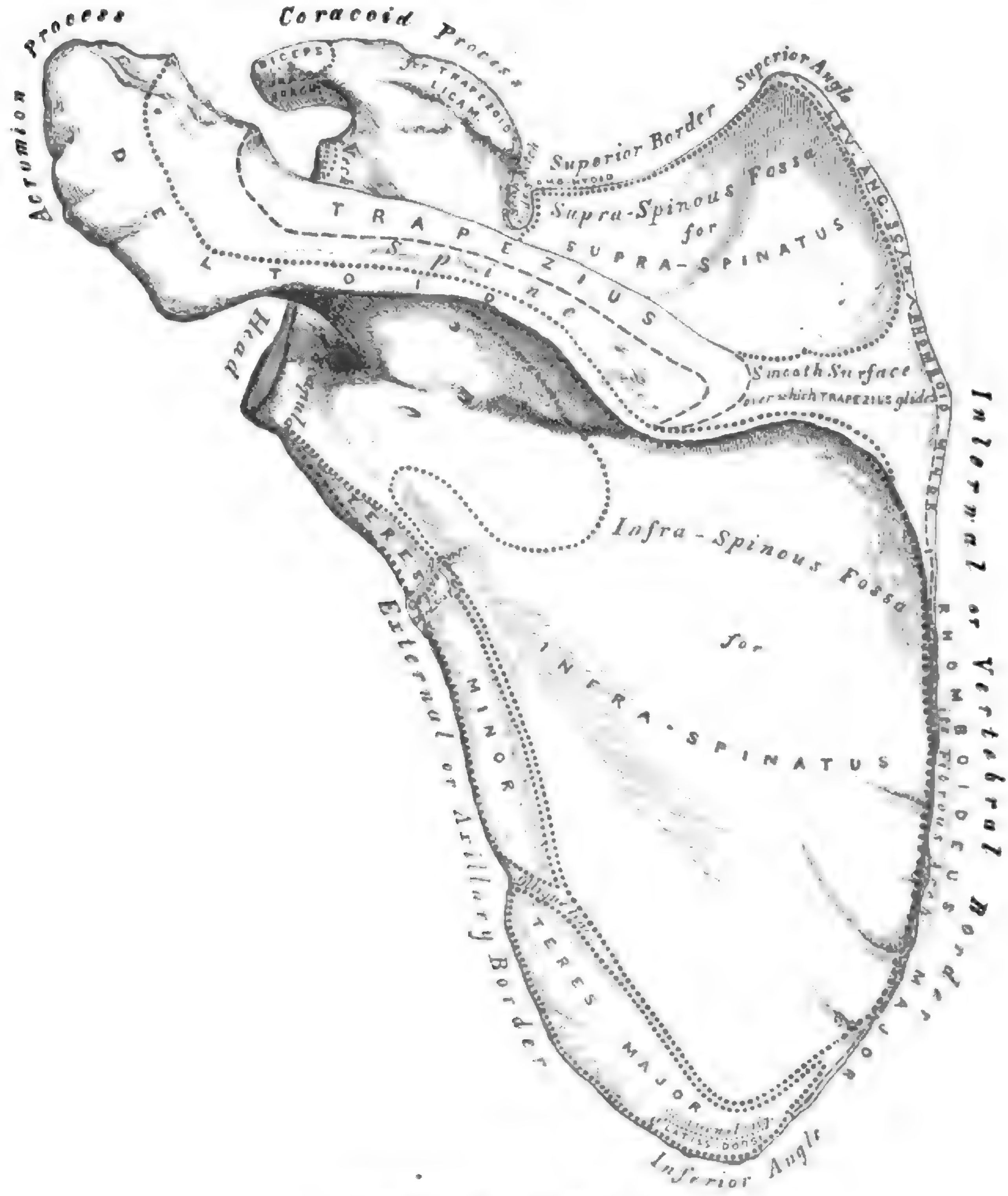
Acromion Process
Coracoid Process
Biceps
For Trapezoid Ligam.
Superior Border
Omo-hyoid
Superior Angle
Supra-Spinous Fossa
for
Supra-Spinatus
Deltoid
Trapezius
Spine
Head
Smooth Surface
over which Trapezius glides
Internal or Vertebral Border
Infra-Spinous Fossa
for
Infra-Spinatus
Teres
Teres Minor
External or Axillary Border
Rhomboideus
Fibrous Arch
Teres Major
Inferior Angle

Left Scapula, posterior surface, or dorsum.

presents two surfaces and three borders. Its *superior surface* is concave, assists in forming the supraspinous fossa, and affords attachment to part of the Supraspinatus muscle. Its *inferior surface* forms part of the infraspinous fossa, gives origin to part of the Infraspinatus muscle, and presents near its centre the orifice of a nutrient canal. Of the three borders, the *anterior* is attached to the dorsum of the bone; the *posterior*, or *crest* of the spine, is broad and presents two lips and an intervening rough interval. To the superior lip is attached the Trapezius, to the extent shown in the figure. A very rough tubercle is generally seen occupying that portion of the spine which receives the insertion of the middle and inferior fibres of this muscle. To the inferior lip, throughout its whole length, is attached the Deltoid. The interval between the lips is also partly covered by the fibres of these muscles. The *external border*, the shortest of the three, is slightly concave, its edges thick and round, continuous above with the under surface of the acromion process; below, with the neck of the scapula. The narrow portion of bone external to this border serves to connect the supra- and infra-spinous fossæ.

The **Acromion Process,** so called from forming the summit of the shoulder (*ἄκρον*, a summit; *ὦμος*, the shoulder), is a large and somewhat triangular process, flattened from behind forward, directed at first a little outward, and then curving forward and upward, so as to overhang the glenoid cavity. Its *upper surface*, directed upward, backward, and outward, is convex, rough, and gives attachment to some fibres of the Deltoid and the Platsyma, and in the rest of its extent it is subcutaneous. Its *under surface* is smooth and concave. Its *outer border*, which is thick and irregular, affords attachment to the Deltoid muscle. Its *inner margin*, shorter than the outer, is concave, gives attachment to a portion of the Trapezius muscle, and presents about its centre a small oval surface for articulation with the acromial end of the clavicle. Its *apex*, which corresponds to the point of meeting of these two borders in front, is thin, and has attached to it the coraco-acromial ligament.

Of the three borders or costæ of the scapula, the *superior* is the shortest and thinnest; it is concave, terminating at its inner extremity at the superior angle, at its outer extremity at the coracoid process. At its outer part is a deep semicircular notch, the *suprascapular*, formed partly by the base of the coracoid process. This notch is converted into a foramen by the transverse ligament [which is occasionally ossified], and serves for the passage of the suprascapular nerve. The adjacent margin of the superior border affords attachment to the Omo-hyoid muscle. The *external*, or *axillary*, *border* is the thickest of the three. It commences above at the lower margin of the glenoid cavity, and inclines obliquely downward and backward to the inferior angle. Immediately below the glenoid cavity is a rough impression, about an inch in length, which affords attachment to the long head of the Triceps muscle; to this succeeds a longitudinal groove which extends as far as its lower third and affords origin to part of the Subscapularis muscle. The inferior third of this border, which is thin and sharp, serves for the attachment of a few fibres of the Teres major behind and of the Subscapularis in front. The *internal*, or *vertebral*, *border*, also named the *base*, is the longest of the three, and extends from the superior to the inferior angle of the bone. It is arched, intermediate in thickness between the superior and the external borders, and the portion of it above the spine is bent considerably outward, so as to form an obtuse angle with the lower part. The vertebral border presents an anterior lip, a posterior lip, and an intermediate space. The *anterior lip* affords attachment to the Serratus magnus; the *posterior lip*, to the Supraspinatus above the spine, the Infraspinatus below; the interval between the two lips, to the Levator anguli scapulæ above the triangular surface at the commencement of the spine; the Rhomboideus minor, to the edge of that surface, the Rhomboideus major being attached by means of a fibrous arch, connected above to the lower part of the triangular surface at the base of the spine and below to the lower part of the posterior border.

Of the three angles, the *superior*, formed by the junction of the superior and internal borders, is thin, smooth, rounded, somewhat inclined outward, and gives attachment to a few fibres of the Levator anguli scapulæ muscle. The *inferior* angle, thick and rough, is formed by the union of the vertebral and axillary borders, its outer surface affording attachment to the Teres major, and occasionally a few fibres of the Latissimus dorsi. The *anterior* angle is the thickest part of the bone, and forms what is called the *head* of the scapula. The head presents a shallow, pyriform, articular surface, the *glenoid cavity* (γλήνη, a socket), whose longest diameter is from above downward, and its direction outward and forward. It is broader below than above: at its apex is attached the long tendon of the Biceps muscle. It is covered with cartilage in the recent state; and its margins, slightly raised, give attachment to a fibro-cartilaginous structure, the *glenoid ligament*, by which its cavity is deepened. The *neck* of the scapula is the slightly depressed surface which surrounds the head; it is more distinct on the posterior than on the anterior surface, and below than above. In the latter situation it has arising from it a thick prominence, the coracoid process.

The **Coracoid Process**, so called from its fancied resemblance to a crow's beak (*κόραξ*, a crow), is a thick curved process of bone which arises by a broad base from the upper part of the neck of the scapula; it is directed at first upward and inward; then, becoming smaller, it changes its direction and passes forward and outward. The ascending portion, flattened from before backward, presents in front a smooth concave surface, over which passes the Subscapularis muscle. The horizontal portion is flattened from above downward; its upper surface is convex and irregular; its under surface is smooth; its anterior border is rough, and gives attachment to the Pectoralis minor; its posterior border is also rough, for the coraco-acromial ligament, while the apex is embraced by the conjoined tendon of origin of the short head of the Biceps and of the Coraco-brachialis. At the inner side of the root of the coracoid process is a rough impression for the attachment of the conoid ligament, and running from it obliquely forward and outward on the upper surface of the horizontal portion an elevated ridge for the attachment of the trapezoid ligament. [The coracoid process can generally be felt in the upper part of the groove, between the Pectoralis major and the Deltoid.]

FIG. 203.

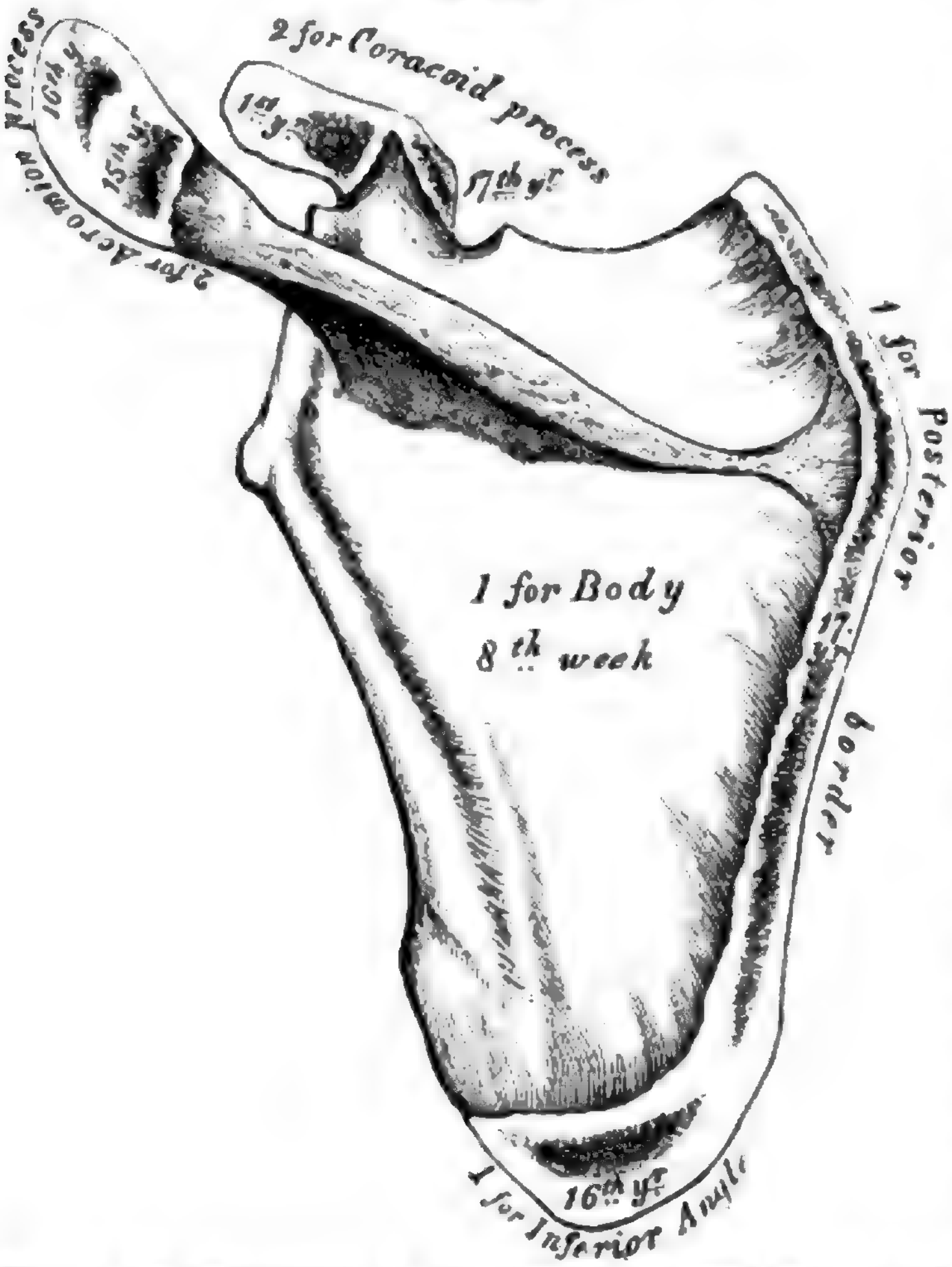

Plan of the Development of the Scapula, by seven centres: the epiphyses (except one for the coracoid process) appear at from fifteen to seventeen years, and unite between the twenty-second and twenty-fifth year.

Structure.—In the head, processes, and all the thickened parts of the bone the scapula is cellular in structure—of a dense, compact tissue in the rest of its extent. The centre and upper part of the dorsum, but especially the former, are usually so thin as to be semi-transparent; occasionally the bone is found wanting in this situation and the adjacent muscles come into contact.

Development (Fig. 203).—By *seven* centres: one for the body, two for the coracoid process, two for the acromion,[1] one for the posterior border, and one for the inferior angle.

Ossification of the body of the scapula commences about the second month of fœtal life by the formation of an irregular quadrilateral plate of bone immediately behind the glenoid cavity. This plate extends itself so as to form the chief part of the bone, the spine growing up from its posterior surface about the third month. At birth the chief part of the scapula is osseous, only the coracoid and acromion processes, the posterior border, and inferior angle being cartilaginous. About the first year after birth ossification takes place in the middle of the coracoid process, which usually becomes joined with the rest of the bone at the time when the other centres make their appearance. Between the fifteenth and seventeenth years ossification of the remaining centres takes place in quick succession, and in the following order: first, near the base of the acromion and in the root of the coracoid process, the latter appearing in the form of a broad scale; secondly, in the inferior angle and contiguous part of the posterior border; thirdly, near the extremity of the acromion; fourthly, in the posterior border. The acromion process, besides being formed of two separate nuclei, has its base formed by an extension into it of the centre of ossification which belongs to the spine, the extent of which varies in different cases. The two separate nuclei unite, and then join with the extension carried in from the spine. These various epiphyses become joined to the bone between the ages of twenty-two and twenty-five years. Sometimes failure of union between the acromion process and spine occurs, the junction being effected by fibrous tissue or by an imperfect articulation; in some cases of supposed fracture of the acromion with ligamentous union it is probable that the detached segment was never united to the rest of the bone.

Articulations.—With the humerus and clavicle.

Attachment of Muscles.—To eighteen: to the anterior surface, the Subscapularis; posterior surface, Supraspinatus, Infraspinatus; spine, Trapezius, Deltoid; superior border, Omo-hyoid; vertebral border, Serratus magnus, Levator anguli scapulæ, Rhomboideus minor and major; axillary border, Triceps, Teres minor, Teres major; glenoid cavity, long head of the Biceps; coracoid process, short head of the Biceps, Coraco-brachialis, Pectoralis minor; acromion process, the Platysma; and to the inferior angle, occasionally a few fibres of the Latissimus dorsi.

THE HUMERUS.

The **Humerus** is the longest and largest bone of the upper extremity; it presents for examination a shaft and two extremities.

The **Upper Extremity** is the largest part of the bone; it presents a rounded head, joined to the shaft by a constricted portion, called the *neck*, and two other eminences, the *greater and lesser tuberosities* (Fig. 204).

The **head**, nearly hemispherical in form,[2] is directed upward, inward, and a little backward; its surface is smooth, coated with cartilage in the recent state, and articulates with the glenoid cavity of the scapula. The circumference of its articular surface is slightly constricted, and is termed the *anatomical neck*, in contradistinction to the constriction which exists below the tuberosities. The latter is called the *surgical neck*, from its often being the seat of fracture. [The *surgical head* of the bone, as it should be named, consists of the anatomical head and neck and the two tuberosities.] It should be remembered, however, that fracture of the *anatomical neck* does sometimes, though rarely, occur.

---

[1] Anatomists are not agreed as to the number of centres of ossification for the coracoid and acromion processes. Humphry describes one only for each process; Cruveilhier gives one for the coracoid and two for the acromion; Thane makes two for the coracoid, and two, sometimes three, for the acromion; and Béclard states that in some instances the coracoid has three centres, additional ones being formed both for the apex and the base of the process.

[2] Though the head is nearly hemispherical in form, its margin, as Professor Humphry has shown, is by no means a true circle. Its greatest measurement is from the top of the bicipital groove in a direction downward, inward, and backward. Hence it follows that the greatest elevation of the arm can be obtained by rolling the articular surface in this direction—that is to say, obliquely upward, outward, and forward.

The **anatomical neck** is obliquely directed, forming an obtuse angle with the shaft. It is more distinctly marked in the lower half of its circumference than in the upper half, where it presents a narrow groove, separating the head from the tuberosities. Its circumference affords attachment to the capsular ligament, and is perforated by numerous vascular foramina.

The **greater tuberosity** is situated on the outer side of the head and lesser tuberosity. Its upper surface is rounded and marked by three flat facets, separated by two slight ridges: the anterior facet gives attachment to the tendon of the Supraspinatus; the middle one, to the Infraspinatus; the posterior facet and the shaft of the bone below it, to the Teres minor. The outer surface of the great tuberosity is convex, rough, and continuous with the outer side of the shaft.

The **lesser tuberosity** is more prominent, although smaller, than the greater: it is situated in front of the head and is directed inward and forward. Its summit presents a prominent facet for the insertion of the tendon of the Subscapularis muscle. The tuberosities are separated from one another by a deep groove, the *bicipital groove*, so called from its lodging the long tendon of the Biceps muscle, with which runs a branch of the anterior circumflex artery. It commences above between the two tuberosities, passes obliquely downward and a little inward, and terminates at the junction of the upper with the middle third of the bone. It is deep and narrow at the commencement, and becomes shallow and a little broader as it descends. [Its borders are called, respectively, the anterior and the posterior *bicipital ridges*.] In the recent state it is covered with a thin layer of cartilage, lined by a prolongation of the synovial membrane of the shoulder-joint, and receives part of the tendons of insertion of the Latissimus dorsi and Pectoralis major muscles.

[The two tuberosities and the bicipital groove can be well felt in the living model, unless he be very fat or muscular.]

The **shaft** of the humerus is almost cylindrical in the upper half of its extent, prismatic and flattened below, and presents three borders and three surfaces for examination.

The **anterior border** runs from the front of the great tuberosity above to the coronoid depression below, separating the internal from the external surface. Its upper part is very prominent and rough, and forms the outer lip of the bicipital groove. It is sometimes called the *pectoral ridge*, and serves for the attachment of the tendon of the Pectoralis major. About its centre it forms the anterior boundary of the rough deltoid impression; below, it is smooth and rounded, affording attachment to the Brachialis anticus.

The **external border** runs from the back part of the greater tuberosity to the external condyle, and separates the external from the posterior surface. It is rounded and indistinctly marked in its upper half, serving for the attachment of the external head of the Triceps muscle; its centre is traversed by a broad but shallow oblique depression, the *musculo-spiral groove;* its lower part is marked by a prominent rough margin, a little curved from behind forward [the *external condyloid ridge*], which presents an anterior lip for the attachment of the Supinator longus above and Extensor carpi radialis longior below, a posterior lip for the Triceps, and an interstice for the attachment of the external intermuscular septum.

The **internal border** extends from the lesser tuberosity to the internal condyle. Its upper third is marked by a prominent ridge, forming the inner lip of the bicipital groove, and gives attachment from above downward to the tendons of the Latissimus dorsi, Teres major, and part of the origin of the inner head of the Triceps. About its centre is a rough ridge for the attachment of the Coraco-brachialis, and just below this is seen the entrance of the nutrient canal, directed downward. Sometimes there is a second canal higher up, which takes a similar direction. The inferior third of this border is raised into a slight ridge, which becomes very prominent below [the *internal condyloid ridge*]; it presents an anterior lip

Fig. 204.

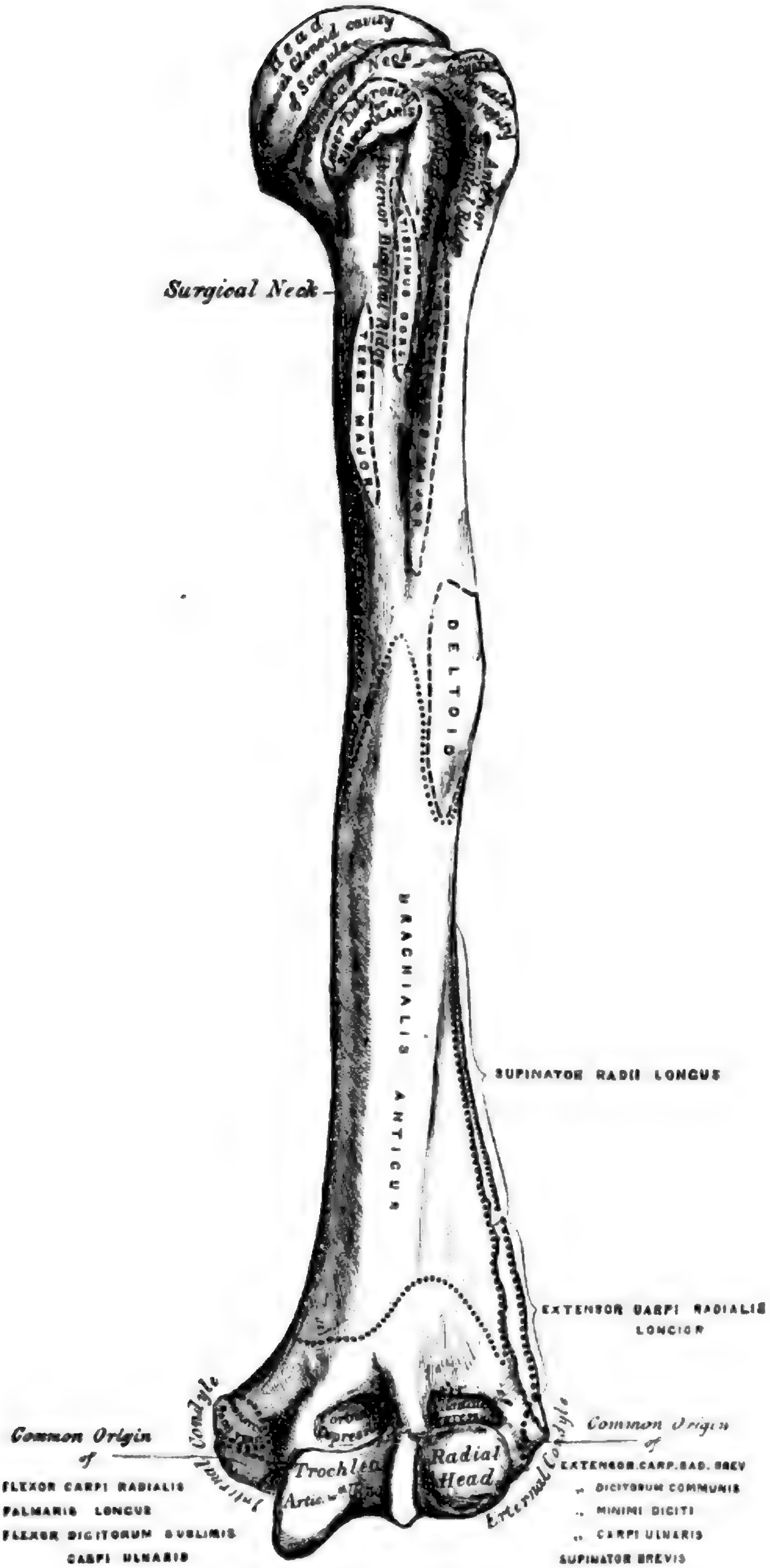
Head
Glenoid cavity
of Scapula
Anatomical Neck
Lesser Tuberosity
Subscapularis
Greater Tuberosity
Anterior Bicipital Ridge
Posterior Bicipital Ridge
LATISSIMUS DORSI
TERES MAJOR
MAJOR
Surgical Neck
DELTOID
BRACHIALIS ANTICUS
SUPINATOR RADII LONGUS
EXTENSOR CARPI RADIALIS LONGIOR
Internal Condyle
Common Origin of
FLEXOR CARPI RADIALIS
PALMARIS LONGUS
FLEXOR DIGITORUM SUBLIMIS
CARPI ULNARIS
Coronoid Depression
Trochlea
Artic.
Radial Head
External Condyle
Common Origin of
EXTENSOR.CARP.RAD.BREV
" DIGITORUM COMMUNIS
" MINIMI DIGITI
" CARPI ULNARIS
SUPINATOR BREVIS

Left Humerus, anterior view.

for the attachment of the Brachialis anticus, a posterior lip for the internal head of the Triceps, and an intermediate space for the internal intermuscular septum.

The **external surface** is directed outward above, where it is smooth, rounded, and covered by the Deltoid muscle; forward and outward below, where it is slightly concave from above downward, and gives origin to part of the Brachialis anticus muscle. About the middle of this surface is seen a rough triangular impression for the insertion of the Deltoid muscle, and below it the musculo-spiral groove, directed obliquely from behind, forward, and downward, and transmitting the musculo-spiral nerve and superior profunda artery.

The **internal surface**, less extensive than the external, is directed inward above, forward and inward below; at its upper part it is narrow and forms the bicipital groove. The middle part of this surface is slightly rough for the attachment of the Coraco-brachialis; its lower part is smooth, concave, and gives attachment to the Brachialis anticus muscle.[1]

The **posterior surface** (Fig. 205) appears somewhat twisted, so that its upper part is directed a little inward, its lower part backward and a little outward. Nearly the whole of this surface is covered by the external and internal heads of the Triceps, the former of which is attached to its upper and outer part, the latter to its inner and back part, the two being separated by the musculo-spiral groove.

The **Lower Extremity** is flattened from before backward, and curved slightly forward; it terminates below in a broad articular surface which is divided into two parts by a slight ridge. Projecting on either side are the external and internal condyles. The articular surface ex-

Fig. 205.



Left Humerus, posterior surface.

---

[1] A small, hook-shaped process of bone, varying from one-tenth to three-quarters of an inch in length, is not unfrequently found projecting from the inner surface of the shaft of the humerus two inches above the internal condyle. It is curved downward, forward, and inward, and its pointed extremity is connected to the internal border, just above the inner condyle, by a ligament or fibrous band, completing an arch through which the median nerve and brachial artery pass when these structures deviate from their usual course. Sometimes the nerve alone is transmitted through it, or the nerve may be accompanied by the ulnar interosseous artery in cases of high division of the brachial. A well-marked groove is usually found behind the process in which the nerve and artery are lodged. This space is analogous to the supracondyloid foramen in many animals, and probably serves in them to protect the nerve and artery from compression during the contraction of the muscles in this region. A detailed account of this process is given by Dr. Struthers in his *Anatomical and Physiological Observations*, p. 202. An accessory portion of the Coraco-brachialis muscle is frequently connected with this process, according to Mr. J. Wood (*Journal of Anatomy and Physiology*, No. 1, Nov., 1866, p. 47).

tends a little lower than the condyles, and is curved slightly forward, so as to occupy the more anterior part of the bone; its greatest breadth is in the transverse diameter, and it is obliquely directed, so that its inner extremity occupies a lower level than the outer. The outer portion of the articular surface presents a smooth rounded eminence which has received the name of the *capitellum*, or *radial head* of the humerus; it articulates with the cup-shaped depression on the head of the radius, and is limited to the front and lower part of the bone, not extending as far back as the other portion of the articular surface. On the inner side of this eminence is a shallow groove in which is received the inner margin of the head of the radius. The inner portion of the articular surface, the *trochlear*, presents a deep depression between two well-marked borders. This surface is convex from before backward, concave from side to side, and occupies the anterior, lower, and posterior parts of the bone. The external border, less prominent than the internal, corresponds to the interval between the radius and the ulna. The internal border is thicker, more prominent, and consequently of greater length than the external. The grooved portion of the articular surface fits accurately within the greater sigmoid cavity of the ulna; it is broader and deeper on the posterior than on the anterior aspect of the bone, and is inclined obliquely from behind forward and from without inward. Above the back part of the trochlear surface is a deep triangular depression, the *olecranon fossa*, in which is received the summit of the olecranon process in extension of the forearm. Above the front part of the trochlear surface is seen a smaller depression, the *coronoid fossa*, which receives the coronoid process of the ulna during flexion of the forearm. These fossæ are separated from one another by a thin transparent lamina of bone, which is sometimes perforated, forming the *supratrochlear foramen;* their upper margins afford attachment to the anterior and posterior ligaments of the elbow-joint, and they are lined in the recent state by the synovial membrane of this articulation. Above the front part of the radial tuberosity is seen a slight depression which receives the anterior border of the head of the radius when the forearm is strongly flexed. The *external condyle* is a small tubercular eminence, less prominent than the internal, curved a little forward, and giving attachment to the external lateral ligament of the elbow-joint and to a tendon common to the origin of some of the extensor and supinator muscles. The *internal condyle*, larger and more prominent than the external, is directed a little backward: it gives attachment to the internal lateral ligament, to the Pronator radii teres, and to a tendon common to the origin of some of the flexor muscles of the forearm. The ulnar nerve runs in a groove at the back of the internal condyle or between it and the olecranon process. These eminences are directly continuous above with the external and internal borders [*i. e.* the external and internal *supracondyloid ridges*]. The great prominence of the inner one renders it more liable to fracture.

Structure.—The extremities consist of cancellous tissue covered with a thin compact layer; the shaft is composed of a cylinder of compact tissue, thicker at the centre than at the extremities, and hollowed out by a large medullary canal, which extends along its whole length.

Development.—By *seven* centres (Fig. 206): one for the shaft, one for the head, one for the tuberosities, one for the radial head, one for the trochlear portion of the articular surface, and one for each condyle. The nucleus for the shaft appears near the centre of the bone in the eighth week, and soon extends toward the extremities. At birth the humerus is ossified nearly in its whole length, the extremities remaining cartilaginous. At the beginning of the second year ossification commences in the head of the bone, and during the third year the centre for the tuberosities makes its appearance, usually by a single ossific point, but sometimes, according to Béclard, by one for each tuberosity, that for the lesser being small and not appearing until after the fourth year. By the fifth year the centres for the head and tuberosities have enlarged and become joined, so as to form a single large epiphysis.

The lower end of the humerus is developed in the following manner: At the end of the second year ossification commences in the radial portion of the articular surface, and from this point extends inward, so as to form the chief part of the articular end of the bone, the centre for the inner part of the articular surface not appearing until about the age of twelve. Ossification commences in the internal condyle about the fifth year, and in the external one not until about the thirteenth or fourteenth year. About the sixteenth or seventeenth year the outer condyle and both portions of the articulating surface (having already joined) unite with the shaft; at the eighteenth year the inner condyle becomes joined, whilst the upper epiphysis, although the first formed, is not united until about the twentieth year.

Fig. 206.

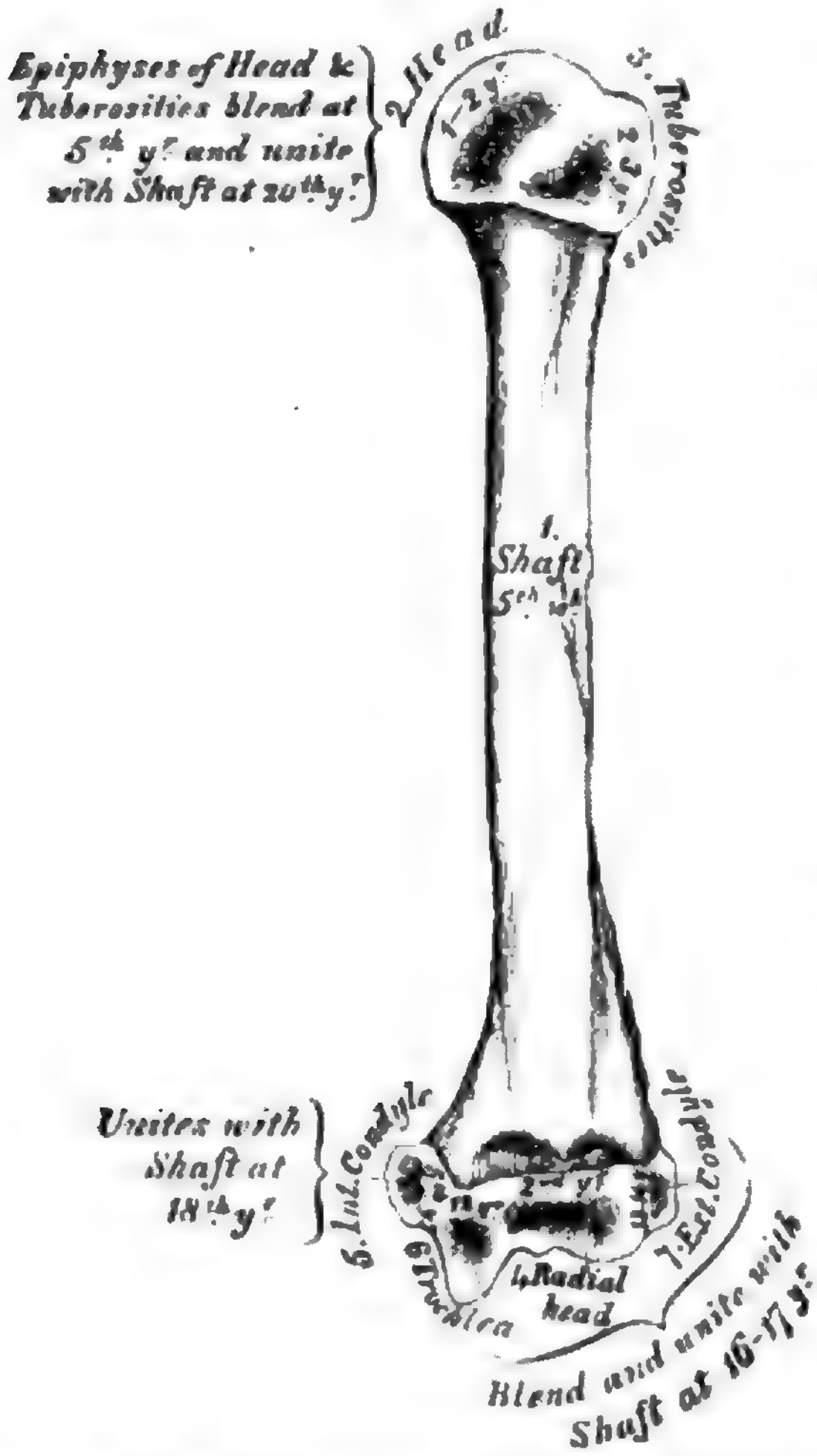
Epiphyses of Head & Tuberosities blend at 5th yr. and unite with Shaft at 20th yr.
2. Head
1-2 yr.
3. Tuberosities
2-3 yr.
1. Shaft
5th wk.
Unites with Shaft at 18th yr.
5. Int. Condyle
2-yr.
7. Ext. Condyle
6. Trochlea
4. Radial head
Blend and unite with Shaft at 16-17 yr.

Plan of the Development of the Humerus, by seven centres.

Articulations.—With the glenoid cavity of the scapula and with the ulna and radius.

Attachment of Muscles.—To twenty-five: to the greater tuberosity, the Supraspinatus, Infraspinatus, and Teres minor; to the lesser tuberosity, the Subscapularis; to the anterior bicipital ridge, the Pectoralis major; to the posterior bicipital ridge and groove, the Latissimus dorsi and Teres major; to the shaft, the Deltoid, Coraco-brachialis, Brachialis anticus, external and internal heads of the Triceps, Subanconeus; to the internal condyle, the Pronator radii teres and common tendon of the Flexor carpi radialis, Palmaris longus, Flexor digitorum sublimis, and Flexor carpi ulnaris; to the external condyloid ridge, the Supinator longus and Extensor carpi radialis longior; to the external condyle, the common tendon of the Extensor carpi radialis brevior, Extensor communis digitorum, Extensor minimi digiti, and Extensor carpi ulnaris and Supinator brevis; to the back of the external condyle, the Anconeus.

The Forearm.

The **Forearm** is that portion of the upper extremity which is situated between the elbow and wrist. It is composed of two bones, the ulna and the radius. [These bones are articulated with the humerus, not in a straight line, but at an angle of about ten degrees, so that when the hands are turned with the palms forward (supi-

[Fig. 207.

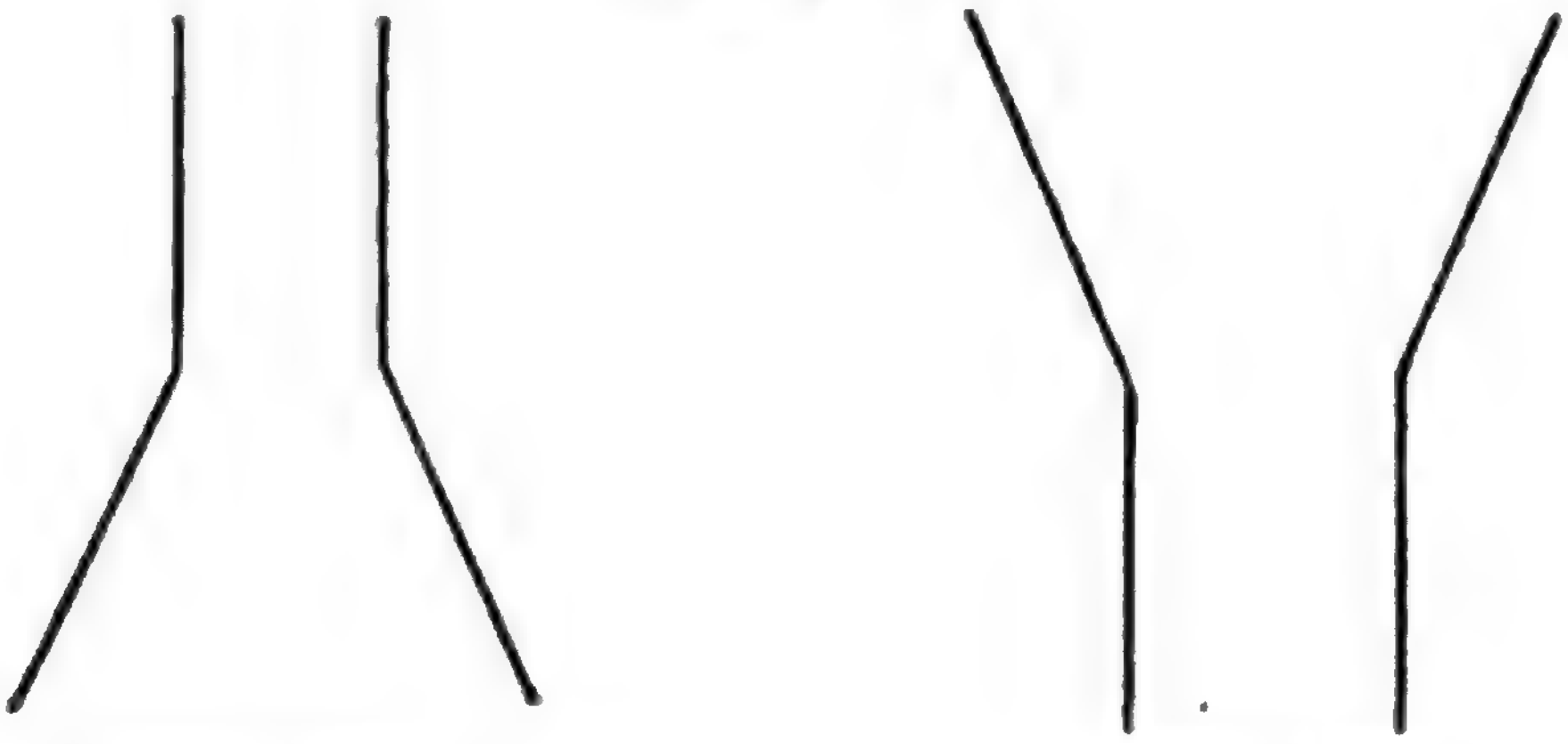

Angle at Elbows.

Angle at Knees.]

nation) the two upper arms are vertical and parallel with each other and with the axis of the trunk, but the forearms diverge. This angle at the elbow should always be borne in mind in examining for fractures and dislocations and in applying splints to the arm and forearm in supination. In pronation the angle disappears, the hand being swung over to the inside. At the knee a similar angle of about ten degrees exists, but there the thighs are convergent and the legs (tibiæ) are vertical (Fig. 207).[1] No joint will better repay careful and minute study in the living model, as most of the bony points described below are accessible to touch and measurement—a matter of the utmost importance in injuries at or near this joint.]

THE ULNA.

The **Ulna** (Figs. 208, 209), so called from its forming the elbow (*ὠλένῃ*), is a long bone, prismatic in form, placed at the inner side of the forearm, parallel with the radius. It is the larger and longer of the two bones. Its upper extremity, of great thickness and strength, forms a large part of the articulation of the elbow-joint; it diminishes in size from above downward, its lower extremity being very small and excluded from the wrist-joint by the interposition of an interarticular fibro-cartilage. It is divisible into a shaft and two extremities.

The **Upper Extremity**, the strongest part of the bone, presents for examination two large curved processes, the olecranon process and the coronoid process; and two concave articular cavities, the greater and lesser sigmoid cavities.

The **Olecranon Process** (*ὠλένῃ*, elbow; *κράνον*, head) is a large, thick, curved eminence situated at the upper and back part of the ulna. It rises somewhat higher than the coronoid, and is curved forward at the summit so as to present a prominent tip, its base being contracted where it joins the shaft. This is the narrowest part of the upper end of the ulna, and consequently the most usual seat of fracture. The posterior surface of the olecranon, directed backward, is triangular, smooth, subcutaneous, and covered by a bursa. Its upper surface, directed upward, is of a quadrilateral form, marked behind by a rough impression for the attachment of the Triceps muscle, and in front, near the margin, by a slight transverse groove for the attachment of part of the posterior ligament of the elbow-joint. Its anterior surface is smooth, concave, covered with cartilage in the recent state, and forms the upper and back part of the great sigmoid cavity. The lateral borders present a continuation of the same groove that was seen on the margin of the superior surface; they serve for the attachment of ligaments—viz. the back part of the internal lateral ligament internally, the posterior ligament externally. To the inner border is also attached a part of the Flexor carpi ulnaris, while to the outer border is attached the Anconeus.

The **Coronoid Process** (*κορώνῃ*, anything hooked like a crow's beak [and *εἶδος*, like]) is a rough triangular eminence of bone which projects horizontally forward from the upper and front part of the ulna, forming the lower part of the great sigmoid cavity. Its base is continuous with the shaft and of considerable strength, so much so that fracture of it is an accident of rare occurrence. Its apex is pointed, slightly curved upward, and received into the coronoid depression of the humerus in flexion of the forearm. Its upper surface is smooth, concave, and forms the lower part of the great sigmoid cavity. The under surface is concave, and marked internally by a rough impression for the insertion of the Brachialis anticus. At the junction of this surface with the shaft is a rough eminence, the *tubercle of the ulna*, for the attachment of the oblique ligament. Its outer surface presents a narrow, oblong, articular depression, the *lesser sigmoid* cavity. The inner surface, by its prominent free margin, serves for the attachment of part of the internal lateral ligament. At the front part of this surface is a small rounded eminence for the attachment of one head of the Flexor digitorum sublimis; behind the eminence, a depression for part of the origin of the Flexor profundus digitorum; and, descend-

---

[1] The angles at the elbow and the knee should be ten degrees, but are exaggerated to emphasize them.

Fig. 208.

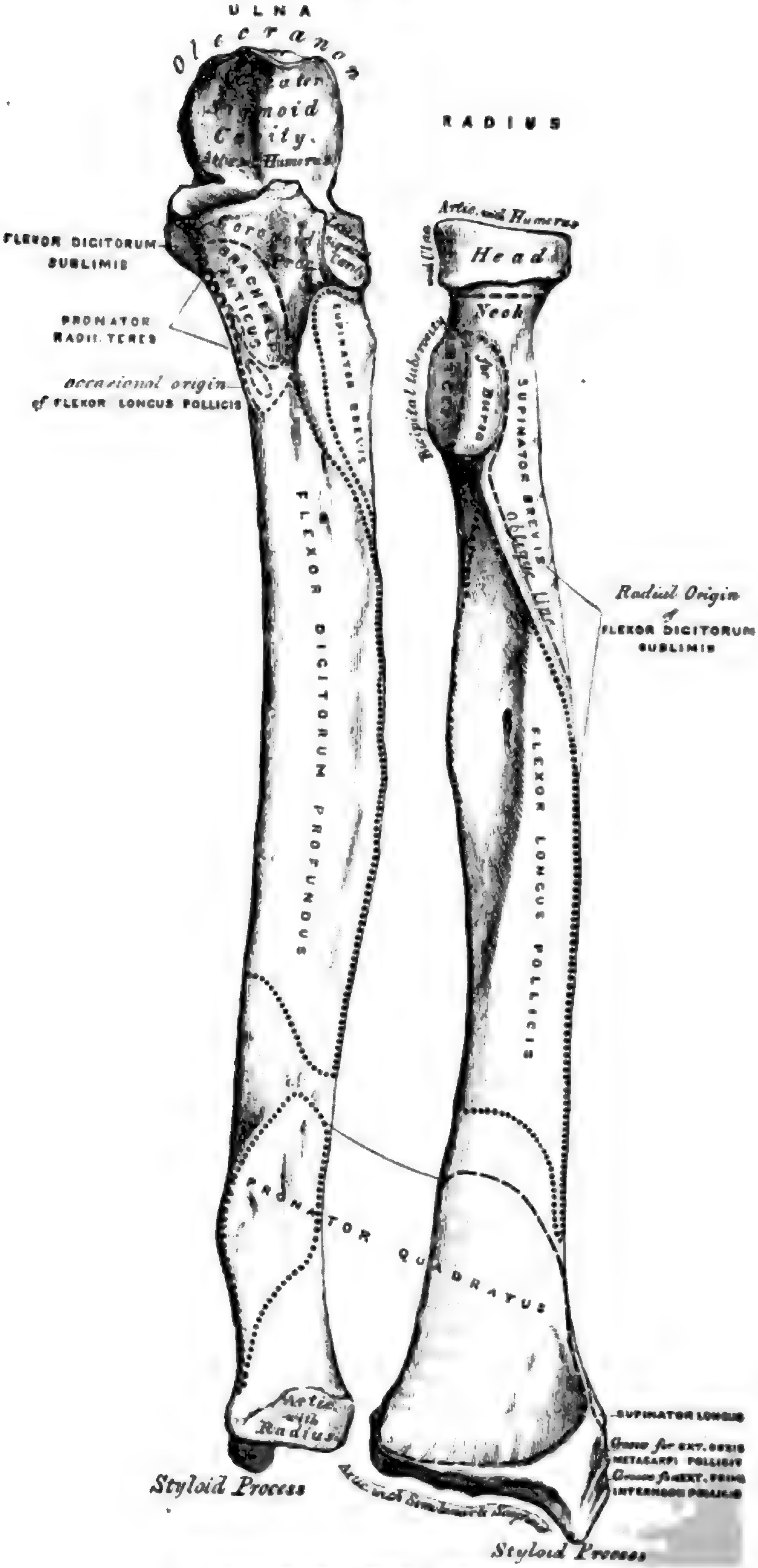
ULNA
Olecranon
Greater Sigmoid Cavity.
Artic. with Humerus
RADIUS
FLEXOR DIGITORUM SUBLIMIS
Coronoid Proc.
Cavity
BRACHIALIS ANTICUS
PRONATOR RADII TERES
occasional origin of FLEXOR LONGUS POLLICIS
SUPINATOR BREVIS
Artic. with Humerus
Artic. with Ulna
Head
Neck
Bicipital tubercle
for Bursa
BICEPS
SUPINATOR BREVIS
Oblique line
Radial Origin of FLEXOR DIGITORUM SUBLIMIS
FLEXOR DIGITORUM PROFUNDUS
FLEXOR LONGUS POLLICIS
PRONATOR QUADRATUS
Artic. with Radius
Styloid Process
Artic. with Scaphoid & Semilunar
SUPINATOR LONGUS
Groove for EXT. OSSIS METACARPI POLLICIS
Groove for EXT. PRIMI INTERNODII POLLICIS
Styloid Process

Bones of the Left Forearm, anterior surface.

ing from the eminence, a ridge which gives attachment to one head of the Pronator radii teres. Occasionally, the Flexor longus pollicis arises from the lower part of the coronoid process by a rounded bundle of muscular fibres.

The **Greater Sigmoid Cavity,** so called from its resemblance to the old shape of the Greek letter Σ, is a semilunar depression of large size formed by the olecranon and coronoid processes, and serving for articulation with the trochlear surface of the humerus. About the middle of either lateral border of this cavity is a notch which contracts it somewhat and serves to indicate the junction of the two processes of which it is formed. The cavity is concave from above downward, and divided into two lateral parts by a smooth elevated ridge which runs from the summit of the olecranon to the tip of the coronoid process. Of these two portions, the internal is the larger; it is slightly concave transversely, the external portion being convex above, slightly concave below.

The **Lesser Sigmoid Cavity** is a narrow, oblong, articular depression placed on the outer side of the coronoid process and serving for articulation with the head of the radius. It is concave from before backward, and its extremities, which are prominent, serve for the attachment of the orbicular ligament.

The **shaft** is prismatic in form at its upper part, and curved from behind forward and from within outward, so as to be convex behind and externally; its central part is quite straight, its lower part rounded, smooth, and bent a little outward; it tapers gradually from above downward, and presents for examination three borders and three surfaces.

The **anterior border** commences above at the prominent inner angle of the coronoid process, and terminates below in front of the styloid process. It is well marked above, smooth and rounded in the middle of its extent, and affords attachment to the Flexor profundus digitorum: its lower fourth, bounded by an oblique ridge, serves for the attachment of the Pronator quadratus. It separates the anterior from the internal surface.

The **posterior border** commences above at the apex of the triangular surface at the back part of the olecranon, and terminates below at the back part of the styloid process; it is well marked in the upper three-fourths, and gives attachment to an aponeurosis common to the Flexor carpi ulnaris, the Extensor carpi ulnaris, and the Flexor profundus digitorum muscles; its lower fourth is smooth and rounded. This border separates the internal from the posterior surface. [It is subcutaneous, and can be readily felt throughout the entire length of the bone—a point of great value in injuries.]

The **external** or **interosseous border** commences above by two lines, which converge one from each extremity of the lesser sigmoid cavity, enclosing between them a triangular space for the attachment of part of the Supinator brevis, and terminates below at the middle of the head of the ulna. Its two middle fourths are very prominent, and serve for the attachment of the interosseous membrane; its lower fourth is smooth and rounded. This border separates the anterior from the posterior surface.

The **anterior surface,** much broader above than below, is concave in the upper three-fourths of its extent, and affords attachment to the Flexor profundus digitorum; its lower fourth, also concave, to the Pronator quadratus. The lower fourth is separated from the remaining portion of the bone by a prominent ridge directed obliquely from above downward and inward; this ridge marks the extent of attachment of the Pronator above. At the junction of the upper with the middle third of the bone is the nutrient canal, directed obliquely upward and inward.

The **posterior surface,** directed backward and outward, is broad and concave above, somewhat narrower and convex in the middle of its course, narrow, smooth, and rounded below. It presents above an *oblique ridge* which runs from the posterior extremity of the lesser sigmoid cavity downward to the posterior border; the triangular surface above this ridge receives the insertion of the Anconeus muscle, whilst the ridge itself affords attachment to the Supinator brevis. The surface of bone below this is subdivided by a longitudinal ridge, sometimes called the *perpen*

FIG. 209.

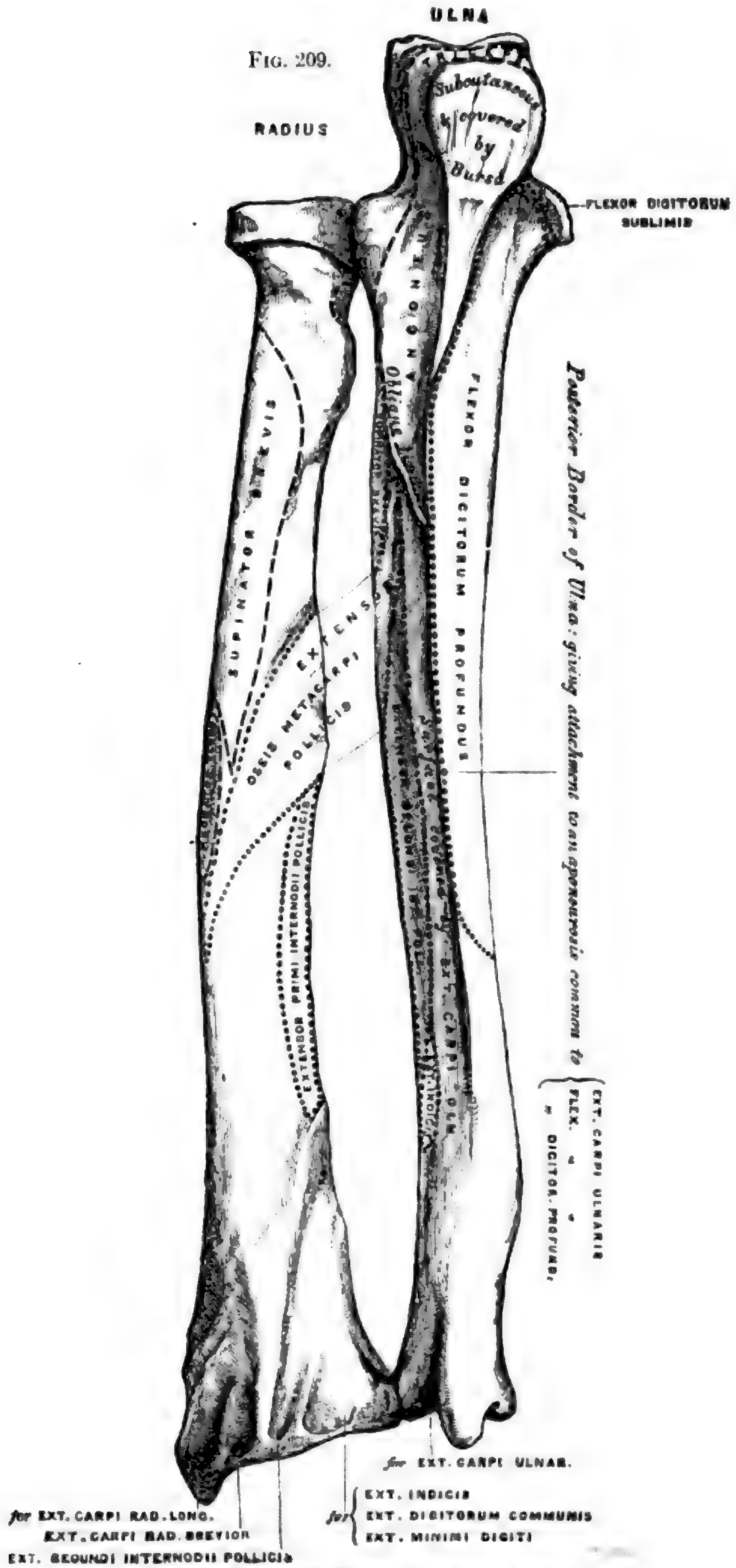
ULNA
RADIUS
Subcutaneous & covered by Bursa
FLEXOR DIGITORUM SUBLIMIS
ANCONEUS
Oblique line
SUPINATOR BREVIS
EXTENSOR OSSIS METACARPI POLLICIS
FLEXOR DIGITORUM PROFUNDUS
Surface covered by ext. carpi uln.
EXTENSOR PRIMI INTERNODII POLLICIS
Posterior Border of Ulna: giving attachment to an aponeurosis common to
EXT. CARPI ULNARIS
FLEX. " "
" DIGITOR. PROFUND.
for EXT. CARPI ULNAR.
for EXT. INDICIS
EXT. DIGITORUM COMMUNIS
EXT. MINIMI DIGITI
for EXT. CARPI RAD. LONG.
EXT. CARPI RAD. BREVIOR
EXT. SECUNDI INTERNODII POLLICIS

Bones of the Left Forearm, posterior surface.

dicular line, into two parts: the internal part is smooth, concave, and gives origin to (occasionally is merely covered by) the Extensor carpi ulnaris; the external portion, wider and rougher, gives attachment from above downward to part of the Supinator brevis, the Extensor ossis metacarpi pollicis, the Extensor secundi internodii pollicis, and the Extensor indicis muscles.

The **internal surface** is broad and concave above, narrow and convex below. It gives attachment by its upper three-fourths to the Flexor profundus digitorum muscle: its lower fourth is subcutaneous.

The **Lower Extremity** of the ulna is of small size and excluded from the articulation of the wrist-joint. It presents for examination two eminences, the outer and larger of which is a rounded articular eminence, termed the *head* of the ulna; the inner, narrower and more projectiug, is a non-articular eminence, the *styloid process.* The *head* presents an articular facet, part of which, of an oval form, is directed downward and plays on the surface of the triangular fibro-cartilage, which separates it from the wrist-joint; the remaining portion, directed outward, is narrow, convex, and received into the sigmoid cavity of the radius. The *styloid process* projects from the inner and back part of the bone, and descends a little lower than the head, terminating in a rounded summit which affords attachment to the internal lateral ligament of the wrist. The head is separated from the styloid process by a depression for the attachment of the triangular interarticular fibro-cartilage, and behind by a shallow groove for the passage of the tendon of the Extensor carpi ulnaris. [When the hand is supine, the elevation seen at the lower end of the ulna is the styloid process; but when the hand is prone, a similar but more globular elevation in the same place is the head of the ulna, the styloid process being then antero-external. This change of relation can be well studied in the living model, as well as seen in an articulated skeleton.]

Structure.—Similar to that of the other long bones.

Development.—By *three* centres: one for the shaft, one for the inferior extremity, and one for the olecranon (Fig. 210). Ossification commences near the middle of the shaft about the eighth week, and soon extends through the greater part of the bone. At birth the ends are cartilaginous. About the fourth year a separate osseous nucleus appears in the middle of the head, which soon extends into the styloid process. About the tenth year ossific matter appears in the olecranon near its extremity, the chief part of this process being formed from an extension of the shaft of the bone into it. At about the sixteenth year the upper epiphysis becomes joined, and at about the twentieth year the lower one.

Fig. 210.

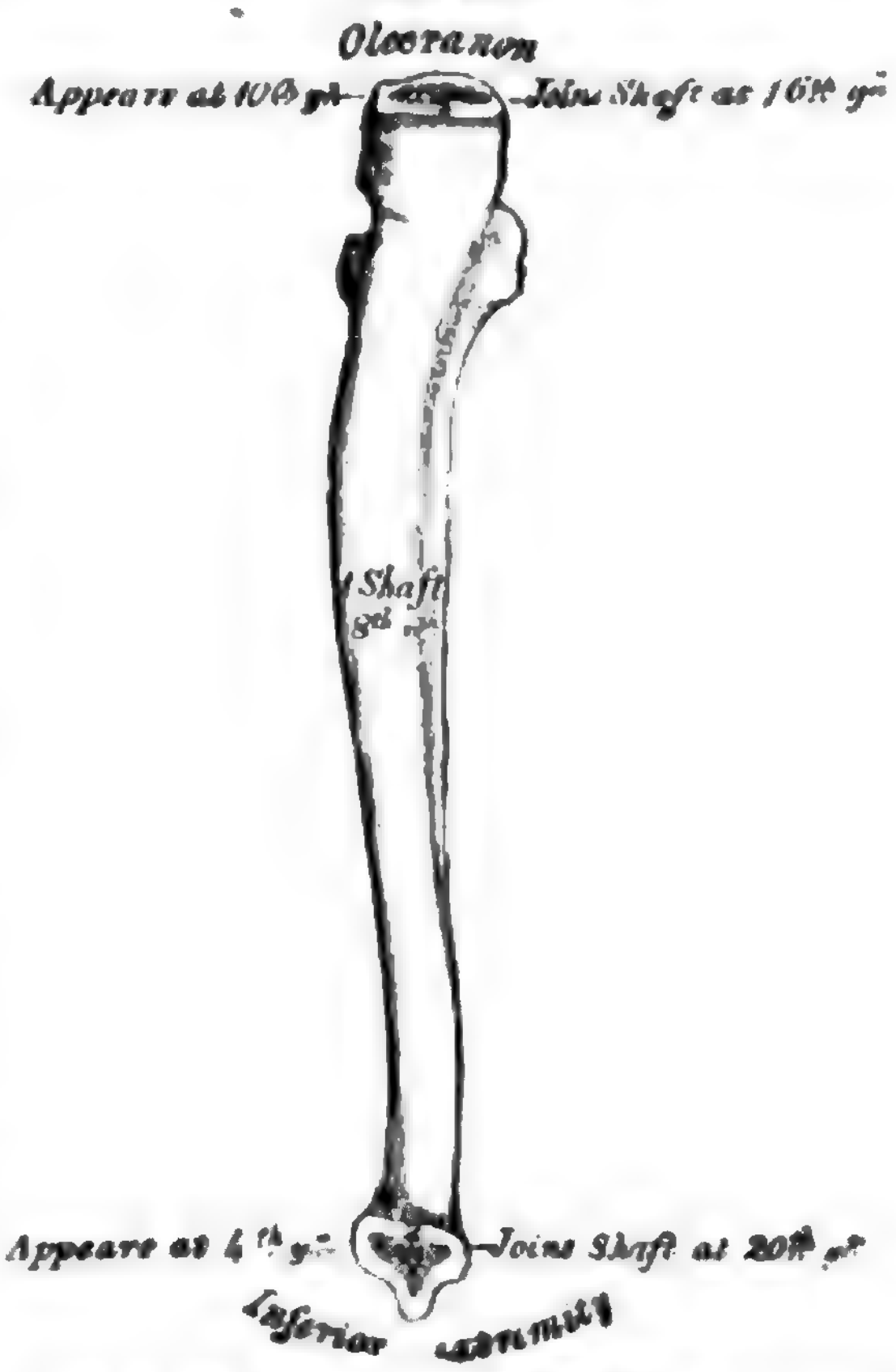

Plan of the Development of the Ulna, by three centres.

Articulations.—With the humerus and radius.

Attachment of Muscles.—To sixteen: to the olecranon, the Triceps, Anconeus, and one head of the Flexor carpi ulnaris; to the coronoid process, the Brachialis anticus, Pronator radii teres, Flexor sublimis digitorum, and Flexor profundus digitorum, occasionally also the Flexor longus pollicis; to the shaft, the Flexor profundus digitorum, Pronator quadratus, Flexor carpi ulnaris, Extensor carpi ulnaris, Anconeus, Supinator brevis, Extensor ossis metacarpi pollicis, Extensor secundi internodii pollicis, and Extensor indicis.

The Radius.

The **Radius** (*radius*, a ray, or spoke of a wheel) is situated on the outer side of the forearm, lying parallel with the ulna, which exceeds it in length and size. [It lies nearly parallel with the ulna in the anatomical position—*i. e.* the thumb turned out. When the hand is pronated—*i. e.* thumb in—the radius crosses the ulna, forming a very long X.] Its upper end is small, and forms only a small part of the elbow-joint, but its lower end is large, and forms the chief part of the wrist. It is one of the long bones, prismatic in form, slightly curved longitudinally, and, like other long bones, has a shaft and two extremities.

The **Upper Extremity** presents a head, neck, and tuberosity. The *head* is of a cylindrical form, depressed on its upper surface into a shallow cup which articulates with the capitellum or radial head of the humerus. Around the circumference of the head is a smooth articular surface coated with cartilage in the recent state, broad internally where it rotates within the lesser sigmoid cavity of the ulna, narrow in the rest of its circumference to play in the orbicular ligament. The head is supported on a round, smooth, and constricted portion of bone called the *neck*, which presents, behind, a slight ridge for the attachment of part of the Supinator brevis. Beneath the neck, at the inner and front aspect of the bone, is a rough eminence, the *bicipital tuberosity*. Its surface is divided into two parts by a vertical line—a posterior rough portion for the insertion of the tendon of the Biceps muscle; and an anterior smooth portion, on which a bursa is interposed between the tendon and the bone. [The head of the bone is always marked by a *dimple*, where it can be readily felt, and its rotation or non-rotation with the lower end be determined—a matter of importance in injuries. This dimple is very marked in extension, but disappears by the time semiflexion is reached.]

The **shaft** of the bone is prismoid in form, narrower above than below, and slightly curved, so as to be convex outward. It presents three surfaces, separated by three borders.

The **anterior border** extends from the lower part of the tuberosity above to the anterior part of the base of the styloid process below. It separates the anterior from the external surface. Its upper third is very prominent, and from its oblique direction, downward and outward, has received the name of the *oblique line of the radius*. It gives attachment externally to the Supinator brevis; internally to the Flexor longus pollicis; and between these to the Flexor digitorum sublimis. The middle third of the anterior border is indistinct and rounded. Its lower fourth is sharp, prominent, affords attachment to the Pronator quadratus, and terminates in a small tubercle, into which is inserted the tendon of the Supinator longus.

The **posterior border** commences above, at the back part of the neck of the radius, and terminates below, at the posterior part of the base of the styloid process; it separates the posterior from the external surface. It is indistinct above and below, but well marked in the middle third of the bone.

The **internal** or **interosseous border** commences above, at the back part of the tuberosity, where it is rounded and indistinct, becomes sharp and prominent as it descends, and at its lower part divides into two ridges, which descend to the anterior and posterior margins of the sigmoid cavity. This border separates the anterior from the posterior surface, and has the interosseous membrane attached to it throughout the greater part of its extent.

The **anterior surface** is narrow and concave for its upper two-thirds, and gives attachment to the Flexor longus pollicis muscle; below, it is broad and flat and gives attachment to the Pronator quadratus. At the junction of the upper and middle thirds of this surface is the nutrient foramen, which is directed obliquely upward.

The **posterior surface** is rounded, convex, and smooth in the upper third of its extent, and covered by the Supinator brevis muscle. Its middle third is broad, slightly concave, and gives attachment to the Extensor ossis metacarpi pollicis above, the Extensor primi internodii pollicis below. Its lower third is broad, convex, and covered by the tendons of the muscles, which subsequently run in the grooves on the lower end of the bone.

The **external surface** is rounded and convex throughout its entire extent. Its upper third gives attachment to the Supinator brevis muscle. About its centre is seen a rough ridge for the insertion of the Pronator radii teres muscle. Its lower part is narrow, and covered by the tendons of the Extensor ossis metacarpi pollicis and Extensor primi internodii pollicis muscles.

The **Lower Extremity** of the radius is large, of quadrilateral form, and provided with two articular surfaces—one at the extremity for articulation with the carpus, and one at the inner side of the bone for articulation with the ulna. The carpal articular surface is of triangular form, concave, smooth, and divided by a slight antero-posterior ridge into two parts. Of these, the external is large, of a triangular form, and articulates with the scaphoid bone; the inner, smaller and quadrilateral, articulates with the semilunar. The articular surface for the ulna is called the *sigmoid cavity* of the radius; it is narrow, concave, smooth, and articulates with the head of the ulna. The circumference of this end of the bone presents three surfaces—an anterior, external, and posterior. The *anterior surface*, rough and irregular, affords attachment to the anterior ligament of the wrist-joint. The *external surface* is prolonged obliquely downward into a strong conical projection, the *styloid process*, which gives attachment by its base to the tendon of the Supinator longus, and by its apex to the external lateral ligament of the wrist-joint. The outer surface of this process is marked by two grooves, which run obliquely downward and forward, and are separated from one another by an elevated ridge. The anterior one gives passage to the tendon of the Extensor ossis metacarpi pollicis, the posterior one to the tendon of the Extensor primi internodii pollicis. The *posterior surface* is convex, affords attachment to the posterior ligament of the wrist, and is marked by three grooves. Proceeding from without inward, the first groove is broad, but shallow, and subdivided into two by a slightly elevated ridge: the outer of these two transmits the tendon of the Extensor carpi radialis longior, the inner the tendon of the Extensor carpi radialis brevior. The second, which is near the centre of the bone, is a deep but narrow groove directed obliquely from above, downward and outward; it transmits the tendon of the Extensor secundi internodii pollicis. The third, lying most internally, is a broad groove for the passage of the tendons of the Extensor indicis, Extensor communis digitorum, and Extensor minimi digiti, the tendon of the last-named muscle passing through the groove at the point of articulation of the radius with the ulna and lying in a separate sheath of the annular ligament.

FIG. 211.

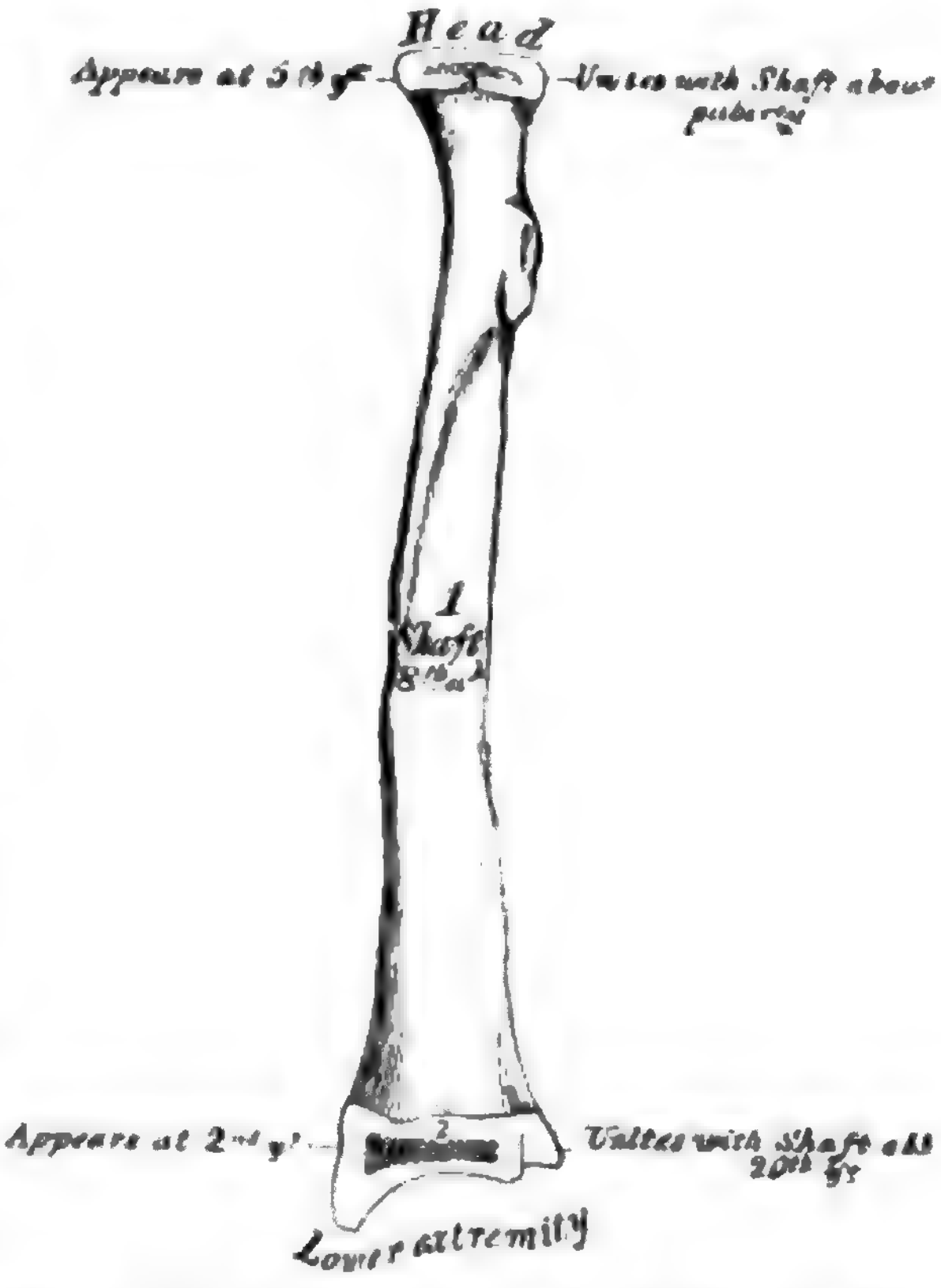

Plan of the Development of the Radius, by three centres.

Structure.—Similar to that of the other long bones.

Development (Fig. 211).—By *three* centres: one for the shaft, and one for each extremity. That for the shaft makes its appearance near the centre of the bone, soon after the development of the humerus commences. At birth the shaft is ossified, but the ends of the bone are cartilaginous. About the end of the second year ossification commences in the lower epiphysis, and about the fifth year in the upper one. At the age of seventeen or eighteen the upper epiphysis becomes joined to the shaft, the lower epiphysis becoming united about the twentieth year.

Articulations.—With four bones: the humerus, ulna, scaphoid, and semilunar.

Attachment of Muscles.—To nine: to the tuberosity, the Biceps; to the oblique ridge, the Supinator brevis, Flexor sublimis digitorum, and Flexor longus pollicis; to the shaft (its anterior surface), the Flexor longus pollicis and Pronator quadratus; (its posterior surface), the Extensor ossis metacarpi pollicis and Extensor primi internodii pollicis; (its outer surface), the Pronator radii teres; and to the styloid process, the Supinator longus.

THE HAND.

The skeleton of the Hand is subdivided into three segments—the Carpus or wrist-bones, the Metacarpus or bones of the palm, and the Phalanges or bones of the fingers. [The anatomical position of the hand is with the thumbs out and palms forward.]

THE CARPUS.

The bones of the **Carpus** (*καρπος*, the wrist), eight in number, are arranged in two rows. Those of the upper row, enumerated from the radial to the ulnar side, are the scaphoid, semilunar, cuneiform, and pisiform; those of the lower row, enumerated in the same order, are the trapezium, trapezoid, os magnum, and unciform.

COMMON CHARACTERS OF THE CARPAL BONES.

Each bone (excepting the pisiform) presents six surfaces. Of these, the *anterior* or *palmar* and the *posterior* or *dorsal* are rough for ligamentous attachment, the dorsal surface being generally the broader of the two. The *superior* [or *proximal*] and *inferior* [or *distal*] are articular, the superior generally convex, the inferior concave; and the *internal* and *external* are also articular when in contact with contiguous bones, otherwise rough and tubercular. Their structure in all is similar, consisting of cancellous tissue enclosed in a layer of compact bone. Each bone is also developed from a single centre of ossification.

BONES OF THE UPPER ROW (Figs. 212, 213).

The **Scaphoid** (*σκαφή*, a boat, and *εἶδος*, like) is the largest bone of the first row. It has received its name from its fancied resemblance to a boat, being broad at one end and narrowed like a prow at the opposite. It is situated at the upper and outer part of the carpus, its direction being from above downward, outward, and forward. The *superior surface* is convex, smooth, of triangular shape, and articulates with the lower end of the radius. The *inferior surface*, directed downward, outward, and backward, is smooth, convex, also triangular, and divided by a slight ridge into two parts, the external of which articulates with the trapezium, the inner with the trapezoid. The *posterior* or *dorsal surface* presents a narrow, rough groove which runs the entire breadth of the bone and serves for the attachment of ligaments. The *anterior* or *palmar surface* is concave above, and elevated at its lower and outer part into a prominent rounded tubercle, which projects forward from the front of the carpus and gives attachment to the anterior annular ligament of the wrist. The *external surface* is rough and narrow, and gives attachment to the external lateral ligament of the wrist. The *internal surface* presents two articular facets; of these, the superior or smaller one is flattened, of semilunar form, and articulates with the semilunar; the inferior or larger is concave, forming with the semilunar bone a concavity for the head of the os magnum.

To ascertain to which side the bone belongs, hold it with the superior or radial convex articular surface upward, and the posterior surface—*i. e.* the narrow non-

Fig. 212.

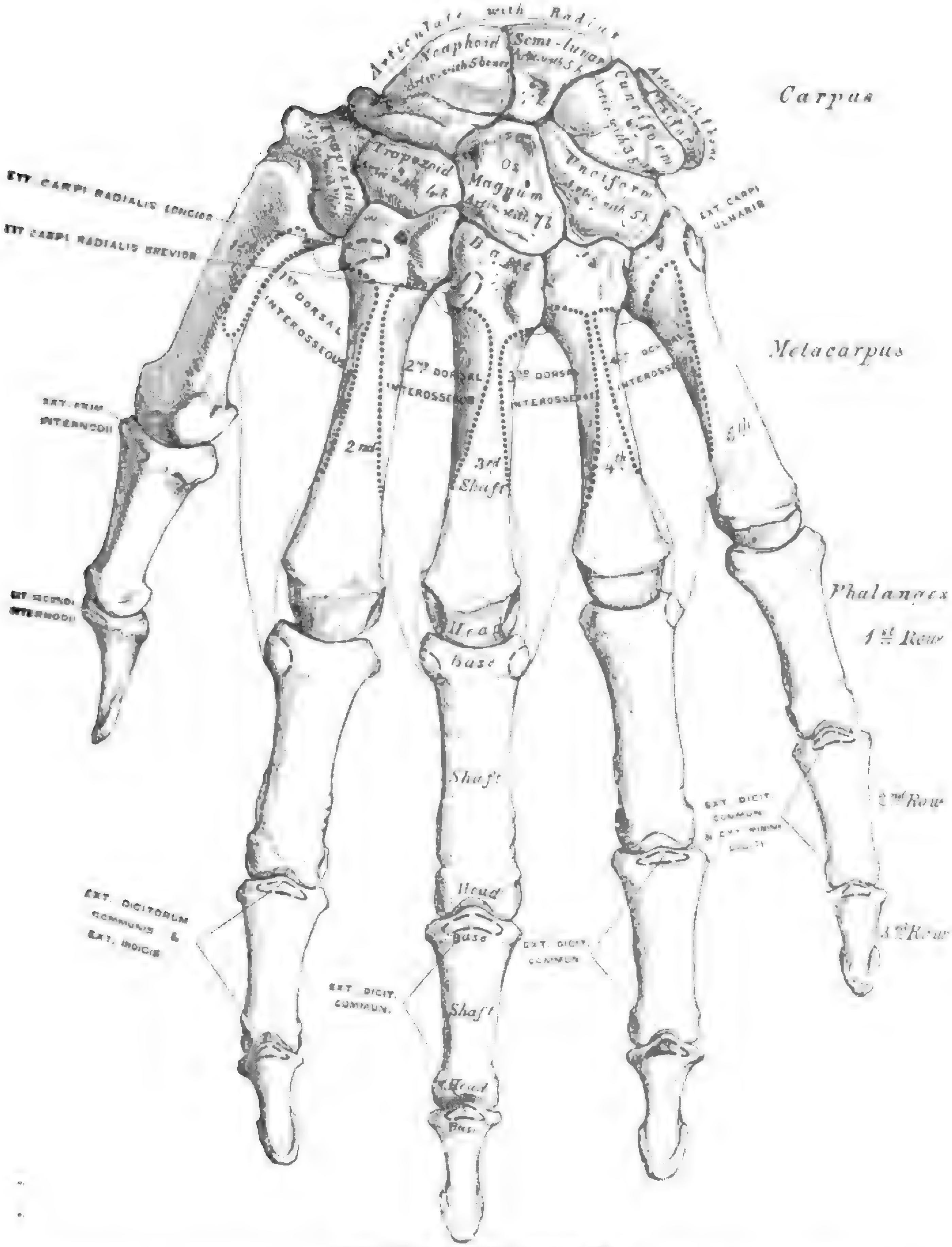
Articulate with Radius
Scaphoid
Artic. with 5 bones
Semi-lunar
Artic. with 5 b.
Cuneiform
Artic. with 3 b.
Pisiform
Carpus
Trapezium
Trapezoid
Artic. with 4 b.
Os Magnum
Artic. with 7 b.
Unciform
Artic. with 5 b.
EXT. CARPI RADIALIS LONGIOR
EXT. CARPI RADIALIS BREVIOR
EXT. CARPI ULNARIS
Base
1ST DORSAL INTEROSSEOUS
2ND DORSAL INTEROSSEOUS
3RD DORSAL INTEROSSEOUS
4TH DORSAL INTEROSSEOUS
Metacarpus
EXT. PRIM. INTERNODII
2nd
3rd
Shaft
4th
5th
EXT. SECUND. INTERNODII
Head
base
Phalanges
1st Row
Shaft
EXT. DIGIT. COMMUN. & EXT. MINIMI DIGITI
2nd Row
Head
Base
EXT. DIGITORUM COMMUNIS & EXT. INDICIS
EXT. DIGIT. COMMUN.
EXT. DIGIT. COMMUN.
3rd Row
Shaft
Head
Base

Bones of the Left Hand, dorsal surface.

articular grooved surface—toward you. The tubercle on the outer surface points to the side to which the bone belongs.[1]

---

[1] In these directions each bone is supposed to be placed in its natural position; that is, such a position as it would occupy when the arm is hanging by the side, the forearm in a position of supination, the thumb being directed outward and the palm of the hand looking forward.

Articulations.—With five bones: the radius above, trapezium and trapezoid below, os magnum and semilunar internally.

The **Semilunar** (*semi*, half; *luna*, moon) bone may be distinguished by its deep concavity and crescentic outline. It is situated in the centre of the upper row of the carpus, between the scaphoid and cuneiform. The *superior surface*, convex, smooth, and bounded by four edges, articulates with the radius. The *inferior surface* is deeply concave, and of greater extent from before backward than transversely; it articulates with the head of the os magnum, and by a long narrow facet (separated by a ridge from the general surface) with the unciform bone. The *anterior* or *palmar* and *posterior* or *dorsal surfaces* are rough, for the attachment of ligaments, the former being the broader and of somewhat rounded form. The *external surface* presents a narrow, flattened, semilunar facet for articulation with the scaphoid. The *internal surface* is marked by a smooth, quadrilateral facet, for articulation with the cuneiform.

Hold it with the convex articular surface for the radius upward and the narrowest non-articular surface toward you. The semilunar facet for the scaphoid will be on the side to which the bone belongs.

Articulations.—With five bones: the radius above, os magnum and unciform below, scaphoid and cuneiform on either side.

The **Cuneiform** (*cuneus*, a wedge, and *forma*, likeness) may be distinguished by its pyramidal shape (*l'Os Pyramidal*), and by its having an oval, isolated facet for articulation with the pisiform bone. It is situated at the upper and inner side of the carpus. The *superior surface* presents an internal, rough, non-articular portion, and an external or articular portion, which is convex, smooth, and articulates with the interarticular fibro-cartilage of the wrist. The *inferior surface*, directed outward, is concave, sinuously curved, and smooth, for articulation with the unciform. The *posterior* or *dorsal surface* is rough, for the attachment of ligaments. The *anterior* or *palmar surface* presents at its inner side an oval facet, for articulation with the pisiform, and is rough externally, for ligamentous attachment. The *external surface*, the base of the pyramid, is marked by a flat, quadrilateral, smooth facet, for articulation with the semilunar. The *internal surface*, the summit of the pyramid, is pointed and roughened, for the attachment of the internal lateral ligament of the wrist.

Hold the bone with the surface supporting the pisiform facet away from you, and the concavo-convex surface for the unciform downward. The base of the wedge (*i. e.* the broad end of the bone) will be on the side to which it belongs.

Articulations.—With three bones: the semilunar externally, the pisiform in front, the unciform below; and with the triangular interarticular fibro-cartilage, which separates it from the lower end of the ulna.

The **Pisiform** (*pisum*, a pea; *forma*, likeness) may be known by its small size and by its presenting a single articular facet. It is situated at the anterior and inner side of the carpus, is nearly circular in form, and presents on its *posterior surface* a smooth oval facet, for articulation with the cuneiform. This facet approaches the superior, but not the inferior, border of the bone. The *anterior* or *palmar surface* is rounded and rough, and gives attachment to the anterior annular ligament. The *outer* and *inner surfaces* are also rough, the former being convex, the latter usually concave.

Hold the bone with the posterior surface, that which presents the articular facet, toward you, in such a manner that the faceted portion of the surface is uppermost. The outer, convex surface will point to the side to which it belongs.

Articulations.—With one bone, the cuneiform.

Attachment of Muscles.—To two: the Flexor carpi ulnaris and Abductor minimi digiti, and to the anterior annular ligament.

Bones of the Lower Row (Figs. 212, 213).

The **Trapezium** (*τράπεζα*, a table) is of very irregular form. It may be distinguished by a deep groove, for the tendon of the Flexor carpi radialis muscle. It is situated at the external and inferior part of the carpus, between the scaphoid and first metacarpal bone. The *superior surface*, concave and smooth, is directed upward and inward, and articulates with the scaphoid. The *inferior surface*, directed downward and outward, is oval, concave from side to side, convex from before backward, so as to form a saddle-shaped surface, for articulation with the base of the first metacarpal bone. The *anterior* or *palmar surface* is narrow and rough. At its upper

Fig. 213.

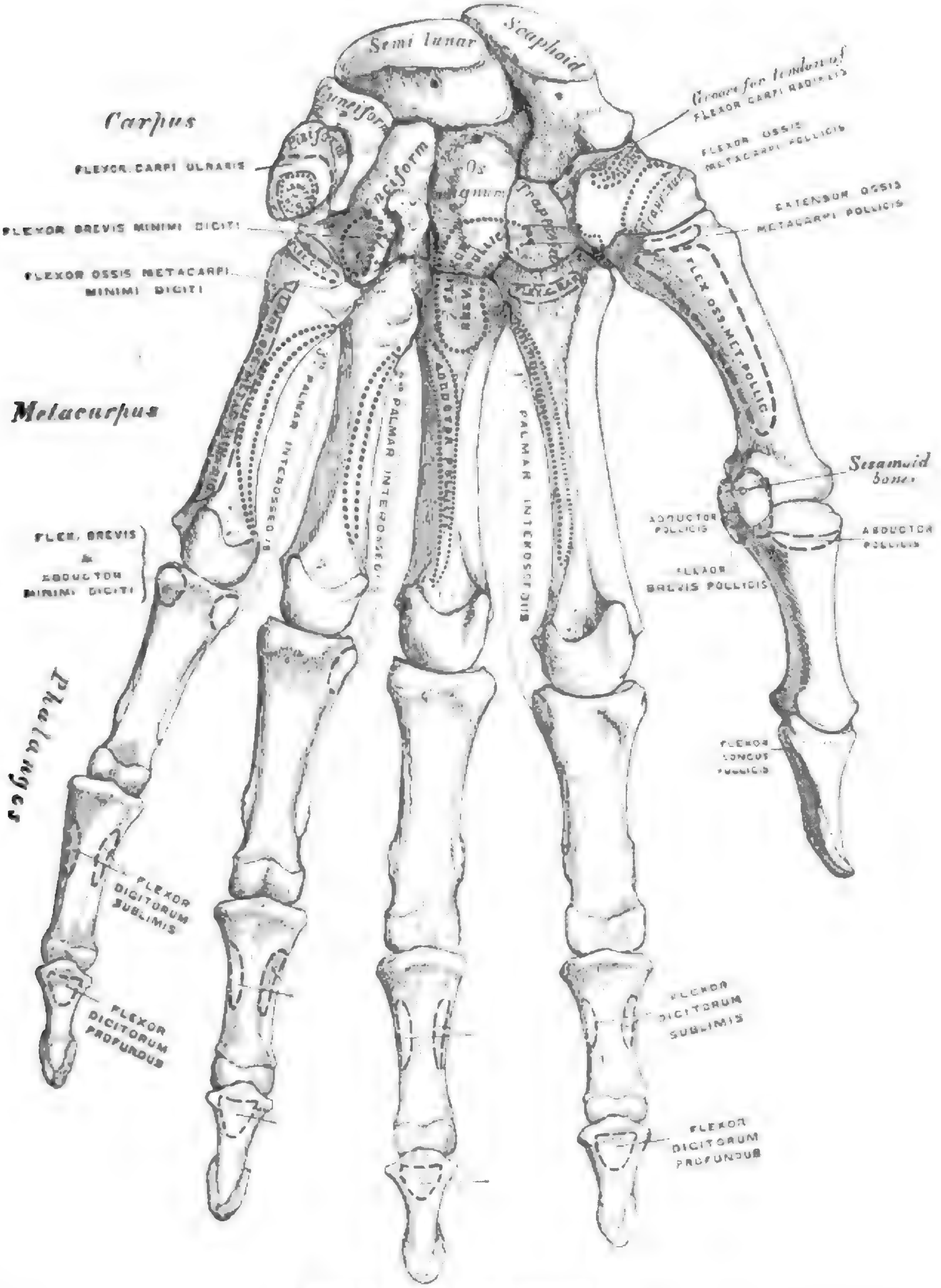
Semi lunar
Scaphoid
Cuneiform
Pisiform
Unciform
Os magnum
Trapezoid
Trapezium
Carpus
FLEXOR CARPI ULNARIS
FLEXOR BREVIS MINIMI DIGITI
FLEXOR OSSIS METACARPI MINIMI DIGITI
Groove for tendon of FLEXOR CARPI RADIALIS
FLEXOR OSSIS METACARPI POLLICIS
EXTENSOR OSSIS METACARPI POLLICIS
FLEX. OSS. MET. POLLIC.
Metacarpus
PALMAR INTEROSSEOUS
PALMAR INTEROSSEOUS
ADDUCTOR POLLICIS
PALMAR INTEROSSEOUS
Sesamoid bones
ADDUCTOR POLLICIS
ABDUCTOR POLLICIS
FLEXOR BREVIS POLLICIS
FLEX. BREVIS & ABDUCTOR MINIMI DIGITI
Phalanges
FLEXOR LONGUS POLLICIS
FLEXOR DIGITORUM SUBLIMIS
FLEXOR DIGITORUM PROFUNDUS
FLEXOR DIGITORUM SUBLIMIS
FLEXOR DIGITORUM PROFUNDUS

Bones of the Left Hand, palmar surface.

LANE LIBRARY STANFORD

part is a deep groove running from above obliquely downward and inward; it transmits the tendon of the Flexor carpi radialis, and is bounded externally by a prominent ridge, the oblique ridge of the trapezium. This surface gives attachment to the Abductor pollicis, Flexor ossis metacarpi pollicis, and Flexor brevis pollicis muscles and the anterior annular ligament. The *posterior* or *dorsal surface* is rough, and the *external surface* also broad and rough, for the attachment of ligaments. The *internal surface* presents two articular facets: the upper one, large and concave, articulates with the trapezoid; the lower one, narrow and flattened, with the base of the second metacarpal bone.

Hold the bone with the saddle-shaped surface downward and the grooved surface away from you. The prominent, rough, non-articular surface points to the side to which the bone belongs.

Articulations.—With four bones: the scaphoid above, the trapezoid and second metacarpal bones internally, the first metacarpal below.

Attachment of Muscles.—Abductor pollicis, Flexor ossis metacarpi pollicis, and part of the Flexor brevis pollicis.

The **Trapezoid** is the smallest bone in the second row. It may be known by its wedge-shaped form, the broad end of the wedge forming the dorsal, the narrow end the palmar surface, and by its having four articular surfaces touching each other and separated by sharp edges. The *superior surface*, quadrilateral in form, smooth and slightly concave, articulates with the scaphoid. The *inferior surface* articulates with the upper end of the second metacarpal bone; it is convex from side to side, concave from before backward, and subdivided by an elevated ridge into two unequal lateral facets. The *posterior* or *dorsal* and *anterior* or *palmar surfaces* are rough, for the attachment of ligaments, the former being the larger of the two. The *external surface*, convex and smooth, articulates with the trapezium. The *internal surface* is concave and smooth in front, for articulation with the os magnum; rough behind, for the attachment of an interosseous ligament.

Hold the bone with the larger non-articular surface toward you and the smooth, quadrilateral articular surface upward. The convex articular surface will point to the side to which the bone belongs.[1]

Articulations.—With four bones: the scaphoid above, second metacarpal bone below, trapezium externally, os magnum internally.

Attachment of Muscles.—Part of the Flexor brevis pollicis.

The **Os Magnum** is the largest bone of the carpus, and occupies the centre of the wrist. It presents above a rounded portion or head, which is received into the concavity formed by the scaphoid and semilunar bones; a constricted portion or neck; and below, the body. The *superior surface* is rounded, smooth, and articulates with the semilunar. The *inferior surface* is divided by two ridges into three facets, for articulation with the second, third, and fourth metacarpal bones, that for the third (the middle facet) being the largest of the three. The *posterior* or *dorsal surface* is broad and rough; the *anterior* or *palmar*, narrow, rounded, and also rough, for the attachment of ligaments. The *external surface* articulates with the trapezoid by a small facet at its anterior inferior angle, behind which is a rough depression for the attachment of an interosseous ligament. Above this is a deep and rough groove which forms part of the neck and serves for the attachment of ligaments, bounded superiorly by a smooth convex surface, for articulation with the scaphoid. The *internal surface* articulates with the unciform by a smooth, concave, oblong facet which occupies its posterior and superior parts, and is rough in front, for the attachment of an interosseous ligament.

Hold the bone with the broader, non-articular surface toward you and the head upward. The small articular facet at the anterior inferior angle of the external surface will point to the side to which the bone belongs.

---

[1] Occasionally in a badly-marked bone there is some difficulty in ascertaining to which side the bone belongs; the following method will sometimes be found useful: Hold the bone with its broader, non-articular surface upward, so that its sloping border is directed toward you. The border will slope to the side to which the bone belongs.

Articulations.—With seven bones: the scaphoid and semilunar above; the second, third, and fourth metacarpal below; the trapezoid on the radial side; and the unciform on the ulnar side.

Attachment of Muscles.—Part of the Flexor brevis pollicis.

The **Unciform** (*uncus*, a hook; *forma*, likeness) may be readily distinguished by its wedge-shaped form and the hook-like process that projects from its palmar surface. It is situated at the inner and lower angle of the carpus, with its base downward, resting on the two inner metacarpal bones and its apex directed upward and outward. The *superior surface*, the apex of the wedge, is narrow, convex, smooth, and articulates with the semilunar. The *inferior surface* articulates with the fourth and fifth metacarpal bones, the concave surface for each being separated by a ridge which runs from before backward. The *posterior* or *dorsal surface* is triangular and rough, for ligamentous attachment. The *anterior* or *palmar surface* presents, at its lower and inner side, a curved hook-like process of bone, the unciform process, directed from the palmar surface forward and outward. It gives attachment by its apex to the annular ligament, by its inner surface to the Flexor brevis minimi digiti and the Flexor ossis metacarpi minimi digiti; and is grooved on its outer side for the passage of the Flexor tendons into the palm of the hand. This is one of the four eminences on the front of the carpus to which the anterior annular ligament is attached, the others being the pisiform internally, the oblique ridge of the trapezium, and the tuberosity of the scaphoid externally. The *internal surface* articulates with the cuneiform by an oblong facet cut obliquely from above, downward and inward. The *external surface* articulates with the os magnum by its upper and posterior part, the remaining portion being rough, for the attachment of ligaments.

Hold the bone with the hooked process away from you, and the articular surface, divided into two parts for the metacarpal bones, downward. The concavity of the process will be on the side to which the bone belongs.

[In lean persons the scaphoid, trapezium, pisiform, and unciform, and sometimes the cuneiform, can be felt. The pisiform is always easily made out.]

Articulations.—With five bones: the semilunar above, the fourth and fifth metacarpal below, the cuneiform internally, the os magnum externally.

Attachment of Muscles.—To two: the Flexor brevis minimi digiti and Flexor ossis metacarpi minimi digiti, and to the anterior annular ligament.

THE METACARPUS.

The **Metacarpal Bones** are five in number: they are long cylindrical bones, presenting for examination a shaft and two extremities.

COMMON CHARACTERS OF THE METACARPAL BONES.

The **shaft** is prismoid in form and curved longitudinally, so as to be convex in the longitudinal direction behind, concave in front. It presents three surfaces, two lateral and one posterior. The *lateral surfaces* are concave, for the attachment of the Interossei muscles, and separated from one another by a prominent line. The *posterior* or *dorsal surface* is triangular, smooth, and flattened below, and covered, in the recent state, by the tendons of the Extensor muscles. In its upper half it is divided by a ridge into two narrow lateral depressions, for the attachment of the Dorsal interossei muscles.[1] This ridge bifurcates a little above the centre of the bone, and its branches run to the small tubercles on each side of the digital extremity.

The **carpal extremity, or base,** is of a cuboidal form, and broader behind than in front: it articulates above with the carpus, and on each side with the adjoining metacarpal bones; its *dorsal* and *palmar surfaces* are rough, for the attachment of tendons and ligaments.

---

[1] By these ridges the metacarpal bones of the hand may be at once differentiated from those of the foot.

The **digital extremity**, or **head**, presents an oblong surface, flattened at each side, for articulation with the first phalanx; it is broader and extends farther forward in front than behind, and is longer in the antero-posterior than in the transverse diameter. On either side of the head is a deep depression, behind which is the tubercle, for the attachment of the lateral ligament of the metacarpo-phalangeal joint. The *posterior surface*, broad and flat, supports the Extensor tendons; the *anterior surface* presents a median groove bounded on each side by a tubercle, for the passage of the Flexor tendons.

Peculiar Characters of the Metacarpal Bones.

The **metacarpal bone of the thumb** is shorter and wider than the rest, diverges to a greater degree from the carpus, and its *palmar surface* is directed inward toward the palm. The *shaft* is flattened and broad on its dorsal aspect, and does not present the bifurcated ridge which is found on the other metacarpal bones; it is concave from before backward on its palmar surface. The *carpal extremity*, or *base*, presents a concavo-convex surface, for articulation with the trapezium, and has no lateral facets. The *digital extremity* is less convex than that of the other metacarpal bones, broader from side to side than from before backward, and terminates anteriorly in a small articular eminence on each side, over which play two sesamoid bones.

The side to which this bone belongs may be known by observing the little prominence which is marked on the outer or radial side of its posterior surface just above the base, for the tendon of the Extensor ossis metacarpi pollicis. If the bone is held with the palmar surface upward and the base toward the student, the prominence will point to the side to which the bone belongs. Another means by which the side to which the bone belongs may be ascertained is by holding it in the position it occupies in the hand, with the carpal extremity upward and the dorsal surface backward; the narrower, radial border will point to the side to which it belongs.

The **metacarpal bone of the index finger** is the longest and its base the largest of the other four. Its *carpal extremity* is prolonged upward and inward. The dorsal and palmar surfaces of this extremity are rough, for the attachment of tendons and ligaments. It presents four articular facets: the first, at the end of the bone, is concave from side to side, convex from before backward, and articulates with the trapezoid; the second, on the radial side, is a flat quadrilateral facet, for the trapezium; the third and fourth are on the ulnar side of the extremity, and are separated by a ridge; the proximal one, long and narrow, articulates with the os magnum; the distal one, considerably broader and notched, with the third metacarpal bone.

The side to which this bone belongs is marked by the absence of the lateral facet on the outer (radial) side of its head, so that if the bone be placed with its base toward the student and the palmar surface upward, the side on which there is no lateral facet will be that to which it belongs. If the head of the bone be indistinctly marked, the base can be recognized, its ulnar or inner surface being marked by the two long narrow facets for the os magnum and third metacarpal, easily distinguishable from the single quadrangular facet on the radial side for the trapezium, which will then mark the side to which the bone belongs.

The **metacarpal bone of the middle finger** is a little smaller than the preceding; it presents a pyramidal eminence (the *styloid process*) on the radial side of its base (dorsal aspect), which extends upward behind the os magnum. [This can always be felt, and is a valuable landmark.] The carpal articular facet is concave behind, flat and horizontal in front, and corresponds to the os magnum. On the radial side is a smooth concave facet, for articulation with the second metacarpal bone; and on the ulnar side two small oval facets, for articulation with the fourth metacarpal.

The side to which this bone belongs is easily recognized by the projecting angle on the lower radial corner of its base. With the palmar surface uppermost and the base toward the student, this projection points toward the side to which the bone belongs.

The **metacarpal bone of the ring finger** is shorter and smaller than the preceding, and its base small and quadrilateral, the carpal surface of the base presenting two facets, for articulation with the unciform and os magnum. On the radial side are two oval facets, for articulation with the third metacarpal bone; and on the ulnar side a single concave facet, for the fifth metacarpal.

If this bone is placed with the base toward the student and the palmar surface upward, the radial side of the base, which has two facets for articulation with the third metacarpal bone, will be on the side to which it belongs. If, as sometimes happens in badly-marked bones, one of these facets is indistinguishable, the side may be known by the greatly larger size in such cases of the facet for the fifth metacarpal bone, which is therefore situated on the side to which the bone does *not* belong.

The **metacarpal bone of the little finger** may be distinguished by the concavo-convex form of its carpal surface, which articulates with the unciform, and by its having only one lateral articular facet, which corresponds with the fourth metacarpal bone. On its ulnar side is a prominent tubercle, for the insertion of the tendon of the Extensor carpi ulnaris. The dorsal surface of the shaft is marked by an oblique ridge which extends from near the ulnar side of the upper extremity to the radial side of the lower. The outer division of this surface serves for the attachment of the fourth Dorsal interosseous muscle; the inner division is smooth, and covered by the Extensor tendons of the little finger.

If this bone is placed with its base toward the student and its palmar surface upward, the side of the head which has a lateral facet will be that to which the bone belongs.

Articulations.—Besides the phalangeal articulations, the first metacarpal bone articulates with the trapezium; the second, with the trapezium, trapezoid, os magnum, and third metacarpal bones; the third, with the os magnum and second and fourth metacarpal bones; the fourth, with the os magnum, unciform, and third and fifth metacarpal bones; and the fifth, with the unciform and fourth metacarpal.

The *first* has therefore no lateral facets on its carpal extremity; the *second* has one on its radial and one on its ulnar side, divided by a ridge into two parts; the third has one on its radial and two on its ulnar side; the fourth has two on its radial and one on its ulnar side; and the fifth has only one on its radial side.

Attachment of Muscles.—To the metacarpal bone of the thumb, three: the Flexor ossis metacarpi pollicis, Extensor ossis metacarpi pollicis, and first Dorsal interosseous; to the second metacarpal bone, five: the Flexor carpi radialis, Extensor carpi radialis longior, first and second Dorsal interosseous, and first Palmar interosseous:[1] to the third, five: the Extensor carpi radialis brevior, Flexor brevis pollicis, Adductor pollicis, and second and third Dorsal interosseous; to the fourth, three: the third and fourth Dorsal and second Palmar interosseous; to the fifth, five: the Extensor carpi ulnaris, Flexor carpi ulnaris, Flexor ossis metacarpi minimi digiti, fourth Dorsal, and third Palmar interosseous.

PHALANGES.

The **Phalanges** (*internodia*) are the bones of the fingers; they are fourteen in number, three for each finger and two for the thumb. They are long bones, and present for examination a shaft and two extremities. The *shaft* tapers from above downward, is convex posteriorly, concave in front from above downward, flat from side to side, and marked laterally by rough ridges which give attachment to the fibrous sheaths of the Flexor tendons. The *metacarpal* [proximal] *extremity* or

---

[1] The Flexor brevis pollicis is also frequently attached to this bone.

base, in the first row, presents an oval concave articular surface, broader from side to side than from before backward; and the same extremity in the other two rows, a double concavity separated by a longitudinal median ridge extending from before backward. The *digital* [distal] *extremities* are smaller than the others, and terminate, in the first and second row, in two small lateral condyles separated by a slight groove, the articular surface being prolonged farther forward on the palmar than on the dorsal surface, especially in the first row.

The **Ungual Phalanges** are convex on their dorsal, flat on their palmar surfaces; they are recognized by their small size and by a roughened elevated surface of a horseshoe form on the palmar aspect of their ungual extremity, which serves to support the sensitive pulp of the finger.

[The first, second, and third phalanges are sometimes called, after the French, the *phalanx*, *phalangine*, and *phalangette*, the phalangette being the terminal phalanx.]

Articulations.—The first row with the metacarpal bones and the second row of phalanges; the second row with the first and third; the third, with the second row.

Attachment of Muscles.—To the base of the first phalanx of the thumb, four muscles: the Extensor primi internodii pollicis, Flexor brevis pollicis, Abductor pollicis, Adductor pollicis; to the second phalanx, two: the Flexor longus pollicis and the Extensor secundi internodii; to the base of the first phalanx of the index finger, the first Dorsal and the first Palmar interosseous; to that of the middle finger, the second and third Dorsal interosseous; to that of the ring-finger, the

FIG. 214.

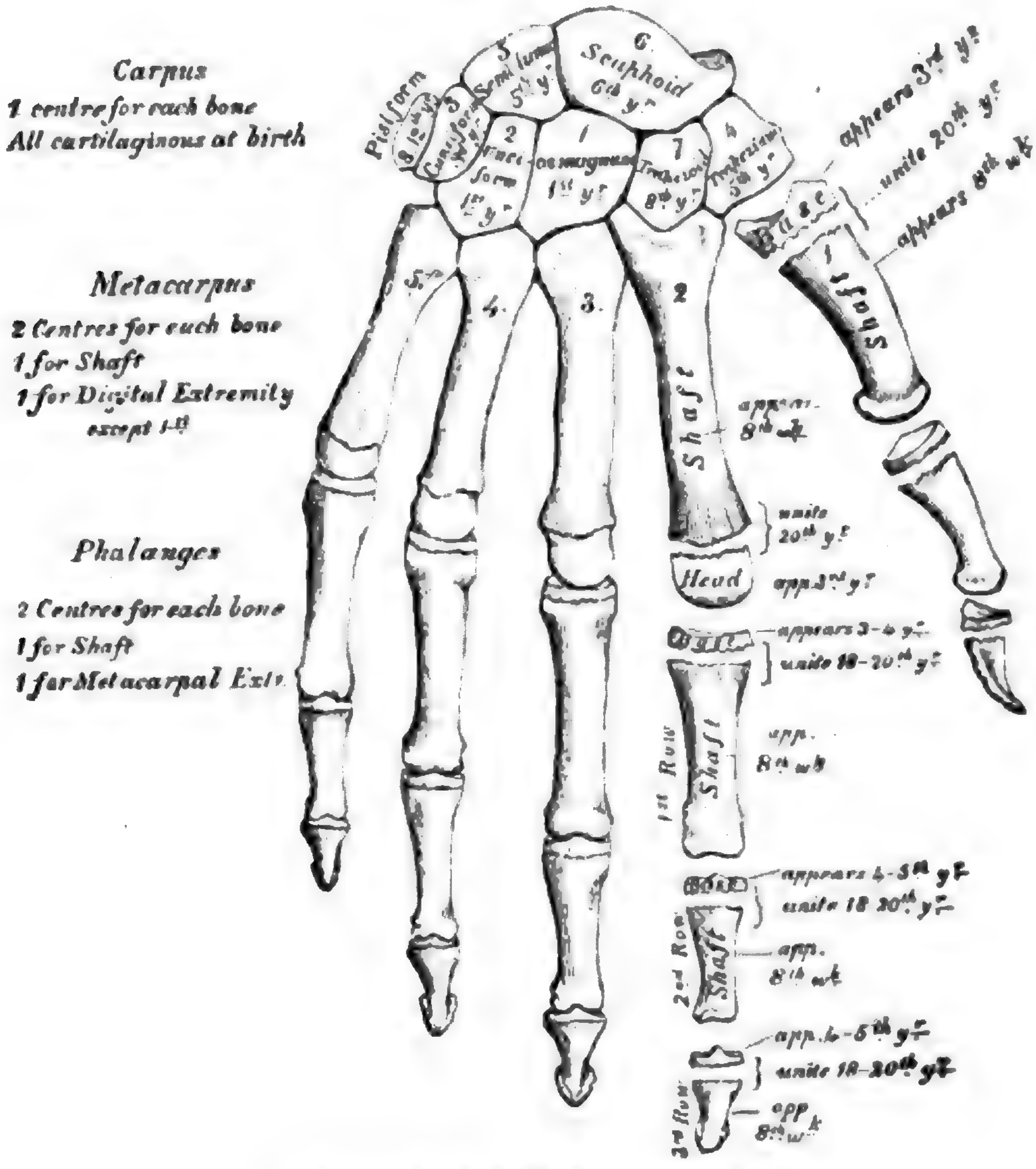
Carpus
1 centre for each bone
All cartilaginous at birth
Metacarpus
2 Centres for each bone
1 for Shaft
1 for Digital Extremity
except 1st
Phalanges
2 Centres for each bone
1 for Shaft
1 for Metacarpal Extr.
Pisiform 8 12th yr.
3 Cuneiform 3rd yr.
5 Semilunar 5th yr.
6 Scaphoid 6th yr.
2 Unciform 1st yr.
1 Os magnum 1st yr.
7 Trapezoid 8th yr.
4 Trapezium 5th yr.
appears 3rd yr.
unite 20th yr.
appears 8th wk.
Base
1
Shaft
5
4
3
2
Shaft
appears 8th wk.
unite 20th yr.
Head
app. 3rd yr.
Base
appears 3-4 yr.
unite 18-20th yr.
1st Row
Shaft
app. 8th wk.
Base
appears 4-5th yr.
unite 18 20th yr.
2nd Row
Shaft
app. 8th wk.
app. 4-5th yr.
unite 18-20th yr.
3rd Row
app. 8th wk.

Plan of the Development of the Hand.

fourth Dorsal and the second Palmar interosseous; and to that of the little finger, the third Palmar interosseous, the Flexor brevis minimi digiti, and Abductor minimi digiti: to the second phalanges, the Flexor sublimis digitorum, Extensor communis digitorum, and, in addition, the Extensor indicis to the index finger, the Extensor minimi digiti to the little finger; to the third phalanges, the Flexor profundus digitorum and Extensor communis digitorum.

Development of the Bones of the Hand.

The **Carpal Bones** are each developed by a *single* centre. At birth they are all cartilaginous. Ossification proceeds in the following order (Fig. 214): In the os magnum and unciform an ossific point appears during the first year, the former preceding the latter; in the cuneiform, at the third year; in the trapezium and semilunar, at the fifth year, the former preceding the latter; in the scaphoid, at the sixth year; in the trapezoid, during the eighth year; and in the pisiform, about the twelfth year.

The **Metacarpal Bones** are each developed by *two* centres: one for the shaft, and one for the digital extremity, for the four inner metacarpal bones; one for the shaft, and one for the base, for the metacarpal bone of the thumb, which in this respect resembles the phalanges.[1] Ossification commences in the centre of the shaft about the eighth or ninth week, and gradually proceeds to either end of the bone; about the third year the digital extremities of the four inner metacarpal bones and the base of the first metacarpal commence to ossify, and they unite about the twentieth year.

The **Phalanges** are each developed by *two* centres: one for the shaft, and one for the base. Ossification commences in the shaft, in all three rows, at about the eighth week, and gradually involves the whole of the bone excepting the upper extremity. Ossification of the base commences in the first row between the third and fourth years, and a year later in those of the second and third rows. The two centres become united in each row between the eighteenth and twentieth years.

OF THE LOWER EXTREMITY.

The **Lower Extremity** consists of three segments, the *thigh*, *leg*, and *foot*, which correspond to the *arm*, *forearm*, and *hand* in the upper extremity. It is connected to the trunk through the os innominatum, or *haunch* [or *hip-bone*], which forms the pelvic girdle.

[Figs. 215 and 216 show the bones of the trunk in black, and those of the extremities shaded. Fig. 215 shows the shoulder girdle, and Fig. 216 the pelvic girdle, both from above.

[Fig. 215.

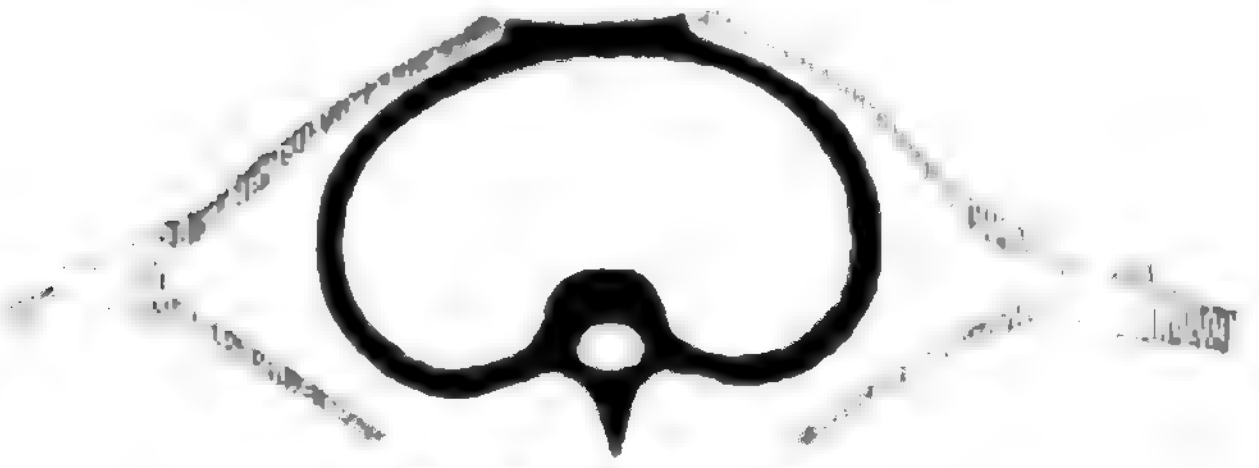

Shoulder Girdle (Henle).]

[Fig. 216.



Pelvic Girdle (Henle).]

The *shoulder girdle* is imperfect in front, but the gap between the two clavicles is filled by the sternum; but it is absolutely imperfect behind, the gap between the two scapulæ being unfilled, and the scapulæ connected to the trunk wholly by muscles and by the clavicle. It is made up of two light, graceful, and very movable bones.

---

[1] Allan Thompson has demonstrated the fact that the first metacarpal bone is often developed from three centres—that is to say, there is a separate nucleus for the distal end, forming a distinct epiphysis visible at the age of seven or eight years. He also states that there are traces of a proximal epiphysis in the second metacarpal bone (*Journal of Anatomy*, 1869).

The pelvic girdle is perfect in front, where the two innominate bones meet, and, though imperfect behind, the gap is filled up by the sacrum. The solidity and immobility of these strong bones are in marked contrast to the lightness and great mobility of the shoulder girdle, each being admirably fitted to its own purpose.]

THE OS INNOMINATUM.

The Os Innominatum (in, negative; nomen, a name), or nameless bone, so called from bearing no resemblance to any known object, is a large, irregular-shaped bone,

Fig. [illegible]

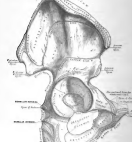

Right Os Innominatum. External surface.

which, with its fellow of the opposite side, forms the sides and anterior wall of the pelvic cavity. In young subjects it consists of three separate parts, which meet and form the large cup-like cavity situated near the middle of the outer side of the bone: and, although in the adult these have become united, it is usual to describe the bone as divisible into three portions—the ilium, the ischium, and the pubes.

The **Ilium,** so called from its supporting the flank (ilia), is the superior broad and expanded portion which runs upward from the upper and back part of the acetabulum, and forms the prominence of the hip.[1]

The **Ischium** (*ἰσχίον*, the hip) is the inferior and strongest portion of the bone; it proceeds downward from the acetabulum, expands into a large tuberosity, and then, curving upward, forms with the descending ramus of the pubes a large aperture, the obturator foramen.

The **Pubes** is that portion which runs horizontally inward from the inner side of the acetabulum for about two inches, then makes a sudden bend and descends to the same extent: it forms the front of the pelvis, supports the external organs of generation, and has received its name from being covered with hair.

The **Ilium** presents for examination two surfaces, an external and an internal, a crest, and two borders, an anterior and a posterior.

External Surface or Dorsum of the Ilium (Fig. 217).—The back part of this surface is directed backward, downward, and outward; its front part forward, downward, and outward. It is smooth, convex in front, deeply concave behind; bounded above by the crest, below by the upper border of the acetabulum, in front and behind by the anterior and posterior borders. This surface is crossed in an arched direction by three semicircular lines—the superior, middle, and inferior curved lines. The *superior curved line*, the shortest of the three, commences at the crest, about two inches in front of its posterior extremity; it is at first distinctly marked, but as it passes downward and outward to the upper part of the great sacro-sciatic notch, where it terminates, it becomes less marked, and is often altogether lost. The rough surface included between this line and the crest affords attachment to part of the Gluteus maximus above and a few fibres of the Pyriformis below. The *middle curved line*, the longest of the three, commences at the crest, about an inch behind its anterior extremity, and, taking a curved direction downward and backward, terminates at the upper part of the great sacro-sciatic notch. The space between the middle and superior curved lines and the crest is concave, and affords attachment to the Gluteus medius muscle. Near the central part of this line may often be observed the orifice of a nutrient foramen. The *inferior curved line*, the least distinct of the three, commences in front at the upper part of the anterior inferior spinous process, and, taking a curved direction backward and downward, terminates at the middle of the great sacro-sciatic notch. The surface of bone included between the middle and inferior curved lines is concave from above downward, convex from before backward, and affords attachment to the Gluteus minimus muscle. Beneath the inferior curved line, and corresponding to the upper part of the acetabulum, is a smooth eminence (sometimes a depression) to which is attached the reflected tendon of the Rectus femoris muscle.

The **internal surface** (Fig. 218) of the ilium is bounded above by the crest, below by a prominent line, the *linea ilio-pectinea*, and before and behind by the anterior and posterior borders. It presents anteriorly a large smooth, concave surface called the *internal iliac fossa*, or *venter of the ilium*, which lodges the Iliacus muscle, and presents at its lower part the orifice of a nutrient canal. Behind the iliac fossa is a rough surface divided into two portions, a superior and an inferior. The inferior or *auricular surface*, so called from its resemblance in shape to the ear, is coated with cartilage in the recent state, and articulates with a surface of similar shape on the side of the sacrum. The superior portion is concave and rough, for the attachment of the posterior sacro-iliac ligaments.

The crest of the ilium is convex in its general outline and sinuously curved, being bent inward anteriorly, outward posteriorly. It is longer in the female than in the male, very thick behind, and thinner at the centre than at the extremities.

[[1] Note the difference in spelling between il*i*um, the bone, and ileum, the third part of the small intestine.]

It terminates at either end in a prominent eminence, the *anterior superior* and the *posterior superior spinous processes.* The surface of the crest is broad, and divided into an external lip, an internal lip, and an intermediate space. To the external lip is attached the Tensor vaginæ femoris, Obliquus externus abdominis, and Latissimus dorsi, and by its whole length the fascia lata; to the interspace between the lips, the Internal oblique; to the internal lip, the Transversalis, Quadratus lumborum, and Erector spinæ, the Iliacus, and the fascia iliaca. [In the very muscular (*e. g.* Hercules) the great abdominal muscles overhang this crest.]

FIG. 218.

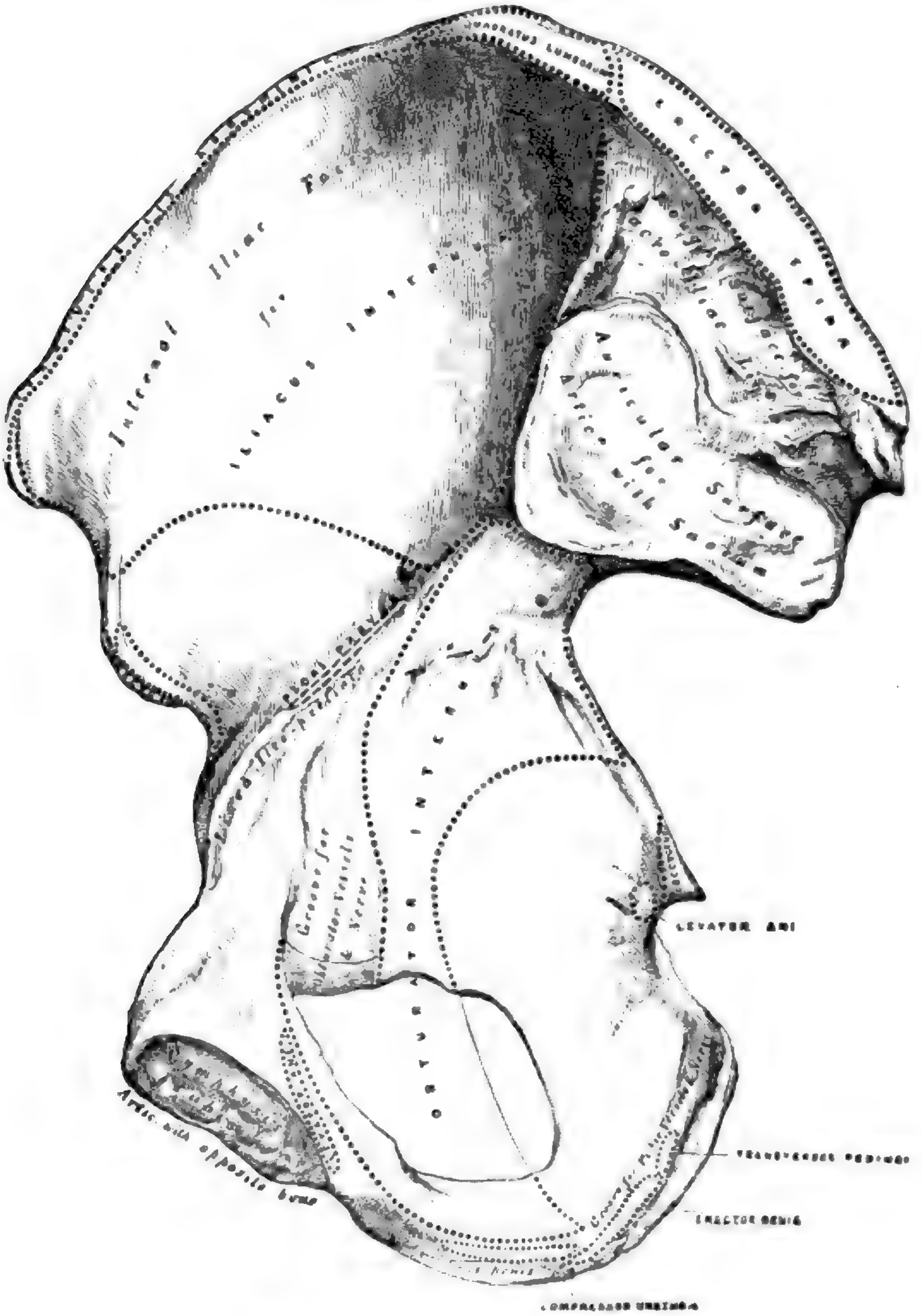
QUADRATUS LUMBORUM
ERECTOR SPINAE
Internal Iliac Fossa
ILIACUS
Articular Surface with Sacrum
Groove for Obturator Vessels & Nerve
OBTURATOR INTERNUS
LEVATOR ANI
Artic. with opposite bone
TRANSVERSUS PERINEI
ERECTOR PENIS
COMPRESSOR URETHRAE

Right Os Innominatum, internal surface.

The anterior border of the ilium is concave. It presents two projections, separated by a notch. Of these, the uppermost, situated at the junction of the crest and anterior border, is called the *anterior superior spinous process of the ilium,* the outer border of which gives attachment to the fascia lata and the origin of the Tensor vaginæ femoris; its inner border, to the Iliacus; whilst its extremity affords attachment to Poupart's ligament and the origin of the Sartorius. [This anterior superior spine can always be felt, even in the very fat, and is one of the most important landmarks of the whole body. In all examinations for hernia, fracture, dislocation, etc. its position should be marked on the skin by an aniline pencil.] Beneath this eminence is a notch which gives attachment to the Sartorius muscle, and across which passes the external cutaneous nerve. Below the notch is the *anterior inferior spinous process*, which terminates in the upper lip of the acetabulum; it gives attachment to the straight tendon of the Rectus femoris muscle and the ilio-femoral ligament. On the inner side of the anterior inferior spinous process is a broad shallow groove over which passes the Iliacus muscle. The posterior border of the ilium, shorter than the anterior, also presents two projections separated by a notch, the posterior superior and the posterior inferior spinous processes. The former corresponds with that portion of the posterior surface of the ilium which serves for the attachment of the oblique portion of the sacro-iliac ligaments and the Multifidus spinæ [it is always marked by a depression in the back, and in the female model this is a noticeable dimple, which adds much to its beauty]; the latter to the auricular portion which articulates with the sacrum. Below the posterior inferior spinous process is a deep notch, the great sacro-sciatic.

The **Ischium** forms the lower and back part of the os innominatum. It is divisible into a thick and solid portion, the *body;* a large rough eminence on which the body rests in sitting, the *tuberosity;* and a thin ascending part, the *ramus.*

The **body,** somewhat triangular in form, presents three surfaces, external, internal, and posterior. The *external surface* corresponds to that portion of the acetabulum formed by the ischium; it is smooth and concave, and forms a little more than two-fifths of the acetabular cavity; its outer margin is bounded by a prominent rim or lip to which the cotyloid fibro-cartilage is attached. Below the acetabulum, between it and the tuberosity, is a deep groove, along which the tendon of the Obturator externus muscle runs as it passes outward to be inserted into the digital fossa of the femur. The *internal surface* is smooth, concave, and forms the lateral boundary of the true pelvic cavity; it is broad above, and separated from the venter of the ilium by the linea ilio-pectinea; narrow below: its posterior border presents, a little below its centre, a sharp process, the spine of the ischium, above and below which are the greater and lesser sacro-sciatic notches; in front it presents a sharp margin, the internal border, which forms the outer boundary of the obturator foramen. This surface is perforated by two or three large vascular foramina, and affords attachment to part of the Obturator internus muscle. The *posterior surface* is quadrilateral in form, broad and smooth above, narrow below, where it becomes continuous with the tuberosity, and presents a portion of the same groove seen below the acetabulum for the tendon of the Obturator externus muscle; it is limited in front by the margin of the acetabulum; behind, by the front part of the great sacro-sciatic notch. This surface supports the Pyriformis, the two Gemelli, and the Obturator internus muscles in their passage outward to the great trochanter. The body of the ischium presents three borders, posterior, external, and internal. The *posterior border* presents a little below the centre a thin and pointed triangular eminence, the *spine of the ischium*, more or less elongated in different subjects. Its external surface gives attachment to the Gemellus superior, its internal surface to the Coccygeus and Levator ani, whilst to the pointed extremity is connected the lesser sacro-sciatic ligament. Above the spine is a notch of large size, the *great sacro-sciatic*, converted into a foramen by the lesser sacro-sciatic ligament; it transmits the Pyriformis muscle, the gluteal vessels, and superior gluteal nerve passing out of the pelvis above the muscle; the sciatic vessels, the greater and lesser sciatic nerves, the internal pudic vessels and nerve, and muscular branches from the sacral plexus below it. Below the spine is a smaller notch, the *lesser sacro-sciatic;* it is smooth, coated in the recent state with cartilage, the surface of which presents numerous markings corresponding to the subdivisions of the tendon of the Obturator internus which winds over it. It is converted into a foramen by the sacro-sciatic ligaments, and transmits the tendon of the Obturator internus, the nerve which supplies that muscle, and the internal pudic vessels and nerve. The *external* border forms the prominent rim of the acetabulum and separates the posterior from the external surface. To it is attached the cotyloid fibro-cartilage. The *internal border* is thin and forms the outer circumference of the obturator foramen.

The **tuberosity** [upon which the body rests in the sitting posture] presents for examination an external lip, an internal lip, and an intermediate space. The external lip gives attachment to the Quadratus femoris and part of the Adductor magnus muscles. The inner lip is bounded by a sharp ridge, for the attachment of a falciform prolongation of the great sacro-sciatic ligament; it presents a groove on the inner side of this, for the lodgment of the internal pudic vessels and nerve; and, more anteriorly, has attached the Transversus perinæi and Erector penis muscles. The intermediate surface is divided into two portions—an anterior, rough, somewhat triangular part, and a posterior, smooth, quadrilateral portion. The anterior surface is divided by a prominent vertical ridge, passing from base to apex, into two parts; the outer one gives attachment to the Adductor magnus, the inner to the great sacro-sciatic ligament. The posterior portion is also divided into two facets by an oblique ridge, which runs forward and outward; from the upper and outer facet arises the Semimembranosus; from the lower and inner, the Biceps and Semitendinosus. The uppermost part of the tuberosity gives attachment to the Gemellus inferior.

The **ramus** or **ascending ramus** is the thin flattened part of the ischium which ascends from the tuberosity upward and inward, and joins the ramus of the pubes, their point of junction being indicated in the adult by a rough eminence. The outer surface of the ramus is rough, for the attachment of the Obturator externus muscle, also some fibres of the Adductor magnus and of the Gracilis; its inner surface forms part of the anterior wall of the pelvis. Its inner border is thick, rough, slightly everted, forms part of the outlet of the pelvis and presents two ridges and an intervening space. The ridges are continuous with similar ones on the descending ramus of the pubes. To the outer one is attached the deep layer of the superficial perineal fascia, and to the inner the anterior layer of the triangular ligament. If these two ridges are traced downward, they will be found to be continuous with each other at the anterior extremity of the tuberosity of the ischium: here the two layers of fascia are blended behind the Transversus perinæi muscle. To the intervening space, just in front of the point of junction of the ridges, is attached the Transversus perinæi muscle, and in front of this a portion of the crus penis (vel clitoridis) and the Erector penis (vel clitoridis) muscle. Its outer border is thin and sharp, and forms part of the inner margin of the obturator foramen.

The **Pubes** forms the anterior part of the os innominatum, and with the bone of the opposite side forms the front boundary of the true pelvic cavity. It is divisible into a body, a horizontal ramus, and a descending ramus.

The **body** is somewhat quadrilateral in shape, and presents for examination two surfaces and three borders. The *anterior* surface is rough, directed forward and outward, and serves for the attachment of various muscles. To the upper and inner angle immediately below the crest is attached the Adductor longus; lower down, from without inward, are attached the Obturator externus, the Adductor magnus, the Adductor brevis, and the upper part of the Gracilis. The *posterior* surface, convex from above downward, concave from side to side, is smooth, and forms part of the anterior wall of the pelvis. It gives attachment to the Levator ani and Obturator internus. The *upper* border presents for examination a prominent tubercle which projects forward and is called the *spine;* to it is attached the outer pillar of the external abdominal ring and Poupart's ligament. Passing outward from this is a prominent ridge, forming part of the *ilio-pectineal* line, which, running outward, marks the brim of the true pelvis. To it is attached a portion of the conjoined tendon of the Internal Oblique and Transversalis muscles, Gimbernat's ligament, and the triangular ligament. Internal to the spine of the pubes is the *crest*, which extends from this process to the inner extremity of the bone. It affords attachment anteriorly to the conjoined tendon of the Internal Oblique and Transversalis, and posteriorly to the Rectus and Pyramidalis muscles. The point of junction of the crest with the inner border of the bone is called the *angle;* to it, as well as to the symphysis, is attached the internal pillar of the external abdominal ring. The *internal* border is the *symphysis;* it is oval, covered by eight or nine transverse ridges, or a series of nipple-like processes arranged in rows separated by grooves; they serve for the attachment of the connecting fibro-cartilage placed between it and the opposite bone. The *outer* border presents a sharp margin, which forms part of the circumference of the obturator foramen and affords attachment to the obturator membrane.

The **horizontal ramus** extends from the body to the point of junction of the pubes with the ilium, and forms the upper part of the circumference of the obturator foramen. It presents for examination a superior, inferior, and posterior surface and an outer extremity. The *superior* surface presents a continuation of the ilio-pectineal line, already mentioned as commencing on the body of the bone. In front of this ridge the surface of bone is triangular in form, wider externally than internally, smooth, and affords attachment to the Pectineus muscle. The surface is bounded externally by a rough eminence, the *ilio-pectineal*, which serves to indicate the point of junction of the ilium and pubes, and gives attachment to the Psoas parvus when this muscle is present. The *inferior* surface forms the upper boundary of the obturator foramen, and presents, externally, a broad and deep oblique groove, for the passage of the obturator vessels and nerve; and, internally, a sharp margin, which forms part of the circumference of the obturator foramen and to which the obturator membrane is attached. The *posterior* surface forms part of the anterior boundary of the true pelvis. It is smooth, convex from above downward, and affords attachment to the upper fibres of the obturator internus. The *outer* extremity, the thickest part of the ramus, forms one-fifth of the cavity of the acetabulum.

The **descending ramus** of the pubes is thin and flattened. It passes outward and downward, becoming narrower as it descends, and joins with the ramus of the ischium. Its *anterior* surface is rough, for the attachment of muscles—the Gracilis along its inner border; a portion of the Obturator externus where it enters into the formation of the foramen of that name; and between these two muscles the Adductors brevis and magnus. The *posterior* surface is smooth, for the Obturator internus, and close to the inner margin the Compressor urethræ. The *inner* border is thick, rough, and everted, especially in females. It presents two ridges, separated by an intervening space. The ridges extend downward through the ascending ramus of the ischium to the tuber ischii, where they become continuous: to the external one is attached the deep layer of the superficial perineal fascia, and to the internal one the anterior layer of the triangular ligament. To the intervening space is attached the crus penis (vel clitoridis) and the Erector penis (vel clitoridis) muscle. The *outer* border is thin and sharp, forms part of the circumference of the obturator foramen, and gives attachment to the Obturator muscle.

The **Cotyloid Cavity**, or **Acetabulum**, is a deep, cup-shaped, hemispherical depression formed, internally, by the pubes, above by the ilium, behind and below by the ischium, a little less than two-fifths being formed by the ilium, a little more than two-fifths by the ischium, and the remaining fifth by the pubes. It is bounded by a prominent uneven rim, which is thick and strong above, and serves for the attachment of a fibro-cartilaginous structure which contracts its orifice and deepens the surface for articulation. It presents on its inner side a deep notch, the *cotyloid notch*, which transmits the nutrient vessels into the interior of the joint, and is continuous with a circular depression at the bottom of the cavity: this depression is perforated by numerous apertures, lodges a mass of fat, and its margins, as well as those of the notch, serve for the attachment of the ligamentum teres. The notch is converted, in the natural state, into a foramen by a dense ligamentous band which passes across it. Through this foramen the nutrient vessels and nerves enter the joint. [The internal surface of the pelvic bones is accessible to the touch by the rectum, and in women by the vagina also. In suspected hip-joint disease this may sometimes give valuable information by disclosing the condition of the floor of the acetabulum.]

The **Obturator** or **Thyroid Foramen** is a large aperture situated between the ischium and pubes. In the male it is large, of an oval form, its longest diameter being obliquely from above downward; in the female it is smaller and more triangular. It is bound by a thin, uneven margin to which a strong membrane is attached, and presents at its upper and outer part a deep groove which runs from the pelvis obliquely forward, inward, and downward. This groove is converted into a foramen by the obturator membrane, and transmits the obturator vessels and nerve.

Structure.—This bone consists of much cancellous tissue, especially where it is thick, enclosed between two layers of dense compact tissue. In the thinner parts of the bone, as at the bottom of the acetabulum and centre of the iliac fossa, it is usually semi-transparent and composed entirely of compact tissue.

Development (Fig. 219).—By *eight* centres: three primary—one for the ilium, one for the ischium, and one for the pubes; and *five* secondary—one for the crest of the ilium, one for the anterior inferior spinous process (said to occur more frequently in the male than the female), one for the tuberosity of the ischium, one for the symphysis pubis (more frequent in the female than the male), and one for the Y-shaped piece at the bottom of the acetabulum. These various centres appear in the following order: First, in the ilium, at the lower part of the bone, immediately above the sciatic notch, at about the same period that the development of the vertebræ commences. Secondly, in the body of the ischium, at about the third month of fœtal life. Thirdly, in the body of the pubes, between the fourth and fifth

Fig. 219.

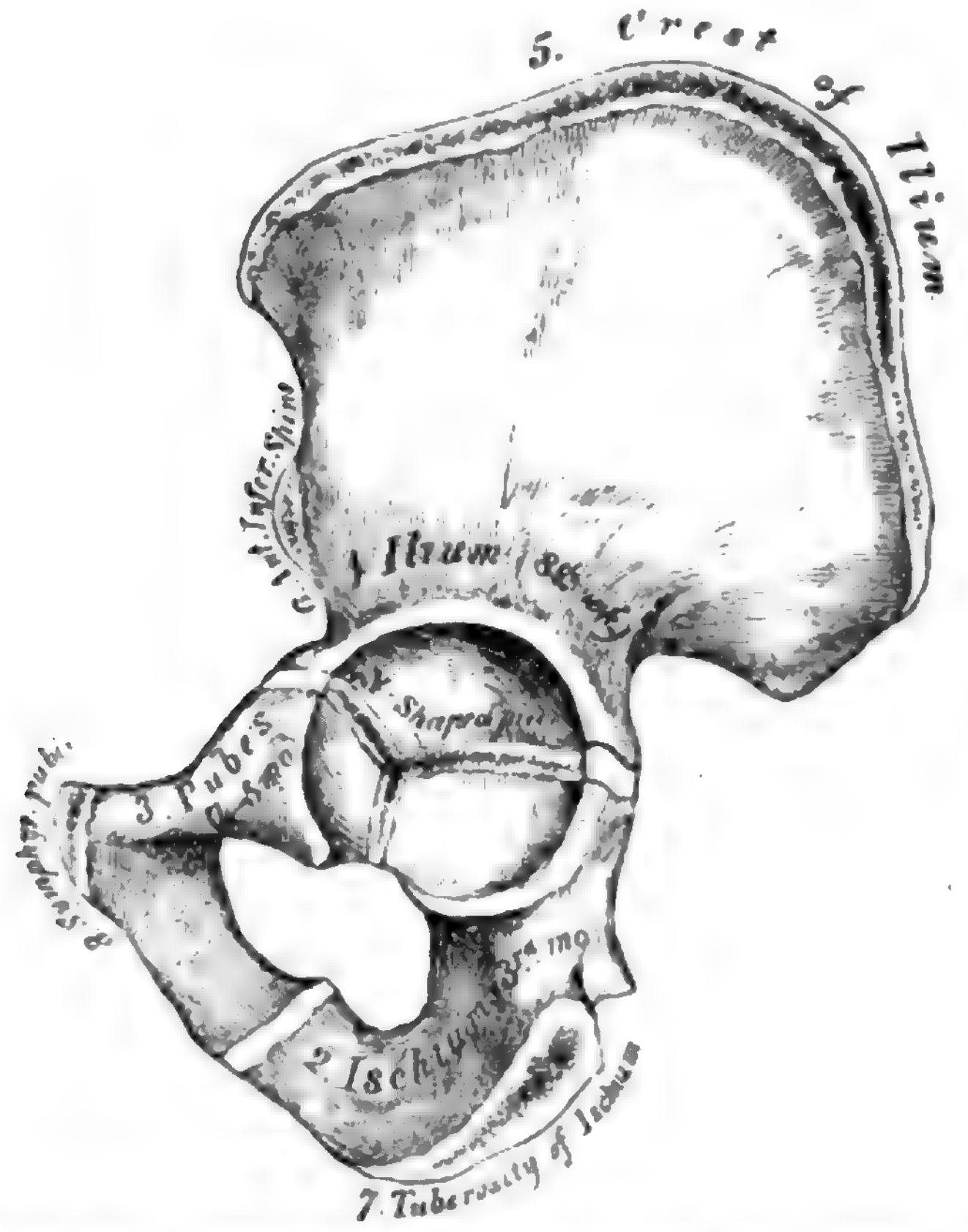

Plan of the Development of the Os Innominatum, by eight centres—three primary (ilium, ischium, and pubes), five secondary. The three primary centres unite through a Y-shaped piece about puberty. Epiphyses appear about puberty, and unite about the twenty-fifth year.

months. At birth the three primary centres are quite separate, the crest, the bottom of the acetabulum, and the rami of the ischium and pubes being still cartilaginous. At about the seventh or eighth year the rami of the pubes and ischium are almost completely ossified. About the thirteenth or fourteenth year the three divisions of the bone have extended their growth into the bottom of the acetabulum, being separated from each other by a Y-shaped portion of cartilage which now presents traces of ossification. The ilium and ischium then become joined, and lastly the pubes, through the intervention of this Y-shaped portion. At about the age of puberty ossification takes place in each of the remaining portions, and they become joined to the rest of the bone about the twenty-fifth year.

Articulations.—With its fellow of the opposite side, the sacrum, and femur.

Attachment of Muscles.—To the *ilium*, fifteen. To the outer lip of the crest, the Tensor vaginæ femoris, Obliquus externus abdominis, and Latissimus dorsi; to the internal lip, the Iliacus, Transversalis, Quadratus lumborum, and Erector spinæ; to the interspace between the lips, the Obliquus internus. To the outer surface of the ilium, the Gluteus maximus, Gluteus medius, Gluteus minimus, reflected tendon of Rectus, portion of Pyriformis; to the internal surface, the Iliacus, and the Multifidus spinæ to the internal surface of the posterior superior spine; to the anterior border, the Sartorius and straight tendon of the Rectus. To the *ischium*, fourteen. To its outer surface, the Obturator externus and Gracilis; internal surface, Obturator internus and Levator ani. To the spine, the Gemellus superior, Levator ani, and Coccygeus. To the tuberosity, the Biceps, Semitendinosus, Semimembranosus, Quadratus femoris, Adductor magnus, Gemellus inferior, Transversus perinæi, Erector penis. To the *pubes*, sixteen, the Obliquus externus, Obliquus internus, Transversalis, Rectus, Pyramidalis, Psoas parvus, Pectineus, Adductor magnus, Adductor longus, Adductor brevis, Gracilis, Obturator externus and internus, Levator ani, Compressor urethræ, and occasionally a few fibres of the Accelerator urinæ.

THE PELVIS (Figs. 220, 221).

The **Pelvis**, so called from its resemblance to a basin (L. *pelvis*), is stronger and more massively constructed than either the cranial or thoracic cavity; it is a bony

FIG. 220.

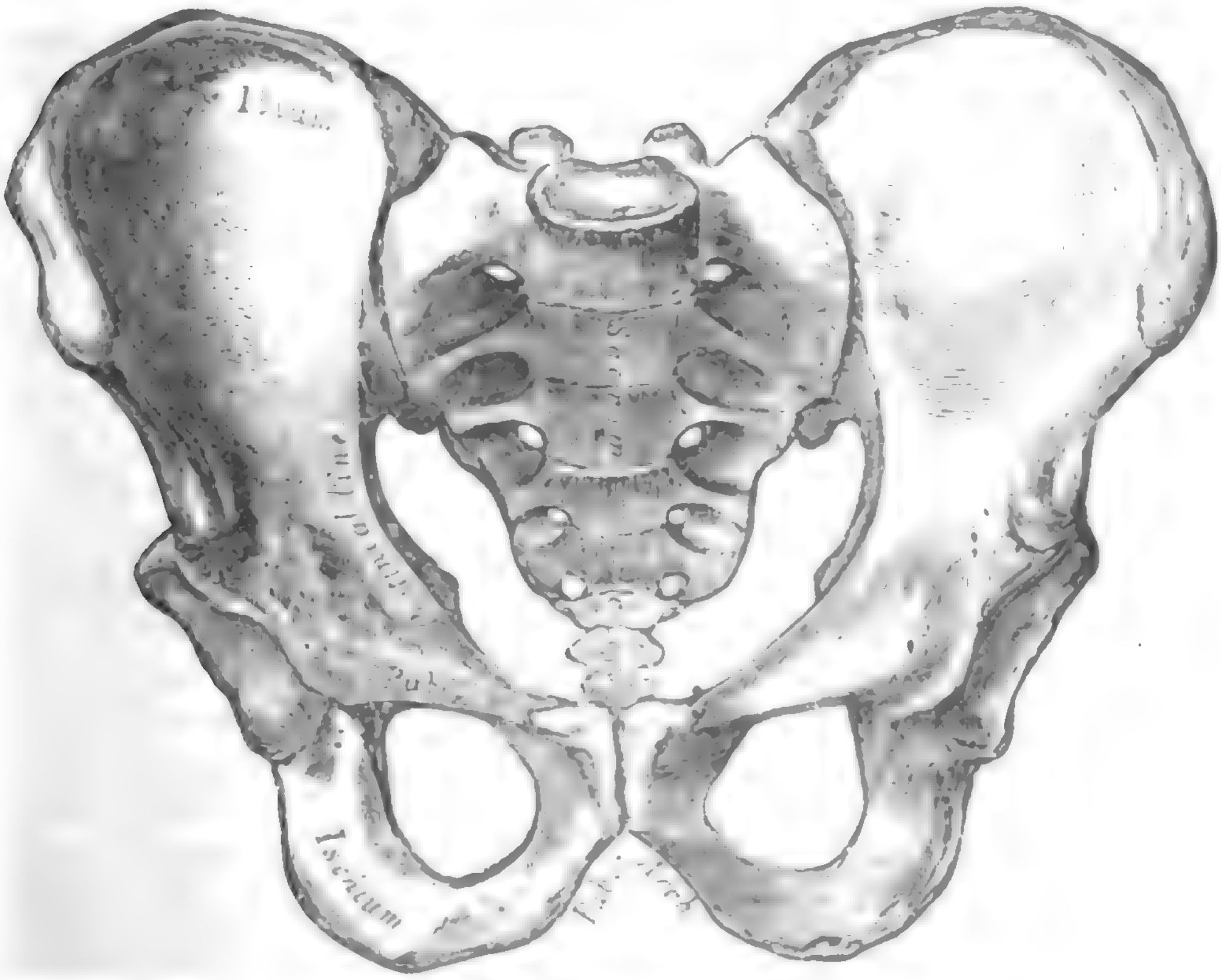

Male Pelvis (adult).

Fig. 221.

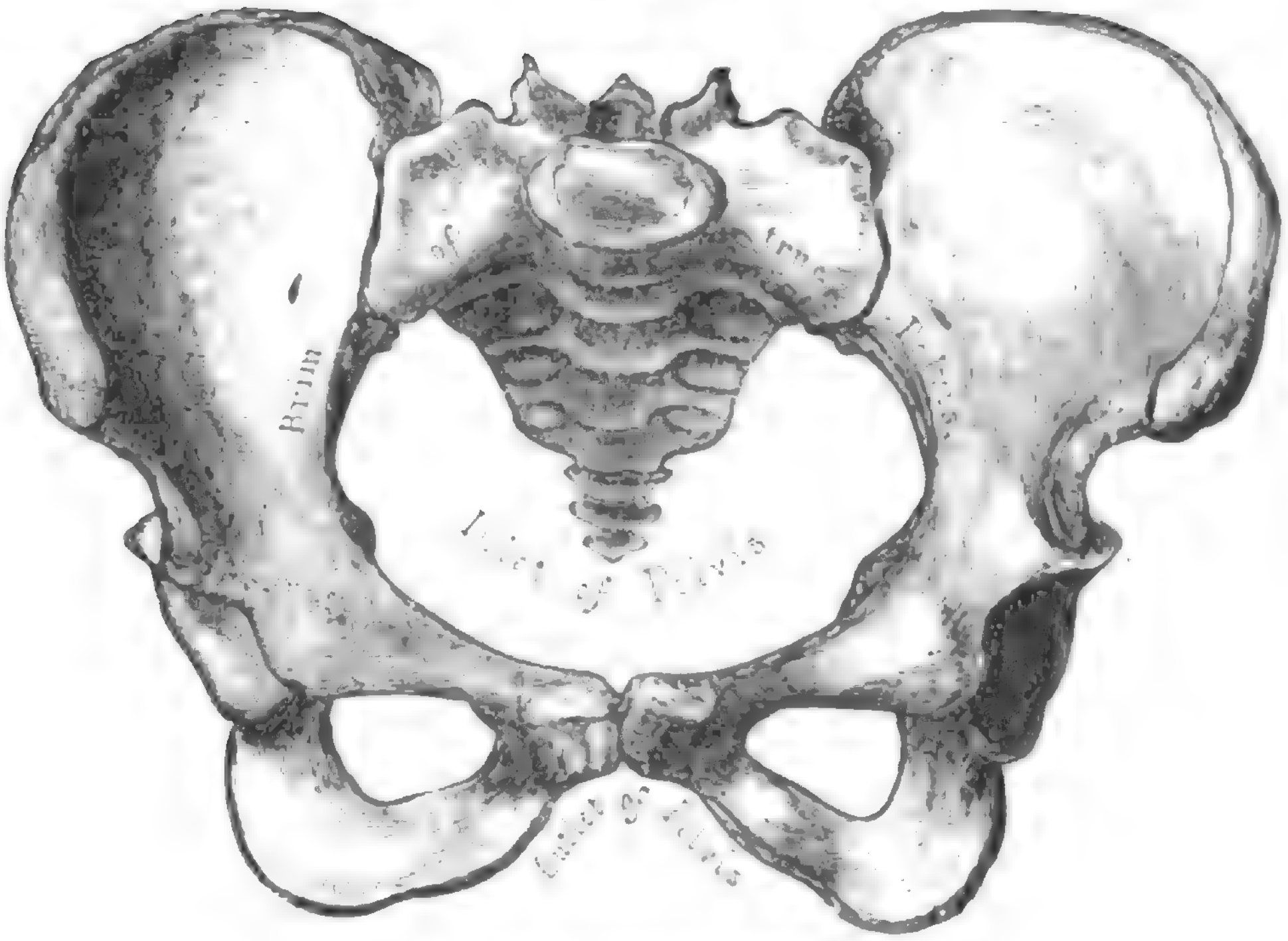

Female Pelvis (adult).

ring interposed between the lower end of the spine, which it supports, and the lower extremities, upon which it rests. It is composed of four bones: the two ossa innominata, which bound it on either side and in front, and the sacrum and coccyx, which complete it behind.

The pelvis is divided by a prominent line, the *linea ilio-pectinea*, into the false and true pelvis.

The **False Pelvis** is all that expanded portion of the pelvic cavity which is situated above the linea ilio-pectinea. It is bounded on each side by the ossa ilii; in front it is incomplete, presenting a wide interval between the spinous processes of the ilia on either side, which is filled up in the recent state by the parietes of the abdomen; behind, in the middle line, is a deep notch. This broad, shallow cavity is fitted to support the intestines and to transmit part of their weight to the anterior wall of the abdomen.

The **True Pelvis** is all that part of the pelvic cavity which is situated beneath the linea ilio-pectinea. It is smaller than the false pelvis, but its walls are more perfect. For convenience of description it is divided into a superior circumference or inlet, an inferior circumference or outlet, and a cavity.

The **superior circumference** forms the margin or brim of the pelvis, the included space being called the *inlet*. It is formed by the linea ilio-pectinea, completed in front by the spine and crest of the pubes, and behind by the anterior margin of the base of the sacrum and sacro-vertebral angle.

The **inlet** of the pelvis is somewhat heart-shaped, obtusely pointed in front, diverging on either side, and encroached upon behind by the projection forward of the promontory of the sacrum. It has three principal diameters—antero-posterior (sacro-pubic), transverse, and oblique. The antero-posterior extends from the sacro-vertebral angle to the symphysis pubis; its average measurement is four inches in the male, four and three-quarters in the female. The transverse extends across the greatest width of the inlet, from the middle of the brim on one side to the same point on the opposite; its average measurement is four and a half in the male, five and a quarter in the female. The oblique extends from the margin of the pelvis, corresponding to the ilio-pectineal eminence on one side, to the sacro-iliac symphysis on the opposite side; its average measurement is four and a quarter in the male and five in the female.

The **cavity** of the true pelvis is bounded in front by the symphysis pubis; behind, by the concavity of the sacrum and coccyx, which, curving forward above and below, contracts the inlet and outlet of the canal; and laterally it is bounded by a broad, smooth, quadrangular plate of bone corresponding to the inner surface of the body of the ischium. The cavity is shallow in front, measuring at the symphysis an inch and a half in depth, three inches and a half in the middle, and four inches and a half posteriorly. From this description it will be seen that the cavity of the pelvis is a short curved canal, considerably deeper on its posterior than on its anterior wall, and broader in the middle than at either extremity, from the projection forward of the sacro-coccygeal column above and below. This cavity contains, in the recent subject, the rectum, bladder, and part of the organs of generation. The rectum is placed at the back of the pelvis, and corresponds to the curve of the sacro-coccygeal column; the bladder in front, behind the symphysis pubis. In the female the uterus and vagina occupy the interval between these parts.

The **lower circumference** of the pelvis is very irregular, and forms what is called the *outlet.* It is bounded by three prominent eminences: one posterior, formed by the point of the coccyx; and one on each side, the tuberosities of the ischia. These eminences are separated by three notches: one in front, the *pubic arch,* formed by the convergence of the rami of the ischia and pubes on each side; the other notches, one on each side, are formed by the sacrum and coccyx behind, the ischium in front, and the ilium above: they are called the *sacro-sciatic notches;* in the natural state they are converted into foramina by the lesser and greater sacro-sciatic ligaments.

The diameters of the outlet of the pelvis are two, antero-posterior and transverse. The *antero-posterior* extends from the tip of the coccyx to the lower part of the symphysis pubis; its average measurement is three and a quarter inches in the male and five in the female. The *transverse* extends from the posterior part of one ischiatic tuberosity to the same point on the opposite side; the average measurement is three and a half inches in the male and four and three-quarters in the female. The antero-posterior diameter varies with the length of the coccyx, and is capable of increase or diminution on account of the mobility of that bone.

Position of the Pelvis.—In the erect posture the pelvis is placed obliquely with regard to the trunk of the body: the bony ring, which separates the true from the false pelvis, and which forms the essential part of the pelvis, is placed so as to form an angle of about sixty to sixty-five degrees with the ground on which we stand. The pelvic surface of the symphysis pubis looks upward and backward, the concavity of the sacrum and coccyx downward and forward, the base of the sacrum in well-formed female bodies being nearly four inches above the upper border of the symphysis pubis, and the apex of the coccyx a little more than half an inch above its lower border. The obliquity is much greater in the fœtus and at an early period of life than in the adult. In consequence of this obliquity of the pelvis the line of gravity of the head, which passes through the middle of the odontoid process of the axis and through the points of junction of the curves of the vertebral column to the sacro-vertebral angle, descends toward the front of the cavity, so that it bisects a line drawn transversely through the middle of the heads of the thigh-bones. And thus the centre of gravity of the head is placed immediately over the heads of the thigh-bones on which the trunk is supported.

Fig. 222.

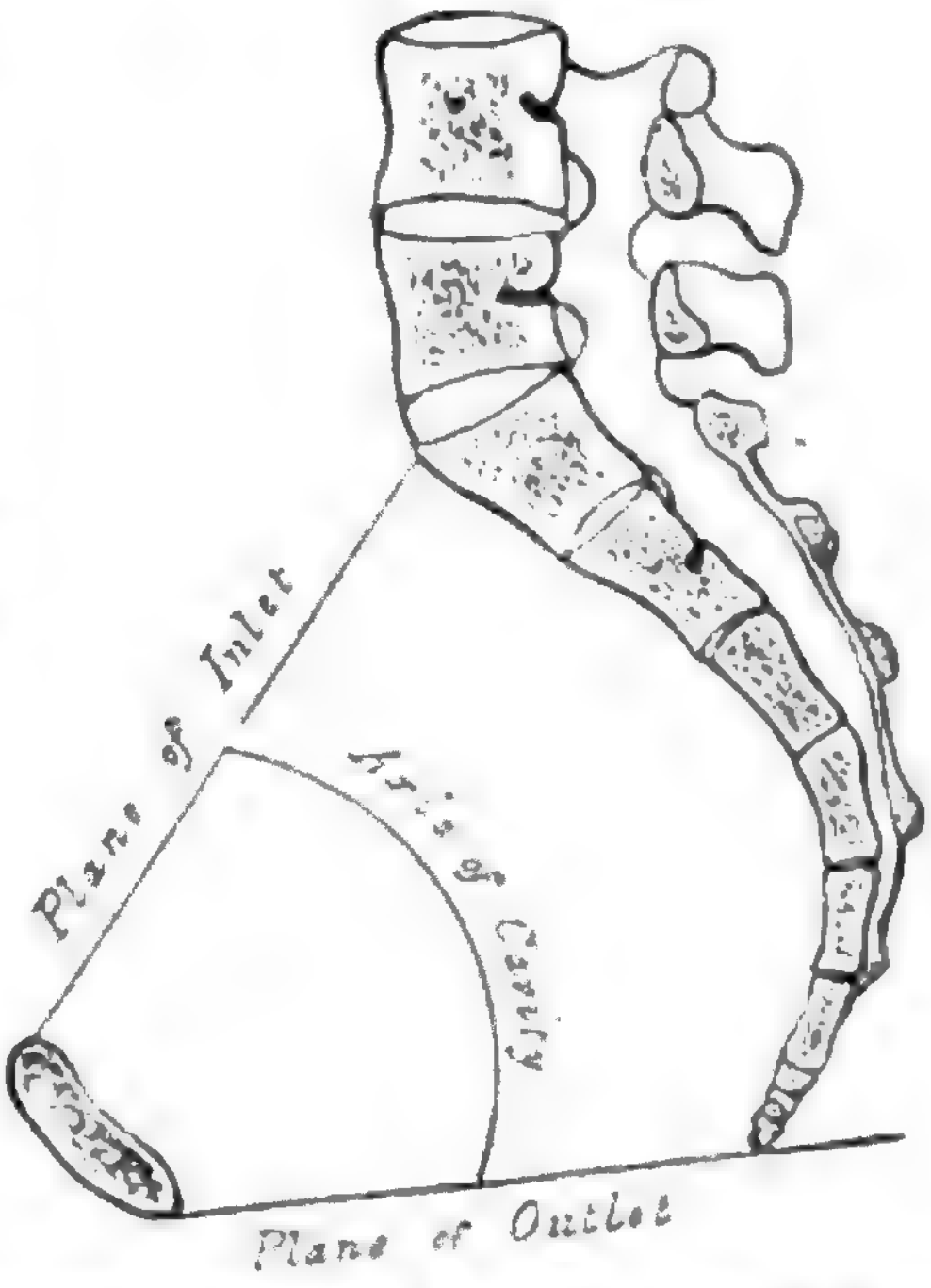

Vertical Section of the Pelvis, with lines indicating the axes of the pelvis.

Axes of the Pelvis (Fig. 222).—The plane of the inlet of the true pelvis will be represented by a line drawn from the base of the sacrum to the upper margin of the symphysis pubis. [This forms with the horizon an angle of from fifty-five to sixty-five degrees.] A line carried at right angles with this at its middle would correspond at one extremity with the umbilicus, and at the other with the middle of the coccyx: the axis of the inlet is therefore directed downward and backward. [The plane of the outlet is represented by a line from the tip of the coccyx to the lower border of the symphysis, and forms with the horizon an angle, varying with the length of the coccyx, of from seven to twenty-seven degrees.] The axis of the outlet produced upward would touch the base of the sacrum, and is therefore directed downward and forward. [This axis is directed downward and backward, not forward, the tip of the coccyx being above the level of the lower border, and often of the upper border, of the symphysis.] The axis of the cavity is curved like the cavity itself: this curve corresponds to the concavity of the sacrum and coccyx, the extremities being indicated by the central points of the inlet and outlet. A knowledge of the direction of these axes serves to explain the course of the fœtus in its passage through the pelvis during parturition. It is also important to the surgeon, as indicating the direction of the force required in the removal of calculi from the bladder, and as determining the direction in which instruments should be used in operations upon the pelvic viscera.

Differences between the Male and Female Pelvis.—In the *male* the bones are thicker and stronger, and the muscular eminences and impressions on their surfaces more strongly marked. The male pelvis is altogether more massive; its cavity is deeper and narrower and the obturator foramina of larger size. In the *female* the bones are lighter and more expanded, the muscular impressions on their surfaces are only slightly marked, and the pelvis generally is less massive in structure. The iliac fossæ are broad, and the spines of the ilia widely separated; hence the great prominence of the hips. The inlet and the outlet are larger, the former being more nearly circular in consequence of the sacral promontory projecting less into it. The cavity is more capacious, and the spines of the ischia project less into it. The promontory is less projecting, the sacrum wider and less curved,[1] and the coccyx more movable. The arch of the pubes is wider and its edges more everted. [This subpubic arch is in the male an angle rather than an arch, and usually measures about seventy-five degrees, but may be much less; in women it is a true arch, and subtends an angle of ninety to one hundred degrees. A narrow subpubic arch in men brings the tuberosities of the ischia together, and is a serious impediment in lithotomy; while in women the same narrowness would greatly impede delivery, and if too marked make normal birth impossible.] The tuberosities of the ischia and the acetabula are wider apart.

The size of the pelvis varies not only in the two sexes, but also in different members of the same sex. This does not appear to be influenced in any way by the height of the individual. Women of short stature, as a rule, have broad pelves. Occasionally the pelvis is equally contracted in all its dimensions, so much so that all its diameters measure an inch less than the average, and this even in women of average height and otherwise well formed. The pelvis of the negro is said to be smaller than that of the European, and the sacrum is somewhat less curved.

In the *fœtus* and for several years after birth the pelvis is small in proportion to that of the adult. The cavity is deep and the projection of the sacro-vertebral angle less marked. The antero-posterior and transverse diameters are nearly equal. *About puberty* the pelvis in both sexes presents the general characters of the adult male pelvis, but *after puberty* it acquires its proper sexual characters.

THE FEMUR OR THIGH-BONE.

The **Femur** (*femur*, the thigh) is the longest,[2] largest, and strongest bone in the skeleton, and almost perfectly cylindrical in the greater part of its extent. In the erect posture it is not vertical, being separated from its fellow above by a considerable interval, which corresponds to the entire breadth of the pelvis, but inclining gradually downward and inward, so as to approach its fellow toward its lower part, for the purpose of bringing the knee-joint near the line of gravity of the body. The degree of this inclination varies in different persons, and is greater in the female than in the male, on account of the greater breadth of the pelvis. [Compare remarks on the difference between the knee- and elbow-joints, p. 242.] The femur, like other long bones, is divisible into a shaft and two extremities.

---

[1] It is not unusual, however, to find the sacrum in the female presenting a considerable curve extending throughout its whole length.

[2] In a man six feet high it measures eighteen inches—one-fourth of the whole body.

The **Upper Extremity** presents for examination a head, a neck, and the greater and lesser trochanters.

The **head,** which is globular and forms rather more than a hemisphere, is directed upward, inward, and a little forward, the greater part of its convexity being above and in front. Its surface is smooth, coated with cartilage in the recent state, and presents, a little behind and below its centre, an ovoid depression, for the attachment of the ligamentum teres. The *neck* is a flattened pyramidal process of bone which connects the head with the shaft. It varies in length and obliquity at various periods of life and under different circumstances. In infancy the angle is widest, and becomes lessened during growth, so that at puberty it forms a gentle curve from the axis of the shaft. In the adult it forms an angle of about one hundred and thirty degrees with the shaft, but varies in inverse proportion to the development of the pelvis and the stature. In consequence of the prominence of the hips and widening of the pelvis in the female the neck of the thigh-bone forms more nearly a right angle with the shaft than it does in man. It has been stated that the angle diminishes in old age and the direction of the neck becomes horizontal, but this statement is founded on insufficient evidence. Professor Humphry states that he has not had the opportunity of making sufficient measurements to settle the question, but, so far as his observation goes, "the change is the exception rather than the rule."[1] The neck is flattened from before backward, contracted in the middle, and broader at its outer extremity, where it is connected with the shaft, than at its summit, where it is attached to the head. The vertical diameter of the outer half is increased by the thickening of the lower edge, which slopes downward to join the shaft at the lesser trochanter, so that the outer half of the neck is flattened from before backward, and its vertical diameter measures one-third more than the antero-posterior. The inner half is smaller and of a more circular shape. The *anterior surface* of the neck is perforated by numerous vascular foramina. The *posterior surface* is smooth, and is broader and more concave than the anterior; it gives attachment externally to the posterior part of the capsular ligament of the hip-joint. The *superior border* is short and thick, bounded externally by the great trochanter, and its surface perforated by large foramina. The *inferior border*, long and narrow, curves a little backward, to terminate at the lesser trochanter.

The **Trochanters** (*τροχάω*, to run or roll) are prominent processes of bone which afford leverage to the muscles which rotate the thigh on its axis. They are two in number, the greater and the lesser.

The **Great Trochanter** is a large, irregular, quadrilateral eminence situated at the outer side of the neck, at its junction with the upper part of the shaft. It is directed a little outward and backward, and in the adult is about three-quarters of an inch lower than the head. It presents for examination two surfaces and four borders. The *external surface*, quadrilateral in form, is broad, rough, convex, and marked by a prominent diagonal line, which extends from the posterior superior to the anterior inferior angle; this line serves for the attachment of the tendon of the Gluteus medius. Above the line is a triangular surface, sometimes rough for part of the tendon of the same muscle, sometimes smooth for the interposition of a bursa between that tendon and the bone. Below and behind the diagonal line is a smooth triangular surface over which the tendon of the Gluteus maximus muscle plays, a bursa being interposed. The *internal surface* is of much less extent than the external, and presents at its base a deep depression, the *digital* or *trochanteric fossa*, for the attachment of the tendon of the Obturator externus muscle. The

---

[1] See *Old Age, and Changes Incidental to it*, p. 25.

Fig. 223.

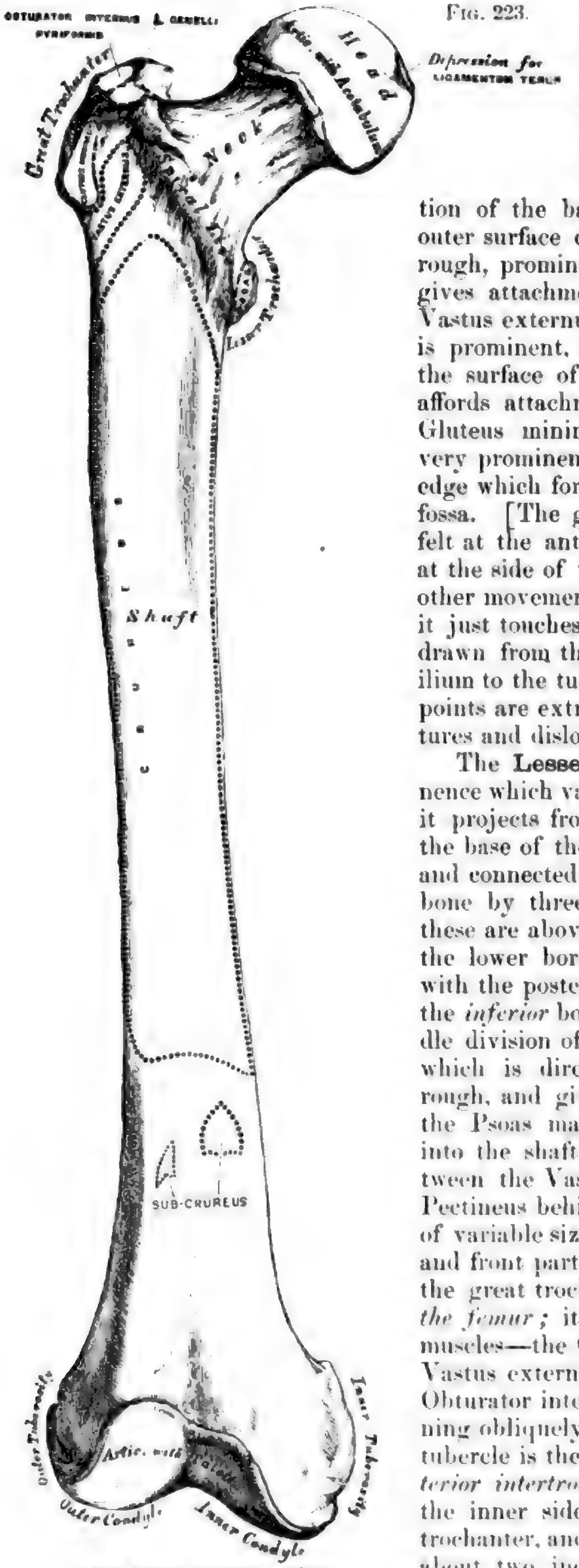

Right Femur, anterior surface.

superior border is free; it is thick and irregular, and marked by impressions, for the attachment of the Pyriformis behind, the Obturator internus and Gemelli in front. The *inferior border* corresponds to the point of junction of the base of the trochanter with the outer surface of the shaft; it is marked by a rough, prominent, slightly curved ridge which gives attachment to the upper part of the Vastus externus muscle. The *anterior border* is prominent, somewhat irregular, as well as the surface of bone immediately below it; it affords attachment by its outer part to the Gluteus minimus. The *posterior border* is very prominent, and appears as a free rounded edge which forms the back part of the digital fossa. [The great trochanter can be readily felt at the anterior part of a marked hollow at the side of the buttock, and its rotation and other movements observed here. The top of it just touches a line, called "Nélaton's line," drawn from the anterior-superior spine of the ilium to the tuberosity of the ischium. These points are extremely useful in relation to fractures and dislocations of the femur.]

The **Lesser Trochanter** is a conical eminence which varies in size in different subjects; it projects from the lower and back part of the base of the neck. Its base is triangular, and connected with the adjacent parts of the bone by three well-marked borders: two of these are above—the *internal* continuous with the lower border of the neck; the *external*, with the posterior intertrochanteric line, while the *inferior* border is continuous with the middle division of the linea aspera. Its summit, which is directed inward and backward, is rough, and gives insertion to the tendon of the Psoas magnus. The Iliacus is inserted into the shaft below the lesser trochanter, between the Vastus internus in front and the Pectineus behind. A well-marked prominence of variable size, which projects from the upper and front part of the neck at its junction with the great trochanter, is called the *tubercle of the femur;* it is the point of meeting of five muscles—the Gluteus minimus externally, the Vastus externus below, and the tendon of the Obturator internus and Gemelli above. Running obliquely downward and inward from the tubercle is the *spiral line* of the femur, or *anterior intertrochanteric line;* it winds round the inner side of the shaft, below the lesser trochanter, and terminates in the linea aspera, about two inches below this eminence. Its upper half is rough, and affords attachment to the capsular ligament of the hip-joint; its lower half is less prominent, and gives attachment to the upper part of the Vastus internus. Running obliquely downward and inward from the summit of the great trochanter on the posterior surface of the neck is a very prominent, well-marked ridge, the *posterior intertrochanteric line*. Its upper half forms the posterior border of the great trochanter, and its lower half runs downward and inward across the neck of the bone to the upper and back part of the lesser trochanter. A slight ridge sometimes commences about the middle of the posterior intertrochanteric line, and passes vertically downward for about two inches along the back part of the shaft; it is called the *linea quadrati*, and gives attachment to the Quadratus femoris and a few fibres of the Adductor magnus muscles.[1]

The **shaft,** almost perfectly cylindrical in form, is a little broader above than in the centre, and somewhat flattened from before backward below. It is slightly arched, so as to be convex in front—concave behind, where it is strengthened by a prominent longitudinal ridge, *the linea aspera*. It presents for examination three borders, separating three surfaces. Of the three borders, one, the linea aspera, is posterior; the other two are placed laterally.

The **linea aspera** (Fig. 224) is a prominent longitudinal ridge or crest, presenting on the middle third of the bone an external lip, an internal lip, and a rough intermediate space. A little above the centre of the shaft this crest divides into three lines;[2] the most

Fig. 224.

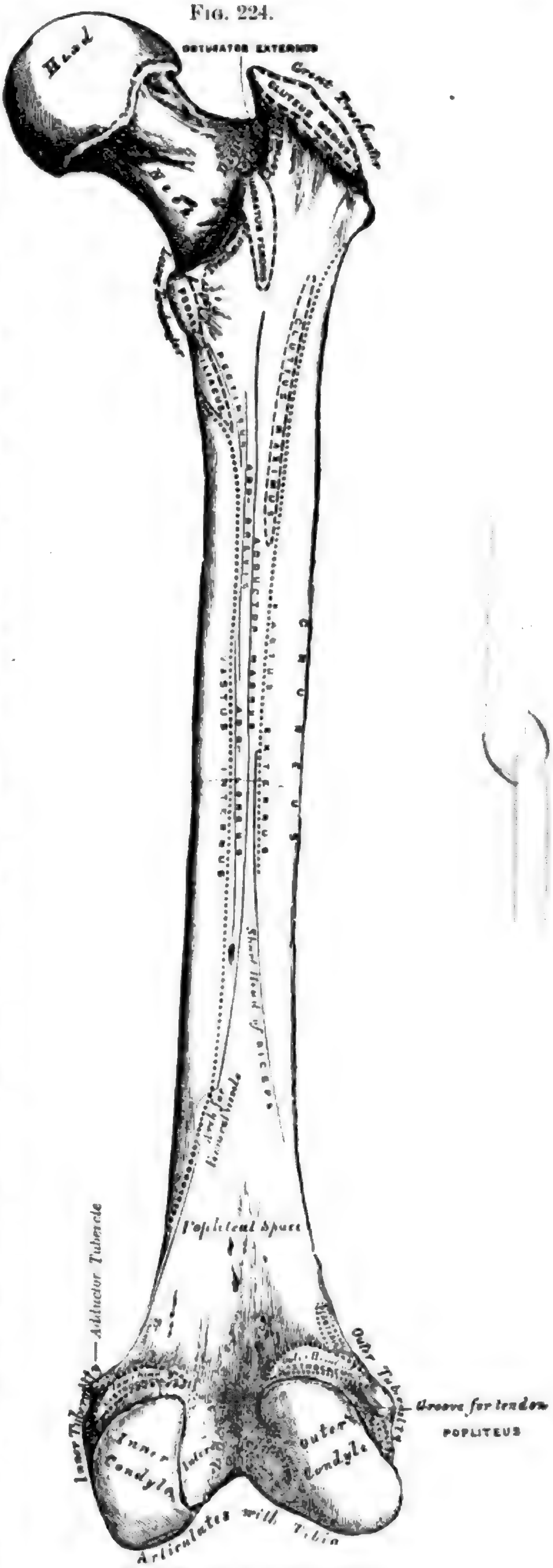
Head
Neck
OBTURATOR EXTERNUS
Great Trochanter
VASTUS INTERNUS
VASTUS EXTERNUS
Short Head of BICEPS
Popliteal Space
Adductor Tubercle
Inner Tuberosity
Outer Tuberosity
Groove for tendon
POPLITEUS
Inner Condyle
Outer Condyle
Articulates with Tibia

Right Femur, posterior surface.

---

[1] Generally there is merely a slight thickening about the centre of the intertrochanteric line, marking the point of attachment of the Quadratus femoris. This is termed by some anatomists the *tubercle of the quadratus.*

[2] Of these three lines, only the outer and inner are described by many anatomists: the linea aspera is then said to bifurcate above and below.

external one becomes very rough, and is continued almost vertically upward to the base of the great trochanter; the middle one, the least distinct, is continued to the base of the trochanter minor; and the internal one is lost above in the spiral line of the femur. Below, the linea aspera divides into two ridges, which enclose between them a triangular space, the *popliteal space*, upon which rests the popliteal artery. Of these two ridges, the outer one is the more prominent and descends to the summit of the outer condyle. The inner one is less marked, especially at its upper part, where it is crossed by the femoral artery. It terminates below, at the summit of the internal condyle, in a small tubercle, the ***adductor tubercle***, which affords attachment to the tendon of the Adductor magnus.

To the inner lip of the linea aspera, along its whole length, is attached the Vastus internus, and to the whole length of the outer lip, the Vastus externus. The Adductor magnus is also attached to the whole length of the linea aspera, being connected with the outer lip above and the inner lip below. Between the Vastus externus and the Adductor magnus are attached two muscles—viz. the Gluteus maximus above and the short head of the Biceps below. Between the Adductor magnus and the Vastus internus four muscles are attached: the Iliacus and Pectineus above (the latter to the middle of the upper divisions); below these the Adductor brevis and Adductor longus. The linea aspera is perforated a little below its centre by the nutrient canal, which is directed obliquely upward.

The *two lateral* borders of the femur are only slightly marked, the outer one extending from the anterior inferior angle of the great trochanter to the anterior extremity of the external condyle; the inner one from the spiral line, at a point opposite the trochanter minor, to the anterior extremity of the internal condyle. The internal border marks the limit of attachment of the Crureus muscle internally.

The **anterior surface** includes that portion of the shaft which is situated between the two lateral borders. It is smooth, convex, broader above and below than in the centre, slightly twisted, so that its upper part is directed forward and a little outward, its lower part forward and a little inward. To the upper three-fourths of this surface the Crureus is attached; the lower fourth is separated from the muscle by the intervention of the synovial membrane of the knee-joint, and affords attachment to the Subcrureus to a small extent. The *external surface* includes the portion of bone between the external border and the outer lip of the linea aspera; it is continuous above with the outer surface of the great trochanter; below with the outer surface of the external condyle: to its upper three-fourths is attached the outer portion of the Crureus muscle. The *internal surface* includes the portion of bone between the internal border and the inner lip of the linea aspera; it is continuous above with the lower border of the neck; below, with the inner side of the internal condyle: it is covered by the Vastus internus muscle.

The **Lower Extremity**, larger than the upper, is of a cuboid form, flattened from before backward, and divided into two large eminences, the *condyles* (*κόνδυλος*, a knuckle), by an interval which presents a smooth depression in front called the *trochlea*, and a notch of considerable size behind—the *intercondyloid notch.* The *external condyle* is the more prominent anteriorly, and is the broader both in the antero-posterior and transverse diameters. The *internal condyle* is the narrower, longer, and more prominent inferiorly. This difference in the length of the two condyles is only observed when the bone is perpendicular, and depends upon the obliquity of the thigh-bones in consequence of their separation above at the articulation with the pelvis. If the femur is held obliquely, the surfaces of the two condyles will be seen to be nearly horizontal. The two condyles are directly continuous in front, and form a smooth trochlear surface, the external border of which is more prominent and ascends higher than the internal one. This surface articulates with the patella. It presents a median groove which extends downward and backward to the intercondyloid notch, and two lateral convexities, of which the external is the broader, more prominent, and prolonged farther upward upon the front of the outer condyle. The intercondyloid notch lodges the crucial ligaments; it is bounded laterally by the opposed surfaces of the two condyles, and in front by the lower end of the shaft.

Outer Condyle.—The *outer surface* of the external condyle presents, a little behind its centre, an eminence, the *outer tuberosity;* it is less prominent than the inner tuberosity, and gives attachment to the external lateral ligaments of the knee. Immediately beneath it is a groove which commences at a depression a little behind the centre of the lower border of this surface: the depression gives origin to the Popliteus muscle, the tendon of which is lodged in the groove, which is smooth, covered with cartilage in the recent state, and runs upward and backward to the posterior extremity of the condyle. The *inner surface* of the outer condyle forms one of the lateral boundaries of the intercondyloid notch, and gives attachment by its posterior part to the anterior crucial ligament. The *inferior surface* is convex, smooth, and broader than that of the internal condyle. The posterior extremity is convex and smooth: just above the articular surface is a depression for the tendon of the outer head of the Gastrocnemius, above which is the origin of the Plantaris.

Inner Condyle.—The *inner surface* of the inner condyle presents a convex eminence, the *inner tuberosity,* rough, for the attachment of the internal lateral ligament. The *outer side* of the inner condyle forms one of the lateral boundaries of the intercondyloid notch, and gives attachment by its anterior part to the posterior crucial ligament. Its *inferior* or *articular surface* is convex, and presents a less extensive surface than the external condyle. Just above the articular surface of the condyle, behind, is a depression for the tendon of origin of the inner head of the Gastrocnemius.

["The inner aspect of the internal condyle in every position of the limb faces nearly in the direction of the head of the femur" (Bigelow).

The careful external study of the knee on the living model is of the greatest use. The patellar groove and its borders, a large part of the articular surfaces of the femur and tibia, the groove between them, and most of the bony prominences on all the bones, and the varying positions of the patella, can be easily noticed. It should be studied both in extension and various degrees of flexion.]

Structure.—The shaft of the femur is a cylinder of compact tissue hollowed by a large medullary canal. The cylinder is of great thickness and density in the middle third of the shaft, where the bone is narrowest and the medullary canal well formed; but above and below this the cylinder gradually becomes thinner, owing to a separation of the layers of the bone into cancelli, which project into the medullary canal, and finally obliterate it, so that the upper and lower ends of the shaft, and the articular extremities more especially, consist of cancellated tissue invested by a thin compact layer.

The arrangement of the cancelli in the ends of the femur is remarkable. In the upper end (Fig. 225) they run in parallel columns, *a*, *a*, from the summit of the head to the under wall of the neck, while a series of transverse fibres, *b*, *b*, cross the parallel columns and connect them to the upper wall of the neck. Another series of plates, *c*, *c*, springs from the whole interior of the cylinder above the lesser trochanter; these pass upward, and converge to form a series of arches beneath the upper wall of the neck near its junction with the great trochanter. This structure is admirably adapted to sustain, with the greatest mechanical advantage, concussion or weight transmitted from above, and serves an important office in strengthening a part especially liable to fracture.

Fig. 225.

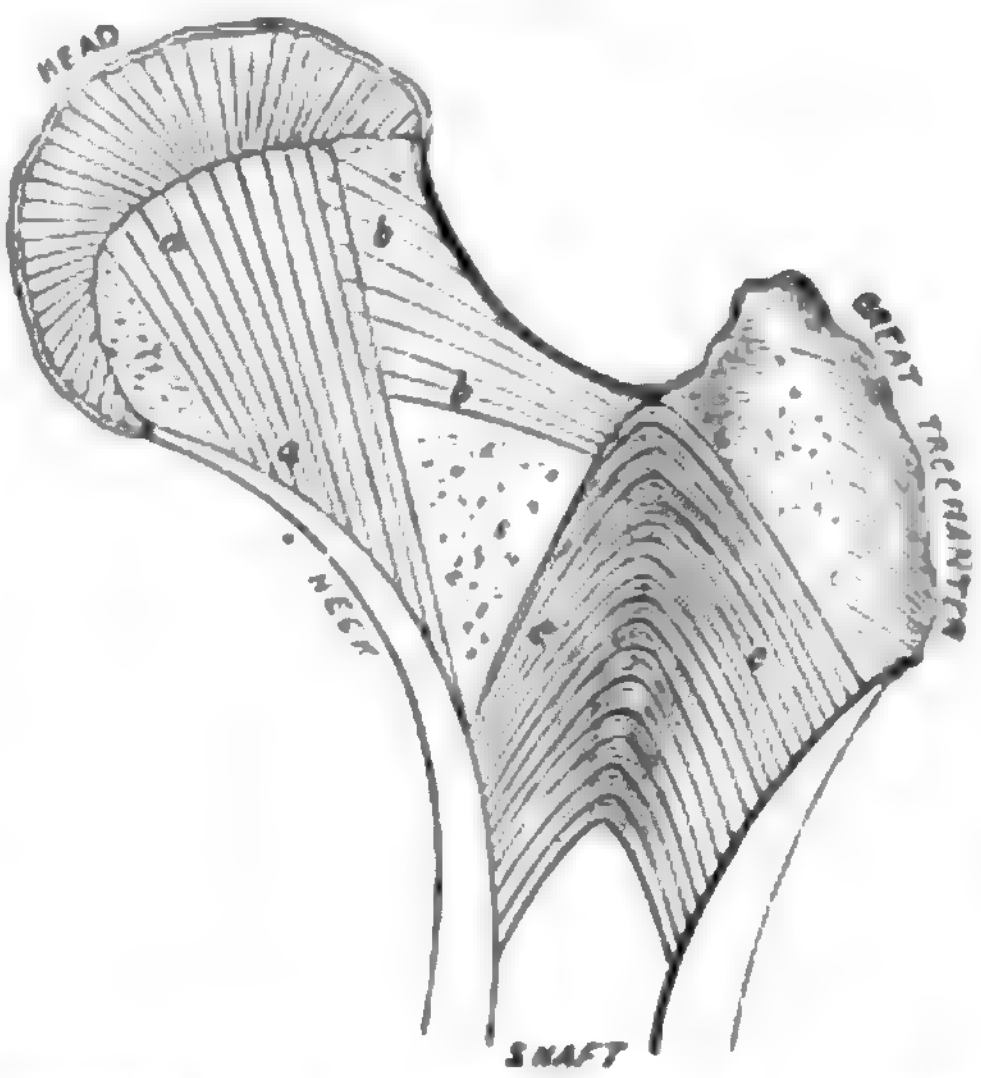

Diagram showing the Structure of the Neck of the Femur (after Ward).

In the lower end the cancelli spring on all sides from the inner surface of the cylinder, and descend in a perpendicular direction to the articular surface, the cancelli being strongest and having a more accurately perpendicular course above the condyles.

Articulations.—With three bones: the os innominatum, tibia, and patella.

Development (Fig. 226).—The femur is developed by *five* centres: one for the shaft, one for each extremity, and one for each trochanter. Of all the long bones except the clavicle, it is the first to show traces of ossification; this commences in the shaft at about the fifth week of fœtal life, the centres of ossification in the epiphyses appearing in the following order: First, in the lower end of the bone at the ninth month of fœtal life; from this the condyles and tuberosities are formed; in the head, at the end of the first year after birth; in the great trochanter, during the fourth year; and in the lesser trochanter, between the thirteenth and fourteenth. The order in which the epiphyses are joined to the shaft is the reverse of that of their appearance: their junction does not commence until after puberty, the lesser trochanter being first joined, then the greater, then the head, and lastly the inferior extremity (the first in which ossification commenced), which is not united until the twentieth year. [The growth of the femur in length is greatest at the junction of the shaft with the inferior epiphysis, owing to its late ossification. While the entire body grows from birth to thirty years of age 3.37 times, the growth at the lower end of the femur is 7.30 times, the greatest in the entire body. This should make the surgeon cautious, in resection of the knee in children, not to disturb the epiphysial cartilage if at all possible, in order to interfere as little as may be with the growth of the leg. This is especially important in girls, on account of its possible influence on the pelvis.]

FIG. 226.

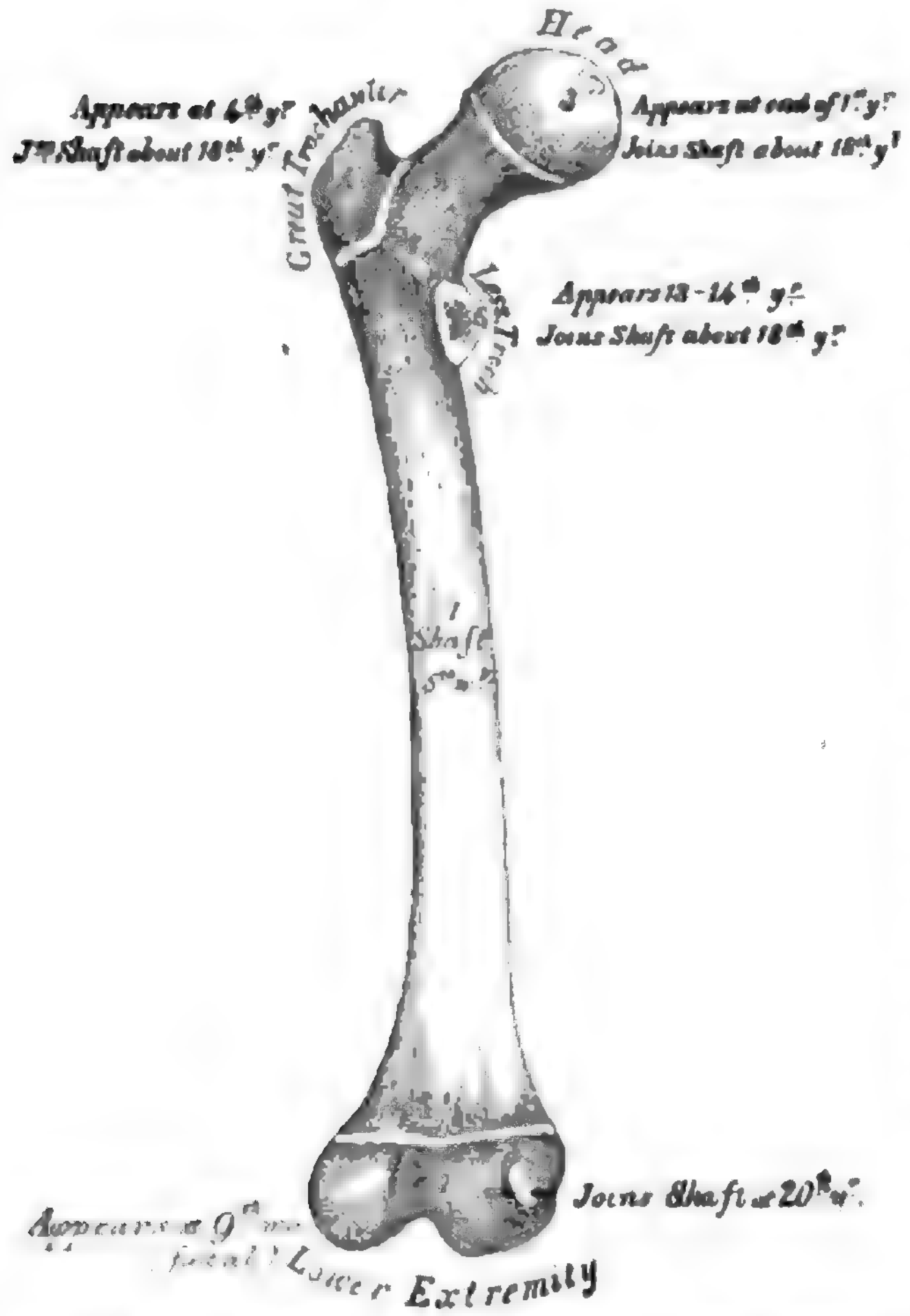

Plan of the Development of the Femur, by five centres.

Attachment of Muscles.—To twenty-three: to the great trochanter, the Gluteus medius, Gluteus minimus, Pyriformis, Obturator internus, Obturator externus, Gemellus superior, Gemellus inferior, and Quadratus femoris. To the lesser trochanter, the Psoas magnus and the Iliacus below it. To the shaft, the Vastus externus, Gluteus maximus, short head of the Biceps, Vastus internus, Adductor magnus, Pectineus, Adductor brevis, Adductor longus, Crureus, and Subcrureus. To the condyles, the Gastrocnemius, Plantaris, and Popliteus.

THE LEG.

The skeleton of the Leg consists of three bones: the Patella, a large sesamoid bone placed in front of the knee, and the Tibia and Fibula.

The Patella (Figs. 227, 228).

The **Patella** (*patella*, a small pan) is a flat, triangular bone situated at the anterior part of the knee-joint. It is usually regarded as a sesamoid bone developed in the tendon of the Quadriceps extensor. It resembles these bones in its structure, being composed mainly of dense cancellous tissue, and in its development, the nucleus presenting a knotty or tuberculated outline similar to other sesamoid bones. It serves to protect the front of the joint, and increases the leverage of the Quadriceps extensor by making it act at a greater angle. It presents an anterior and posterior surface, three borders, and an apex.

Fig. 227.



Right Patella, anterior surface.

Fig. 228.



Posterior Surface.

The **anterior surface** is convex, perforated by small apertures for the passage of nutrient vessels, and marked by numerous rough longitudinal striæ. This surface is covered, in the recent state, by an expansion from the tendon of the Quadriceps extensor, which is continuous below with the superficial fibres of the ligamentum patellæ. It is separated from the integument by a bursa. The **posterior surface** presents a smooth, oval-shaped, articular surface covered with cartilage in the recent state, and divided into two facets by a vertical ridge, which descends from the superior toward the inferior angle of the bone. The ridge corresponds to the groove on the trochlear surface of the femur, and the two facets to the articular surfaces of the two condyles; the outer facet, for articulation with the outer condyle, being the broader and deeper. This character serves to indicate the side to which the bone belongs. In a well-marked bone these two articular surfaces may be seen to be divided into three distinct facets by two transverse ridges which pass outward from the central vertical ridges. Of these, the middle one is the largest; it is concave from above downward and occupies two-thirds of the surface. This part rests against the prominent condyles of the femur when the joint is in the mid-position between flexion and extension. Above and below this are narrow, flat facets separated by the transverse ridges, which respectively rest against the condyles in the extended and flexed positions of the joint. Below the articular surface is a rough, convex, non-articular depression, the lower half of which gives attachment to the ligamentum patellæ, the upper half being separated from the head of the tibia by adipose tissue.

The *superior border* is thick, directed upward, and cut obliquely at the expense of its anterior surface; it gives attachment to that portion of the Quadriceps extensor which is derived from the Rectus and Crureus muscles. The *lateral borders* are thinner, converging below. They give attachment to that portion of the Quadriceps extensor derived from the external and internal Vasti muscles. According to Goodsir, the inner border is marked posteriorly by a narrow marginal facet, which is cut off from the rest of the articular surface by a slightly marked vertical ridge. This facet rests against the outer border of the inner condyle during flexion of the knee.

The **apex** is pointed, and gives attachment to the ligamentum patellæ.

[In the model, when the leg is entirely extended, the patella is very movable, but so soon as flexion begins it is fixed in its groove. It is always in contact with the femur in extension, unless separated from it by an accumulation of fluid inside the joint. In periarticular accumulation of pus or other fluid this floating of the patella will not take place. Its varying positions and relations in different degrees of flexion are important and can readily be studied.]

Structure.—It consists of a nearly uniform, dense cancellous tissue covered by a thin, compact lamina. The cancelli immediately beneath the anterior surface are arranged parallel with it. In the rest of the bone they radiate from the posterior articular surface toward the other parts of the bone.

Development.—By a single centre, which makes its appearance, according to Béclard, about the third year. In two instances I have seen this bone cartilaginous throughout at a much later period (six years). More rarely, the bone is developed by two centres, placed side by side. Ossification is completed about the age of puberty.

Articulations.—With the two condyles of the femur.

Attachment of Muscles.—To four: the Rectus, Crureus, Vastus internus, and Vastus externus. These muscles, joined at their insertion, constitute the Quadriceps extensor cruris.

FIG. 229.


Head
Spine
External Tuberosity
Internal Tuberosity
Head
Styloid process
Tubercle
Ext. Lateral Lig.
Ligament Patellæ
Fibula
Tibia
Peroneus
Sartorius
Attachment of Interosseous Membrane
Crest
Internal Surface, Subcutaneous
Subcutaneous
Surface covered by Ext. Tendons
Internal Malleolus
External Malleolus

Bones of the Right Leg, anterior surface.

THE TIBIA (Figs. 229, 230).

The **Tibia** (*tibia*, a flute or pipe) is situated at the front and inner side of the leg, and, excepting the femur, is the longest and largest bone in the skeleton. It is prismoid in form, expanded above, where it enters into the knee-joint, more slightly enlarged below. In the male its direction is vertical and parallel with the bone of the opposite side; but in the female it has a slight oblique direction downward and outward, to compensate for the oblique direction of the femur inward. It presents for examination a shaft and two extremities.

The **Upper Extremity,** or head, is large and expanded on each side into two lateral eminences, the *tuberosities*. *Superiorly*, the tuberosities present two smooth, concave surfaces, which articulate with the condyles of the femur; the internal articular surface is longer and deeper, but narrower, than the external, and oval from before backward, to articulate with the internal condyle; the external one being broader, flatter, and more circular, to articulate with the external condyle. Between the two articular surfaces, and nearer the posterior than the anterior aspect of the bone, is an eminence, the *spinous process* of the tibia, surmounted by a prominent tubercle on each side, which gives attachment to the extremities of the semilunar fibro-cartilages; in front and behind the spinous process is a rough depression, for the attachment of the anterior and posterior crucial ligaments and the semilunar cartilages. The *anterior surfaces* of the tuberosities are continuous with one another, forming a single large surface which is somewhat flattened: it is triangular, broad above, and perforated by large vascular foramina; narrow below, where it terminates in a prominent oblong elevation of large size, the *tubercle* of the tibia: the lower half of this tubercle is rough, for the attachment of the ligamentum patellæ; the upper half is a smooth facet, corresponding, in the recent state, with a bursa which separates the ligament from the bone. *Posteriorly*, the tuberosities are separated from each other by a shallow depression, the *popliteal notch*, which gives attachment to part of the posterior crucial ligament and part of the posterior ligament of the knee-joint. The posterior surface of the inner tuberosity presents a deep transverse groove, for the insertion of one of the fasciculi of the tendon of the Semimembranosus. The *lateral surfaces* are convex and rough: the *internal* one, the most prominent, gives attachment to the internal lateral ligament, and is marked by a groove, for the insertion of the innermost fasciculus of the tendon of the Semimembranosus. The *external* surface is the least prominent; it presents posteriorly a flat articular facet, nearly circular in form, directed downward, backward, and outward, for articulation with the fibula. In front it presents a prominent rough eminence situated on a level with the upper border of the tubercle of the tibia, for the attachment of the ilio-tibial band. Just below this the Extensor longus digitorum and a slip from the Biceps are attached.

FIG. 230.

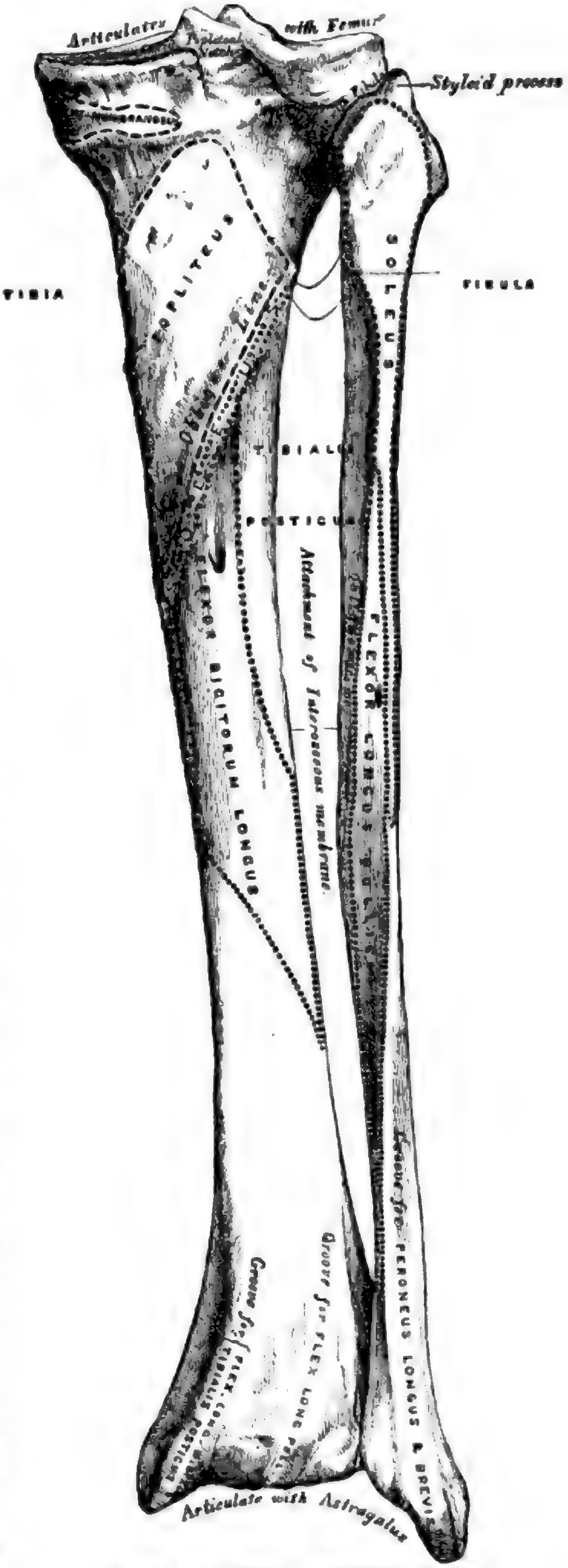
Articulates with Femur
Popliteal Notch
Styloid process
TIBIA
FIBULA
POPLITEUS
Oblique Line
SOLEUS
TIBIALIS
POSTICUS
Attachment of Interosseous membrane
FLEXOR DIGITORUM LONGUS
FLEXOR LONGUS POLLICIS
Groove for PERONEUS LONGUS & BREVIS
Groove for FLEX. LONG. POL.
Groove for TIBIALIS POSTICUS FLEX. LONG. DIGIT.
Articulate with Astragalus

Bones of the Right Leg, posterior surface.

The **Shaft** of the tibia is of a triangular prismoid form, broad above, gradually decreasing in size to its most slender part, at the commencement of its lower fourth, where fracture most frequently occurs; it then enlarges again toward its lower extremity. It presents for examination three surfaces and three borders.

The **anterior border,** the most prominent of the three, is called the *crest of the tibia*, or, in popular language, the *shin;* it commences above at the tubercle, and terminates below at the anterior margin of the inner malleolus. This border is very prominent in the upper two-thirds of its extent, smooth and rounded below. It presents a very flexuous course, being curved outward above and inward below; it gives attachment to the deep fascia of the leg.

The **internal border** is smooth and rounded above and below, but more prominent in the centre; it commences at the back part of the inner tuberosity, and terminates at the posterior border of the internal malleolus; its upper part gives attachment to the internal lateral ligament of the knee to the extent of about two inches, and to some fibres of the Popliteus muscle; its middle third, to some fibres of the Soleus and Flexor longus digitorum muscles.

The **external border, or interosseous ridge,** is thin and prominent, especially its central part, and gives attachment to the interosseous membrane; it commences above in front of the fibular articular facet, and bifurcates below to form the boundaries of a triangular rough surface, for the attachment of the interosseous ligament connecting the tibia and fibula.

The **internal surface** is smooth, convex, and broader above than below; its upper third, directed forward and inward, is covered by the aponeurosis derived from the tendon of the Sartorius and by the tendons of the Gracilis and Semitendinosus, all of which are inserted nearly as far forward as the anterior border; in the rest of its extent it is subcutaneous. [All this surface, together with the crest and the internal malleolus, can be well studied on the living model. They are of great use in determining the question of fracture, periostitis, œdema, etc.]

The **external surface** is narrower than the internal; its upper two-thirds present a shallow groove for the attachment of the Tibialis anticus muscle; its lower third is smooth, convex, curves gradually forward to the anterior part of the bone, and is covered from within outward by the tendons of the following muscles: Tibialis anticus, Extensor proprius pollicis, Extensor longus digitorum.

The **posterior surface** (Fig. 230) presents at its upper part a prominent ridge, the *oblique line* of the tibia, which extends from the back part of the articular facet for the fibula obliquely downward to the internal border, at the junction of its upper and middle thirds. It marks the limit for the insertion of the Popliteus muscle, and serves for the attachment of the popliteal fascia and part of the Soleus, Flexor longus digitorum, and Tibialis posticus muscles; the triangular concave surface, above and to the inner side of this line, gives attachment to the Popliteus muscle. The middle third of the posterior surface is divided by a vertical ridge into two lateral halves: the ridge is well marked at its commencement at the oblique line, but becomes gradually indistinct below: the inner and broader half gives attachment to the Flexor longus digitorum, the outer and narrower to part of the Tibialis posticus. The remaining part of the bone presents a smooth surface covered by the Tibialis posticus, Flexor longus digitorum, and Flexor longus pollicis muscles. Immediately below the oblique line is the medullary foramen, which is directed obliquely downward.

The **Lower Extremity,** much smaller than the upper, presents five surfaces; it is prolonged downward, on its inner side, into a strong process, the *internal malleolus.* The *inferior surface* of the bone is quadrilateral, and smooth for articulation with the astragalus. This surface is concave from before backward, and broader in front than behind. It is traversed from before backward by a slight elevation separating two lateral depressions. It is narrow internally, where the articular surface becomes continuous with that on the inner malleolus. The *anterior surface* of the lower extremity is smooth and rounded above, and covered by the tendons of the Extensor muscles of the toes; its lower margin presents a rough transverse depression, for the attachment of the anterior ligament of the ankle-joint; the *posterior* *surface* presents a superficial groove directed obliquely downward and inward, continuous with a similar groove on the posterior extremity of the astragalus, and serving for the passage of the tendon of the Flexor longus pollicis; the *external surface* presents a triangular rough depression for the attachment of the inferior interosseous ligament connecting it with the fibula; the lower part of this depression is smooth, covered with cartilage in the recent state, and articulates with the fibula. This surface is bounded by two prominent ridges, continuous above with the interosseous ridge: they afford attachment to the anterior and posterior tibio-fibular ligaments. The *internal surface* of the lower extremity is prolonged downward to form a strong pyramidal process, flattened from without inward—the *inner malleolus*. The *inner surface* of this process is convex and subcutaneous; its *outer surface*, smooth and slightly concave, deepens the articular surface for the astragalus; its *anterior border* is rough, for the attachment of the anterior fibres of the Deltoid ligament; its *posterior border* presents a broad and deep groove directed obliquely downward and inward, which is occasionally double; this groove transmits the tendons of the Tibialis posticus and Flexor longus digitorum muscles. The *summit* of the internal malleolus is marked by a rough depression behind, for the attachment of the internal lateral ligament of the ankle-joint.

Structure.—Like that of the other long bones. At the junction of the middle and lower third, where the bone is smallest, the wall of the shaft is thicker than in other parts, in order to compensate for the smallness of the calibre of the bone.

Development.—By *three* centres (Fig. 231): one for the shaft and one for each extremity. Ossification commences in the centre of the shaft about the seventh week, and gradually extends toward either extremity. The centre for the upper epiphysis appears at birth; it is flattened in form, and has a thin, tongue-shaped process in front, which forms the tubercle. That for the lower epiphysis appears in the second year. The lower epiphysis joins the shaft at about the eighteenth, and the upper one about the twentieth, year. Two additional centres occasionally exist—one for the tongue-shaped process of the upper epiphysis, the tubercle, and one for the inner malleolus.

Fig. 231.

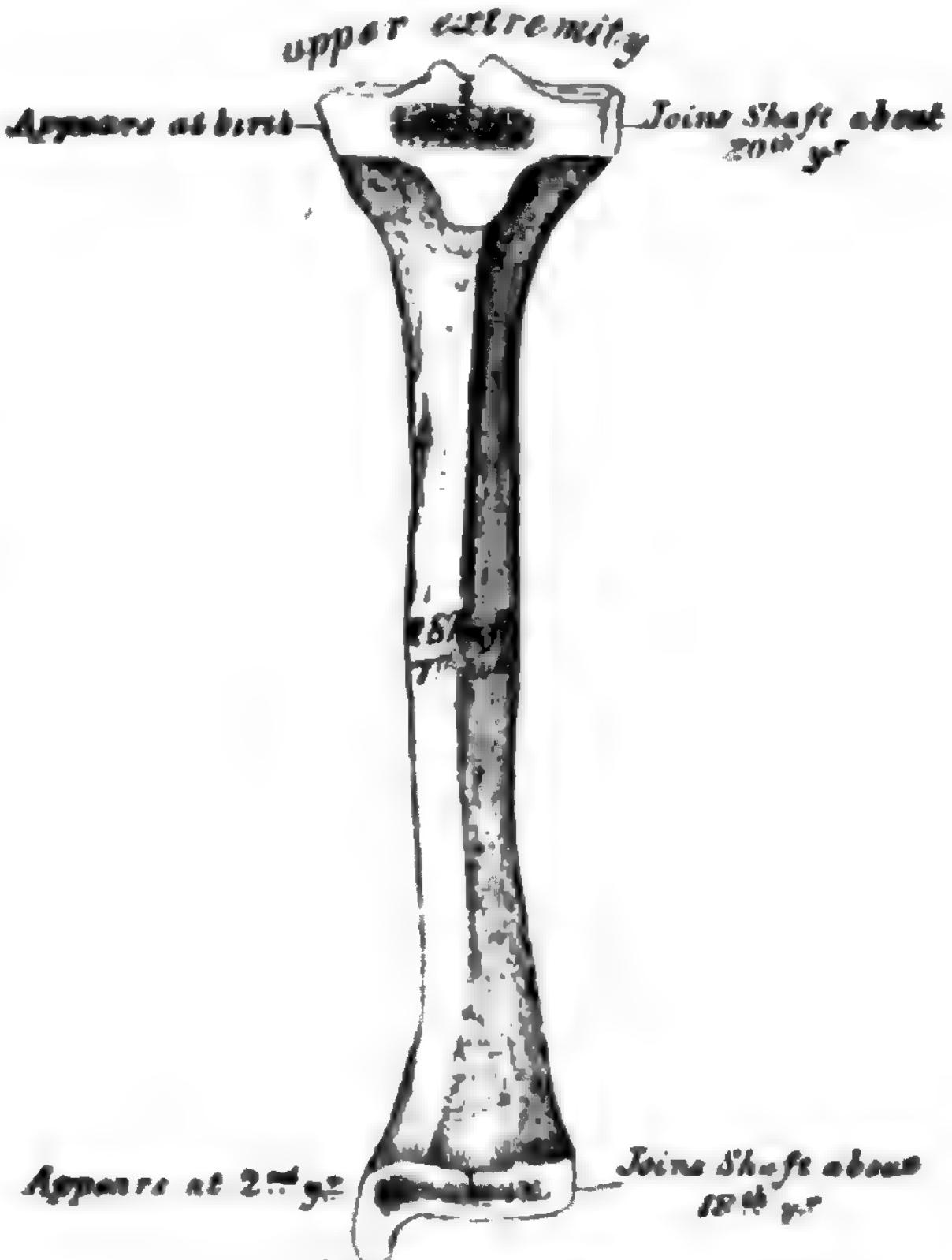

Plan of the Development of the Tibia, by three centres.

Articulations.—With three bones: the femur, fibula, and astragalus.

Attachment of Muscles.—To twelve: to the inner tuberosity, the Semimembranosus; to the outer tuberosity, the Tibialis anticus and Extensor longus digitorum and Biceps; to the shaft, its internal surface, the Sartorius, Gracilis, and Semitendinosus; to its external surface, the Tibialis anticus; to its posterior surface, the Popliteus, Soleus, Flexor longus digitorum, and Tibialis posticus; to the tubercle, the ligamentum patellæ.

THE FIBULA (Figs. 229, 230).

The **Fibula** (*fibula*, a clasp) is situated at the outer side of the leg. It is the smaller of the two bones, and, in proportion to its length, the most slender of all the long bones; it is placed nearly parallel with the tibia. Its upper extremity is small, placed [toward the back of the head of the tibia, and] below the level of the knee-joint, and excluded from its formation; the lower extremity inclines a little forward, so as to be on a plane anterior to that of the upper end, projects below the tibia, and forms the outer angle. It presents for examination a shaft and two extremities.

The **Upper Extremity,** or **head,** is of an irregular rounded form, presenting above a flattened articular facet directed upward and inward, for articulation with a corresponding facet on the external tuberosity of the tibia. [This extremity can always be felt in the model.] On the outer side is a thick and rough prominence, continued behind into a pointed eminence, the *styloid process,* which projects upward from the posterior part of the head. The prominence gives attachment to the tendon of the Biceps muscle and to the long external lateral ligament of the knee, the ligament dividing the tendon into two parts. The summit of the styloid process gives attachment to the short external lateral ligament. The remaining part of the circumference of the head is rough, for the attachment of the anterior superior tibio-fibular ligament and the upper and anterior part of the Peroneus longus in front, and of the posterior superior tibio-fibular ligament and the upper fibres of the outer head of the Soleus muscle behind.

The **Lower Extremity,** or **external malleolus,** is of a pyramidal form, somewhat flattened from without inward, and is longer and descends lower than the internal malleolus. Its *external surface* is convex, subcutaneous, and continuous with the triangular (also subcutaneous) surface on the outer side of the shaft. The *internal surface* presents in front a smooth triangular facet, broader above than below and convex from above downward, which articulates with a corresponding surface on the outer side of the astragalus. Behind and beneath the articular surface is a rough depression, which gives attachment to the posterior fasciculus of the external lateral ligament of the ankle. The *anterior border* is thick and rough, and marked below by a depression, for the attachment of the anterior fasciculus of the external lateral ligament. The *posterior border* is broad and marked by a shallow groove, for the passage of the tendons of the Peroneus longus and brevis muscles. The *summit* is rounded, and gives attachment to the middle fasciculus of the external lateral ligament.

The **shaft** presents four surfaces—anterior, posterior, internal, and external; and four borders—the antero-external, the antero-internal, the postero-external, and the postero-internal.

The **antero-external border** commences above in front of the head, runs vertically downward to a little below the middle of the bone, and then, curving somewhat outward, bifurcates so as to embrace the triangular subcutaneous surface immediately above the outer surface of the external malleolus. This border gives attachment to an intermuscular septum which separates the extensor muscles on the anterior surface of the leg from the Peroneus longus and brevis muscles.

The **antero-internal border,** or **interosseous ridge,** is situated close to the inner side of the preceding, and runs nearly parallel with it in the upper third of its extent, but diverges from it so as to include a broader space in the lower two-thirds. It commences above just beneath the head of the bone (sometimes it is quite indistinct for about an inch below the head), and terminates below at the apex of a rough triangular surface immediately above the articular facet of the external malleolus. It serves for the attachment of the interosseous membrane, and separates the extensor muscles in front from the flexor muscles behind. The portion of bone included between the anterior and interosseous lines forms the anterior surface.

The **postero-external border** is sharp and prominent; it commences above at the base of the styloid process, and terminates below in the posterior border of the outer malleolus. It is directed outward above, backward in the middle of its course, backward and a little inward below, and gives attachment to an aponeurosis which separates the peronei muscles on the outer surface of the shaft from the flexor muscles on its posterior surface.

The **postero-internal border,** sometimes called the *oblique line,* commences above at the inner side of the head, and terminates by becoming continuous with the antero-internal border or interosseous ridge at the lower fourth of the bone. It is well marked and prominent at the upper and middle parts of the bone, less marked below, where it terminates at the apex of the rough triangular surface immediately above the articular facet of the external malleolus. It gives attachment to an aponeurosis which separates the Tibialis posticus from the Soleus above and the Flexor longus pollicis below.

The **anterior surface** is the interval between the antero-external and antero-internal borders. It is extremely narrow and flat in the upper third of its extent, broader and grooved longitudinally in its lower third; it serves for the attachment of three muscles—the Extensor longus digitorum, Peroneus tertius, and Extensor proprius pollicis.

The **external surface** is the space between the antero-external and postero-external borders. It is much broader than the preceding, and often deeply grooved, and is directed outward in the upper two-thirds of its course, backward in the lower third, where it is continuous with the posterior border of the external malleolus. This surface is completely occupied by the Peroneus longus and brevis muscles.

The **internal surface** is the interval included between the antero-internal and the postero-internal borders. It is directed inward, and is grooved for the attachment of the Tibialis posticus muscle.

The **posterior surface** is the space included between the postero-external and the postero-internal borders; it is continuous below with the rough triangular surface above the articular facet of the outer malleolus; it is directed backward above, backward and inward at its middle, directly inward below. Its upper third is rough, for the attachment of the Soleus muscle; its lower part presents a triangular rough surface connected to the tibia by a strong interosseous ligament, and between these two points the entire surface is covered by the fibres of origin of the Flexor longus pollicis muscle. At about the middle of this surface is the nutrient foramen, which is directed downward.

In order to distinguish the side to which the bone belongs, hold it with the lower extremity downward, and the broad groove for the Peronei tendons backward—*i. e.* toward the holder: the triangular subcutaneous surface will then be directed to the side to which the bone belongs.

Articulations.—With two bones: the tibia and astragalus.

Development.—By *three* centres (Fig. 232): one for the shaft and one for each extremity. Ossification commences in the shaft about the eighth week of fœtal life, a little later than in the tibia, and extends gradually toward the extremities. At birth both ends are cartilaginous. Ossification commences in the lower end in the second year, and in the upper one about the fourth year. The lower epiphysis, the first in which ossification commences, becomes united to the shaft first, contrary to the law which appears to prevail with regard to the junction of epiphyses with diaphyses: this takes place about the twentieth year; the upper epiphysis is joined about the twenty-fifth year.[1]

FIG. 232.



Plan of the Development of the Fibula, by three centres.

Attachment of Muscles.—To nine: to the head, the Biceps, Soleus, and Peroneus longus; to the shaft, its anterior surface, the Extensor longus digitorum, Peroneus tertius, and Extensor proprius pollicis; to the internal surface, the Tibialis posticus; to the posterior surface, the Soleus and Flexor longus pollicis; to the external surface, the Peroneus longus and brevis.

---

[1] It will be observed that in the fibula, as in other long bones, the epiphysis toward which the nutrient artery is directed is the one first joined to the shaft.

THE FOOT (Figs. 233, 234).

The skeleton of the Foot consists of three divisions: the Tarsus, Metatarsus, and Phalanges.

THE TARSUS.

The bones of the **Tarsus** are seven in number—viz. the calcaneum, or os calcis, astragalus, cuboid, scaphoid, internal, middle, and external cuneiform bones.

THE CALCANEUM.

The **Calcaneum,** or **Os Calcis** (*calx*, the heel), is the largest and strongest of the tarsal bones. It is irregularly cuboidal in form, and situated at the lower and back part of the foot, serving to transmit the weight of the body to the ground, and forming a strong lever for the muscles of the calf. It presents for examination six surfaces—superior, inferior, external, internal, anterior, and posterior.

The **superior surface** is formed, behind, of the upper aspect of that part of the os calcis which projects backward to form the heel. It varies in length in different individuals; is convex from side to side, concave from before backward, and corresponds above to a mass of adipose substance placed in front of the tendo Achillis. In the middle of the superior surface are two (sometimes three) articular facets, separated by a broad shallow groove which is directed obliquely forward and outward, and is rough for the attachment of the interosseous ligament connecting the astragalus and os calcis. Of the two articular surfaces, the *external* is the larger, and situated on the body of the bone: it is of an oblong form, wider behind than in front and convex from before backward. The *internal articular surface* is supported on a projecting process of bone called the *lesser process* of the calcaneum (*sustentaculum tali*); it is also oblong, concave longitudinally, and sometimes subdivided into two parts, which differ in size and shape. More anteriorly is seen the upper surface of the *greater process*, marked by a rough depression, for the attachment of numerous ligaments and the origin of the Extensor brevis digitorum muscle.

The **inferior surface** is narrow, rough, uneven, wider behind than in front, and convex from side to side; it is bounded posteriorly by two tubercles separated by a rough depression: the *external*, small, prominent, and rounded, gives attachment to part of the Abductor minimi digiti; the *internal*, broader and larger, for the support of the heel, gives attachment by its prominent inner margin to the Abductor pollicis, and in front to the Flexor brevis digitorum muscles; the depression between the tubercles attaches the Abductor minimi digiti and plantar fascia. The rough surface in front of the tubercles gives attachment to the long plantar ligament and to the outer head of the Flexor accessorius muscle; and to a prominent tubercle nearer the anterior part of the bone, as well as to a transverse groove in front of it, is attached the short plantar ligament.

The **external surface** is broad, flat, and almost subcutaneous; it presents near its centre a tubercle, for the attachment of the middle fasciculus of the external lateral ligament. Above the tubercle is a broad smooth surface giving attachment, at its upper and anterior part, to the external calcaneo-astragaloid ligament; and in front of the tubercle a narrow surface marked by two oblique grooves, separated by an elevated ridge which varies much in size in different bones: it is named the *peroneal ridge* or *spine*, and gives attachment to a prolongation from the external

FIG. 233.

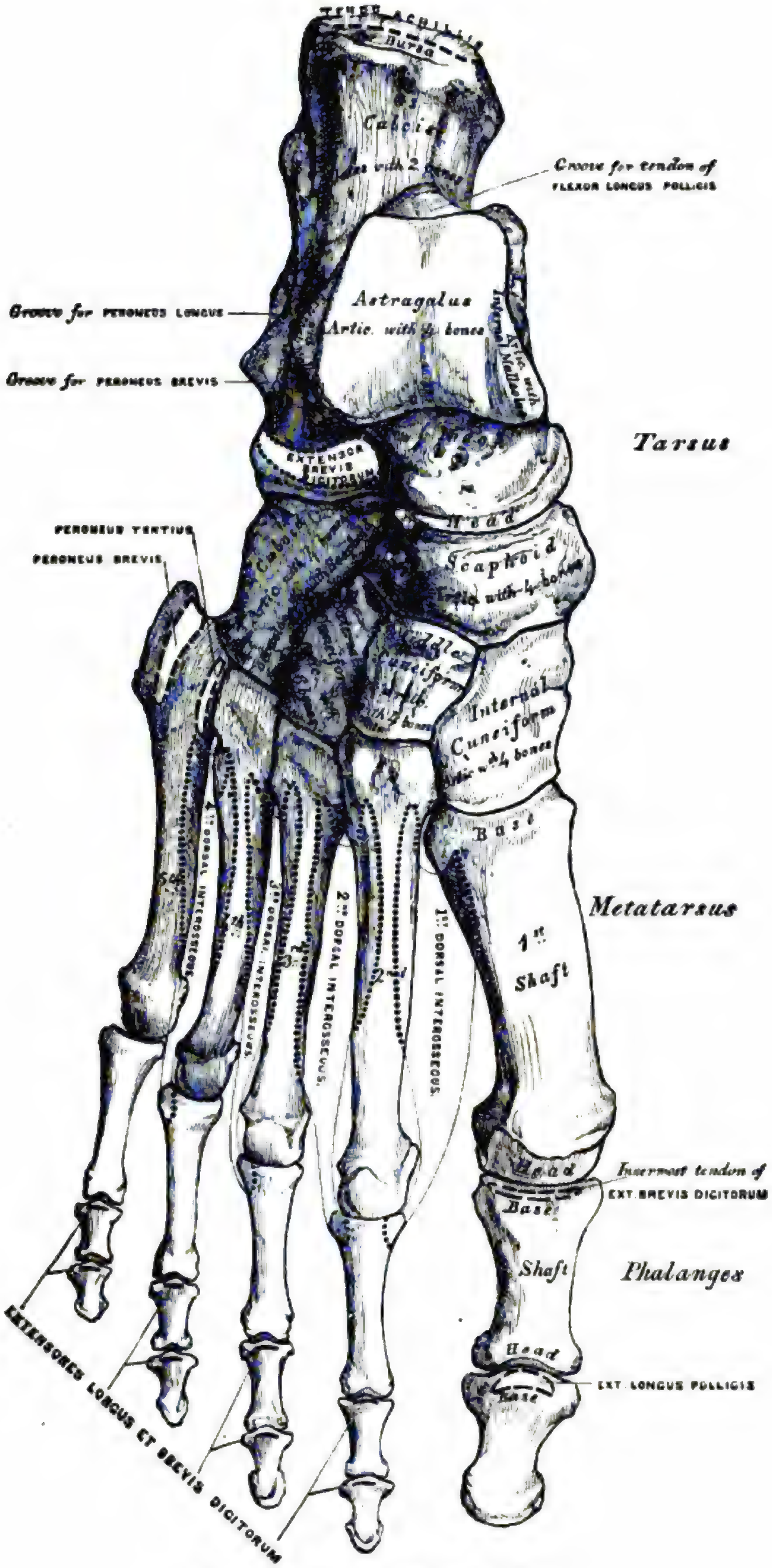
TENDO ACHILLIS
Bursa
Calcis
Artic. with 2 bones
Groove for tendon of FLEXOR LONGUS POLLICIS
Groove for PERONEUS LONGUS
Groove for PERONEUS BREVIS
Astragalus
Artic. with 4 bones
Artic. with Internal Malleolus
Tarsus
EXTENSOR BREVIS DIGITORUM
Head
PERONEUS TERTIUS
PERONEUS BREVIS
Scaphoid
Artic. with 4 bones
Middle Cuneiform
Artic. with 4 bones
Internal Cuneiform
Artic. with 4 bones
Base
Metatarsus
1st Shaft
5th
4th
3rd
2nd
4th DORSAL INTEROSSEOUS
3rd DORSAL INTEROSSEOUS
2nd DORSAL INTEROSSEOUS
1st DORSAL INTEROSSEOUS
Head
Innermost tendon of EXT. BREVIS DIGITORUM
Base
Shaft
Phalanges
Head
Base
EXT. LONGUS POLLICIS
EXTENSORES LONGUS ET BREVIS DIGITORUM

Bones of the Right Foot, dorsal surface.

FIG. 234.

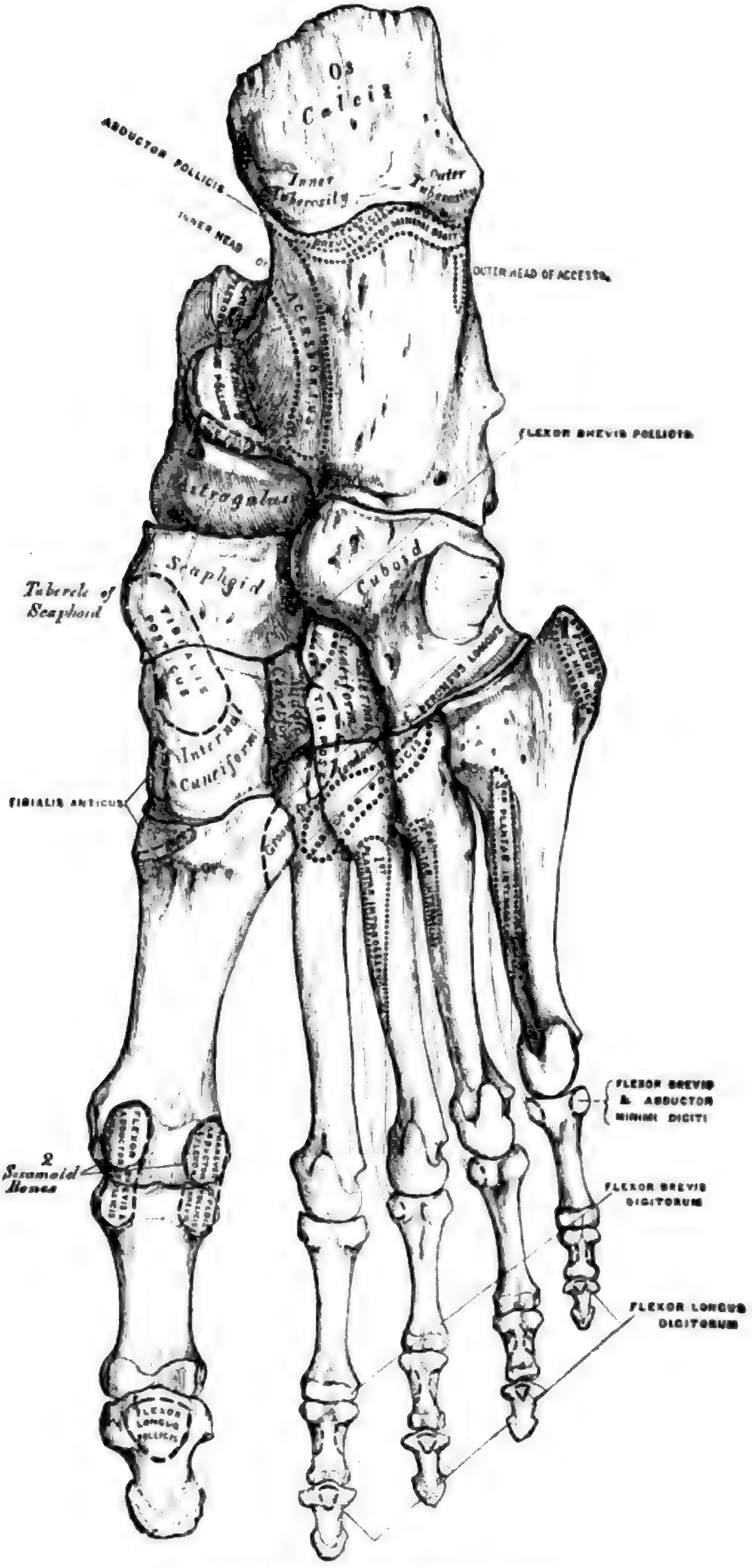
Os Calcis
Inner Tuberosity
Outer Tuberosity
ABDUCTOR POLLICIS
INNER HEAD OF
OUTER HEAD OF ACCESS.
Accessorius
FLEXOR BREVIS POLLICIS
Astragalus
Scaphoid
Cuboid
Tubercle of Scaphoid
TIBIALIS POSTICUS
PERONEUS LONGUS
Internal Cuneiform
TIBIALIS ANTICUS
PLANTAR INTEROSSEI
FLEXOR ABDUCTOR
FLEXOR BREVIS
2 Sesamoid Bones
FLEXOR BREVIS & ABDUCTOR MINIMI DIGITI
FLEXOR BREVIS DIGITORUM
FLEXOR LONGUS DIGITORUM
FLEXOR LONGUS POLLICIS

Bones of the Right Foot, plantar surface.

annular ligament. The *superior groove* transmits the tendon of the Peroneus brevis; the inferior, the tendon of the Peroneus longus.

The **internal surface** presents a deep concavity directed obliquely downward and forward, for the transmission of the plantar vessels and nerves and Flexor tendons into the sole of the foot; it affords attachment to part of the Flexor accessorius muscle. This surface presents an eminence of bone, the *lesser process* or *sustentaculum tali*, which projects horizontally inward from its upper and fore part, and to which a slip of the tendon of the Tibialis posticus is attached. This process is concave above, and supports the anterior articular surface of the astragalus; below it is grooved for the tendon of the Flexor longus pollicis. Its free margin is rough for the attachment of part of the internal lateral ligament of the ankle-joint.

The **anterior surface**, of a somewhat triangular form, is smooth, concavo-convex, and articulates with the cuboid. It is surmounted on its outer side by a rough prominence which forms an important guide to the surgeon in the performance of Chopart's amputation.

The **posterior surface** is rough, prominent, convex, and wider below than above. Its lower part is rough, for the attachment of the tendo Achillis and of the Plantaris muscle; its upper part is smooth, and is covered by a bursa which separates the tendon from the bone.

[The calcaneum, in nearly all its extent, is accessible to touch, and can be grasped to fix it or move it, in the determination of suspected fractures or other injuries.]

Articulations.—With two bones: the astragalus and cuboid.

Attachment of Muscles.—To eight: part of the Tibialis posticus, the tendo Achillis, Plantaris, Abductor pollicis, Abductor minimi digiti, Flexor brevis digitorum, Flexor accessorius, and Extensor brevis digitorum.

THE CUBOID.

The Cuboid (*κύβος*, a cube, and *εἶδος*, like) bone is placed on the outer side of the foot, in front of the os calcis, and behind the fourth and fifth metatarsal bones. It is of a pyramidal shape, its base being directed upward and inward, its apex downward and outward. It may be distinguished from the other tarsal bones by the existence of a deep groove on its under surface, for the tendon of the Peroneus longus muscle. It presents for examination six surfaces, three articular and three non-articular.

The **non-articular surfaces** are the superior, inferior, and external. The *superior* or *dorsal surface*, directed upward and outward, is rough, for the attachment of numerous ligaments. The *inferior* or *plantar surface* presents in front a deep groove, which runs obliquely from without, forward and inward; it lodges the tendon of the Peroneus longus, and is bounded behind by a prominent ridge, to which is attached the long calcaneo-cuboid ligament. The ridge terminates externally in an eminence, the *tuberosity of the cuboid*, the surface of which presents a convex facet, for articulation with the sesamoid bone of the tendon contained in the groove. The surface of bone behind the groove is rough, for the attachment of the short plantar ligament and a few fibres of the Flexor brevis pollicis. The *external surface*, the smallest and narrowest of the three, presents a deep notch formed by the commencement of the peroneal groove.

The **articular surfaces** are the posterior, anterior, and internal. The *posterior surface* is smooth, triangular, and concavo-convex, for articulation with the anterior surface of the os calcis. The *anterior*, of smaller size, but also irregularly triangular, is divided by a vertical ridge into two facets: the inner facet, quadrilateral in form, articulates with the fourth metatarsal bone; the outer one, larger and more triangular, articulates with the fifth metatarsal. The *internal surface* is broad, rough, irregularly quadrilateral, presenting at its middle and upper part a smooth oval facet, for articulation with the external cuneiform bone; and behind this (occasionally) a smaller facet, for articulation with the scaphoid; it is rough in the rest of its extent, for the attachment of strong interosseous ligaments.

To ascertain to which foot it belongs, hold the bone so that its under surface, marked by the peroneal groove, looks downward, and the large concavo-convex articular surface backward toward the holder: the narrow non-articular surface, marked by the commencement of the peroneal groove, will point to the side to which the bone belongs.

Articulations.—With four bones: the os calcis, external cuneiform, and the fourth and fifth metatarsal bones; occasionally with the scaphoid.

Attachment of Muscles.—Part of the Flexor brevis pollicis.

THE ASTRAGALUS.

The **Astragalus** (ἀστράγαλος, a die) is the largest of the tarsal bones, next to the os calcis. It occupies the middle and upper part of the tarsus, supporting the tibia above, articulating with the malleoli on either side, resting below upon the os calcis, and joined in front to the scaphoid. This bone may easily be recognized by its large rounded head, by the broad articular facet on its upper convex surface, or by the two articular facets separated by a deep groove on its under concave surface. It presents six surfaces for examination.

The *superior surface* presents, behind, a broad smooth trochlear surface, for articulation with the tibia. The trochlea is broader in front than behind, convex from before backward, slightly concave from side to side; in front of it is the upper surface of the neck of the astragalus, rough for the attachment of ligaments. The *inferior surface* presents two articular facets separated by a deep groove. The groove runs obliquely forward and outward, becoming gradually broader and deeper in front; it corresponds with a similar groove upon the upper surface of the os calcis, and forms, when articulated with that bone, a canal filled up in the recent state by the interosseous calcaneo-astragaloid ligament. Of the two articular facets, the posterior is the larger, of an oblong form and deeply concave from side to side; the anterior, although nearly of equal length, is narrower, of an elongated oval form, convex longitudinally, and often subdivided into two by an elevated ridge; of these, the posterior articulates with the lesser process of the os calcis; the anterior, with the upper surface of the calcaneo-scaphoid ligament. The *internal surface* presents at its upper part a pear-shaped articular facet for the inner malleolus, continuous above with the trochlear surface; below the articular surface is a rough depression, for the attachment of the deep portion of the internal lateral ligament. The *external surface* presents a large triangular facet, concave from above downward, for articulation with the external malleolus; it is continuous above with the trochlear surface; and in front of it is a rough depression, for the attachment of the anterior fasciculus of the external lateral ligament of the ankle-joint. The *anterior surface*, convex and rounded, forms the *head* of the astragalus; it is smooth, of an oval form, and directed obliquely inward and downward; it articulates with the scaphoid. On its under surface is a small facet, continuous in front with the articular surface of the head; behind with the smaller facet, for the os calcis. This rests on the inferior calcaneo-scaphoid ligament, being separated from it by a prolongation of the synovial sac of the astragalo-scaphoid joint. The head is surrounded by a constricted portion, the *neck* of the astragalus. The *posterior surface* is narrow, and traversed by a groove which runs obliquely downward and inward, and transmits the tendon of the Flexor longus pollicis, external to which is a horizontal notch or depression in which the posterior fasciculus of the external lateral ligament is lodged.

[Much of this bone, especially its trochlear surface and edges and the head, can be excellently studied in the living model, especially if the foot be extended.]

To ascertain to which foot it belongs, hold the bone with the broad articular surface upward and the rounded head forward; the lateral triangular articular surface for the external malleolus will then point to the side to which the bone belongs.

Articulations.—With four bones: tibia, fibula, os calcis, and scaphoid.

THE SCAPHOID.

The **Scaphoid or Navicular Bone,** so called from its fancied resemblance to a boat (σκαφή, a boat), is situated at the inner side of the tarsus, between the astragalus behind and the three cuneiform bones in front. This bone may be distinguished by its form, being concave behind, convex and subdivided into three facets in front.

The *anterior surface*, of an oblong form, is convex from side to side, and subdivided by two ridges into three facets, for articulation with the three cuneiform bones. The *posterior surface* is oval, concave, broader externally than internally, and articulates with the rounded head of the astragalus. The *superior surface* is convex from side to side, and rough, for the attachment of ligaments. The *inferior* is somewhat concave, irregular, and also rough, for the attachment of ligaments. The *internal surface* presents a rounded tubercular eminence, the *tuberosity* of the scaphoid, which gives attachment to part of the tendon of the Tibialis posticus. [This can always be felt, and is one of the important landmarks of the foot.] The *external surface* is rough, and irregular, for the attachment of ligamentous fibres, and occasionally presents a small facet for articulation with the cuboid bone.

To ascertain to which foot it belongs, hold the bone with the concave articular surface backward and the convex dorsal surface upward; the external surface will point to the side to which the bone belongs.

Articulations.—With four bones: astragalus and three cuneiform; occasionally also with the cuboid.

Attachment of Muscles.—Part of the Tibialis posticus.

The **Cuneiform Bones** have received their name from their wedge-like shape (*cuneus*, a wedge, and *forma*, likeness). They form with the cuboid the most anterior row of the tarsus, being placed between the scaphoid behind, the three innermost metatarsal bones in front, and the cuboid externally. They are called the *first*, *second*, and *third*, counting from the inner to the outer side of the foot, and, from their position, *internal*, *middle*, and *external*.

THE INTERNAL CUNEIFORM.

The **Internal Cuneiform** is the largest of the three. It is situated at the inner side of the foot, between the scaphoid behind and the base of the first metatarsal in front. It may be distinguished from the other two by its large size and its more irregular wedge-like form. Without the others it may be known by the large kidney-shaped anterior articulating surface, and by the prominence on the inferior or plantar surface for the attachment of the Tibialis posticus. It presents for examination six surfaces.

The *internal surface* is subcutaneous, and forms part of the inner border of the foot; it is broad, quadrilateral, and presents at its anterior inferior angle a smooth oval facet into which the tendon of the Tibialis anticus is partially inserted; in the rest of its extent it is rough, for the attachment of ligaments. The *external surface* is concave, presenting along its superior and posterior borders a narrow L-shaped surface for articulation with the middle cuneiform behind and second metatarsal bone in front: in the rest of its extent it is rough for the attachment of ligaments, and prominent below, where it forms part of the tuberosity. The *anterior surface*, kidney-shaped, much larger than the posterior, articulates with the metatarsal bone of the great toe. The *posterior surface* is triangular, concave, and articulates with the innermost and largest of the three facets on the anterior surface of the scaphoid. The *inferior* or *plantar surface* is rough, and presents a prominent tuberosity at its back part for the attachment of part of the tendon of the Tibialis posticus. It also gives attachment in front to part of the tendon of the Tibialis anticus. The *superior surface* is the narrow pointed end of the wedge, which is directed upward and outward; it is rough, for the attachment of ligaments.

To ascertain to which side it belongs, hold the bone so that its superior narrow edge looks upward and the long, kidney-shaped articular surface forward; the external surface, marked by its vertical and horizontal articular facets, will point to the side to which it belongs.

Articulations.—With four bones: scaphoid, middle cuneiform, first and second metatarsal bones.

Attachment of Muscles.—To two: the Tibialis anticus and posticus.

The Middle Cuneiform.

The **Middle Cuneiform,** the smallest of the three, is of very regular wedge-like form, the broad extremity being placed upward, the narrow end downward. It is situated between the other two bones of the same name, and articulates with the scaphoid behind and the second metatarsal in front. It may be distinguished from the external cuneiform bone, which it much resembles in general appearance, by the articular facet, of angular form, which runs round the upper and back part of its inner surface; and, if the two bones from the same foot are together, the middle cuneiform is much the smaller.

The *anterior surface*, triangular in form and narrower than the posterior, articulates with the base of the second metatarsal bone. The *posterior surface*, also triangular, articulates with the scaphoid. The *internal surface* presents an L-shaped articular facet running along the superior and posterior borders, for articulation with the internal cuneiform, and is rough in the rest of its extent, for the attachment of ligaments. The *external surface* presents posteriorly a smooth facet, for articulation with the external cuneiform bone. The *superior surface* forms the base of the wedge; it is quadrilateral, broader behind than in front, and rough, for the attachment of ligaments. The *inferior surface*, pointed and tubercular, is also rough, for ligamentous attachment.

To ascertain to which foot the bone belongs, hold its superior or dorsal surface upward, the broadest edge being toward the holder: the smooth facet (limited to the posterior border) will then point to the side to which it belongs.

Articulations.—With four bones: scaphoid, internal and external cuneiform, and second metatarsal bone.

Attachment of Muscle.—A slip from the tendon of the Tibialis posticus is attached to this bone.

The External Cuneiform.

The **External Cuneiform,** intermediate in size between the two preceding, is of a very regular wedge-like form, the broad extremity being placed upward, the narrow end downward. It occupies the centre of the front row of the tarsus, between the middle cuneiform internally, the cuboid externally, the scaphoid behind, and the third metatarsal in front. It is distinguished from the internal cuneiform bone by its more regular wedge-like shape, and by the absence of the kidney-shaped articular surface: from the middle cuneiform, by the absence of the L-shaped facet and by the two articular facets which are present on both its inner and outer surfaces. It has six surfaces for examination.

The *anterior surface*, triangular in form, articulates with the third metatarsal bone. The *posterior surface* articulates with the most external facet of the scaphoid, and is rough below, for the attachment of ligamentous fibres. The *internal surface* presents two articular facets, separated by a rough depression: the anterior one, situated at the superior angle of the bone, articulates with the outer side of the base of the second metatarsal bone; the posterior one skirts the posterior border, and articulates with the middle cuneiform; the rough depression between the two gives attachment to an interosseous ligament. The *external surface* also presents two articular facets, separated by a rough non-articular surface; the anterior facet, situated at the superior angle of the bone, is small, and articulates with the inner side of the base of the fourth metatarsal; the posterior and larger one articulates with the cuboid; the rough non-articular surface serves for the attachment of an interosseous ligament. The three facets for articulation with the three metatarsal bones are continuous with one another, and covered by a prolongation of the same cartilage; the facets for articulation with the middle cuneiform and scaphoid are also continuous, but that for articulation with the cuboid is usually separate. The *superior* or *dorsal surface* is of an oblong square form, its posterior external angle being prolonged backward. The *inferior* or *plantar surface* is an obtuse rounded margin, and serves for the attachment of part of the tendon of the Tibialis posticus, part of the Flexor brevis pollicis, and ligaments.

To ascertain to which side it belongs, hold the bone with the broad dorsal surface upward, the prolonged edge backward; the separate articular facet for the cuboid will point to the proper side.

Articulations.—With six bones: the scaphoid, middle cuneiform, cuboid, and second, third, and fourth metatarsal bones.

Attachment of Muscles.—To two: part of the Tibialis posticus and Flexor brevis pollicis.

THE METATARSAL BONES.

The **Metatarsal Bones** are five in number; they are long bones, and subdivided into a shaft and two extremities.

COMMON CHARACTERS.—The *shaft* is prismoid in form, tapers gradually from the tarsal to the phalangeal extremity, and is slightly curved longitudinally, so as to be concave below, slightly convex above. The *posterior extremity*, or *base*, is wedge-shaped, articulating by its terminal surface with the tarsal bones and by its lateral surfaces with the contiguous metatarsal bones, its dorsal and plantar surfaces being rough, for the attachment of ligaments. The *anterior extremity*, or *head*, presents a terminal rounded articular surface, oblong from above downward, and extending farther backward below than above. Its sides are flattened, and present a depression, surmounted by a tubercle, for ligamentous attachment. Its under surface is grooved in the middle line for the passage of the Flexor tendon, and marked on each side by an articular eminence continuous with the terminal articular surface.

PECULIAR CHARACTER.—The **First** is remarkable for its great size, but is the shortest of all the metatarsal bones. The *shaft* is strong, and of well-marked prismoid form. The *posterior extremity* presents no lateral articular facets; its terminal articular surface is of large size, kidney-shaped, and its circumference grooved, for the tarso-metatarsal ligaments; its inferior angle presents a rough oval prominence, for the insertion of the tendon of the Peroneus longus. The *head* is of large size; on its plantar surface are two grooved facets, over which glide sesamoid bones; the facets are separated by a smooth elevated ridge.

This bone is known by the single kidney-shaped articular surface on its base, the deeply grooved appearance of the plantar surface of its head, and its great thickness relatively to its length. When it is placed in its natural position the concave border of the kidney-shaped articular surface on its base points to the side to which the bone belongs.

The **Second** is the longest and largest of the remaining metatarsal bones, being prolonged backward into the recess formed between the three cuneiform bones. Its *tarsal* extremity is broad above, narrow and rough below. It presents four articular surfaces: one behind, of a triangular form, for articulation with the middle cuneiform; one at the upper part of its internal lateral surface, for the articulation with the internal cuneiform; and two on its external lateral surface, a superior and an inferior, separated by a rough depression. Each of the latter articular surfaces is divided by a vertical ridge into two parts; the anterior segment of each facet articulates with the third metatarsal, the two posterior (sometimes continuous) with the external cuneiform.

The facets on the tarsal extremity of the second metatarsal bone serve at once to distinguish it from the rest and to indicate the foot to which it belongs, there being one facet at the upper angle of the internal surface, and two facets, each subdivided into two parts, on the external surface, pointing to the side to which the bone belongs. The fact that the two posterior subdivisions of these external facets sometimes run into one should not be forgotten.

The **Third** articulates behind, by means of a triangular smooth surface, with the external cuneiform; on its inner side, by two facets, with the second metatarsal; and on its outer side, by a single facet, with the fourth metatarsal. The latter facet is of circular form and situated at the upper angle of the base.

The third metatarsal is known by its having at its tarsal end two undivided facets on the inner side and a single facet on the outer. This distinguishes it from the second metatarsal, in which the two facets found on one side of its tarsal end are each subdivided into two. The single facet (when the bone is put in its natural position) is on the side to which the bone belongs.

The **Fourth** is smaller in size than the preceding; its *tarsal extremity* presents a terminal quadrilateral surface for articulation with the cuboid; a smooth facet on the inner side, divided by a ridge into an anterior portion for articulation with the third metatarsal, and a posterior portion for articulation with the external cuneiform; on the outer side a single facet, for articulation with the fifth metatarsal.

The fourth metatarsal is known by its having a single facet on either side of the tarsal extremity, that on the inner side being divided into two parts. If this subdivision be not recognizable, the fact that its tarsal end is bent somewhat outward will indicate the side to which it belongs, as Mr. Holden points out.

The **Fifth** is recognized by the tubercular eminence on the outer side of its base. [This can always be felt, and is an important landmark in the foot.] It articulates behind, by a triangular surface cut obliquely from without inward, with the cuboid; and internally with the fourth metatarsal.

The projection on the outer side of this bone at its tarsal end at once distinguishes it from the others and points to the side to which it belongs.

Articulations.—Each bone articulates with the tarsal bones by one extremity, and by the other with the first row of phalanges. The number of tarsal bones with which each metatarsal articulates is one for the first, three for the second, one for the third, two for the fourth, and one for the fifth.

Attachment of Muscles.—To the first metatarsal bone, three: part of the Tibialis anticus, the Peroneus longus, and first Dorsal interosseous. To the second, four: the Adductor pollicis and first and second Dorsal interosseous, and a slip from the tendon of the Tibialis posticus. To the third, five: the Adductor pollicis, second and third Dorsal, and first Plantar interosseous, and a slip from the tendon of the Tibialis posticus. To the fourth, five: the Adductor pollicis, third and fourth Dorsal, and second Plantar interosseous, and a slip from the tendon of the Tibialis posticus. To the fifth, six: the Peroneus brevis, Peroneus tertius, Flexor brevis minimi digiti, Transversus pedis, fourth Dorsal, and third Plantar interosseous.

PHALANGES.

The **Phalanges** of the foot, both in number and general arrangement, resemble those in the hand, there being two in the great toe and three in each of the other toes.

The phalanges of the *first row* resemble closely those of the hand. The *shaft* is compressed from side to side, convex above, concave below. The *posterior extremity* is concave, and the *anterior extremity* presents a trochlear surface, for articulation with the second phalanges.

The phalanges of the *second row* are remarkably small and short, but rather broader than those of the first row.

The *ungual* phalanges in form resemble those of the fingers, but they are smaller, flattened from above downward, presenting a broad base for articulation with the second row, and an expanded extremity for the support of the nail and end of the toe.

Articulation.—The first row, with the metatarsal bones and second phalanges; the second of the great toe, with the first phalanx; and of the other toes, with the first and third phalanges; the third, with the second row.

Attachment of Muscles.—To the first phalanges: Great toe, five muscles: innermost tendon of Extensor brevis digitorum, Abductor pollicis, Adductor pollicis, Flexor brevis pollicis, Transversus pedis. Second toe, three muscles: first and second Dorsal interosseous and first Lumbrical. Third toe, three muscles: third Dorsal and first Plantar interosseous, and second Lumbrical. Fourth toe, three muscles: fourth Dorsal and second Plantar interosseous, and third Lumbrical. Fifth toe, four muscles: Flexor brevis minimi digiti, Abductor minimi digiti, and third Plantar interosseous, and fourth Lumbrical.—Second phalanges: Great toe: Extensor longus pollicis, Flexor longus pollicis. Other toes: Flexor brevis digitorum, one slip of the common tendon of the Extensor longus and brevis digitorum.[1]—Third phalanges: two slips from the common tendon of the Extensor longus and Extensor brevis digitorum, and the Flexor longus digitorum.

The foot is constructed on the same principles as the hand, but modified to form a firm basis of support for the rest of the body when in the erect position. It is more solidly constructed, and its component parts are less movable on each other than in the hand. This is especially the case with the great toe, which has to assist in supporting the body and is therefore constructed with greater solidity; it lies parallel with the other toes, and has a very limited degree of mobility. On the contrary, the thumb, which is occupied in numerous and varied movements, is constructed in such a manner as to permit of great mobility: its metacarpal bone is directed away from the others, so as to form an acute angle with the second, and it enjoys a considerable range of motion at its articulation with the carpus. The foot is placed at right angles to the leg—a position which is almost peculiar to man, and has relation to the erect position which he maintains. In order to allow of its supporting the weight of the whole body in this position with the least expenditure of material, it is constructed in the form of an arch. This arch is not, however, made up of two equal limbs. The hinder one, which is made up of the os calcis and the posterior part of the astragalus, is about half the length of the anterior limb, and measures about three inches. The anterior limb consists of the rest of the tarsal and the metatarsal bones, and measures about six inches. It may be said to consist of two parts—an inner segment, made up of the head of the astragalus, the scaphoid, the three cuneiform, and the three inner metatarsal bones; and an outer segment, composed of the cuboid and the two outer metatarsal bones. The summit of the arch is at the superior articular surface of the astragalus and its two extremities; that is to say, the two points on which the arch rests in standing are the tubercles on the under surface of the os calcis posteriorly and the heads of the metatarsal bones anteriorly. The weakest part of the arch is the joint between the astragalus and scaphoid; and here it is more liable to yield in those who are overweighted and in those in whom the ligaments which complete and preserve the arch are relaxed. This weak point in the arch is braced on its concave surface by the inferior calcaneo-scaphoid ligament, which is said to be more elastic than most other ligaments, and thus allows the arch to yield from jars or shocks applied to the anterior portion of the foot, and quickly restores it to its pristine condition. This ligament is supported on its under surface by the tendon of the Tibialis posticus muscle, which is spread out into a fan-shaped insertion, and prevents undue tension of the ligament or such an amount of stretching as would permanently elongate it.

In addition to this longitudinal arch, the foot is said to present a transverse arch at the anterior part of the tarsus and hinder part of the metatarsus. This, however, can scarcely be described as a true arch, but presents more the character of a half-dome [or half arch. This is especially supported by the tendon of the Peroneus longus, running from the outer edge of the sole to its inner border at the base of the first metatarsal, and by the Transversus pedis]. The inner border of the central portion of the longitudinal arch is elevated from the ground, and from this point the bones arch over to the outer border, which is in contact with the ground, and, assisted by the longitudinal arch, produce a sort of rounded niche on the inner side of the foot, which gives the appearance of a transverse as well as a longitudinal arch.

---

[1] Except the second phalanx of the fifth toe, which receives no slip from the Extensor brevis digitorum.

The arch of the foot, from the point of the heel to the toes, is not quite straight, but is directed a little outward, so that the inner border is a little convex and the outer border concave. This disposition of the bones becomes more marked when the longitudinal arch of the foot is lost, as in the disease known under the name of "flat-foot."

[The imprint of the foot-sole is a matter of great interest. If the sole be wetted, and placed for a moment on the bare floor, the normally-arched foot shows a broad imprint at the heel and at the ball of the toes, the two being connected on the outer edge of the sole by a band which is narrower or wider as the arch is more or less marked. In very arched feet the two may be entirely disconnected, while in the flat foot the imprint is continuous, the narrow band widening to the full width of the sole, its inner edge being a straight line instead of a marked curve. (See the *Medical News*, Aug. 12, 1882.)]

DEVELOPMENT OF THE FOOT (Fig. 235).

The **Tarsal** bones are each developed by a single centre, excepting the os calcis, which has an epiphysis for its posterior extremity. The centres make their appearance in the following order: os calcis at the sixth month of fœtal life; astragalus, about the seventh month; cuboid, at the ninth month; external cuneiform, during the first year; internal cuneiform, in the third year; middle cuneiform and scaphoid, in the fourth year. The epiphysis for the posterior tuberosity of the os calcis appears at the tenth year, and unites with the rest of the bone soon after puberty.

The **Metatarsal** bones are each developed by *two* centres—one for the shaft and one for the digital extremity in the four outer metatarsal; one for the shaft and one for the base in the metatarsal bone of the great toe.[1] Ossification commences in the centre of the shaft about the seventh week, and extends toward either extremity, and in the digital epiphyses about the third year; they become joined between the eighteenth and twentieth years.

The **Phalanges** are developed by *two* centres for each bone: one for the shaft and one for the metatarsal extremity.

SESAMOID BONES.

These are small rounded masses, cartilaginous in early life, osseous in the adult, which are developed in those tendons which exert a great amount of pressure upon the parts over which they glide. It is said that they are more commonly found in the male than in the female, and in persons of an active muscular habit than in those who are weak and debilitated. They are invested throughout their whole surface by the fibrous tissue of the tendon in which they are found, excepting upon that side which lies in contact with the part over which they play, where they present a free articular facet. They may be divided into two kinds—those which glide over the articular surfaces of joints, and those which play over the cartilaginous facets found on the surfaces of certain bones.

The sesamoid bones of the joints are—in the lower extremity, the patella, which is developed in the tendon of the Quadriceps extensor; two small sesamoid bones, found in the tendons of the Flexor brevis pollicis, opposite the metatarso-phalangeal joint of the great toe, and occasionally one in the metatarso-phalangeal joint of the second toe, the little toe, and, still more rarely, the third and fourth toes.

---

[1] As was noted in the first metacarpal bone, so in the first metatarsal, there is often to be observed a tendency to the formation of a second epiphysis in the distal extremity. (See foot-note, p. 223.)

In the upper extremity there are two on the palmar surface of the metacarpo-phalangeal joint in the thumb, developed in the tendons of the Flexor brevis pollicis, occasionally one or two opposite the metacarpo-phalangeal articulations of the fore and little fingers, and, still more rarely, one opposite the same joints of the third and fourth fingers.

FIG. 235.

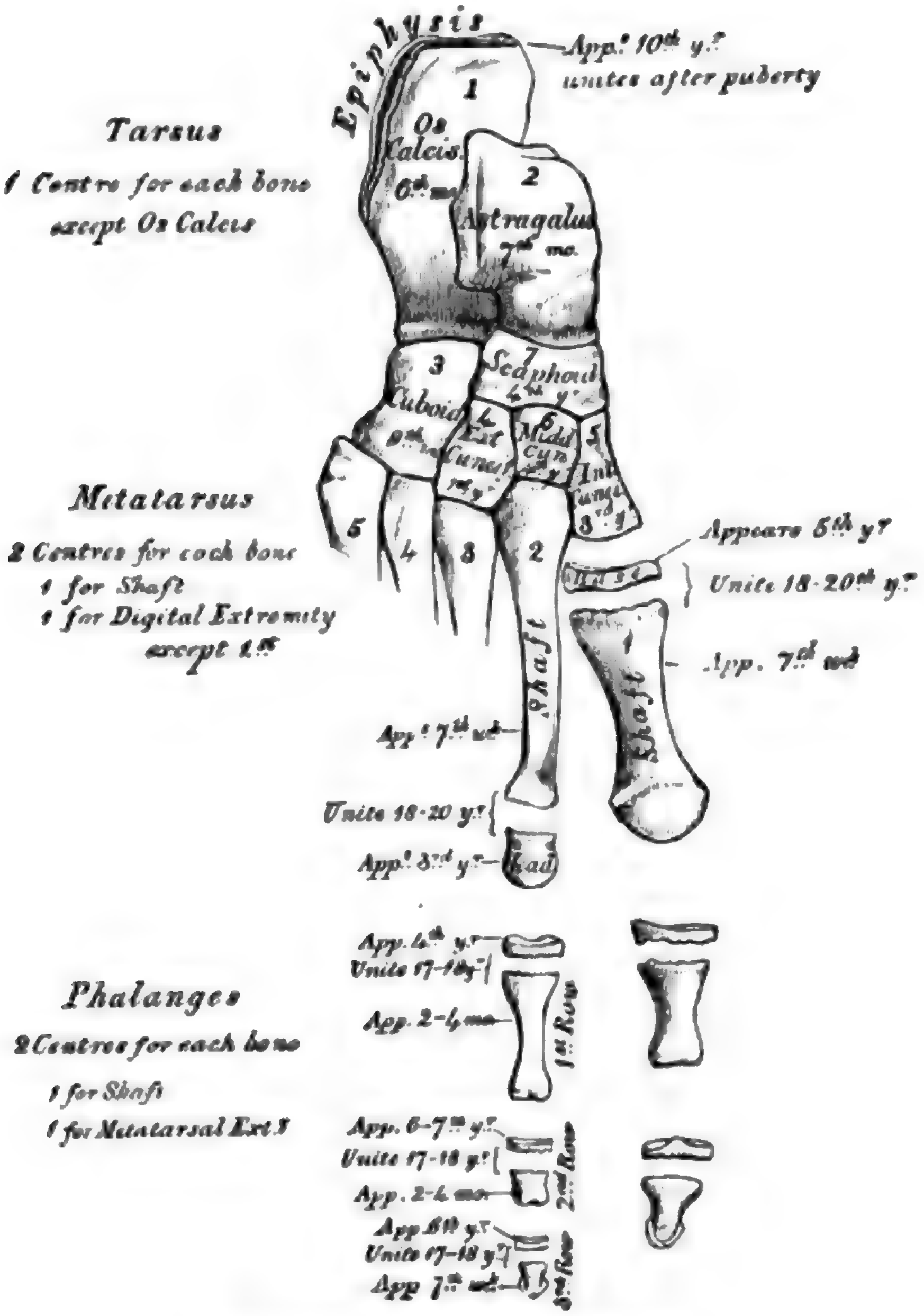
Epiphysis
App.t 10th y.r unites after puberty
Tarsus
1 Centre for each bone except Os Calcis
1
Os Calcis 6th mo.
2
Astragalus 7th mo.
3
Cuboid 9th mo.
7
Scaphoid 4th y.r
4
Ext Cuneif 1st y.r
6
Midd Cun
5
Int Cuneif 3rd y.r
Metatarsus
2 Centres for each bone
1 for Shaft
1 for Digital Extremity except 1st
5
4
3
2
Appears 3rd y.r
Unite 18-20th y.r
1
App. 7th wk
Shaft
Shaft
App.t 7th wk
Unite 18-20 y.r
App.t 3rd y.r
Head
Phalanges
2 Centres for each bone
1 for Shaft
1 for Metatarsal Ext.y
App. 4th y.r
Unite 17-18 y.r
App. 2-4 mo.
1st Row
App. 6-7th y.r
Unite 17-18 y.r
App. 2-4 mo.
2nd Row
App. 6th y.r
Unite 17-18 y.r
App 7th wk
3rd Row

Plan of the Development of the Foot.

Those found in the tendons which glide over certain bones occupy the following situations: one in the tendon of the Peroneus longus, where it glides through the groove in the cuboid bone; one appears late in life in the tendon of the Tibialis anticus, opposite the smooth facet on the internal cuneiform bone; one is found in the tendon of the Tibialis posticus, opposite the inner side of the astragalus; one in the outer head of the Gastrocnemius, behind the outer condyle of the femur; and one in the Psoas and Iliacus, where they glide over the body of the pubes. Sesamoid bones are found occasionally in the tendon of the Biceps, opposite the tuberosity of the radius; in the tendon of the Gluteus maximus, as it passes over the great trochanter; and in the tendons which wind round the inner and outer malleoli.

The Articulations.

THE various bones of which the Skeleton consists are connected together at different parts of their surfaces, and such a connection is designated by the name of *Joint* or *Articulation.* If the joint is *immovable*, as between the cranial and most of the facial bones, their adjacent margins are applied in almost close contact, a thin layer of fibrous membrane, the *sutural ligament*, and, at the base of the skull, in certain situations, a thin layer of cartilage, being interposed. Where slight movement is required, combined with great strength, the osseous surfaces are united by tough and elastic fibro-cartilages, as in the joints of the spine, the sacro-iliac and interpubic articulations; but in the *movable* joints the bones forming the articulation are generally expanded for greater convenience of mutual connection, covered by *cartilage*, held together by strong bands or capsules of fibrous tissue called *ligaments*, and partially lined by a membrane, the *synovial membrane*, which secretes a fluid to lubricate the various parts of which the joint is formed; so that the structures which enter into the formation of a joint are bone, cartilage, fibro-cartilage, ligament, and synovial membrane.

Bone constitutes the fundamental element of all the joints. In the long bones the extremities are the parts which form the articulations; they are generally somewhat enlarged, consisting of spongy cancellous tissue with a thin coating of compact substance. In the flat bones the articulations usually take place at the edges, and in the short bones at various parts of their surface. The layer of compact bone which forms the articular surface, and to which the cartilage is attached, is called the *articular lamella.* It is of a white color, extremely dense, and varies in thickness. Its structure differs from ordinary bone-tissue in this respect, that it contains no Haversian canals and its lacunæ are much larger than in ordinary bone and have no canaliculi. The vessels of the cancellous tissue as they approach the articular lamella turn back in loops, and do not perforate it; this layer is consequently more dense and firmer than ordinary bone, and is evidently designed to form a firm and unyielding support for the articular cartilage.

The **cartilage**, which covers the articular surfaces of bone, and is therefore called *articular*, and also the varieties of fibro-cartilage, will be found described in the section on General Anatomy (p. 50).

Ligaments are found in nearly all the movable articulations; they consist of bands of various forms, serving to connect together the articular extremities of bones, and composed mainly of bundles of *white fibrous tissue* placed parallel with, or closely interlaced with, one another, and presenting a white, shining silvery aspect. A ligament is pliant and flexible, so as to allow of the most perfect freedom of movement, but strong, tough, and inextensile, so as not readily to yield under the most severely applied force; it is consequently well adapted to serve as the connecting medium between the bones. Some ligaments consist entirely of *yellow elastic tissue*, as the ligamenta subflava, which connect together the adjacent arches of the vertebræ, and the ligamentum nuchæ in the lower animals. In these cases it will be observed that the elasticity of the ligament is intended to act as a substitute for muscular power.

Synovial Membrane is a thin, delicate membrane, arranged in its simplest form like a short wide tube, attached by its open ends to the margins of the articular cartilages, and covering the inner surface of the various ligaments which connect the articulating surfaces, so that, along with the cartilages, it completely encloses the joint-cavity. Its secretion is thick, viscid, and glairy, like the white of egg, and is hence termed *synovia*. The synovial membranes found in the body aamit of subdivision into three kinds—articular, bursal, and vaginal.

The *articular synovial membranes* are found in all the freely movable joints. In the fœtus this membrane is said by Toynbee to be continued over the surface of the cartilages; but in the adult it is wanting, excepting at their circumference, upon which it encroaches for a short distance and to which it is firmly attached; it then invests the inner surface of the capsular or other ligaments enclosing the joint, and is reflected over the surface of any tendons passing through its cavity, as the tendon of the Popliteus in the knee and the tendon of the Biceps in the shoulder. In several of the joints the synovial membrane is thrown into folds which pass across the cavity. They are called *synovial ligaments*, and are especially distinct in the knee. Others are flattened folds, subdivided at their margins into fringe-like processes, the vessels of which have a convoluted arrangement. The latter generally project from the synovial membrane near the margin of the cartilage, and lie flat upon its surface. They consist of connective tissue covered with epithelium, and contain fat-cells in variable quantities, and, more rarely, isolated cartilage-cells. The larger folds often contain considerable quantities of fat. They are found in most of the bursal and vaginal, as well as in the articular, synovial membranes, and were described by Clopton Havers as *mucilaginous glands* and as the source of the synovial secretion. Under certain diseased conditions similar processes are found covering the entire surface of the synovial membrane, forming a mass of pedunculated fibro-fatty growths which project into the joint.

The *bursæ* are found interposed between surfaces which move upon each other, producing friction, as in the gliding of a tendon or of the integument over projecting bony surfaces. They admit of subdivision into two kinds—the *bursæ mucosæ* and the *synovial bursæ*. The former are large, simple, or irregular cavities in the subcutaneous areolar tissue, enclosing a clear viscid fluid. They are found in various situations, as between the integument and the front of the patella, over the olecranon, the malleoli, and other prominent parts. The *synovial bursæ* are found interposed between muscles or tendons as they play over projecting bony surfaces, as between the Glutei muscles and the surface of the great trochanter. They consist of a thin wall of connective issue partially covered by epithelium, and contain a viscid fluid. Where one of these exists in the neighborhood of a joint, it usually communicates with its cavity, as is generally the case with the bursa between the tendon of the Psoas and Iliacus and the capsular ligament of the hip, or the one interposed between the under surface of the Subscapularis and the neck of the scapula.

The *vaginal synovial membranes* (*synovial sheaths*) serve to facilitate the gliding of tendons in the osseo-fibrous canals through which they pass. The membrane is here arranged in the form of a sheath, one layer of which adheres to the wall of the canal, and the other is reflected upon the outer surface of the contained tendon, the space between the two free surfaces of the membrane being partially filled with synovia. These sheaths are chiefly found surrounding the tendons of the flexor and extensor muscles of the fingers and toes as they pass through the osseo-fibrous canals in the hand or foot.

Synovia is a transparent, yellowish-white or slightly reddish fluid, viscid like the white of egg, having an alkaline reaction and slightly saline taste. It consists, according to Frerichs, in the ox, of 94.85 water, 0.56 mucus and epithelium, 0.07 fat, 3.51 albumen and extractive matter, and 0.99 salts.

The articulations are divided into three classes: *Synarthrosis*, or immovable; *Amphiarthrosis*, or mixed; and *Diarthrosis*, or movable joints.

1. Synarthrosis—Immovable Articulations.

Synarthrosis includes all those articulations in which the surfaces of the bones are in almost direct contact, and in which there is no appreciable motion [as, for instance, the immovable "joint" between the blade and handle of a table-knife], as the joints between the bones of the cranium and face, excepting those of the lower jaw. The varieties of synarthrosis are three in number: Sutura, Schindylesis, and Gomphosis.

Sutura (a seam).—Where the articulating surfaces are connected by a series of processes and indentations interlocked together, it is termed *sutura vera*, of which there are three varieties—sutura dentata, serrata, and limbosa. The surfaces of the bones are not in direct contact, being separated by a layer of membrane continuous externally with the pericranium, internally with the dura mater. The *sutura dentata* (*dens*, a tooth) is so called from the tooth-like form of the projecting articular processes, as in the suture between the parietal bones. In the *sutura serrata* (*serra*, a saw) the edges of the two bones forming the articulation are serrated like the teeth of a fine saw, as between the two portions of the frontal bone. In the *sutura limbosa* (*limbus*, a selvage), besides the dentated processes there is a certain degree of bevelling of the articular surfaces, so that the bones overlap one another, as in the suture between the parietal and frontal bones. When the articulation is formed by roughened surfaces placed in apposition with one another, it is termed the *false suture*, *sutura notha*, of which there are two kinds—the *sutura squamosa* (*squama*, a scale), formed by the overlapping of two contiguous bones by broad bevelled margins, as in the temporo-parietal (squamous) suture; and the *sutura harmonia* (*ἁρμονία*, a joining together), where there is simple apposition of two contiguous rough bony surfaces, as in the articulation between the two superior maxillary bones or of the horizontal plates of the palate bones.

Schindylesis (*σχινδύλησις*, a fissure) is that form of articulation in which a thin plate of bone is received into a cleft or fissure formed by the separation of two laminæ of another, as in the articulation of the rostrum of the sphenoid and perpendicular plate of the ethmoid with the vomer, or in the reception of the latter in the fissure between the superior maxillary and palate bones.

Gomphosis (*γόμφος*, a nail) is an articulation formed by the insertion of a conical process into a socket, as a nail is driven into a board; this is not illustrated by any articulations between bones properly so called, but is seen in the articulation of the teeth with the alveoli of the maxillary bones.

2. AMPHIARTHROSIS—MIXED ARTICULATIONS.

In this form of articulation the contiguous osseous surfaces are either connected together by broad flattened disks of fibro-cartilage which adhere to the end of each bone, as in the articulation between the bodies of the vertebræ, or else the articulating surfaces are covered with fibro-cartilage, partially lined by synovial membrane, and connected together by external ligaments, as in the sacro-iliac and pubic symphyses, both these forms being capable of limited motion in every direction. The former resemble the synarthrodial joints in the continuity of their surfaces and absence of synovial sac; the latter, the diarthrodial. These joints occasionally become obliterated in old age, as is frequently the case in the pubic articulation and occasionally in the intervertebral and sacro-iliac.

3. DIARTHROSIS—MOVABLE ARTICULATIONS.

This form of articulation includes the greater number of the joints in the body, mobility being their distinguishing character. They are formed by the approximation of two contiguous bony surfaces covered with cartilage, connected by ligaments, and lined by synovial membrane. The varieties of joints in this class have been determined by the kind of motion permitted in each: they are six in number—Arthrodia, Enarthrosis, Ginglymus, Diarthrosis rotatoria, Condyloid, and Articulations by Reciprocal Reception.

Arthrodia is that form of joint which admits of a gliding movement: it is formed by the approximation of plane surfaces, or one slightly concave, the other slightly convex, the amount of motion between them being limited by the ligaments

Table of the Different Kinds of Articulations.

- *Synarthrosis*, or Immovable Joint. Surfaces separated by fibrous membrane, without any intervening synovial cavity, and immovably connected with each other. As in joints of cranium and face (except lower jaw).
  - *Sutura*, articulation by processes and indentations interlocked together.
    - *Sutura vera* (true), articulate by indented borders.
      - *Dentata*, having tooth-like processes. As in interparietal suture.
      - *Serrata*, having serrated edges, like the teeth of a saw. As in interfrontal suture.
      - *Limbosa*, having bevelled margins and dentated processes. As in fronto-parietal suture.
    - *Sutura notha* (false), articulate by rough surfaces.
      - *Squamosa*, formed by thin bevelled margins overlapping each other. As in squamo-parietal suture.
      - *Harmonia*, formed by the apposition of contiguous rough surfaces. As in intermaxillary suture.
  - *Schindylesis.*—Articulation formed by the reception of a thin plate of one bone into a fissure of another. As in articulation of rostrum of sphenoid with vomer.
  - *Gomphosis.*—Articulation formed by the insertion of a conical process into a socket. The teeth.
- *Amphiarthrosis*—Mixed Articulation.
  - 1. Surfaces connected by fibro-cartilage, not separated by synovial membrane, and having limited motion. As in joints between bodies of vertebræ.
  - 2. Surfaces covered by fibro-cartilage, lined by a partial synovial membrane. As in sacro-iliac and pubic symphyses.
- *Diarthrosis* — Movable Joint.
  - *Arthrodia.*—Gliding joint; articulations by plane surfaces, which glide upon each other. As in sterno- and acromio-clavicular articulations.
  - *Enarthrosis.*—Ball-and-socket joint, capable of motion in all directions. Articulations by a globular head received into a cup-like cavity. As in hip- and shoulder-joints.
  - *Ginglymus.*—Hinge-joint; motion limited to two directions, forward and backward. Articular surfaces fitted together so as to permit of movement in one plane. As in the elbow, ankle, and knee.
  - *Diarthrosis Rotatoria, or Lateral Ginglymus.*—Articulation by a pivot process turning within a ring or ring around a pivot. As in superior radio-ulnar articulation and atlo-axoid joint.
  - *Condyloid.*—Ovoid head received into elliptical cavity. Movements in every direction except axial rotation. As the wrist-joint.
  - *Reciprocal Reception.*—Articular surfaces inversely convex in one direction and concave in the other. Movement in every direction except axial rotation. As in the metacarpo-phalangeal joint of the thumb.

or osseous processes surrounding the articulation, as in the articular processes of the vertebræ, temporo-maxillary, sterno- and acromio-clavicular, carpal, superior tibio-fibular, and tarsal joints.

Enarthrosis is that form of joint which is capable of motion in all directions. It is formed by the reception of a globular head into a deep cup-like cavity (hence the name *ball-and-socket*), the parts being kept in apposition by a capsular ligament strengthened by accessory ligamentous bands. Examples of this form of articulation are found in the hip and shoulder.

Ginglymus or Hinge-joint (γίγγλυμος, a hinge).—In this form of joint the articular surfaces are moulded to each other in such a manner as to permit motion only in two directions, forward and backward, the extent of motion at the same time being considerable. The articular surfaces are connected together by strong lateral ligaments, which form their chief bond of union. The most perfect form of ginglymus is the elbow; the knee and ankle are less perfect, as they allow a slight degree of rotation or lateral movement in certain positions of the limb.

Diarthrosis Rotatoria (*Lateral Ginglymus*).—Where the movement is limited to rotation, the joint is formed by a pivot-like process turning within a ring or the ring on the pivot, the ring being formed partly of bone, partly of ligament. In the articulation of the odontoid process of the axis with the atlas the ring is formed in front by the anterior arch of the atlas; behind, by the transverse ligament: here the ring rotates round the odontoid process. In the superior radio-ulnar articulation the ring is formed partly by the lesser sigmoid cavity of the ulna; in the rest of its extent by the orbicular ligament; here the head of the radius rotates within the ring.

Condyloid Articulations.—In this form of joint an ovoid articular head or condyle is received into an elliptical cavity in such a manner as to permit of flexion and extension, adduction and abduction, and circumduction, but no axial rotation. The articular surfaces are connected together by anterior, posterior, and lateral ligaments. An example of this form of joint is found in the wrist.

Articulations by Reciprocal Reception.—In this variety the articular surfaces are concavo-convex; that is to say, they are inversely convex in one direction and concave in the other. The movements are the same as in the preceding form; that is to say, there is flexion, extension, adduction, abduction, and circumduction, but no axial rotation. The articular surfaces are connected by a capsular ligament. The best example of this form of joint is the metacarpo-phalangeal joint of the thumb.

THE KINDS OF MOVEMENT ADMITTED IN JOINTS.

The movements admissible in joints may be divided into four kinds—gliding, angular movement, circumduction, and rotation. These movements are often, however, more or less combined in the various joints, so as to produce an infinite variety, and it is seldom that we find only one kind of motion in any particular joint.

Gliding movement is the most simple kind of motion that can take place in a joint, one surface gliding or moving over another without any angular or rotatory movement. It is common to all movable joints, but in some, as in the articulations of the carpus and tarsus, it is the only motion permitted. This movement is not confined to plane surfaces, but may exist between any two contiguous surfaces of whatever form, limited by the ligaments which enclose the articulation.

Angular movement occurs only between the long bones, and by it the angle between the two bones is increased or diminished. It may take place in four directions—forward and backward, constituting flexion and extension, or inward and outward, constituting adduction and abduction. The strictly ginglymoid or hinge joints admit of flexion and extension only. Abduction and adduction, combined with flexion and extension, are met with in the more movable joints, as in the hip, shoulder, and metacarpal joint of the thumb, and partially in the wrist.

Circumduction is that limited degree of motion which takes place between the head of a bone and its articular cavity whilst the extremity and sides of the limb are made to circumscribe a conical space, the base of which corresponds with the inferior extremity of the limb, the apex with the articular cavity; this kind of motion is best seen in the shoulder- and hip-joints.

Rotation is the movement of a bone upon its own axis, the bone retaining the same relative situation with respect to the adjacent parts, as in the articulation between the atlas and axis, where the odontoid process serves as a pivot around which the atlas turns, or in the rotation of the radius upon the humerus, and also in the hip and shoulder.

[*Ligamentous Action of Muscles.*]—The actions of the different joints of a limb are combined by means of the long muscles which pass over more than one joint, and which [when relaxed and stretched to their greatest length] act to a certain extent as elastic ligaments in restraining certain actions of one joint, except when combined with corresponding movements of the other, these latter movements being usually in the opposite direction. Thus, the shortness of the hamstring muscles prevents complete flexion of the hip unless the knee-joint be also flexed, so as to bring their attachments nearer together. The uses of this arrangement are threefold: 1. It co-ordinates the kinds of movement which are the most habitual and necessary, and enables them to be performed with the least expenditure of power. "Thus in the usual gesture of the arms, whether in grasping or rejecting, the shoulder and the elbow are flexed simultaneously and simultaneously extended," in consequence of the passage of the Biceps and Triceps cubiti over both joints. 2. It enables the short muscles which pass over only one joint to act upon more than one. "Thus if the Rectus femoris remain tonically of such length that, when stretched over the extended hip, it compels extension of the knee, then the Gluteus maximus becomes not only an extensor of the hip, but an extensor of the knee as well." 3. It provides the joints with ligaments, which, while they are of very great power in resisting movements to an extent incompatible with the mechanism of the joint, at the same time spontaneously yield when necessary. "Taxed beyond its strength a ligament will be ruptured, whereas a contracted muscle is easily relaxed; also, if neighboring joints be united by ligaments, the amount of flexion or extension of each must remain in constant proportion to that of the other; while if the union be by muscles, the separation of the points of attachment of those muscles may vary considerably in different varieties of movement, the muscles adapting themselves tonically to the length required." The quotations are from a very interesting paper by Dr. Cleland in the *Journal of Anatomy and Physiology*, No. 1, 1866, p. 85, by whom I believe this important fact in the mechanism of joints was first clearly pointed out, though it has been independently observed afterward by other anatomists. [It is very important that the surgeon should remember this ligamentous action of muscles in making passive motion—for instance, at the wrist after Colles' fracture. If the fingers be extended, the wrist can be flexed to a right angle. If, however, they be first flexed, as in "making a fist," flexion at the wrist is quickly limited to from forty to fifty degrees in different persons, and is very painful beyond that point. Hence passive motion here should be made with the fingers extended. In the leg, when flexing the hip, the knee should be flexed.[1]]

The articulations may be arranged into those of the trunk, those of the upper extremity, and those of the lower extremity.

ARTICULATIONS OF THE TRUNK.

These may be divided into the following groups, viz.:

I. Of the vertebral column.
II. Of the atlas with the axis.
III. Of the atlas with the occipital bone.
IV. Of the axis with the occipital bone.
V. Of the lower jaw.
VI. Of the ribs with the vertebræ.
VII. Of the cartilages of the ribs with the sternum and with each other.
VIII. Of the sternum.
IX. Of the vertebral column with the pelvis.
X. Of the pelvis.

I. Articulations of the Vertebral Column.

The different segments of the spine are connected together by ligaments, which admit of the same arrangement as the Vertebræ. They may be divided into five sets: 1, Those connecting the *bodies* of the vertebræ; 2, those connecting the

---

[[1] A beautiful illustration of this is seen in the perching of birds, whose toes are forced to clasp the perch by just such a passive ligamentous action so soon as they stoop. Hence they can go to sleep and not fall off the perch.]

laminæ; 3, those connecting the *articular processes;* 4, those connecting the *spinous processes;* 5, that of the *transverse processes.*

The articulations of the *bodies* of the vertebræ with each other form a series of amphiarthrodial joints; those between the *articular processes* form a series of arthrodial joints.

1. The Ligaments of the Bodies.

Anterior Common Ligament. Posterior Common Ligament.
Intervertebral Substance.

The **Anterior Common Ligament** (Figs. 236, 237, 244, 247) is a broad and strong band of ligamentous fibres which extends along the front surface of the bodies of the vertebræ from the axis to the sacrum. It is broader below than above, thicker in the dorsal than in the cervical or lumbar regions, and somewhat thicker opposite the front of the body of each vertebra than opposite the intervertebral substance. It is attached above to the body of the axis by a pointed process which is connected with the tendon of insertion of the Longus colli muscle, and extends down as far as the upper bone of the sacrum. It consists of dense longitudinal fibres, which are intimately adherent to the intervertebral substance and the prominent margins of the vertebræ, but less closely to the middle of the bodies. In the latter situation the fibres are exceedingly thick, and serve to fill up the concavities on their front surface and to make the anterior surface of the spine more even. This ligament is composed of several layers of fibres which vary in length, but are closely interlaced with each other. The most superficial or longest fibres extend between four or five vertebræ. A second subjacent set extend between two or three vertebræ, whilst a third set, the shortest and deepest, extend from one vertebra to the next. At the side of the bodies the ligament consists of a few short fibres which pass from one vertebra to the next, separated from the median portion by large oval apertures for the passage of vessels.

Fig. 236.

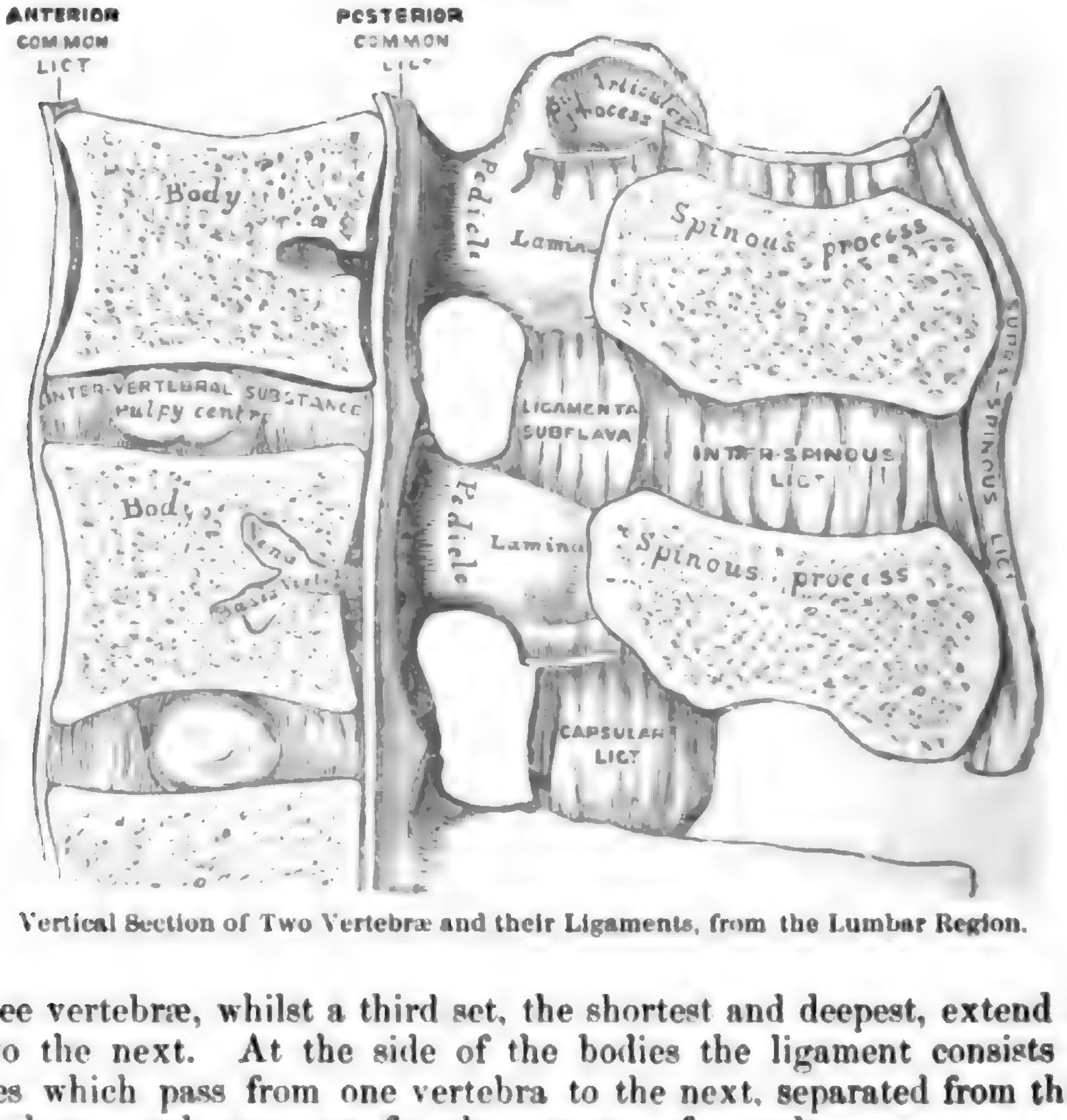
ANTERIOR COMMON LIG'T
POSTERIOR COMMON LIG'T
Articular process
Body
Pedicle
Lamina
Spinous process
SUPRA-SPINOUS LIG'T
INTER-VERTEBRAL SUBSTANCE
Pulpy centre
LIGAMENTA SUBFLAVA
INTER-SPINOUS LIG'T
Body
Pedicle
Lamina
Spinous process
CAPSULAR LIG'T

Vertical Section of Two Vertebræ and their Ligaments, from the Lumbar Region.

The **Posterior Common Ligament** (Figs. 236, 240) is situated within the spinal canal, and extends along the posterior surface of the bodies of the vertebræ from the body of the axis above, where it is continuous with the occipito-axoid ligament, to the sacrum below. It is broader at the upper than at the lower part of the spine, and thicker in the dorsal than in the cervical or lumbar regions. In the situation of the intervertebral substance and contiguous margins of the vertebræ, where the ligament is more intimately adherent, it is broad, and presents a series of dentations with intervening concave margins; but it is narrow and thick over the centre of the bodies, from which it is separated by the *venæ basis vertebræ*. This ligament is composed of smooth, shining, longitudinal fibres, denser and more compact than those of the anterior ligament, and composed of a superficial layer occupying the interval between three or four vertebræ, and of a deeper layer which extends between one vertebra and the next adjacent to it. It is separated from the dura mater of the spinal cord by some loose connective tissue very liable to serous infiltration.

The **Intervertebral Substance** (Fig. 236) is a lenticular disk of fibro-cartilage interposed between the adjacent surfaces of the bodies of the vertebræ from the axis to the sacrum, and forming the chief bond of connection between those bones. These disks vary in shape, size, and thickness in different parts of the spine. In *shape* they accurately correspond with the surfaces of the bodies between which they are placed, being oval in the cervical and lumbar regions and circular in the dorsal. Their *size* is greatest in the lumbar region. In *thickness* they vary not only in the different regions of the spine, but in different parts of the same disk: thus, they are much thicker in front than behind in the cervical region, and also in the lumbar, but they are uniformly thick in the dorsal region. They thus contribute in a great measure to the curvatures of the spine in the neck and loins, whilst the concavity of the dorsal region is chiefly due to the shape of the bodies of the vertebræ. The intervertebral disks form about one-fourth of the spinal column, exclusive of the first two vertebræ; they are not equally distributed, however, between the various bones, the dorsal portion of the spine having, in proportion to its length, a much smaller quantity than in the cervical and lumbar regions, which necessarily gives to the latter parts greater pliancy and freedom of movement. The intervertebral disks are adherent by their surfaces to a thin layer of cartilage which covers the upper and under surfaces of the bodies of the vertebræ, and by their circumference are closely connected in front to the anterior and behind to the posterior common ligament, whilst in the dorsal region they are connected laterally, by means of the interarticular ligament, to the heads of those ribs which articulate with two vertebræ; they consequently form part of the articular cavities in which the heads of these bones are received.

The intervertebral substance is composed at its circumference of laminæ of fibrous tissue and fibro-cartilage, and at its centre of a soft, elastic, pulpy matter. The laminæ are arranged concentrically one within the other, the outermost consisting of ordinary fibrous tissue, but the others and more numerous consisting of white fibro-cartilage. These plates are not quite vertical in their direction, those near the circumference being curved outward and closely approximated, whilst those nearest the centre curve in the opposite direction and are somewhat more widely separated. The fibres of which each plate is composed are directed, for the most part, obliquely from above downward; the fibres of an adjacent plate have an exactly opposite arrangement, varying in their direction in every layer, so that the fibres of one layer are directed across those of another, like the limbs of the letter X. In some few instances horizontal fibres may be observed. This laminar arrangement belongs to about the outer half of each disk, the central part being occupied by a soft, pulpy, highly elastic substance of a yellowish color, which rises up considerably above the surrounding level when the disk is divided horizontally. This substance presents no concentric arrangement, and consists of a fine fibrous matrix containing cells united to form a reticular structure. The pulpy matter, which is especially well developed in the lumbar region, is the remains of the chorda dorsalis, and, according to Luschka, contains a small synovial cavity in its centre.

[The intervertebral disks are compressible. In 287 soldiers measured by M. Robert the measurement in the erect posture was on an average 65.28 inches, and when in the horizontal, 65.79—a difference of half an inch.]

2. LIGAMENTS CONNECTING THE LAMINÆ.

Ligamenta Subflava.

The **Ligamenta Subflava** (Fig. 236) are interposed between the laminæ of the vertebræ from the axis to the sacrum. They are most distinct when seen from the interior of the spinal canal; when viewed from the outer surface they appear short, being overlapped by the laminæ. Each ligament consists of two lateral portions, which commence on each side at the root of either articular process, and pass backward to the point where the laminæ converge to form the spinous process, where their margins are thickest, and separated by a slight interval filled up with areolar tissue. These ligaments consist of yellow elastic tissue, the fibres of which, almost perpendicular in direction, are attached to the anterior surface of the margin of the lamina above, and to the posterior surface, as well as to the margin of the lamina below. In the cervical region they are thin in texture, but very broad and long; they become thicker in the dorsal region, and in the lumbar acquire very considerable thickness. Their highly elastic property serves to preserve the upright posture and to assist in resuming it after the spine has been flexed. These ligaments do not exist between the occiput and atlas or between the atlas and axis.

3. LIGAMENTS CONNECTING THE ARTICULAR PROCESSES.

Capsular.

The **Capsular Ligaments** (Fig. 238) are thin and loose ligamentous sacs attached to the contiguous margins of the articulating processes of each vertebra through the greater part of their circumference, and completed internally by the ligamenta subflava. They are longer and looser in the cervical than in the dorsal or lumbar regions. The capsular ligaments are lined on their inner surface by synovial membrane.

4. LIGAMENTS CONNECTING THE SPINOUS PROCESSES.

Interspinous. Supraspinous.

The **Interspinous Ligaments** (Fig. 236), thin and membranous, are interposed between the spinous processes. Each ligament extends from the root to near the summit of each spinous process, and connects together their adjacent margins. They are narrow and elongated in the dorsal region, broader, quadrilateral in form, and thicker in the lumbar region, and only slightly developed in the neck.

The **Supraspinous Ligament** is a strong fibrous cord which connects together the apices of the spinous processes from the seventh cervical to the spinous processes of the sacrum. It is thicker and broader in the lumbar than in the dorsal region, and intimately blended in both situations with the neighboring aponeurosis. The most superficial fibres of this ligament connect three or four vertebræ; those deeper-seated pass between two or three vertebræ; whilst the deepest connect the contiguous extremities of neighboring vertebræ. It is continued upward to the external occipital protuberance, as the ligamentum nuchæ, which in the human subject is thin and forms merely an intermuscular septum.

5. LIGAMENTS CONNECTING THE TRANSVERSE PROCESSES.

Intertransverse.

The **Intertransverse Ligaments** consist of bundles of fibres interposed between the transverse processes. In the cervical region they consist of a few irregular, scattered fibres; in the dorsal they are rounded cords intimately connected with the deep muscles of the back; in the lumbar region they are thin and membranous.

ACTIONS.—The movements permitted in the spinal column are, Flexion, Extension, Lateral Movement, Circumduction, and Rotation.

In *Flexion*, or movement of the spine forward, the anterior common ligament is relaxed and the intervertebral substances are compressed in front, while the posterior common ligament, the ligamenta subflava, and the inter- and supra-spinous ligaments are stretched, as well as the posterior fibres of the intervertebral disks. The interspaces between the laminæ are widened, and the inferior articular processes of the vertebræ above glide upward upon the articular processes of the vertebræ below. Flexion is the most extensive of all the movements of the spine.

In *Extension*, or movement of the spine backward, an exactly opposite disposition of the parts takes place. This movement is not extensive, being limited by the anterior common ligament and by the approximation of the spinous processes.

Flexion and extension are most free in the lower part of the lumbar region, between the third and fourth and fourth and fifth lumbar vertebræ; above the third they are much diminished, and reach their minimum in the middle and upper part of the back. They increase again in the neck, the capability of motion backward from the upright position being in this region greater than that of the motion forward, whereas in the lumbar region the reverse is the case.

In *Lateral Movement* the sides of the intervertebral disks are compressed, the extent of motion being limited by the resistance offered by the surrounding ligaments and by the approximation of the transverse processes. This movement may take place in any part of the spine, but is most free in the neck and loins.

Circumduction is very limited, and is produced merely by a succession of the preceding movements.

Rotation is produced by the twisting of the intervertebral substances; this, although only slight between any two vertebræ, produces a great extent of movement when it takes place in the whole length of the spine, the front of the column being turned to one or the other side. This movement takes place only to a slight extent in the neck, but is freer in the upper part of the dorsal region, and is altogether absent in the lumbar region.

It is thus seen that the *cervical region* enjoys the greatest extent of each variety of movement, flexion and extension especially being very free. In the *dorsal region* the three movements of flexion, extension, and circumduction are only permitted to each side to a slight extent, while rotation is very free in the upper part and ceases below. In the lumbar region there is free flexion, extension, and lateral movement, but no rotation. [The rotation of the head and atlas on the axis amounts to about 25°, and of the remaining cervical and upper dorsal vertebræ to about 45° more, making 70° in all in the neck. In the dorsal region about 30° more are added, to which the hips add 65° to 80° more, a total rotation of 165° to 180°. The various movements of the spine are beautifully seen in the well-known statues of Psyche, the Wrestlers, the Dying Gladiator, Angelo's Night and Morning, etc., and the living model may be made to assume these and many other positions.]

As Professor Humphry has pointed out, the movements permitted are mainly due to the shape and position of the articulating processes. In the loins the inferior articulating processes, turned outward and embraced by the superior, render rotation in this region of the spine impossible, whilst there is nothing to prevent a sliding upward and downward of the surfaces on each other, so as to allow of flexion and extension. In the dorsal region, on the other hand, the articulating processes, by their direction and mutual adaptation, especially at the upper part of the series, permit of rotation, but prevent extension and flexion, while in the cervical region the greater obliquity and lateral slant of the articular processes allows not only flexion and extension, but also rotation.

The principal muscles which produce *extension* are the fourth layer of the muscles of the back, assisted in the neck by the Splenius, Rectus capitis posticus minor, and the Superior oblique.

Flexion is produced by the Sterno-mastoid, Rectus capitis anticus major and minor, the Scaleni, the abdominal muscles, and the Psoas magnus. *Lateral* motion is produced by the fourth layer of the muscles of the back, by the Splenius and the Scaleni, the muscles of one side only acting; and *rotation* by the action of the following muscles of one side only—viz. the Sterno-mastoid, the Recti antici, the Scaleni, the Multifidus spinæ, the Complexus, the Rectus capitis posticus major, Inferior oblique, and the abdominal muscles.

II. ARTICULATIONS OF THE ATLAS WITH THE AXIS.

The articulation of the Atlas with the Axis is of a complicated nature, comprising no less than four distinct joints. There is a lateral ginglymus joint (diarthrosis rotatoria) between the odontoid process of the axis and the ring formed between the anterior arch of the atlas and the transverse ligament. (See Fig. 239.) Here there are two joints—one in front, between the posterior surface of the anterior arch of the atlas and the front of the odontoid process (the *atlo-odontoid joint* of Cruveilhier); the other between the anterior surface of the transverse ligament and the back of the process (the *syndesmo-odontoid joint*). Between the articulating processes of the two bones there is a double arthrodia or gliding joint. The ligaments which connect these bones are the

Two Anterior Atlo-axoid.	Transverse.
Posterior Atlo-axoid.	Two Capsular.

Of the **Two Anterior Atlo-axoid Ligaments** (Fig. 237), the more superficial is a rounded cord situated in the middle line; it is attached above to the tubercle on the anterior arch of the atlas, below to the base of the odontoid process and to the front of the body of the axis. The deeper ligament is a membranous layer, attached above to the lower border of the anterior arch of the atlas, below to the

FIG. 237.

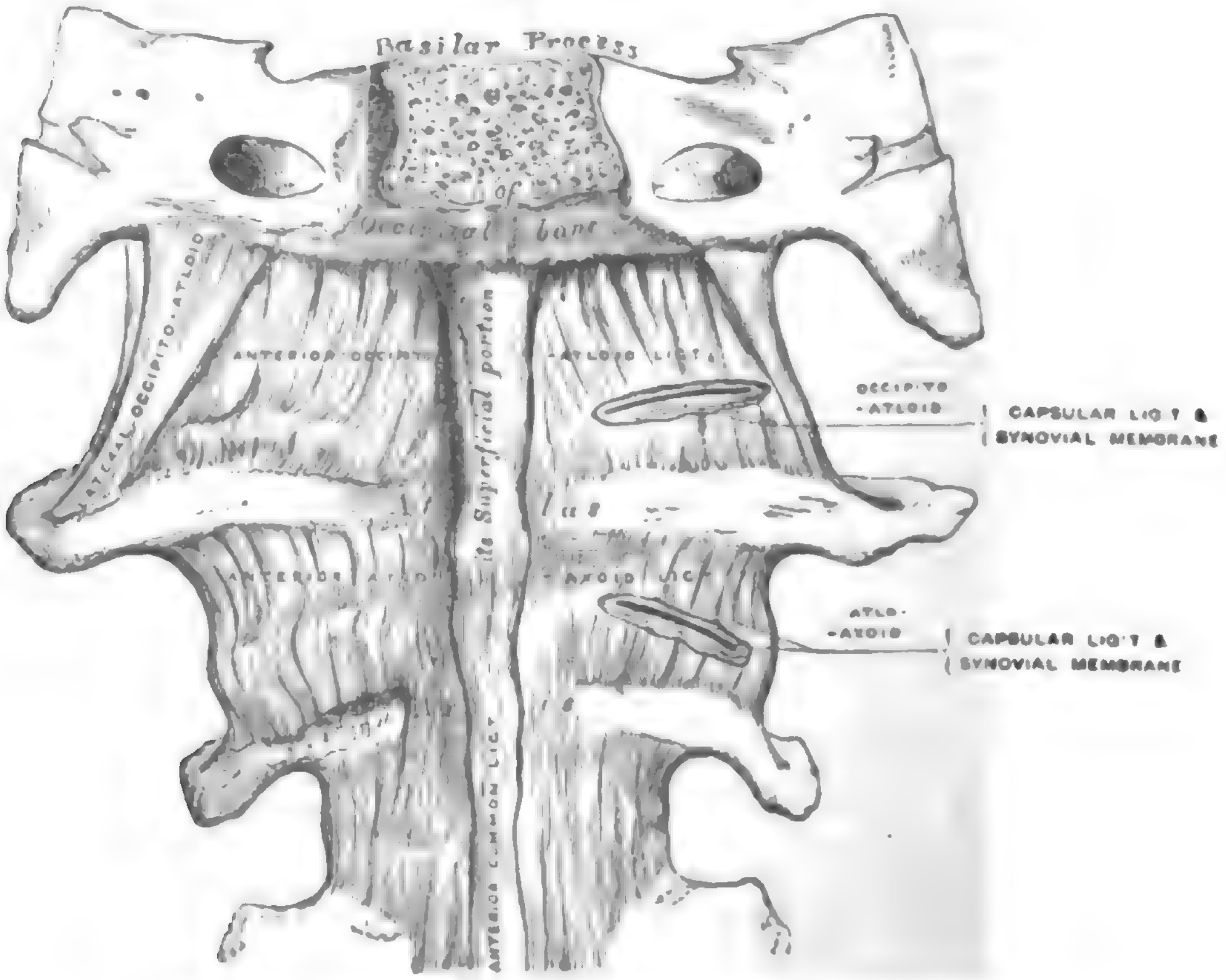
Basilar Process
of
Occipital bone
LATERAL OCCIPITO-ATLOID
ANTERIOR OCCIPITO-ATLOID LIG'T
its Superficial portion
OCCIPITO-ATLOID
CAPSULAR LIG'T &
SYNOVIAL MEMBRANE
Atlas
ANTERIOR ATLO-AXOID LIG'T
ATLO-AXOID
CAPSULAR LIG'T &
SYNOVIAL MEMBRANE
ANTERIOR COMMON LIG'T

Occipito-atloid and Atlo-axoid Ligaments, front view.

base of the odontoid process and front of the body of the axis. These ligaments are in relation, in front, with the Recti antici majores.

FIG. 238.

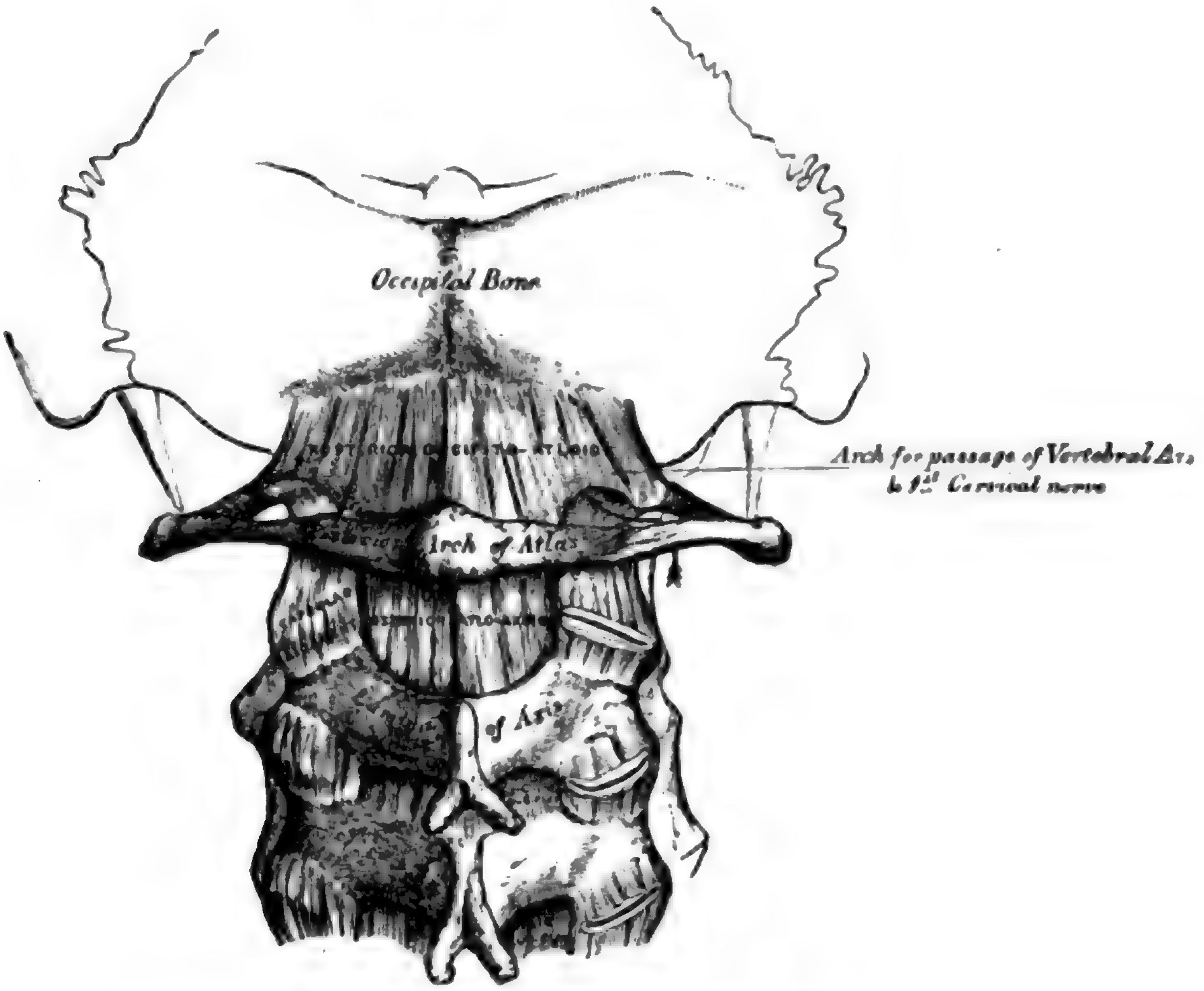
Occipital Bone
Arch of Atlas
of Axis
Arch for passage of Vertebral Ar. & 1st Cervical nerve

Occipito-atloid and Atlo-axoid Ligaments, posterior view.

The **Posterior Atlo-axoid Ligament** (Fig. 238) is a broad and thin membranous layer, attached above to the lower border of the posterior arch of the atlas, below to the upper edge of the laminæ of the axis. This ligament supplies the place of the ligamenta subflava, and is in relation, behind, with the Inferior oblique muscles.

FIG. 239.

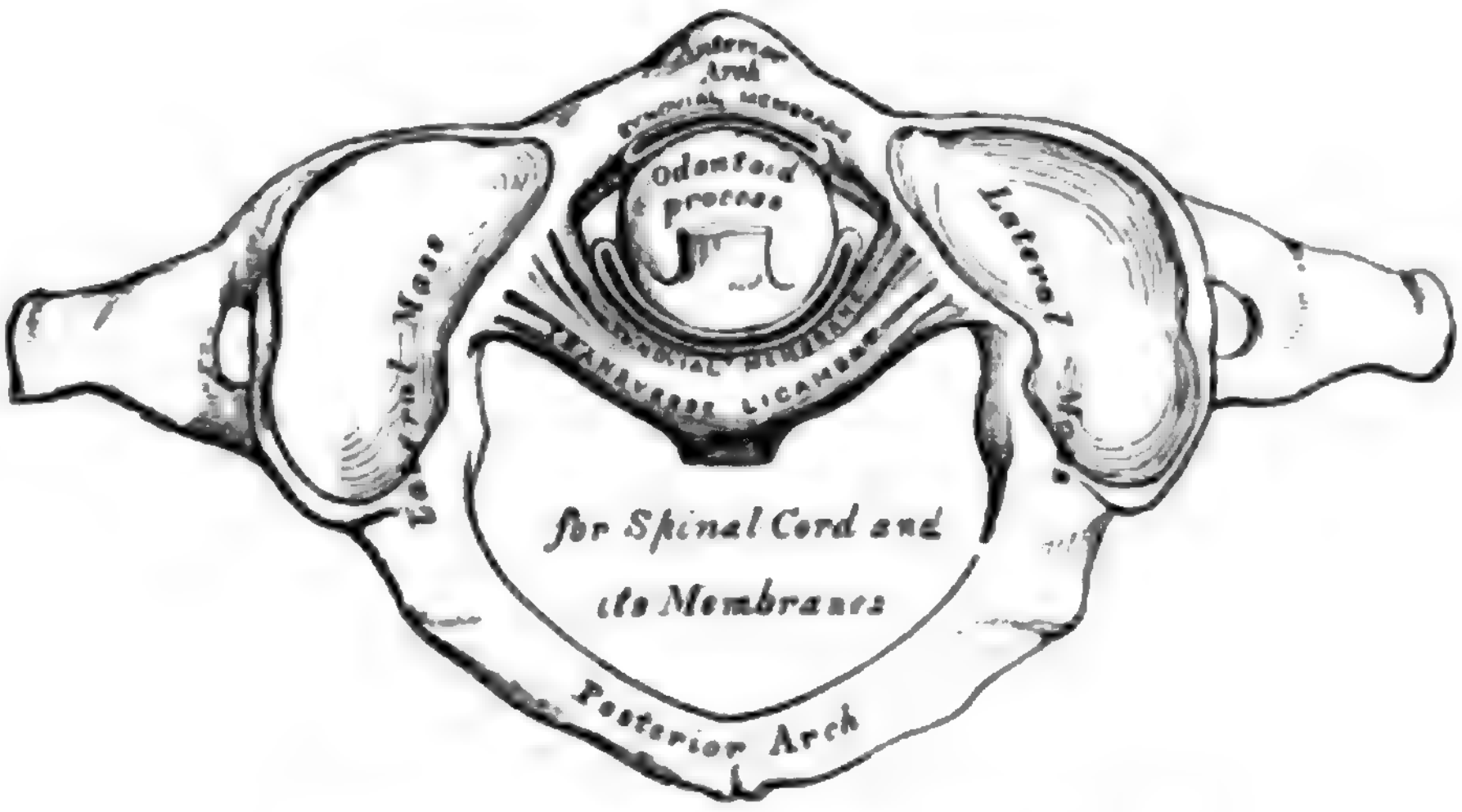
Anterior Arch
Odontoid process
Lateral Mass
Lateral Mass
Transverse Ligament
for Spinal Cord and its Membranes
Posterior Arch

Articulation between Odontoid Process and Atlas.

The **Transverse Ligament**[1] (Figs. 239, 240) is a thick and strong ligamentous band which arches across the ring of the atlas, and serves to retain the odontoid process in firm connection with its anterior arch. This ligament is flattened from before backward, broader and thicker in the middle than at either extremity, and firmly attached on each side of the atlas to a small tubercle on the inner surface of its lateral mass. As it crosses the odontoid process a small fasciculus is derived from its upper and lower borders, the former, passing upward, to be inserted into the basilar process of the occipital bone; the latter, downward, to be attached to the root of the odontoid process; hence the whole ligament has received the name of *cruciform*.

---

[1] It has been found necessary to describe the transverse ligament with those of the atlas and axis; but the student must remember that it is really a portion of the mechanism by which the movements of the head on the spine are regulated, so that the connections between the atlas and axis ought always to be studied together with those between the latter bones and the skull.

FIG. 240.

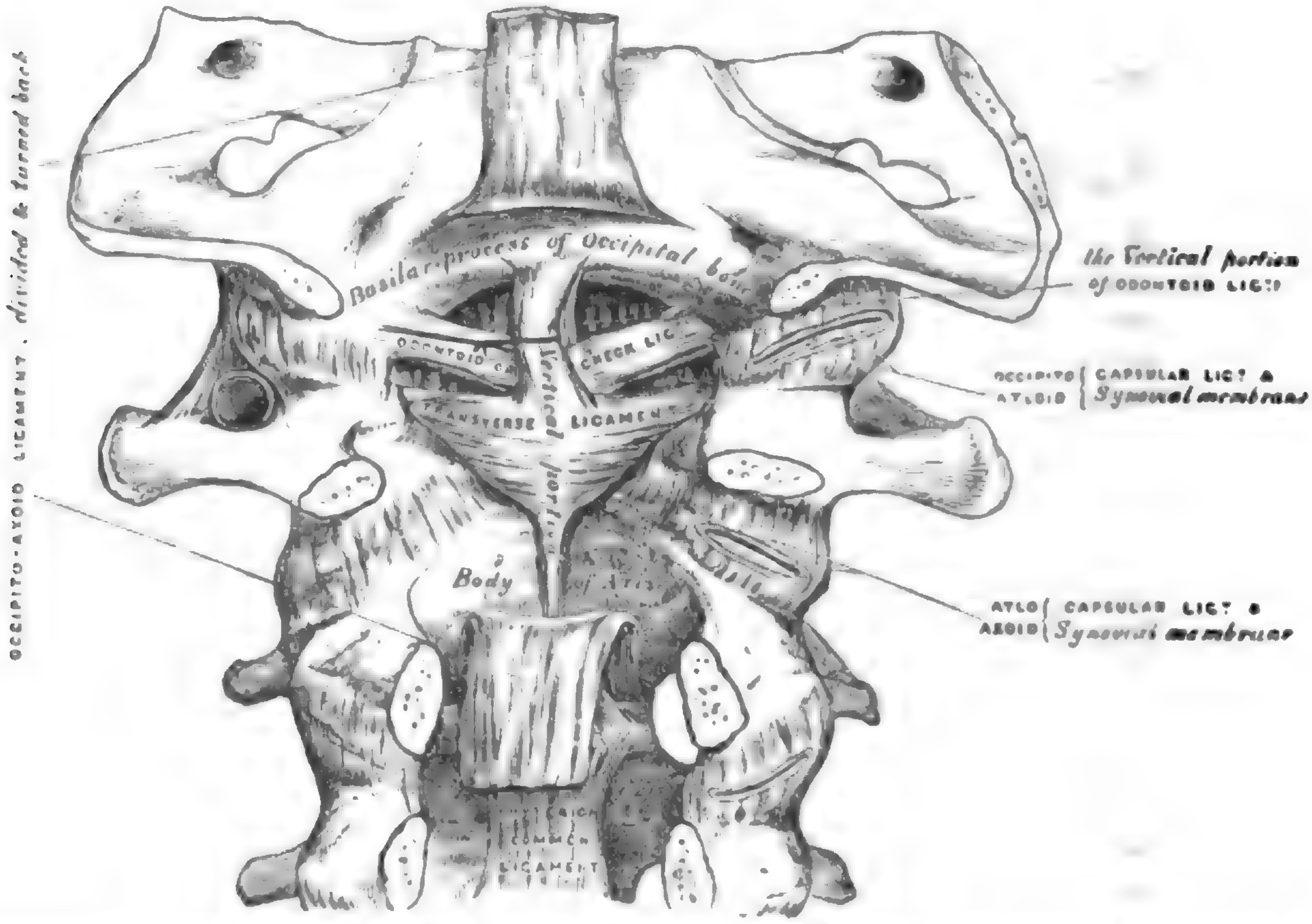
Occipito-axoid ligament, divided & turned back
Basilar process of Occipital bone
Odontoid
Check lig.
Vertical portion
Transverse ligament
Body of Axis
the Vertical portion of odontoid lig.
Occipito-atloid { Capsular lig. & Synovial membrane
Atlo-axoid { Capsular lig. & Synovial membrane
Common ligament

Occipito-axoid and Atlo-axoid Ligaments, posterior view, obtained by removing the arches of the vertebræ and the posterior part of the skull.

The transverse ligament divides the ring of the atlas into two unequal parts: of these the posterior and larger serves for the transmission of the cord and its membranes and the spinal accessory nerves; the anterior and smaller contains the odontoid process. Since the lower border of the space between the anterior arch of the atlas and the transverse ligament is smaller than the upper (because the transverse ligament embraces firmly the narrow neck of the odontoid process), this process is retained in firm connection with the atlas when all the other ligaments have been divided.

The **Capsular Ligaments** are two thin and loose capsules, connecting the articular surfaces of the atlas and axis, the fibres being strongest on the anterior and external part of the articulation.

There are *four* **synovial membranes** in this articulation—one lining the inner surface of each of the capsular ligaments; one between the anterior surface of the odontoid process and the anterior arch of the atlas, the atlo-odontoid joint; and one between the posterior surface of the odontoid process and the transverse ligament, the syndesmo-odontoid joint. The latter often communicates with those between the condyles of the occipital bone and the articular surfaces of the atlas.

ACTIONS.—This joint is capable of great mobility, and allows the rotation of the atlas (and, with it, of the cranium) upon the axis, the extent of rotation being limited by the odontoid ligaments. The principal muscles by which this action is produced are the Rectus capitis posticus major and the Obliquus inferior, assisted to a certain extent by the Rectus capitis anticus major and by other muscles which pass obliquely from the spine to the head, as the Trachelo-mastoid.

ARTICULATIONS OF THE SPINE WITH THE CRANIUM.

The ligaments connecting the spine with the cranium may be divided into two sets, those connecting the occipital bone with the atlas, and those connecting the occipital bone with the axis.

III. ARTICULATION OF THE ATLAS WITH THE OCCIPITAL BONE.

This articulation is a double arthrodia. Its ligaments are the

Two Anterior Occipito-atloid.	Two Lateral Occipito-atloid.
Posterior Occipito-atloid.	Two Capsular.

Of the **Two Anterior Ligaments** (Fig. 237), the superficial is a strong, narrow, rounded cord, attached above to the basilar process of the occiput, below to the tubercle on the anterior arch of the atlas: the deeper ligament is a broad and thin membranous layer which passes between the anterior margin of the foramen magnum above and the whole length of the upper border of the anterior arch of the atlas below. This ligament is in relation in front with the Recti antici minores, behind with the odontoid ligaments.

The **Posterior Occipito-atloid Ligament** (Fig. 238) is a very broad but thin membranous lamina intimately blended with the dura mater. It is connected above to the posterior margin of the foramen magnum, below to the upper border of the posterior arch of the atlas. This ligament is incomplete at each side, and forms, with the superior intervertebral notch, an opening for the passage of the vertebral artery and suboccipital nerve. It is in relation behind with the Recti postici minores and Obliqui superiores, in front with the dura mater of the spinal canal, to which it is intimately adherent.

The **Lateral Ligaments** are strong fibrous bands directed obliquely upward and inward, attached above to the jugular process of the occipital bone, below to the base of the transverse process of the atlas.

The **Capsular Ligaments** surround the condyles of the occipital bone, and connect them with the articular surfaces of the atlas; they consist of thin and loose capsules which enclose the synovial membrane of the articulation. The synovial membranes between the occipital bone and atlas communicate occasionally with that between the posterior surface of the odontoid process and transverse ligament.

ACTIONS.—The movements permitted in this joint are flexion and extension, which give rise to the ordinary forward or backward nodding of the head, besides slight lateral motion to one or the other side. When either of these actions is carried beyond a slight extent, the whole of the cervical portion of the spine assists in its production. Flexion is mainly produced by the action of the Rectus capitis anticus major and minor and the Sterno-mastoid muscles. Extension by the Rectus capitis posticus major and minor and the Superior oblique; by the Complexus and upper fibres of the Trapezius. The Recti laterales are mainly concerned in the slight lateral movement. According to Cruveilhier, there is a slight motion of rotation in this joint.

IV. ARTICULATION OF THE AXIS WITH THE OCCIPITAL BONE.

Occipito-axoid.	Three Odontoid.

To expose these ligaments the spinal canal should be laid open by removing the posterior arch of the atlas, the laminæ and spinous process of the axis, and the portion of the occipital bone behind the foramen magnum, as seen in Fig. 240.

The **Occipito-axoid Ligament** (*apparatus ligamentosus colli*) is situated at the upper part of the front surface of the spinal canal. It is a broad and strong ligamentous band which covers the odontoid process and its ligaments, and appears to be a prolongation upward of the posterior common ligament of the spine. It is attached below to the posterior surface of the body of the axis, and, becoming expanded as it ascends, is inserted into the basilar groove of the occipital bone in front of the foramen magnum, where it becomes blended with the dura mater of the skull.

RELATIONS.—By its anterior surface it is intimately connected with the transverse ligament, by its posterior surface with the dura mater. By cutting this ligament across and turning its ends aside the transverse and odontoid ligaments are exposed.

The **Odontoid** or **Check Ligaments** (alar ligaments) are strong, rounded, fibrous cords which arise one on either side of the apex of the odontoid process, and, passing obliquely upward and outward, are inserted into the rough depressions on the inner side of the condyles of the occipital bone. In the triangular interval left between these ligaments and the margin of the foramen magnum a third strong ligamentous band (ligamentum suspensorium) may be seen, which passes almost perpendicularly from the apex of the odontoid process to the anterior margin of the foramen, being intimately blended with the anterior occipito-atloid ligament and upper fasciculus of the transverse ligament of the atlas.

ACTIONS.—The odontoid ligaments serve to limit the extent to which rotation of the cranium may be carried; hence they have received the name of *check ligaments.*

In addition to these ligaments, which connect the atlas and axis to the skull, the ligamentum nuchæ must be regarded as one of the ligaments by which the spine is connected with the cranium. (For a description of this ligament see the description of the Trapezius muscle.)

V. TEMPORO-MAXILLARY ARTICULATION.

This is a double or bilateral condyloid joint; the parts entering into its formation are, on each side, the anterior part of the glenoid cavity of the temporal bone

FIG. 241.

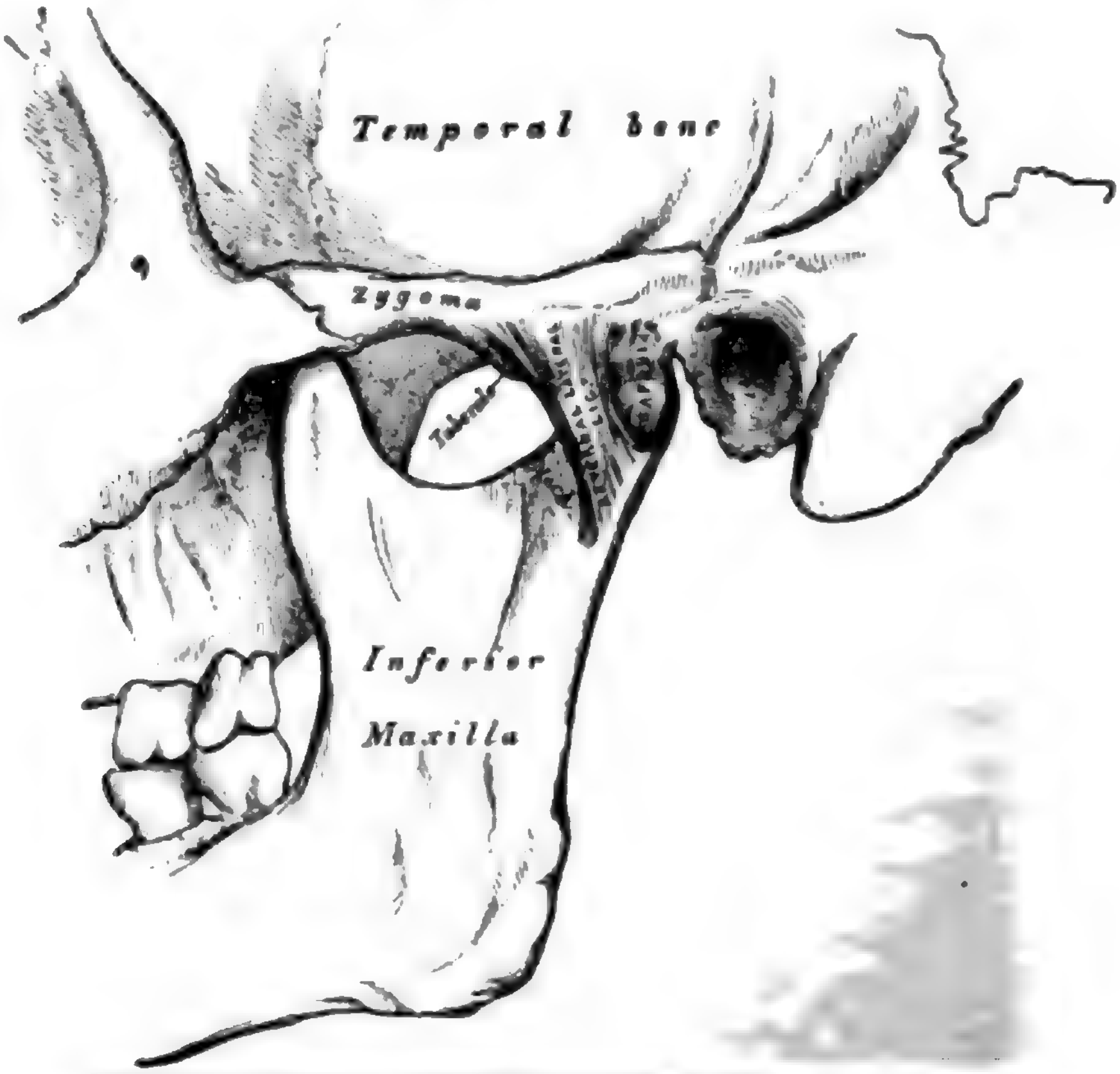

Temporo-maxillary Articulation, external view.

and the eminentia articularis above with the condyle of the lower jaw below. The ligaments are the following:

External Lateral.	Stylo-maxillary.
Internal Lateral.	Capsular.

Interarticular Fibro-cartilage.

The **External Lateral Ligament** (Fig. 241) is a short, thin, and narrow fasciculus attached above to the outer surface of the zygoma and to the rough tubercle on its lower border; below, to the outer surface and posterior border of the neck of the lower jaw. This ligament is broader above than below; its fibres are placed parallel with one another and directed obliquely downward and backward. Externally, it is covered by the parotid gland and by the integument. Internally, it is in relation with the interarticular fibro-cartilage and the synovial membrane.

The **Internal Lateral Ligament** (Fig. 242) is a long, thin, and loose band which is attached above to the spinous process of the sphenoid bone, and, becoming broader as it descends, is inserted into the inner margin of the dental foramen. Its outer surface is in relation above with the External pterygoid muscle; lower down it is separated from the neck of the condyle by the internal maxillary artery; and still more inferiorly the inferior dental vessels and nerve separate it from the ramus of the jaw. Internally, it is in relation with the internal pterygoid.

The **Stylo-maxillary Ligament** is a thin aponeurotic cord which extends from near the apex of the styloid process of the temporal bone to the angle and posterior border of the ramus of the lower jaw, between the Masseter and Internal pterygoid muscles. This ligament separates the parotid from the submaxillary gland, and has attached to its inner side part of the fibres of origin of the Stylo-glossus muscle. Although usually classed among the ligaments of the jaw, it can only be considered as an accessory in the articulation. It is derived from the deep cervical fascia.

FIG. 242.

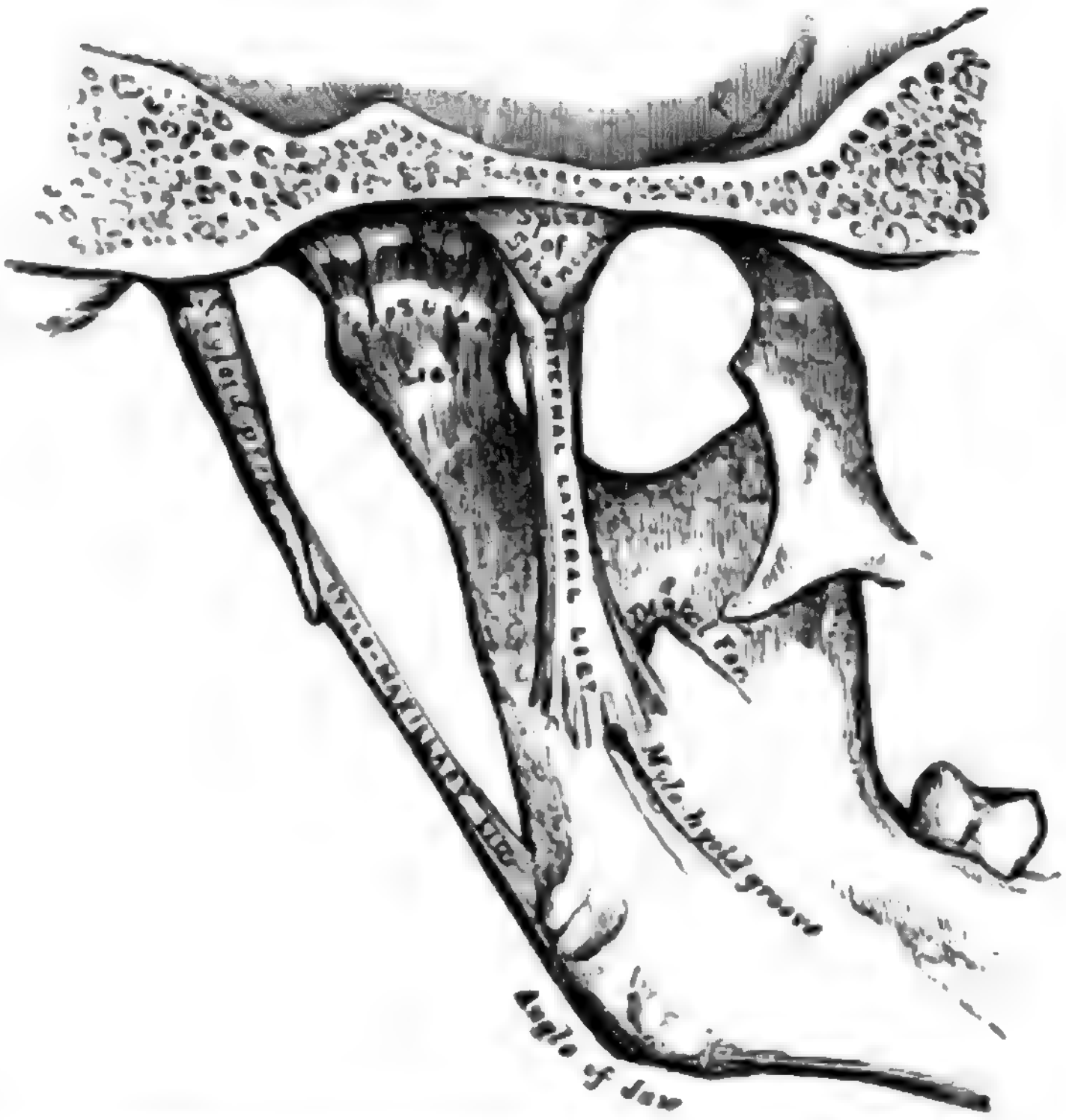

Temporo-maxillary Articulation, internal view.

Along with the stylo-maxillary ligament may be described the *stylo-hyoid ligament*, although it is in no way connected with the functions of the lower jaw. This is a fibrous cord which continues the styloid process down to the hyoid bone, being attached to the tip of the former and the small cornu of the latter. It is often more or less ossified.

The **Capsular Ligament** forms a thin and loose ligamentous capsule attached above to the circumference of the glenoid cavity and the articular surface immediately in front; below, to the neck of the condyle of the lower jaw. It consists of a few thin scattered fibres, and can hardly be considered as a distinct ligament: it is thickest at the back part of the articulation.[1]

The **Interarticular Fibro-cartilage** (Fig. 243) is a thin plate of an oval form placed horizontally between the condyle of the jaw and the glenoid cavity. Its

---

[1] Dr. Humphry describes the internal portion of the capsular ligament separately as the *short internal lateral ligament*; and it certainly seems as deserving of a separate description as the external lateral ligament is.

FIG. 243.

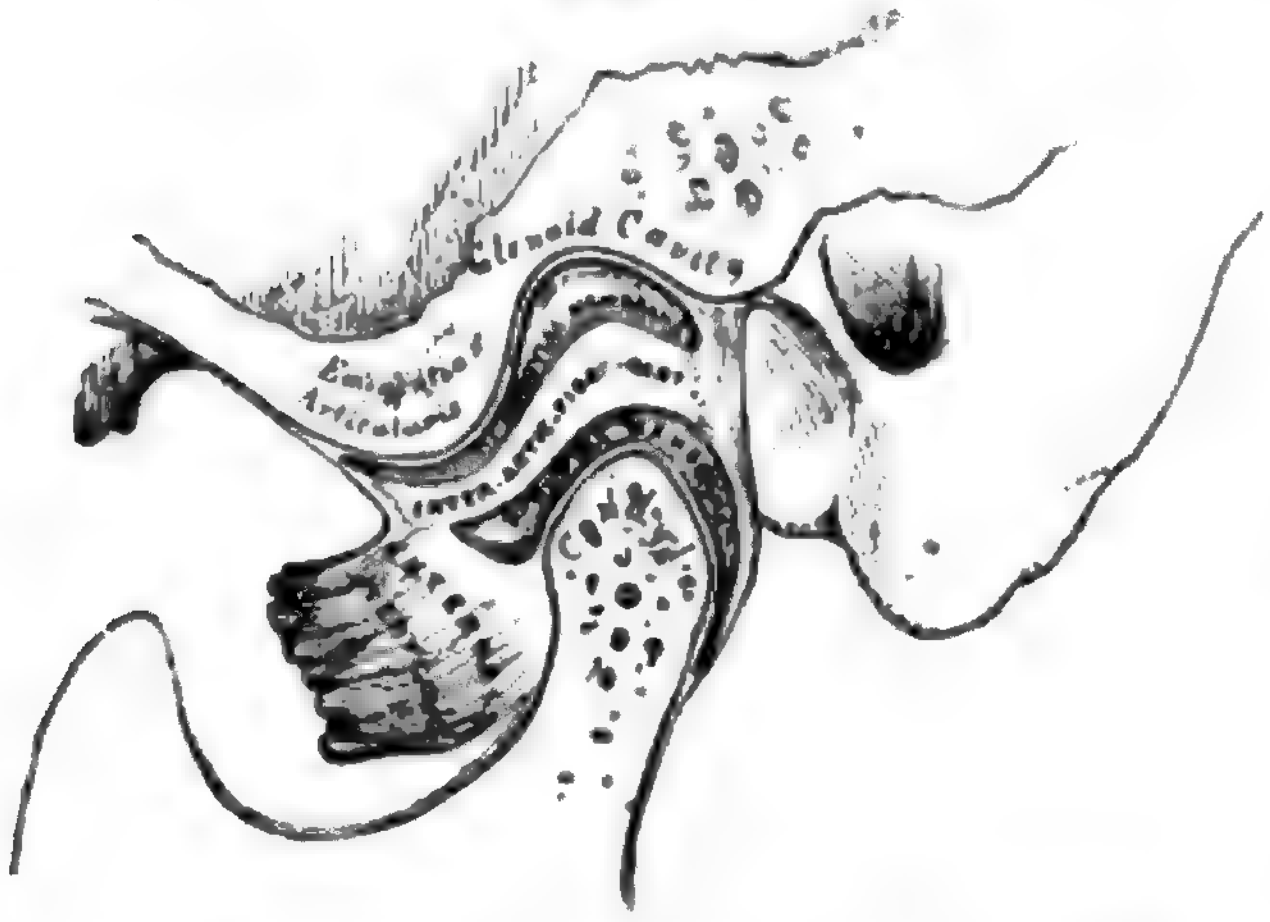

Vertical Section of Temporo-maxillary Articulation.

upper surface is concavo-convex from before backward and a little convex transversely, to accommodate itself to the form of the glenoid cavity. Its under surface, where it is in contact with the condyle, is concave. Its circumference is connected externally to the external lateral ligament, internally to the capsular ligament, and in front to the tendon of the External pterygoid muscle. It is thicker at its circumference, especially behind, than at its centre, where it is sometimes perforated. The fibres of which it is composed have a concentric arrangement, more apparent at the circumference than at the centre. Its surfaces are smooth, and divide the joint into two cavities, each of which is furnished with a separate synovial membrane. When the fibro-cartilage is perforated the synovial membranes are continuous with one another.

The **synovial membranes**, two in number, are placed one above and the other below the fibro-cartilage. The upper one, the larger and looser of the two, is continued from the margin of the cartilage covering the glenoid cavity and eminentia articularis on to the upper surface of the fibro-cartilage. The lower one passes from the under surface of the fibro-cartilage to the neck of the condyle of the jaw, being prolonged downward a little farther behind than in front.

The *Nerves* of this joint are derived from the auriculo-temporal and masseteric branches of the inferior maxillary.

ACTIONS.—The movements permitted in this articulation are very extensive. Thus, the jaw may be depressed or elevated, or it may be carried forward or backward or from side to side. It is by the alternation of these movements, performed in succession, that a kind of rotatory motion of the lower jaw upon the upper takes place, which materially assists in the mastication of the food.

If the movement of depression is carried only to a slight extent, the condyles remain in the glenoid cavities, rotating on a transverse axis against the interarticular fibro-cartilage; but if the depression is considerable, the condyles glide from the glenoid fossæ on to the articular eminences, carrying with them the interarticular fibro-cartilages, so that in opening the mouth widely the two movements are combined; the condyle rotates on a transverse axis and at the same time glides forward, carrying the fibro-cartilage with it. When this movement is carried to too great an extent—as, for instance, during a convulsive yawn—dislocation of the condyle into the zygomatic fossa may occur, the interarticular cartilage being displaced forward and the capsular ligament ruptured. When the jaw is elevated after forced depression, the condyles and fibro-cartilages return to their original position. When the jaw is carried horizontally forward and backward or from side to side, a horizontal gliding movement of the fibro-cartilages and condyles upon the glenoid cavities takes place in the corresponding direction.

The lower jaw is *depressed* by its own weight, assisted by the Platysma, the Digastric, the Mylo-hyoid, and the Genio-hyoid. It is *elevated* by the Temporal, Masseter, and Internal pterygoid. It is drawn *forward* by the External pterygoid, Internal pterygoid, and the superficial fibres of the Masseter, and it is drawn backward by the deep fibres of the Masseter and the posterior fibres of the Temporal muscle.

VI. ARTICULATIONS OF THE RIBS WITH THE VERTEBRÆ.

The articulations of the ribs with the vertebral column may be divided into two sets: 1, Those which connect the heads of the ribs with the bodies of the vertebræ;

2, those which connect the necks and tubercles of the ribs with the transverse processes.

1. Articulations between the Heads of the Ribs and the Bodies of the Vertebræ (Fig. 244).

These constitute a series of arthrodial joints, formed by the articulation of the heads of the ribs with the cavities on the contiguous margins of the bodies of the dorsal vertebræ, connected together by the following ligaments:

Anterior Costo-vertebral or Stellate.
Capsular.
Interarticular.

The **Anterior Costo-vertebral** or **Stellate Ligament** connects the anterior part of the head of each rib with the sides of the bodies of two vertebræ and the intervertebral disk between them. It consists of three flat bundles of ligamentous fibres which radiate from the anterior part of the head of the rib. The superior fasciculus passes upward to be connected with the body of the vertebra above; the inferior one descends to the body of the vertebra below; and the middle one, the smallest and least distinct, passes horizontally inward, to be attached to the intervertebral substance.

Fig. 244.

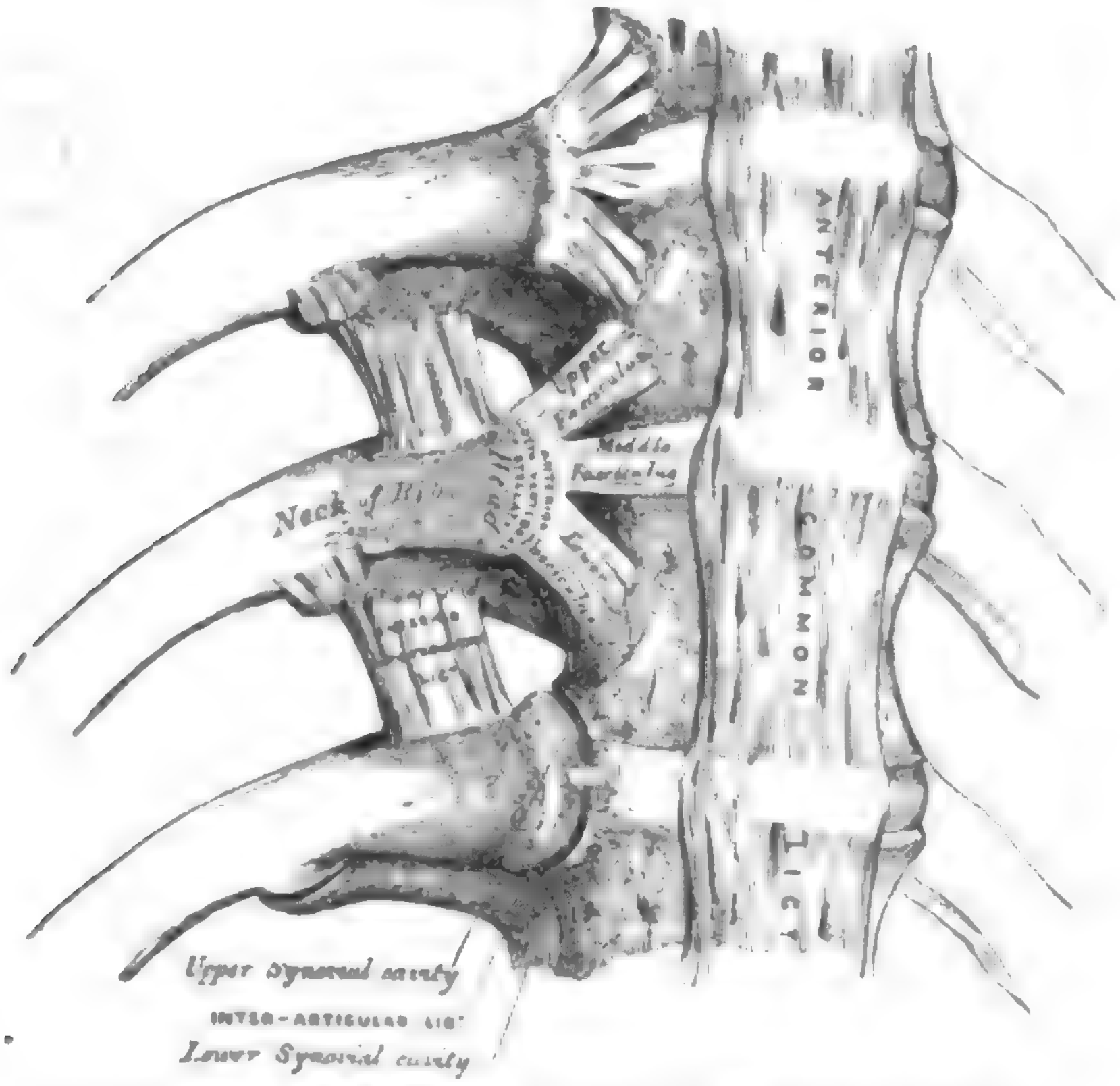

Costo-vertebral and Costo-transverse Articulations, anterior view.

Relations.—In front, with the thoracic ganglia of the sympathetic, the pleura, and, on the right side, with the vena azygos major; behind, with the interarticular ligament and synovial membranes.

In the first rib, which articulates with a single vertebra only, this ligament does not present a distinct division into three fasciculi: its superior fibres, however, pass to be attached to the body of the last cervical vertebra, as well as to the body of the vertebra with which the rib articulates. In the tenth, eleventh, and twelfth ribs also, which likewise articulate with a single vertebra, the division does not exist; but the upper fibres of the ligament in each case are connected with the vertebra above, as well as that with which the ribs articulate.

The **Capsular Ligament** is a thin and loose ligamentous bag which surrounds the joint between the head of the rib and the articular cavity formed by the junction of the vertebræ. It is very thin, firmly connected with the anterior ligament, and most distinct at the upper and lower parts of the articulation.

The **Interarticular Ligament** is situated in the interior of the joint. It consists of a short band of fibres flattened from above downward, attached by one extremity to the sharp crest on the head of the rib, and by the other to the intervertebral disk. It divides the joint into two cavities which have no communication with one another, but are each lined by a separate synovial membrane. In the first, tenth, eleventh, and twelfth ribs the interarticular ligament does not exist; consequently, there is but one synovial membrane.

ACTIONS.—The movement of the ribs is limited to elevation and depression, and to a slight rotation upward and downward. The former movement is produced by the head of the rib moving upon an axis directed transversely through the costovertebral joint; the latter is a rotation about an axis passing between their vertebral and sternal ends, and produces an inversion or eversion of the ribs. The mobility of the different ribs varies very much. The first rib is more fixed than the others, on account of the weight of the upper extremity and the strain of the ribs beneath; but on the freshly dissected thorax it moves as freely as the others. From the same causes the movement of the second rib is also not very extensive. In the other ribs their mobility increases successively down to the last two, which are very movable. The ribs are generally more movable in the female than in the male. [It should not be overlooked that elevation of the ribs, in consequence of their oblique position, pushes the sternum forward, and thus increases the anteroposterior capacity of the chest.]

2. ARTICULATIONS OF THE NECKS AND TUBERCLES OF THE RIBS WITH THE TRANSVERSE PROCESSES (Fig. 245).

The articular portion of the tubercle of the rib and adjacent transverse process form an arthrodial joint provided with a thin *capsular ligament* attached to the circumference of the articulating surfaces, and enclosing a small *synovial membrane.* In the *eleventh* and *twelfth ribs* this articulation is wanting.

FIG. 245.

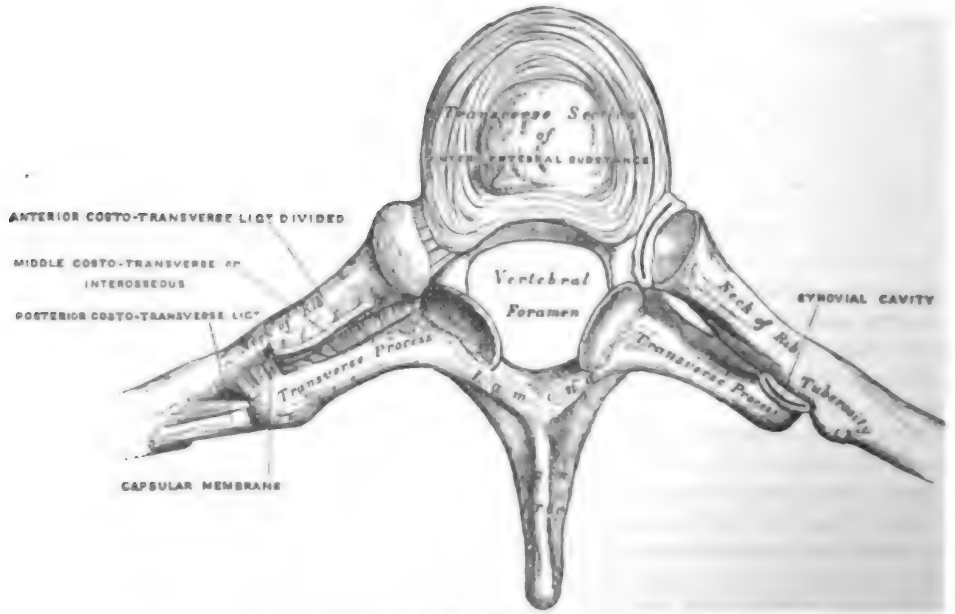
Transverse Section of Intervertebral Substance
ANTERIOR COSTO-TRANSVERSE LIG^T DIVIDED
MIDDLE COSTO-TRANSVERSE or INTEROSSEOUS
POSTERIOR COSTO-TRANSVERSE LIG^T
CAPSULAR MEMBRANE
Vertebral Foramen
Transverse Process
Transverse Process
Neck of Rib
Neck of Rib
SYNOVIAL CAVITY
Tuberosity
Lamina

Costo-transverse Articulation, seen from above.

The ligaments connecting these parts are the

Anterior Costo-transverse.
Middle Costo-transverse (Interosseous).
Posterior Costo-transverse.
Capsular.

The **Anterior Costo-transverse Ligament** (superior or long) is a broad and strong band of fibres attached below to the sharp crest on the upper border of the neck of each rib, and passing obliquely upward and outward to the lower border of the transverse process immediately above. It is broader below than above, broader and thinner between the lower ribs than between the upper, and more distinct in front than behind. This ligament is in relation, in front, with the intercostal vessels and nerves; behind with the Longissimus dorsi. Its *internal border* completes an aperture formed between it and the articular processes, through which pass the posterior branches of the intercostal vessels and nerves. Its *external border* is continuous with a thin aponeurosis which covers the External intercostal muscle.

The *first rib* has no anterior costo-transverse ligament.

The **Middle Costo-transverse** or **Interosseous Ligament** consists of short but strong fibres which pass between the rough surface on the posterior part of the neck of each rib and the anterior surface of the adjacent transverse process. In order fully to expose this ligament, a horizontal section should be made across the transverse process and corresponding part of the rib, or the rib may be forcibly separated from the transverse process and its fibres put on the stretch.

In the *eleventh* and *twelfth ribs* this ligament is quite rudimentary.

The **Posterior Costo-transverse Ligament** is a short but thick and strong fasciculus which passes obliquely from the summit of the transverse process to the rough, non-articular portion of the tubercle of the rib. This ligament is shorter and more oblique in the upper than in the lower ribs. Those corresponding to the superior ribs ascend, while those of the inferior ribs descend slightly.

In the *eleventh* and *twelfth ribs* this ligament is wanting.

ACTIONS.—The movement permitted in these joints is limited to a slight gliding motion of the articular surfaces one upon the other, the tubercles of the ribs moving backward and upward in inspiration, downward and forward in expiration.

VII. ARTICULATION OF THE CARTILAGES OF THE RIBS WITH THE STERNUM, ETC. (Fig. 246).

The articulations of the cartilages of the true ribs with the sternum are arthrodial joints with the exception of the first, in which the cartilage is almost always directly united with the sternum, and which must, therefore, be regarded as a synarthrodial articulation. The ligaments connecting them are the

Anterior Chondro-sternal.
Posterior Chondro-sternal.
Capsular.

The **Anterior Chondro-sternal Ligament** is a broad and thin membranous band that radiates from the front of the inner extremity of the cartilages of the true ribs to the anterior surface of the sternum. It is composed of fasciculi which pass in different directions. The *superior* fasciculi ascend obliquely, the *inferior* pass obliquely downward, and the *middle* fasciculi horizontally. The superficial fibres of this ligament are the longest; they intermingle with the fibres of the ligaments above and below them, with those of the opposite side, and with the tendinous fibres of origin of the Pectoralis major, forming a thick fibrous membrane which covers the surface of the sternum. This is more distinct at the lower than at the upper part.

The **Posterior Chondro-sternal Ligament,** less thick and distinct than the

Fig. 246.

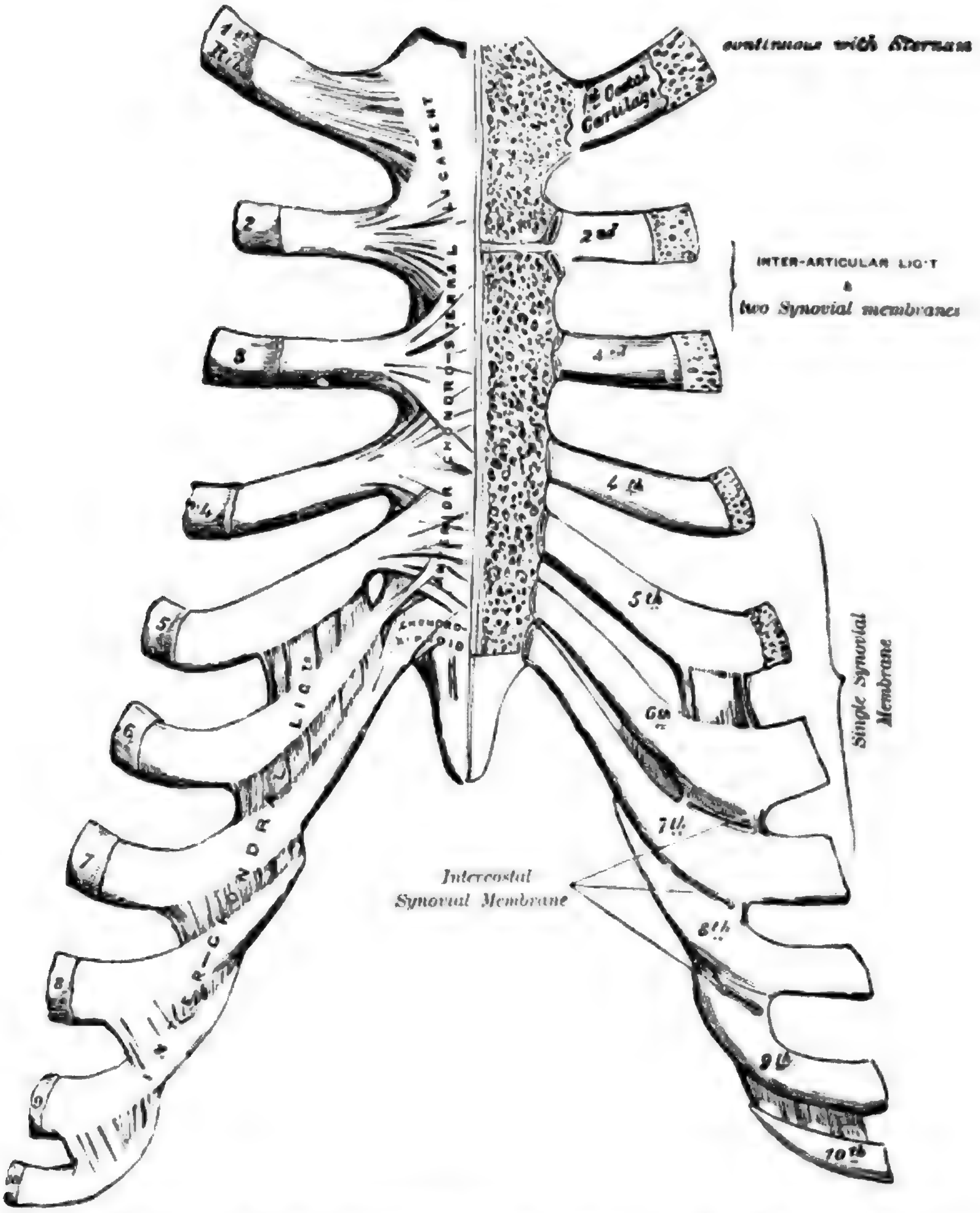
1st Rib
continuous with Sternum
1st Costal Cartilage
2
2nd
INTER-ARTICULAR LIG'T
&
two Synovial membranes
3
3rd
ANTERIOR CHONDRO-STERNAL LIGAMENT
4
4th
5
5th
Single Synovial Membrane
CHONDRO-XIPHOID
6
6th
INTER-CHONDRAL LIG'T
7
7th
Intercostal Synovial Membrane
8
8th
9
9th
10
10th

Chondro-sternal, Chondro-xiphoid, and Interchondral Articulations, anterior view. The synovial cavities exposed by a vertical section of the sternum and cartilages.

anterior, is composed of fibres which radiate from the posterior surface of the sternal end of the cartilages of the true ribs to the posterior surface of the sternum, becoming blended with the periosteum.

The **Capsular Ligament** surrounds the joints formed between the cartilages of the true ribs and the sternum. It is very thin, intimately blended with the anterior and posterior ligaments, and strengthened at the upper and lower part of the articulation by a few fibres which pass from the cartilage to the side of the sternum. These ligaments protect the synovial membranes.

Synovial Membranes.—The cartilage of the first rib is directly continuous with the sternum, without any synovial membrane. The cartilage of the *second rib* is connected with the sternum by means of an interarticular ligament attached by one extremity to the cartilage of the second rib, and by the other extremity to the cartilage which unites the first and second pieces of the sternum. This articulation is provided with two synovial membranes. That of the third rib has also two synovial membranes, and that of the fourth, fifth, sixth, and seventh, each a single synovial membrane.[1] Thus there are *eight* synovial cavities on each side in the articulations between the costal cartilages of the true ribs and the sternum. They may be demonstrated by removing a thin section from the anterior surface of the sternum and cartilages, as seen in the figure. After middle life the articular surfaces lose their polish, become roughened, and the synovial membranes appear to be wanting. In old age the articulations do not exist, the cartilages of most of the ribs becoming continuous with the sternum. The cartilage of the *seventh rib*, and occasionally also that of the *sixth*, is connected to the anterior surface of the ensiform appendix by a band of ligamentous fibres which varies in length and breadth in different subjects. It is called the *chondro-xiphoid ligament.*

ACTIONS.—The movements which are permitted in the chondro-sternal articulations are limited to elevation and depression, and these only to a slight extent.

ARTICULATIONS OF THE CARTILAGES OF THE RIBS WITH EACH OTHER (INTERCHONDRAL) (Fig. 246).

The cartilages of the sixth, seventh, and eighth ribs articulate, by their lower borders, with the corresponding margin of the adjoining cartilages by means of a small, smooth, oblong-shaped facet. Each articulation is enclosed in a thin *capsular ligament* lined by *synovial membrane*, and strengthened externally and internally by ligamentous fibres (interchondral ligaments) which pass from one cartilage to the other. Sometimes the cartilage of the fifth rib, more rarely that of the ninth, articulates by its lower border with the adjoining cartilage by a small oval facet; more frequently they are connected together by a few ligamentous fibres. Occasionally the articular surfaces above mentioned are wanting.

ARTICULATIONS OF THE RIBS WITH THEIR CARTILAGES (COSTO-CHONDRAL) (Fig. 246).

The outer extremity of each costal cartilage is received into a depression in the sternal end of the ribs and held together by the periosteum.

VIII. LIGAMENTS OF THE STERNUM.

The second piece of the sternum is united to the first either by an amphiarthrodial joint—a single piece of true fibro-cartilage uniting the segments—or by a diarthrodial joint, in which each bone is clothed with a distinct lamina of cartilage, adherent on one side, free and lined with synovial membrane on the other. In the latter case the cartilage covering the gladiolus is continued without interruption on to the cartilages of the second ribs. Mr. Rivington has found the diarthrodial form of joint in about one-third of the specimens examined by him; Mr. Maisonneuve more frequently. It appears to be rare in childhood, and is formed, in Mr. Rivington's opinion, from the amphiarthrodial form by absorption. The diarthrodial joint seems to have no tendency to ossify at any age, while the amphiarthrodial is very liable to do so, and has been found ossified as early as thirty-four years of age. The two segments are further connected by an

Anterior intersternal ligament, and a
Posterior intersternal ligament.

The **Anterior Intersternal Ligament** consists of a layer of fibres having a longitudinal direction; it blends with the fibres of the anterior chondro-sternal ligaments on both sides, and with the aponeurosis of origin of the Pectoralis major. This ligament is rough, irregular, and much thicker at the lower than at the upper part of the bone.

---

[1] The synovial membrane is sometimes wanting in the sixth and seventh chondro-sternal joints.

The **Posterior Intersternal Ligament** is disposed in a somewhat similar manner on the posterior surface of the articulation.

IX. ARTICULATION OF THE PELVIS WITH THE SPINE.

The ligaments connecting the last lumbar vertebra with the sacrum are similar to those which connect the segments of the spine with each other—viz.: 1, The continuation downward of the anterior and posterior common ligaments; 2, the intervertebral substance connecting the flattened oval surfaces of the two bones and forming an amphiarthrodial joint; 3, ligamenta subflava, connecting the arch of the last lumbar vertebra with the posterior border of the sacral canal; 4, capsular ligaments connecting the articulating processes and forming a double arthrodia; 5, inter- and supra-spinous ligaments.

The two proper ligaments connecting the pelvis with the spine are the lumbo-sacral and ilio-lumbar.

The **Lumbo-sacral Ligament** (sacro-vertebral) (Fig. 247) is a short, thick, triangular fasciculus which is connected above to the lower and front part of the transverse process of the last lumbar vertebra, passes obliquely outward, and is attached below to the lateral surface of the base of the sacrum, becoming blended with the anterior sacro-iliac ligament. This ligament is in relation in front with the Psoas muscle.

FIG. 247.

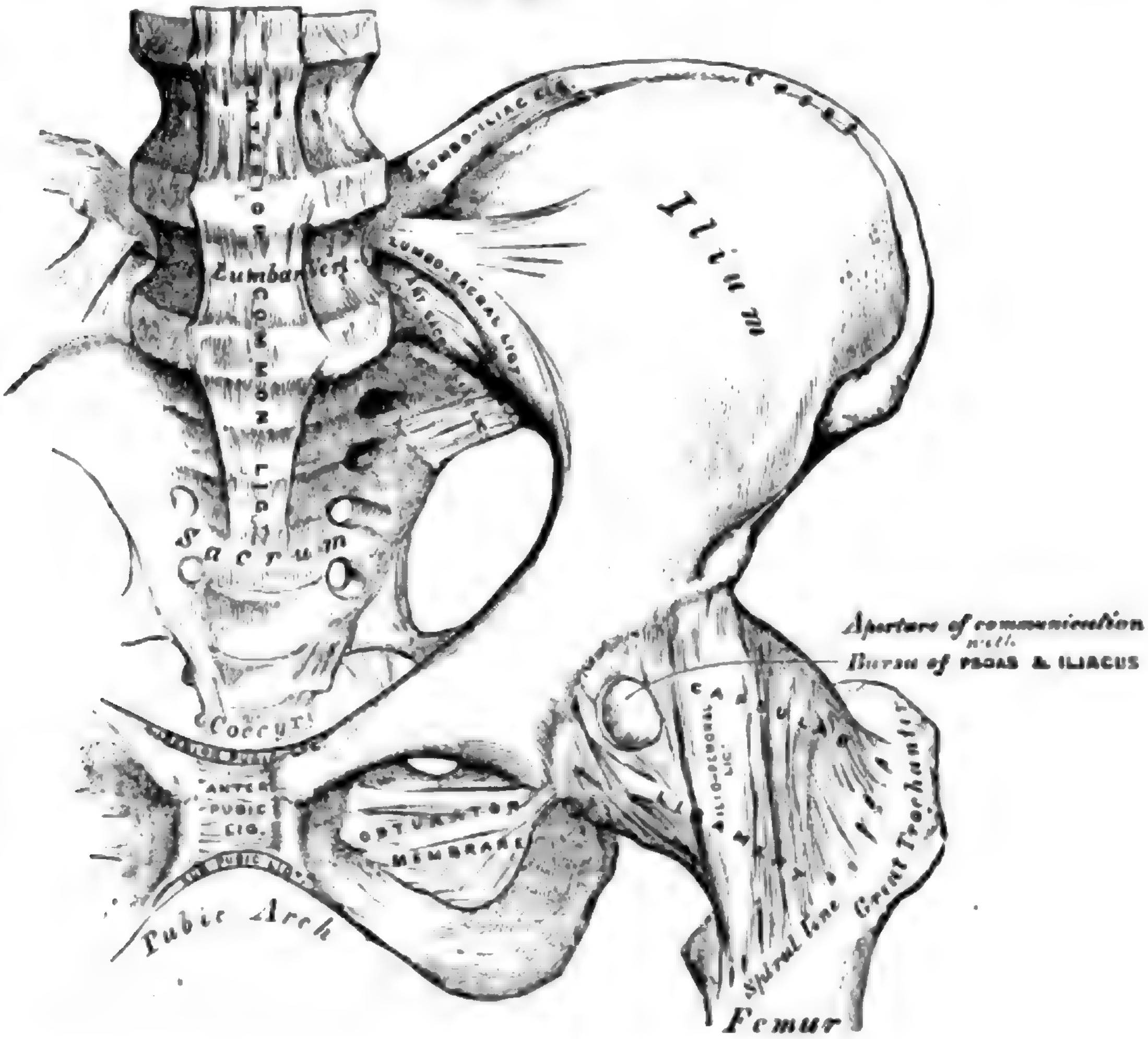
Anterior Common Lig.
Lumbar Vert.
Lumbo-iliac Lig.
Crest
Ilium
Lumbo-sacral Lig.
Ant. Sacro-iliac Lig.
Sacrum
Coccyx
Anter. Pubic Lig.
Sub-pubic Lig.
Obturator Membrane
Pubic Arch
Aperture of communication with Bursa of Psoas & Iliacus
Capsular
Ilio-femoral Lig.
Great Trochanter
Spiral line
Femur

Articulations of Pelvis and Hip, anterior view.

The **Ilio-lumbar Ligament** (Fig. 247) passes horizontally outward from the apex of the transverse process of the last lumbar vertebra to the crest of the ilium immediately in front of the sacro-iliac articulation. It is of a triangular form, thick and narrow internally, broad and thinner externally. It is in relation, in front, with the Psoas muscle; behind, with the muscles occupying the vertebral groove; above, with the Quadratus lumborum.

X. Articulations of the Pelvis.

The ligaments connecting the bones of the pelvis with each other may be divided into four groups: 1, Those connecting the sacrum and ilium; 2, those passing between the sacrum and ischium; 3, those connecting the sacrum and coccyx; 4, those between the two pubic bones.

1. Articulation of the Sacrum and Ilium.

The sacro-iliac articulation is an amphiarthrodial joint formed between the lateral surfaces of the sacrum and ilium. The anterior or auricular portion of each articular surface is covered with a thin plate of cartilage, thicker on the sacrum than on the ilium. The surfaces of these cartilages in the adult are rough and irregular, and separated from one another by a soft yellow pulpy substance. At an early period of life, occasionally in the adult, and in the female during pregnancy, they are smooth and lined by a delicate synovial membrane. The ligaments connecting these surfaces are the anterior and posterior sacro-iliac.

The **Anterior Sacro-iliac Ligament** (Fig. 247) consists of numerous thin ligamentous bands which connect the anterior surfaces of the sacrum and ilium.

The **Posterior Sacro-iliac** (Fig. 248) is a strong interosseous ligament situated in a deep depression between the sacrum and ilium behind, and forming the chief band of connection between those bones. It consists of numerous strong fasciculi which pass between the bones in various directions. Three of these are of large size: the *two superior*, nearly horizontal in direction, arise from the first and second transverse tubercles on the posterior surface of the sacrum, and are inserted into the rough, uneven surface at the posterior part of the inner surface of the ilium. The

Fig 248.

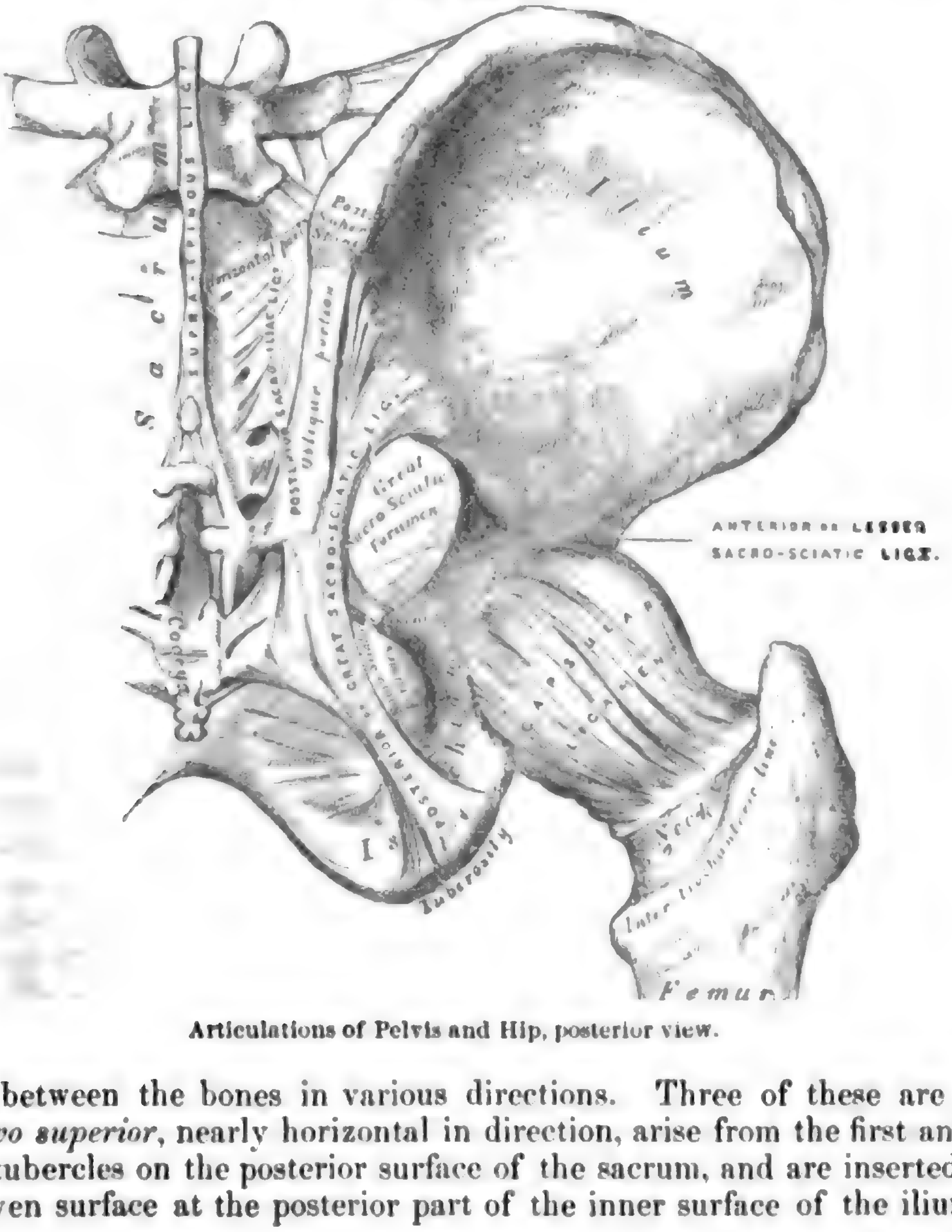
Sacrum
SUPRA-SPINOUS LIG.
Horizontal part
POSTERIOR SACRO-ILIAC LIG.
Oblique portion
Post. Super. Spine
Ilium
Great Sacro Sciatic Foramen
GREAT SACRO-SCIATIC LIG.
POSTERIOR or GREAT SACRO-SCIATIC
ANTERIOR or LESSER SACRO-SCIATIC LIGT.
Coccyx
Capsular Ligament
Is
Tuberosity
Neck
Inter trochanteric line
Femur

Articulations of Pelvis and Hip, posterior view.

third fasciculus, oblique in direction, is attached by one extremity to the third transverse tubercle on the posterior surface of the sacrum, and by the other to the posterior superior spine of the ilium; it is sometimes called the *oblique sacro-iliac ligament.*

2. Ligaments passing between the Sacrum and Ischium (Fig. 248).

The Great Sacro-sciatic (Posterior).
The Lesser Sacro-sciatic (Anterior).

The **Great** or **Posterior Sacro-sciatic Ligament** is situated at the lower and back part of the pelvis. It is thin, flat, and triangular in form; narrower in the middle than at the extremities; attached by its broad base to the posterior inferior spine of the ilium, to the fourth and fifth transverse tubercles on the sacrum, and to the lower part of the lateral margin of that bone and the coccyx; passing obliquely downward, outward, and forward, it becomes narrow and thick, and at its insertion into the inner margin of the tuberosity of the ischium it increases in breadth, and is prolonged forward along the inner margin of the ramus, forming what is known as the *falciform ligament.* The free concave edge of this prolongation has attached to it the obturator fascia, with which it forms a kind of groove, protecting the internal pudic vessels and nerve. One of its surfaces is turned towards the perineum, the other toward the Obturator internus muscle.

The *posterior surface* of this ligament gives origin, by its whole extent, to fibres of the Gluteus maximus. Its *anterior surface* is united to the lesser sacro-sciatic ligament. Its *superior border* forms the lower boundary of the lesser sacro-sciatic foramen. Its *lower border* forms part of the boundary of the perineum. It is pierced by the coccygeal branch of the sciatic artery and coccygeal nerve.

The **Lesser** or **Anterior Sacro-sciatic Ligament**, much shorter and smaller than the preceding, is thin, triangular in form, attached by its apex to the spine of the ischium, and internally, by its broad base, to the lateral margin of the sacrum and coccyx, anterior to the attachment of the great sacro-sciatic ligament, with which its fibres are intermingled.

It is in relation *anteriorly* with the Coccygeus muscle; *posteriorly*, it is covered by the posterior ligament and crossed by the internal pudic vessels and nerve. Its *superior border* forms the lower boundary of the great sacro-sciatic foramen; its *inferior border*, part of the lesser sacro-sciatic foramen.

These two ligaments convert the sacro-sciatic notches into foramina. The *superior* or *great* sacro-sciatic foramen is bounded in front and above by the posterior border of the os innominatum, behind by the great sacro-sciatic ligament, and below by the lesser ligament. It is partially filled up, in the recent state, by the Pyriformis muscle, which passes through it. Above this muscle the gluteal vessels and superior gluteal nerve emerge from the pelvis, and below it the ischiatic vessels and nerves, the internal pudic vessels and nerve, and the muscular branches from the sacral plexus. The *inferior* or *lesser* sacro-sciatic foramen is bounded in front by the tuber ischii, above by the spine and lesser ligament, behind by the greater ligament. It transmits the tendon of the Obturator internus muscle, its nerve, and the internal pudic vessels and nerve.

3. Articulation of the Sacrum and Coccyx.

This articulation is an amphiarthrodial joint formed between the oval surface on the apex of the sacrum and the base of the coccyx. It is analogous to the joints between the bodies of the vertebræ, and is connected by similar ligaments. They are the

Anterior Sacro-coccygeal.
Posterior Sacro-coccygeal.
Lateral Sacro-coccygeal.
Interposed Fibro-cartilage.

The **Anterior Sacro-coccygeal Ligament** consists of a few irregular fibres which descend from the anterior surface of the sacrum to the front of the coccyx, becoming blended with the periosteum.

The **Posterior Sacro-coccygeal Ligament** is a flat band of ligamentous fibres, of a pearly tint, which arises from the margin of the lower orifice of the sacral canal, and descends to be inserted into the posterior surface of the coccyx. This ligament completes the lower and back part of the sacral canal. Its superficial fibres are much longer than the deep-seated. This ligament is in relation, behind, with the Gluteus maximus.

The **Lateral Sacro-coccygeal Ligaments** are ligamentous bands which pass from the cornua of the last sacral vertebra to the cornua of the first piece of the coccyx.

A **fibro-cartilage** is interposed between the contiguous surface of the sacrum and coccyx; it differs from that interposed between the bodies of the vertebræ in being thinner and its central part more firm in texture. It is somewhat thicker in front and behind than at the sides. Occasionally, a synovial membrane is found when the coccyx is freely movable, which is more especially the case during pregnancy.

The different segments of the coccyx are connected together by an extension downward of the anterior and posterior sacro-coccygeal ligaments, a thin annular disk of fibro-cartilage being interposed between each of the bones. In the adult male all the pieces become ossified, but in the female this does not commonly occur until a later period of life. The separate segments of the coccyx are first united, and at a more advanced age the joint between the sacrum and coccyx is obliterated.

ACTIONS.—The movements which take place between the sacrum and coccyx, and between the different pieces of the latter bone, are slightly forward and backward; they are very limited. Their extent increases during pregnancy.

4. ARTICULATION OF THE PUBES (Fig. 249).

The articulation between the pubic bones is an amphiarthrodial joint, formed by the junction of the two oval articular surfaces of the ossa pubis. The articular surface has been described above under the name of *symphysis*, and the same name is given to the joint. The ligaments of this articulation are the

Anterior Pubic. Posterior Pubic.
Superior Pubic. Subpubic.
Interposed Fibro-cartilage.

The **Anterior Pubic Ligament** consists of several superimposed layers which pass across the front of the articulation. The superficial fibres pass obliquely from one bone to the other, decussating and forming an interlacement with the fibres of the aponeurosis of the External oblique muscle. The deep fibres pass transversely across the symphysis and are blended with the fibro-cartilage.

The **Posterior Pubic Ligament** consists of a few thin, scattered fibres which unite the two pubic bones posteriorly.

The **Superior Pubic Ligament** is a band of fibres which connect together the two pubic bones superiorly.

The **Subpubic Ligament** is a thick, triangular arch of ligamentous fibres connecting together the two pubic bones below and forming the upper boundary of the pubic arch. Above it is blended with the interarticular fibro-cartilage, laterally with the rami of the pubes. Its fibres are of a yellowish color, closely connected, and have an arched direction.

The **Interposed Fibro-cartilage** consists of two oval-shaped plates, one covering the surface of each symphysis pubis. They vary in thickness in different subjects, and project somewhat beyond the level of the bones, especially behind. The outer surface of each plate is firmly connected to the bone by a series of nipple-like processes which accurately fit within corresponding depressions on the osseous surface. Their opposed surfaces are connected in the greater part of their extent by an intermediate elastic fibrous tissue, and by their circumference to the various ligaments surrounding the joint. An interspace is left between the plates at the upper and back part of the articulation, where the fibrous tissue is deficient, and the surface of the fibro-cartilage is lined by epithelium. This space is found at all periods of life, both in the male and female; but it is larger in the latter, especially during pregnancy and after parturition. It is most frequently limited to the upper and back part of the joint, but it occasionally reaches to the front, and may extend the entire length of the cartilage. This structure may be easily demonstrated by making a vertical section of the symphysis pubis near its posterior surface.

Fig. 249.

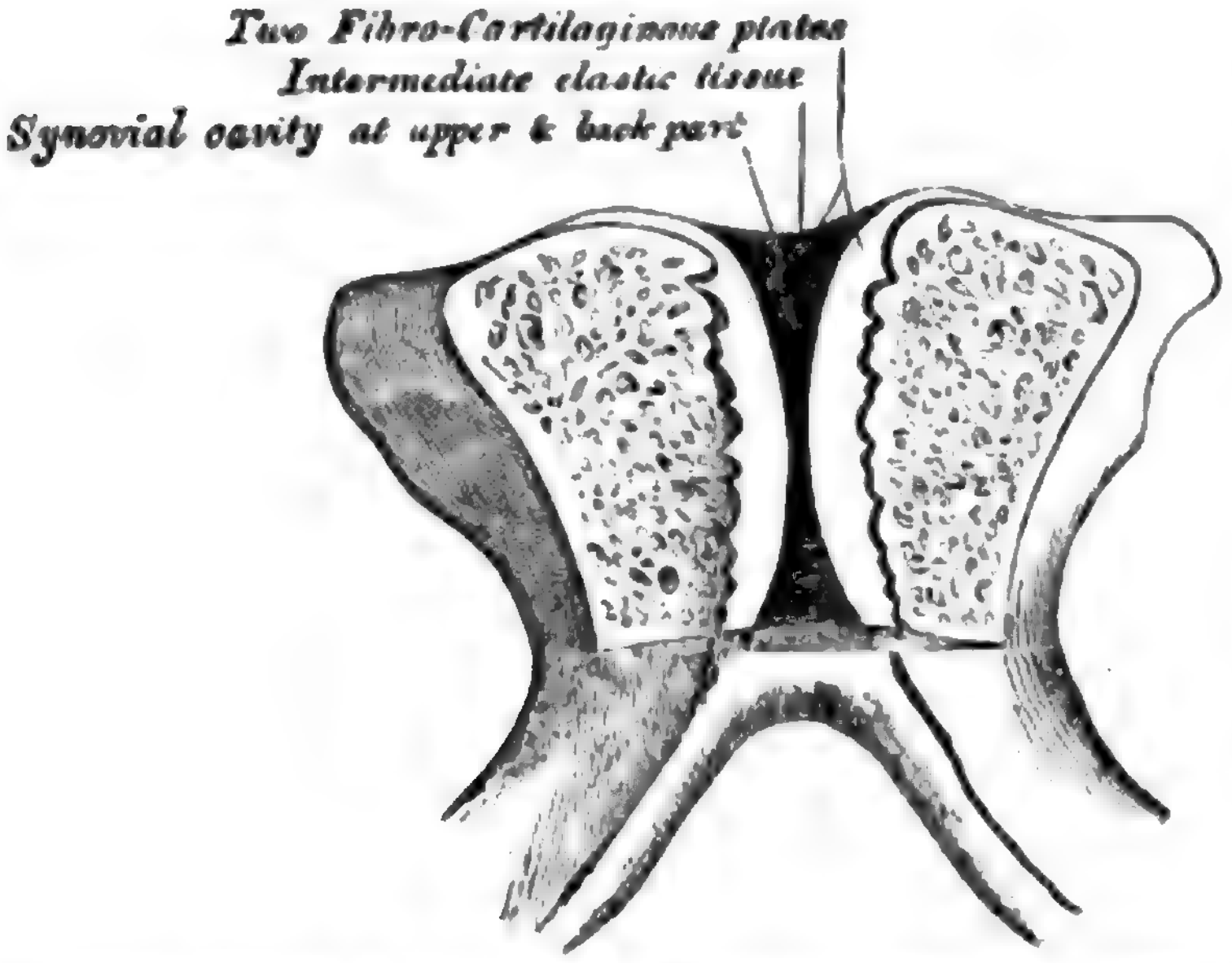
Two Fibro-Cartilaginous plates
Intermediate elastic tissue
Synovial cavity at upper & back part

Vertical Section of the Symphysis Pubis, made near its posterior surface.

The **Obturator Ligament** is more properly regarded as analogous to the muscular fasciæ, with which it will therefore be described.

ARTICULATIONS OF THE UPPER EXTREMITY.

The articulations of the Upper Extremity may be arranged in the following groups: I. Sterno-clavicular articulation. II. Acromio-clavicular articulation. III. Ligaments of the Scapula. IV. Shoulder-joint. V. Elbow-joint. VI. Radio-ulnar articulations. VII. Wrist-joint. VIII. Articulations of the Carpal bones. IX. Carpo-metacarpal articulations. X. Metacarpo-phalangeal articulations. XI. Articulations of the Phalanges.

I. STERNO-CLAVICULAR ARTICULATION (Fig. 250).

The **Sterno-clavicular [Articulation]** is regarded by most anatomists as an arthrodial joint, but Cruveilhier considers it to be an articulation by reciprocal reception. Probably the former opinion is the correct one, the varied movements which the joint enjoys being due to the imposition of an interarticular fibro-cartilage between the joint surfaces. The parts entering into its formation are the sternal end of the clavicle, the upper and lateral part of the first piece of the sternum, and the cartilage of the first rib. The articular surface of the clavicle is much larger than that of the sternum, and invested with a layer of cartilage[1] which is considerably thicker than that on the latter bone. The ligaments of this joint are the

Anterior Sterno-clavicular.	Interclavicular.
Posterior Sterno-clavicular.	Costo-clavicular (rhomboid).

Interarticular Fibro-cartilage.

The **Anterior Sterno-clavicular Ligament** is a broad band of fibres which covers the anterior surface of the articulation, being attached above to the upper and front part of the inner extremity of the clavicle, and, passing obliquely downward and inward, is attached below to the upper and front part of the first piece of the sternum. This ligament is covered in front by the sternal portion of the Sterno-cleido-mastoid and the integument; behind, it is in relation with the interarticular fibro-cartilage and the two synovial membranes.

---

[1] According to Bruch, the sternal end of the clavicle is covered by a tissue which is rather fibrous than cartilaginous in structure.

The **Posterior Sterno-clavicular Ligament** is a similar band of fibres which covers the posterior surface of the articulation, being attached above to the upper and back part of the inner extremity of the clavicle, and which, passing obliquely downward and inward, is attached below to the upper and back part of the sternum. It is in relation in front with the interarticular fibro-cartilage and synovial membranes; behind, with the Sterno-hyoid and Sterno-thyroid muscles.

FIG. 250.

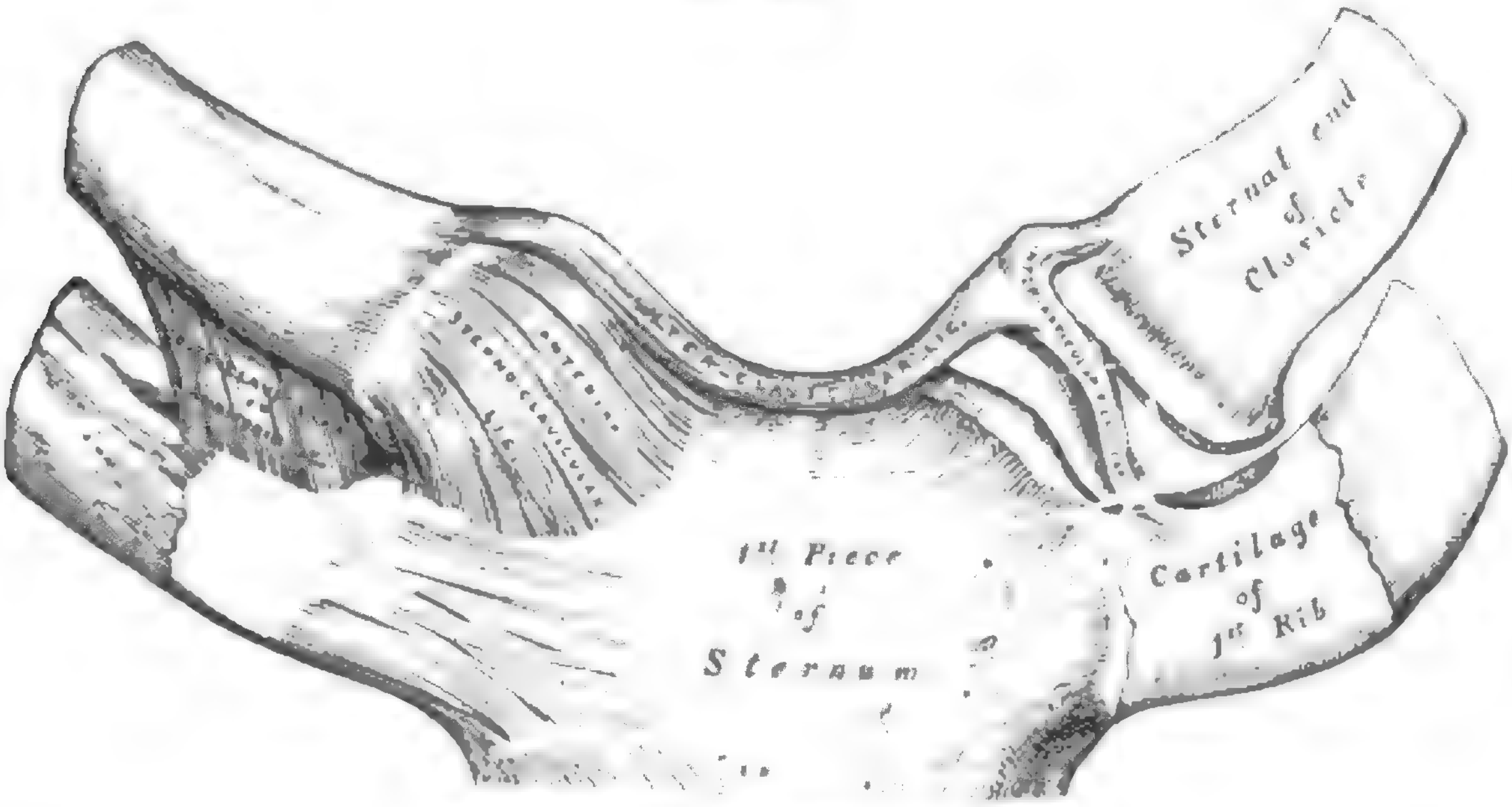

Sterno-clavicular Articulation, anterior view.

The **Interclavicular Ligament** is a flattened band which varies considerably in form and size in different individuals; it passes in a curved direction from the upper part of the inner extremity of one clavicle to the other, and is closely attached to the upper margin of the sternum. It is in relation in front with the integument; behind, with the Sterno-thyroid muscles.

The **Costo-clavicular Ligament** (**rhomboid**) is short, flat, and strong: it is of a rhomboid form, attached below to the upper and inner part of the cartilage of the first rib: it ascends obliquely backward and outward, and is attached above to the rhomboid depression on the under surface of the clavicle. It is in relation in front with the tendon of origin of the Subclavius; behind, with the subclavian vein.

The **Interarticular Fibro-cartilage** is a flat and nearly circular disk interposed between the articulating surfaces of the sternum and clavicle. It is attached above to the upper and posterior border of the clavicle, below to the cartilage of the first rib at its junction with the sternum, and by its circumference to the anterior and posterior sterno-clavicular ligaments. It is thicker at the circumference, especially its upper and back part, than at its centre or below. It divides the joint into two cavities, each of which is furnished with a separate synovial membrane; when the fibro-cartilage is perforated, which not unfrequently occurs, the synovial membranes communicate.

Of the two **synovial membranes** found in this articulation, one is reflected from the sternal end of the clavicle over the adjacent surface of the fibro-cartilage and cartilage of the first rib; the other is placed between the articular surface of the sternum and adjacent surface of the fibro-cartilage; the latter is the more loose of the two. They seldom contain much synovia.

ACTIONS.—This articulation is the centre of the movements of the shoulder, and admits of a limited amount of motion in nearly every direction—upward, downward, backward, forward, as well as circumduction. "The movements attendant on elevation and depression of the shoulder take place between the clavicle and the interarticular ligament, the bone rotating upon the ligament on an axis drawn from before backward through its own articular facet. When the shoulder is moved forward and backward, the clavicle, with the interarticular ligament, rolls to and fro on the articular surface of the sternum, revolving, with a slightly sliding movement, round an axis drawn nearly vertically through the sternum. In the circumduction of the shoulder, which is compounded of these two movements, the clavicle revolves upon the interarticular cartilage, and the latter, with the clavicle, rolls upon the sternum."[1]

II. ACROMIO-CLAVICULAR ARTICULATION (Fig. 251).

The **Acromio-clavicular** is an arthrodial joint formed between the outer extremity of the clavicle and the upper edge of the acromion process of the scapula. Its ligaments are the

Superior Acromio-clavicular.
Inferior Acromio-clavicular.
Coraco-clavicular { Trapezoid and Conoid.
Interarticular Fibro-cartilage.

The **Superior Acromio-clavicular Ligament** is a broad band of a quadrilateral form which covers the superior part of the articulation, extending between the upper part of the outer end of the clavicle and the adjoining part of the upper surface of the acromion. It is composed of parallel fibres which interlace with the aponeurosis of the Trapezius and Deltoid muscles; below it is in contact with the interarticular fibro-cartilage (when it exists) and the synovial membranes.

The **Inferior Acromio-clavicular Ligament,** somewhat thinner than the preceding, covers the under part of the articulation, and is attached to the adjoining surfaces of the two bones. It is in relation above with the interarticular fibro-cartilage (when it exists) and the synovial membranes; below, with the tendon of the Supraspinatus. These two ligaments are continuous with each other in front and behind, and form a complete capsule round the joint.

The **Coraco-clavicular Ligament** serves to connect the clavicle with the coracoid process of the scapula. It does not properly belong to this articulation, but as it forms a most efficient means in retaining the clavicle in contact with the acromial process, it is usually described with it. It consists of two fasciculi, called the trapezoid and conoid ligaments.

The **Trapezoid Ligament,** the anterior and external fasciculus, is broad, thin, and quadrilateral: it is placed obliquely between the coracoid process and the clavicle. It is attached below to the upper surface of the coracoid process; above, to the oblique line on the under surface of the clavicle. Its anterior border is free; its posterior border is joined with the conoid ligament, the two forming by their junction a projecting angle.

The **Conoid Ligament,** the posterior and internal fasciculus, is a dense band of fibres conical in form, the base being turned upward, the summit downward. It is attached by its apex to a rough impression at the base of the coracoid process, internal to the preceding; above, by its expanded base, to the conoid tubercle on the under surface of the clavicle, and to a line proceeding internally from it for half an inch. These ligaments are in relation in front with the Subclavius; behind, with the Trapezius: they serve to limit rotation of the scapula forward and backward.

The **Interarticular Fibro-cartilage** is most frequently absent in this articulation. When it exists it generally only partially separates the articular surfaces and occupies the upper part of the articulation. More rarely it completely separates the joint into two cavities.

---

[1] Humphry, *On the Human Skeleton*, p. 402.

There are *two* **synovial membranes** when a complete interarticular cartilage exists; more frequently there is only one synovial membrane.

ACTIONS.—The movements of this articulation are of two kinds: 1, A gliding motion of the articular end of the clavicle on the acromion; 2, rotation of the scapula forward and backward upon the clavicle, the extent of this rotation being limited by the two portions of the coraco-clavicular ligament.

FIG. 251.

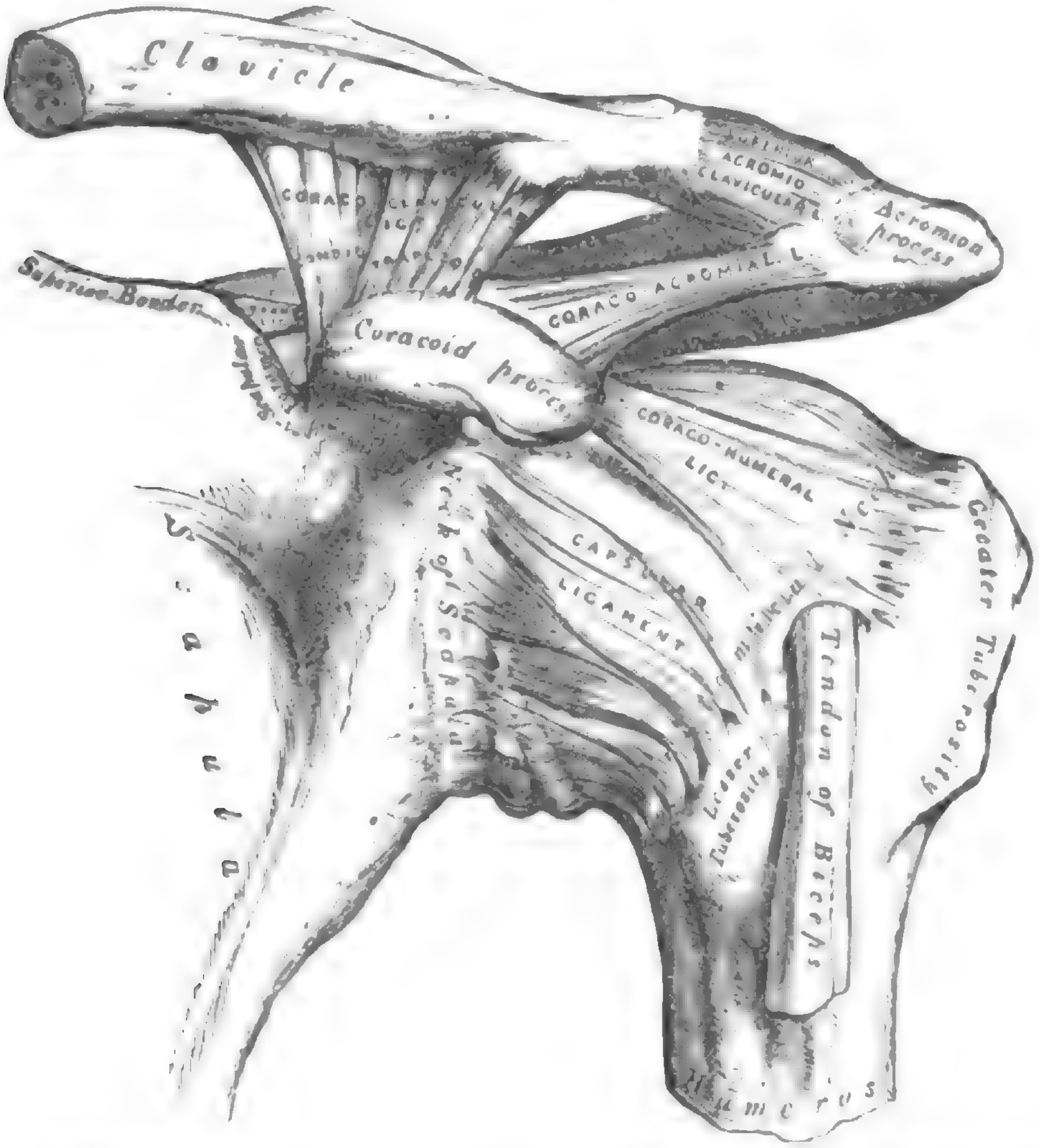
Clavicle
Superior Acromio Clavicular L.
Acromion process
Coraco Clavicular Lig.
Conoid
Trapezoid
Superior Border
Coraco Acromial L.
Coracoid process
Coraco-Humeral Lig.
Capsular Ligament
Neck of Scapula
Scapula
Greater Tuberosity
Tendon of Biceps
Lesser Tuberosity
Humerus

The Left Shoulder-joint: Scapulo-clavicular Articulations and Proper Ligaments of Scapula.

The scapulo-clavicular joint has important functions in the movements of the upper extremity. It has been well pointed out by Prof. Humphry that if there had been no joint between the clavicle and scapula the circular movement of the scapula on the ribs (as in throwing both shoulders backward or forward) would have been attended with a greater alteration in the direction of the shoulder than is consistent with the free use of the arm in such positions, and it would have been impossible to give a blow straight forward with the full force of the arm—that is to say, with the combined force of the scapula, arm, and forearm. "This joint," as he happily says, "is so adjusted as to enable either bone to turn in a hinge-like manner upon a vertical axis drawn through the other, and it permits the surfaces of the scapula, like the baskets in a roundabout swing, to look the same way in every position, or nearly so." Again, when the whole arch formed by the clavicle and scapula rises and falls (in elevation or depression of the shoulders) the joint between these two bones enables the scapula still to maintain its lower part in contact with the ribs.

III. PROPER LIGAMENTS OF THE SCAPULA (Fig. 251).

The proper ligaments of the scapula are the

Coraco-acromial. Transverse.

The **Coraco-acromial Ligament** is a broad, thin, flat band of a triangular shape extended transversely above the upper part of the shoulder-joint, between the coracoid and acromial processes. It is attached by its apex to the summit of the acromion just in front of the articular surface for the clavicle; and by its broad base to the whole length of the outer border of the coracoid process. Its posterior fibres are directed obliquely backward and inward, its anterior fibres transversely inward.* This ligament completes the vault formed by the coracoid and acromion processes for the protection of the head of the humerus. It is in relation above with the clavicle and under surface of the Deltoid; below, with the tendon of the Supraspinatus muscle, a bursa being interposed. Its anterior border is continuous with a dense cellular lamina that passes beneath the Deltoid upon the tendons of the Supra- and Infra-spinatus muscles.

The **Transverse** or **Coracoid** (*suprascapular*) **Ligament** converts the suprascapular notch into a foramen. It is a thin and flat fasciculus, narrower at the middle than at the extremities, attached by one end to the base of the coracoid process, and by the other to the inner extremity of the scapular notch. The suprascapular nerve passes through the foramen; the suprascapular vessels above it. [It is sometimes wholly ossified.]

IV. SHOULDER-JOINT (Fig. 251).

The **Shoulder** is an enarthrodial or ball-and-socket joint. The bones entering into its formation are the large globular head of the humerus, received into the shallow glenoid cavity of the scapula—an arrangement which permits of very considerable movement, whilst the joint itself is protected against displacement by the tendons which surround it and by atmospheric pressure. The ligaments have nothing directly to do with maintaining the joint surfaces in apposition; if they alone remain, the humerus can be separated to a considerable extent from the glenoid cavity: their use, therefore, is to limit the amount of movement. [This separation of the humerus from the glenoid cavity is at its maximum when the humerus is halfway between *ab*- and *ad*-duction, and diminishes as we approach either extreme. In extreme *ab*- or *ad*-duction the lower or upper fibres of the capsular ligament respectively are made tense and hold the bones together.] Above, the joint is protected by an arched vault formed by the under surface of the coracoid and acromion processes and the coraco-acromial ligament. The articular surfaces are covered by a layer of cartilage: that on the head of the humerus is thicker at the centre than at the circumference, the reverse being the case in the glenoid cavity. The ligaments of the shoulder are the

Capsular. Coraco-humeral.
Glenoid.[1]

The **Capsular Ligament** completely encircles the articulation, being attached above to the circumference of the glenoid cavity beyond the glenoid ligament, below to the anatomical neck of the humerus, approaching nearer to the articular cartilage above than in the rest of its extent. It is thicker above than below, remarkably loose and lax, and much larger and longer than is necessary to keep the bones in contact, allowing them to be separated from each other more than an inch—an evident provision for that extreme freedom of movement which is peculiar to this articulation. Its external surface is strengthened above by the Supraspinatus, below by the long head of the Triceps, externally by the tendons of the Infraspinatus and Teres minor, and internally by the tendon of the Subscapularis. The capsular ligament usually presents three openings: one at its inner side, below the coracoid process, partially filled up by the tendon of the Subscapularis; it establishes a communication between the synovial membrane of the joint and a bursa beneath the tendon of that muscle. The second, which is not constant, is at the outer part, where a communication sometimes exists between the joint and a bursal sac belonging to the Infraspinatus muscle. The third is seen in the lower border of the ligament, between the two tuberosities, for the passage of the long tendon of the Biceps muscle.

---

[1] The long tendon of origin of the Biceps muscle also acts as one of the ligaments of this joint. See the observations on p. 301 on the function of the muscles passing over more than one joint.

The capsular ligament is strengthened by supplemental bands in addition to the Coraco-humeral or accessory ligament, which is usually described as a distinct structure. Some of these are situated on the inner side of the joint, and pass from the inner edge of the glenoid cavity to the lower part of the lesser tubercle of the humerus. Others are situated at the lower part of the joint, and pass from the under edge of the glenoid cavity to the under part of the neck of the humerus.

The **Coraco-humeral** or **Accessory Ligament** is a broad band which strengthens the upper part of the capsular ligament. It arises from the outer border of the coracoid process, and passes obliquely downward and outward to the front of the great tuberosity of the humerus, being blended with the tendon of the Supraspinatus muscle. This ligament is intimately united to the capsular in the greater part of its extent. Some of the fibres of this ligament are prolonged into the joint through the opening in the capsular ligament for the tendon of the Biceps, and are inserted into the inner margin of the upper end of the bicipital groove. They have been called the *gleno-humeral* (Flood's) ligament, and are supposed to correspond with the ligamentum teres in the hip-joint.

The **Glenoid Ligament** is a fibro-cartilaginous rim attached round the margin of the glenoid cavity. It is triangular on section, the thickest portion being fixed to the circumference of the cavity, the free edge being thin and sharp. It is continuous above with the long tendon of the Biceps muscle, which bifurcates at the upper part of the cavity into two fasciculi encircling the margin of the glenoid cavity and uniting at its lower part. This ligament deepens the cavity for articulation and protects the edges of the bone. It is lined by the synovial membrane.

The **synovial membrane** is reflected from the margin of the glenoid cavity over the fibro-cartilaginous rim surrounding it; it is then reflected over the internal surface of the capsular ligament, covers the lower part and sides of the neck of the humerus, and is continued a short distance over the cartilage covering the head of the bone. The long tendon of the Biceps muscle which passes through the capsular ligament is enclosed in a tubular sheath of synovial membrane, which is reflected

[Fig. 252.

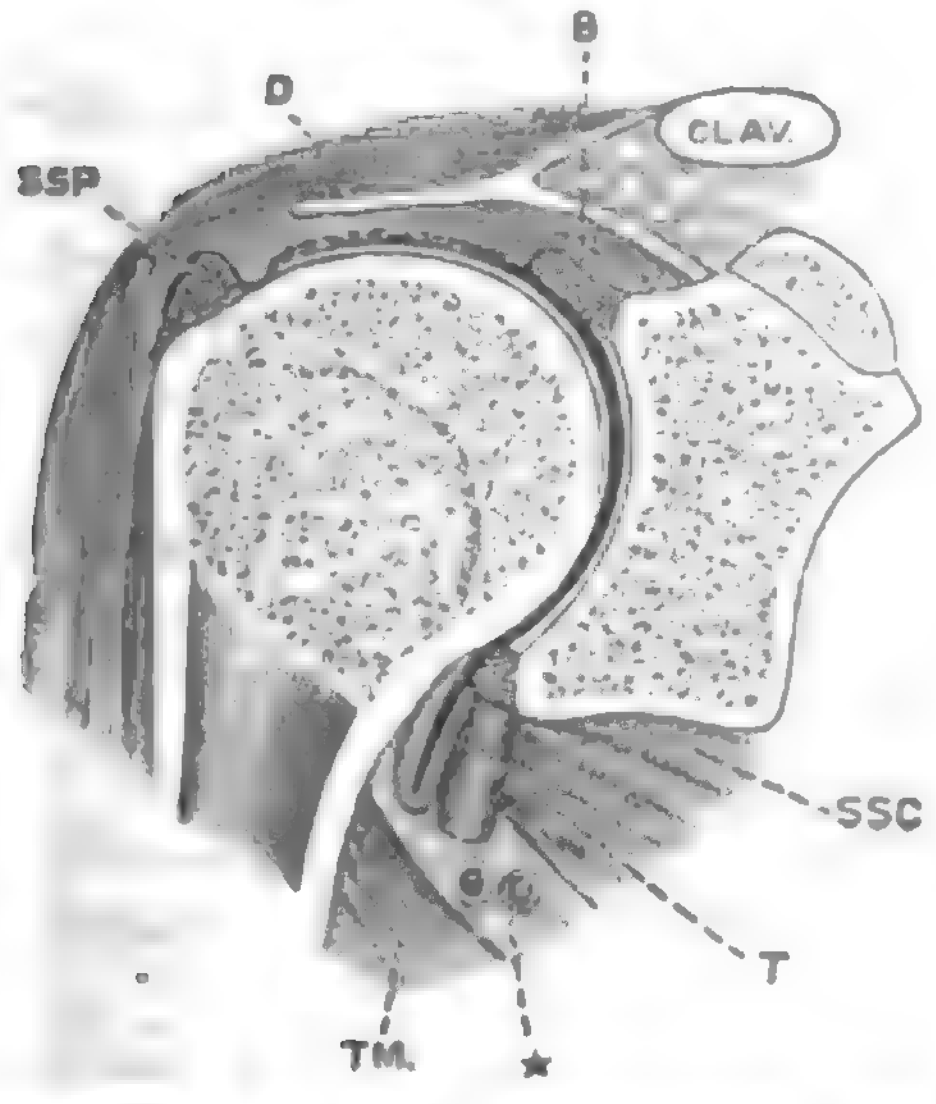

[Fig. 253.

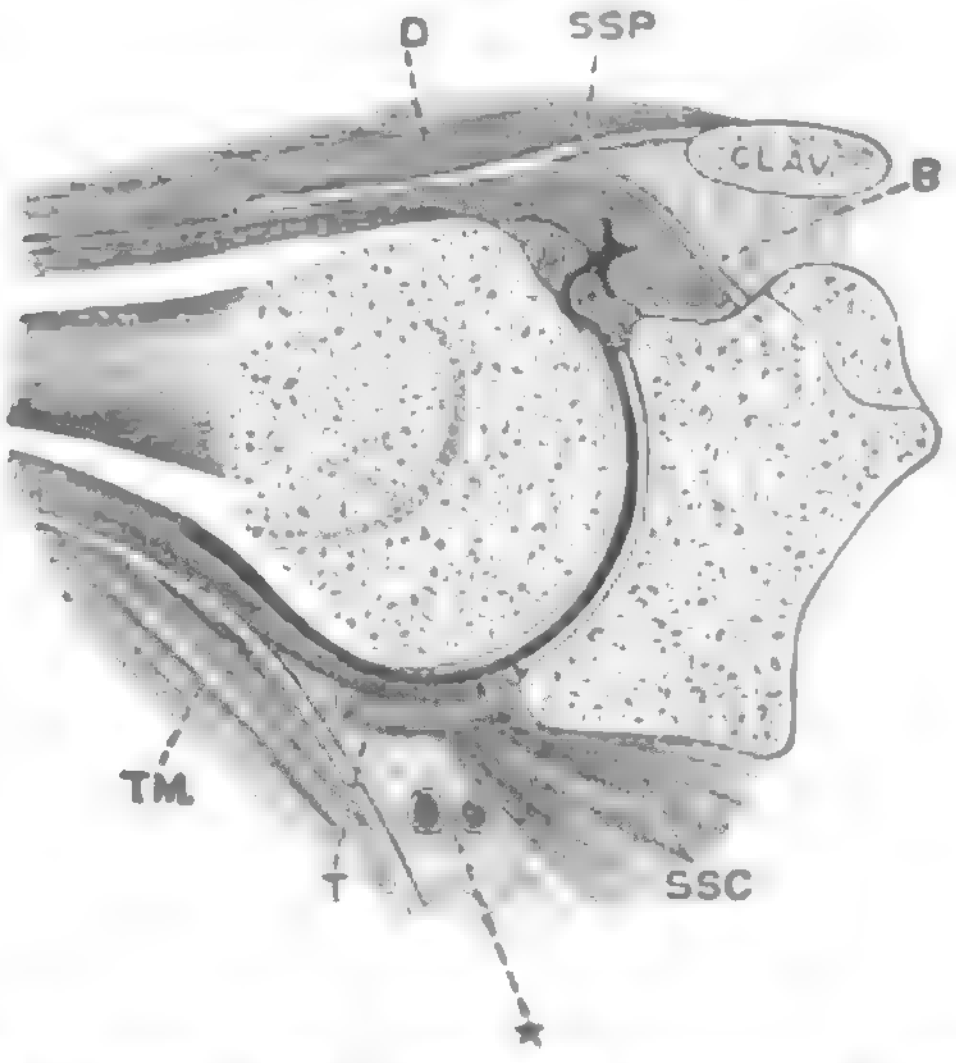

Vertical Sections through the Shoulder-joint, the arm being vertical (Fig. 252) and horizontal (Fig. 253): SSP, tendon of supraspinatus; D, deltoid; B, tendon of long head of biceps; SSC, subscapularis; T, tendon of long head of triceps; *, posterior circumflex artery and circumflex nerve; TM, teres major (Henle).]

upon it at the point where it perforates the capsule, and is continued around it as far as the summit of the glenoid cavity. The tendon of the Biceps is thus enabled to traverse the articulation, but it is not contained in the interior of the synovial cavity. The synovial membrane communicates with a large bursal sac beneath the tendon of the Subscapularis by an opening at the inner side of the capsular ligament; it also occasionally communicates with another bursal sac beneath the tendon of the Infraspinatus through an orifice at its outer part. A third bursal sac, which does not communicate with the joint, is placed between the under surface of the Deltoid and the outer surface of the capsule.

The *Muscles* in relation with the joint are—above, the Supraspinatus; below, the long head of the Triceps; internally, the Subscapularis; externally, the Infraspinatus and Teres minor; within, the long tendon of the Biceps. The Deltoid is placed most externally, and covers the articulation on its outer side as well as in front and behind.

The *Arteries* supplying the joint are articular branches of the anterior and posterior circumflex and suprascapular.

The *Nerves* are derived from the circumflex and suprascapular.

Actions.—The shoulder-joint is capable of movement in every direction, forward, backward, abduction, adduction, circumduction, and rotation. The humerus is drawn *forward* by the Pectoralis major, anterior fibres of the Deltoid, Coraco-brachialis, and by the Biceps when the elbow is fixed; *backward*, by the Latissimus dorsi, Teres major, posterior fibres of the Deltoid, and by the Triceps when the elbow is fixed; it is *abducted* (elevated) by the Deltoid and Supraspinatus; it is *adducted* (depressed) by the Subscapularis, Pectoralis major, Latissimus dorsi, and Teres major; it is *rotated outward* by the Infraspinatus and Teres minor; and it is *rotated inward* by the Subscapularis, Latissimus dorsi, and Teres major.

The most striking peculiarities in this joint are—1, The large size of the head of the humerus in comparison with the depth of the glenoid cavity, even when supplemented by the glenoid ligament; 2, the looseness of the capsule of the joint; 3, the intimate connection of the capsule with the muscles attached to the head of the humerus; 4, the peculiar relation of the biceps tendon to the joint.

It is in consequence of the relative size of the two articular surfaces that the joint enjoys such free movement in every possible direction. When these movements of the arm are arrested in the shoulder-joint by the contact of the bony surfaces and by the tension of the corresponding fibres of the capsule, together with that of the muscles acting as accessory ligaments, they can be carried considerably farther by the movements of the scapula, involving, of course, motion at the acromio- and sterno-clavicular joints. These joints are therefore to be regarded as accessory structures to the shoulder-joint.[1] The extent of these movements of the scapula is very considerable, especially in extreme elevation of the arm; which movement is best accomplished when the arm is thrown somewhat forward, since the articular surface of the humerus is broader in the middle than at either end, especially the lower, so that the range of elevation directly forward is less, and that directly backward still more restricted. The great width of the central portion of the humeral head also allows of very free horizontal movement when the arm is raised to a right angle; in which movement the arch formed by the acromion, the coracoid process, and the coraco-acromial ligament constitutes a sort of supplemental articular cavity for the head of the bone.

The looseness of the capsule is so great that the arm will fall about an inch from the scapula when the muscles are dissected from the capsular ligament and an opening made in it to remove the atmospheric pressure. The movements of the joint, therefore, are not regulated by the capsule so much as by the surrounding muscles and by the pressure of the atmosphere—an arrangement which "renders the movements of the joint much more easy than they would otherwise have been, and permits a swinging, pendulum-like vibration of the limb when the muscles are at rest" (Humphry). The fact also that in all ordinary positions of the joint the capsule is not put on the stretch enables the arm to move freely in all directions. Extreme movements are checked by the tension of appropriate portions of the capsule, as well as by the interlocking of the bones. Thus it is said that "abduction is checked by the contact of the great tuberosity with the upper edge of the glenoid cavity; adduction, by the tension of the coraco-humeral ligaments" (Beaunis et Bouchard).

---

[1] See pp. 322, 324.

[Nothing is more striking in the anatomy of the back, when studied in the living model, than this mobility of the scapula and its influence on the form of the trunk. Shrugging one shoulder shows, by comparison, the vertical movement; when the arm is raised to about thirty degrees the scapula already begins to take part in the movement, and by the time the arms are well thrown forward or upward the distance between the two inferior angles has been increased by as much as ten or twelve inches, the inferior angles being displaced to the sides of the thorax, and the direction of the vertebral borders and the spine of the scapula is entirely changed, while the back, which formerly showed the rugged outlines of the scapula and its muscles, is flattened and almost smooth; leaning the weight on one arm or on a crutch shows its passive mobility by pressure and the disparity of the two sides to great advantage. In Michael Angelo's statues on Julian de Medici's tomb in Florence, Sir Charles Bell has noticed the correctness of the anatomy on this point. Mr. Wagstaffe (*Human Osteology*) has called attention to the great advantage that this mobility of the scapula gives in increasing the usefulness of the arm by its acting as a "shifting fulcrum," and well compares this to the advantage given the modern oarsman by the "sliding seat."

The mobility of the scapula is of the greatest use in ankylosis of the shoulder-joint, diminishing to a large extent the loss of usefulness resulting from the immobility. Whenever there is unequal prominence of the scapulæ the spine should be examined for curvature.]

The intimate union of the tendons of the four short muscles with the capsule converts these muscles into elastic and spontaneously acting ligaments of the joint, and it is regarded as being also intended to prevent the folds into which all portions of the capsule would alternately fall in the varying positions of the joint from being driven between the bones by the pressure of the atmosphere.

The peculiar relations of the Biceps tendon to the shoulder-joint appear to subserve various purposes. In the first place, by its connection with both the shoulder and elbow the muscle harmonizes the action of the two joints and acts as an elastic ligament in all positions, in the manner previously adverted to.[1] Next it strengthens the upper part of the articular cavity, and prevents the head of the humerus from being pressed up against the acromion process when the deltoid contracts, instead of forming the centre of motion in the glenoid cavity. By its passage along the bicipital groove it assists in rendering the head of the humerus steady in the various movements of the arm and forearm. To these offices Prof. Humphry adds that "it assists the Supra- and Infra-spinatus muscles to cause the head of the humerus to revolve in the glenoid cavity when the arm is raised from the side, and that it holds the head of the humerus firmly in contact with the glenoid cavity, and prevents its slipping over the lower edge of the cavity, or being displaced by the action of the Latissimus dorsi and Pectoralis major when the arm is raised from the side, as in climbing and many other movements."

V. ELBOW-JOINT.

The **Elbow** is a *ginglymus* or hinge-joint. The bones entering into its formation are the trochlear surface of the humerus, which is received in the greater sigmoid cavity of the ulna, and admits of the movements peculiar to this joint, those of flexion and extension, whilst the cup-shaped depression on the head of the radius articulates with the lesser or radial head of the humerus, and the circumference of the head of the radius with the lesser sigmoid cavity of the ulna, allowing of the movement of rotation of the radius on the ulna, the chief action of the superior radio-ulnar articulation. [For the angle formed at the elbow between the arm and forearm, see p. 242.] The articular surfaces are covered with a thin layer of cartilage and connected together by the following ligaments:

---

[1] See p. 301.

Anterior.	Internal Lateral.
Posterior.	External Lateral.

The orbicular ligament of the upper radio-ulnar articulation must also be reckoned among the ligaments of the elbow.

FIG. 254.

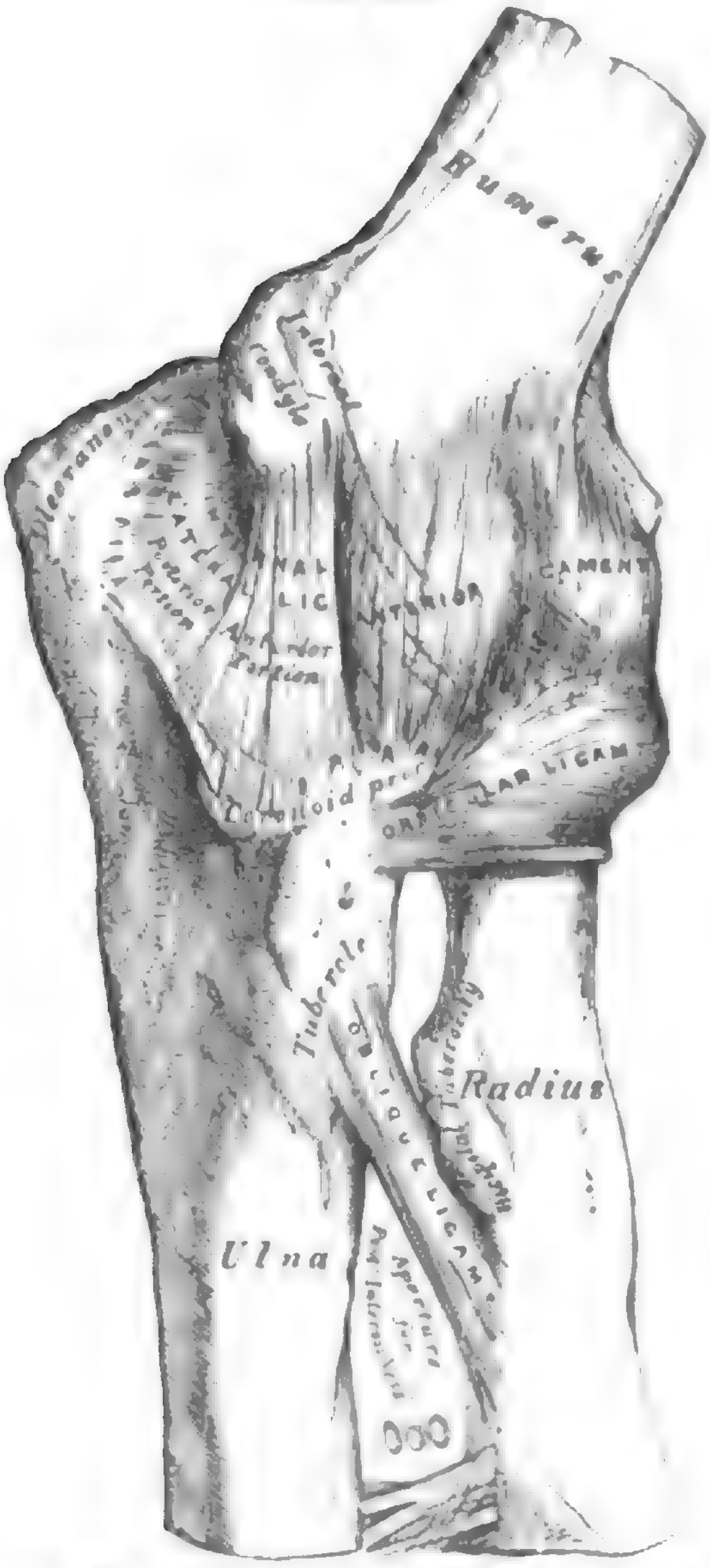

Left Elbow-joint, showing anterior and internal ligaments.

The **Anterior Ligament** (Fig. 254) is a broad and thin fibrous layer which covers the anterior surface of the joint. It is attached to the front of the internal condyle and to the front of the humerus immediately above the coronoid fossa; below, to the anterior surface of the coronoid process of the ulna and orbicular ligament, being continuous on each side with the lateral ligaments. Its superficial oblique fibres pass from the inner condyle of the humerus outward to the orbicular ligament. The middle fibres, vertical in direction, pass from the upper part of the coronoid depression, and become partly blended with the preceding, but mainly inserted into the anterior surface of the coronoid process. A third or transverse set intersects these at right angles. This ligament is in relation in front with the Brachialis anticus; behind with the synovial membrane.

The **Posterior Ligament** (Fig. 255) is a thin and loose membranous fold attached above to the lower end of the humerus, immediately above the olecranon fossa; below to the margin of the olecranon. The superficial or transverse fibres pass between the adjacent margins of the olecranon fossa. The deeper portion consists of vertical fibres which pass from the upper part of the olecranon fossa to the margin of the olecranon. This ligament is in relation behind with the tendon of the Triceps and the Anconeus; in front with the synovial membrane.

The **Internal Lateral Ligament** (Fig. 254) is a thick triangular band consisting of two distinct portions, an anterior and a posterior. The *anterior portion*, directed obliquely forward, is attached above, by its apex, to the front part of the internal condyle of the humerus, and below, by its broad base, to the inner margin of the coronoid process. The *posterior portion*, also of triangular form, is attached above, by its apex, to the lower and back part of the internal condyle; below to the inner margin of the olecranon. This ligament is in relation internally with the Triceps and Flexor carpi ulnaris muscles and the ulnar nerve.

The **External Lateral Ligament** (Fig. 255) is a short and narrow fibrous fasciculus less distinct than the internal, attached above to a depression below the external condyle of the humerus; below to the orbicular ligament, some of its most posterior fibres passing over that ligament to be inserted into the outer margin of the ulna. This ligament is intimately blended with the tendon of origin of the Supinator brevis muscle.

The **synovial membrane** is very extensive. It covers the margin of the articular surface of the humerus and lines the coronoid and olecranon fossæ on that bone; from these points it is reflected over the anterior, posterior, and lateral ligaments, and forms a pouch between the lesser sigmoid cavity, the internal surface of the orbicular ligament, and the circumference of the head of the radius.

Fig. 255.

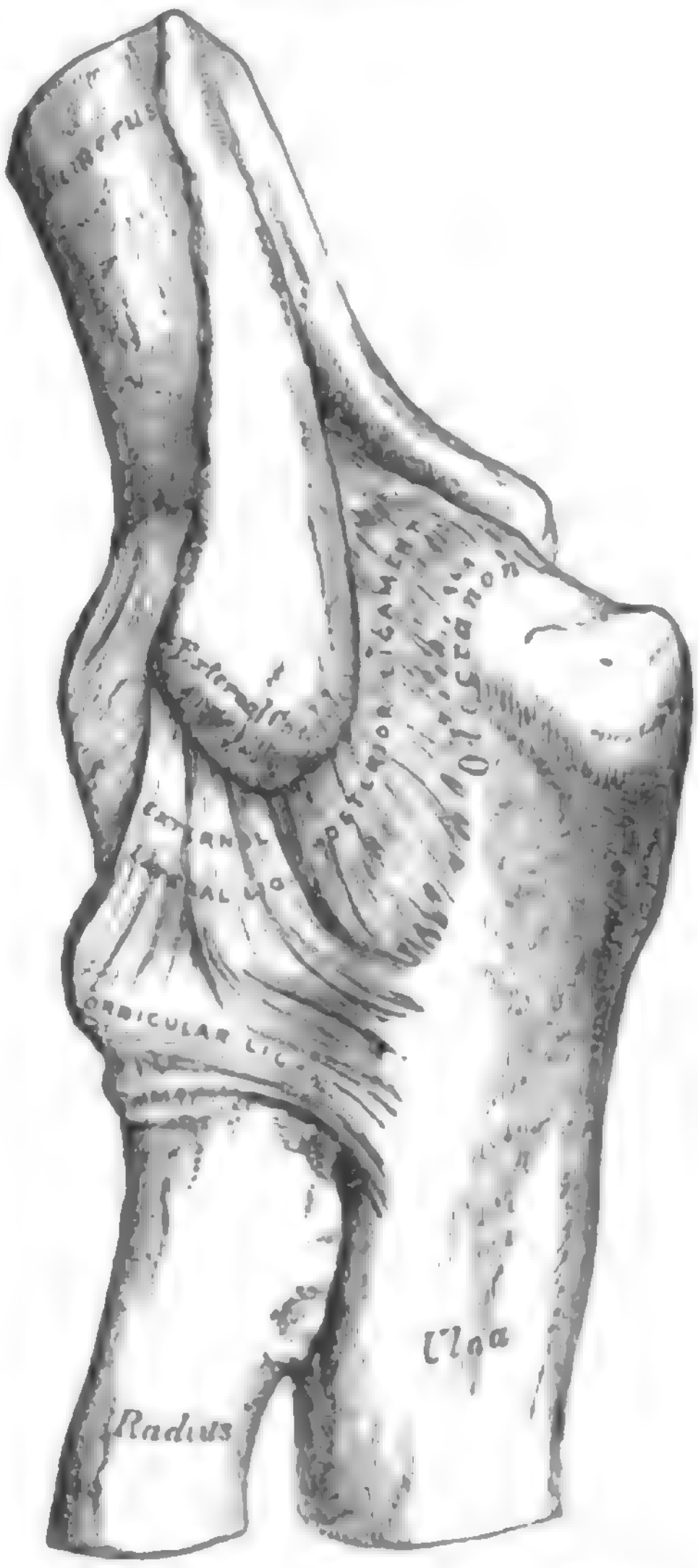

Left Elbow-joint, showing posterior and external ligaments.

The *Muscles* in relation with the joint are—in front, the Brachialis anticus; behind, the Triceps and Anconeus; externally, the Supinator brevis and the common tendon of origin of the Extensor muscles; internally, the common tendon of origin of the Flexor muscles and the Flexor carpi ulnaris with the ulnar nerve.

The *Arteries* supplying the joint are derived from the communicating branches between the superior profunda, inferior profunda, and anastomotic branches of the brachial with the anterior, posterior, and interosseous recurrent branches of the ulnar and the recurrent branch of the radial. These vessels form a complete chain of inosculation around the joint.

The *Nerves* are derived from the ulnar as it passes between the internal condyle and the olecranon, and a few filaments from the musculo-cutaneous.

[Fig. 256.

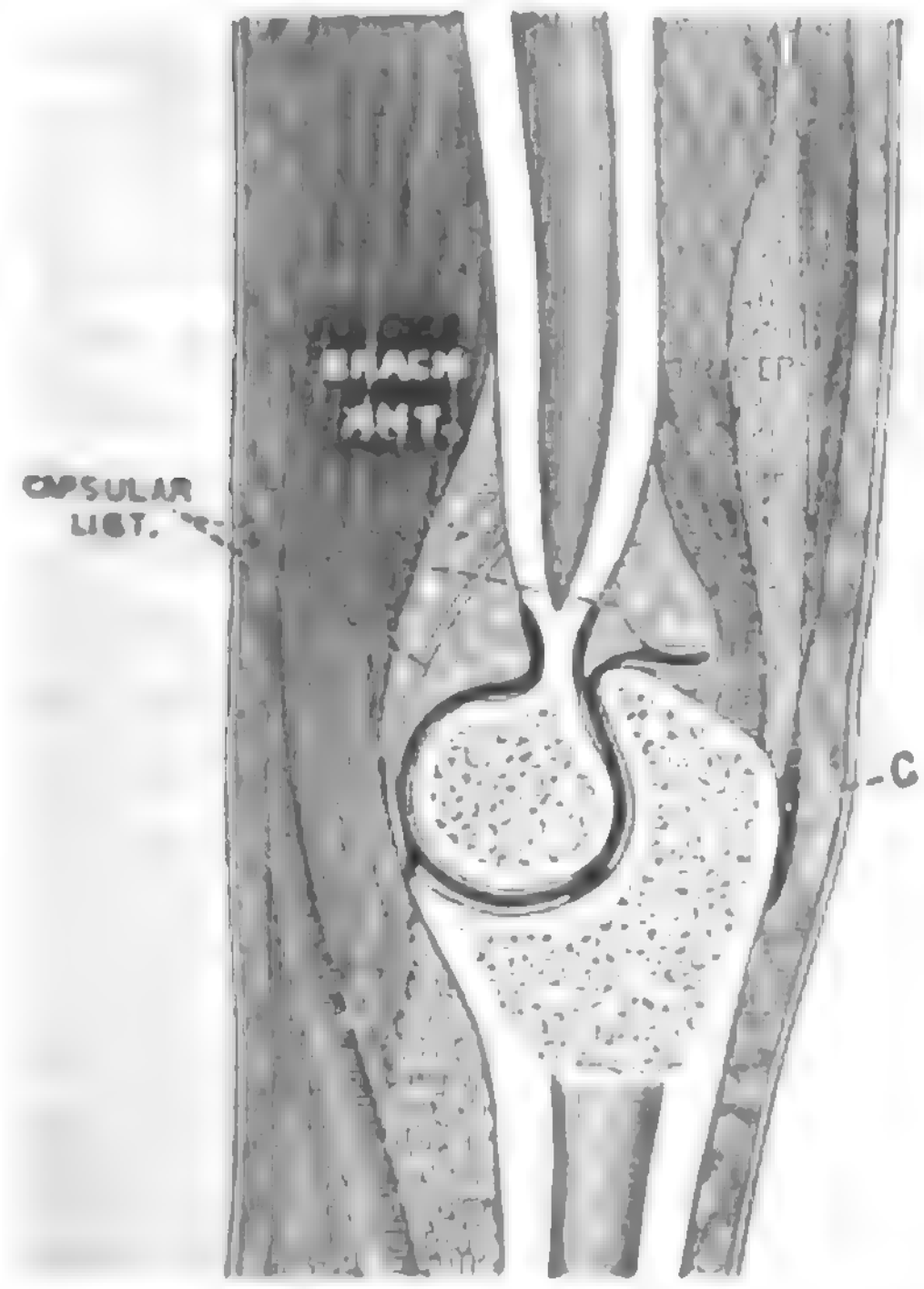

[Fig. 257.

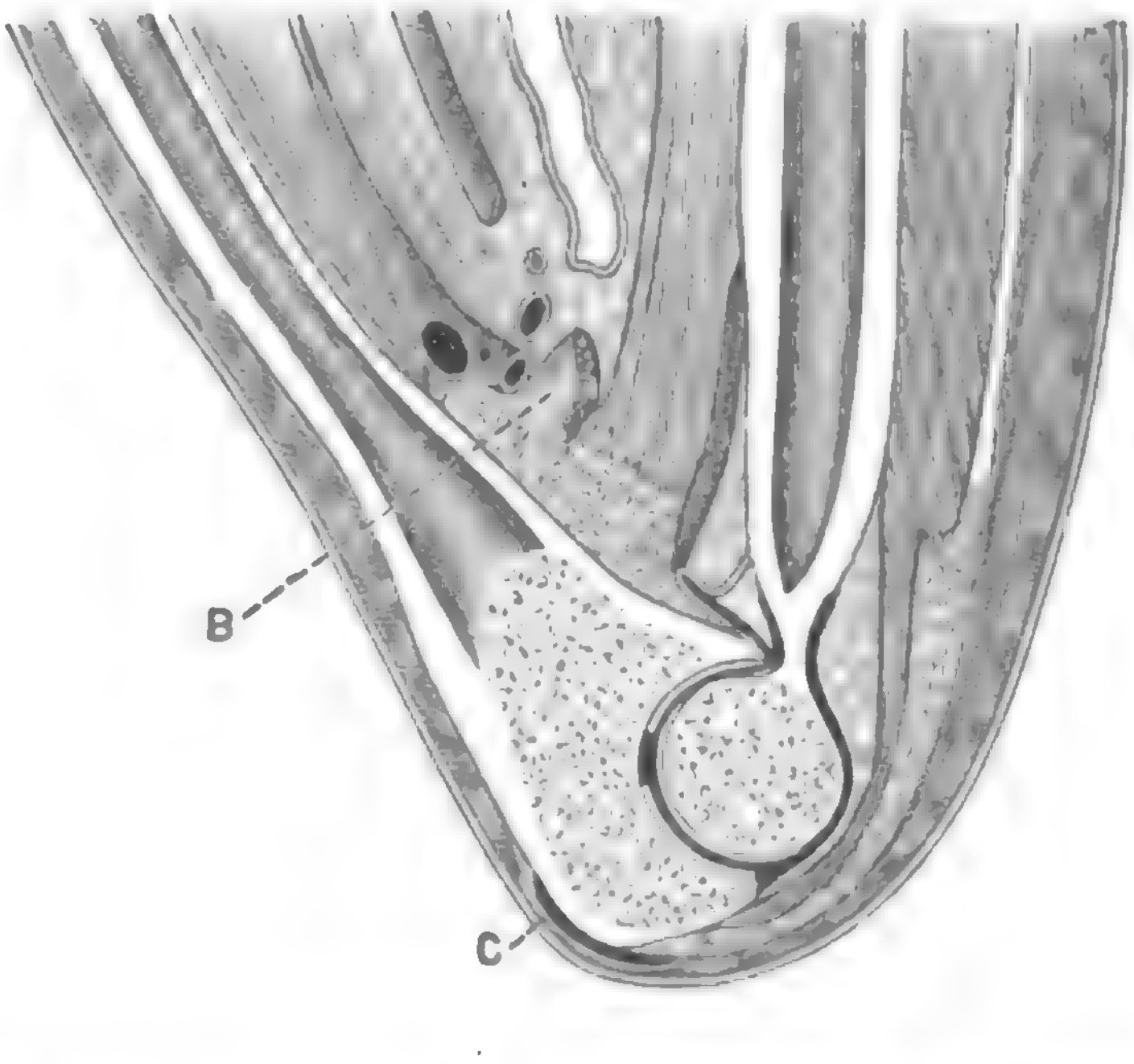

Sections through the Elbow-joint in extension (Fig. 256) and flexion (Fig. 257): B, tendon of biceps; C, synovial bursa over olecranon (Henle).]

Actions.—The elbow-joint comprises three different portions—viz. the joint between the ulna and humerus, that between the head of the radius and the humerus, and the superior radio-ulnar articulation, described below. All these articular surfaces are invested by a common synovial membrane, and the movements of the whole joint should be studied together. The combination of the movements of flexion and extension of the forearm with those of pronation and supination of the hand, which is ensured by the two being performed at the same joint, is essential to the accuracy of the various minute movements of the hand.

The portion of the joint between the ulna and humerus is a simple hinge-joint, and allows of movements of flexion and extension only. The shape of the trochlear surface of the humerus, with its prominences and depressions accurately adapted to the opposing surfaces of the olecranon, prevents any lateral movement. In the ordinary position assumed by the humerus when resting on the prominent internal condyle this direct movement of flexion carries the hand inward toward the chest and mouth. *Flexion* is produced by the action of the Biceps and Brachialis anticus, assisted by the muscles arising from the internal condyle of the humerus and the Supinator longus; *extension*, by the Triceps and Anconeus, assisted by the extensors of the wrist and by the Extensor communis digitorum and Extensor minimi digiti.

The joint between the head of the radius and the capitellum or radial head of the humerus is an arthrodial joint. The bony surfaces would of themselves constitute an enarthrosis, and allow of movement in all directions, were it not for the orbicular ligament by which the head of the radius is bound down firmly to the sigmoid cavity of the ulna, and which prevents any separation of the two bones laterally. It is to the same ligament that the head of the radius owes its security from dislocation, which would otherwise constantly occur as a consequence of the shallowness of the cup-like surface on the head of the radius. In fact, but for this ligament the tendon of the biceps would be liable to pull the head of the radius out of the joint.[1] In complete extension the head of the radius glides so far back on the outer condyle that its edge is plainly felt at the back of the joint.

In combination with any position of flexion or extension the head of the radius can be rotated in the upper radio-ulnar joint, carrying the hand with it. The hand is articulated to the lower surface of the radius only, and the concave or sigmoid surface on the lower end of the radius travels round the lower end of the ulna. The latter bone is excluded from the wrist-joint (as will be seen in the sequel) by the triangular fibro-cartilage. Thus, rotation of the head of the radius round an axis which passes through the external condyle of the humerus imparts circular movement to the hand through a very considerable arc. If it is necessary to turn the hand upward and downward without changing its place (as in using a corkscrew), this circular movement is obviated by rapid instinctive compensating changes in the position of the elbow.

[Mr. Henry Morris (*Anatomy of the Joints*) has called attention to the fact that the humerus and ulna often act as one rigid rod, which he calls the "humero-ulnar shaft." By its rotation at the shoulder it materially adds to the range of rotation of the hand, which would otherwise be limited strictly to that of the radius on the ulna. Besides this, as he notes especially, it has been entirely overlooked that this "humero-ulnar shaft" when the hand is fixed also rotates as a whole on the head of the radius as a centre, thus adding to the mobility of the shoulder. This action is well seen in vaulting, or in walking round a chair while one hand is firmly fixed on its back. The muscles which rotate the humerus will also rotate the ulnar portion of this humero-ulnar shaft; and some of the muscles which rotate the radius will, when the hand is fixed, have the reverse action on the ulna, and through it on the humerus.]

VI. Radio-ulnar Articulations.

The articulation of the radius with the ulna is effected by ligaments which connect together both extremities as well as the shafts of these bones. They may, consequently, be subdivided into three sets: 1, The superior radio-ulnar, which is a portion of the elbow-joint; 2, the middle radio-ulnar; and, 3, the inferior radio-ulnar articulations.

---

[1] *Humphry, op. cit.*, p. 419.

1. Superior Radio-ulnar Articulation.

This articulation is a lateral ginglymus (*diarthrodia rotatoria*). The bones entering into its formation are the inner side of the circumference of the head of the radius rotating within the lesser sigmoid cavity of the ulna. These surfaces are covered with cartilage, and invested with a duplicature of synovial membrane continuous with that which lines the elbow-joint. Its only ligament is the *annular* or *orbicular.*

The **Orbicular Ligament** (Fig. 255) is a strong, flat band of ligamentous fibres which surrounds the head of the radius and retains it in firm connection with the lesser sigmoid cavity of the ulna. It forms about four-fifths of a fibrous ring attached by each end to the extremities of the lesser sigmoid cavity, and is broader at the upper part of its circumference than below, by which means the head of the radius is more securely held in its position. Its *outer surface* is strengthened by the external lateral ligament of the elbow, and affords origin to part of the Supinator brevis muscle. Its *inner surface* is smooth and lined by synovial membrane.

Actions.—The movement which takes place in this articulation is limited to rotation of the head of the radius within the orbicular ligament and upon the lesser sigmoid cavity of the ulna, rotation foward being called *pronation;* rotation backward, *supination. Supination* is performed by the Biceps, Supinator brevis, and Supinator longus, assisted to a slight extent by the Extensor muscles of the thumb. Pronation is performed by the Pronator radii teres and the Pronator quadratus.

2. Middle Radio-ulnar Articulation.

The interval between the shafts of the radius and ulna is occupied by two ligaments:

Oblique. Interosseous.

The **Oblique** or **Round Ligament** (Fig. 254) is a small, round fibrous cord which extends obliquely downward and outward from the tubercle of the ulna at the base of the coronoid process to the radius a little below the bicipital tuberosity. Its fibres run in the opposite direction to those of the interosseous ligament, and it appears to be placed as a substitute for it in the upper part of the interosseous interval. This ligament is sometimes wanting.

The **Interosseous Membrane** [which acts as a ligament] is a broad and thin plane of aponeurotic fibres descending obliquely downward and inward from the interosseous ridge on the radius to that on the ulna [and so supports the humero-ulnar shaft when the weight comes on the hand]. It is deficient above, commencing about an inch beneath the tubercle of the radius, is broader in the middle than at either extremity, and presents an oval aperture just above its lower margin for the passage of the anterior interosseous vessels to the back of the forearm. This ligament serves to connect the bones and to increase the extent of surface for the attachment of the deep muscles. Between its upper border and the oblique ligament an interval exists through which the posterior interosseous vessels pass. Two or three fibrous bands are occasionally found on the posterior surface of this membrane which descend obliquely from the ulna toward the radius, and which have, consequently, a direction contrary to that of the other fibres. It is in relation in *front* by its upper three-fourths with the Flexor longus pollicis on the outer side, and with the Flexor profundus digitorum on the inner, lying upon the interval between which are the anterior interosseous vessels and nerve; by its lower fourth, with the Pronator quadratus; *behind*, with the Supinator brevis, Extensor ossis metacarpi pollicis, Extensor primi internodii pollicis, Extensor secundi internodii pollicis, Extensor indicis; and, near the wrist, with the anterior interosseous artery and posterior interosseous nerve.

3. Inferior Radio-ulnar Articulation.

This is a lateral ginglymus (*diarthrodia rotatoria*) formed by the head of the ulna received into the sigmoid cavity at the inner side of the lower end of the radius.

The articular surfaces are covered by a thin layer of cartilage and connected together by the following ligaments:

Anterior Radio-ulnar.
Posterior Radio-ulnar.
Triangular Interarticular Fibro-cartilage.

The **Anterior Radio-ulnar Ligament** (Fig. 258) is a narrow band of fibres extending from the anterior margin of the sigmoid cavity of the radius to the anterior surface of the head of the ulna.

The **Posterior Radio-ulnar Ligament** (Fig. 259) extends between similar points on the posterior surface of the articulation.

The **Triangular Fibro-cartilage** (Fig. 260, p. 339) is placed transversely beneath the head of the ulna, binding the lower end of this bone and radius firmly together. Its circumference is thicker than its centre, which is thin and occasionally perforated. It is attached by its apex to a depression which separates the styloid process of the ulna from the head of that bone, and by its base, which is thin, to the prominent edge of the radius, which separates the sigmoid cavity from the carpal articulating surface. Its lateral margins are united to the ligaments of the wrist-joint. Its *upper surface*, smooth and concave, articulates with the head of the ulna, forming an arthrodial joint; its *under surface*, also concave and smooth, forms part of the wrist-joint and articulates with the cuneiform bone. Both surfaces are lined by a synovial membrane—the upper surface by one peculiar to the radio-ulnar articulation, the under surface by the synovial membrane of the wrist.

FIG. 258.

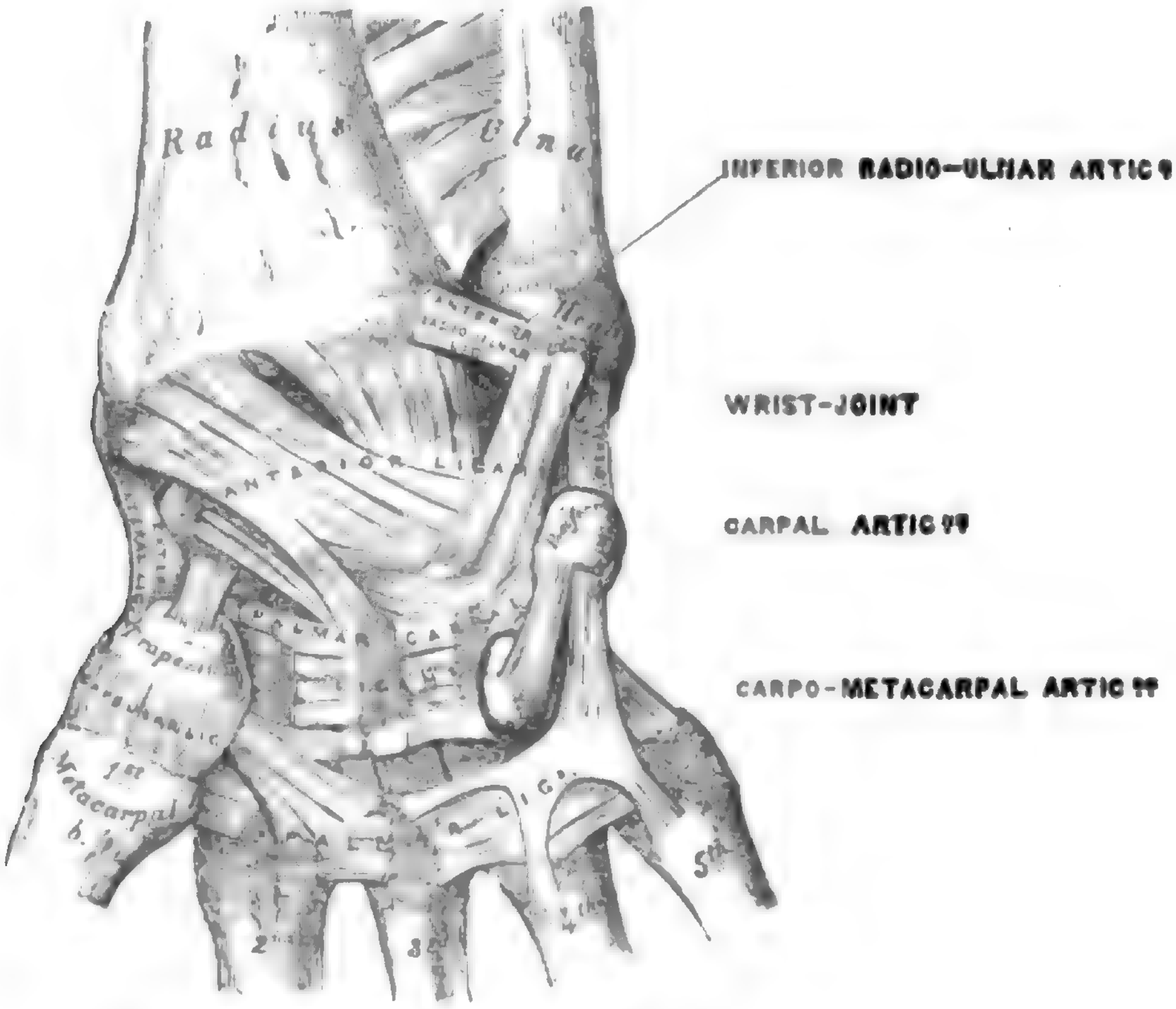

Ligaments of Wrist and Hand, anterior view.

The **synovial membrane** (Fig. 260) of this articulation has been called, from its extreme looseness, the *membrana sacciformis;* it extends horizontally inward between the head of the ulna and the interarticular fibro-cartilage, and upward between the radius and the ulna, forming here a very loose cul-de-sac. [This laxity of the synovial membrane is necessary, in consequence of the large range of movement in pro- and supi-nation.] The quantity of synovia which it contains is usually considerable. When the fibro-cartilage is perforated the synovial membrane is continuous with that which lines the wrist.

ACTIONS.—The arrangement in the inferior radio-ulnar articulation is just the reverse of that between the two bones above: motion is limited to rotation of the radius round the head of the ulna, rotation forward being termed *pronation*, rotation backward *supination*. In pronation the sigmoid cavity glides forward on the articular edge of the ulna; in supination it rolls in the opposite direction, the extent of these movements being limited by the anterior and posterior ligaments. It will thus be seen that in pronation and supination of the forearm and hand the radius describes a segment of a cone, the axis of which extends from the centre of the head of the radius to the styloid process of the ulna.[1]

FIG. 259.

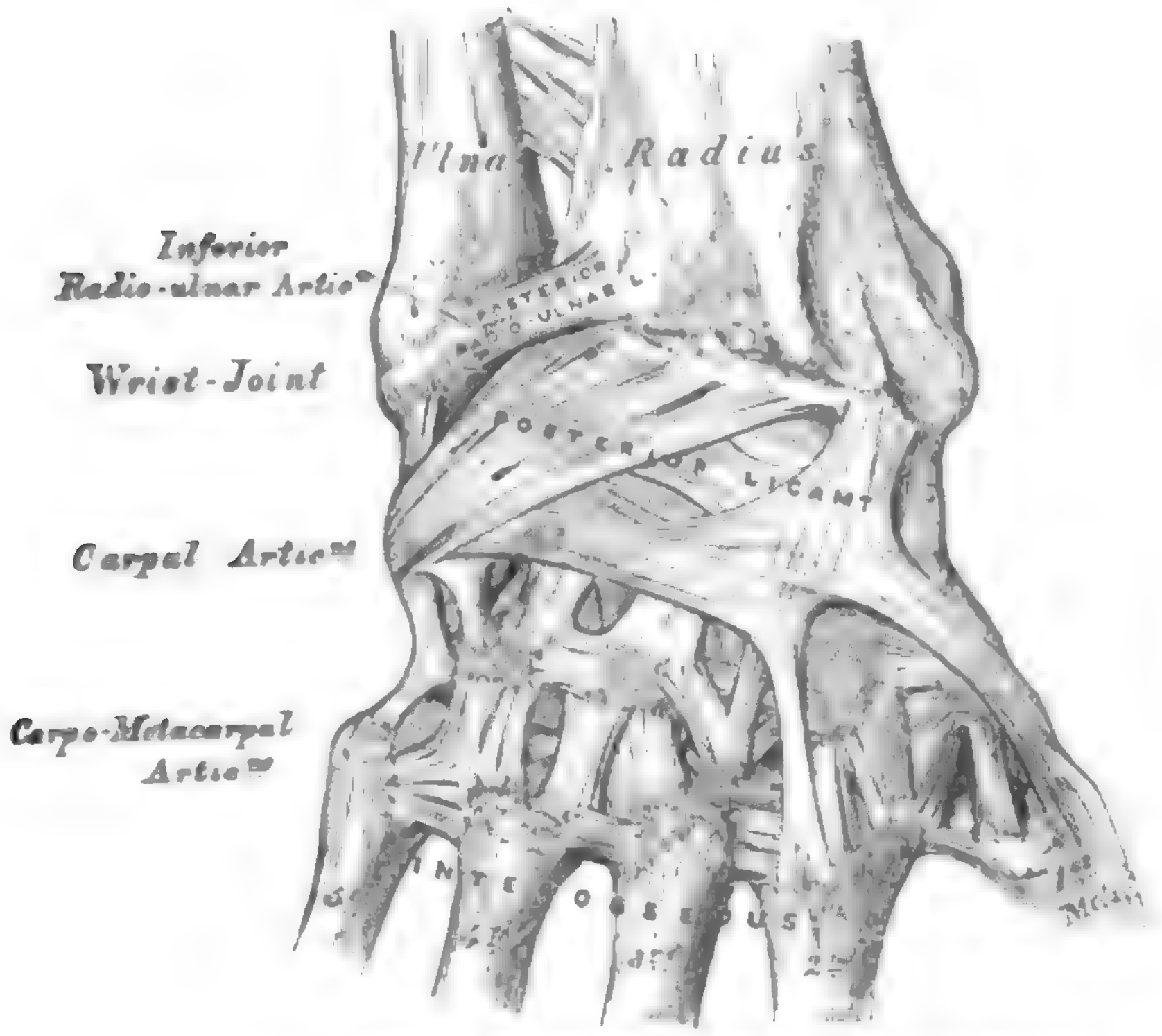

Ligaments of Wrist and Hand, posterior view.

VII. RADIO-CARPAL OR WRIST-JOINT.

The **Wrist** is a condyloid articulation. The parts entering into its formation are the lower end of the radius and under surface of the triangular interarticular fibro-cartilage, which form together the receiving cavity, consisting of a transversely elliptical concave surface, and the scaphoid, semilunar, and cuneiform bones, which form the condyle. The surface of the radius is subdivided into two parts by a line extending from before backward; and these, together with the interarticular cartilage, form three facets, one for each carpal bone. The three carpal bones are connected together, and form a convex surface which is received into the concavity above mentioned. All the bony surfaces of the articulation are covered with cartilage, and connected together by the following ligaments:

---

[1] [The lower end of this axis is rather the centre of the head of the ulna, and if prolonged would pass through the ring-finger. "The head of the radius is so disposed in relation to the sigmoid cavity of the lower extremity that the axis of the former, if prolonged downward, falls upon the centre of the circle of which the latter is a segment" (Ward)—a necessity, in fact, if the head of the radius is fixed.]

Until recently it has been almost universally taught that in rotation it is the radius which revolves and the ulna which remains at rest. Professor Heiberg of Christiania has, however, come to the conclusion that the "rotation of the forearm is due to the combined and complementary movements of the two bones, both of which rotate." Though this is probably not the case, there is no doubt that the lower end of the ulna is not stationary, but undergoes a certain amount of lateral movement during the acts of pronation and supination of the forearm. Dr. Cathcart believes that this movement takes place principally at the shoulder-joint. (See *Journal of Anatomy and Physiology*, vol. xix. Parts II., III., and IV.)

External Lateral. Anterior.
Internal Lateral. Posterior.

The **External Lateral Ligament** (*radio-carpal*) (Fig. 258) extends from the summit of the styloid process of the radius to the outer side of the scaphoid, some of its fibres being prolonged to the trapezium and annular ligament.

The **Internal Lateral Ligament** (*ulno-carpal*) is a rounded cord attached, above, to the extremity of the styloid process of the ulna, and dividing below into two fasciculi, which are attached, one to the inner side of the cuneiform bone, the other to the pisiform bone and annular ligament.

The **Anterior Ligament** is a broad membranous band consisting of three fasciculi attached, above, to the anterior margin of the lower end of the radius, its styloid process, and the ulna; its fibres pass downward and inward to be inserted into the palmar surface of the scaphoid, semilunar, and cuneiform bones, some of the fibres being continued to the os magnum. In addition to this broad membrane there is a distinct rounded fasciculus, superficial to the rest, which passes from the base of the styloid process of the ulna to the semilunar and cuneiform bones. This ligament is perforated by numerous apertures for the passage of vessels, and is in relation, in front, with the tendons of the Flexor profundus digitorum and Flexor longus pollicis; behind, with the synovial membrane of the wrist-joint. [This ligament has an important bearing in producing the deformity of Colles' fracture, as has been shown by Pilcher.[1]]

The **Posterior Ligament** (Fig. 259), less thick and strong than the anterior, is attached above to the posterior border of the lower end of the radius; its fibres pass obliquely downward and inward to be attached to the dorsal surface of the scaphoid, semilunar, and cuneiform bones, being continuous with those of the dorsal carpal ligaments. This ligament is in relation behind with the extensor tendons of the fingers; in front with the synovial membrane of the wrist.

The **synovial membrane** (Fig. 260) lines the under surface of the triangular interarticular fibro-cartilage above, and is reflected on the inner surface of the ligaments just described.

RELATIONS.—The wrist-joint is covered in front by the flexor, and behind by the extensor tendons; it is also in relation with the radial and ulnar arteries.

The *Arteries* supplying the joint are the anterior and posterior carpal branches of the radial and ulnar, the anterior and posterior interosseous, and some ascending branches from the deep palmar arch.

The *Nerves* are derived from the ulnar and posterior interosseous.

ACTIONS.—The movements permitted in this joint are flexion, extension, abduction, adduction, and circumduction. It is totally incapable of rotation. Its actions will be further studied with those of the carpus, with which they are combined.

VIII. ARTICULATIONS OF THE CARPUS.

These articulations may be subdivided into three sets:

1. The Articulations of the First Row of Carpal Bones.
2. The Articulations of the Second Row of Carpal Bones.
3. The Articulations of the Two Rows with each other.

1. ARTICULATIONS OF THE FIRST ROW OF CARPAL BONES.

These are arthrodial joints. The articular surfaces are covered with cartilage, and connected together by the following ligaments:

Two Dorsal. Two Palmar.
Two Interosseous.

The **Dorsal Ligaments** are placed transversely behind the bones of the first row; they connect the scaphoid and semilunar and the semilunar and cuneiform.

---

[1] *N. Y. Med. Record*, July 27, 1878.

The **Palmar Ligaments** connect the scaphoid and semilunar and the semilunar and cuneiform bones; they are less strong than the dorsal, and placed very deep under the anterior ligament of the wrist.

The **Interosseous Ligaments** (Fig. 260) are two narrow bundles of fibrous tissue connecting the semilunar bone on one side with the scaphoid, on the other with the cuneiform. They are on a level with the superior surfaces of these bones, and close the upper part of the interspaces between them. Their upper surfaces are smooth, and form with the bones the convex articular surface of the wrist-joint.

The articulation of the pisiform with the cuneiform is provided with a separate synovial membrane protected by a thin capsular ligament. There are also two strong fibrous fasciculi, which connect this bone to the unciform and the base of the fifth metacarpal bone (Fig. 258).

2. ARTICULATIONS OF THE SECOND ROW OF CARPAL BONES.

These are also arthrodial joints. The articular surfaces are covered with cartilage, and connected by the following ligaments:

Three Dorsal. Three Palmar.
Three Interosseous.

The **three Dorsal Ligaments** extend transversely from one bone to another on the dorsal surface, connecting the trapezium with the trapezoid, the trapezoid with the os magnum, and the os magnum with the unciform.

The **three Palmar Ligaments** have a similar arrangement on the palmar surface.

The **three Interosseous Ligaments**, much thicker than those of the first row, are placed one between the os magnum and the unciform, a second between the os magnum and the trapezoid, and a third between the trapezium and trapezoid. The first of these is much the strongest, and the third is sometimes wanting.

3. ARTICULATIONS OF THE TWO ROWS OF CARPAL BONES WITH EACH OTHER.

The articulations between the two rows of the carpus consist of a kind of enarthrodial joint in the middle, formed by the reception of the head of the os magnum into a cavity formed by the scaphoid and semilunar bones, and of an arthrodial joint on each side, the outer one formed by the articulation of the scaphoid with the trapezium and trapezoid, the internal one by the articulation of the cuneiform and unciform. The articular surfaces are covered by a thin layer of cartilage, and connected by the following ligaments:

Anterior or Palmar. External Lateral.
Posterior or Dorsal. Internal Lateral.

The **Anterior** or **Palmar Ligaments** consist of short fibres which pass, for the most part, from the palmar surface of the bones of the first row to the front of the os magnum.

The **Posterior** or **Dorsal Ligaments** consist of short, irregular bundles of fibres passing between the bones of the first and second row on the dorsal surface of the carpus.

The **Lateral Ligaments** are very short; they are placed, one on the radial, the other on the ulnar, side of the carpus; the former, the stronger and more distinct, connecting the scaphoid and trapezium bones; the latter, the cuneiform and unciform; they are continuous with the lateral ligaments of the wrist-joint.

The **Common Synovial Membrane of the Carpus** is very extensive; it passes from the under surface of the scaphoid, semilunar, and cuneiform bones to the upper surface of the bones of the second row, sending upward two prolongations between the scaphoid and semilunar and the semilunar and cuneiform, sending downward three prolongations between the four bones of the second row, which are further continued downward into the carpo-metacarpal joints of the four inner metacarpal bones, and also for a short distance between the metacarpal bones. There is a separate synovial membrane between the pisiform and cuneiform bones.

ACTIONS.—The articulation of the hand and wrist, considered as a whole, is divided by Meyer[1] into three parts: 1. The radius and the triangular cartilage; 2, the hand proper—viz. the metacarpal bones with the four carpal bones on which they are supported, the trapezium, trapezoid, os magnum, and unciform; and 3, the *meniscus*, formed by the scaphoid, semilunar, and cuneiform, the pisiform bone having no essential part in the movements of the hand.

These three elements form two joints: 1, The anterior, between the hand and meniscus (transverse or mid-carpal joint, as it may be called), mainly ginglymoid in character; 2, the posterior (wrist-joint proper), between the meniscus and bones of the forearm, chiefly arthrodial.

1. The joint between the scaphoid, semilunar, and cuneiform and the second row of the carpus or *mid-carpal* joint is made up of three distinct portions: in the centre the head of the os magnum and the superior surface of the unciform articulate with the deep, cup-shaped cavity formed by the scaphoid and semilunar bones, and constitute a sort of ball-and-socket joint. On the outer side the trapezium and trapezoid articulate with the scaphoid, and on the inner side the unciform articulates with the cuneiform, forming gliding joints. In flexion and extension at the mid-carpal joint, which is the movement most freely enjoyed, the trapezium and trapezoid on the radial side and the unciform on the ulnar side glide forward and backward on the scaphoid and cuneiform respectively, while the head of the os magnum and the superior surface of the unciform rotate in the cup-shaped cavity of the scaphoid and semilunar. Flexion at this joint would appear to be more free than extension. A very trifling amount of rotation is also permitted, the head of the os magnum rotating round a vertical axis drawn through its own centre, while at the same time a slight gliding movement takes place in the lateral joints.

2. The articulation between the forearm and carpus is a true condyloid articulation, and therefore all movements but rotation are permitted. Flexion and extension are the most free, and of these a greater amount of extension than flexion is permitted on account of the articulating surfaces extending farther on the dorsal than on the palmar aspect of the carpal bones. In this movement the carpal bones rotate on a transverse axis drawn between the tips of the styloid processes of the radius and ulna. A certain amount of adduction (or ulnar flexion) and abduction (or radial flexion) is also permitted. Of these, the former is considerably greater in extent than the latter. In this movement the carpus revolves upon an antero-posterior axis drawn through the centre of the wrist. Finally, circumduction is permitted by the consecutive movements of adduction, extension, abduction, and flexion, with intermediate movements between them. There is no rotation, but this is provided for by the supination and pronation of the radius on the ulna.

IX. CARPO-METACARPAL ARTICULATIONS.

1. ARTICULATION OF THE METACARPAL BONE OF THE THUMB WITH THE TRAPEZIUM.

This is a joint of reciprocal reception, and enjoys great freedom of movement, on account of the configuration of its articular surfaces, which are saddle-shaped [the saddle-shaped surfaces of the two bones being at right angles to each other], so that on section each bone appears to be received into a cavity in the other, according to the direction in which they are cut. It has a capsular ligament and a synovial membrane.

The **Capsular Ligament** is a thick but loose capsule which passes from the circumference of the upper extremity of the metacarpal bone to the rough edge bounding the articular surface of the trapezium; it is thickest externally and behind, and lined by a separate *synovial membrane*.

---

[1] Reichert u. Du Bois Reymond, *Archiv*, 1866.

2. ARTICULATIONS OF THE METACARPAL BONES OF THE FINGERS WITH THE CARPUS.

The joints formed between the carpus and four inner metacarpal bones are connected together by dorsal, palmar, and interosseous ligaments.

The **Dorsal Ligaments**, the strongest and most distinct, connect the carpal and metacarpal bones on their dorsal surface. The second metacarpal bone receives two fasciculi—one from the trapezium, the other from the trapezoid; the third metacarpal receives two—one from the trapezoid, and one from the os magnum; the fourth, two—one from the os magnum, and one from the unciform; the fifth receives a single fasciculus from the unciform bone.

The **Palmar Ligaments** have a somewhat similar arrangement on the palmar surface, with the exception of the third metacarpal, which has three ligaments—an external one from the trapezium, situated above the sheath of the tendon of the Flexor carpi radialis; a middle one, from the os magnum; and an internal one, from the unciform.

The **Interosseous Ligaments** consist of short, thick fibres which are limited to one part of the carpo-metacarpal articulation; they connect the contiguous inferior angles of the os magnum and unciform with the adjacent surfaces of the third and fourth metacarpal bones.

The **synovial membrane** is a continuation of that between the two rows of carpal bones. Occasionally the articulation of the unciform with the fourth and fifth metacarpal bones has a separate synovial membrane.

The synovial membranes of the wrist (Fig. 260) are thus seen to be five in number. The *first*, the *membrana sacciformis*, passes from the lower end of the ulna to the sigmoid cavity of the radius, and lines the upper surface of the triangular fibro-cartilage. The *second* passes from the lower end of the radius and interarticular fibro-cartilage above to the bones of the first row below. The *third*, the most extensive, passes between the contiguous margins of the two rows of carpal bones—between the bones of the second row to the carpal extremities of the four inner metacarpal bones. The *fourth* is between the trapezium and the metacarpal bone of the thumb. The *fifth* is between the cuneiform and pisiform bones.

FIG. 260.

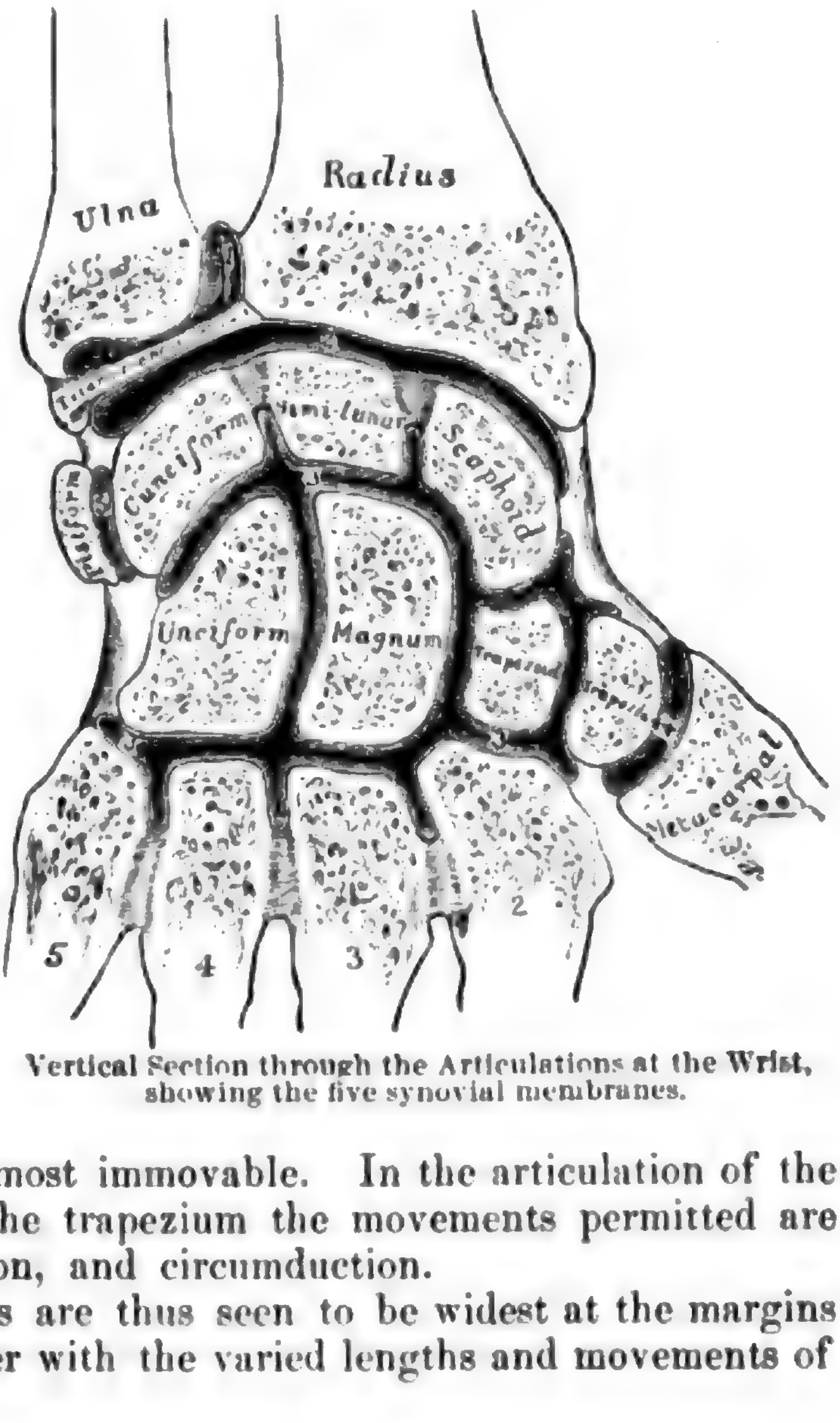

Vertical Section through the Articulations at the Wrist, showing the five synovial membranes.

ACTIONS.—The movement permitted in the carpo-metacarpal articulations is limited to a slight gliding of the articular surfaces upon each other, the extent of which varies in the different joints. Thus the articulation of the metacarpal bone of the thumb with the trapezium is the most movable, then the fifth metacarpal, and then the fourth. The second and third are almost immovable. In the articulation of the metacarpal bone of the thumb with the trapezium the movements permitted are flexion, extension, adduction, abduction, and circumduction.

[The movements of the metacarpus are thus seen to be widest at the margins and least in the centre. This, together with the varied lengths and movements of the fingers, is very important in adapting the hand to grasp the many different-shaped bodies we have to seize. We can thus fit the hand to the surface of a ball, a cylinder, etc., and even, to some extent, to any irregular body.

Three very marked lines in the palm are produced by these movements: (1) that encircling the ball of the thumb; (2) that running from between the thumb and forefinger toward the ulnar border of the hand; and (3) one running from between the fore and middle fingers to the ulnar border of the hand. These last two correspond to the knuckle-joints, and are produced by their constant flexion. It is very important to note that the web of the fingers runs far beyond the knuckles (Fig. 261).]

[Fig. 261.

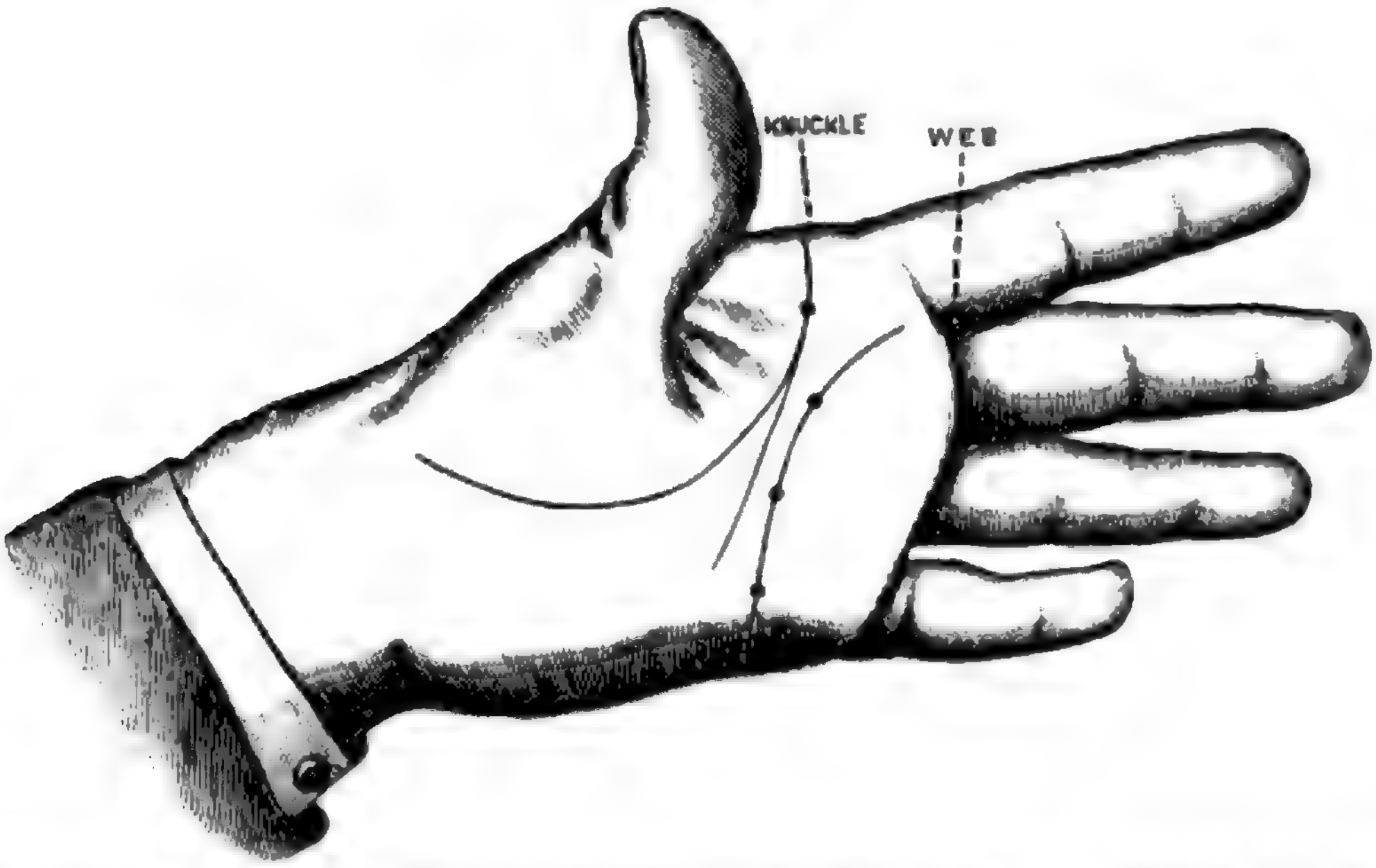

Palm of Hand, showing the relations of the knuckles and the web of the fingers. The dots show the points corresponding to the knuckle-joints. The interval between the transverse fibres of the palmar fascia and the fibres of Gerdy (Fig. 321, p. 451) extends from the level of the knuckles nearly to the web.—W. W. K.]

3. Articulations of the Metacarpal Bones with each other.

The carpal extremities of the four inner metacarpal bones articulate with one another at each side by small surfaces covered with cartilage and connected together by dorsal, palmar, and interosseous ligaments.

The **Dorsal** and **Palmar Ligaments** pass transversely from one bone to another on the dorsal and palmar surfaces. The *Interosseous Ligaments* pass between their contiguous surfaces, just beneath their lateral articular facets.

The **synovial membrane** between the lateral facets is a reflection from that between the two rows of carpal bones.

The digital extremities of the metacarpal bones are connected together by a narrow fibrous band, the transverse ligament (Fig. 262), which passes transversely across their anterior surfaces, and is blended with the ligaments of the metacarpo-phalangeal articulations. Its *anterior surface* presents four grooves for the passage of the flexor tendons. Its *posterior surface* blends with the ligaments of the metacarpo-phalangeal articulations.

X. Metacarpo-phalangeal Articulations (Fig. 262).

These articulations are of the condyloid kind, formed by the reception of the rounded head of the metacarpal bone into a superficial cavity in the extremity of the first phalanx. They are connected by the following ligaments:

Anterior. Two Lateral.

The **Anterior Ligaments** (*Glenoid Ligaments* of Cruveilhier) are thick, dense, fibrous structures placed on the palmar surface of the joints in the intervals between the lateral ligaments, to which they are connected; they are loosely united to the metacarpal bone, but very firmly to the base of the first phalanges. Their palmar surface is intimately blended with the transverse ligament, forming a groove for the passage of the flexor tendons, the sheath surrounding which is connected to each side of the groove. By their deep surface they form part of the articular surface for the head of the metacarpal bone, and are lined by a synovial membrane.

The **Lateral Ligaments** are strong rounded cords placed one on each side of the joint, each being attached by one extremity to the posterior tubercle on the side of the head of the metacarpal bone, and by the other to the contiguous extremity of the phalanx.

The **Posterior Ligament** is supplied by the extensor tendon placed over the back of each joint.

Actions.—The movements which occur in these joints are flexion, extension, adduction, abduction, and circumduction; the lateral movements are very limited.

Fig. 262.

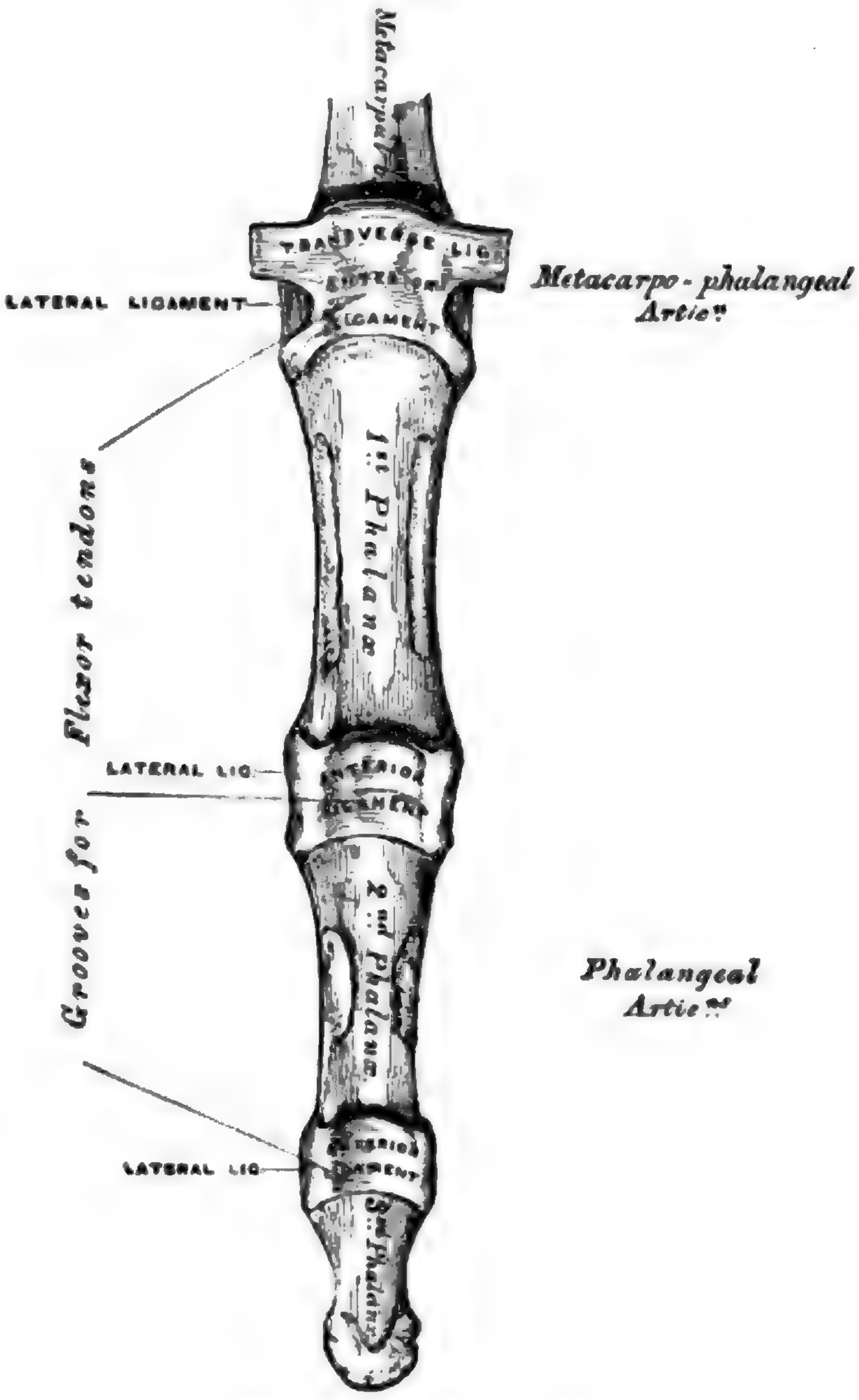
Metacarpal b.
Transverse lig.
Anterior ligament
Lateral ligament
Metacarpo-phalangeal Artic.n
1st Phalanx
Flexor tendons
Grooves for
Lateral lig.
Anterior ligament
2nd Phalanx
Phalangeal Artic.ns
Lateral lig.
Anterior ligament
3rd Phalanx

Articulations of the Phalanges.

XI. Articulations of the Phalanges.

These are ginglymus joints, connected by the following ligaments:

Anterior. Two Lateral.

The arrangement of these ligaments is similar to that of those in the metacarpo-phalangeal articulations; the extensor tendon supplies the place of a posterior ligament.

Actions.—The only movements permitted in the phalangeal joints are flexion and extension; these movements are more extensive between the first and second phalanges than between the second and third. The movement of flexion is very considerable, but the extension is limited by the anterior and lateral ligaments.

ARTICULATIONS OF THE LOWER EXTREMITY.

The Articulations of the Lower Extremity comprise the following groups: I. The hip-joint. II. The knee-joint. III. The articulations between the tibia and fibula.

IV. The ankle-joint. V. The articulations of the tarsus. VI. The tarso-metatarsal articulations. VII. The metatarso-phalangeal articulations. VIII. The articulations of the phalanges.

I. HIP-JOINT (Fig. 263).

This articulation is an enarthrodial or ball-and-socket joint, formed by the reception of the head of the femur into the cup-shaped cavity of the acetabulum. The articulating surfaces are covered with cartilage, that on the head of the femur being thicker at the centre than at the circumference, and covering the entire surface, with the exception of a depression just below its centre for the ligamentum teres; that covering the acetabulum is much thinner at the centre than at the circumference. It forms an incomplete cartilaginous ring of a horseshoe shape, deficient below and in front, and having in its centre a circular depression, which is occupied in the recent state by a mass of fat surrounded by synovial membrane. The ligaments of the joint are the

FIG. 263.

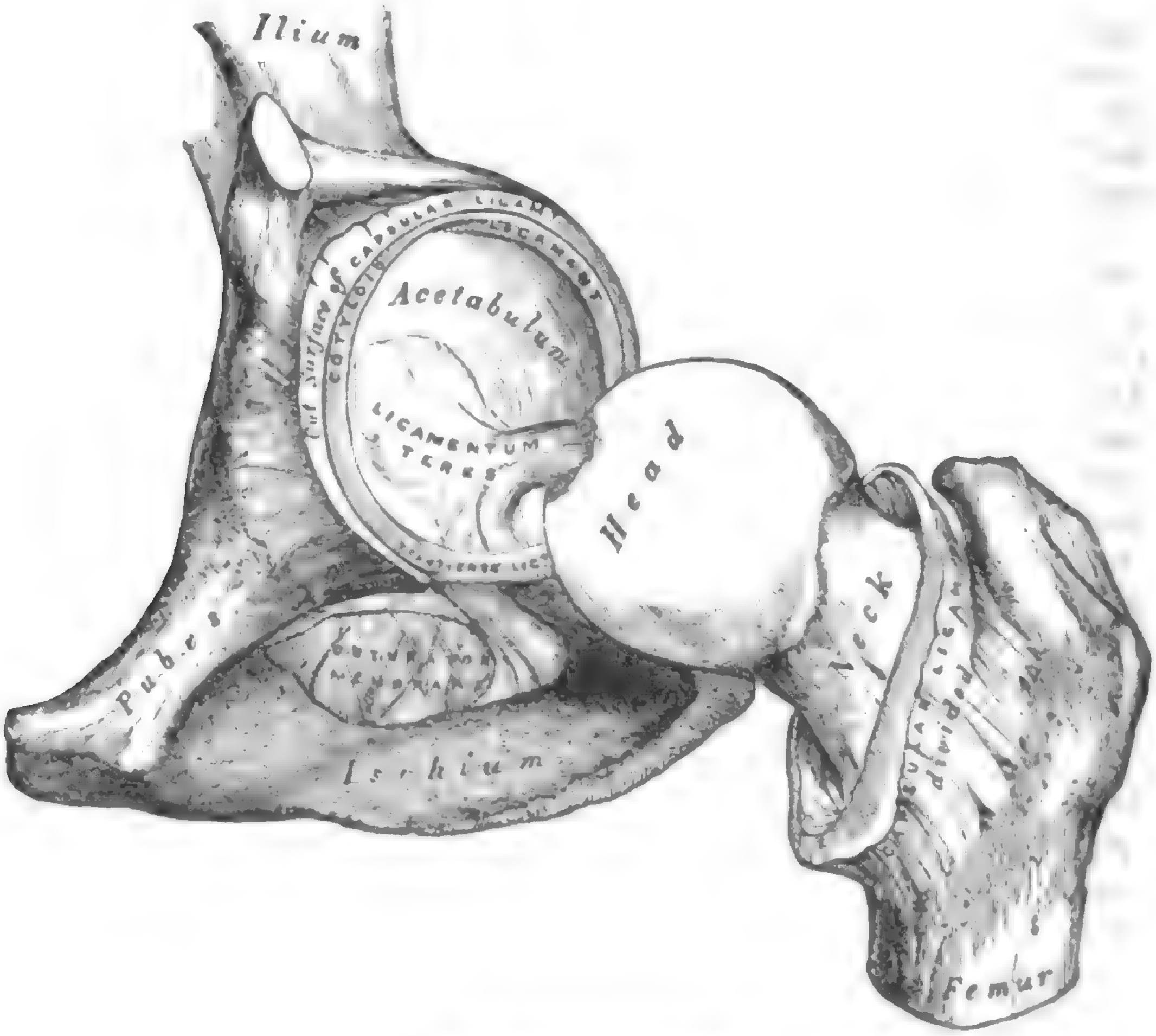
Ilium
Cut Surface of Capsular Ligament
Capsular Ligament
Cotyloid Ligament
Acetabulum
Ligamentum Teres
Transverse Lig.
Head
Neck
Pubes
Obturator Membrane
Ischium
Capsular Ligament divided
Femur

Left Hip-joint laid open.

Capsular. Teres.
Ilio-femoral. Cotyloid.
Transverse.

The **Capsular Ligament** is a strong, dense, ligamentous capsule embracing the margin of the acetabulum above and surrounding the neck of the femur below. Its *upper circumference* is attached to the acetabulum two or three lines external to the cotyloid ligament; but opposite to the notch where the margin of this cavity is deficient it is connected with the transverse ligament, and by a few fibres to the edge of the obturator foramen. Its *lower circumference* surrounds the neck of the femur, being attached in front to the spiral or anterior intertrochanteric line; above, to the base of the neck; behind, to the middle of the neck of the bone about half an inch above the posterior intertrochanteric line. From this insertion the fibres are reflected upward over the neck of the femur, forming a sort of tubular sheath which blends with the periosteum and can be traced as far as the articular cartilage. It is much thicker at the upper and fore part of the joint, where the greatest amount of resistance is required, than below and internally, where it is thin, loose, and longer than in any other part. It consists of two sets of fibres, circular and longitudinal. The circular fibres are most abundant at the lower and back part of the capsule, while the longitudinal fibres are greatest in amount at the front and upper part of the joint, where they form distinct bands or accessory ligaments, of which the most important is the ilio-femoral. The other accessory bands are known as the *pubo-femoral*, passing from the ilio-pectineal eminence to the front of the capsule; the *ilio-trochanteric*, from the anterior inferior spine of the ilium to the front of the great trochanter; and the *ischio-capsular*, passing from the ischium, just below the acetabulum, to blend with the circular fibres at the lower part of the joint. Its external surface (Fig. 247, p. 318) is rough, covered by numerous muscles, and separated in front from the Psoas and Iliacus by a synovial bursa, which not unfrequently communicates by a circular aperture with the cavity of the joint. It differs from the capsular ligament of the shoulder in being much less loose and lax, and in not being perforated for the passage of a tendon.

[Fig. 264.

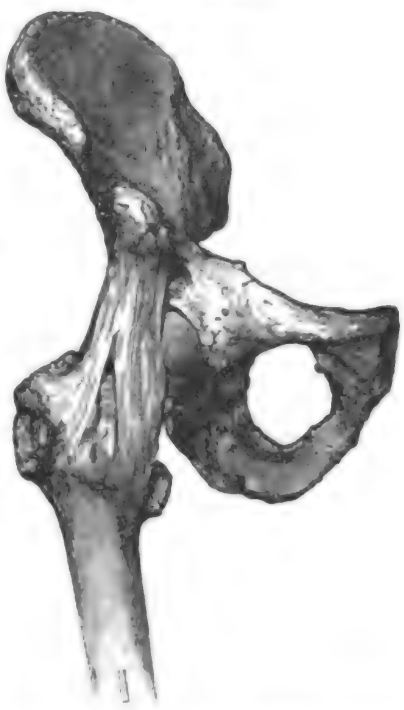

Hip-joint, showing inverted Y-ligament (Bigelow).]

The Ilio-femoral Ligament (Fig. 247, p. 318, and Fig. 264) is an accessory band of fibres extending obliquely across the front of the joint; it is intimately connected with the capsular ligament, and serves to strengthen it in this situation. It is attached above to the lower part of the anterior inferior spine of the ilium, and,

Fig. 265.

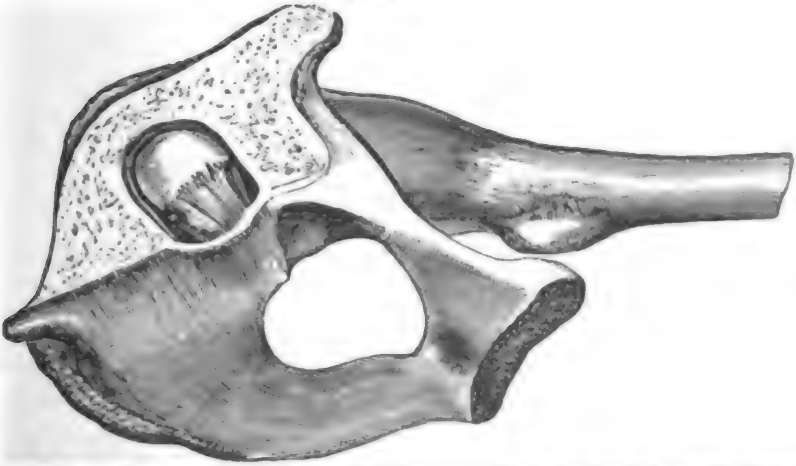

The Hip-joint laid open from the Pelvis, to show the Ligamentum Teres put on the stretch by rotation of the Femur outward.

spreading out into a flat triangular band, it is attached below into the whole length of the anterior intertrochanteric line. Its lower part, instead of forming a flat band, is sometimes bifurcated, and forms two bands, the one of which passes almost vertically to the lower part of the intertrochanteric line, the other obliquely to the upper part of the line. This arrangement Bigelow seems to regard as the usual one, so that he describes it under the name of the "inverted Y-ligament."[1] [This "inverted Y-ligament" is of such importance, particularly in relation to dislocations and their reduction by manipulation, that its careful examination and dissection are especially recommended to the student. It is well shown in Fig. 264.]

Fig. 266.

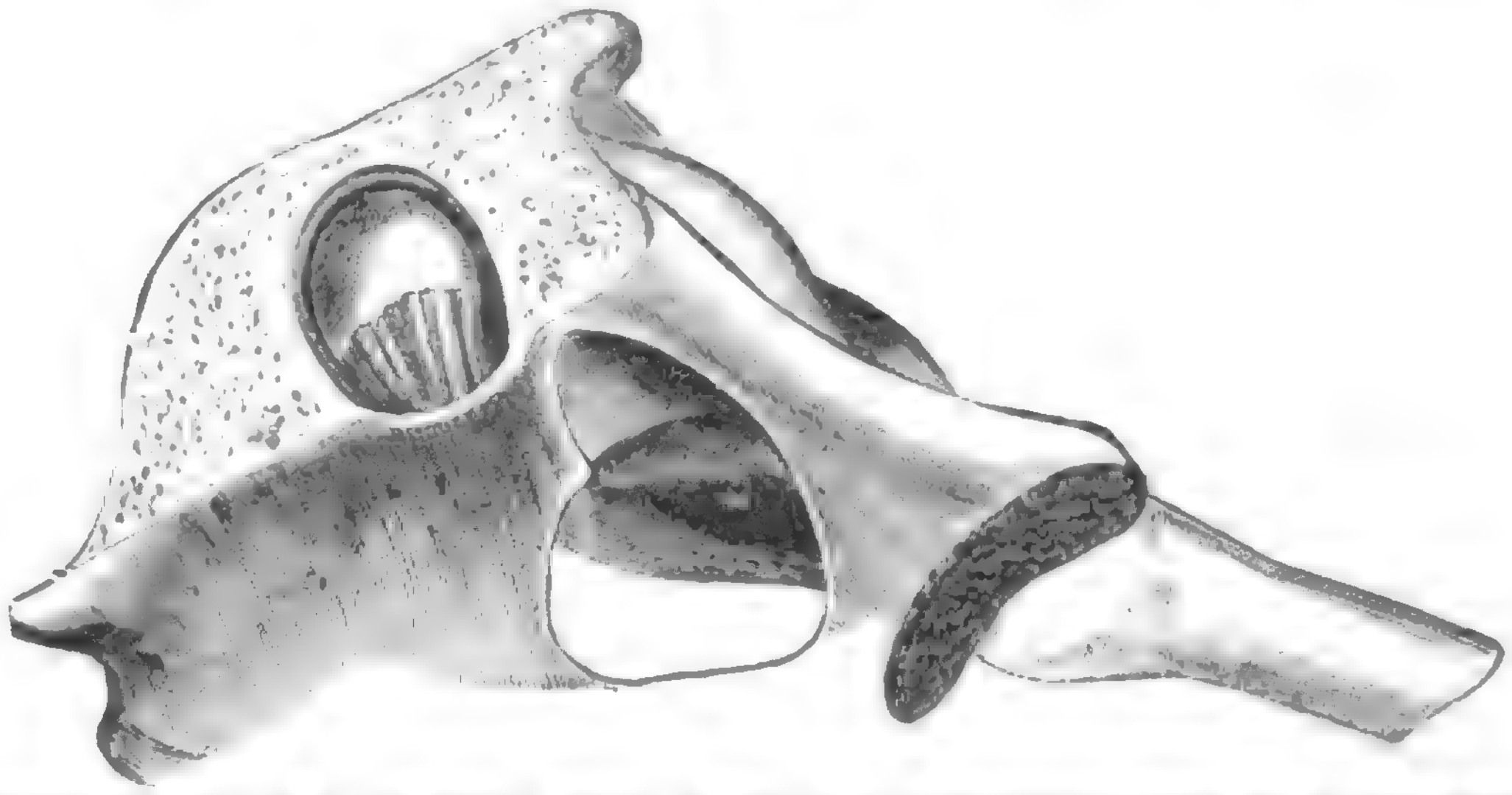

The Same View of the Hip as in the former figure, to show the Ligamentum Teres put on the stretch by adduction in the flexed position.

The **Ligamentum Teres** is a triangular band of fibres implanted, by its apex, into the depression a little behind and below the centre of the head of the femur, and by its broad base, which consists of two bundles of fibres, into the margins of the notch at the bottom of the acetabulum, becoming blended with the transverse ligament. It is formed of a bundle of fibres, the thickness and strength of which are very variable, surrounded by a tubular sheath of synovial membrane. Sometimes only the synovial fold exists, or the ligament may be altogether absent. The use of the round ligament is to check rotation outward, as well as adduction in the flexed position (Figs. 265, 266): it thus assists in preventing dislocation of the head of the femur forward and outward—an accident likely to occur from the necessary mechanism of the joint if not provided against by this ligament and the thick anterior part of the capsule.[2]

The **Cotyloid Ligament** is a fibro-cartilaginous rim attached to the margin of the acetabulum, the cavity of which it deepens; at the same time it protects the edges of the bone and fills up the inequalities on its surface. It bridges over the notch as the *transverse ligament*, and thus forms a complete circle which closely surrounds the head of the femur and assists in holding it in its place, acting as a sort of valve and preventing the admission of air into the joint. It is prismoid in form, its base being attached to the margin of the acetabulum and its opposite edge being free and sharp, whilst its two surfaces are invested by synovial membrane, the external one being in contact with the capsular ligament, the internal one being inclined inward, so as to narrow the acetabulum and embrace the cartilaginous surface of the head of the femur. It is much thicker above and behind than below and in front, and consists of close compact fibres which arise from different points of the circumference of the acetabulum and interlace with one another at very acute angles.

---

[1] Bigelow, *On the Hip-joint.*

[2] See an interesting paper, "On the Use of the Round Ligament of the Hip-joint," by Dr. J. Struthers, *Edinburgh Medical Journal*, 1858. This ligament is best studied with the assistance of a preparation in which the floor of the acetabulum has been removed with a trephine, and the ligament exposed by cleaning away the fat. Mr. Savory, without denying the other uses attributed to this ligament, says that it is always made tense in the upright position, and is still further tightened in standing on one leg; and therefore he maintains that its main function is to support the weight of the body and distribute its pressure equally over the whole surface of the acetabulum and head of the femur (*Lancet*, May 23, 1874). [The ligamentum teres is sometimes absent.]

The **Transverse Ligament** is in reality a portion of the cotyloid ligament, strengthened in this situation by some deep fibres. It consists of strong flattened fibres which cross the notch at the lower part of the acetabulum and convert it into a foramen. An interval is left beneath the ligament for the passage of nutrient vessels to the joint.

The **synovial membrane** is very extensive. Commencing at the margin of the cartilaginous surface of the head of the femur, it covers all that portion of the neck which is contained within the joint; from the neck it is reflected on the internal surface of the capsular ligament, covers both surfaces of the cotyloid ligament and the mass of fat contained in the fossa at the bottom of the acetabulum, and is prolonged in the form of a tubular sheath around the ligamentum teres as far as the head of the femur.

The muscles in relation with the joint are, in front, the Psoas and Iliacus, separated from the capsular ligament by a synovial bursa; above, the straight head of the Rectus and Gluteus minimus, the latter being closely adherent to the capsule; internally, the Obturator externus and Pectineus; behind, the Pyriformis, Gemellus superior, Obturator internus, Gemellus inferior, Obturator externus, and Quadratus femoris (Fig. 267).

FIG. 267.

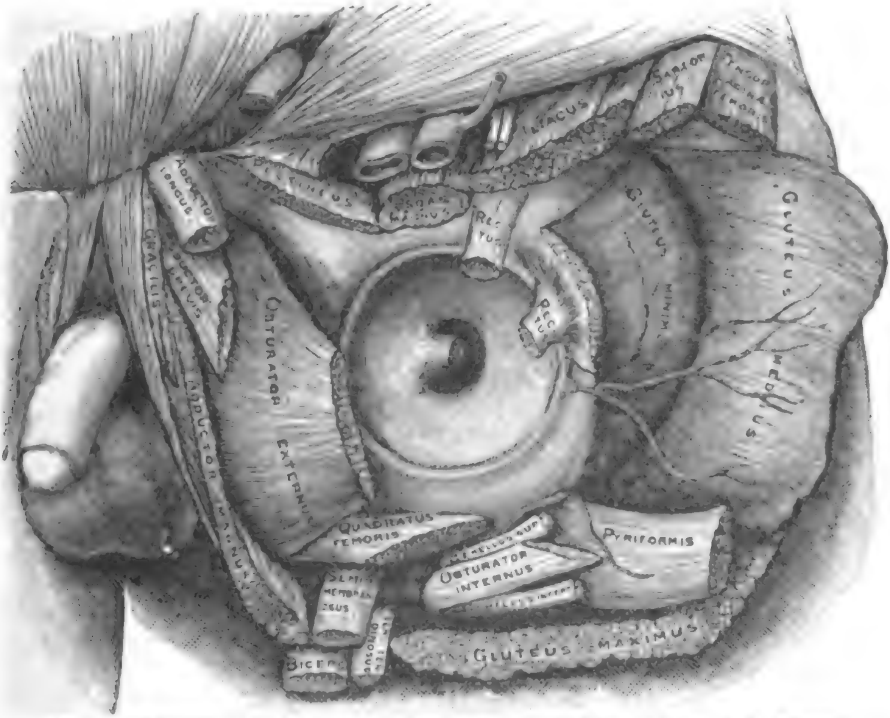
Sartorius
Tensor vaginae femoris
Iliacus
Pectineus
Psoas magnus
Rectus
Rectus
Gluteus minimus
Gluteus medius
Adductor longus
Gracilis
Adductor brevis
Obturator externus
Adductor magnus
Quadratus femoris
Gemellus sup.
Pyriformis
Obturator internus
Semimembranosus
Semitendinosus
Biceps
Gluteus maximus

Relation of Muscles to the Capsule of the Hip-joint (from a drawing by Mr. F. A. Barton).

The *Arteries* supplying the joint are derived from the obturator, sciatic, internal circumflex, and gluteal.

The *Nerves* are articular branches from the sacral plexus, great sciatic, obturator, and accessory obturator nerves.

ACTIONS.—The movements of the hip, like [those of] all enarthrodial joints, are very extensive; they are flexion, extension, adduction, abduction, circumduction, and rotation.

The hip-joint presents a very striking contrast to the other great enarthrodial joint—the shoulder—in the much more complete mechanical arrangements for its security and for the limitation of its motions. In the shoulder, as we have seen, the head of the humerus is not adapted at all in shape to the glenoid cavity, and is hardly restrained in any of its ordinary movements by the capsular ligament. In the hip-joint, on the contrary, the head of the femur is closely fitted to the acetabulum for a distance extending over nearly half a sphere, and at the margin of the bony cup it is still more closely embraced by the ligamentous ring of the cotyloid ligament, so that the head of the femur is held in its place by that ligament even when the fibres of the capsule have been quite divided (Humphry). The anterior portion of the capsule, described as the ilio-femoral or accessory ligament, is the strongest of all the ligaments in the body, and is put on the stretch by any attempt to extend the femur beyond a straight line with the trunk. That is to say, this ligament is the chief agent in maintaining the erect position without muscular fatigue, the action of the extensor muscles of the buttock being balanced by the tension of the ilio-femoral and capsular ligaments. The security of the joint is also provided for by the two bones being directly united through the ligamentum teres. Flexion of the hip-joint is arrested by the soft parts of the thigh and abdomen being brought into contact:[1] extension, by the tension of the ilio-femoral ligament and front of the capsule; adduction, by the outer band of the ilio-femoral ligament and the ilio-trochanteric ligament, and in the flexed position of the limb by the ligamentum teres; abduction, by the lower portion of the ilio-femoral ligament and the pubo-femoral band; rotation outward, by the outer part of the ilio-femoral ligament and the ligamentum teres; and rotation inward, by the ischio-capsular ligament and the hinder part of the capsule. The muscles which *flex* the femur on the pelvis are the Psoas, Iliacus, Rectus, Sartorius, Pectineus, and Adductor brevis. *Extension* is mainly performed by the Gluteus maximus, assisted by the hamstring muscles. The thigh is *adducted* by the Adductor magnus, longus and brevis, the Pectineus, Sartorius, and Gracilis, and *abducted* by the Gluteus maximus, medius, and minimus. The muscles which *rotate* the thigh *inward* are the anterior fibres of the Gluteus medius, the Gluteus minimus, and the Tensor vaginæ femoris; while those which rotate it *outward* are the posterior fibres of the Gluteus medius, the Pyriformis, Obturator externus and internus, Gemellus superior and inferior, Quadratus femoris, Psoas, Iliacus, Gluteus maximus, the three Adductors, and the Pectineus.

[Fig. 268.

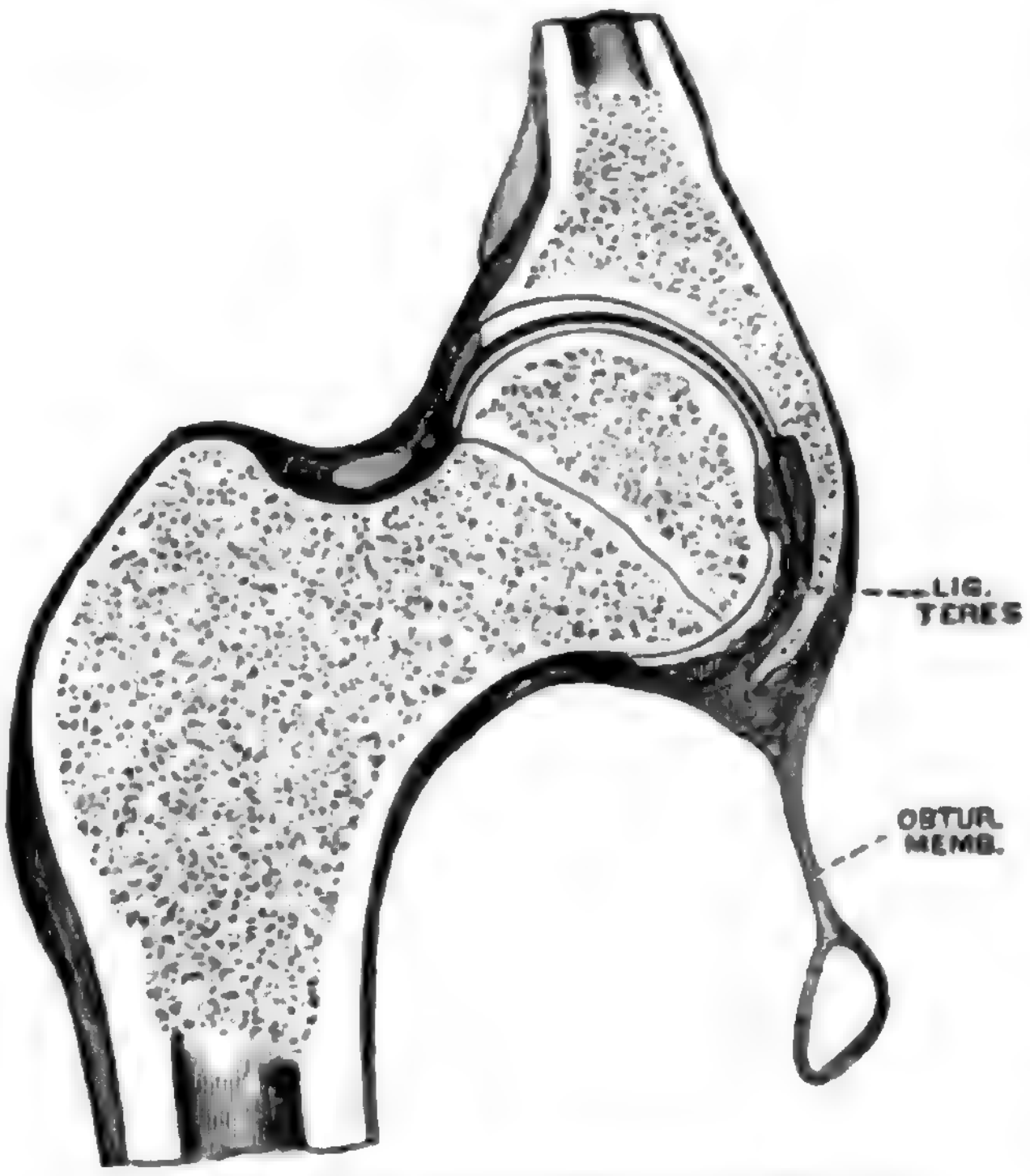

Vertical Section through Hip-joint (Henle).]

II. KNEE-JOINT.

The knee-joint was formerly described as a ginglymus or hinge-joint, but is really of a much more complicated character. It must be regarded as consisting of three articulations together: one between each condyle of the femur and the corresponding tuberosity of the tibia, which are condyloid joints; and one between the patella and the femur, which is partly arthrodial, but not completely so, since the articular surfaces are mutually adapted to each other, so that the movement is not a simply gliding one. This view of the construction of the knee-joint receives confirmation from the study of the articulations in some of the lower mammals, where three synovial membranes are sometimes found, corresponding to these three subdivisions, either entirely distinct or only connected together by small communications. This view is further rendered probable by the existence of the two crucial ligaments within the joint, which must be regarded as the external and internal lateral ligaments of the inner and outer joints respectively. The existence of the ligamentum mucosum would further indicate a tendency to separation of the synovial cavity into two minor sacs, one corresponding to each joint. [For a comparison of the angle formed between the thigh and leg at the knee with the similar angle at the elbow, see p. 242.]

---

[1] The hip-joint cannot be completely flexed, in most persons, without at the same time flexing the knee, on account of the shortness of the hamstring muscles (Cleland, *Journ. of Anat. and Phys.*, No. 1, Old Series, p. 87). [See ligamentous action of muscles, p. 301.]

The bones entering into the formation of the knee-joint are the condyles of the femur above, the head of the tibia below, and the patella in front. The articular surfaces are covered with cartilage and connected together by ligaments, some of which are placed on the exterior of the joint, whilst others occupy its interior.

External Ligaments.	*Interior Ligaments.*
Anterior, or Ligamentum patellæ.	Anterior, or External Crucial.
Posterior, or Ligamentum posticum Winslowii.	Posterior, or Internal Crucial.
Internal Lateral.	Two Semilunar Fibro-cartilages.
Two External Lateral.	Transverse.
Capsular.	Coronary.
	Ligamentum mucosum.
	Ligamenta alaria.

The **Anterior Ligament, or Ligamentum patellæ** (Fig. 269), is that portion of the common tendon of the extensor muscles of the thigh which is continued from the patella to the tubercle of the tibia, supplying the place of an anterior ligament. It is a strong, flat, ligamentous band about three inches in length, attached above to the apex of the patella and the rough depression on its posterior surface: below, to the lower part of the tuberosity of the tibia, its superficial fibres being continuous across the front of the patella with those of the tendon of the Quadriceps extensor. [The ligamentum patellæ is best shown by trying to lift a heavy bureau or other weight by one foot, the leg being in semi-extension.] Two synovial bursæ are connected with this ligament and the patella: one is interposed between the patella and the skin covering its anterior surface [see p. 311]; the other of small size, between the ligamentum patellæ and the upper part of the tuberosity of the tibia. The posterior surface of the ligament is separated above from the knee-joint by a large mass of adipose tissue [this fatty tissue recedes into the space between the bones when the leg is flexed, but is forced out on each side of the ligament when the leg is extended, and is not to be mistaken for fluid inside the joint]: its lateral margins are continuous with the aponeurosis derived from the Vasti muscles.

The **Posterior Ligament, Ligamentum posticum Winslowii**[1] (Fig. 270), is a broad, flat, fibrous band which covers over the whole of the back part of the joint. It consists of a central and two lateral portions, the latter formed chiefly of vertical fibres, which arise above from the condyles of the femur and are connected below with the back part of the head of the tibia, being closely united with the tendons of the Gastrocnemius, Plantaris, and Popliteus muscles; the central portion is formed of fasciculi obliquely directed and separated from one another by apertures for the passage of vessels and nerves. The strongest of these fasciculi is derived from the tendon of the Semimembranosus, and passes from the back part of the inner tuberosity of the tibia obliquely upward and outward to the back part of the outer condyle of the femur. The posterior ligament forms part of the floor of the popliteal space, and the popliteal artery rests upon it.

The **Internal Lateral Ligament** is a broad, flat, membranous band, thicker behind than in front, and situated nearer to the back than the front of the joint. It is attached above to the inner tuberosity of the femur, below to the inner tuberosity and inner surface of the shaft of the tibia to the extent of about two inches. It is crossed at its lower part by the aponeurosis of the Sartorius and the tendons of the Gracilis and Semitendinosus muscles, a synovial bursa being interposed. Its *deep surface* covers the anterior portion of the tendon of the Semimembranosus, the synovial membrane of the joint, and the inferior internal articular artery and nerve; it is intimately adherent to the internal semilunar fibro-cartilage.

---

[1] [The "oblique fasciculus" is the only part described by Winslow as the "posterior ligament." The rest of it is described by him with the "capsular ligament."]

Fig. 269.

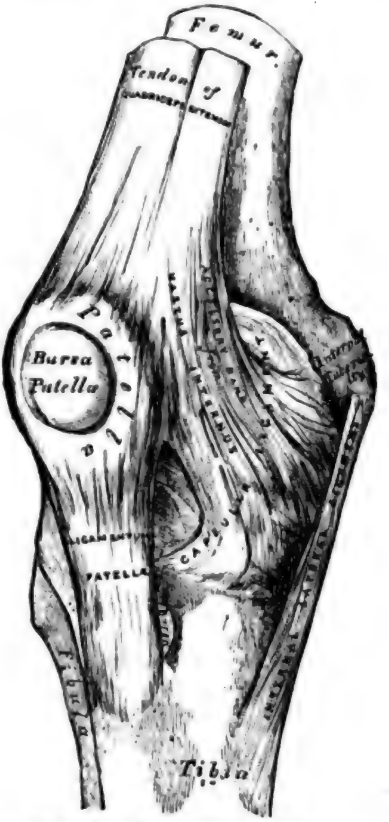
Femur.
Tendon of
Quadriceps Extensor
Patella
Bursa
Patellæ
Ligamentum
Patellæ
Capsul
Tibia
Fibula

Right Knee-joint, anterior view.

Fig. 270.

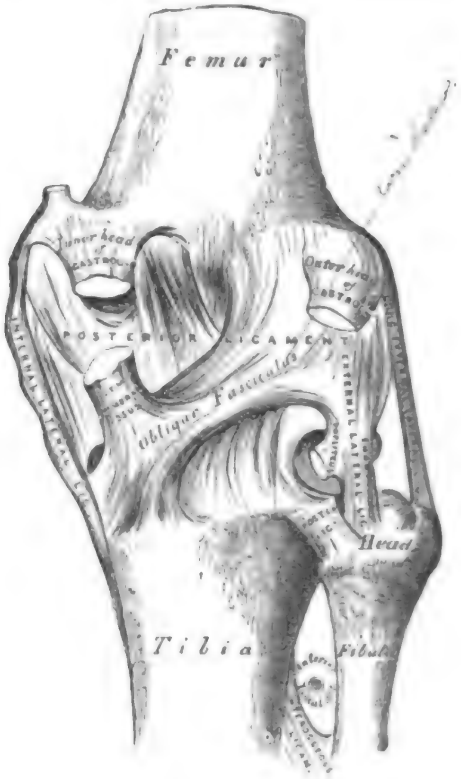
Femur
Inner head of Gastroc.
Outer head of Gastroc.
Posterior Ligament
Oblique Fasciculus
Internal Lateral Lig.
External Lateral Lig.
Head
Tibia
Fibula

Right Knee-joint, posterior view.

The **Long External Lateral Ligament** is a strong, rounded, fibrous cord situated nearer to the back than the front of the joint. It is attached above to the back part of the outer tuberosity of the femur, below to the outer part of the head of the fibula. Its *outer surface* is covered by the tendon of the Biceps, which divides at its insertion into two parts, separated by the ligament. The ligament has passing beneath it the tendon of the Popliteus muscle and the inferior external articular vessels and nerve.

The **Short External Lateral Ligament** is an accessory bundle of fibres placed behind and parallel with the preceding, attached above to the lower part of the outer tuberosity of the femur, below to the summit of the styloid process of the fibula. This ligament is intimately connected with the capsular ligament, and has passing beneath it the tendon of the Popliteus muscle.

The **Capsular Ligament** consists of an exceedingly thin but strong fibrous membrane which fills in the intervals left by the preceding ligaments. It is attached to the femur immediately above its articular surface, but is incomplete in front, not extending beneath the extensor tendons; below, to the upper border and sides of the patella and the margins of the head of the tibia and interarticular cartilages, and is continuous behind with the posterior ligament. This membrane is strengthened by fibrous expansions derived from the fascia lata, from the Vasti and Crureus muscles, and from the Biceps, Sartorius, and tendon of the Semimembranosus. The expansions from the fascia lata and Vasti muscles form strong fibrous bands on either side of the patella, which are sometimes called the lateral patellar ligaments. [The tendon of the Quadriceps extensor (the so-called ligamentum patellæ) is so strong and tense that any liquid accumulating inside the knee-joint distends only the relatively weaker capsular ligament, and forms a marked swelling on each side of the tendon and below the patella. The contrast between this and the median swelling in front of the patella in "housemaid's knee" is to be borne in mind.]

The **Crucial** are two interosseous ligaments of considerable strength situated in the interior of the joint, nearer its posterior than its anterior part. They are called *crucial* because they cross each other, somewhat like the lines of the letter X, and have received the names *anterior* and *posterior* from the position of their attachment to the tibia.

The **Anterior** or **External Crucial Ligament** (Fig. 271), smaller than the posterior, is attached to the inner side of the depression in front of the spine of the tibia, being blended with the anterior extremity of the external semilunar fibro-cartilage, and, passing obliquely upward, backward, and outward, is inserted into the inner and back part of the outer condyle of the femur.

FIG. 271.

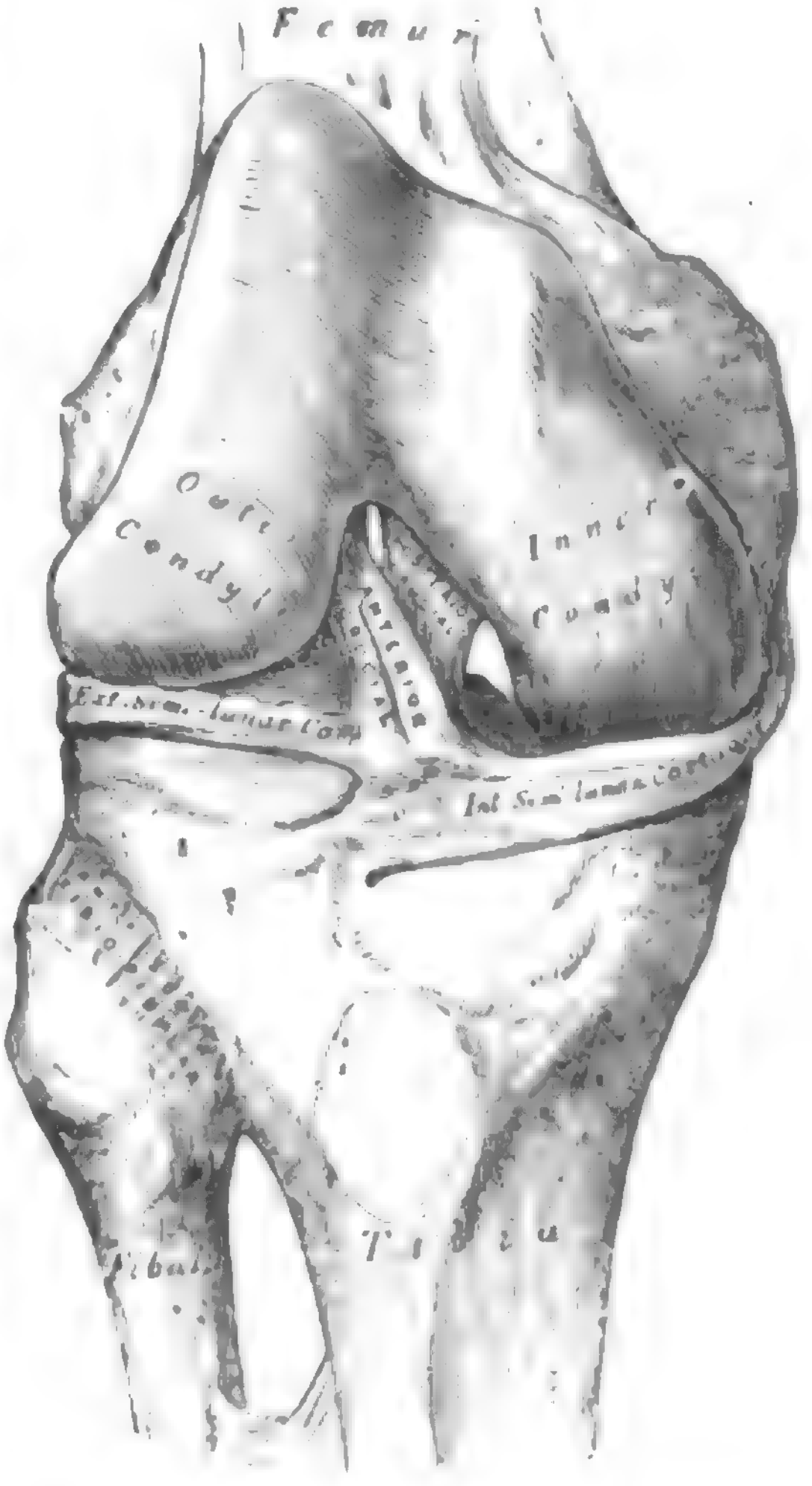

Right Knee-joint, showing internal ligaments.

The **Posterior** or **Internal Crucial Ligament** is larger in size, but less oblique in its direction than the anterior. It is attached to the back part of the depression behind the spine of the tibia, to the popliteal notch, and to the posterior extremity of the external semilunar fibro-cartilage, and passes upward, forward, and inward to be inserted into the outer and fore part of the inner condyle of the femur. As it crosses the anterior crucial ligament a fasciculus is given off from it which blends with the posterior part of that ligament. It is in relation in front with the anterior crucial ligament, behind with the ligamentum posticum Winslowii.

The **Semilunar Fibro-cartilages** (Fig. 272) are two crescentic lamellæ which are attached to the margins of the head of the tibia, and serve to deepen its surface for articulation with the condyles of the femur. The circumference of each cartilage is thick and convex, the inner free border thin and concave. Their upper surfaces are concave, and in relation with the condyles of the femur; their lower surfaces are flat, and rest upon the head of the tibia. Each cartilage covers nearly the outer two-thirds of the corresponding articular surface of the tibia, leaving the

FIG. 272.

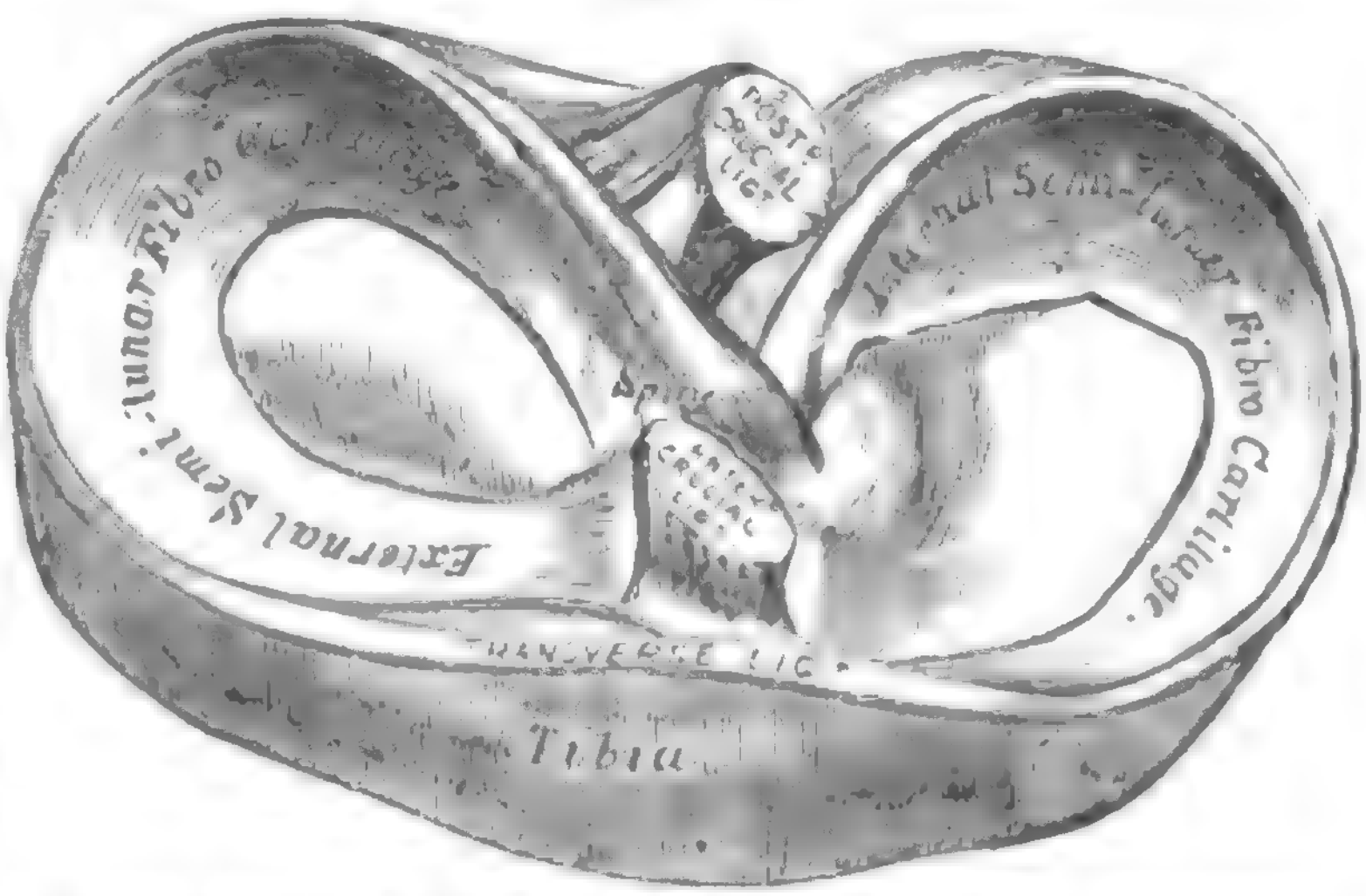
Posterior Crucial Lig.
External Semilunar Fibro Cartilage
Internal Semilunar Fibro Cartilage
Spine
Anterior Crucial Lig.
Transverse Lig.
Tibia

Head of Tibia, with Semilunar Cartilages, etc., seen from above, right side.

inner third uncovered; both surfaces are smooth and invested by synovial membrane.

The **Internal Semilunar Fibro-cartilage** is nearly semicircular in form, a little elongated from before backward, and broader behind than in front; its convex border is united to the internal lateral ligament and to the head of the tibia by means of the coronary ligaments; its anterior extremity, thin and pointed, is firmly implanted into a depression on the anterior margin of the head of the tibia in front of the anterior crucial ligament; its posterior extremity into the depression behind the spine, between the attachment of the external cartilage and posterior crucial ligament.

The **External Semilunar Fibro-cartilage** forms nearly an entire circle, covering a larger portion of the articular surface than the internal one. It is grooved on its outer side for the tendon of the Popliteus muscle. Its circumference is held in connection with the head of the tibia by means of the coronary ligaments, and its two extremities are firmly implanted in the depressions in front of and behind the spine of the tibia. These extremities at their insertion are interposed between the attachments of the internal cartilage, the anterior extremity being attached, in front of the spine of the tibia, to the outer side of the anterior crucial ligament. The posterior is attached behind the spine, but in front of the posterior extremity of the internal cartilage. Just before its insertion it gives off a strong fasciculus which passes obliquely upward and outward, to be inserted into the inner condyle of the femur close to the attachment of the posterior crucial ligament. Occasionally a small fasciculus is given off which passes forward to be inserted into the back part of the anterior crucial ligament. The external semilunar fibro-cartilage gives off from its *anterior border* a fasciculus which forms the transverse ligament.

The **Transverse Ligament** is a band of fibres which passes transversely from the anterior convex margin of the external semilunar cartilage to the anterior extremity of the internal cartilage; its thickness varies considerably in different subjects, and it is sometimes absent altogether.

[FIG. 273.

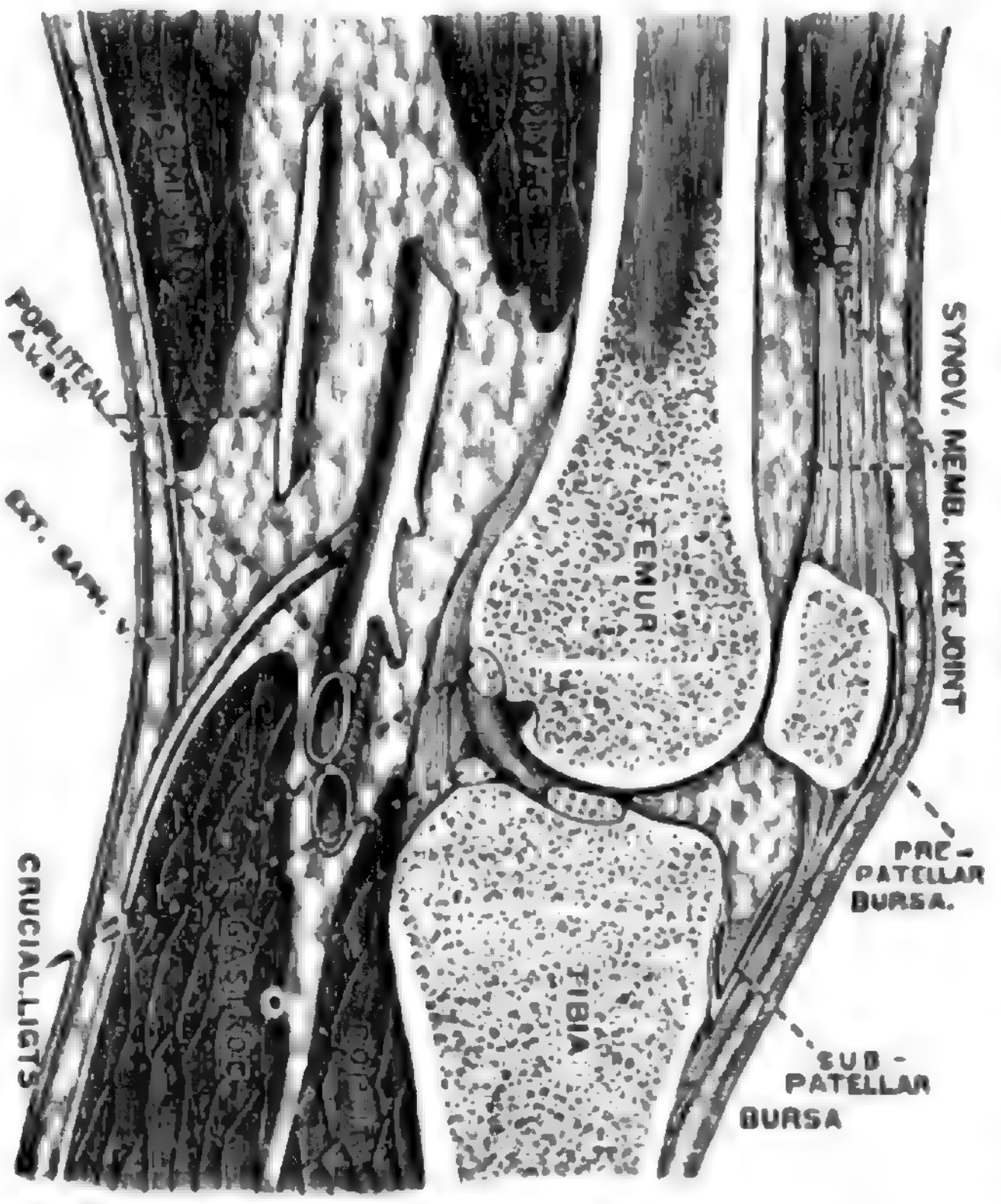

Sagittal Section through Knee-joint (Volz).]

The **Coronary Ligaments** consist of numerous short fibrous bands which connect the convex border of the semilunar cartilages with the circumference of the head of the tibia and with the other ligaments surrounding the joint.

The **synovial membrane** of the knee-joint is the largest and most extensive in the body. Commencing at the upper border of the patella, it forms a short cul-de sac beneath the Quadriceps extensor tendon on the thigh; this communicates with a synovial bursa interposed between the tendon and the front of the femur, by an orifice of variable size. [These two cavities are practically one. If a blowpipe be inserted through a hole drilled in the patella or secured in a small opening in the capsular ligament, and the cavity of the joint be distended by air, the synovial sac will be found to extend usually two inches above the upper margin of the patella—an important fact to be remembered in operations in this region. In synovitis of this joint the distension thus extends above the patella, and if marked it will float the patella away from the femur.] On each side of the patella the synovial membrane extends beneath the aponeurosis of the Vasti muscles, and more especially beneath that of the Vastus internus; and below the patella it is separated from the anterior ligament by a considerable quantity of adipose tissue. In this situation it sends off a triangular prolongation, containing a few ligamentous fibres, which extends from the anterior part of the joint below the patella to the front of the intercondyloid notch. This fold has been termed the *ligamentum mucosum.* The *ligamenta alaria* consist of two fringe-like folds which extend from the sides of the ligamentum mucosum upward and laterally between the patella and femur. The synovial membrane invests the semilunar fibro-cartilages, and on the back part of the external one forms a cul-de-sac between the groove on its surface and the tendon of the Popliteus; it is continued to the articular surface of the tibia, surrounds the crucial ligaments and the inner surface of the ligaments which enclose the joint; lastly, it approaches the condyles of the femur, and from them is continued on to the lower part of the front of the shaft. The pouch of synovial membrane between the extensor tendon and front of the femur is supported during the movements of the knee by a small muscle, the Subcrureus, which is inserted into it.

The folds of synovial membrane and the fatty processes contained in them act, as it seems, mainly as padding to fill up interspaces and obviate concussions.

The *Bursæ* in connection with the synovial membrane will be found described with the regional anatomy of the popliteal space.

The *Arteries* supplying the joint are derived from the anastomotic branch of the femoral articular branches of the popliteal, recurrent branch of the anterior tibial, and descending branch from the external circumflex of the profunda.

The *Nerves* are derived from the obturator, anterior crural, and external and internal popliteal.

ACTIONS.—The knee-joint permits of movements of flexion and extension, and in certain positions of slight rotation inward and outward. The movement of flexion and extension does not, however, take place in a simple, hinge-like manner, as in other joints, but is a complicated movement consisting of an irregular motion combining a certain amount of gliding and rotation, so that the same part of one articular surface is not always applied to the same part of the other articular surface, and the axis of motion is not a fixed one. If the recently-dissected knee-joint is examined while in a condition of extreme flexion, the posterior rounded extremities of the condyles of the femur will be found to be resting against the posterior part of the articular facets on the tibia, and if a simple hinge-like movement were to take place, the axis, round which the revolving movement of the tibia occurs, would be in the back part of the condyle. If the leg is now brought forward into a position of semiflexion, the upper surface of the tibia will be seen to glide over the condyles of the femur, so that the middle part of the articular facets are in contact, and the axis of rotation must therefore be shifted forward to nearer the centre of the condyles. If the leg is now brought into the extended position, a still further gliding takes place, and a further shifting forward of the axis of rotation. This is not, however, a simple movement, but is accompanied by a certain amount of rotation outward round a vertical axis drawn through the centre of the head of the tibia. This rotation is due to the greater length of the internal condyle, and to the fact that the anterior portion of its articular surface is inclined obliquely outward. In consequence of this it will be seen that toward the close of the movement of extension—that is to say, just before complete extension is effected—the tibia is directed obliquely upward and outward over this oblique surface on the inner condyle, and the leg is therefore necessarily rotated outward. In flexion of the joint the converse of these movements takes place. The tibia glides backward round the end of the femur, and at the commencement of the movement the tibia is directed downward and inward along the oblique curve of the inner condyle, thus causing an inward rotation to the leg. [This "pronation" and "supination" of the leg amounts to about 36°. It begins when the leg is flexed at 150° to 155°, and becomes more pronounced as the joint is further flexed.]

During flexion and extension the patella moves on the lower end of the femur, but this movement is not a simple gliding one; for if the articular surface of this bone is examined, it will be found to present on each side of the central vertical ridge two less-marked transverse ridges, which divide each half of the bone into three facets, and does not present a uniform curved surface, as would be the case if a simple gliding movement took place. These three facets correspond to and denote the parts of the bone respectively in contact with the condyles of the femur during flexion, semiflexion, and extension. In flexion only the upper facets on the patella are in contact with the condyles of the femur; the lower two-thirds of the bone rest upon the mass of fat which occupies the space between the femur and tibia. In the semiflexed position of the joint the middle facets on the patella rest upon the most prominent portion of the condyles, and thus afford increased leverage to the quadriceps by increasing its distance from the centre of motion. In complete extension the patella is drawn up, so that only the lower facets are in contact with the articular surfaces of the condyles.

In addition to the slight rotation during flexion and extension the tibia enjoys an independent rotation on the condyles of the femur in certain positions of the joint. This takes place in the semiflexed position of the limb when all the ligaments are relaxed.

During *flexion* the ligamentum patellæ is put upon the stretch, as is also the posterior crucial ligament in extreme flexion. The other ligaments are all relaxed by flexion of the joint, though the relaxation of the anterior crucial ligament is very trifling. Flexion is only checked during life by the contact of the leg with the thigh. In *extension* the ligamentum patellæ becomes relaxed, and in extreme extension completely so, so as to allow free lateral movement to the patella, which then rests on the front of the lower end of the femur. The other ligaments, with the exception of the posterior crucial, which is partly relaxed, are all on the stretch. When the limb has been brought into a straight line extension is checked mainly by the tension of all the ligaments except the posterior crucial and ligamentum patellæ. [In the position at rest, when the weight is thrown on one leg, the knee-joint of this leg is slightly over-extended, so as to form an angle the apex of which is directed posteriorly, and the posterior ligament is stretched to its utmost in supporting the leg, and thus resting the muscles. At the same time, the pelvis is tilted backward, and supported by the now tense anterior part of the capsular ligament at the hip, especially the inverted Y-ligament. The pelvis is still more markedly tilted over to the other side, making the other leg relatively the longer, and thus necessitating its flexion. It is supported here by the external part of the capsular and the λ-ligaments. The changes in the level of the pelvis are best seen by comparing the levels of the two anterior superior spines on the living model; or if a light rod be fixed by adhesive plaster to these two spines, and the model alternately throw his weight on one leg and then on the other, it will show still better. The rocking of the pelvis in walking can be excellently shown by this experiment, especially in the female model. To make the rod touch the anterior superior spines, it should be of this shape, ———⌒———, to fit the projecting abdomen, or a straight rod may be fixed to the posterior superior spines, and will show the pelvic rocking equally well.] The movements of *rotation* of which the knee is susceptible are permitted in the semiflexed condition by the partial relaxation of both crucial ligaments, as well as the lateral ligaments. Rotation inward appears to be limited by the tension of the anterior crucial ligament and by the interlocking of the two ligaments, but rotation outward does not appear to be checked by either ligament, since they uncross during the execution of this movement, but by the lateral ligaments, especially the internal. The main function of the crucial ligaments is to act as a direct bond of union between the tibia and femur, preventing the former bone from being carried too far backward or forward. Thus the anterior crucial ligament prevents the tibia being carried too far forward by the extensor tendons, and the posterior crucial checks too great movement backward by the flexors. They also assist the lateral ligaments in resisting any lateral bending of the joint. The interarticular cartilages are intended, as it seems, to adapt the surface of the tibia to the shape of the femur to a certain extent, so as to fill up the intervals which would otherwise be left in the varying positions of the joint, and to interrupt the jars which would be so frequently transmitted up the limb in jumping or falls on the feet.[1] The patella is a great defence to the knee-joint from any injury inflicted in front, and it distributes upon a large and tolerably even surface during kneeling the pressure which would otherwise fall upon the prominent ridges of the condyles: it also affords leverage to the Quadriceps extensor muscle to act upon the tibia; and Mr. Ward has pointed out[2] how this leverage varies in the various positions of the joint, so that the action of the muscle produces velocity at the expense of force in the commencement of extension, and, on the contrary, at the close of extension tends to diminish the velocity, and therefore the shock to the ligaments, whilst in the standing position it draws the tibia powerfully forward, and thus maintains it in its place.

Extension of the leg on the thigh is performed by the Quadriceps extensor; *flexion*, by the hamstring muscles, assisted by the Gracilis and Sartorius; *rotation outward*, by the Biceps; and *rotation inward*, by the Popliteus, Semitendinosus, and, to a slight extent, the Semimembranosus.

III. ARTICULATIONS BETWEEN THE TIBIA AND FIBULA.

The articulations between the tibia and fibula are effected by ligaments which connect both extremities, as well as the shafts of the bones. They may, consequently, be subdivided into three sets: 1, The Superior Tibio-fibular articulation; 2, the Middle Tibio-fibular articulation; 3, the Inferior Tibio-fibular articulation.

1. SUPERIOR TIBIO-FIBULAR ARTICULATION.

This articulation is an arthrodial joint. The contiguous surfaces of the bones present two flat oval facets covered with cartilage and connected together by the following ligaments:

Anterior Superior Tibio-fibular.
Posterior Superior Tibio-fibular.

The **Anterior Superior Ligament** (Fig. 271) consists of two or three broad and flat bands which pass obliquely upward and inward from the front of the head of the fibula to the front of the outer tuberosity of the tibia.

The **Posterior Superior Ligament** is a single thick and broad band which passes from the back part of the head of the fibula to the back part of the outer tuberosity of the tibia. It is covered by the tendon of the Popliteus muscle.

A **synovial membrane** lines this articulation, which at its upper and back part is occasionally continuous with that of the knee-joint.

2. MIDDLE TIBIO-FIBULAR ARTICULATION.

An interosseous membrane extends between the contiguous margins of the tibia and fibula, and separates the muscles on the front from those on the back of the leg. It consists of a thin aponeurotic lamina composed of oblique fibres, which pass downward and outward between the interosseous ridges on the two bones. It is broader above than below, and presents at its upper part a large oval aperture for the passage of the anterior tibial artery forward to the anterior aspect of the leg, and at its lower part an opening for the passage of the anterior peroneal vessels. It is continuous below with the inferior interosseous ligament, and is perforated in numerous parts for the passage of small vessels. It is in relation in front with the Tibialis anticus, Extensor longus digitorum, Extensor proprius pollicis, Peroneus tertius, and the anterior tibial vessels and nerve; behind, with the Tibialis posticus and Flexor longus pollicis.

---

[1] Prof. Humphry teaches that the interarticular cartilages do not follow the movements of the tibia in pronation and supination; so that these movements take place between the tibia and the cartilages, while the chief movements of the joint take place between the cartilages and the femur. If this be so, it would establish an interesting analogy with other joints (such as the lower jaw) in which interarticular cartilages are present.

[2] *Human Osteology*, p. 405.

3. INFERIOR TIBIO-FIBULAR ARTICULATION.

This articulation is formed by the rough convex surface of the inner side of the lower end of the fibula, connected with a similar rough surface on the outer side of the tibia. Below, to the extent of about two lines, these surfaces are smooth and covered with cartilage, which is continuous with that of the ankle-joint. The ligaments of this joint are—

Inferior Interosseous.
Anterior Inferior Tibio-fibular.
Posterior Inferior Tibio-fibular.
Transverse.

The **Inferior Interosseous Ligament** consists of numerous short, strong fibrous bands which pass between the contiguous rough surfaces of the tibia and fibula, and constitute the chief bond of union between the bones. This ligament is continuous above with the interosseous membrane.

The **Anterior Inferior Ligament** (Fig. 275) is a flat, triangular band of fibres, broader below than above, which extends obliquely downward and outward between the adjacent margins of the tibia and fibula on the front aspect of the articulation. It is in relation in front with the Peroneus tertius, the aponeurosis of the leg, and the integument, behind with the inferior interosseous ligament, and lies in contact with the cartilage covering the astragalus.

The **Posterior Inferior Ligament**, smaller than the preceding, is disposed in a similar manner on the posterior surface of the articulation.

The **Transverse Ligament** is a long narrow band continuous with the preceding, passing transversely across the back of the joint from the external malleolus to the tibia, a short distance from its malleolar process. This ligament projects below the margin of the bones, and forms part of the articulating surface for the astragalus.

The **synovial membrane** lining the articular surface is derived from that of the ankle-joint.

ACTIONS.—The movement permitted in these articulations is limited to a very slight gliding of the articular surfaces one upon another.

IV. ANKLE-JOINT.

The **Ankle** is a ginglymus or hinge-joint. The bones entering into its formation are the lower extremity of the tibia and its malleolus and the external malleolus of the fibula. These bones are united above, and form an arch to receive the upper convex surface of the astragalus and its two lateral facets. The bony surfaces are covered with cartilage and connected together by the following ligaments:

Anterior.
Posterior.
Internal Lateral.
External Lateral.

The **Anterior Tibio-tarsal Ligament** (Fig. 274) is a broad, thin, membranous layer attached above to the margin of the articular surface of the tibia, below to the margin of the astragalus in front of its articular surface. It is in relation in front with the Extensor tendons of the toes, with the tendons of the Tibialis anticus and Peroneus tertius, and the anterior tibial vessels and nerve; behind, it lies in contact with the synovial membrane.

The **Posterior Tibio-tarsal Ligament** is very thin, and consists of a few fibres, principally transverse, which are attached to the tibia and astragalus close to their articular surfaces. Externally it is thicker than internally, where a somewhat

Fig. 274.

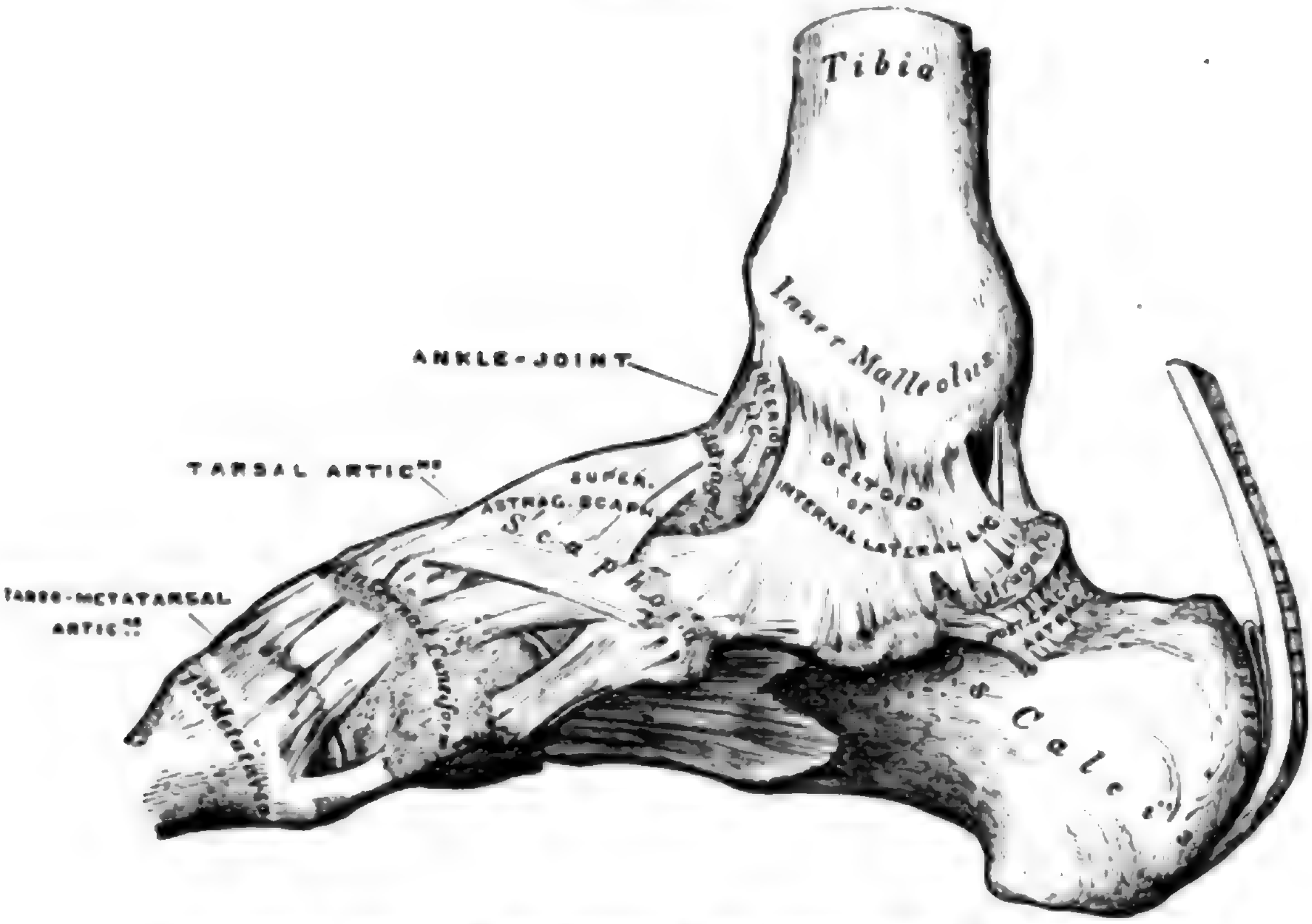
Tibia
Inner Malleolus
ANKLE-JOINT
TARSAL ARTICNS
TARSO-METATARSAL ARTICNS
SUPER. ASTRAG. SCAPH.
Scaphoid
DELTOID OF INTERNAL LATERAL LIG.
Anterior Lig.
Astragalus
Os Calcis
Internal Cuneiform
1st Metatarsal

Ankle-joint: Tarsal and Tarso-metatarsal Articulations, internal view, right side.

thickened band of transverse fibres are attached to the hollow on the inner surface of the external malleolus.

The **Internal Lateral** or **Deltoid Ligament** consists of two layers, superficial

Fig. 275.

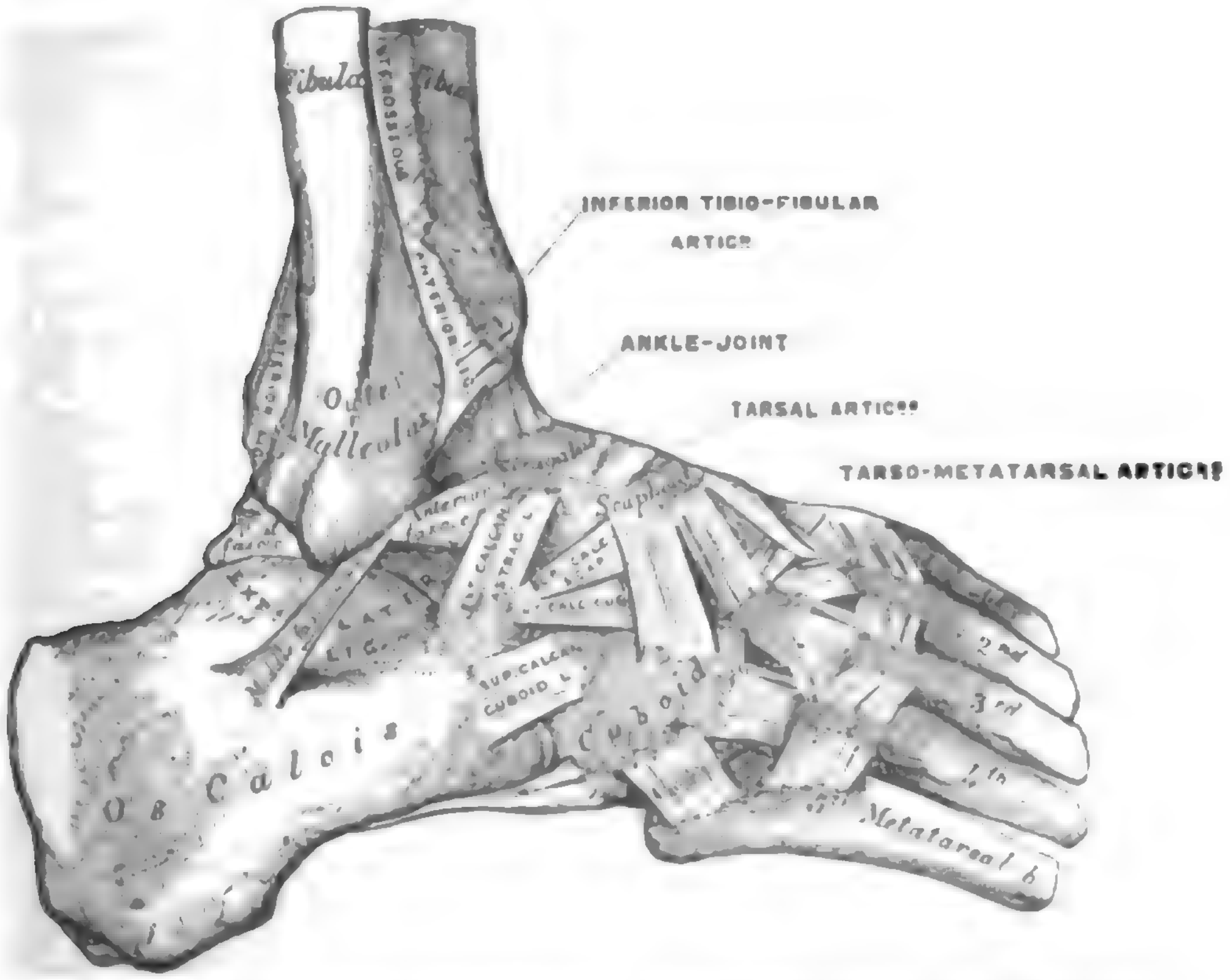
Fibula
Tibia
INTEROSSEOUS
ANTERIOR LIG.
INFERIOR TIBIO-FIBULAR ARTICN
ANKLE-JOINT
TARSAL ARTICNS
TARSO-METATARSAL ARTICNS
Outer Malleolus
Scaphoid
EXT. LATERAL LIGAMENT
SUP. CALCAN. CUBOID L.
Cuboid
Os Calcis
2nd
3rd
4th
5th Metatarsal

Ankle-joint: Tarsal and Tarso-metatarsal Articulations, external view, right side.

and deep. The *superficial layer* is a strong, flat, triangular band attached above to the apex and anterior and posterior borders of the inner malleolus. The most anterior fibres pass forward to be inserted into the scaphoid and inferior calcaneo-scaphoid ligament; the middle descend almost perpendicularly to be inserted into the sustentaculum tali of the os calcis; and the posterior fibres pass backward and outward to be attached to the inner side of the astragalus. The *deeper layer* consists of a short, thick, and strong fasciculus which passes from the apex of the malleolus to the inner surface of the astragalus, below the articular surface. This ligament is covered by the tendons of the Tibialis posticus and Flexor longus digitorum muscles.

The **External Lateral Ligament** (Fig. 275) consists of three fasciculi, taking different directions and separated by distinct intervals; for which reason it is described by some anatomists as three distinct ligaments.[1] This would seem the preferable description, were it not that the old nomenclature has passed into general use.

The *anterior fasciculus*, the shortest of the three, passes from the anterior margin of the summit of the external malleolus downward and forward to the astragalus in front of its external articular facet.

The *posterior fasciculus*, the most deeply seated, passes from the depression at the inner and back part of the external malleolus to a horizontal notch or depression on the posterior surface of the astragalus. Its fibres are almost horizontal in direction.

The *middle fasciculus*, the longest of the three, is a narrow rounded cord passing from the apex of the external malleolus downward and slightly backward to the middle of the outer side of the os calcis. It is covered by the tendons of the Peroneus longus and brevis.

The **synovial membrane** invests the inner surface of the ligaments, and sends a duplicature upward between the lower extremities of the tibia and fibula for a short distance.

Relations.—The tendons, vessels, and nerves in connection with the joint are in front, from within outward, the Tibialis anticus, Extensor proprius pollicis, anterior tibial vessels, anterior tibial nerve, Extensor communis digitorum, and Peroneus tertius; behind, from within outward, the Tibialis posticus, Flexor longus digitorum, posterior tibial vessels, posterior tibial nerve, Flexor longus pollicis; and in the groove behind the external malleolus the tendons of the Peroneus longus and brevis.

[Fig. 276.

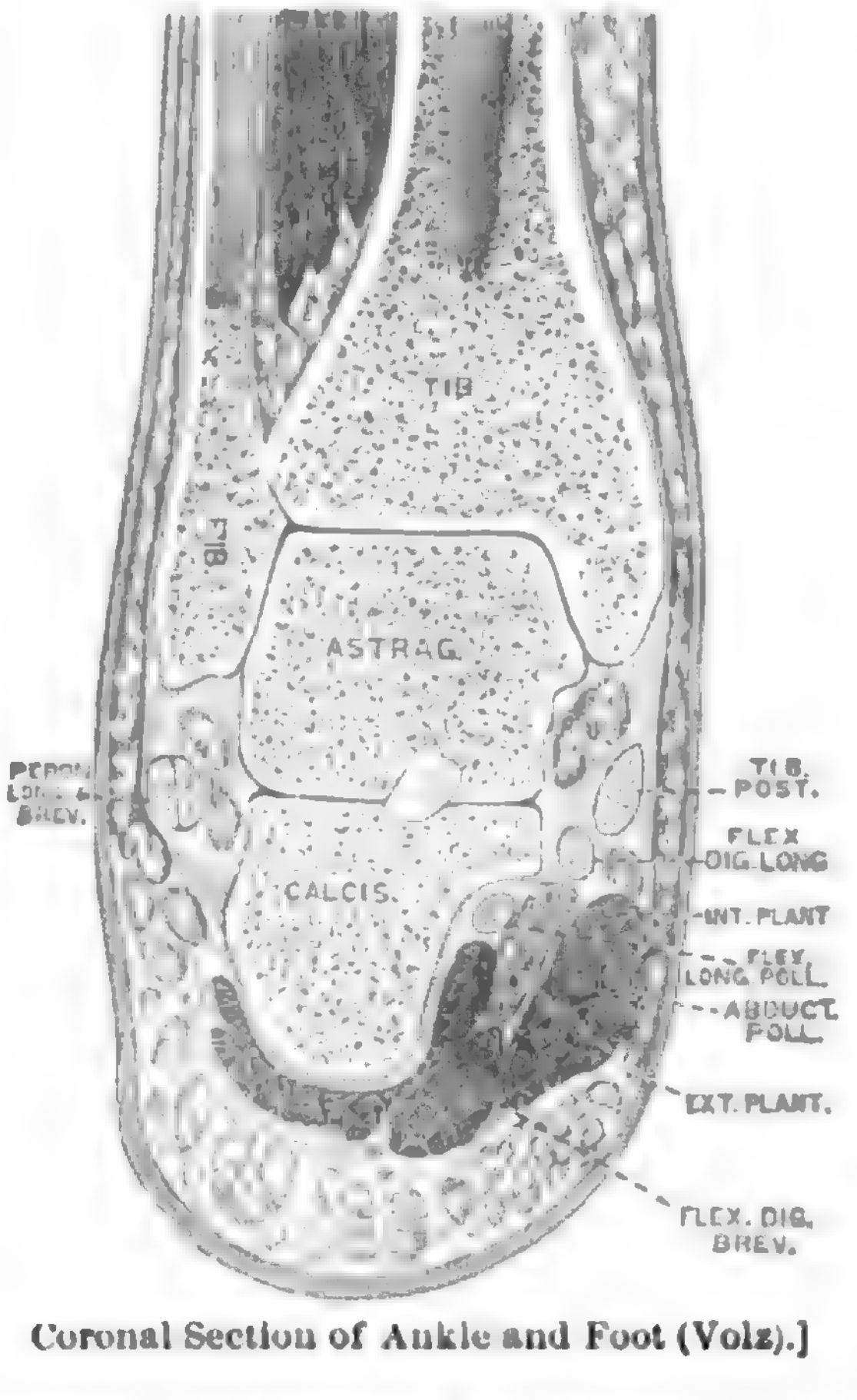

Coronal Section of Ankle and Foot (Volz).]

The *Arteries* supplying the joint are derived from the malleolar branches of the anterior tibial and peroneal.

The *Nerves* are derived from the anterior and posterior tibial.

Actions.—The movements of the joint are mainly those of flexion and extension, but a certain amount of lateral motion is permitted when the foot is in the extended position. This is in consequence of the shape of the articular surface of the astragalus, which is considerably wider in front than behind (Fig. 233, p. 285), and of the tibio-fibular mortise, which is also broader in front than behind; hence in complete extension the narrowest part of the astragalus is lodged in the widest part of the tibio-fibular arch, and therefore a certain amount of lateral movement is possible. In the flexed position, on the other hand, the astragalus is tightly embraced by the two malleoli, and no lateral movement is possible. In extreme extension there is also a slight amount of adduction, or inward movement of the fore part of the foot; this is in consequence of the external border of the upper articular surface of the astragalus being longer than the inner one and somewhat curved, which has a tendency to turn the foot inward if extension is carried to its extreme limit. Of the ligaments, the internal or deltoid is of very great power, so much so that it usually resists a force which fractures the process of bone to which it is attached. Its middle portion, together with the middle fasciculus of the external lateral ligament, binds the bones of the leg firmly to the foot and resists displacement in every direction. Its anterior and posterior fibres limit extension and flexion of the foot respectively, and the anterior fibres also limit abduction. The posterior portion of the external lateral ligament assists the middle portion in resisting the displacement of the foot backward, and deepens the cavity for the reception of the astragalus. The anterior fasciculus is a security against the displacement of the foot forward, and limits extension of the joint. The movements of abduction and adduction of the foot, together with the minute changes in form by which it is applied to the ground or takes hold of an object in climbing, etc., are mainly effected in the tarsal joints, the one which enjoys the greatest amount of motion being that between the astragalus and os calcis behind and the scaphoid and cuboid in front. This is often called the *transverse* [or *medio-*] *tarsal joint*, and it, with the subordinate joints of the tarsus, can replace the ankle-joint in a great measure when the latter has become ankylosed.

---

[1] Humphry on *The Skeleton*, p. 559.

[Fig. 277.

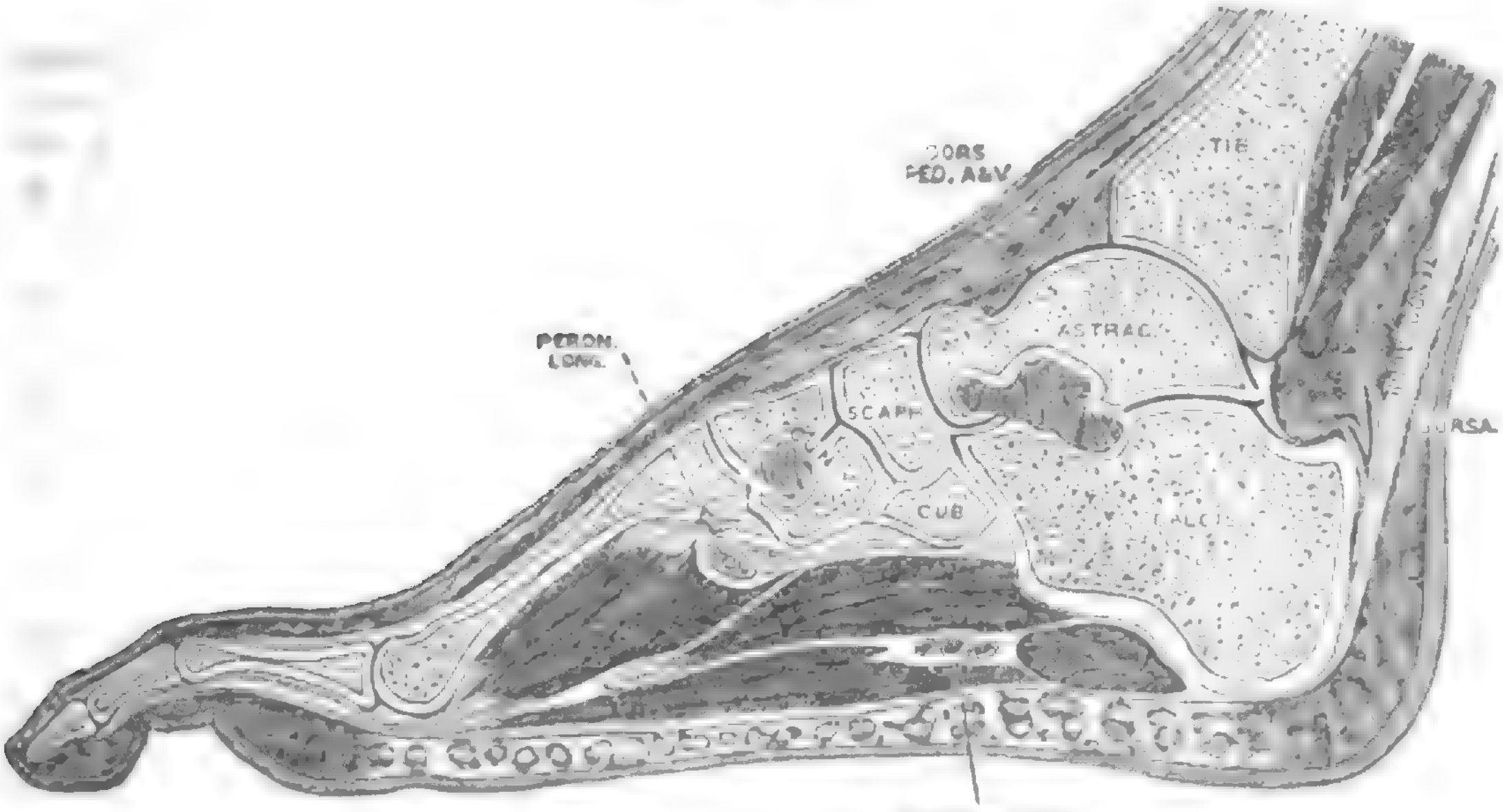

Sagittal Section of Ankle and Foot (Volz).]

Extension of the tarsal bones upon the tibia and fibula is produced by the Gastrocnemius, Soleus, Tibialis posticus, Peroneus longus and brevis, Flexor longus digitorum, and Flexor longus pollicis; *flexion*, by the Tibialis anticus, Peroneus tertius, Extensor longus digitorum, and Extensor proprius pollicis;[1] *adduction*, in the extended position, is produced by the Tibialis anticus and posticus; and *abduction*, by the Peronei.

V. Articulations of the Tarsus.

These articulations may be subdivided into three sets: 1, The articulations of the first row of tarsal bones; 2, the articulations of the second row of tarsal bones; 3, the articulations of the two rows with each other.

---

[1] The student must bear in mind that the Extensor longus digitorum and Extensor proprius pollicis are *extensors* of the toes, but *flexors* of the ankle, and that the Flexor longus digitorum and Flexor longus pollicis are *flexors* of the toes, but *extensors* of the ankle.

1. ARTICULATIONS OF THE FIRST ROW OF TARSAL BONES.

The articulations between the astragalus and os calcis are two in number—anterior and posterior. They are arthrodial joints. The bones are connected together by three ligaments:

External Calcaneo-astragaloid.
Posterior Calcaneo-astragaloid.
Interosseous.

The **External Calcaneo-astragaloid Ligament** (Fig. 275, p. 355) is a short strong fasciculus passing from the outer surface of the astragalus, immediately beneath its external malleolar facet, to the outer surface of the os calcis. It is placed in front of the middle fasciculus of the external lateral ligament of the ankle-joint, with the fibres of which it is parallel.

The **Posterior Calcaneo-astragaloid Ligament** (Fig. 274, p. 355) connects the posterior extremity of the astragalus with the upper contiguous surface of the os calcis; it is a short narrow band, the fibres of which are directed obliquely backward and inward.

The **Interosseous Ligament** forms the chief bond of union between the bones. It consists of numerous vertical and oblique fibres attached by one extremity to the groove between the articulating surface of the astragalus; by the other to a corresponding depression on the upper surface of the os calcis. It is very thick and strong, being at least an inch in breadth from side to side, and serves to unite the os calcis and astragalus solidly together.

The **synovial membranes** (Fig. 279) are two in number—one for the posterior calcaneo-astragaloid articulation; a second for the anterior calcaneo-astragaloid joint. The latter synovial membrane is continued forward between the contiguous surfaces of the astragalus and scaphoid bones.

2. ARTICULATIONS OF THE SECOND ROW OF TARSAL BONES.

The articulations between the scaphoid, cuboid, and three cuneiform are effected by the following ligaments:

Dorsal.
Plantar.
Interosseous.

The **Dorsal Ligaments** are small bands of parallel fibres which pass from each bone to the neighboring bones, with which it articulates.

The **Plantar Ligaments** have the same arrangement on the plantar surface.

The **Interosseous Ligaments** are four in number. They consist of strong transverse fibres which pass between the rough non-articular surfaces of adjoining bones. There is one between the sides of the scaphoid and cuboid, a second between the internal and middle cuneiform bones, a third between the middle and external cuneiform, and a fourth between the external cuneiform and cuboid. The scaphoid and cuboid when in contact present each a small articulating facet covered with cartilage, and lined either by a separate synovial membrane or by an offset from the great tarsal synovial membrane.

3. ARTICULATIONS OF THE TWO ROWS OF THE TARSUS WITH EACH OTHER.

These may be conveniently divided into three sets: the joint between the os calcis and the cuboid, the ligaments connecting the os calcis with the scaphoid, the joint between the astragalus and the scaphoid.

The ligaments connecting the os calcis with the cuboid are four in number:

Dorsal.. { Superior Calcaneo-cuboid.
Internal Calcaneo-cuboid (Interosseous).
Plantar. { Long Calcaneo-cuboid.
Short Calcaneo-cuboid.

The **Superior Calcaneo-cuboid Ligament** (Fig. 275) is a thin and narrow fasciculus which passes between the contiguous surfaces of the os calcis and cuboid on the dorsal surface of the joint.

The **Internal Calcaneo-cuboid (Interosseous) Ligament** (Fig. 275) is a short but thick and strong band of fibres arising from the os calcis in the deep hollow which intervenes between it and the astragalus, and closely blended at its origin with the superior calcaneo-scaphoid ligament. It is inserted into the inner side of the cuboid bone. This ligament forms one of the chief bonds of union between the first and second row of the tarsus.

The **Long Calcaneo-cuboid** (Fig. 278), the more superficial of the two plantar ligaments, is the longest of all the ligaments of the tarsus: it is attached to the under surface of the os calcis, from near the tuberosities, as far forward as the anterior tubercle; its fibres pass forward to be attached to the ridge on the under surface of the cuboid bone, the more superficial fibres being continued onward to the bases of the second, third, and fourth metatarsal bones. This ligament crosses the groove on the under surface of the cuboid bone, converting it into a canal for the passage of the tendon of the Peroneus longus.

The **Short Calcaneo-cuboid Ligament** lies nearer to the bones than the preceding, from which it is separated by a little areolar adipose tissue. It is exceedingly broad, about an inch in length, and extends from the tubercle and the depression in front of it on the fore part of the under surface of the os calcis to the inferior surface of the cuboid bone behind the peroneal groove. A separate synovial membrane is found in the calcaneo-cuboid articulation.

The ligaments connecting the os calcis with the scaphoid are two in number:

Superior Calcaneo-scaphoid.
Inferior Calcaneo-scaphoid.

The **Superior Calcaneo-scaphoid** (Fig. 275) arises, as already mentioned, with the internal calcaneo-cuboid in the deep hollow between the astragalus and os calcis; it passes forward from the inner side of the anterior extremity of the os calcis to the outer side of the scaphoid bone. These two ligaments resemble the letter Y, being blended together behind, but separated in front.

The **Inferior Calcaneo-scaphoid** (Fig. 278) is by far the larger and stronger of the two ligaments of this articulation: it is a broad and thick band of fibres, which passes forward and inward from the interior and inner extremity of the os calcis to the under surface of the scaphoid bone. This ligament not only serves to connect the os calcis and scaphoid, but supports the head of the astragalus, forming part of the articular cavity in which it is received. The *upper surface* is lined by the synovial membrane continued from the anterior calcaneo-astragaloid articulation. Its *under surface* is in contact with the tendon of the Tibialis posticus muscle.[1]

FIG. 278.

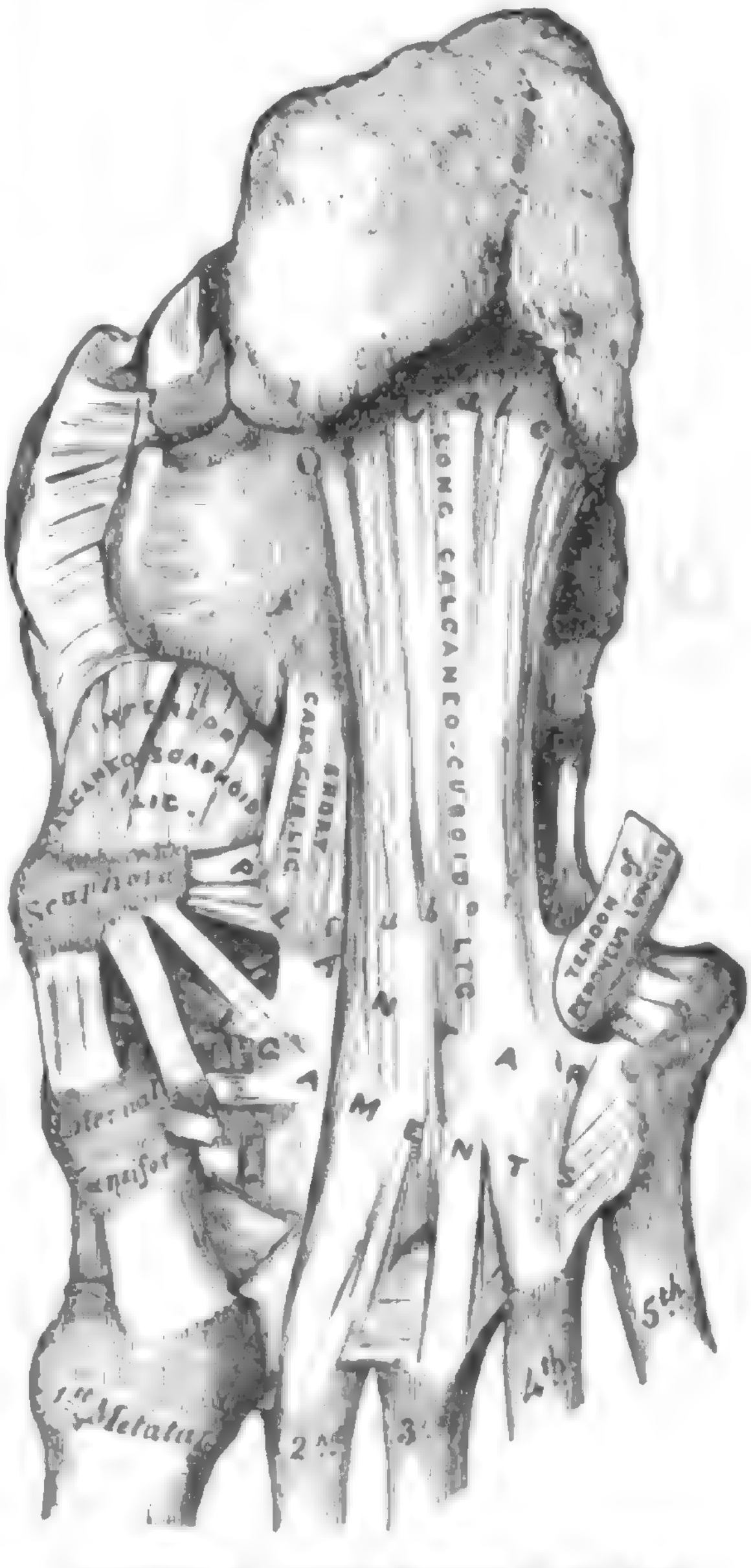

Ligaments of Plantar Surface of the Foot.

---

[1] Mr. Hancock describes an extension of this ligament upward on the inner side of the foot, which completes the socket of the joint in that direction (*Lancet*, 1866, vol. i. p. 618).

The articulation between the astragalus and scaphoid is an arthrodial joint, the rounded head of the astragalus being received into the concavity formed by the posterior surface of the scaphoid, the anterior articulating surface of the calcaneum, and the upper surface of the calcaneo-scaphoid ligament, which fills up the triangular interval between those bones. The only ligament of this joint is the *superior astragalo-scaphoid*, a broad band which passes obliquely forward from the neck of the astragalus to the superior surface of the scaphoid bone. It is thin and weak in texture, and covered by the Extensor tendons. The inferior calcaneo-scaphoid supplies the place of an inferior ligament.

The **synovial membrane** which lines the joint is continued forward from the anterior calcaneo-astragaloid articulation. This articulation permits of considerable mobility, but its feebleness is such as to allow occasionally of dislocation of the astragalus.

Actions.—The movements permitted between the bones of the first row, the astragalus, and os calcis are limited to a gliding upon each other from before backward and from side to side. The gliding movement which takes place between the bones of the second row is very slight, the articulation between the scaphoid and cuneiform bones being more movable than those of the cuneiform with each other and with the cuboid. The movement which takes place between the two rows is more extensive, and consists in a sort of rotation by means of which the sole of the foot may be slightly flexed and extended and carried inward and outward.

VI. Tarso-metatarsal Articulations.

These are arthrodial joints. The bones entering into their formation are four tarsal bones—viz. the internal, middle, and external cuneiform, and the cuboid—which articulate with the metatarsal bones of the five toes. The metatarsal bone of the great toe articulates with the internal cuneiform; that of the second is deeply wedged in between the internal and external cuneiform, resting against the middle cuneiform, and being the most strongly articulated of all the metatarsal bones; the third metatarsal articulates with the extremity of the external cuneiform; the fourth with the cuboid and external cuneiform; and the fifth with the cuboid. The articular surfaces are covered with cartilage lined by synovial membrane, and connected together by the following ligaments:

Dorsal. Plantar.
Interosseous.

The **Dorsal Ligaments** consist of strong, flat, fibrous bands which connect the tarsal with the metatarsal bones. The first metatarsal is connected to the internal cuneiform by a single broad, thin, fibrous band; the second has three dorsal ligaments, one from each cuneiform bone; the third has one from the external cuneiform; and the fourth and fifth have one each from the cuboid.

The **Plantar Ligaments** consist of longitudinal and oblique fibrous bands connecting the tarsal and metatarsal bones, but disposed with less regularity than on the dorsal surface. Those for the first and second metatarsal are the most strongly marked; the second and third metatarsal receive strong fibrous bands, which pass obliquely across from the internal cuneiform; the plantar ligaments of the fourth and fifth metatarsal consist of a few scanty fibres derived from the cuboid.

The **Interosseous Ligaments** are three in number—internal, middle, and external. The *internal* one passes from the outer extremity of the internal cuneiform to the adjacent angle of the second metatarsal. The *middle* one, less strong than the preceding, connects the external cuneiform with the adjacent angle of the second metatarsal. The *external* interosseous ligament connects the outer angle of the external cuneiform with the adjacent side of the third metatarsal.

The **synovial membranes** (Fig. 279) found in the articulations of the tarsus and metatarsus are six in number—one for the posterior calcaneo-astragaloid articulation; a second for the anterior calcaneo-astragaloid and astragalo-scaphoid articulations; a third for the calcaneo-cuboid articulation; a fourth for the articulations of the scaphoid with the three cuneiform, the three cuneiform with each other, the external cuneiform with the cuboid, and the middle and external cuneiform with the bases of the second and third metatarsal bones; a fifth for the metatarsal bone of the great toe and the internal cuneiform; and a sixth for the fourth and fifth metatarsal bones with the cuboid. A small synovial membrane is sometimes found between the contiguous surfaces of the scaphoid and cuboid bones.

FIG. 279.

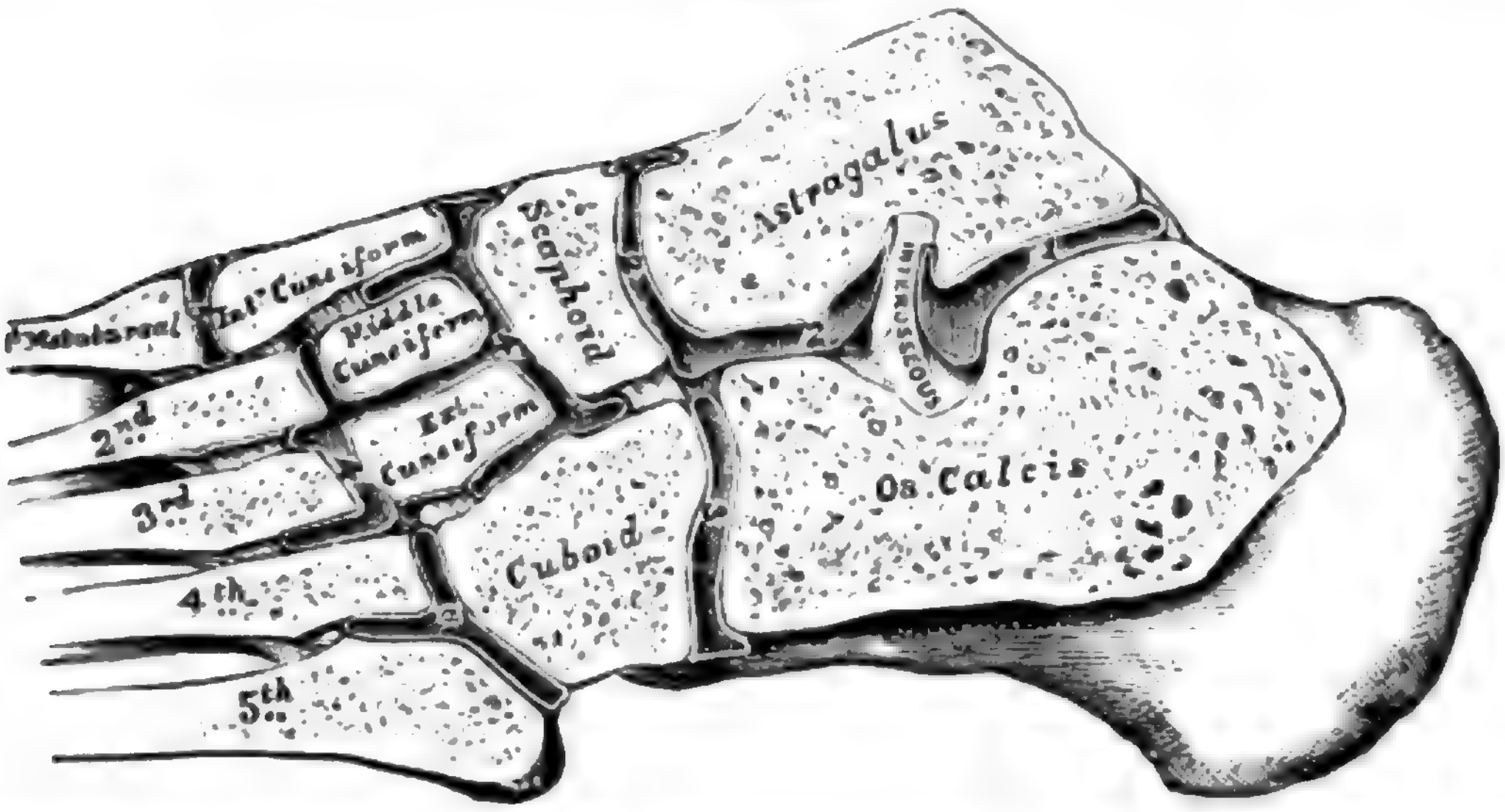

Oblique Section of the Articulations of the Tarsus and Metatarsus, showing the six synovial membranes.

ARTICULATIONS OF THE METATARSAL BONES WITH EACH OTHER.

The bases of the metatarsal bones, except the first, are connected together by dorsal, plantar, and interosseous ligaments. The *dorsal* and *plantar ligaments* pass from one metatarsal bone to another. The *interosseous ligaments* lie deeply between the rough, non-articular portions of the lateral surfaces. The articular surfaces are covered with cartilage, and provided with synovial membrane continued forward from the tarso-metatarsal joints. The digital extremities of the metatarsal bones are united by the *transverse metatarsal ligament*. It connects the great toe with the rest of the metatarsal bones, and in this respect differs from the transverse ligament in the hand, which does not extend to the metacarpal bone of the thumb.

ACTIONS.—The movement permitted in the tarsal ends of the metatarsal bones is limited to a slight gliding of the articular surfaces upon one another; considerable motion, however, takes place in the digital extremities.

VII. METATARSO-PHALANGEAL ARTICULATIONS.

The heads of the metatarsal bones are connected with the concave articular surfaces of the first phalanges by the following ligaments:

Plantar. Two Lateral.

Their arrangement is precisely similar to the corresponding parts in the hand. The expansion of the Extensor tendon supplies the place of a dorsal ligament.

ACTIONS.—The movements permitted in the metatarso-phalangeal articulations are flexion, extension, abduction, and adduction.

VIII. ARTICULATIONS OF THE PHALANGES.

The ligaments of these articulations are similar to those found in the hand, each pair of phalanges being connected by a plantar and two lateral ligaments, and their articular surfaces lined by synovial membrane. Their actions are also similar.

The Muscles and Fasciæ.

THE Muscles are connected with the bones, cartilages, ligaments, and skin, either directly or through the intervention of fibrous structures called tendons or aponeuroses. Where a muscle is attached to bone or cartilage the fibres terminate in blunt extremities upon the periosteum or perichondrium, and do not come into direct relation with the osseous or cartilaginous tissue. Where muscles are connected with the skin, they either lie as a flattened layer beneath it or are connected with its areolar tissue by larger or smaller bundles of fibres, as in the muscles of the face.

The muscles vary extremely in their *form*. In the limbs they are of considerable length, especially the more superficial ones, the deep ones being generally broad; they surround the bones and form an important protection to the various joints. In the trunk they are broad, flattened, and expanded, forming the parietes of the cavities which they enclose; hence the reason of the terms *long*, *broad*, *short*, etc. used in the description of a muscle.

There is a considerable variation in the *arrangement of the fibres* of certain muscles with reference to the tendons to which they are attached In some the fibres are arranged longitudinally and terminate at either end in a narrow tendon. If the fibres converge, like the plumes of a pen, to one side of a tendon which runs the entire length of a muscle, the muscle is said to be *penniform*, as the Peronei; if they converge to both sides of the tendon, the muscle is called *bipenniform*, as the Rectus femoris; if they converge from a broad surface to a narrow tendinous point, the muscle is said to be *radiated*, as the Temporal and Glutei muscles.

[The arrangement of the muscular fibres in respect of their attachment to the tendons of origin and insertion is a matter of great importance as to their relative strength and range of contraction. Thus in Fig. 280 A, the muscular belly, M, is a direct continuation of the tendons, and the length of the muscular belly is the same as that of the individual fibres. In B and C the muscular bellies arise from aponeuroses on their surfaces, but the arrangement of the fibres is very different. In B the fibres are many and short; the fibres arising from the upper end of one aponeurosis are inserted into the upper end of the other aponeurosis, and *vice versâ*. In this case the muscular belly *a* to *b* is apparently long, but the individual fibres are short, but very many, thus giving great power and short range, as in the Triceps, the hamstrings, etc. In C the muscular belly is of the same shape and length as in B, but the muscular fibres, while they are comparatively few, are nearly as long as the belly, giving great range, with lessened strength. In D the upper tendon penetrates the tissue of the muscle, as in the Rectus femoris, and the short muscular fibres are inserted into aponeuroses which terminate in the lower tendon, and again give great power and short range.]

They differ no less in *size:* the Gastrocnemius forms the chief bulk of the back of the leg, and the fibres of the Sartorius are nearly two feet in length, whilst the Stapedius, a small muscle of the internal ear, weighs about a grain and its fibres are not more than two lines in length.

[It is worthy of note that in the well-nourished living model the projecting bony points of the skeleton—*e. g.* great trochânter, vertebral spines, etc—are rep-

---

[1] The Muscles and Fasciæ are described conjointly, in order that the student may consider the arrangement of the latter in his dissection of the former. It is rare for the student of anatomy in this country to have the opportunity of dissecting the fasciæ separately; and it is for this reason, as well as from the close connection that exists between the muscles and their investing sheaths, that they are considered together. Some general observations are first made on the anatomy of the muscles and fasciæ, the special description being given in connection with the different regions.

resented by depressions instead of projections. The reason for this is the bulk of the neighboring muscles, which usually arise by small tendons from such bony prominences, the tendons quickly giving place to the large muscular bellies. In very thin persons this rule is reversed, the skeleton forms showing, while in long sickness the wasting of these muscles and the fat reproduces the bony prominences of the skeleton and leads to bed-sores.]

The *names* applied to the various muscles have been derived—1, from their situation, as the Tibialis, Radialis, Ulnaris, Peroneus; 2, from their direction, as the Rectus abdominis, Obliqui capitis, Transversalis; 3, from their uses, as Flexors, Extensors, Abductors, etc.; 4, from their shape, as the Deltoid, Trapezius, Rhomboideus; 5, from the number of their divisions, as the Biceps, the Triceps; 6, from their points of attachment, as the Sterno-cleido-mastoid, Sterno-hyoid, Sterno-thyroid. [In the Latin names of the muscles it must be remembered that the word "musculus" always is supposed to precede the remainder of the name, which consists really of one or more adjectives qualifying this name. Many of these, however, are abbreviated, as "Sterno-hyoid" for "musculus sterno-hyoideus."]

[Fig. 280.

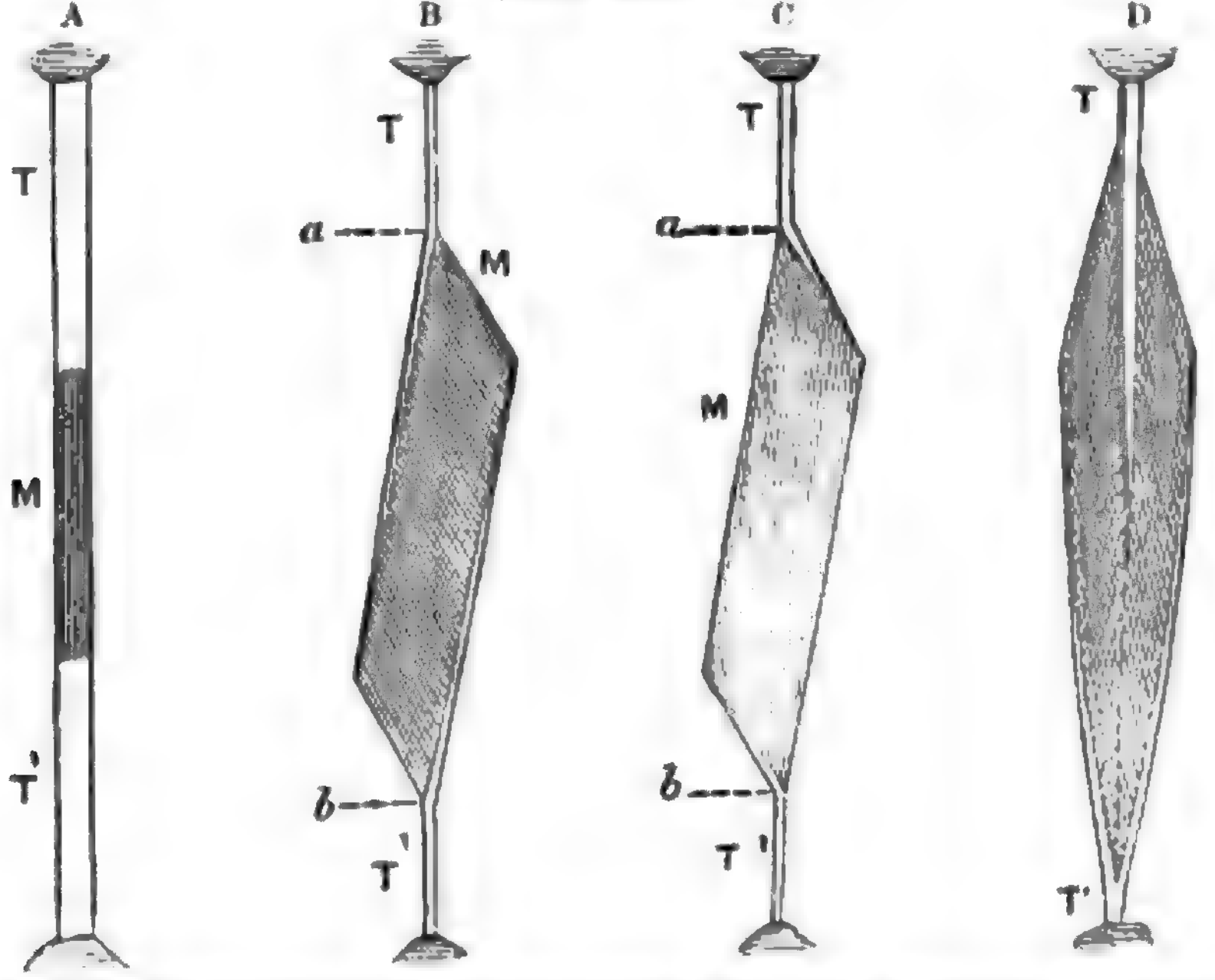

Arrangement of Muscular Fibres in Muscles in relation to the tendons and muscular aponeuroses: T, T', tendons of origin and insertion; M, muscular belly; *a*, *b*, length of muscular belly (Beaunis and Bouchard).]

In the description of a muscle the term *origin* is meant to imply its more [usually] fixed or central attachment, and the term *insertion* the movable point to which the force of the muscle is directed; but the origin is absolutely fixed in only a very small number of muscles, such as those of the face, which are attached by one extremity to the bone and by the other to the movable integument; in the greater number the muscle can be made to act *from either extremity*.

[To ascertain the *action* of any *single* muscle, the best means is to apply electricity to it on the living model. (See figures at the end of the section on the Muscles.) On the cadaver any motion which relaxes the muscle represents its active contraction, while any which makes it tense is the reverse of its action.]

In the *dissection* of the muscles the student should pay especial attention to the exact *origin*, *insertion*, and *actions* of each, and its more important *relations* with surrounding parts. An accurate knowledge of the points of attachment of the muscles is of great importance in the determination of their action. By a knowledge of the action of the muscles the surgeon is able to explain the causes of displacement in various forms of fracture and the causes which produce distortion in various deformities, and consequently to adopt appropriate treatment in each case. The relations also of some of the muscles, especially those in immediate apposition with the larger blood-vessels, and the surface-markings they produce, should be especially remembered, as they form useful guides in the application of a ligature to those vessels. [After dissecting superficial muscles, it is often desirable to cut them, so as to reach the deeper structures. In doing so it is better not to cut them at their origin or insertion, but somewhere near the middle, so that the origin and insertion may be the better studied after more thorough dissection. If a number of muscles lie together, as in the forearm, cut them at different levels, so that the upper and lower portions may be the better recognized.

It is especially recommended to the student *not* to dissect the muscles of the *face* and *perineum* until he has dissected those of other parts of the body, as these muscles present peculiarities which make their dissection very difficult. (See p. 365 and the Perineum.)]

Tendons are white, glistening, fibrous cords varying in length and thickness, sometimes round, sometimes flattened, of considerable strength, and devoid of elasticity. They consist almost entirely of white fibrous tissue, the fibrils of which have an undulating course parallel with each other and are firmly united together. They are very sparingly supplied with blood-vessels, the smaller tendons presenting in their interior not a trace of them. Nerves also are not present in the smaller tendons; but the larger ones, as the tendo Achillis, receive nerves which accompany the nutrient vessels. The tendons consist principally of a substance which yields gelatin.

[Remarkable changes occur in the muscles with *age*. In childhood the muscular bellies are relatively long and the tendons short. With advancing years the tendons invade the muscular bellies, so that the contractile element is a constantly diminishing factor. This accounts for the greater agility and suppleness of youth, which as we get older is lost to such a degree that professional acrobats well know that to excel in such athletic feats it is needful to begin in childhood and to practise these feats constantly. A baby can readily put its feet in its mouth, or when sitting on a bed with the legs at right angles with the body can easily lift the legs to an acute angle with the trunk—a feat that is impossible with an adult, since the ligamentous action of the muscles (p. 301) has been increased by the preponderance of the tendon over the muscular belly. These natural limitations of motion are always to be considered by the surgeon when making passive motion.]

Aponeuroses are flattened or ribbon-shaped tendons of a pearly-white color, iridescent, glistening, and similar in structure to the tendons. They are destitute of nerves, and the thicker ones are only sparingly supplied with blood-vessels.

The tendons and aponeuroses are connected, on the one hand, with the muscles, and on the other hand with the movable structures, as the bones, cartilages, ligaments, fibrous membranes (for instance, the sclerotic), and the synovial membranes (subcrureus, subanconeus). Where the muscular fibres are in a direct line with those of the tendon or aponeurosis, the two are directly continuous, the muscular fibre being distinguishable from that of the tendon only by its striation. But where the muscular fibre joins the tendon or aponeurosis at an oblique angle, the former terminates, according to Kölliker, in rounded extremities, which are received into corresponding depressions on the surface of the latter, the connective tissue between the fibres being continuous with that of the tendon. The latter mode of attachment occurs in all the penniform and bipenniform muscles, and in those muscles the tendons of which commence in a membranous form, as the Gastrocnemius and Soleus.

The *fasciæ* (*fascia*, a bandage) are fibro-areolar or aponeurotic laminæ of variable thickness and strength, found in all regions of the body, investing the softer and more delicate organs. The fasciæ have been subdivided, from the situation in which they are found, into two groups, superficial and deep.

The *superficial fascia* is found immediately beneath the integument over almost the entire surface of the body. It connects the skin with the deep or aponeurotic fascia, and consists of fibro-areolar-tissue, containing in its meshes follicles of fat in varying quantity. In the eyelids and scrotum, where adipose tissue is rarely deposited, this tissue is very liable to serous infiltration. The superficial fascia varies in thickness in different parts of the body: in the groin it is so thick as to be capable of being subdivided into several laminæ, but in the palm of the hand it is of extreme thinness and intimately adherent to the integument. The superficial fascia is capable of separation into two or more layers, between which are found the superficial vessels and nerves [the mammary gland] and the superficial lymphatic glands, as the superficial epigastric vessels in the abdominal region, the radial and ulnar veins in the forearm, the saphenous veins in the leg and thigh: certain cutaneous muscles also are situated in the superficial fascia, as the Platysma myoides in the neck and the Orbicularis palpebrarum around the eyelids. This fascia is most distinct at the lower part of the abdomen, the scrotum, perineum, and extremities; is very thin in those regions where muscular fibres are inserted into the integument, as on the side of the neck, the face, and around the margin of the anus; and is almost entirely wanting in the palms of the hands and soles of the feet, where the integument is adherent to the deep fascia.

The superficial fascia connects the skin to the subjacent parts, facilitates the movement of the skin, serves as a soft nidus for the passage of vessels and nerves to the integument, and retains the warmth of the body, since the adipose tissue contained in its areolæ is a bad conductor of caloric.

The *deep fascia* is a dense, inelastic, unyielding fibrous membrane, forming sheaths for the muscles and affording them broad surfaces for attachment. It consists of shining tendinous fibres placed parallel with one another and connected together by other fibres disposed in a rectilinear manner. It is usually exposed on the removal of the superficial fascia, forming a strong investment, which not only binds down collectively the muscles in each region, but gives a separate sheath to each, as well as to the vessels and nerves. The fasciæ are thick in unprotected situations, as on the outer side of a limb, and thinner on its inner side. The deep fasciæ assist the muscles in their action by the degree of tension and pressure they make upon the surface; and in certain situations this is increased and regulated by muscular action, as, for instance, by the Tensor vaginæ femoris and Gluteus maximus in the thigh, by the Biceps in the leg, and the Palmaris longus in the hand. In the limbs the fasciæ not only invest the entire limb, but give off septa which separate the various muscles and are attached beneath to the periosteum: these prolongations of fasciæ are usually spoken of as intermuscular septa.

The Muscles and Fasciæ may be arranged, according to the general division of the body, into those of the cranium, face, and neck, those of the trunk, those of the upper extremity, and those of the lower extremity.

MUSCLES AND FASCIÆ OF THE CRANIUM AND FACE.

[The muscles of the face may be divided into two classes: the muscles of *Expression*, supplied by the *seventh* nerve, and the muscles of *Mastication* (Masseter, Temporal, and Pterygoids), supplied by the *fifth* nerve. The muscles of expression differ from those of the body in general in several particulars. They do not go from bone to bone, but from bone to soft parts, and in the sphincters of the mouth and eyelids, as is the case in all sphincter muscles, the connection to the bone is very slight. They have no proper tendons of origin or insertion, as a rule. They have no muscular sheath, and are very loose in texture (compare Fig. 284), the fibres being intermingled with fatty and fibrous tissue. Frequently, fibres beginning in one muscle, especially those at its periphery, pass into another muscle, thus modifying greatly the action of both. They vary in development, not only from person to person, and so vary the expression; but also in the same person at different ages, and on the two sides of the face great variations occur which influence the expression. Sir Charles Bell's and Darwin's works on *Expression* should be carefully read by the student who desires to understand them well.]

The muscles of the cranium and face consist of ten groups, arranged according to the region in which they are situated:

1. Cranial Region.
2. Auricular Region.
3. Palpebral Region.
4. Orbital Region.
5. Nasal Region.
6. Superior Maxillary Region.
7. Inferior Maxillary Region.
8. Intermaxillary Region.
9. Temporo-maxillary Region.
10. Pterygo-maxillary Region.

The muscles contained in each of these groups are the following:

1. *Cranial Region.*

Occipito-frontalis.

2. *Auricular Region.*

Attollens aurem.
Attrahens aurem.
Retrahens aurem.

3. *Palpebral Region.*

Orbicularis palpebrarum.
Corrugator supercilii.
Tensor tarsi.

4. *Orbital Region.*

Levator palpebræ.
Rectus superior.
Rectus inferior.
Rectus internus.
Rectus externus.
Obliquus superior.
Obliquus inferior.

5. *Nasal Region.*

Pyramidalis nasi.
Levator labii superioris alæque nasi.
Dilatator naris posterior.
Dilatator naris anterior.
Compressor nasi.
Compressor narium minor.
Depressor alæ nasi.

6. *Superior Maxillary Region.*

Levator labii superioris.
Levator anguli oris.
Zygomaticus major.
Zygomaticus minor.

7. *Inferior Maxillary Region.*

Levator labii inferioris.
Depressor labii inferioris.
Depressor anguli oris.

8. *Intermaxillary Region.*

Buccinator.
Risorius.
Orbicularis oris.

9. *Temporo-maxillary Region.*

Masseter.
Temporal.

10. *Pterygo-maxillary Region.*

Pterygoideus externus.
Pterygoideus internus.

1. CRANIAL REGION.

Occipito-frontalis.

Dissection (Fig. 281).—The head being shaved and a block placed beneath the back of the neck, make a vertical incision through the skin from before backward, commencing at the root of the nose in front and terminating behind at the occipital protuberance; make a second incision in a horizontal direction along the forehead and round the side of the head from the anterior to the posterior extremity of the preceding. Raise the skin in front from the subjacent muscle from below upward: this must be done with extreme care, removing the integument from the outer surface of the vessels and the nerves which lie between the two.

The **Superficial Fascia** in the cranial region is a firm, dense layer, intimately adherent to the integument and to the Occipito-frontalis and its tendinous aponeurosis; it is continuous behind with the superficial fascia at the back part of the neck, and laterally is continued over the temporal fascia.

The **Occipito-frontalis** (Figs. 282, 284) is a broad musculo-fibrous layer which covers the whole of one side of the vertex of the skull from the occiput to the eyebrow. It consists of two muscular slips separated by an intervening tendinous aponeurosis. The *occipital portion*, thin, quadrilateral in form, and about an inch and a half in length, arises from the outer two-thirds of the superior curved line of the occipital bone and from the mastoid portion of the temporal. Its fibres of origin are tendinous, but they soon become muscular, and ascend in a parallel direction to terminate in the tendinous aponeurosis. The *frontal portion* is thin, of a quadrilateral form, and intimately adherent to the skin. It is broader, its fibres are longer, and their structure paler than the occipital portion. Its internal fibres are continuous with those of the pyramidalis nasi. Its middle fibres become blended with the Corrugator supercilii and Orbicularis, and the outer fibres are also blended with the latter muscle over the external angular process. According to Theile, the innermost fibres are attached to the nasal bones, the outer to the external angular process of the frontal bone. From this attachment the fibres are directed upward and join the aponeurosis below the coronal suture. The inner margins of the frontal portions of the two muscles are joined together for some distance above the root of the nose; but between the occipital portions there is a considerable though variable interval which is occupied by the aponeurosis.

FIG. 281.

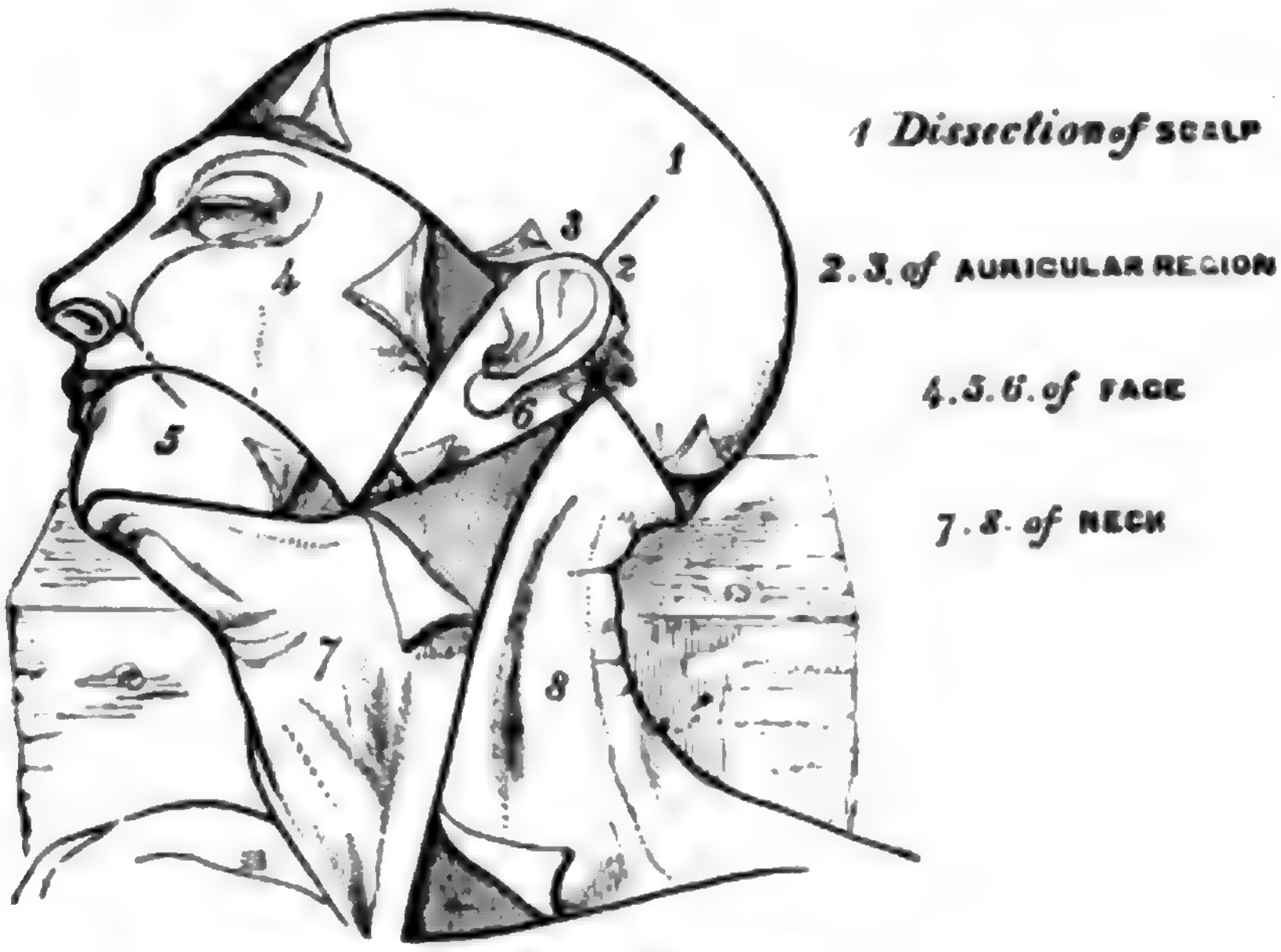

Dissection of the Head, Face, and Neck.

The **aponeurosis** [*galea capitis*] covers the upper part of the vertex of the skull, being continuous in the middle line with the aponeurosis of the opposite muscle. Behind it is attached, in the interval between the occipital origins, to the occipital protuberance and superior curved lines above the attachment of the Trapezius; in front it forms a short angular prolongation between the frontal portions; and on each side it has connected with it it the Attollens and Attrahens aurem muscles: in this situation it loses its aponeurotic character, and is continued over the temporal fascia to the zygoma as a layer of laminated areolar tissue. This aponeurosis is closely connected to the integument by a dense fibro-cellular tissue which contains much granular fat, and in which ramify the numerous vessels and nerves of the integument; it is loosely connected with the pericranium by a quantity of loose cellular tissue which allows of a considerable degree of movement of the integument.

NERVES.—The frontal portion of the Occipito-frontalis is supplied by the facial nerve, its occipital portion by the posterior auricular branch of the facial, and sometimes by the occipitalis minor.

ACTIONS.—The frontal portion of the muscle raises the eyebrows and the skin over the root of the nose, and at the same time draws the scalp forward, throwing the integument of the forehead into transverse wrinkles. The posterior portion draws the scalp backward. By bringing alternately into action the occipital and frontal portions the entire scalp may be moved forward and backward. In the ordinary action of the muscles the eyebrows are elevated and at the same time the aponeurosis is fixed by the posterior portion, thus giving to the face the expression of surprise: if the action is more exaggerated, the eyebrows are still farther

FIG. 282.

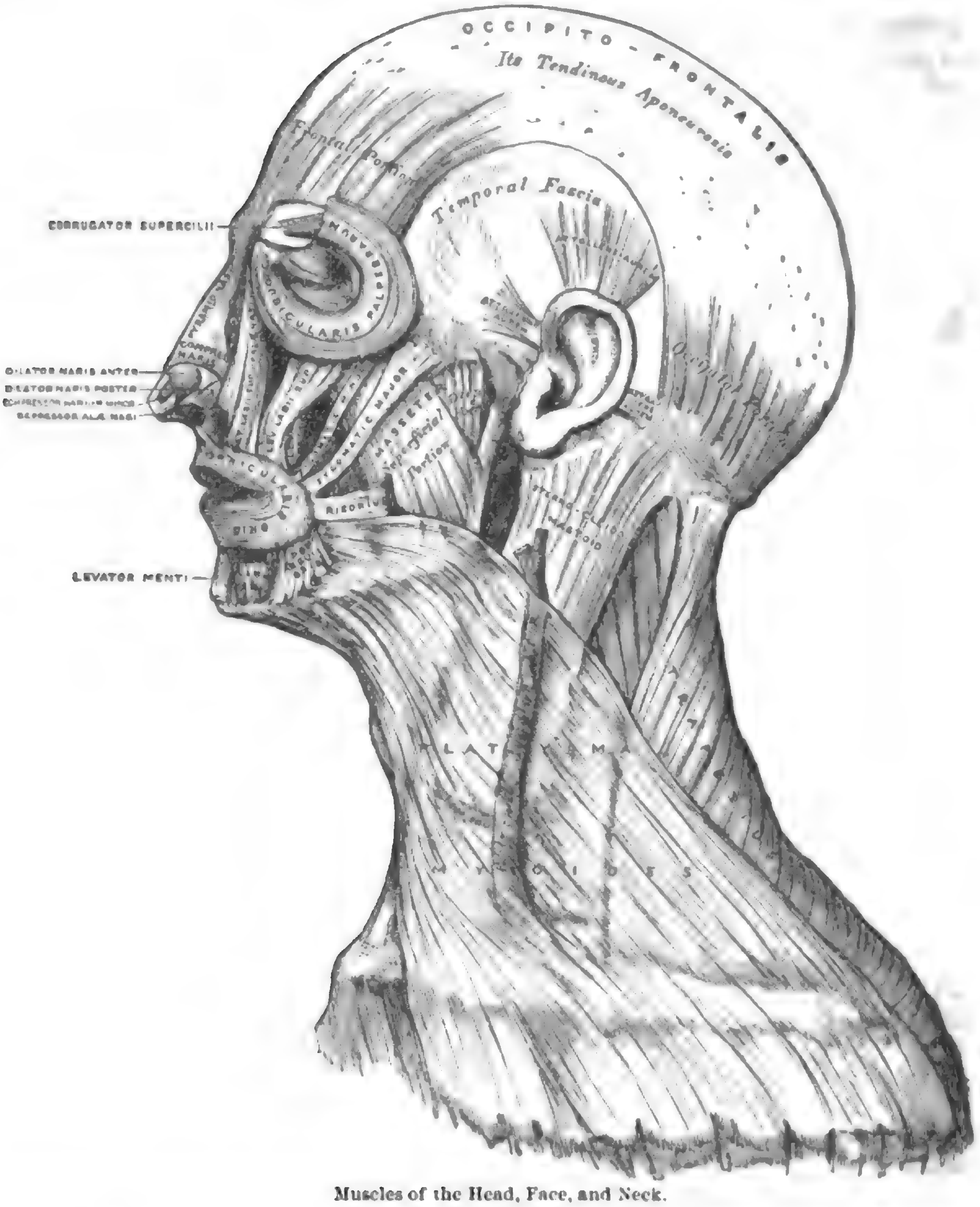
OCCIPITO-FRONTALIS
Its Tendinous Aponeurosis
Frontal Portion
Temporal Fascia
CORRUGATOR SUPERCILII
ORBICULARIS PALPEBRARUM
COMPRESSOR NARIS
DILATOR NARIS ANTER.
DILATOR NARIS POSTER.
COMPRESSOR NARIUM MINOR
DEPRESSOR ALÆ NASI
ZYGOMATIC MAJOR
MASSETER
Superficial Portion
RISORIUS
ORBICULARIS ORIS
LEVATOR MENTI
STERNO-CLEIDO-MASTOID
Occipital Portion
PLATYSMA MYOIDES

Muscles of the Head, Face, and Neck.

raised and the skin of the forehead thrown into transverse wrinkles, as in the expression of fright or horror. [On lifting the eyebrows, the line where the frontal belly joins the aponeurosis is easily seen. This is usually not a horizontal line, but curved like the wrinkles of the forehead. These wrinkles, when typical, are curved thus (Fig. 283), 1 being the central member of the curve above the nose; 2, 2, the lateral members above the eyebrows. From this type they vary, and in some persons become straight lines. Either the central or the lateral portions may be poorly marked or even absent. If the central portion be lost, the lateral often meet, or even cross each other. These variations in type, development, and number produce the most diverse results in expression and are very important to the artist. Their number depends on the thickness of the skin: the thicker the skin the

[FIG. 283.



Typical Wrinkle in Forehead: 1, central; 2, 2, lateral portions of the curve.—W. W. K.]

fewer the wrinkles. In early childhood the skin of the forehead can always be elevated in mass, but it is seldom distinctly wrinkled before six years of age, and sometimes not till eleven.]

2. AURICULAR REGION (Fig. 282).

Attollens aurem. Attrahens aurem.
Retrahens aurem.

These three small muscles are placed immediately beneath the skin around the external ear. In man, in whom the external ear is almost immovable, they are rudimentary. They are the analogues of large and important muscles in some of the Mammalia.

Dissection.—This requires considerable care, and should be performed in the following manner: To expose the Attollens aurem: draw the pinna or broad part of the ear downward, when a tense band will be felt beneath the skin passing from the side of the head to the upper part of the concha; by dividing the skin over the tendon in a direction from below upward, and then reflecting it on each side, the muscle is exposed. To bring into view the Attrahens aurem, draw the helix backward by means of a hook, when the muscle will be made tense, and may be exposed in a similar manner to the preceding. To expose the Retrahens aurem, draw the pinna forward, when the muscle, being made tense, may be felt beneath the skin at its insertion into the back part of the concha, and may be exposed in the same manner as the other muscles.

The **Attollens aurem** (*Auricularis superior*), the largest of the three, is thin and fan-shaped: its fibres arise from the aponeurosis of the Occipito-frontalis, and converge to be inserted by a thin, flattened tendon into the upper part of the cranial surface of the pinna.

RELATIONS.—*Externally*, with the integument; *internally*, with the temporal fascia and the areolar layer derived from the aponeurosis.

The **Attrahens aurem** (*Auricularis anterior*), the smallest of the three, is thin, fan-shaped, and its fibres pale and indistinct; they arise from the lateral edge of the aponeurosis of the Occipito-frontalis, and converge to be inserted into a projection on the front of the helix.

RELATIONS.—*Externally*, with the skin; *internally*, with the temporal fascia which separates it from the temporal artery and vein.

The **Retrahens aurem** (*Auricularis posterior*) consists of two or three fleshy fasciculi which arise from the mastoid portion of the temporal bone by short aponeurotic fibres. They are inserted into the lower part of the cranial surface of the concha.

RELATIONS.—*Externally*, with the integument; *internally*, with the mastoid portion of the temporal bone.

NERVES.—The Attollens aurem is supplied by the occipitalis minor; the Attrahens aurem, by the facial; and the Retrahens aurem, by the posterior auricular branch of the facial.

ACTIONS.—In man these muscles possess very little action; the Attollens aurem slightly raises the ear; the Attrahens aurem draws it forward and upward; and the Retrahens aurem draws it backward. [Many persons can move the ear upward and backward, and most people do so to a slight but perceptible extent in smiling and laughter.]

3. PALPEBRAL REGION (Figs. 282, 284).

Orbicularis palpebrarum. Levator palpebræ.
Corrugator supercilii. Tensor tarsi.

Dissection (Fig. 281).—In order to expose the muscles of the face, continue the longitudinal incision, made in the dissection of the Occipito-frontalis, down the median line of the face to the tip of the nose, and from this point onward to the upper lip, and carry another incision along the margin of the lip to the angle of the mouth, and transversely across the face to the angle of the jaw. Then make an incision in front of the external ear from the angle of the jaw upward, to join the transverse incision made in exposing the Occipito-frontalis. These incisions include a square-shaped flap, which should be removed with care in the direction marked in the figure, as the muscles at some points are intimately adherent to the integument.

Digitized

The **Orbicularis palpebrarum** is a sphincter muscle which surrounds the circumference of the orbit and eyelids. It arises from the internal angular process of the frontal bone, from the nasal process of the superior maxillary in front of the lachrymal groove, and from the anterior surface and borders of a short tendon, the *tendo palpebrarum*, placed at the inner angle of the orbit. From this origin the fibres are directed outward, forming a broad, thin, and flat layer which covers the eyelids, surrounds the circumference of the orbit, and spreads out over the temple and downward on the cheek, becoming blended with the Occipito-frontalis and Corrugator supercilii. The palpebral portion (ciliaris) of the Orbicularis is thin and pale; it arises from the bifurcation of the tendo palpebrarum, and forms a series of concentric curves which are united on the outer side of the eyelids at an acute angle by a cellular raphé, some being inserted into the external tarsal ligament and malar bone. The orbicular portion (orbicularis latus) is thicker and of a reddish color: its fibres are well developed and form complete ellipses.

[Fig. 284.

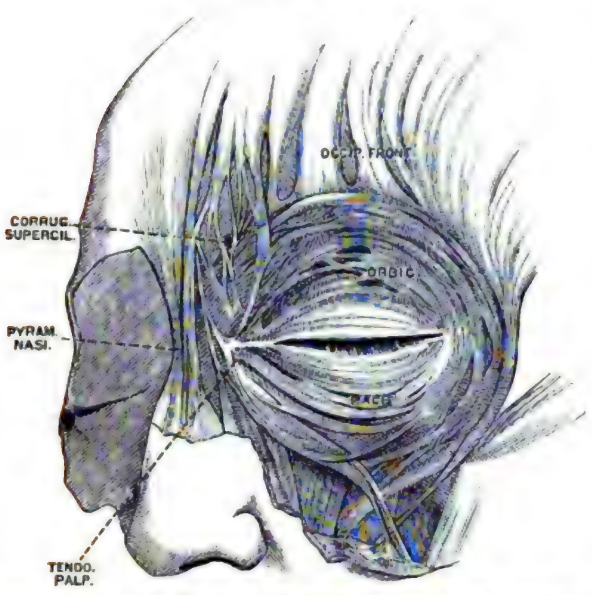

Frontal and Ocular Muscles, showing their loose texture and intermingling fibres when minutely dissected (Henle).]

Relations.—By its *superficial surface* with the integument; by its *deep surface* above with the Occipito-frontalis and Corrugator supercilii, with which it is intimately blended, and with the supraorbital vessels and nerve; below it covers the lachrymal sac and the origin of the Levator labii superioris and the Levator labii superioris alæque nasi muscles. *Internally*, it is occasionally blended with the Pyramidalis nasi; *externally*, it lies on the temporal fascia. On the eyelids it is separated from the conjunctiva by a fibrous membrane and the so-called tarsal cartilage.[1]

The *tendo palpebrarum* (tendo oculi) is a short tendon, about two lines in length and one in breadth, attached to the nasal process of the superior maxillary bone in front of the lachrymal groove. Crossing the lachrymal sac, it divides into two parts, each division being attached to the inner extremity of the corresponding tarsal cartilage. As the tendon crosses the lachrymal sac a strong aponeurotic lamina is given off from the posterior surface, which expands over the sac and is attached to the ridge on the lachrymal bone. This is the reflected aponeurosis of the tendo palpebrarum.

The **Corrugator supercilii** is a small, narrow, pyramidal muscle placed at the inner extremity of the eyebrow, beneath the Occipito-frontalis and Orbicularis palpebrarum muscles. It arises from the inner extremity of the superciliary ridge, whence its fibres pass upward and outward to be inserted into the under surface of the orbicularis opposite the middle of the orbital arch.

Relations.—By its *anterior surface* with the Occipito-frontalis and Orbicularis palpebrarum muscles; by its *posterior surface* with the frontal bone and supratrochlear nerve.

---

[1] The student should bear in mind that the tarsal cartilages do not really consist of cartilaginous tissue, and that therefore the name is a bad one; it has, however, been sanctioned by such long usage that it seems inexpedient to alter it, since it might lead to confusion.

The **Levator palpebræ** will be described with the muscles of the orbital region.

The **Tensor tarsi** [Horner's muscle] is a small thin muscle, about three lines in breadth and six in length, situated at the inner side of the orbit, behind the tendo oculi. It arises from the crest and adjacent part of the orbital surface of the lachrymal bone, and, passing across the lachrymal sac, divides into two slips, which cover the lachrymal canals and are inserted into the tarsal cartilages near the puncta lachrymalia. Its fibres appear to be continuous with those of the palpebral portion of the Orbicularis; it is occasionally very indistinct.

Nerves.—The Orbicularis palpebrarum, Corrugator supercilii, and Tensor tarsi are supplied by the facial nerve.

Actions.—The Orbicularis palpebrarum is the sphincter muscle of the eyelids. The palpebral portion acts [for the most part] involuntarily in closing the lids and independently of the orbicular portion, which is subject to the will. The palpebral portion closes the eyelids gently, as in sleep or in blinking; the entire muscle, when brought into action, brings the lids into close contact, as in photophobia. The skin of the forehead, temple, and cheek is then drawn inward toward the inner angle of the eye, and is thrown into folds, especially radiating from the outer angle of the eyelids, which give rise in old age to the so-called "crow's feet." The Levator palpebræ is the direct antagonist of this muscle; it raises the upper eyelid and exposes the globe. The Corrugator supercilii draws the eyebrow downward and inward, producing the vertical wrinkles of the forehead. It is the "frowning" muscle, and may be regarded as the principal agent in the expression of suffering. [These vertical wrinkles are above the nose, and vary to a moderate extent in number and degree. In marked contrast to the transverse wrinkles, I have never seen a child, even a baby, who could not produce these wrinkles and frown.] The Tensor tarsi draws the eyelids and the extremities of the lachrymal canals inward and compresses them against the surface of the globe of the eye, thus placing them in the most favorable situation for receiving the tears. It serves also to compress the lachrymal sac.

4. Orbital Region (Fig. 285).

Levator palpebræ superioris.
Rectus superior.
Rectus inferior.
Rectus internus.
Rectus externus.
Obliquus superior.
Obliquus inferior.

Dissection.—To open the cavity of the orbit, remove the skull-cap and brain; then saw through the frontal bone at the inner extremity of the supraorbital ridge and externally at its junction with the malar. Break in pieces the thin roof of the orbit by a few slight blows of the hammer, and take it away; drive forward the superciliary portion of the frontal bone by a smart stroke, but do not remove it, as that would destroy the pulley of the Obliquus superior. When the fragments are cleared away, the periosteum of the orbit will be exposed; this being removed, together with the fat which fills the cavity of the orbit, the several muscles of this region can be examined. The dissection will be facilitated by distending the globe of the eye. In order to effect this, puncture the optic nerve near the eyeball with a curved needle, and push the needle onward into the globe; insert the point of a blowpipe through this aperture and force a little air into the cavity of the eyeball; then apply a ligature round the nerve so as to prevent the air escaping. The globe being now drawn forward, the muscles will be put upon the stretch. [Heusman's method of inflating the ball through a valvular opening in the cornea is much preferable. If the air escapes, the ball can be reinflated.]

The **Levator palpebræ superioris** is thin, flat, and triangular in shape. It arises from the under surface of the lesser wing of the sphenoid, immediately in front of the optic foramen, and is inserted by a broad aponeurosis into the anterior surface of the superior tarsal cartilage. At its origin it is narrow and tendinous, but soon becomes broad and fleshy, and finally terminates in a broad aponeurosis.

Relations.—By its *upper surface* with the frontal nerve and artery, the periosteum of the orbit, and in front with the inner surface of the broad tarsal ligament; by its *under surface* with the Superior rectus, and in the lid with the conjunctiva. A small branch of the third nerve enters its under surface.

The **Superior rectus**, the thinnest and narrowest of the four Recti, arises from the upper margin of the optic foramen beneath the Levator palpebræ and Superior oblique, and from the fibrous sheath of the optic nerve, and is inserted, by a tendinous expansion, into the sclerotic coat about three or four lines from the margin of the cornea.

FIG. 285.

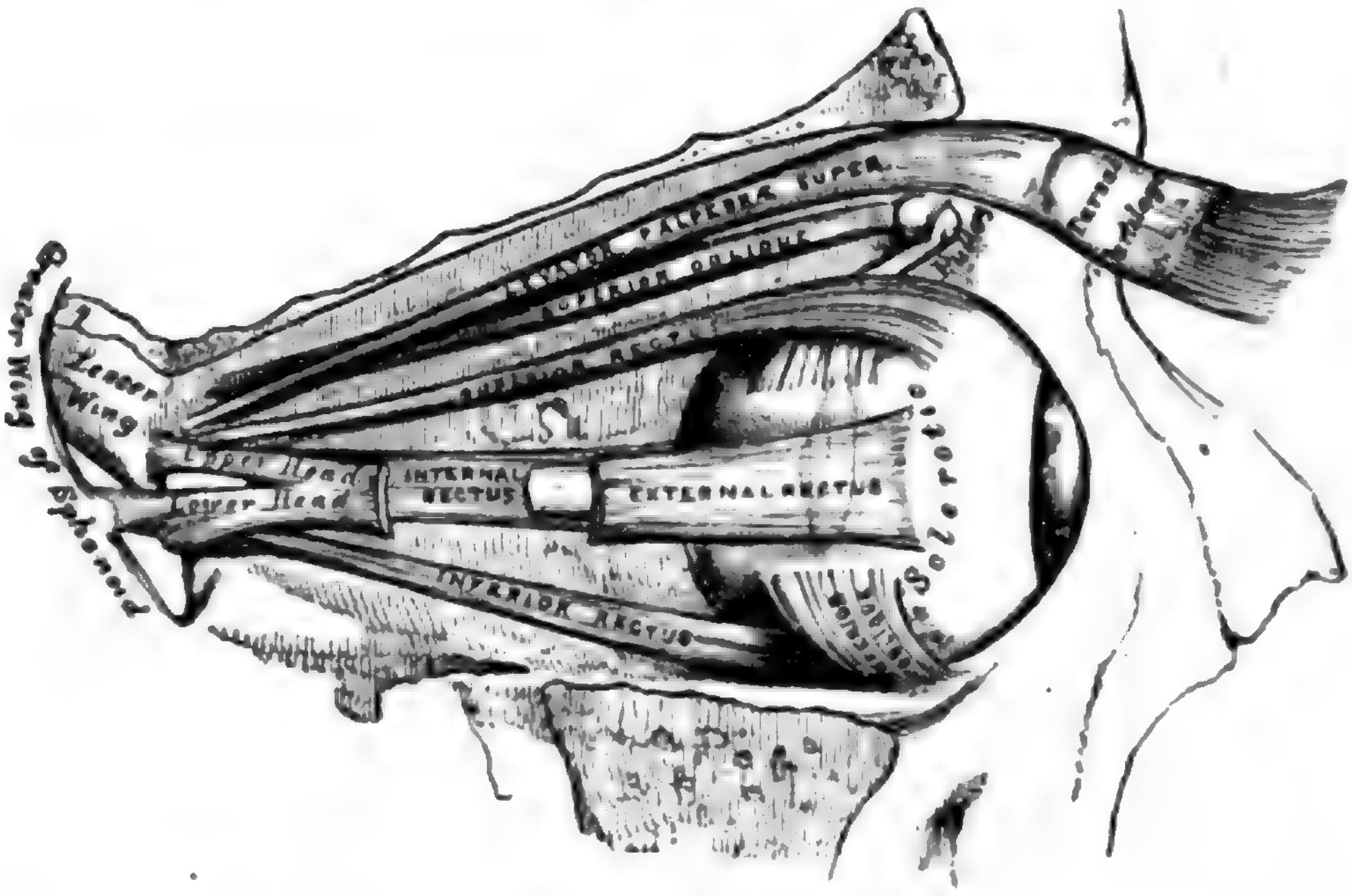
Greater Wing of Sphenoid
Lesser Wing
Levator Palpebræ Super.
Superior Oblique
Superior Rect.
Upper Head
Lower Head
Internal Rectus
External Rectus
Inferior Rectus
Sclerotic

Muscles of the Right Orbit.

RELATIONS.—By its *upper surface* with the Levator palpebræ; by its *under surface* with the optic nerve, the ophthalmic artery, the nasal nerve, and the branch of the third nerve which supplies it; and in front with the tendon of the Superior oblique and the globe of the eye.

The **Inferior** and **Internal Recti** arise by a common tendon (the *ligament of Zinn*),[1] which is attached round the circumference of the optic foramen, except at its upper and outer part. The **External rectus** has two heads: the upper one arises from the outer margin of the optic foramen immediately beneath the Superior rectus; the lower head, partly from the ligament of Zinn and partly from a small pointed process of bone on the lower margin of the sphenoidal fissure. Each muscle passes forward in the position implied by its name, to be inserted by a tendinous expansion (the *tunica albuginea*) into the sclerotic coat, about three or four lines from the margin of the cornea. Between the two heads of the External rectus is a narrow interval, through which pass the third, the nasal branch of the fifth and the sixth nerves, and the ophthalmic vein. Although nearly all of these muscles present a common origin and are inserted in a similar manner into the sclerotic coat, there are certain differences to be observed in them as regards their length and breadth. The Internal rectus is the broadest; the External, the longest; and the Superior, the thinnest and narrowest.

FIG. 286.

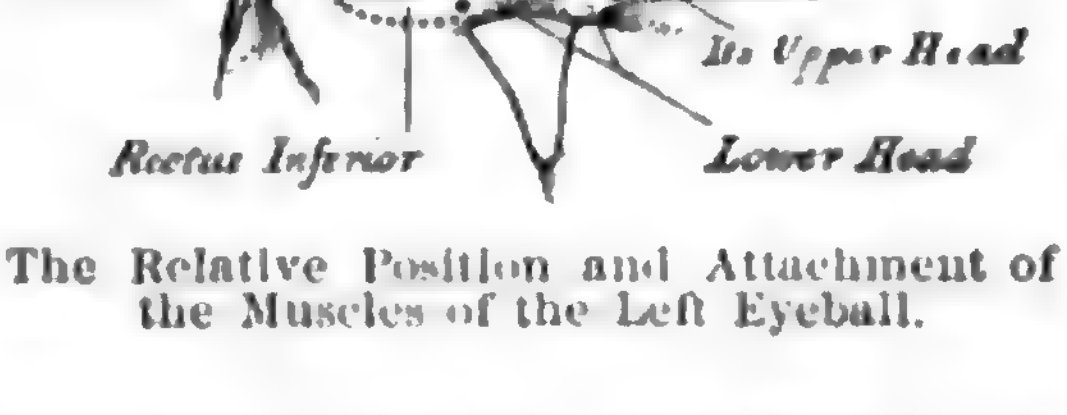
Rectus Superior
Levator Palpebræ Superior
Obliquus Superior
Lesser Wing
Optic foramen
Rectus Externus
Rectus Internus
Its Upper Head
Rectus Inferior
Lower Head

The Relative Position and Attachment of the Muscles of the Left Eyeball.

The **Superior oblique** is a fusiform muscle placed at the upper and inner side of the orbit internal to the Levator palpebræ. It arises about a line above the inner margin of the optic foramen, and, passing forward to the inner angle of the orbit, terminates in a rounded tendon, which plays in a ring or pulley formed by fibro-cartilaginous tissue attached to a depression beneath the internal angular process of the frontal bone, the contiguous surfaces of the tendon and ring being lined by a delicate synovial membrane and enclosed in a thin fibrous investment. The tendon is reflected backward, outward, and downward beneath the Superior rectus to the outer part of the globe of the eye, and is inserted into the sclerotic coat midway between the cornea and entrance of the optic nerve, the insertion of the muscle lying between the Superior and External recti.

---

[1] The ligament of Zinn ought, perhaps more appropriately, to be termed the *aponeurosis* or *tendon* of Zinn. Mr. C. B. Lockwood has described a somewhat similar structure on the under surface of the superior rectus muscle which is attached to the lesser wing of the sphenoid, forming the upper and outer margin of the optic foramen. This *superior* tendon gives origin to the superior rectus, the superior head of the external rectus, and the upper part of the internal rectus (*Journal of Anatomy and Physiology*, vol. xx. Part I. p. 1).

RELATIONS.—By its *upper surface* with the periosteum covering the roof of the orbit and the fourth nerve: the tendon, where it lies on the globe of the eye, is covered by the Superior rectus; by its *under surface* with the nasal nerve and the upper border of the Internal rectus.

The **Inferior oblique** is a thin, narrow muscle placed near the anterior margin of the orbit. It arises from a depression in the orbital plate of the superior maxillary bone external to the orifice of the nasal duct. Passing outward, backward, and upward beneath the Inferior rectus, and between the eyeball and the External rectus, it is inserted into the outer part of the sclerotic coat between the Superior and External recti, near the tendon of insertion of the Superior oblique.

RELATIONS.—By its *ocular surface* with the globe of the eye and with the Inferior rectus; by its *orbital surface* with the periosteum covering the floor of the orbit and with the External rectus. Its borders look forward and backward; the posterior one receives a branch of the third nerve.

NERVES.—The Levator palpebræ, Inferior oblique, and all the Recti excepting the External are supplied by the third nerve; the Superior oblique, by the fourth; the External rectus, by the sixth.

ACTIONS.—The Levator palpebræ raises the upper eyelid, and is the direct antagonist of the Orbicularis palpebrarum. The four Recti muscles are attached in such a manner to the globe of the eye that, acting singly, they will turn it either upward, downward, inward, or outward, as expressed by their names. The movement produced by the Superior and Inferior rectus is not quite a simple one, for, inasmuch as they pass obliquely outward and forward to the eyeball, the elevation or depression of the cornea must be accompanied by a certain deviation inward, with a slight amount of rotation, which, however, is corrected by the Oblique muscles, the Inferior oblique correcting the deviation inward of the Superior rectus, and the Superior oblique that of the Inferior rectus. The contraction of the External and Internal recti, on the other hand, produces a precisely horizontal movement. If any two Recti [of one eye] act together, they carry the globe of the eye in the diagonal of these directions—viz. upward and inward, upward and outward, downward and inward, or downward and outward. The movement of circumduction, as in looking round a room, is performed by the alternate action of the four Recti. The Oblique muscles rotate the eyeball on its *antero-posterior axis*, this kind of movement being required for the correct viewing of an object when the head is moved laterally, as from shoulder to shoulder, in order that the picture may fall in all respects on the same part of the retina of each eye.[1] [It should be noted that sometimes the *corresponding* Recti muscles and sometimes the *opposite* ones of the two eyes act together; for instance, the two Superior and Inferior recti carry both eyeballs upward and downward respectively. In looking toward the right the right External and left Internal recti act together, the reverse being the case in looking toward the left. In turning both eyes toward the middle line, as in directing our vision toward an object less than twenty feet distant, the two Internal recti act together.]

Surgical Anatomy.—The position and exact point of insertion of the tendons of the

---

[1] "On the Oblique Muscles of the Eye in Man and Vertebrate Animals," by John Struthers, M. D., in *Anatomical and Physiological Observations*. (For a more full account of the various co-ordinated actions of the muscles of a single eye and of both eyes than our space allows, the reader may be referred to Dr. M. Foster's *Textbook of Physiology* 4th ed., pp. 542-547.)

Internal and External recti muscles into the globe should be carefully examined from the front of the eyeball, as the surgeon is often required to divide one or the other muscle for the cure of strabismus. In convergent strabismus, which is the more common form of the disease, the eye is turned inward, requiring the division of the Internal rectus. In the divergent form, which is more rare, the eye is turned outward, the External rectus being especially implicated. The deformity produced in either case is to be remedied by division of one or the other muscle. The operation is thus effected: The lids are to be well separated; the eyeball being drawn outward, the conjunctiva should be raised by a pair of forceps and divided immediately beneath the lower border of the tendon of the Internal rectus, a little behind its insertion into the sclerotic; the capsule of Tenon is then divided, and into the small aperture thus made a blunt hook is passed upward between the muscle and the globe, and the tendon of the muscle and conjunctiva covering it divided by a pair of blunt-pointed scissors. Or the tendon may be divided by a subconjunctival incision, one blade of the scissors being passed upward between the tendon and the conjunctiva, and the other between the tendon and the sclerotic. The student when dissecting these muscles should remove on one side of the subject the conjunctiva from the front of the eye, in order to see more accurately the position of the tendons, while on the opposite side the operation may be performed.

5. NASAL REGION (Figs. 282, 284).

Pyramidalis nasi.
Levator labii superioris alæque nasi.
Dilatator naris posterior.
Dilatator naris anterior.
Compressor nasi.
Compressor narium minor.
Depressor alæ nasi.

The **Pyramidalis nasi** is a small pyramidal slip prolonged downward from the Occipito-frontalis upon the side of the nose, where it becomes tendinous and blends with the Compressor nasi. As the two muscles descend they diverge, leaving an angular interval between them.

RELATIONS.—By its *upper surface* with the skin; by its *under surface* with the frontal and nasal bones.

The **Levator labii superioris alæque nasi** is a thin triangular muscle placed by the side of the nose and extending between the inner margin of the orbit and upper lip. It arises by a pointed extremity from the upper part of the nasal process of the superior maxillary bone, and, passing obliquely downward and outward, divides into two slips, one of which is inserted into the cartilage of the ala of the nose; the other is prolonged into the upper lip, becoming blended with the Orbicularis and Levator labii superioris proprius.

RELATIONS.—In front with the integument, and with a small part of the Orbicularis palpebrarum above.

The **Dilatator naris posterior** is a small muscle which is placed partly beneath the proper elevator of the nose and lip. It arises from the margin of the nasal notch of the superior maxilla and from the sesamoid cartilages, and is inserted into the skin near the margin of the nostril.

The **Dilatator naris anterior** is a thin delicate fasciculus passing from the cartilage of the ala of the nose to the integument near its margin. This muscle is situated in front of the preceding.

The **Compressor nasi** is a small, thin, triangular muscle arising by its apex from the superior maxillary bone, above and a little external to the incisive fossa; its fibres proceed upward and inward, expanding into a thin aponeurosis which is attached to the fibro-cartilage of the nose, and is continuous on the bridge of the nose with that of the muscle of the opposite side and with the aponeurosis of the Pyramidalis nasi.

The **Compressor narium minor** is a small muscle attached by one end to the alar cartilage, and by the other to the integument at the end of the nose.

The **Depressor alæ nasi** is a short, radiated muscle arising from the incisive fossa of the superior maxilla; its fibres ascend to be inserted into the septum and back part of the ala of the nose. This muscle lies between the mucous membrane and muscular structure of the lip.

NERVES.—All the muscles of this group are supplied by the facial nerve.

ACTIONS.—The Pyramidalis nasi draws down the inner angle of the eyebrows and produces transverse wrinkles over the bridge of the nose; by some anatomists it is also considered as an elevator of the ala, and consequently a dilator of the nose. [Although this muscle anatomically seems to be a continuation of the Occipito frontalis downward, it is really the reverse. Its origin is from the nose below, and its insertion into the Occipito-frontal and skin. If one pole of a battery be placed in front of the lobe of the ear, and the other (a small pointed one) be carried up and down over the nose and forehead in the middle line, it is easy to find a nodal point of indifference, above which the Occipito-frontal draws the parts upward, and below which the Pyramidalis draws them downward.] The Levator labii superioris alæque nasi draws upward the upper lip and ala of the nose; its most important action is upon the nose, which it dilates to a considerable extent. The action of this muscle produces a marked influence over the countenance, and it is the principal agent in the expression of indignation [and disgust]. The two Dilatatores nasi enlarge the aperture of the nose. Their action in ordinary breathing is to resist the tendency of the nostrils to close from atmospheric pressure, but in difficult breathing they may be noticed to be in violent action, as well as in some emotions, as anger. The Depressor alæ nasi is a direct antagonist of the preceding muscles, drawing the ala of the nose downward, and thereby constricting the aperture of the nares. The Compressor nasi depresses the cartilaginous part of the nose and compresses the alæ together.

6. Superior Maxillary Region (Fig. 282).

Levator labii superioris.	Zygomaticus major.
Levator anguli oris.	Zygomaticus minor.

The **Levator labii superioris** (**proprius**) is a thin muscle of a quadrilateral form. It arises from the lower margin of the orbit immediately above the infraorbital foramen, some of its fibres being attached to the superior maxilla, others to the malar bone: its fibres converge to be inserted into the muscular substance of the upper lip.

Relations.—By its *superficial surface* with the lower segment of the Orbicularis palpebrarum; below, it is subcutaneous. By its *deep surface* it conceals the origin of the Compressor nasi and Levator anguli oris muscles, and the infraorbital vessels and nerve as they escape from the infraorbital foramen.

The **Levator anguli oris** arises from the canine fossa immediately below the infraorbital foramen; its fibres incline downward and a little outward, to be inserted into the angle of the mouth, intermingling with those of the Zygomaticus major, the Depressor anguli oris, and the Orbicularis.

Relations.—By its *superficial surface* with the Levator labii superioris and the infraorbital vessels and nerves; by its *deep surface* with the superior maxilla, the Buccinator, and the mucous membrane.

The **Zygomaticus major** is a slender fasciculus which arises from the malar bone in front of the zygomatic suture, and, descending obliquely downward and inward, is inserted into the angle of the mouth, where it blends with the fibres of the Levator anguli oris, the Orbicularis, and the Depressor anguli oris.

Relations.—By its *superficial surface* with the subcutaneous adipose tissue; by its *deep surface* with the malar bone and the Masseter and Buccinator muscles.

The **Zygomaticus minor** arises from the malar bone immediately behind the maxillary suture, and, passing downward and inward, is continuous with the Orbicularis oris at the outer margin of the Levator labii superioris: it lies in front of the preceding.

Relations.—By its *superficial surface* with the integument and the Orbicularis palpebrarum above; by its *deep surface* with the Levator anguli oris.

Nerves.—This group of muscles is supplied by the facial nerve.

Actions.—The Levator labii superioris is the proper elevator of the upper lip, carrying it at the same time a little forward. It assists in forming the naso-labial ridge, which passes from the side of the nose to the upper lip and gives to the face an expression of sadness. The Levator anguli oris raises the angle of the mouth and assists the preceding muscle in producing the naso-labial ridge. The Zygomaticus major draws the angle of the mouth backward and upward, as in laughing; whilst the Zygomaticus minor, being inserted into the outer part of the upper lip, and not into the angle of the mouth, draws it backward, upward, and outward, and thus gives to the face an expression of sadness.

7. INFERIOR MAXILLARY REGION (Fig. 282).

Levator labii inferioris (Levator menti).
Depressor labii inferioris (Quadratus menti).
Depressor anguli oris (Triangularis menti).

Dissection.—The muscles in this region may be dissected by making a vertical incision through the integument from the margin of the lower lip to the chin: a second incision should then be carried along the margin of the lower jaw as far as the angle, and the integument carefully removed in the direction shown in Fig. 281.

The **Levator labii inferioris (Levator menti)** is to be dissected by everting the lower lip and raising the mucous membrane. It is a small conical fasciculus placed on the side of the frænum of the lower lip. It arises from the incisive fossa, external to the symphysis of the lower jaw: its fibres descend to be inserted into the integument of the chin.

RELATIONS.—On the *inner surface* with the mucous membrane; in the *median line* it is blended with the muscle of the opposite side; and on its *outer side* with the Depressor labii inferioris.

The **Depressor labii inferioris (Quadratus menti)** is a small quadrilateral muscle situated at the outer side of the preceding. It arises from the external oblique line of the lower jaw, between the symphysis and mental foramen, and passes obliquely upward and inward, to be inserted into the integument of the lower lip, its fibres blending with the Orbicularis and with those of its fellow of the opposite side. It is continuous with the fibres of the Platysma at its origin. This muscle contains much yellow fat intermingled with its fibres.

RELATIONS.—By its *superficial surface* with part of the Depressor anguli oris and with the integument, to which it is closely connected; by its *deep surface* with the mental vessels and nerves, the mucous membrane of the lower lip, the labial glands, and the Levator menti, with which it is intimately united.

The **Depressor anguli oris** is triangular in shape, arising by its broad base from the external oblique line of the lower jaw, whence its fibres pass upward to be inserted by a narrow fasciculus into the angle of the mouth. It is continuous with the Platysma at its origin, and with the Orbicularis and Risorius at its insertion, and some of its fibres are directly continuous with those of the Levator anguli oris.

RELATIONS.—By its *superficial surface* with the integument; by its *deep surface* with the Depressor labii inferioris and Buccinator.

NERVES.—The group of muscles is supplied by the facial nerve.

ACTIONS.—The Levator labii inferioris raises the lower lip and protrudes it forward, and at the same time wrinkles the integument of the chin, expressing doubt or disdain. [A tremulous action of this muscle is excellently shown in children just on the verge of tears. In Delaroche's "Marie Antoinette going to Execution," one of the female spectators has a very delicate expression of sorrow by the slight elevation of the chin by this muscle, while the angles of the mouth are slightly drawn down by the Depressor anguli oris.] The Depressor labii inferioris draws the lower lip directly downward and a little outward, as in the expression of irony. The Depressor anguli oris depresses the angle of the mouth, being the antagonist to the Levator anguli oris and Zygomaticus major; acting with these muscles, it will draw the angle of the mouth directly backward. [The Depressor anguli oris is perhaps the most peculiar and most expressive single muscle in the human face. In fact, the angle of the mouth is the most mobile and important centre of expression in the face. By no one line can the expression be so easily and so widely changed. If two circles be drawn to represent two faces, and two dots and a line in each for the eyes and nose, thus reducing the features to their simplest expression, one face can be made to smile by inserting a line for the mouth, the angles being turned upward; while the other can be made to express great sadness by turning the angles of the mouth downward.]

8. INTERMAXILLARY REGION.

Orbicularis oris. Buccinator. Risorius.

Dissection.—The dissection of these muscles may be considerably facilitated by filling the cavity of the mouth with tow, so as to distend the cheeks and lips: the mouth should then be closed by a few stitches and the integument carefully removed from the surface.

The **Orbicularis oris** (Fig. 282) is a sphincter muscle, elliptic in form, composed of concentric fibres which surround the orifice of the mouth. It consists of two thick semicircular planes of muscular fibre which interlace on either side with those of the Buccinator and other muscles inserted into the lips. On the free margin of the lips the muscular fibres (*marginal* or *labial* fibres) are continued uninterruptedly from one lip to the other around the corner of the mouth, forming a roundish fasciculus of fine pale fibres closely approximated. Outside these are other fibres (*facial*), which are thinner than the others and are continuous at the angle of the mouth with the Buccinator; some of the fibres, the central ones, decussating in this situation, and others, the outer ones, being directly continuous with the fibres of the Buccinator. The various muscles which converge to the lips blend with the facial portion, the fibres of the muscles becoming directly continuous. To the outer part of the muscle some accessory fibres are added by which the lips are connected directly with the maxillary bones and septum of the nose. The additional fibres for the upper segment consist of four bands, two of which (*Accessorii orbicularis superioris*) arise from the alveolar border of the superior maxilla opposite the incisor teeth, and, arching outward on each side, are continuous at the angles of the mouth with the other muscles inserted into this part. The two remaining muscular slips, called the *Naso-labialis*, connect the upper lip to the septum of the nose; as they descend from the septum an interval is left between them. It is this interval which forms the depression seen on the surface of the skin beneath the septum of the nose [called the *philtrum*]. The additional fibres of the lower segment (*Accessorii orbicularis inferioris*) arise from the inferior maxilla externally to the Levator labii inferioris, and arch outward to the angles of the mouth to join the Buccinator and the other muscles attached to this part.

RELATIONS.—By its *superficial surface* with the integument, to which it is closely connected; by its *deep surface* with the buccal mucous membrane, the labial glands, and coronary vessels. By its *outer circumference* it is blended with the numerous muscles which converge to the mouth from various parts of the face. Its *inner circumference* is free and covered by the mucous membrane.

The **Buccinator** (Fig. 294) is a broad, thin muscle, quadrilateral in form, which occupies the interval between the jaws at the side of the face. It arises from the outer surface of the alveolar processes of the upper and lower jaws, corresponding to the three molar teeth, and behind from the anterior border of the pterygo-maxillary ligament. The fibres converge toward the angle of the mouth, where the central fibres intersect each other, those from below being continuous with the upper segment of the Orbicularis oris, and those from above with the inferior segment: the highest and lowest fibres continue forward uninterruptedly into the corresponding segment of the lip, without decussation.

RELATIONS.—By its *superficial surface* behind with a large mass of fat, which separates it from the ramus of the lower jaw, the Masseter, and a small portion of the Temporal muscle; anteriorly, with the Zygomatici, Risorius, Levator anguli oris, Depressor anguli oris, and Stenson's duct, which pierces it opposite the second molar tooth of the upper jaw; the facial artery and vein cross it from below upward; it is also crossed by the branches of the facial and buccal nerves; by its *internal surface* with the buccal glands and mucous membrane of the mouth.

The *Pterygo-maxillary ligament* separates the Buccinator muscle from the Superior constrictor of the pharynx. It is a tendinous band, attached by one extremity to the apex of the internal pterygoid plate, and by the other to the posterior extremity of the internal oblique line of the lower jaw. Its *inner surface* corresponds to the cavity of the mouth and is lined by mucous membrane. Its *outer surface* is separated from the ramus of the jaw by a quantity of adipose tissue. Its *posterior border* gives attachment to the Superior constrictor of the pharynx; its *anterior border*, to the fibres of the Buccinator. (See Fig. 295.)

The **Risorius (Santorini)** (Fig. 282) consists of a narrow bundle of fibres which arises in the fascia over the Masseter muscle, and, passing horizontally forward, is inserted into the angle of the mouth, joining with the fibres of the Depressor anguli oris. It is placed superficial to the Platysma, and is broadest at its outer extremity. This muscle varies much in its size and form.

NERVES.—The Orbicularis oris and the Risorius are supplied by the facial, the Buccinator by the facial and by the buccal branch of the inferior maxillary nerve; which latter, however, is by many anatomists regarded as a sensory nerve only.

ACTIONS.—The Orbicularis oris is the direct antagonist of all those muscles which converge to the lips from the various parts of the face, its ordinary action producing the direct closure of the lips, and its forcible action throwing the integument into wrinkles, on account of the firm connection between the latter and the surface of the muscle. [These wrinkles radiate from the mouth, and can be best seen in the faces of some old women.] The Buccinators contract and compress the cheeks, so that during the process of mastication the food is kept under the immediate pressure of the teeth. When the cheeks have been previously distended with air, the Buccinator muscles expel it from between the lips, as in blowing a trumpet. Hence the name (*buccina*, a trumpet). The Risorius retracts the angles of the mouth, and is therefore regarded as the "smiling" muscle.

9. TEMPORO-MAXILLARY REGION.

Masseter. Temporal.

Masseteric Fascia.—Covering the masseter muscle and firmly connected with it is a strong layer of fascia derived from the deep cervical fascia of the neck. Above, this fascia is attached to the lower border of the zygoma, and behind it covers the parotid gland, constituting the *parotid fascia.*

The **Masseter** is exposed by the removal of this fascia (Fig. 282); it is a short, thick muscle, somewhat quadrilateral in form, consisting of two portions, superficial and deep. The *superficial portion*, the larger, arises by a thick tendinous aponeurosis from the malar process of the superior maxilla, and from the anterior two-thirds of the lower border of the zygomatic arch: its fibres pass downward and backward, to be inserted into the angle and lower half of the outer surface of the ramus of the jaw. The *deep portion* is much smaller and more muscular in texture; it arises from the posterior third of the lower border and the whole of the inner surface of the zygomatic arch; its fibres pass downward and forward, to be inserted into the upper half of the ramus and outer surface of the coronoid process of the jaw. The deep portion of the muscle is partly concealed in front by the superficial portion: behind, it is covered by the parotid gland. The fibres of the two portions are united at their insertion.

RELATIONS.—By its *superficial surface* with the integument; above, with the Orbicularis palpebrarum and Zygomatici, and with Stenson's duct, the branches of the facial nerve, and the transverse facial vessels, which cross it; by its *deep surface* with the ramus of the jaw and the Buccinator, from which it is separated by a mass of fat. Its *posterior margin* is overlapped by the parotid gland. Its *anterior margin* projects over the Buccinator muscle, and the facial vein lies on it below.

The *Temporal Fascia* is seen at this stage of the dissection covering in the Temporal muscle. It is a strong fibrous investment, affording attachment by its inner surface to the superficial fibres of the muscle. Above, it is a single layer attached to the entire extent of the temporal ridge, but below, where it is attached to the zygoma, it consists of two layers, one of which is inserted into the outer, and the other into the inner border of the zygomatic arch. A small quantity of fat, the orbital branch of the temporal artery, and a filament from the orbital branch of the superior maxillary nerve are contained between these two layers. It is covered on its outer surface by the aponeurosis of the Occipito-frontalis, the Orbicularis palpebrarum, the Attollens and Attrahens aurem muscles; the temporal vessels and nerves cross it from below upward.

Dissection.—In order to expose the temporal muscle remove the temporal fascia, which may be effected by separating it at its attachment along the upper border of the zygoma and dissecting it upward from the surface of the muscle. The zygomatic arch should then be divided, in front, at its junction with the malar bone, and behind near the external auditory meatus, and drawn downward with the Masseter, which should be detached from its insertion into the ramus and angle of the jaw. The whole extent of the temporal muscle is then exposed.

The **Temporal** (Fig. 287) is a broad radiating muscle situated at the side of the head and occupying the entire extent of the temporal fossa. It arises from the whole of the temporal fossa, except that portion formed by the malar bone. Its attachment extends from the external angular process of the frontal in front to the mastoid portion of the temporal behind, and from the curved line on the frontal and parietal bones above to the pterygoid ridge on the great wing of the sphenoid below. It is also attached to the inner surface of the temporal fascia. Its fibres converge as they descend, and terminate in an aponeurosis, the fibres of which, radiated at its commencement, converge into a thick and flat tendon which is inserted into the inner surface, apex, and anterior border of the coronoid process of the jaw, nearly as far forward as the last molar tooth.

FIG. 287.

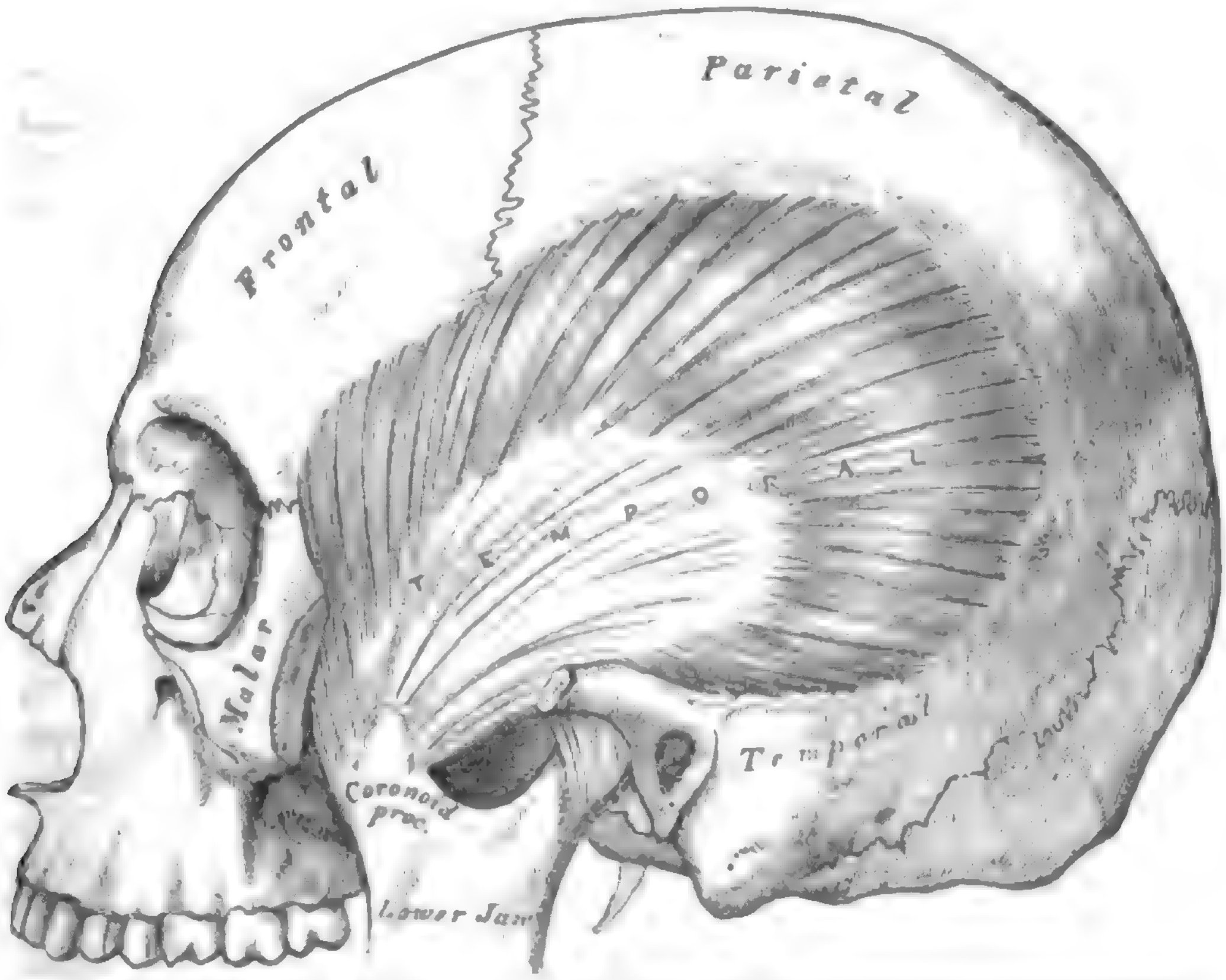

The Temporal Muscle, the Zygoma and the Masseter muscle having been removed.

RELATIONS.—By its *superficial surface* with the integument, the temporal fascia, the aponeurosis of the Occipito-frontalis, the Attollens and Attrahens aurem muscles, the temporal vessels and nerves, the zygoma and Masseter; by its *deep surface* with the temporal fossa, the External pterygoid and part of the Buccinator muscles,

Digitized

the internal maxillary artery, its deep temporal branches, and the temporal nerves. Behind the tendon are the masseteric vessels and nerve, and in front of it the buccal vessels and nerve.

NERVES.—Both muscles are supplied by the inferior maxillary nerve.

10. PTERYGO-MAXILLARY REGION (Fig. 288).

External Pterygoid.	Internal Pterygoid.

Dissection.—The Temporal muscle having been examined, saw through the base of the coronoid process, and draw it upward, together with the Temporal muscle, which should be detached from the surface of the temporal fossa. Divide the ramus of the jaw just below the condyle, and also, by a transverse incision extending across the middle, just above the dental foramen; remove the fragment, and the Pterygoid muscles will be exposed.

The **External pterygoid** is a short thick muscle, somewhat conical in form, which extends almost horizontally between the zygomatic fossa and the condyle of the jaw. It arises from the pterygoid ridge on the great wing of the sphenoid and the portion of bone included between it and the base of the pterygoid process, and from the outer surface of the external pterygoid plate. Its fibres pass horizontally backward and outward, to be inserted into a depression in front of the neck of the condyle of the lower jaw, and into the corresponding part of the interarticular fibro-cartilage. This muscle at its origin appears to consist of two portions separated by a slight interval, hence the terms *upper* and *lower* head sometimes used in the description of the muscle.

RELATIONS.—By its *external surface* with the ramus of the lower jaw, the internal maxillary artery, which crosses it,[1] the tendon of the Temporal muscle, and the Masseter; by its *internal surface* it rests against the upper part of the Internal pterygoid, the internal lateral ligament, the middle meningeal artery, and inferior maxillary nerve; by its *upper border* it is in relation with the temporal and masseteric branches of the inferior maxillary nerve; by its lower border it is in relation with the inferior dental and gustatory nerves, and it is pierced by the buccal nerve.

FIG. 288.

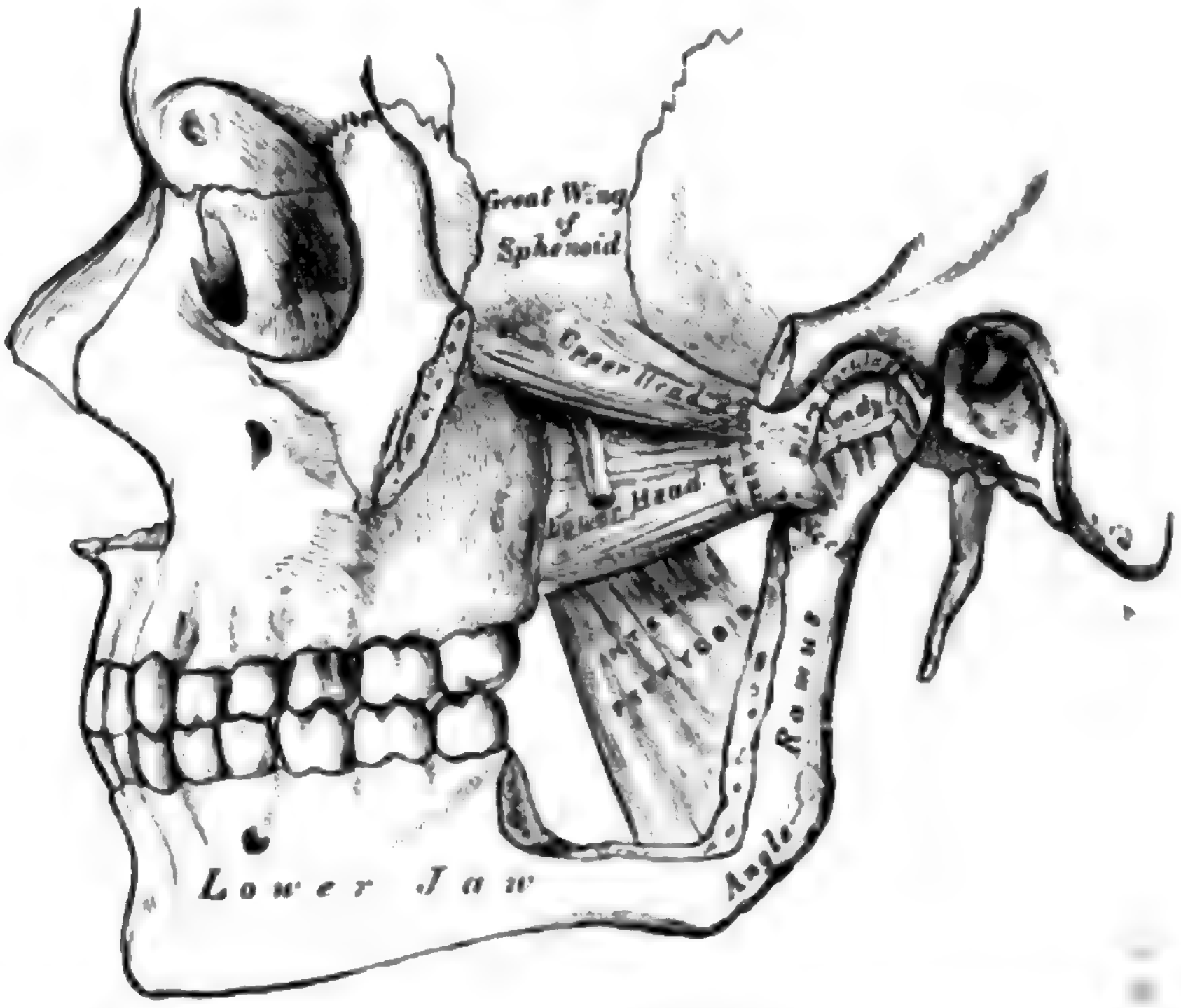

The Pterygoid Muscles, the Zygomatic Arch and a portion of the Ramus of the Jaw having been removed.

---

[1] This is the usual relation, but in many cases the artery will be found below the muscle.

The **Internal pterygoid** is a thick quadrilateral muscle, and resembles the Masseter in form, structure, and the direction of its fibres. It arises from the pterygoid fossa, being attached to the inner surface of the external pterygoid plate and to the grooved surface of the tuberosity of the palate bone, and by a second slip from the outer surface of the tuberosity of the palate bone, and from the tuberosity of the superior maxillary bone; its fibres pass downward, outward, and backward, to be inserted by strong tendinous laminæ into the lower and back part of the inner side of the ramus and angle of the lower jaw as high as the dental foramen.

Relations.—By its *external surface* with the ramus of the lower jaw, from which it is separated, at its upper part, by the External pterygoid, the internal lateral ligament, the internal maxillary artery, and the dental vessels and nerves; by its *internal surface* with the Tensor palati, being separated from the Superior constrictor of the pharynx by a cellular interval.

Nerves.—These muscles are supplied by the inferior maxillary nerve.

Actions.—The Temporal and Masseter and Internal pterygoid raise the lower jaw against the upper with great force. The superficial portion of the Masseter and the Internal pterygoid assist the External pterygoid in drawing the lower jaw forward upon the upper, the jaw being drawn back again by the deep fibres of the Masseter and posterior fibres of the Temporal. The External Pterygoid muscles are the direct agents in the trituration of the food, drawing the lower jaw directly forward, so as to make the lower teeth project beyond the upper. If the muscle of one side acts, the corresponding side of the jaw is drawn forward, and, the other condyle remaining fixed, the symphysis deviates to the opposite side. The alternation of these movements on the two sides produces trituration. [The finger placed on the Temporal and Masseter while they are alternately contracted and relaxed appreciates very distinctly their limits.]

MUSCLES AND FASCIÆ OF THE NECK.

The Muscles of the Neck may be arranged into groups corresponding with the region in which they are situated. These groups are nine in number:

1. Superficial Region.
2. Depressors of the Os Hyoides and Larynx.
3. Elevators of the Os Hyoides and Larynx.
4. Muscles of the Tongue.
5. Muscles of the Pharynx.
6. Muscles of the Soft Palate.
7. Muscles of the Anterior Vertebral Region.
8. Muscles of the Lateral Vertebral Region.
9. Muscles of the Larynx.

The muscles contained in each of these groups are the following:

1. *Superficial Region.*

Platysma myoides.
Sterno-cleido-mastoid.

2. *Infrahyoid Region.*

Depressors of the Os Hyoides and Larynx.

Sterno-hyoid.
Sterno-thyroid.
Thyro-hyoid.
Omo-hyoid.

3. *Suprahyoid Region.*

Elevators of the Os Hyoides and Larynx.

Digastric.
Stylo-hyoid.
Mylo-hyoid.
Genio-hyoid.

4. *Lingual Region.*

Muscles of the Tongue.

Genio-hyo-glossus.
Hyo-glossus.

Lingualis.
Stylo-glossus.
Palato-glossus.

5. *Muscles of the Pharynx.*

Constrictor inferior.
Constrictor medius.
Constrictor superior.
Stylo-pharyngeus.
Palato-pharyngeus.

6. *Muscles of the Soft Palate.*

Levator palati.
Tensor palati.
Azygos uvulæ.
Palato-glossus.
Palato-pharyngeus.

7. *Muscles of the Anterior Vertebral Region.*

Rectus capitis anticus major.
Rectus capitis anticus minor.
Rectus lateralis.
Longus colli.

8. *Muscles of the Lateral Vertebral Region.*

Scalenus anticus.
Scalenus medius.
Scalenus posticus.

9. *Muscles of the Larynx.*

Included in the description of the Larynx.

1. Superficial Cervical Region.

Platysma myoides.
Sterno-cleido-mastoid.

Dissection.—A block having been placed at the back of the neck, and the face turned to the side opposite that to be dissected, so as to place the parts upon the stretch, make two transverse incisions—one from the chin, along the margin of the lower jaw, to the mastoid process; and the other along the upper border of the clavicle. Connect these by an oblique incision made in the course of the Sterno-mastoid muscle from the mastoid process to the sternum; the two flaps of integument having been removed in the direction shown in Fig. 281, the superficial fascia will be exposed.

The **Superficial Cervical Fascia** is exposed on the removal of the integument from the side of the neck; it is an extremely thin aponeurotic lamina which is hardly demonstrable as a separate membrane. Beneath it are found the Platysma myoides muscle, the external jugular vein, and some superficial branches of the cervical plexus of nerves.

The **Platysma myoides** (Fig. 282, p. 368) is a broad, thin plane of muscular fibres placed immediately beneath the skin on each side of the neck. It arises by thin fibrous bands from the clavicle and acromion and from the fascia covering the upper part of the Pectoral, Deltoid, and Trapezius muscles: its fibres proceed obliquely upward and inward along the side of the neck, to be inserted into the lower jaw beneath the external oblique line, some passing forward to the angle of the mouth, and others becoming lost in the cellular tissue of the face. The most anterior fibres interlace in front of the jaw with the fibres of the muscle of the opposite side; those next in order become blended with the Depressor labii inferioris and the Depressor anguli oris; others are prolonged upon the side of the cheek, and interlace, near the angle of the mouth, with the muscles in this situation, and may occasionally be traced to the Zygomatic muscles or to the margin of the Orbicularis palpebrarum. Beneath the Platysma the external jugular vein may be seen descending from the angle of the jaw to the clavicle. It is essential to remember the direction of the fibres of the Platysma in connection with the operation of bleeding from this vessel; for if the point of the lancet is introduced in the direction of the muscular fibres, the orifice made will be filled up by the contraction of the muscle, and blood will not flow; but if the incision is made across the course of the fibres, they will retract and expose the orifice in the vein, and so facilitate the flow of blood.

Relations.—By its *external surface* with the integument, to which it is united closely below, but more loosely above; by its *internal surface* with the Pectoralis major, Deltoid, and Trapezius, and with the clavicle; in the *neck* with the external and anterior jugular veins, the deep cervical fascia, the superficial branches of the cervical plexus, the Sterno-mastoid, Sterno-hyoid, Omo-hyoid, and Digastric muscles. In front of the Sterno-mastoid it covers the sheath of the carotid vessels, and behind it the Scaleni muscles and the nerves of the brachial plexus. On the *face* it is in relation with the parotid gland, the facial artery and vein, and the Masseter and Buccinator muscles.

The **Deep Cervical Fascia** (Fig. 289) is exposed on the removal of the Platysma myoides. It is a strong fibrous layer which invests the muscles of the neck and encloses the vessels and nerves. It commences as an extremely thin layer at

FIG. 289.

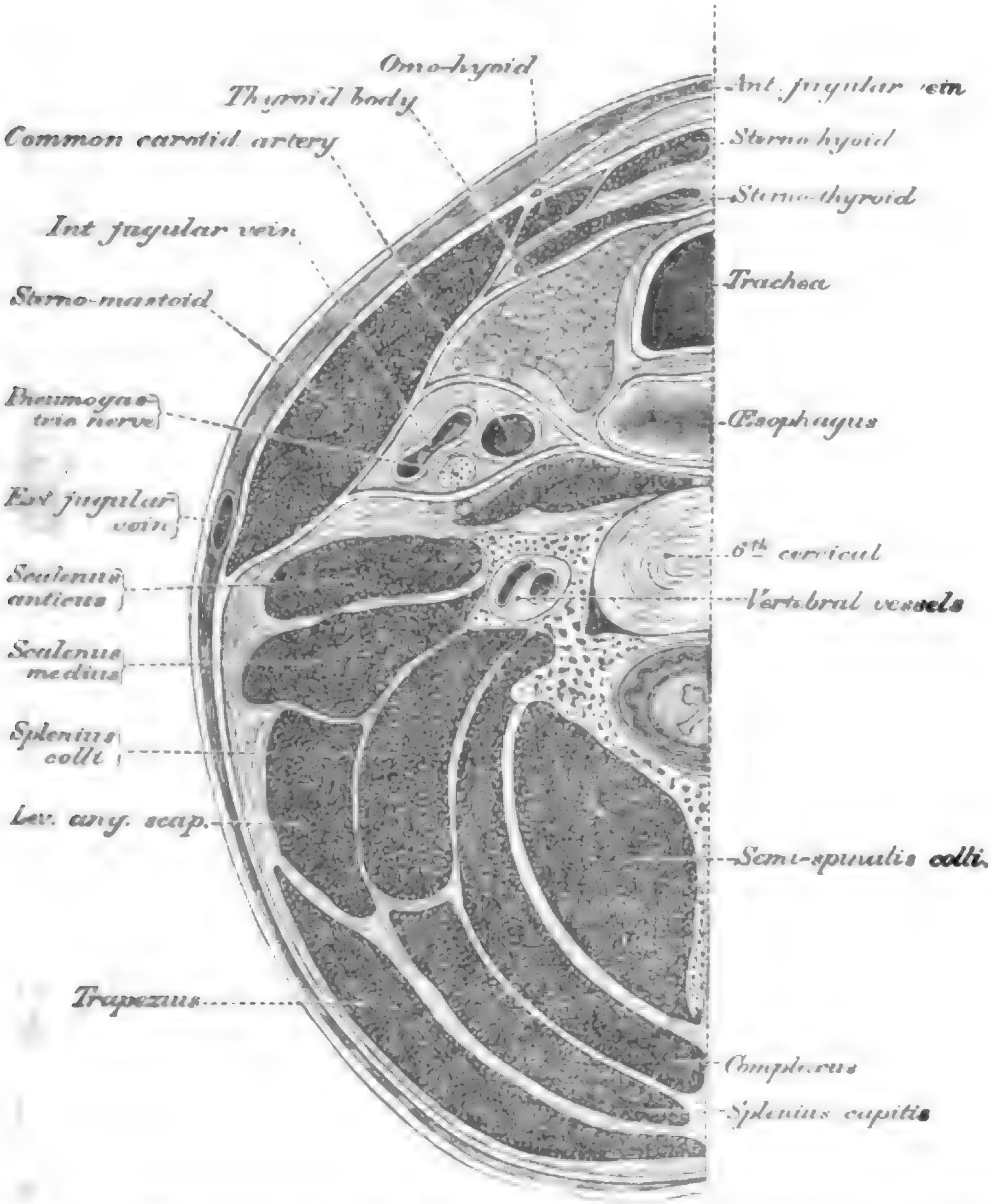
Omo-hyoid
Thyroid body
Common carotid artery
Int. jugular vein
Sterno-mastoid
Pneumogastric nerve
Ext. jugular vein
Scalenus anticus
Scalenus medius
Splenius colli
Lev. ang. scap.
Trapezius
Ant. jugular vein
Sterno-hyoid
Sterno-thyroid
Trachea
Œsophagus
6th cervical
Vertebral vessels
Semi-spinalis colli
Complexus
Splenius capitis

Section of the Neck at about the level of the Sixth Cervical Vertebra, showing the arrangement of the Deep Cervical Fascia.

the back part of the neck, where it is attached to the spinous process of the seventh cervical vertebra and to the ligamentum nuchæ, and, passing forward, invests the Trapezius muscle; from the anterior border of this muscle it forms a layer which covers in the posterior triangle of the neck, and, passing forward to the posterior border of the Sterno-mastoid muscle, divides into two layers, one of which passes in front and the other behind that muscle. These join again at the anterior border of the Sterno-mastoid, and, being continued forward to the front of the neck, blend with the fascia of the opposite side covering the anterior triangle. If traced upward, it is found to pass across the parotid gland and Masseter muscle, forming the parotid and masseteric fascia, and is attached to the lower border of the zygoma, and more anteriorly to the lower border of the body of the jaw; if traced downward, it is seen to pass to the upper border of the clavicle and sternum, being pierced just above the former bone by the external jugular vein. In the middle line of the neck the fascia is thin above and connected to the hyoid bone; but it becomes thicker below, and divides, just below the thyroid gland, into two layers, the more superficial of which is attached to the upper border of the sternum and interclavicular ligament; the deeper and stronger layer is connected to the posterior border of that bone, covering in the Sterno-hyoid and Sterno-thyroid muscles. Between these two layers is a little areolar tissue and fat, and occasionally a small lymphatic gland. The deep layer of the cervical fascia (that which lies behind the posterior surface of the Sterno-mastoid) sends numerous prolongations, which invest the muscles and vessels of the neck; if traced upward, a process of the fascia of extreme density is found passing behind and to the inner side of the parotid gland, to be attached to the apex of the styloid process and angle of the lower jaw, termed the *stylo-maxillary* ligament; if traced downward and outward, the fascia will be found to enclose the posterior belly of the Omo-hyoid muscle, binding it down by a distinct process which descends to be inserted into the sternum and cartilage of the first rib, and becomes connected with the costo-coracoid membrane. The deep layer of the cervical fascia also assists in forming the sheath which encloses the common carotid artery, internal jugular vein, and pneumogastric nerve. There are fibrous septa intervening between each of these parts, which, however, are included together in one common investment. More internally, a thin layer is continued across the trachea and thyroid gland, beneath the Sterno-thyroid muscles, and at the root of the neck this may be traced, over the large vessels, to be continuous with the fibrous

FIG. 290.

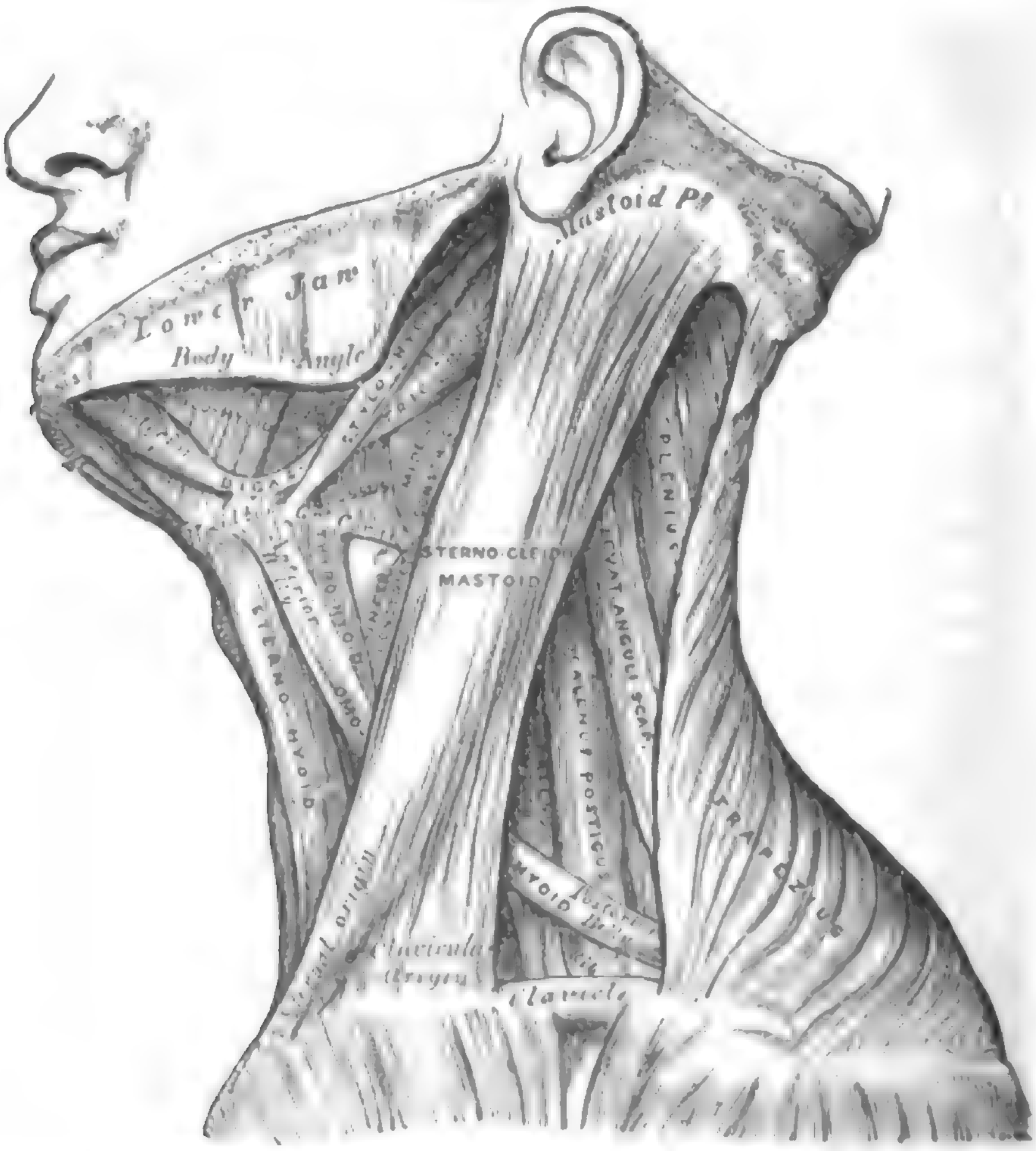

Muscles of the Neck and Boundaries of the Triangles.

layer of the pericardium. Lastly a layer of fascia, the *prevertebral fascia*, is derived from the under surface of the cervical fascia; this passes beneath the carotid vessels, forming the back of the sheath, and is then prolonged inward, behind the pharynx and œsophagus, forming a sheath for the Prevertebral muscles, and downward and outward over the Scaleni muscles, the brachial plexus, and subclavian vessels, to assist in forming the axillary sheath.

The **Sterno-mastoid,** or **Sterno-cleido-mastoid** (Fig. 290), is a large thick muscle, which passes obliquely across the side of the neck, being enclosed between the two layers of the deep cervical fascia. It is thick and narrow at its central part, but is broader and thinner at each extremity. It arises by two heads from the sternum and clavicle. The *sternal portion* is a rounded fasciculus, tendinous in front, fleshy behind, which arises from the upper and anterior part of the first piece of the sternum, and is directed upward, outward, and backward. The *clavicular portion* arises from the inner third of the superior border of the clavicle, being composed of fleshy and aponeurotic fibres; it is directed almost vertically upward. These two portions are separated from one another at their origin by a triangular cellular interval, but become gradually blended below the middle of the neck into a thick rounded muscle, which is inserted by a strong tendon into the outer surface of the mastoid process from its apex to its superior border, and by a thin aponeurosis into the outer two-thirds of the superior curved line of the occipital bone. The Sterno-mastoid varies much in its extent of attachment to the clavicle: in one case the clavicular may be as narrow as the sternal portion; in another, as much as three inches in breadth. When the clavicular origin is broad, it is occasionally subdivided into numerous slips separated by narrow intervals. More rarely, the corresponding margins of the Sterno-mastoid and Trapezius have been found in contact. In the application of a ligature to the third part of the subclavian artery it will be necessary, where the muscles come close together, to divide a portion of one or of both.

This muscle divides the quadrilateral space at the side of the neck into two triangles, an anterior and a posterior. The boundaries of the *anterior* triangle are, in front, the median line of the neck; above, the lower border of the body of the jaw and an imaginary line drawn from the angle of the jaw to the mastoid process; behind, the anterior border of the Sterno-mastoid muscle. The boundaries of the *posterior* triangle are, in front, the posterior border of the Sterno-mastoid; below, the upper border of the clavicle; behind, the anterior margin of the Trapezius.[1]

The anterior edge of the muscle forms a very prominent ridge beneath the skin which it is important to notice, as it forms a guide to the surgeon in making the necessary incisions for ligature of the common carotid artery and for œsophagotomy.

Relations.—By its *superficial surface* with the integument and Platysma, from which it is separated by the external jugular vein, the superficial branches of the cervical plexus, and the anterior layer of the deep cervical fascia. By its *deep surface* it rests on the sterno-clavicular articulation, the deep layer of the cervical fascia, the Sterno-hyoid, Sterno-thyroid, Omo-hyoid, the posterior belly of the Digastric, Levator anguli scapulæ, the Splenius, and Scaleni muscles. Below it is in relation with the lower part of the common carotid artery, internal jugular vein, pneumogastric, descendens noni, and communicans noni nerves, and with the deep lymphatic glands—with the spinal accessory nerve, which pierces its upper third, the cervical plexus, the occipital artery, and part of the parotid gland.

Nerves.—The Platysma myoides is supplied by the facial and superficial branches of the cervical plexus; the Sterno-cleido-mastoid, by the spinal accessory and deep branches of the cervical plexus.

Actions.—The Platysma myoides produces a slight wrinkling of the surface of the skin of the neck in an oblique direction when the entire muscle is brought into action. Its anterior portion, the thickest part of the muscle, depresses the lower jaw; it also serves to draw down the lower lip and angle of the mouth on each side, being one of the chief agents in the expression of melancholy. The Sterno-mastoid muscles, when both are brought into action, serve to depress the head upon the neck and the neck upon the chest. Either muscle, acting singly, flexes the head, and (combined with the Splenius and the Obliquus inferior capitis of the opposite side) draws it toward the shoulder of the same side, and rotates it so as to carry the face toward the opposite side. If the head is fixed they assist in elevating the thorax in forced inspiration. [The action of the Platysma can be well shown in the living model by its voluntary contraction, either unilateral or bilateral. Its striated oblique bundles of fibres, and its action in drawing up the skin of the chest even as far down as the nipple, are well seen. The Sterno-mastoid is best brought out by endeavoring to turn the chin to one side and forcibly resisting this motion by one hand. The rounded sternal cord shows especially well.]

---

[1] The anatomy of these triangles will be more exactly described with that of the vessels of the neck.

Surgical Anatomy.—The relations of the sternal and clavicular parts of the Sterno-mastoid should be carefully examined, as the surgeon is sometimes required to divide one or both portions of the muscle in *wry-neck*. One variety of this distortion is produced by spasmodic contraction or rigidity of the Sterno-mastoid, the head being carried down toward the shoulder of the same side, and the face turned to the opposite side and fixed in that position. When all other remedies for the relief of this disease have failed subcutaneous division of the muscle is resorted to. This is performed by introducing a tenotomy-knife beneath it about half an inch above its origin, and dividing it from behind forward whilst the muscle is put well upon the stretch. There is seldom any difficulty in dividing the sternal portion. In dividing the clavicular portion care must be taken to avoid wounding the external jugular vein, which runs parallel with the posterior border of the muscle in this situation, or the anterior jugular vein, which crosses beneath it.

2. Infrahyoid Region (Figs. 290, 291).

Depressors of the Os Hyoides and Larynx.

Sterno-hyoid.	Thyro-hyoid.
Sterno-thyroid.	Omo-hyoid.

Dissection.—The muscles in this region may be exposed by removing the deep fascia from the front of the neck. In order to see the entire extent of the Omo-hyoid, it is necessary to divide the Sterno-mastoid at its centre and turn its ends aside, and to detach the Trapezius from the clavicle and scapula. This, however, should not be done until the Trapezius has been dissected.

The **Sterno-hyoid** is a thin, narrow, ribbon-like muscle which arises from the inner extremity of the clavicle and the upper and posterior part of the first piece of the sternum; passing upward and inward, it is inserted by short tendinous fibres into the lower border of the body of the os hyoides. This muscle is separated below from its fellow by a considerable interval, but they approach one another in the middle of their course, and again diverge as they ascend. It sometimes presents, immediately above its origin, a transverse tendinous intersection, like those in the Rectus abdominis.

Relations.—By its *superficial surface* below with the sternum, the sternal end of the clavicle, and the Sterno-mastoid, and above with the Platysma and deep cervical fascia; by its *deep surface* with the Sterno-thyroid, Crico-thyroid, and Thyro-hyoid muscles, the thyroid gland, the superior thyroid vessels, the crico-thyroid and thyro-hyoid membranes.

The **Sterno-thyroid** is situated beneath the preceding muscle, but is shorter and wider than it. It arises from the posterior surface of the first bone of the sternum below the origin of the Sterno-hyoid, and generally from the edge of the cartilage of the first rib, and is inserted into the oblique line on the side of the ala of the thyroid cartilage. This muscle is in close contact with its fellow at the lower part of the neck, and is occasionally traversed by a transverse or oblique tendinous intersection, like those in the Rectus abdominis.

Relations.—By its *anterior surface* with the Sterno-hyoid, Omo-hyoid, and Sterno-mastoid; by its *posterior surface*, from below upward, with the trachea, vena innominata, common carotid (and on the right side the arteria innominata), the thyroid gland and its vessels, and the lower part of the larynx. The middle thyroid vein lies along its inner border—a relation which it is important to remember in the operation of tracheotomy.

The **Thyro-hyoid** is a small quadrilateral muscle appearing like a continuation of the Sterno-thyroid. It arises from the oblique line on the side of the thyroid cartilage, and passes vertically upward to be inserted into the lower border of the body and greater cornu of the hyoid bone.

FIG. 291.

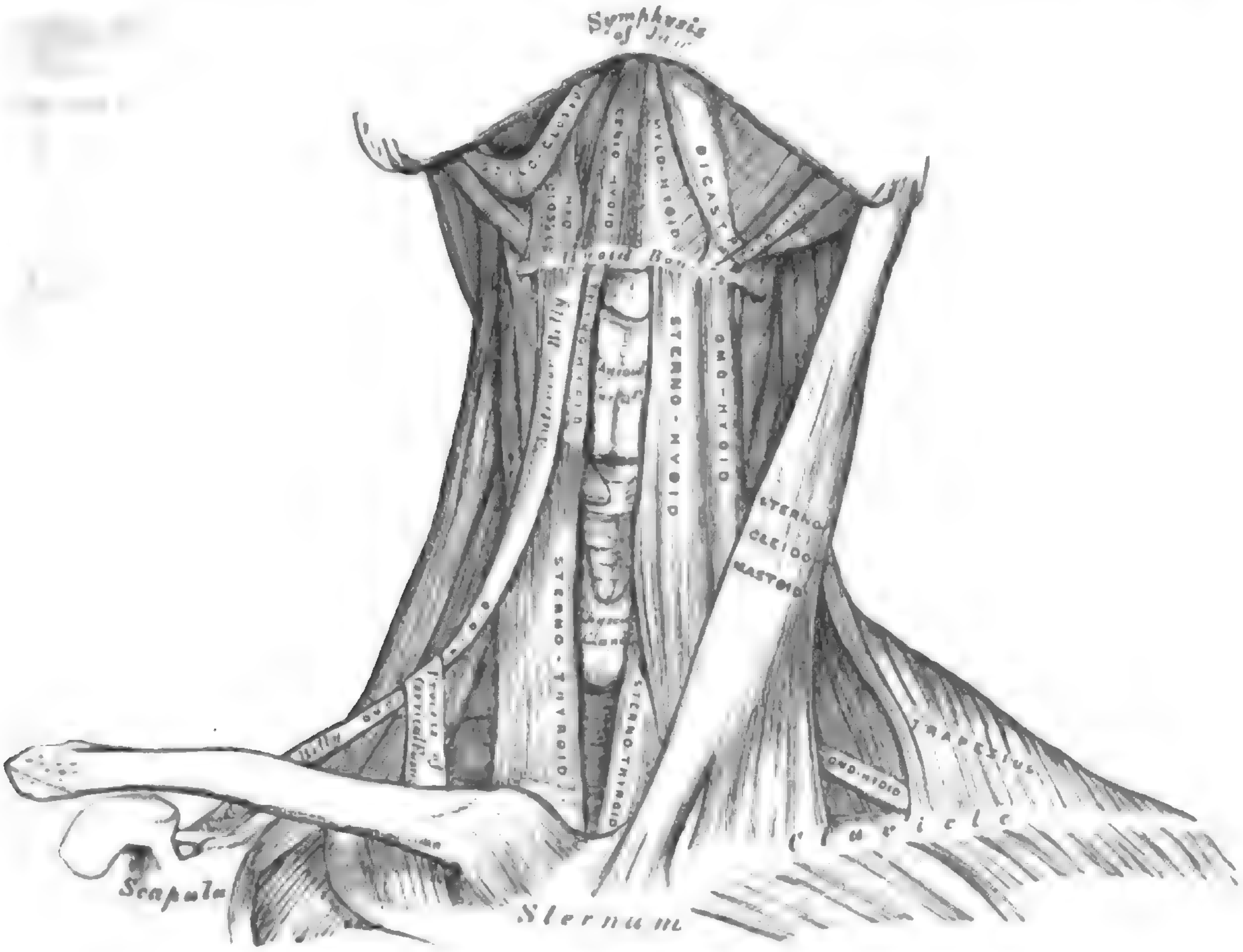

Muscles of the Neck, anterior view.

RELATIONS.—By its *external surface* with the Sterno-hyoid and Omo-hyoid muscles; by its *internal surface* with the thyroid cartilage, the thyro-hyoid membrane, and the superior laryngeal vessels and nerve.

The **Omo-hyoid** passes across the side of the neck from the scapula to the hyoid bone. It consists of two fleshy bellies united by a central tendon. It arises from the upper border of the scapula, and occasionally from the transverse ligament which crosses the suprascapular notch, its extent of attachment to the scapula varying from a few lines to an inch. From this origin the posterior belly forms a flat, narrow fasciculus which inclines forward across the lower part of the neck, behind the Sterno-mastoid muscle, where it becomes tendinous; it then changes its direction, forming an obtuse angle, and the anterior belly ascends almost vertically upward close to the outer border of the Sterno-hyoid, to be inserted into the lower border of the body of the os hyoides just external to the insertion of the Sterno-hyoid. The tendon of this muscle, which varies much in its length and form in different subjects, is held in its position by a process of the deep cervical fascia, which includes it in a sheath, and is prolonged down to be attached to the cartilage of the first rib and the sternum. It is by this means that the angular form of the muscle is maintained.

This muscle subdivides each of the two large triangles at the side of the neck into two smaller triangles, the two posterior ones being the *posterior superior* or *occipital* and the *posterior inferior* or *subclavian;* the two anterior, the *anterior superior* or *superior carotid* and the *anterior inferior* or *inferior carotid* triangle.

Relations.—By its *superficial surface* with the Trapezius, Subclavius, the clavicle, the Sterno-mastoid, deep cervical fascia, Platysma, and integument; by its *deep surface* with the Scaleni, phrenic nerve, lower cervical nerves, sheath of the common carotid artery and internal jugular vein, the Sterno-thyroid and Thyro-hyoid muscles.

Nerves.—The Thyro-hyoid is supplied by the hypoglossal, the other muscles of this group by branches from the loop of communication between the descendens and communicans noni.

Actions.—These muscles depress the larynx and hyoid bone after they have been drawn up with the pharynx in the act of deglutition. The Omo-hyoid muscles not only depress the hyoid bone, but carry it backward and to one or the other side. It is concerned especially in the act of sucking. They are also tensors of the cervical fascia. The Thyro-hyoid may act as an elevator of the thyroid cartilage when the hyoid bone ascends, drawing upward the thyroid cartilage behind the os hyoides.[1]

3. Suprahyoid Region (Figs. 290, 291).

Elevators of the Os Hyoides—Depressors of the Lower Jaw.

Digastric.	Mylo-hyoid.
Stylo-hyoid.	Genio-hyoid.

Dissection.—To dissect these muscles a block should be placed beneath the back of the neck, and the head drawn backward and retained in that position. On the removal of the deep fascia the muscles are at once exposed.

The **Digastric** consists of two fleshy bellies united by an intermediate rounded tendon. It is a small muscle, situated below the side of the body of the lower jaw, and extending in a curved form from the side of the head to the symphysis of the jaw. The *posterior belly*, longer than the anterior, arises from the digastric groove on the inner side of the mastoid process of the temporal bone, and passes downward, forward, and inward. The *anterior belly* arises from a depression on the inner side of the lower border of the jaw close to the symphysis, and passes downward and backward. The two bellies are inserted into a central tendon which perforates the Stylo-hyoid, and is held in connection with the side of the body and the greater cornu of the hyoid bone by a fibrous loop lined by a synovial membrane. A broad aponeurotic layer is given off from the tendon of the Digastric on each side, which is attached to the body and great cornu of the hyoid bone: this is termed the *suprahyoid aponeurosis*. It forms a strong layer of fascia between the anterior portion of the two muscles, and a firm investment for the other muscles of the supra-hyoid region which lie deeper.

The Digastric muscle divides the anterior superior triangle of the neck into two smaller triangles, the upper or *submaxillary* being bounded above by the lower jaw and mastoid process; below, by the two bellies of the Digastric muscle, the lower or *superior carotid* triangle being bounded above by the posterior belly of the Digastric; behind, by the Sterno-mastoid; below, by the Omo-hyoid.

Relations.—By its *superficial surface* with the Platysma, Sterno- and Trachelo-mastoid, part of the Stylo-hyoid muscle, and the parotid gland; by its *deep surface* the anterior belly lies on the Mylo-hyoid; the posterior belly, on the Stylo-glossus, Stylo-pharyngeus, and Hyo-glossus muscles, the external carotid artery and its lingual and facial branches, the internal carotid artery, internal jugular vein, and hypoglossal nerve.

The **Stylo-hyoid** is a small, slender muscle lying in front of and above the posterior belly of the Digastric. It arises from the outer surface of the styloid process near the base, and, passing downward and forward, is inserted into the body of the hyoid bone just at its junction with the greater cornu and immediately above the Omo-hyoid. This muscle is perforated near its insertion by the tendon of the Digastric.

---

[1] It is this action of the Thyro-hyoid muscle which, as Dr. Buchanan has pointed out, "causes or permits the folding back of the epiglottis over the upper orifice of the larynx" (*Journ. of Anat. and Phys.*, 2d Series, No. III. p. 255).

RELATIONS.—The same as the posterior belly of the Digastric.

The Digastric and Stylo-hyoid should be removed, in order to expose the next muscle.

The **Mylo-hyoid** is a flat triangular muscle situated immediately beneath the anterior belly of the Digastric, and forming, with its fellow of the opposite side, a muscular floor for the cavity of the mouth. It arises from the whole length of the mylo-hyoid ridge, from the symphysis in front to the last molar tooth behind. The posterior fibres pass obliquely forward, to be inserted into the body of the os hyoides. The middle and anterior fibres are inserted into a median fibrous raphé, where they join at an angle with the fibres of the opposite muscle. This median raphé is sometimes wanting; the muscular fibres of the two sides are then directly continuous with one another.

RELATIONS.—By its *cutaneous surface* with the Platysma, the anterior belly of the Digastric, the suprahyoid fascia, the submaxillary gland, submental vessels, and mylo-hyoid vessels and nerve; by its *deep* or *superior surface* with the Genio-hyoid, part of the Hyo-glossus, and Stylo-glossus muscles, the hypoglossal and gustatory nerves, the sublingual gland, and the buccal mucous membrane. Wharton's duct curves round its posterior border in its passage to the mouth.

Dissection.—The Mylo-hyoid should now be removed, in order to expose the muscles which lie beneath; this is effected by detaching it from its attachments to the hyoid bone and jaw, and separating it by a vertical incision from its fellow of the opposite side.

The **Genio-hyoid** is a narrow, slender muscle situated immediately beneath[1] the inner border of the preceding. It arises from the inferior genial tubercle on the inner side of the symphysis of the jaw, and passes downward and backward to be inserted into the anterior surface of the body of the os hyoides. This muscle lies in close contact with its fellow of the opposite side, and increases slightly in breadth as it descends.

RELATIONS.—It is covered by the Mylo-hyoid and lies on the Genio-hyo-glossus.

NERVES.—The Digastric is supplied, its anterior belly, by the mylo-hyoid branch of the inferior dental; its posterior belly, by the facial; the Stylo-hyoid, by the facial; the Mylo-hyoid, by the mylo-hyoid branch of the inferior dental; the Genio-hyoid, by the hypoglossal.

ACTIONS.—This group of muscles performs two very important actions. They raise the hyoid bone, and with it the base of the tongue, during the act of deglutition; or, when the hyoid bone is fixed by its depressors and those of the larynx, they depress the lower jaw. During the first act of deglutition, when the mass is being driven from the mouth into the pharynx, the hyoid bone, and with it the tongue, is carried upward and forward by the anterior belly of the Digastric, the Mylo-hyoid, and Genio-hyoid muscles. In the second act, when the mass is passing through the pharynx, the direct elevation of the hyoid bone takes place by the combined action of all the muscles; and after the food has passed the hyoid bone is carried upward and backward by the posterior belly of the Digastric and Stylo-hyoid muscles, which assist in preventing the return of the morsel into the mouth.

4. LINGUAL REGION.

Genio-hyo-glossus.
Hyo-glossus.
Lingualis.
Stylo-glossus.
Palato-glossus.

Dissection.—After completing the dissection of the preceding muscles saw through the lower jaw just external to the symphysis. Then draw the tongue forward, and attach it by a stitch to the nose, and its muscles, which are thus put on the stretch, may be examined.

---

[1] This refers to the depth of the muscles from the skin in dissecting. In the erect position of the body each of these muscles lies above the preceding.

The **Genio-hyo-glossus** has received its name from its triple attachment to the jaw, hyoid bone, and tongue: it is a thin, flat, triangular muscle placed vertically on either side of the middle line, its apex corresponding with its point of attachment to the lower jaw, its base with its insertion into the tongue and hyoid bone. It arises by a short tendon from the superior genial tubercle on the inner side of the symphysis of the jaw, immediately above the Genio-hyoid; from this point the muscle spreads out in a fan-like form, the inferior fibres passing downward, to be inserted into the upper part of the body of the hyoid bone, a few being continued into the side of the pharynx; the middle fibres passing backward, and the superior ones upward and forward, to be attached to the whole length of the under surface of the tongue from the base to the apex.

Relations.—By its *internal surface* it is in contact with its fellow of the opposite side, from which it is separated, at the back part of the tongue, by the fibrous septum, which extends through the middle of the organ; by its *external surface* with the inferior lingualis, Hyo-glossus, and Stylo-glossus, the lingual artery and hypoglossal nerve, the gustatory nerve, and sublingual gland; by its *upper border* with the mucous membrane of the floor of the mouth (frænum linguæ); by its *lower border* with the Genio-hyoid.

The **Hyo-glossus** is a thin, flat, quadrilateral muscle which arises from the side of the body, the lesser cornu, and whole length of the greater cornu of the hyoid bone, and, passing almost vertically upward, is inserted into the side of the tongue between the Stylo-glossus and Lingualis. Those fibres of this muscle which arise from the body (Basio-glossus) are directed upward and backward, overlapping those from the greater cornu (Kerato-glossus), which are directed obliquely forward. Those from the lesser cornu (Chondro-glossus) extend forward and outward along the side of the tongue under cover of the portion arising from the body.

Fig. 292.

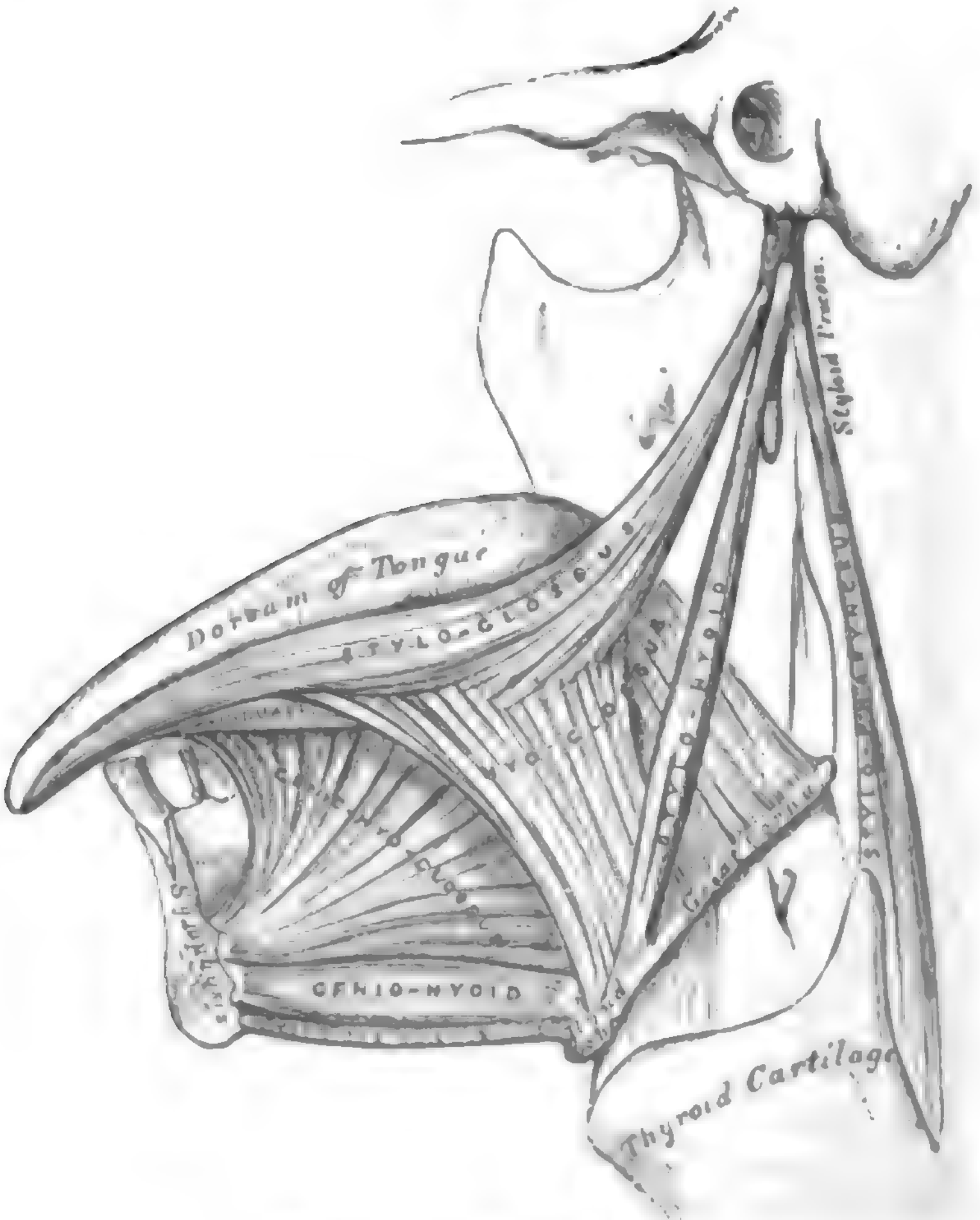

Muscles of the Tongue, left side.

The difference in the direction of the fibres of this muscle, and their separate origin from different parts of the hyoid bone, led Albinus and other anatomists to describe it as three muscles, under the names of the Basio-glossus, the Kerato-glossus, and the Chondro-glossus. Undoubtedly, the Chondro-glossus is distinct from the rest, and at the present day is described by some anatomists as a separate muscle. Sometimes it is separated from the rest of the muscle by a few fibres of the Genio-hyo-glossus passing to the side of the pharynx; at other times it is altogether absent.

Fig. 293.

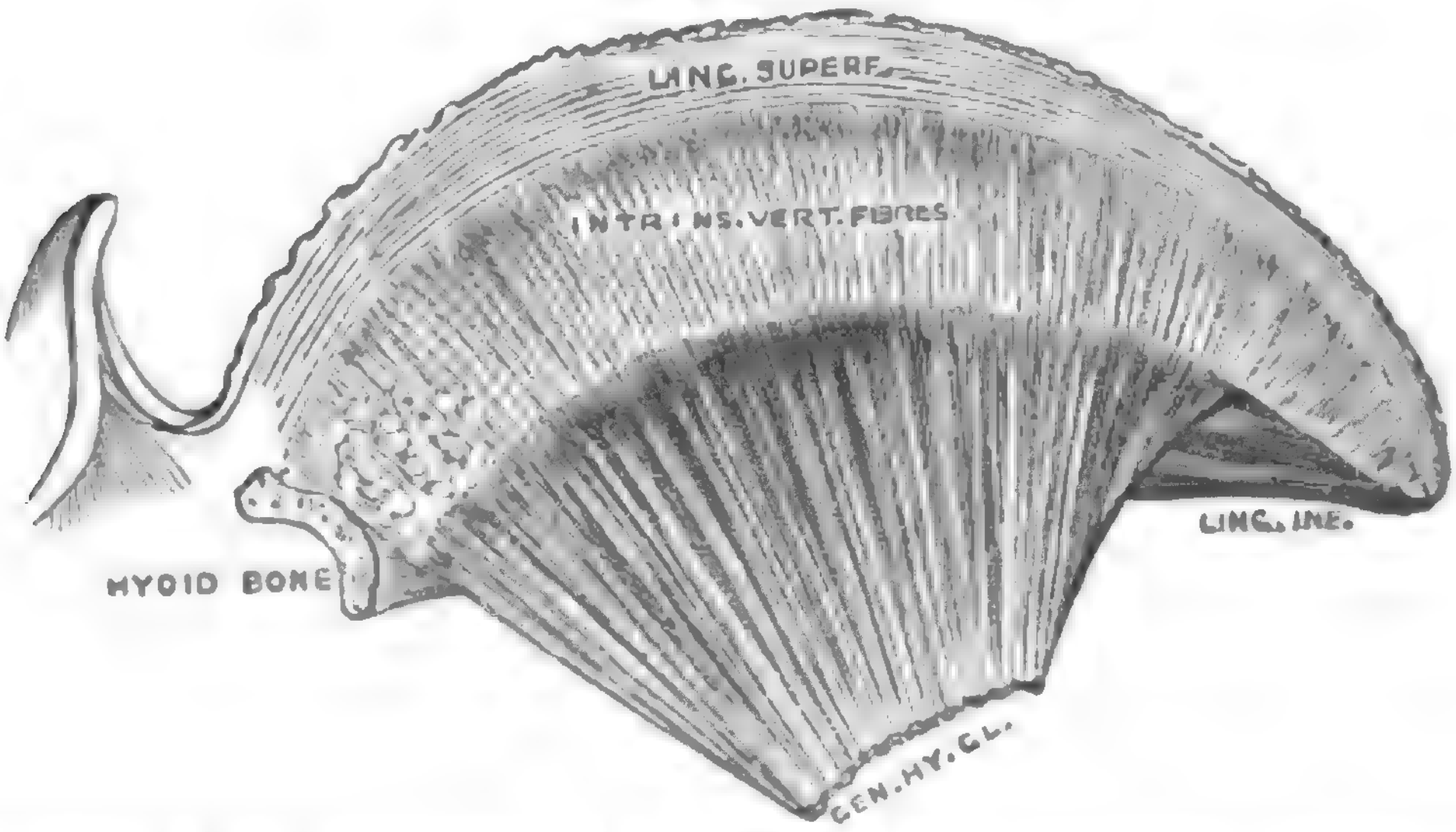

A Longitudinal Section of the Tongue near the middle line, to show the Superficial lingualis and the intrinsic vertical fibres.

Relations.—By its *external surface* with the Digastric, the Stylo-hyoid, Stylo-glossus, and Mylo-hyoid muscles, the gustatory and hypoglossal nerves, Wharton's duct, and the submaxillary gland; by its *deep surface* with the Genio-hyo-glossus, Lingualis, and Middle constrictor, the lingual vessels, and the glosso-pharyngeal nerve.

The greater part of the muscular substance of the tongue is formed by its intrinsic muscle, the **Lingualis**, inferior, superficial, transverse, and vertical. The *inferior* lingualis (Figs. 292, 293) is a longitudinal band of muscular fibres situated on the under surface of the tongue, lying in the interval between the Hyo-glossus and the Genio-hyo-glossus, and extending from the base to the apex of the organ. Posteriorly, some of its fibres are lost in the base of the tongue, and others are occasionally attached to the hyoid bone. It blends with the fibres of the Stylo-glossus in front of the Hyo-glossus, and is continued forward as far as the apex of the tongue. It is in relation, by its under surface, with the ranine artery. The *superficial* lingualis (Fig. 293) consists of fibres running more or less longitudinally along the dorsum of the tongue beneath the mucous membrane from base to apex, and blending with the deeper fibres. At the sides of the tongue these fibres are crossed by those of the Palato- and Hyo-glossus. Between these two sets of fibres are found transverse fibres (Fig. 294) which arise from the median septum and blend with the fibres of the Palato-glossus and other muscles, as well as a large number of vertical fibres. The vertical fibres are arranged somewhat parallel with those of the Genio-hyo-glossus, with which

Fig. 294.

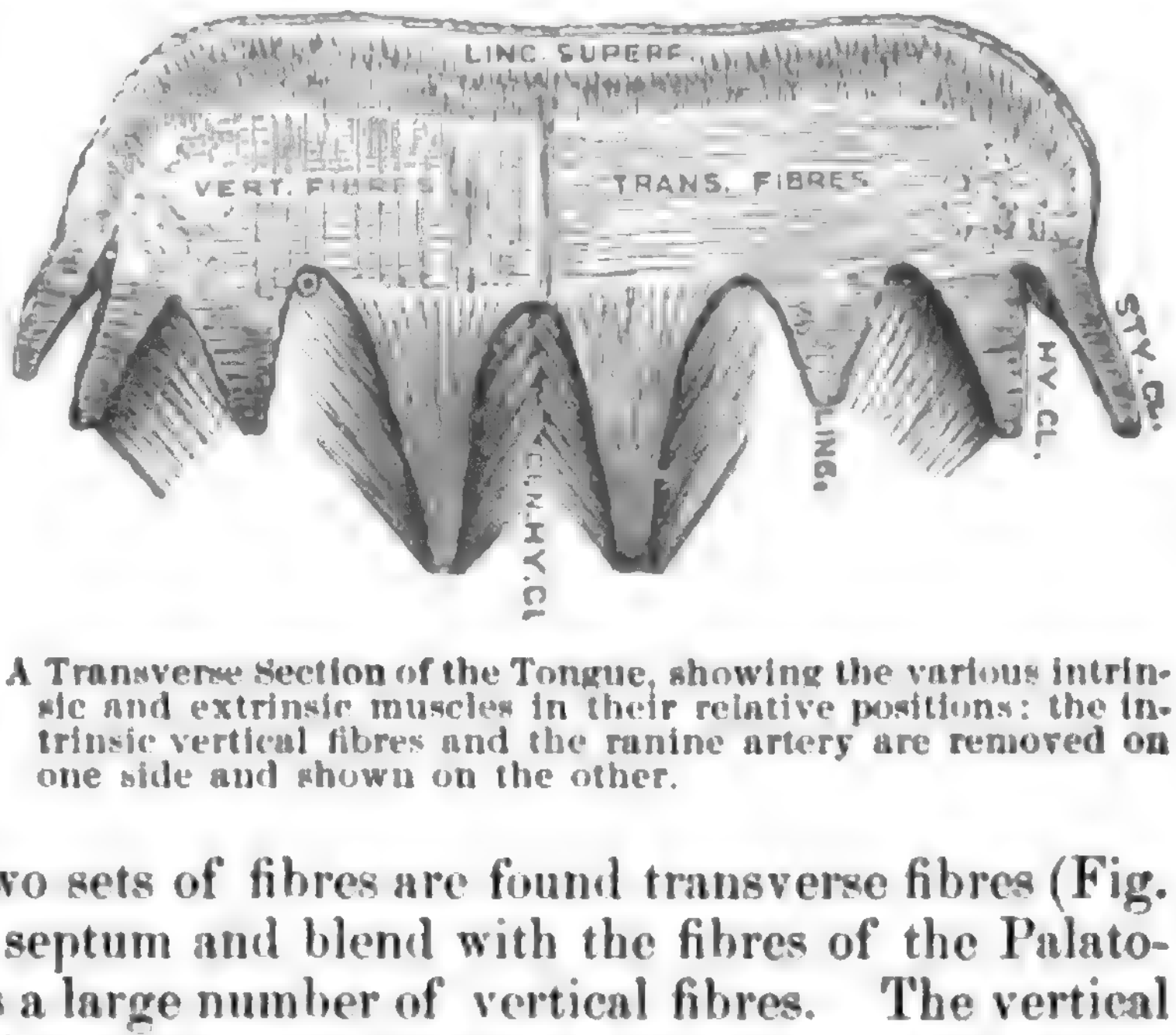

A Transverse Section of the Tongue, showing the various intrinsic and extrinsic muscles in their relative positions: the intrinsic vertical fibres and the ranine artery are removed on one side and shown on the other.

many of those near the middle line are continuous; they extend from the upper to the lower surface of the tongue, decussating with the fibres of the other muscles, and especially with the transverse. The interstices of the muscular fibres are filled with a large quantity of fat and glandular tissue.

A very distinct fibrous septum exists between the two halves of the tongue, so that the anastomoses between the two lingual arteries are not very free—a fact often illustrated by injecting one half of the tongue with colored size, while the other is left uninjected or is injected of a different color.

The **Stylo-glossus**, the shortest and smallest of the three styloid muscles, arises from the anterior and outer side of the styloid process near its apex, and from the stylo-maxillary ligament, to which its fibres in most cases are attached by a thin aponeurosis. Passing downward and forward, so as to become nearly horizontal in its direction, it divides upon the side of the tongue into two portions—one longitudinal, which is inserted along the side of the tongue, blending with the fibres of the Lingualis in front of the Hyo-glossus; the other oblique, which overlaps the Hyo-glossus muscle and decussates with its fibres.

RELATIONS.—By its *external surface*, from above downward, with the parotid gland, the Internal pterygoid muscle, the sublingual gland, the gustatory nerve, and the mucous membrane of the mouth; by its *internal surface* with the tonsil, the Superior constrictor, and the Hyo-glossus muscle.

The **Palato-glossus** or **Constrictor isthmi faucium**, although it is one of the muscles of the tongue, serving to draw its base upward during the act of deglutition, is more nearly associated with the soft palate both in its situation and function; it will consequently be described with that group of muscles.

NERVES.—The Palato-glossus is supplied by the palatine branches of Meckel's ganglion; the Lingualis, according to some authors, by the chorda tympani; the remaining muscles of this group, by the hypoglossal.

ACTIONS.—The movements of the tongue, although numerous and complicated, may be understood by carefully considering the direction of the fibres of its muscles. The *Genio-hyo-glossi* by means of their posterior and inferior fibres draw upward the hyoid bone, bringing it and the base of the tongue forward, so as to protrude the apex from the mouth. The anterior fibres draw the tongue back into the mouth. In their whole length these two muscles, acting along the middle line of the tongue, draw it downward, so as to make it concave from side to side, forming a channel along which fluids may pass toward the pharynx, as in sucking. The *Hyo-glossi* muscles draw down the sides of the tongue, so as to render it convex from side to side. The *Linguales*, superficial and inferior, by drawing downward the centre and apex of the tongue render it convex from before backward. The *Palato-glossi* draw the base of the tongue upward, and the *Stylo-glossi* upward and backward.

5. PHARYNGEAL REGION.

Constrictor inferior.	Constrictor superior.
Constrictor medius.	Stylo-pharyngeus.

Palato-pharyngeus. (See next section.)

Dissection (Fig. 295).—In order to examine the muscles of the pharynx, cut through the trachea and œsophagus just above the sternum, and draw them upward by dividing the loose areolar tissue connecting the pharynx with the front of the vertebral column. The parts being drawn well forward, apply the edge of the saw immediately behind the styloid processes and saw the base of the skull through from below upward. The pharynx and mouth should then be stuffed with tow, in order to distend its cavity and render the muscles tense and easier of dissection.

The **Inferior Constrictor**, the most superficial and thickest of the three constrictors, arises from the side of the cricoid and thyroid cartilages. To the cricoid cartilage it is attached in the interval between the Crico-thyroid muscle in front and the articular facet for the thyroid cartilage behind. To the thyroid cartilage it is attached along the oblique line on the side of the great ala, the cartilaginous surface behind it nearly as far as its posterior border, and to the inferior cornu. From these attachments the fibres spread backward and inward, to be inserted into the fibrous raphé in the posterior median line of the pharynx. The inferior fibres are horizontal, and continuous with the fibres of the œsophagus; the rest ascend, increasing in obliquity, and overlap the Middle constrictor. The superior laryngeal nerve and artery pass near the upper border, and the inferior or recurrent laryngeal beneath the lower border of this muscle, previous to their entering the larynx.

Fig. 295.

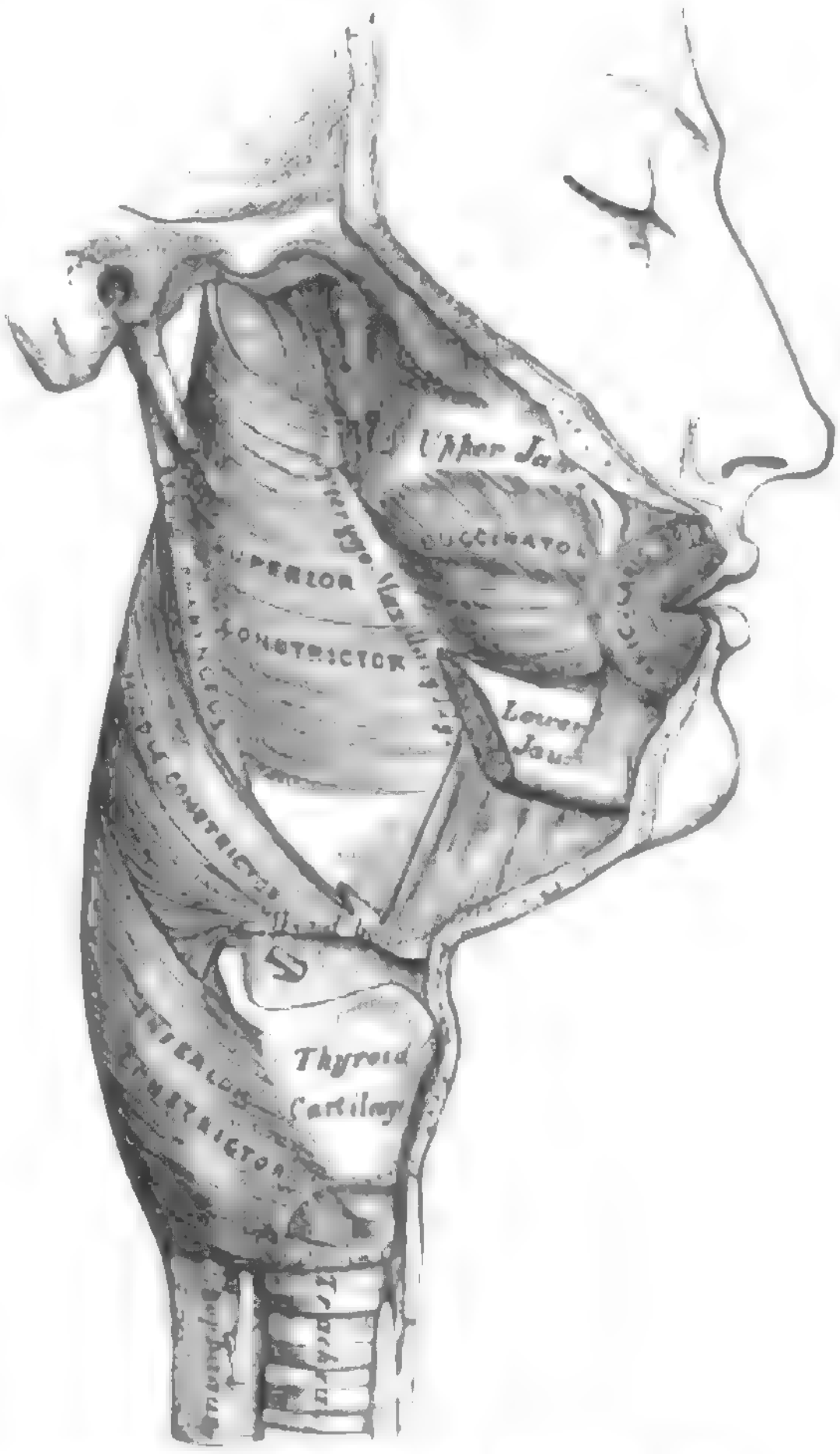

Muscles of the Pharynx, external view.

Relations.—It is covered by a dense cellular membrane which surrounds the entire pharynx. *Behind* it is in relation with the vertebral column and the Longus colli muscle; *laterally*, with the thyroid gland, the common carotid artery, and the Sterno-thyroid muscle; by its *internal surface*, with the Middle constrictor, the Stylo-pharyngeus, Palato-pharyngeus, the fibrous coat and mucous membrane of the pharynx.

The **Middle Constrictor** is a flattened, fan-shaped muscle smaller than the preceding. It arises from the whole length of the upper surface of the greater cornu of the hyoid bone, from the lesser cornu, and from the stylo-hyoid ligament. The fibres diverge from their origin, the lower ones descending beneath the Inferior constrictor, the middle fibres passing transversely, and the upper fibres ascending and overlapping the Superior constrictor. The muscle is inserted into the posterior median fibrous raphé, blending in the middle line with that of the opposite side.

Relations.—This muscle is separated from the Superior constrictor by the glosso-pharyngeal nerve and the Stylo-pharyngeus muscle, and from the Inferior constrictor by the superior laryngeal nerve. *Behind* it lies on the vertebral column, the Longus colli, and the Rectus capitis anticus major. *On each side* it is in relation with the carotid vessels, the pharyngeal plexus, and some lymphatic glands. Near its origin it is covered by the Hyo-glossus, from which it is separated by the lingual vessels It lies upon the Superior constrictor, the Stylo-pharyngeus, the Palato-pharyngeus, the fibrous coat, and the mucous membrane of the pharynx.

The **Superior Constrictor** is a quadrilateral muscle thinner and paler than the other constrictors, and situated at the upper part of the pharynx. It arises from the lower third of the posterior margin of the internal pterygoid plate and its hamular process, from the contiguous portion of the palate bone and the reflected tendon of the Tensor palati muscle, from the pterygo-maxillary ligament, from the alveolar process above the posterior extremity of the mylo-hyoid ridge, and by a few fibres from the side of the tongue in connection with the Genio-hyo-glossus. From these points the fibres curve backward, to be inserted into the median raphé, being also prolonged by means of a fibrous aponeurosis to the pharyngeal spine on the basilar process of the occipital bone. The superior fibres arch beneath the Levator palati and the Eustachian tube, the interval between the upper border of the muscle and the basilar process being deficient in muscular fibres and closed by fibrous membrane. This interval is known as *the sinus of Morgagni*.

Relations.—By its *outer surface* with the vertebral column, the internal carotid artery, the internal jugular vein, the pneumogastric, glosso-pharyngeal, and spinal accessory nerves, the sympathetic, the hypoglossal nerve, the Middle constrictor, which overlaps it, and the Stylo-pharyngeus. It covers the Palato-pharyngeus and the tonsil, and is lined by the fibrous coat and by mucous membrane.

The **Stylo-pharyngeus** is a long, slender muscle, round above, broad and thin below. It arises from the inner side of the base of the styloid process, passes downward along the side of the pharynx between the Superior and Middle constrictors, and spreads out beneath the mucous membrane, where some of its fibres are lost in the Constrictor muscles, and others, joining with the Palato-pharyngeus, are inserted into the posterior border of the thyroid cartilage. The glosso-pharyngeal nerve runs on the outer side of this muscle and crosses over it in passing forward to the tongue.

RELATIONS.—*Externally* with the Stylo-glossus muscle, the external carotid artery, the parotid gland, and the Middle constrictor; *internally* with the internal carotid, the internal jugular vein, the Superior constrictor, Palato-pharyngeus, and mucous membrane.

NERVES.—The Constrictors are supplied by branches from the pharyngeal plexus; the Stylo-pharyngeus, by the glosso-pharyngeal nerve; and the Inferior constrictor, by an additional branch from the external laryngeal nerve and by the recurrent laryngeal.

ACTIONS.—When deglutition is about to be performed the pharynx is drawn upward and dilated in different directions to receive the morsel propelled into it from the mouth. The Stylo-pharyngei, which are much farther removed from one another at their origin than at their insertion, draw the sides of the pharynx upward and outward, its breadth in the antero-posterior direction being increased by the larynx and tongue being carried forward in their ascent. As soon as the morsel is received in the pharynx the Elevator muscles relax, the bag descends, and the Constrictors contract upon the morsel and convey it gradually downward into the œsophagus. Besides its action in deglutition the pharynx also exerts an important influence in the modulation of the voice, especially in the production of the higher tones.

6. PALATAL REGION.

Levator palati. Azygos uvulæ.
Tensor palati. Palato-glossus.
Palato-pharyngeus.

Dissection (Fig. 296).—Lay open the pharynx from behind by a vertical incision extending from its upper to its lower part, and partially divide the occipital attachment by a transverse incision on each side of the vertical one; the posterior surface of the soft palate is then exposed. Having fixed the uvula so as to make it tense, the mucous membrane and glands should be carefully removed from the posterior surface of the soft palate, and the muscles of this part are at once exposed.

The **Levator palati** is a long, thick, rounded muscle placed on the outer side of the posterior nares. It arises from the under surface of the apex of the petrous portion of the temporal bone and from the adjoining cartilaginous portion of the Eustachian tube; after passing into the pharynx, above the upper concave margin of the Superior constrictor, it descends obliquely downward and inward, its fibres spreading out on the posterior surface of the soft palate as far as the middle line, where they blend with those of the opposite side.

RELATIONS.—*Externally* with the Tensor palati and Superior constrictor; *internally* with the mucous membrane of the pharynx; *posteriorly* with the mucous lining of the soft palate. This muscle must be removed and the pterygoid attachment of the Superior constrictor dissected away in order to expose the next muscle.

The **Circumflexus, or Tensor palati,** is a broad, thin, ribbon-like muscle placed on the outer side of the preceding, and consisting of a vertical and a horizontal portion. The vertical portion arises by a broad, thin, and flat lamella from the scaphoid fossa at the base of the internal pterygoid plate; from the spine of the sphenoid, the vaginal process of the temporal bone, and the anterior aspect of the cartilaginous portion of the Eustachian tube: descending vertically between the internal pterygoid plate and the inner surface of the Internal pterygoid muscle, it terminates in a tendon which winds round the hamular process, being retained in this situation by some of the fibres of origin of the Internal pterygoid muscle, and lubricated by a bursa. The tendon or horizontal portion then passes horizontally inward, and expands into a broad aponeurosis on the anterior surface of the soft palate, which unites in the median line with the aponeurosis of the opposite muscle, the fibres being attached in front to the transverse ridge on the horizontal portion of the palate bone.

Relations.—*Externally* with the Internal pterygoid; *internally* with the Levator palati, from which it is separated by the Superior constrictor, and with the internal pterygoid plate. In the soft palate its aponeurotic expansion is anterior to that of the Levator palati, being covered by mucous membrane.

Fig. 296.

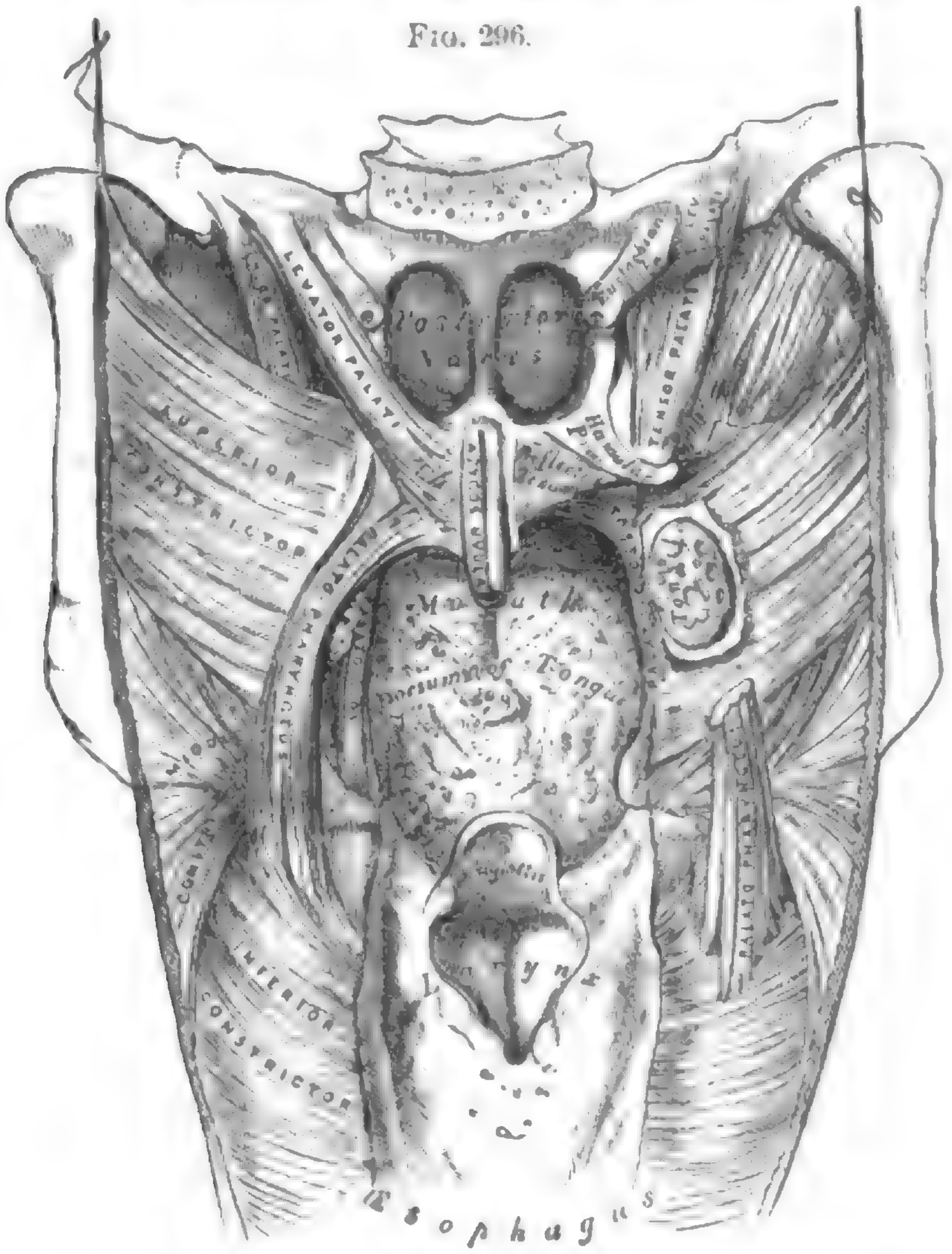
Levator palati
Posterior Nares
Eustachian
Tensor palati
Superior constrictor
Hamular Process
Azygos uvulæ
Palato-pharyngeus
Tonsil
Mouth
Dorsum of Tongue
Epiglottis
Larynx
Inferior constrictor
Palato-pharyngeus
Œsophagus

Muscles of the Soft Palate, the pharynx being laid open from behind.

The **Azygos** [or **Levator**] **uvulæ** is not a single muscle, as would be inferred from its name, but a pair of narrow, cylindrical fleshy fasciculi placed side by side in the median line of the soft palate. Each muscle arises from the posterior nasal spine of the palate bone and from the contiguous tendinous aponeurosis of the soft palate, and descends to be inserted into the uvula.

Relations.—*Anteriorly* with the tendinous expansion of the Levatores palati; *behind* with the mucous membrane.

[Actions.—The actions of these muscles, which in general are well indicated by their names, have been most ingeniously studied by a new method by Dr. Harrison Allen (*Trans. Coll. Phys. Phila.*, 1884). He uses the "Palate myograph," a rod passing through the nose, the inner end resting on the palate and the outer against a revolving drum. The student is referred to this paper for the results.]

The two next muscles are exposed by removing the mucous membrane from the pillars of the soft palate throughout nearly their whole extent.

The **Palato-glossus (Constrictor isthmi faucium)** is a small fleshy fasciculus, narrower in the middle than at either extremity, forming, with the mucous membrane covering its surface, the anterior pillar of the soft palate. It arises from the anterior surface of the soft palate on each side of the uvula, and, passing downward, forward, and outward in front of the tonsil, is inserted into the side and dorsum of the tongue, where it blends with the fibres of the Stylo-glossus muscle. In the soft palate the fibres of this muscle are continuous with those of the muscle of the opposite side.

The **Palato-pharyngeus** is a long, fleshy fasciculus, narrower in the middle than at either extremity, forming, with the mucous membrane covering its surface, the posterior pillar of the soft palate. It is separated from the preceding by an angular interval, in which the tonsil is lodged. It arises from the soft palate by an expanded fasciculus, which is divided into two parts by the Levator palati and Azygos uvulæ. The *anterior fasciculus*, the thicker, lies in the soft palate between the Levator and Tensor, and joins in the middle line the corresponding part of the opposite muscle; the *posterior fasciculus* lies in contact with the mucous membrane, and also joins with the corresponding muscle in the middle line. Passing outward and downward behind the tonsil, the Palato-pharyngeus joins the Stylo-pharyngeus, and is inserted with that muscle into the posterior border of the thyroid cartilage, some of its fibres being lost on the side of the pharynx, and others passing across the middle line posteriorly to decussate with the muscle of the opposite side. Connected with the Palato-pharyngeus there is sometimes found a slip arising above from the Eustachian tube and called the Salpingo-pharyngeus.

RELATIONS.—In the soft palate its *posterior surface* is covered by mucous membrane, from which it is separated by a layer of palatine glands. By its *superior border* it is in relation with the Levator palati. Where it forms the posterior pillar of the fauces it is covered by mucous membrane, excepting on its outer surface. In the *pharynx* it lies between the mucous membrane and the Constrictor muscles.

In a dissection of the soft palate from its posterior or nasal surface to its anterior or oral surface the muscles would be exposed in the following order—viz. the posterior fasciculus of the Palato-pharyngeus, covered over by the mucous membrane reflected from the floor of the nasal fossæ; the Azygos uvulæ; the Levator palati; the anterior fasciculus of the Palato-pharyngeus; the aponeurosis of the Tensor palati; and the Palato-glossus, covered over by a reflection from the oral mucous membrane.

NERVES.—The Tensor palati is supplied by a branch from the otic ganglion; the Levator palati, Azygos uvulæ, and other muscles, by the descending palatine branches from Meckel's ganglion. These nerves are derived primarily from the facial.

ACTIONS.—During the *first stage* of deglutition the morsel of food is driven back into the fauces by the pressure of the tongue against the hard palate, the base of the tongue being at the same time retracted and the larynx raised with the pharynx and carried forward under it. During the *second* stage the epiglottis is pressed over the superior aperture of the larynx, and the morsel glides past it; then the Palato-glossi muscles, the constrictors of the fauces, contract behind the food; the soft palate is slightly raised by the Levator palati and made tense by the Tensor palati; and the Palato-pharyngei contract and come nearly together, the uvula filling up the slight interval between them. By these means the food is prevented passing into the upper part of the pharynx or the posterior nares: at the same time the latter muscles form an inclined plane, directed obliquely downward and backward, along the under surface of which the morsel descends into the lower part of the pharynx.

Surgical Anatomy.—The muscles of the soft palate should be carefully dissected, the relations they bear to the surrounding parts especially examined, and their action attentively studied upon the dead subject, as the surgeon is required to divide one or more of these muscles in the operation of staphylorraphy. Sir W. Fergusson was the first to show that in the congenital deficiency called *cleft palate* the edges of the fissure are forcibly separated by the action of the Levatores palati and Palato-pharyngei muscles, producing very considerable impediment to the healing process after the performance of the operation for uniting their margins by adhesion; he consequently recommended the division of these muscles as one of the most important steps in the operation. This he effected by an incision made with a curved knife introduced behind the soft palate. The incision is to be halfway between the hamular process and Eustachian tube, and perpendicular to a line drawn between them. This incision perfectly accomplishes the division of the Levator palati. The Palato-pharyngeus may be divided by cutting across the posterior pillar of the soft palate, just below the tonsil, with a pair of blunt-pointed curved scissors; and the anterior pillar may be divided also. To divide the Levator palati the plan recommended by Mr. Pollock is to be greatly preferred. The soft palate being put upon the stretch, a double-edged knife is passed through it just on the inner side of the hamular process and above the line of the Levator palati. The handle being now alternately raised and depressed, a sweeping cut is made along the posterior surface of the soft palate, and the knife withdrawn, leaving only a small opening in the mucous membrane on the anterior surface. If this operation is performed on the dead body and the parts afterward dissected, the Levator palati will be found completely divided.

7. ANTERIOR VERTEBRAL REGION.

Rectus capitis anticus major.	Rectus lateralis.
Rectus capitis anticus minor.	Longus colli.

The **Rectus capitis anticus major** (Fig. 297), broad and thick above, narrow below, appears like a continuation upward of the Scalenus anticus. It arises by four tendinous slips from the anterior tubercles of the transverse processes of the third, fourth, fifth, and sixth cervical vertebræ, and ascends, converging toward its fellow of the opposite side, to be inserted into the basilar process of the occipital bone.

RELATIONS.—By its *anterior surface* with the pharynx, the sympathetic nerve, and the sheath enclosing the carotid artery, internal jugular vein, and pneumogastric nerve; by its *posterior surface*, with the Longus colli, the Rectus anticus minor, and the upper cervical vertebræ.

The **Rectus capitis anticus minor** is a short flat muscle situated immediately behind the upper part of the preceding. It arises from the anterior surface of the lateral mass of the atlas and from the root of its transverse process, and, passing obliquely upward and inward, is inserted into the basilar process immediately behind the preceding muscle.

FIG. 297.

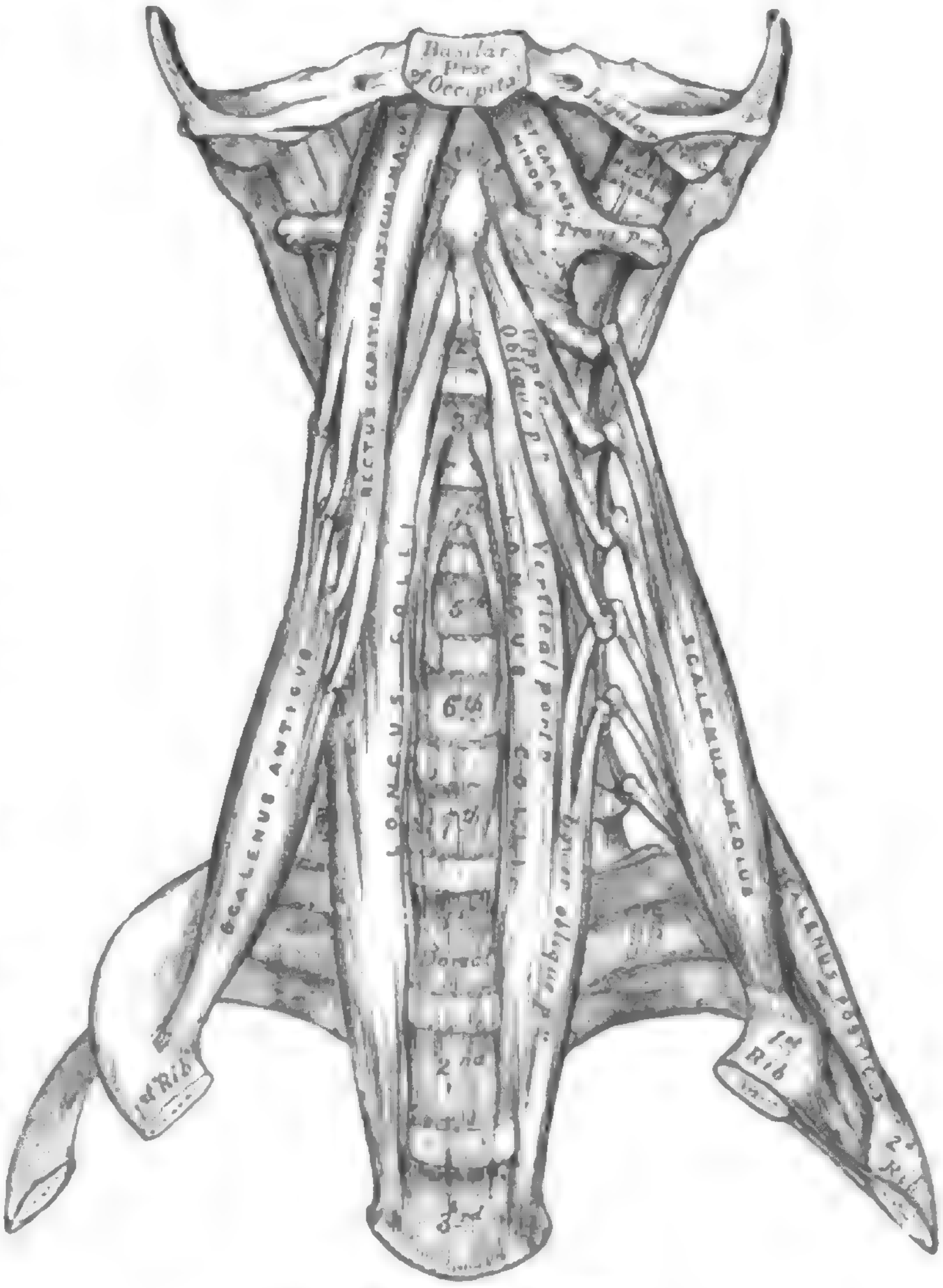

The Prevertebral Muscles.

RELATIONS.—By its *anterior surface* with the Rectus capitis anticus major; by its *posterior surface* with the front of the occipito-atloid articulation; *externally* with the superior cervical ganglion of the sympathetic.

The **Rectus lateralis** is a short flat muscle which arises from the upper surface of the transverse process of the atlas, and is inserted into the under surface of the jugular process of the occipital bone.

RELATIONS.—By its *anterior surface* with the internal jugular vein; by its *posterior surface* with the vertebral artery; on its *outer side* lies the occipital artery, on its *inner side* the suboccipital nerve.

The **Longus colli** is a long flat muscle situated on the anterior surface of the spine, between the atlas and the third dorsal vertebra. It is broad in the middle, narrow and pointed at each extremity, and consists of three portions—a superior oblique, an inferior oblique, and a vertical portion. The *superior oblique portion* arises from the anterior tubercles of the transverse processes of the third, fourth, and fifth cervical vertebræ, and, ascending obliquely inward, is inserted by a narrow tendon into the tubercle on the anterior arch of the atlas. The *inferior oblique portion*, the smallest part of the muscle, arises from the front of the bodies of the first two or three dorsal vertebræ, and, ascending obliquely outward, is inserted into the anterior tubercles of the transverse processes of the fifth and sixth cervical vertebræ. The *vertical portion* lies directly on the front of the spine, and is extended between the front of the bodies of the lower three cervical and the upper three dorsal vertebræ below and the front of the bodies of the second, third, and fourth cervical vertebræ above.

RELATIONS.—By its *anterior surface* with the pharynx, the œsophagus, sympathetic nerve, the sheath of the great vessels of the neck, the inferior thyroid artery, and recurrent laryngeal nerve; by its *posterior surface* with the cervical and dorsal portions of the spine. Its *inner border* is separated from the opposite muscle by a considerable interval below, but they approach each other above.

8. LATERAL VERTEBRAL REGION.

Scalenus anticus. Scalenus medius.
Scalenus posticus.

The **Scalenus anticus** is a conical-shaped muscle situated deeply at the side of the neck, behind the Sterno-mastoid. It arises by a narrow, flat tendon from the tubercle on the inner border and upper surface of the first rib, and, ascending almost vertically, is inserted into the anterior tubercles of the transverse processes of the third, fourth, fifth, and sixth cervical vertebræ. The lower part of this muscle separates the subclavian artery and vein, the latter being in front, and the former, with the brachial plexus, behind.

RELATIONS.—*In front* with the clavicle, the Subclavius, Sterno-mastoid, and Omo-hyoid muscles, the transversalis colli, and ascending cervical arteries, the subclavian vein, and the phrenic nerve; by its *posterior surface* with the pleura, the subclavian artery, and brachial plexus of nerves. It is separated from the Longus colli on the inner side by the vertebral artery.

The **Scalenus medius**, the largest and longest of the three Scaleni, arises by a broad origin from the upper surface of the first rib, behind the groove for the subclavian artery, as far back as the tubercle, and, ascending along the side of the vertebral column, is inserted by separate tendinous slips into the posterior tubercles of the transverse processes of the lower six cervical vertebræ. It is separated from the Scalenus anticus by the subclavian artery below and the cervical nerves above. The posterior thoracic, or nerve of Bell, is formed in the substance of the Scalenus medius and emerges from it.

RELATIONS.—By its *anterior surface* with the Sterno-mastoid; it is crossed by the clavicle, the Omo-hyoid muscle, subclavian artery, and the cervical nerves. To its *outer side* is the Levator anguli scapulæ and the Scalenus posticus muscle.

The **Scalenus posticus**, the smallest of the three Scaleni, arises by a thin tendon from the outer surface of the second rib, behind the attachment of the Serratus magnus, and, enlarging as it ascends, is inserted by two or three separate tendons into the posterior tubercles of the transverse processes of the lower two or three cervical vertebræ. This is the most deeply placed of the three Scaleni, and is occasionally blended with the Scalenus medius.

Nerves.—The Rectus capitis anticus major and minor and the Rectus lateralis are supplied by the suboccipital and deep internal branches of the cervical plexus; the Longus colli and Scaleni by anterior branches of the lower cervical nerves before they form the brachial plexus.

Actions.—The Rectus anticus major and minor are the direct antagonists of the muscles at the back of the neck, serving to restore the head to its natural position after it has been drawn backward. These muscles also serve to flex the head, and from their obliquity rotate it, so as to turn the face to one or the other side. The Longus colli flexes and slightly rotates the cervical portion of the spine. The Scaleni muscles, taking their fixed point from below, bend the spinal column to one or the other side. If the muscles of both sides act, lateral movement is prevented, but the spine is slightly flexed. When they take their fixed point from above they elevate the first and second ribs, and are therefore inspiratory muscles. The Rectus lateralis, acting on one side, bends the head laterally.

MUSCLES AND FASCIÆ OF THE TRUNK.

The Muscles of the Trunk may be arranged in four groups: the muscles of the Back, of the Abdomen, of the Thorax, and of the Perineum.[1]

Muscles of the Back.

The Muscles of the Back are very numerous, and may be subdivided into five layers:

First Layer.

Trapezius.
Latissimus dorsi.

Second Layer.

Levator anguli scapulæ.
Rhomboideus minor.
Rhomboideus major.

Third Layer.

Serratus posticus superior.
Serratus posticus inferior.
Splenius capitis.
Splenius colli.

Fourth Layer.

Sacral and Lumbar Regions.

Erector spinæ.

Dorsal Region.

Sacro-lumbalis.
Musculus accessorius ad sacro-lumbalem.
Longissimus dorsi.
Spinalis dorsi.

Cervical Region.

Cervicalis ascendens.
Transversalis colli.
Trachelo-mastoid.
Complexus.
Biventer cervicis.
Spinalis colli.

Fifth Layer.

Semispinalis dorsi.
Semispinalis colli.
Multifidus spinæ.
Rotatores spinæ.
Supraspinales.
Interspinales.
Extensor coccygis.
Intertransversales.
Rectus capitis posticus major.
Rectus capitis posticus minor.
Obliquus capitis superior.
Obliquus capitis inferior.

First Layer.

Trapezius. Latissimus dorsi.

Dissection (Fig. 298).—Place the body in the prone position, with the arms extended over the sides of the table, and the chest and abdomen supported by several blocks, so as to render the muscles tense. Then make an incision along the middle line of the back from the occipital protuberance to the coccyx. Make a transverse incision from the upper end of this to the mastoid process, and a third incision from its lower end, along the crest of the ilium, to about its middle. This large intervening space should, for convenience of dissection, be subdivided by a fourth incision, extending obliquely from the spinous process of the last dorsal vertebra upward and outward to the acromion process. This incision corresponds with the lower border of the Trapezius muscle. The flaps of integument are then to be removed in the direction shown in the figure.

---

[1] The muscles of the perineum are described with the Surgical Anatomy of this region at the end of the volume.

The *superficial fascia* is exposed upon removing the skin from the back. It forms a layer of considerable thickness and strength, in which a quantity of granular pinkish fat is contained. It is continuous with the superficial fascia in other parts of the body. The *deep fascia* is a dense fibrous layer attached to the occipital bone, the spines of the vertebræ, the crest of the ilium, and the spine of the scapula. It covers over the superficial muscles, forming sheaths for them, and is continuous in the neck at the anterior border of the Trapezius with the deep cervical fascia; in the thorax, with the deep fascia of the axilla and chest; and in the abdomen, with that covering the abdominal muscles.

The Trapezius (Fig. 300) is a broad, flat, triangular muscle placed immediately beneath the skin and fascia, and covering the upper and back part of the neck and shoulders. It arises from the inner third of the superior curved line of the occipital bone, from the ligamentum nuchæ, the spinous process of the seventh cervical, and those of all the dorsal vertebræ, and from the corresponding portion of the supraspinous ligament. From this origin the superior fibres proceed downward and outward, the inferior ones upward and outward, and the middle fibres horizontally, and are inserted, the superior ones into the outer third of the posterior border of the clavicle, the middle fibres into the inner margin of the acromion process and into the superior lip of the crest of the spine of the scapula. The inferior fibres converge near the scapula, and are attached to a triangular aponeurosis which glides over a smooth surface at the inner extremity of the spine, and is inserted into a tubercle at the outer part of the surface. The Trapezius is fleshy in the greater part of its extent, but tendinous at its origin and insertion. At its occipital origin it is connected to the bone by a thin fibrous lamina firmly adherent to the skin and wanting the lustrous, shining appearance of aponeurosis. At its origin from the spines of the vertebræ it is connected to the bones by means of a broad semielliptical aponeurosis which occupies the space between the sixth cervical and the third dorsal vertebræ, and forms, with the aponeurosis of the opposite muscle, a tendinous ellipse. The rest of the muscle arises by numerous short tendinous fibres. If the Trapezius is dissected on both sides, the two muscles resemble a trapezium or diamond-shaped quadrangle—two angles corresponding to the shoulders, a third to the occipital protuberance, and the fourth to the spinous process of the last dorsal vertebra.

FIG. 298.

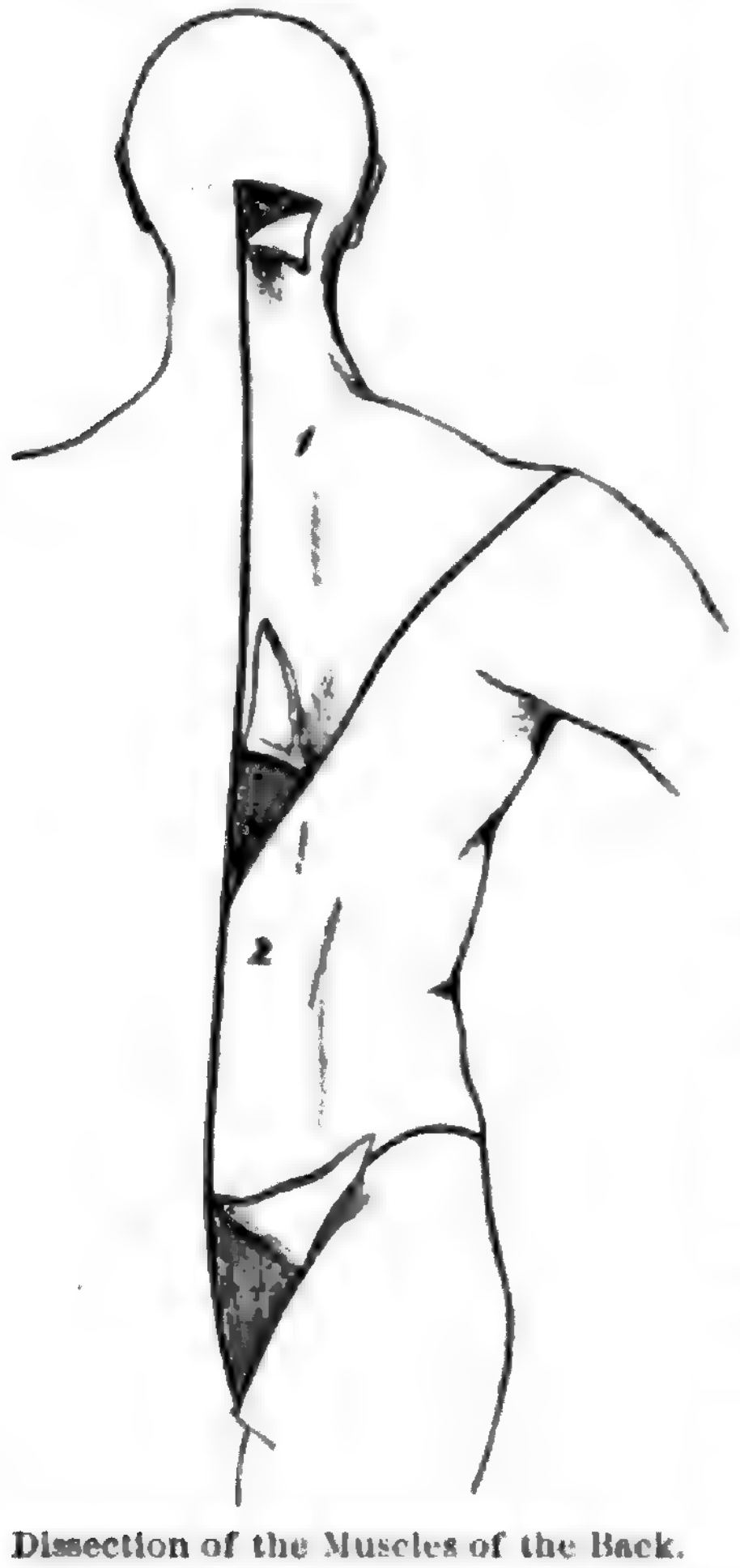

Dissection of the Muscles of the Back.

The clavicular insertion of this muscle varies as to the extent of its attachment: it sometimes advances as far as the middle of the clavicle, and may even become blended with the posterior edge of the Sterno-mastoid or overlap it. This should be borne in mind in the operation for tying the third part of the subclavian artery.

RELATIONS.—By its *superficial surface* with the integument; by its *deep surface* in the neck with the Complexus, Splenius, Levator anguli scapulæ, and

Rhomboideus minor; in the back with the Rhomboideus major, Supraspinatus, Infraspinatus, the lumbar fascia (which separates it from the Erector spinæ), and the Latissimus dorsi. The spinal accessory nerve and the superficial cervical artery pass beneath the anterior border of this muscle near the clavicle. The anterior margin of its cervical portion forms the posterior boundary of the posterior triangle of the neck, the other boundaries being the Sterno-mastoid in front and the clavicle below.

The **Ligamentum nuchæ** (Figs. 299, 300) is a thin band of condensed cellulo-fibrous membrane placed in the line of union between the two Trapezii in the neck. It extends from the external occipital protuberance to the spinous process of the seventh cervical vertebra, where it is continuous with the supraspinous ligament. From its anterior surface a fibrous slip is given off to the spinous process of each of the cervical vertebræ, excepting the atlas, so as to form a septum between the muscles on each side of the neck. In man it is merely the rudiment of an important elastic ligament which in some of the lower animals serves to sustain the weight of the head.[1]

The **Latissimus dorsi** is a broad flat muscle which covers the lumbar and the lower half of the dorsal regions, and is gradually contracted into a narrow fasciculus at its insertion into the humerus. It arises by an aponeurosis from the spinous processes of the six inferior dorsal, from those of the lumbar and sacral vertebræ, and from the supraspinous ligament. Over the sacrum the aponeurosis of this muscle blends with the tendon of the Erector spinæ. It also arises from the external lip of the crest of the ilium behind the origin of the External oblique, and by fleshy digitations from the three or four lower ribs, which are interposed between similar processes of the External oblique muscle (Fig. 303, p. 413). From this extensive origin the fibres pass in different directions, the upper ones horizontally, the middle obliquely upward, and the lower vertically upward, so as to converge and form a thick fasciculus which crosses the inferior angle of the scapula and occasionally receives a few fibres from it. The muscle then curves around the lower border of the Teres major, and is twisted upon itself, so that the superior fibres become at first posterior and then inferior, and the vertical fibres at first anterior and then superior. It then terminates in a short quadrilateral tendon about three inches in length, which, passing in front of the tendon of the Teres major, is inserted into the inner lip and into the bottom of the bicipital groove of the humerus, its insertion extending higher on the humerus than that of the tendon of the Pectoralis major. The lower border of the tendon of this muscle is united with that of the Teres major, the surfaces of the two being separated by a bursa; another bursa is sometimes interposed between the muscle and the inferior angle of the scapula.

[Fig. 299.

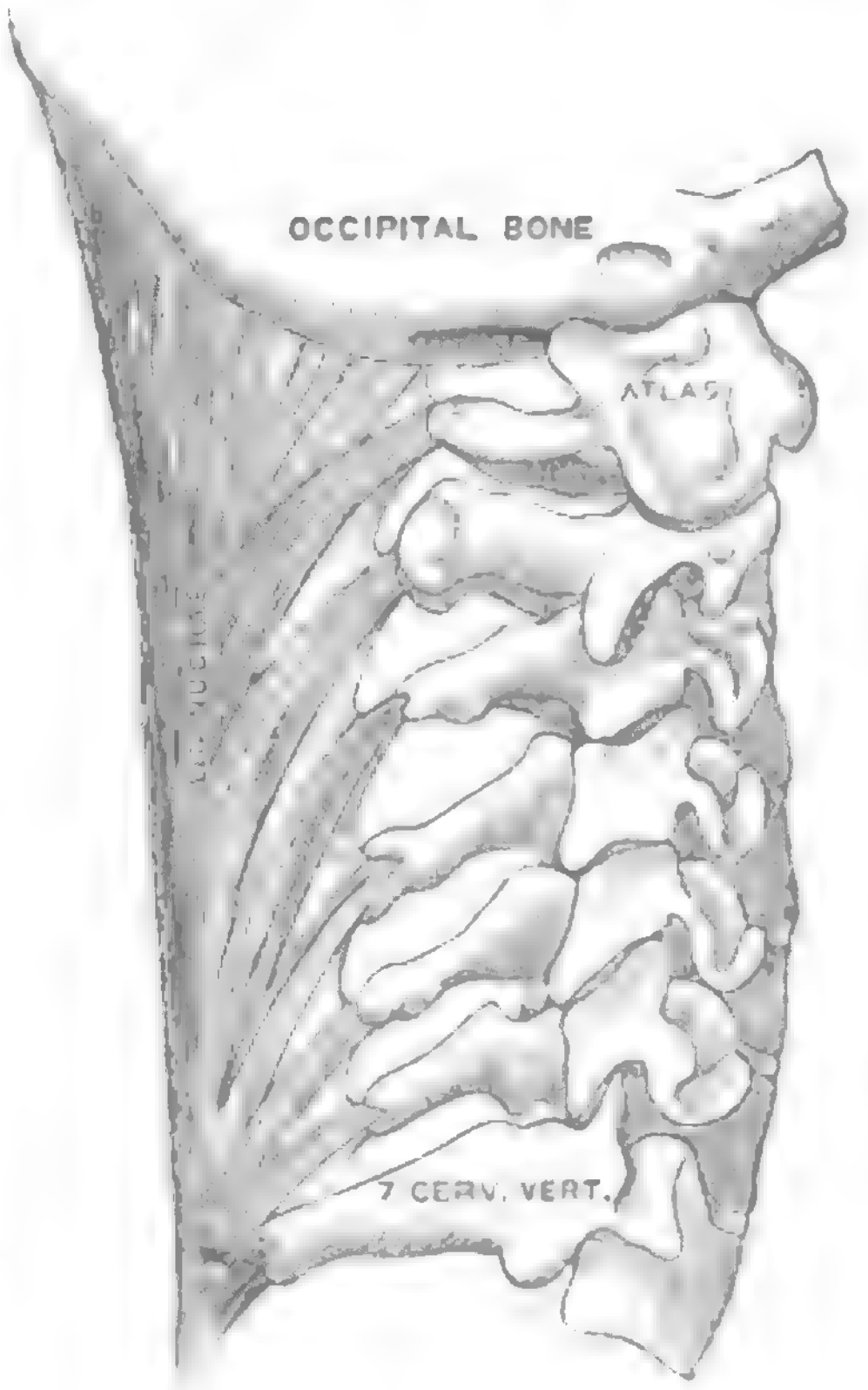

The Ligamentum Nuchæ (Henle).]

A muscular slip, varying from three to four inches in length and from one-quarter to three-quarters of an inch in breadth, occasionally arises from the upper edge of the Latissimus dorsi about the middle of the posterior fold of the axilla, and crosses the axilla in front of the axillary vessels and nerves to join the under surface of the tendon of the Pectoralis major, the Coraco-brachialis, or the fascia over the Biceps. The position of this abnormal slip is a point

---

[[1] Shepherd of Montreal has recorded one case in which the upper part of this ligament was replaced by strong *muscular* fibres (*Brooklyn Annals of Anatomy and Surgery*, 1881, iv. 111).]

Fig. 300.

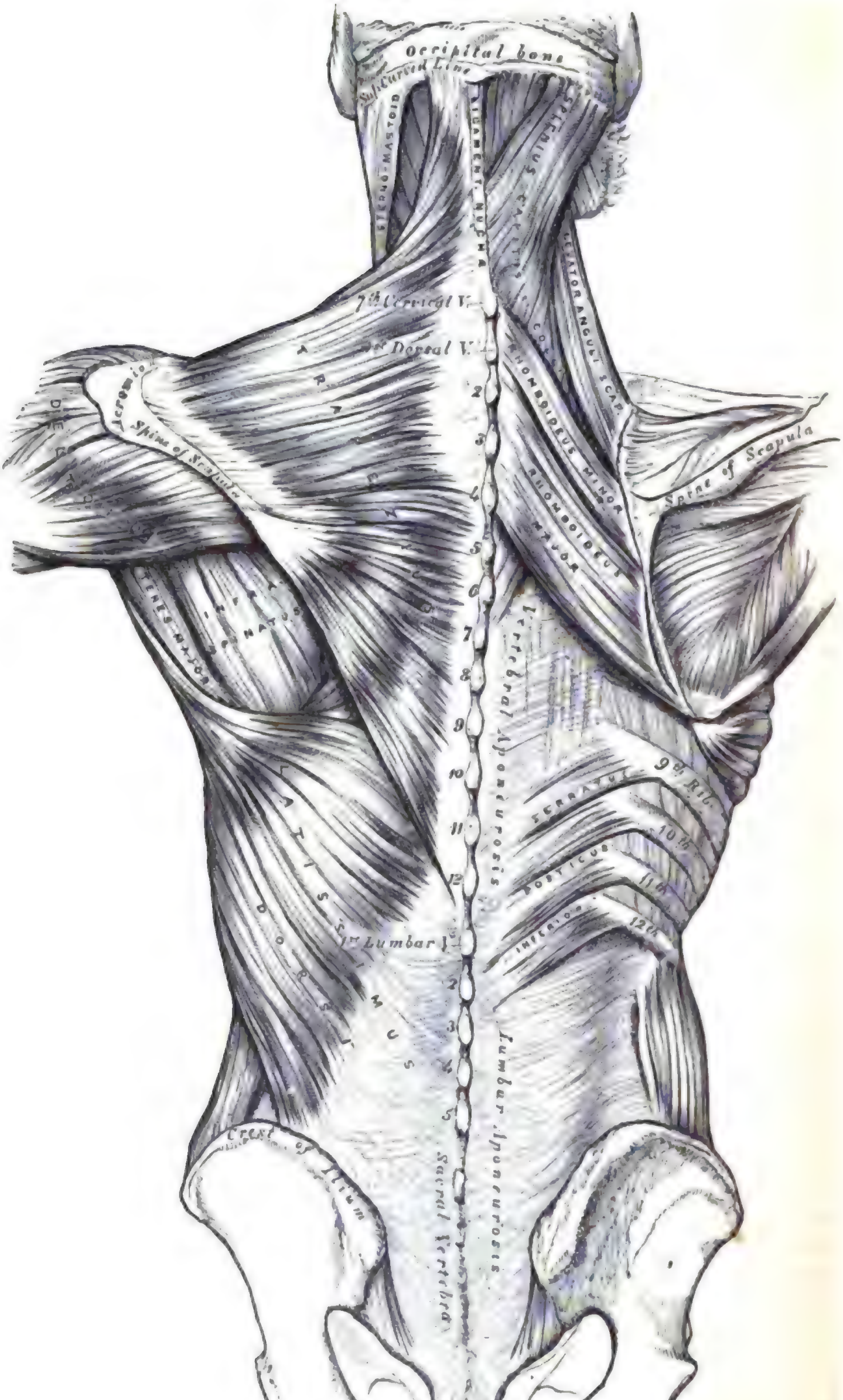
Occipital bone
Sup. Curved Line
STERNO-MASTOID
LIGAMENT. NUCHA
SPLENIUS CAPITIS
LEVATOR ANGULI SCAP.
COLLI
7th Cervical V.
1st Dorsal V.
TRAPEZIUS
Acromion
Spine of Scapula
DELTOID
RHOMBOIDEUS MINOR
RHOMBOIDEUS MAJOR
Spine of Scapula
INFRA SPINATUS
TERES MAJOR
2
3
4
5
6
7
8
9
10
11
12
Vertebral Aponeurosis
SERRATUS
POSTICUS
INFERIOR
9th Rib
10th
11th
12th
LATISSIMUS DORSI
1st Lumbar
2
3
4
5
Lumbar Aponeurosis
Crest of Ilium
Sacral Vertebra

Muscles of the Back. On the left side is exposed the first layer; on the right side, the second layer and part of the third.

of interest in its relation to the axillary artery, as it crosses the vessel just above the spot usually selected for the application of a ligature, and may mislead the surgeon during the operation. It may be easily recognized by the transverse direction of its fibres. Dr. Struthers found it in 8 out of 105 subjects, occurring seven times on both sides.

Relations.—Its *superficial surface* is subcutaneous, excepting at its upper part, where it is covered by the Trapezius, and at its insertion, where its tendon is crossed by the axillary vessels and the brachial plexus of nerves. By its *deep surface* it is in relation with the Erector spinæ, the Serratus posticus inferior, the lower external intercostal muscles and ribs, inferior angle of the scapula, Rhomboideus major, Infraspinatus, and Teres major. Its outer margin is separated below from the External oblique by a small triangular interval; and another triangular interval exists between its upper border and the margin of the Trapezius, in which the Rhomboideus major muscle is exposed.

Nerves.—The Trapezius is supplied by the spinal accessory and by branches from the anterior divisions of the third and fourth cervical nerves; the Latissimus dorsi, by the long subscapular nerve.

Second Layer.

Levator anguli scapulæ. Rhomboideus minor.
Rhomboideus major.

Dissection.—The Trapezius must be removed in order to expose the next layer; to effect this, detach the muscle from its attachment to the clavicle and spine of the scapula and turn it back toward the spine.

The **Levator anguli scapulæ** is situated at the back part and side of the neck. It arises by three, four, or five tendinous slips from the posterior tubercles of the transverse processes of the three, four, or five upper cervical vertebræ; these, becoming fleshy, are united so as to form a flat muscle, which, passing downward and backward, is inserted into the posterior border of the scapula, between the superior angle and the triangular smooth surface at the root of the spine.

Relations.—By its *superficial* (*anterior*) *surface* with the integument, Trapezius, and Sterno-mastoid; by its *deep* (*posterior*) *surface* with the Splenius colli, Transversalis colli, Cervicalis ascendens, and Serratus posticus superior, and with the transversalis colli and posterior scapular arteries.

The **Rhomboideus minor** arises from the ligamentum nuchæ and spinous processes of the seventh cervical and first dorsal vertebræ. Passing downward and outward, it is inserted into the margin of the triangular smooth surface at the root of the spine of the scapula. This small muscle is usually separated from the Rhomboideus major by a slight cellular interval.

The **Rhomboideus major** is situated immediately below the preceding, the adjacent margins of the two being occasionally united. It arises by tendinous fibres from the spinous processes of the four or five upper dorsal vertebræ and the supraspinous ligament, and is inserted into a narrow tendinous arch attached above to the triangular surface near the spine; below, to the inferior angle, the arch being connected to the border of the scapula by a thin membrane. When the arch extends, as it occasionally does, but a short distance, the muscular fibres are inserted into the scapula itself.

Relations.—By their *superficial* (*posterior*) *surface* with the integument and Trapezius, the Rhomboideus major with the Latissimus dorsi; by their *deep* (*anterior*) *surface* with the Serratus posticus superior, posterior scapular artery, prolongations from the Erector spinæ, the intercostal muscles, and ribs.

Nerves.—The Rhomboid muscles are supplied by branches from the fifth cervical nerve; the Levator anguli scapulæ, by the interior division of the third and fourth cervical nerves.

Actions.—The movements effected by the preceding muscles are numerous, as may be conceived from their extensive attachment. If the head is fixed, the upper part of the *Trapezius* will elevate the point of the shoulder, as in supporting weights;

when the middle and lower fibres are brought into action, partial rotation of the scapula upon the side of the chest is produced. If the shoulders are fixed, both Trapezii, acting together, will draw the head directly backward, or if only one acts, the head is drawn to the corresponding side. [This muscle can be well shown on the living model by shrugging the shoulders, especially if the hands are weighted by dumb-bells, by clasping the hands behind the head, and so resisting extension of the head, and by drawing the two shoulders backward and crossing the arms behind the back.]

The *Latissimus dorsi*, when it acts upon the humerus, draws it backward and downward, and at the same time rotates it inward. It is the muscle which is principally employed in giving a downward blow, as in felling a tree or in sabre practice. If the arm is fixed, the muscle may act in various ways upon the trunk: thus, it may raise the lower ribs and assist in forcible inspiration, or if both arms are fixed the two muscles may assist the abdominal and great Pectoral muscles in suspending and drawing the whole trunk forward, as in climbing or walking on crutches. [Let the model hang by one arm from a ring or place his arm on your shoulder or other similar support and press downward, and the Latissimus will show finely.]

The *Levator anguli scapulæ* raises the superior angle of the scapula, assisting the Trapezius in bearing weights or in shrugging the shoulders, whilst the *Rhomboid* muscles carry the inferior angle backward and upward, thus producing a slight rotation of the scapula upon the side of the chest, the Rhomboideus major acting especially on the lower angle of the scapula through the tendinous arch by which it is inserted. If the shoulder be fixed, the Levator anguli scapulæ inclines the neck to the corresponding side and rotates it backward. The Rhomboid muscles, acting together with the middle and inferior fibres of the Trapezius, will draw the scapula directly backward toward the spine. [Clasping the hands behind the occiput and resisting the postero-lateral movement of the head, and shrugging the weighted shoulders as above, show the Levator anguli scapulæ well. The Rhomboids are best seen when the model crosses the arms behind the back and then shrugs the shoulders.]

THIRD LAYER.

Serratus posticus superior. Serratus posticus inferior.
Splenius { Splenius capitis.
Splenius colli.

Dissection.—To bring into view the third layer of muscles, remove the whole of the second, together with the Latissimus dorsi; by cutting through the Levator anguli scapulæ and Rhomboid muscles near their insertion, and reflecting them upward, to expose the Serratus posticus inferior, dividing the Latissimus dorsi in the middle by a vertical incision carried from its upper to its lower part, and reflecting the two halves of the muscle.

The **Serratus posticus superior** is a thin, flat, quadrilateral muscle situated at the upper and back part of the thorax. It arises by a thin and broad aponeurosis from the ligamentum nuchæ, and from the spinous processes of the last cervical and two or three upper dorsal vertebræ. Inclining downward and outward, it becomes muscular, and is inserted by four fleshy digitations into the upper borders of the second, third, fourth, and fifth ribs a little beyond their angles.

RELATIONS.—By its *superficial surface* with the Trapezius, Rhomboidei, and Levator anguli scapulæ; by its *deep surface* with the Splenius, prolongations from the Erector spinæ, Intercostal muscles, and ribs.

The **Serratus posticus inferior** is situated at the junction of the dorsal and lumbar regions: it is of an irregularly quadrilateral form, broader than the preceding, and separated from it by a considerable interval. It arises by a thin aponeurosis from the spinous processes of the last two dorsal and two or three upper lumbar vertebræ, and from the interspinous ligaments. Passing obliquely upward and outward, it becomes fleshy and divides into four flat digitations, which are inserted into the lower borders of the four lower ribs a little beyond their angles.

RELATIONS.—By its *superficial surface* with the Latissimus dorsi, with the aponeurosis of which its own aponeurotic origin is inseparably blended; by its *deep surface* with the lumbar fascia, the Erector spinæ, ribs, and Intercostal muscles. Its upper margin is continuous with the vertebral aponeurosis.

The *Vertebral Fascia* or *Aponeurosis* is a thin, fibrous lamina extending along the whole length of the back part of the thoracic region, serving to bind down the long extensor muscles of the back which support the spine and head, and separate them from those muscles which connect the spine to the upper extremity. It consists of longitudinal and transverse fibres blended together, forming a thin lamella, which is attached in the median line to the spinous processes of the dorsal vertebræ, externally to the angles of the ribs, and below to the upper border of the Inferior serratus and tendon of origin of the Latissimus dorsi; above, it passes beneath the Serratus posticus superior and the Splenius and blends with the deep fascia of the neck.

Now detach the Serratus posticus superior from its origin and turn it outward, when the Splenius muscle will be brought into view.

The **Splenius** is situated at the back of the neck and upper part of the dorsal region. At its origin it is a single muscle, narrow and pointed in form, but it soon becomes broader and divides into two portions, which have separate insertions. It arises by tendinous fibres from the lower half of the ligamentum nuchæ, from the spinous processes of the last cervical and of the six upper dorsal vertebræ, and from the supraspinous ligament. From this origin the fleshy fibres proceed obliquely upward and outward, forming a broad flat muscle which divides as it ascends into two portions, the Splenius capitis and Splenius colli.

The **Splenius capitis** is inserted into the mastoid process of the temporal bone, and into the rough surface on the occipital bone just beneath the superior curved line.

The **Splenius colli** is inserted by tendinous fasciculi into the posterior tubercles of the transverse processes of the three or four upper cervical vertebræ.

The Splenius is separated from its fellow of the opposite side by a triangular interval, in which is seen the Complexus.

RELATIONS.—By its *superficial surface* with the Trapezius, from which it is separated below by the Rhomboidei and the Serratus posticus superior: it is covered at its insertion by the Sterno-mastoid; by its *deep surface* with the Spinalis dorsi, Longissimus dorsi, Semispinalis colli, Complexus, Trachelo-mastoid, and Transversalis colli.

NERVES.—The Splenius and Superior serratus are supplied from the external branches of the posterior divisions of the cervical nerves; the Inferior serratus, from the external branches of the posterior divisions of the lower dorsal nerves.

ACTIONS.—The Serrati are respiratory muscles. The Serratus posticus superior elevates the ribs: it is therefore an inspiratory muscle; while the Serratus inferior draws the lower ribs downward and backward, and thus elongates the thorax. It also fixes the lower ribs, thus aiding the downward action of the diaphragm and resisting the tendency which it has to draw the lower ribs upward and forward. It must therefore be regarded as a muscle of inspiration, though by some anatomists it has been considered an expiratory muscle. This muscle is also probably a tensor of the vertebral aponeurosis. The Splenii muscles of the two sides, acting together, draw the head directly backward, assisting the Trapezius and Complexus; acting separately, they draw the head to one or the other side and slightly rotate it, turning the face to the same side. They also assist in supporting the head in the erect position.

FOURTH LAYER.

Sacral and Lumbar Regions.

Erector spinæ.

Dorsal Region.

Sacro-lumbalis.
Musculus accessorius ad sacro-lumbalem.
Longissimus dorsi.
Spinalis dorsi.

Cervical Region.

Cervicalis ascendens.
Transversalis colli.
Trachelo-mastoid.
Complexus.
Biventer cervicis.
Spinalis colli.

Dissection.—To expose the muscles of the fourth layer remove entirely the Serrati and the vertebral and lumbar fasciæ. Then detach the Splenius by separating its attachment to the spinous processes and reflecting it outward.

The **Erector spinæ** (Fig. 301) and its prolongations in the dorsal and cervical regions fill up the vertebral groove on each side of the spine. It is covered in the lumbar region by the lumbar fascia, in the dorsal region by the Serrati muscles and the vertebral fascia, and in the cervical region by a layer of cervical fascia continued beneath the Trapezius. This large muscular and tendinous mass varies in size and structure at different parts of the spine. In the sacral region the Erector spinæ is narrow and pointed, and its origin chiefly tendinous in structure. In the lumbar region the muscle becomes enlarged, and forms a large fleshy mass. In the dorsal region it subdivides into two parts, which gradually diminish in size as they ascend to be inserted into the vertebræ and ribs, and are gradually lost in the cervical region, where a number of special muscles are superadded: these are continued upward to the head, and support it upon the spine.

The Erector spinæ arises from the sacro-iliac groove, and from the anterior surface of a very broad and thick tendon, which is attached internally to the spines of the sacrum, to the spinous processes of the lumbar and two or three lower dorsal vertebræ, and to the supraspinous ligament; externally to the back part of the inner lip of the crest of the ilium, and to the series of eminences on the posterior part of the sacrum which represent the transverse processes, where it blends with the great sacro-sciatic ligament. The muscular fibres form a single large fleshy mass, bounded in front by the transverse processes of the lumbar vertebræ, and by the middle lamella of the aponeurosis of origin of the Transversalis muscle. Opposite the last rib it divides into two parts, the Sacro-lumbalis and the Longissimus dorsi.

The **Sacro-lumbalis** (Ilio-costalis), the external and smaller portion of the Erector spinæ, is inserted by six or seven flattened tendons into the angles of the six or seven lower ribs. If this muscle is reflected outward, it will be seen to be reinforced by a series of muscular slips which arise from the angles of the ribs: by means of these the Sacro-lumbalis is continued upward to the upper ribs and the cervical portion of the spine. The accessory portions form two additional muscles, the Musculus accessorius and the Cervicalis ascendens.

The **Musculus accessorius ad sacro-lumbalem** arises by separate flattened tendons from the angles of the six lower ribs; these become muscular, and are finally inserted by separate tendons into the angles of the six upper ribs.

The **Cervicalis ascendens**[1] is the continuation of the Accessorius upward into the neck; it is situated on the inner side of the tendons of the Accessorius, arising from the angles of the four or five upper ribs, and is inserted by a series of slender tendons into the posterior tubercles of the transverse processes of the fourth, fifth, and sixth cervical vertebræ.

The **Longissimus dorsi**, the inner and larger portion of the Erector spinæ, arises, with the Sacro-lumbalis, from the common origin above described. In the lumbar region, where it is as yet blended with the Sacro-lumbalis, some of the fibres are attached to the whole length of the posterior surface of the transverse processes of the lumbar vertebræ, to the tubercles at the back of the articular processes, and to the middle layer of the aponeurosis of origin of the Transversalis abdominis muscle. In the dorsal region the Longissimus dorsi is inserted by long thin tendons into the tips of the transverse processes of all the dorsal vertebræ, and into from seven to eleven of the lower ribs between their tubercles and angles. This muscle is continued upward to the cranium and cervical portion of the spine by means of two additional muscles, the Transversalis colli and Trachelo-mastoid.

The **Transversalis colli** (or **cervicis**), placed on the inner side of the Longis-

---

[1] This muscle is sometimes called "Cervicalis descendens." The student should remember that these long muscles take their fixed point from above or from below, according to circumstances.

FIG. 301.

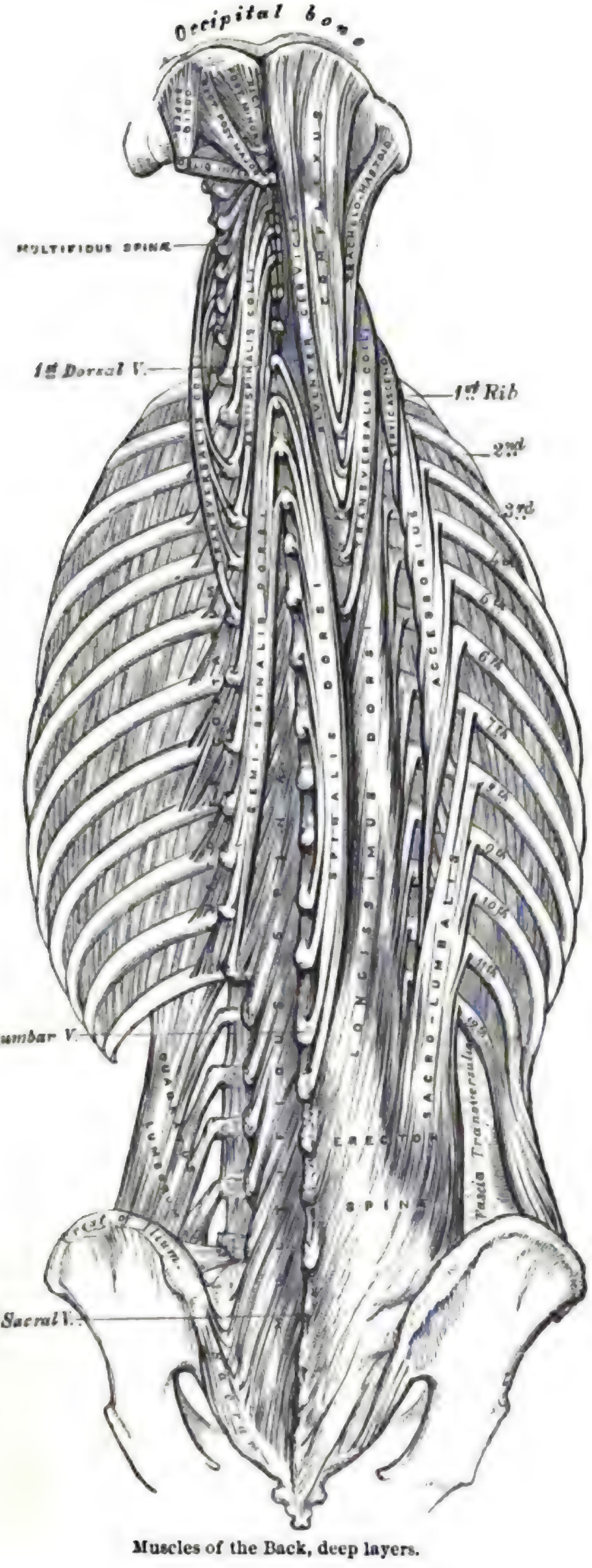
Occipital bone
Obliq. sup.
Rect. post. major
Complexus
Obliq. inf.
Trachelo-mastoid
Multifidus spinæ
1st Dorsal V.
1st Rib
2nd
3rd
4th
5th
6th
7th
8th
9th
10th
11th
12th
Spinalis colli
Transversalis colli
Cervicalis ascend.
Semi-spinalis dorsi
Spinalis dorsi
Longissimus dorsi
Accessorius
Sacro-lumbalis
Erector spinæ
Multifidus spinæ
Fascia Transversalis
1st Lumbar V.
Quadratus
Crest of Ilium.
4th Sacral V.

Muscles of the Back, deep layers.

simus dorsi, arises by long thin tendons from the summits of the transverse processes of the six upper dorsal vertebræ, and is inserted by similar tendons into the posterior tubercles of the transverse processes of the cervical from the second to the sixth.

The **Trachelo-mastoid** lies on the inner side of the preceding, between it and the Complexus muscle. It arises by four tendons from the transverse processes of the third, fourth, fifth, and sixth dorsal vertebræ, and by additional separate tendons from the articular processes of the three or four lower cervical. The fibres form a small muscle which ascends to be inserted into the posterior margin of the mastoid process, beneath the Splenius and Sterno-mastoid muscles. This small muscle is almost always crossed by a tendinous intersection near its insertion into the mastoid process.

The **Spinalis dorsi** connects the spinous processes of the upper lumbar and the dorsal vertebræ together by a series of muscular and tendinous slips which are intimately blended with the Longissimus dorsi. It is situated at the inner side of the Longissimus dorsi, arising by three or four tendons from the spinous processes of the first two lumbar and the last two dorsal vertebræ: these, uniting, form a small muscle which is inserted by separate tendons into the spinous processes of the dorsal vertebræ, the number varying from four to eight. It is intimately united with the Semispinalis dorsi, which lies beneath it.

The **Spinalis colli** is a small muscle connecting together the spinous processes of the cervical vertebræ, and analogous to the Spinalis dorsi in the dorsal region. It varies considerably in its size and in its extent of attachment to the vertebræ, not only in different bodies, but on the two sides of the same body. It usually arises by fleshy or tendinous slips, varying from two to four in number, from the spinous processes of the fifth, sixth, and seventh cervical vertebræ, and occasionally from the first and second dorsal, and is inserted into the spinous process of the axis, and occasionally into the spinous processes of the two vertebræ below it. This muscle was found absent in five cases out of twenty-four.

The **Complexus** is a broad, thick muscle situated at the upper and back part of the neck, beneath the Splenius and internal to the Transversalis colli and Trachelo-mastoid. It arises by a series of tendons, about seven in number, from the tips of the transverse processes of the upper three dorsal and seventh cervical, and from the articular processes of the three cervical above this. The tendons uniting form a broad muscle which passes obliquely upward and inward, and is inserted into the innermost depression between the two curved lines of the occipital bone. This muscle about its middle is traversed by a transverse tendinous intersection.

The **Biventer cervicis** is a small fasciculus situated on the inner side of the preceding, and in the majority of cases blended with it; it has received its name from having a tendon intervening between two fleshy bellies. It is sometimes described as a separate muscle, arising by from two to four tendinous slips from the transverse processes of as many of the upper dorsal vertebræ, and inserted on the inner side of the Complexus into the superior curved line of the occipital bone.

RELATIONS.—The muscles of the fourth layer are bound down to the vertebræ and ribs in the dorsal and lumbar regions by the lumbar and vertebral fasciæ. The inner part covers the muscles of the fifth layer. In the neck they are in relation by their *superficial surface* with the Trapezius and Splenius—by their *deep surface* with the Semispinalis dorsi and colli and the Recti and Obliqui. The Biventer cervicis is separated from its fellow of the opposite side by the ligamentum nuchæ, and the Complexus from the Semispinalis colli by the profunda cervicis artery, the princeps cervicis artery, and branches of the posterior cervical plexus of nerves.

NERVES.—The Erector spinæ and its subdivisions in the dorsal region are supplied by the external branches of the posterior divisions of the lumbar and dorsal nerves; the Cervicalis ascendens, Transversalis colli, Trachelo-mastoid, and Spinalis colli, by the external branches of the posterior divisions of the cervical nerves; the Complexus, by the internal branches of the posterior divisions of the cervical nerves, the suboccipital, and great occipital.

FIFTH LAYER.

Semispinalis dorsi.
Semispinalis colli.
Multifidus spinæ.
Rotatores spinæ.
Supraspinales.
Interspinales.
Extensor coccygis.
Intertransversales.
Rectus capitis posticus major.
Rectus capitis posticus minor.
Obliquus capitis superior.
Obliquus capitis inferior.

Dissection.—Remove the muscles of the preceding layer by dividing and turning aside the Complexus, then detaching the Spinalis and Longissimus dorsi from their attachments, dividing the Erector spinæ at its connection below to the sacral and lumbar spines and turning it outward. The muscles filling up the interval between the spinous and transverse processes are then exposed.

The **Semispinales muscles** (Fig. 301) connect the transverse and articular processes to the spinous processes of the vertebræ, extending from the lower part of the dorsal region to the upper part of the cervical.

The **Semispinalis dorsi** consists of thin, narrow, fleshy fasciculi interposed between tendons of considerable length. It arises by a series of small tendons from the transverse processes of the lower dorsal vertebræ, from the tenth or eleventh to the fifth or sixth, and is inserted by five or six tendons into the spinous processes of the upper four dorsal and lower two cervical vertebræ.

The **Semispinalis colli**, thicker than the preceding, arises by a series of tendinous and fleshy points from the transverse processes of the upper four dorsal vertebræ and from the articular processes of the lower four cervical vertebræ, and is inserted into the spinous processes of four cervical vertebræ from the axis to the fifth cervical. The fasciculus connected with the axis is the largest, and chiefly muscular in structure.

RELATIONS.—By their *superficial surface* from below upward with the Longissimus dorsi, Spinalis dorsi, Splenius, Complexus, the profunda cervicis artery, the princeps cervicis artery, and the internal branches of the posterior divisions of the first, second, and third cervical nerves; by their *deep surface* with the Multifidus spinæ.

The **Multifidus spinæ** consists of a number of fleshy and tendinous fasciculi which fill up the groove on either side of the spinous processes of the vertebræ from the sacrum to the axis. In the sacral region these fasciculi arise from the back of the sacrum as low as the fourth sacral foramen, and from the aponeurosis of origin of the Erector spinæ; in the iliac region, from the inner surface of the posterior superior spine of the ilium and posterior sacro-iliac ligaments; in the lumbar and cervical regions, from the articular processes; and in the dorsal region, from the transverse processes. Each fasciculus, ascending obliquely upward and inward, is inserted into the lamina and whole length of the spinous process of one of the vertebræ above. These fasciculi vary in length: the most superficial, the longest, pass from one vertebra to the third or fourth above; those next in order pass from one vertebra to the second or third above; whilst the deepest connect two contiguous vertebræ.

RELATIONS.—By its *superficial surface* with the Longissimus dorsi, Spinalis dorsi, Semispinalis dorsi, and Semispinalis colli; by its *deep surface* with the laminæ and spinous processes of the vertebræ and with the Rotatores spinæ in the dorsal region.

The **Rotatores spinæ** are found only in the dorsal region of the spine, beneath the Multifidus spinæ; they are eleven in number on each side. Each muscle is small and somewhat quadrilateral in form; it arises from the upper and back part of the transverse process, and is inserted into the lower border and outer surface of the lamina of the vertebra above, the fibres extending as far inward as the root of the spinous process. The first is found between the first and second dorsal; the last, between the eleventh and twelfth. Sometimes the number of these muscles is diminished by the absence of one or more from the upper or lower end.

The **Supraspinales** consist of a series of fleshy bands which lie on the spinous processes in the cervical region of the spine.

The **Interspinales** are short muscular fasciculi placed in pairs between the spinous processes of the contiguous vertebræ. In the *cervical region* they are most distinct, and consist of six pairs, the first being situated between the axis and third vertebra, and the last between the last cervical and the first dorsal. They are small narrow bundles, attached above and below to the apices of the spinous processes. In the *dorsal region* they are found between the first and second vertebræ, and occasionally between the second and third, and below between the eleventh and twelfth. In the *lumbar region* there are four pairs of these muscles in the intervals between the five lumbar vertebræ. There is also occasionally one in the interspinous space, between the last dorsal and first lumbar and between the fifth lumbar and the sacrum.

The **Extensor coccygis** is a slender muscular fasciculus occasionally present which extends over the lower part of the posterior surface of the sacrum and coccyx. It arises by tendinous fibres from the last bone of the sacrum or first piece of the coccyx, and passes downward to be inserted into the lower part of the coccyx. It is a rudiment of the Extensor muscle of the caudal vertebræ which exists in some animals.

The **Intertransversales** are small muscles placed between the transverse processes of the vertebræ. In the *cervical region* they are most developed, consisting of two rounded muscular and tendinous fasciculi which pass between the anterior and posterior tubercles of the transverse processes of two contiguous vertebræ, separated from one another by the anterior branch of a cervical nerve, which lies in the groove between them, and by the vertebral artery and vein. In this region there are seven pairs of these muscles, the first being between the atlas and axis, and the last between the seventh cervical and first dorsal vertebræ. In the *dorsal region* they are least developed, consisting chiefly of rounded tendinous cords in the intertransverse spaces of the upper dorsal vertebræ; but between the transverse processes of the lower three dorsal vertebræ and the first lumbar they are muscular in structure. In the *lumbar region* they are four in number, and consist of a single muscular layer which occupies the entire interspace between the transverse processes of the lower lumbar vertebræ, whilst those between the transverse processes of the upper lumbar are not attached to more than half the breadth of the process.

The **Rectus capitis posticus major** arises by a pointed tendinous origin from the spinous process of the axis, and, becoming broader as it ascends, is inserted into the inferior curved line of the occipital bone and the surface of bone immediately below it. As the muscles of the two sides ascend upward and outward, they leave between them a triangular space in which are seen the Recti capitis postici minores muscles.

RELATIONS.—By its *superficial surface* with the Complexus, and at its insertion with the Superior oblique; by its *deep surface* with the posterior arch of the atlas, the posterior occipito-atloid ligament, and part of the occipital bone.

The **Rectus capitis posticus minor,** the smallest of the four muscles in this region, is of a triangular shape: it arises by a narrow pointed tendon from the tubercle on the posterior arch of the atlas, and, becoming broader as it ascends, is inserted into the rough surface beneath the inferior curved line nearly as far as the foramen magnum, nearer to the middle line than the preceding.

RELATIONS.—By its *superficial surface* with the Complexus and Rectus capitis posticus major; by its *deep surface* with the posterior occipito-atloid ligament.

The **Obliquus capitis inferior,** the larger of the two Oblique muscles, arises from the apex of the spinous process of the axis, and passes almost horizontally outward to be inserted into the lower and back part of the transverse process of the atlas.

RELATIONS.—By its *superficial surface* with the Complexus, and with the posterior branch of the second cervical nerve which crosses it; by its *deep surface* with the vertebral artery and posterior atlo-axoid ligament.

The **Obliquus capitis superior**, narrow below, wide and expanded above, arises by tendinous fibres from the upper surface of the transverse process of the atlas, joining with the insertion of the preceding, and, passing obliquely upward and inward, is inserted into the occipital bone between the two curved lines external to the Complexus. Between the two oblique muscles and the Rectus posticus major a triangular interval exists in which are seen the vertebral artery and the posterior branch of the suboccipital nerve.

RELATIONS.—By its *superficial surface* with the Complexus and Trachelo-mastoid; by its *deep surface* with the posterior occipito-atloid ligament.

NERVES.—The Semispinalis dorsi and Rotatores spinæ are supplied by the internal branches of the posterior divisions of the dorsal nerves; the Semispinalis colli, Supraspinales, and Interspinales, by the internal branches of the posterior divisions of the cervical nerves; the Intertransversales, by the internal branches of the posterior divisions of the cervical, dorsal, and lumbar nerves; the Multifidus spinæ, by the same, with the addition of the internal branches of the posterior divisions of the sacral nerves. The Recti and Obliqui muscles are all supplied by the suboccipital nerve; the Inferior oblique is also supplied by the great occipital nerve.

ACTIONS.—The Erector spinæ, comprising the Sacro-lumbalis with its accessory muscles, the Longissimus dorsi, and Spinalis dorsi, serves, as its name implies, to maintain the spine in the erect posture; it also serves to bend the trunk backward when it is required to counterbalance the influence of any weight at the front of the body; as, for instance, when a heavy weight is suspended from the neck or when there is any great abdominal development, as in pregnancy or dropsy: the peculiar gait under such circumstances depends upon the spine being drawn backward by the counterbalancing action of the Erector spinæ muscles. [Let the model bend forward and slowly lift a heavy weight from the floor. Watch the Erector spinæ mass spring into marked rounded relief until he is entirely erect and balanced, when it quickly subsides.] The muscles which form the continuation of the Erector spinæ upward steady the head and neck and fix them in the upright position. If the Sacro-lumbalis and Longissimus dorsi of one side act, they serve to draw down the chest and spine to the corresponding side. The Cervicalis ascendens, taking its fixed point from the cervical vertebræ, elevates those ribs to which it is attached. The Multifidus spinæ acts successively upon the different parts of the spine; thus, the sacrum furnishes a fixed point from which the fasciculi of this muscle act upon the lumbar region; these then become the fixed points for the fasciculi moving the dorsal region, and so on throughout the entire length of the spine; it is by the successive contraction and relaxation of the separate fasciculi of this and other muscles that the spine preserves the erect posture without the fatigue that would necessarily have been produced had this position been maintained by the action of a single muscle. The Multifidus spinæ, besides preserving the erect position of the spine, serves to rotate it, so that the front of the trunk is turned to the side opposite to that from which the muscle acts, this muscle being assisted in its action by the Obliquus externus abdominis. The Complexi, the analogues of the Multifidus spinæ in the neck, draw the head directly backward; if one muscle acts, it draws the head to one side and rotates it so that the face is turned to the opposite side. The Rectus capitis posticus minor and the Superior oblique draw the head backward; and the latter, from the obliquity in the direction of its fibres, may turn the face to the opposite side. The Rectus capitis posticus major and the Obliquus inferior rotate the atlas, and with it the cranium, round the odontoid process, and turn the face to the same side.

MUSCLES OF THE ABDOMEN.

The muscles in this region are the

Obliquus externus.
Obliquus internus.
Transversalis.
Rectus.
Pyramidalis.
Quadratus lumborum.

Dissection (Fig. 302).—To dissect the abdominal muscles make a vertical incision from the ensiform cartilage to the pubes, a second incision from the umbilicus obliquely upward and outward to the outer surface of the chest, as high as the lower border of the fifth or sixth rib, and a third, commencing midway between the umbilicus and pubes, transversely outward to the anterior superior iliac spine and along the crest of the ilium as far as its posterior third. Then reflect the three flaps included between these incisions from within outward in the lines of direction of the muscular fibres. If necessary, the abdominal muscles may be made tense by inflating the peritoneal cavity through the umbilicus.

Fig. 302.

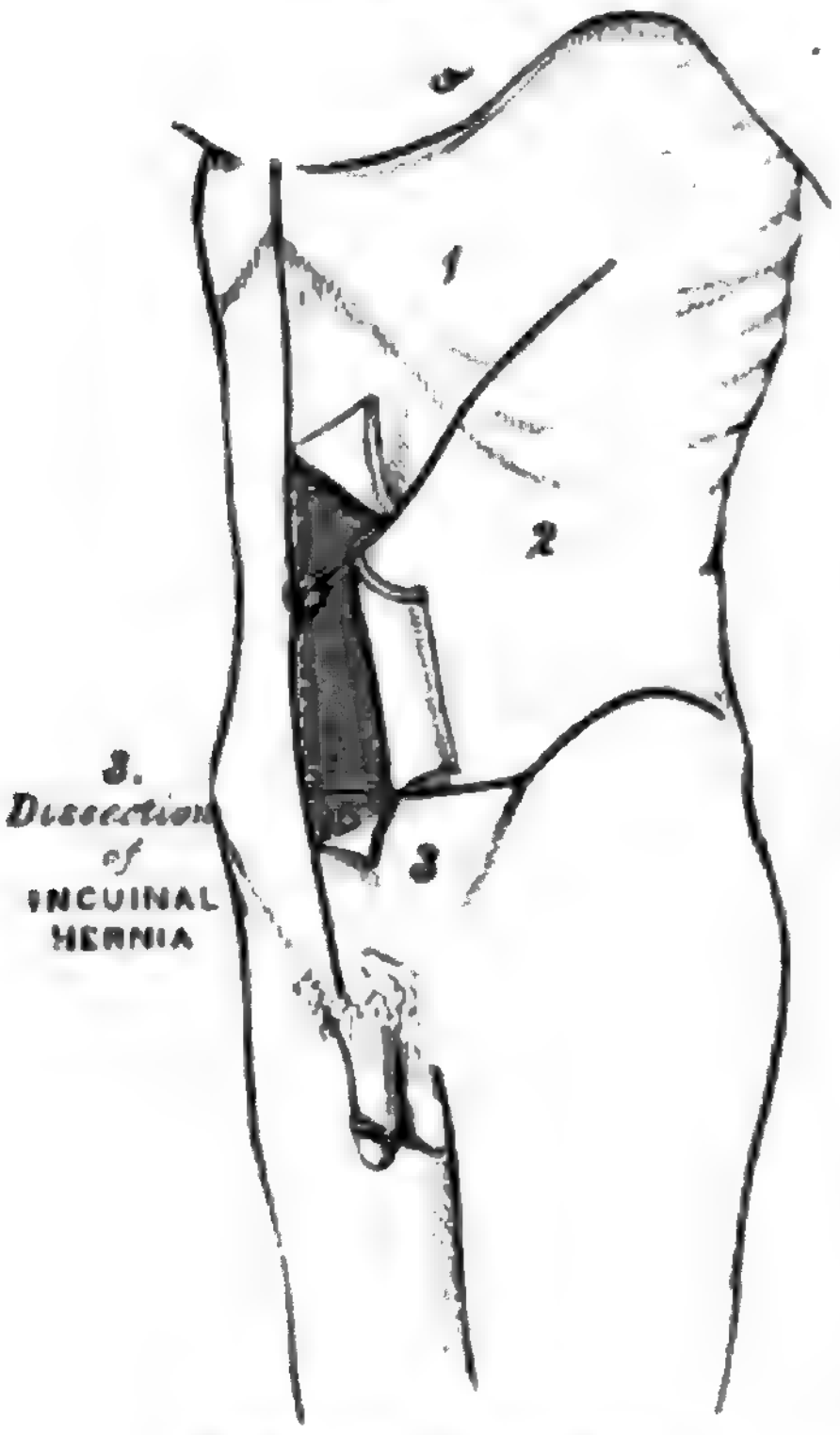

Dissection of Abdomen.

The **Superficial Fascia** of the abdomen consists over the greater part of the abdominal wall of a single layer of fascia, which contains a variable amount of fat; but as this layer approaches the groin it is easily divisible into two layers, of which the superficial one is fatty, and is continuous with the subcutaneous fat in the upper part of the abdomen and in the thigh: the deeper layer is thinner and more membranous in character, and is separated from the superficial one by the subcutaneous vessels. Above it is continuous with the superficial fascia over the rest of the trunk, but below it blends with the fascia lata of the thigh a little below Poupart's ligament, and below and internally it is continued to the penis and scrotum, where it becomes very thin and reaches the perineum. This fascia will be described more particularly in connection with the subject of the surgical anatomy of inguinal hernia, to which the student is referred.

The [**Obliquus externus abdominis**] **External** or **Descending Oblique Muscle** (Fig. 303) is situated on the side and fore part of the abdomen, being the largest and the most superficial of the three flat muscles in this region. It is broad, thin, and irregularly quadrilateral, its muscular portion occupying the side, its aponeurosis the anterior wall of the abdomen. It arises by eight fleshy digitations from the external surface and lower borders of the eight inferior ribs; these digitations are arranged in an oblique line running downward and backward, the upper ones being attached close to the cartilages of the corresponding ribs; the lowest to the apex of the cartilage of the last rib; the intermediate ones to the ribs at some distance from their cartilages. The five superior serrations increase in size from above downward, and are received between corresponding processes of the Serratus magnus: the three lower ones diminish in size from above downward, receiving between them corresponding processes from the Latissimus dorsi. From these attachments the fleshy fibres proceed in various directions. Those from the lowest ribs pass nearly vertically downward, to be inserted into the anterior half of the outer lip of the crest of the ilium; the middle and upper fibres, directed downward and forward, terminate in tendinous fibres, which spread out into a broad aponeurosis. This aponeurosis, joined with that of the opposite muscle along the median line, covers the whole of the front of the abdomen; above, it is connected with the lower border of the Pectoralis major; below, its fibres are closely aggregated together, and extend obliquely across from the anterior superior spine of the ilium to the spine of the os pubis and the linea ilio-pectinea. In the median line it interlaces with the aponeurosis of the opposite muscle, forming the linea alba, and extends from the ensiform cartilage to the symphysis pubis.

That portion of the aponeurosis which extends between the anterior superior spine of the ilium and the spine of the os pubis is a broad, stout band folded inward, and continuous below with the fascia lata; it is called **Poupart's ligament** [and is one of the most important landmarks of the abdomen and thigh]. The portion which is reflected from Poupart's ligament on to the pectineal line is called *Gimbernat's ligament.*[1] From the point of attachment of the latter to the pectineal line a few fibres pass upward and inward, behind the inner pillar of the ring, to the linea alba. They diverge as they ascend, and form a thin, triangular, fibrous band which is called the *triangular ligament.*

In the aponeurosis of the External oblique, immediately above the crest of the os pubis, is a triangular opening, the *external abdominal ring*, formed by a separation of the fibres of the aponeurosis in this situation: it serves for the transmission of the spermatic cord in the male and the round ligament in the female. This opening is directed obliquely upward and outward, and corresponds with the course of the fibres of the aponeurosis. It is bounded below by the crest of the os pubis; above by some curved fibres, which pass across the aponeurosis at the upper angle

FIG. 303.

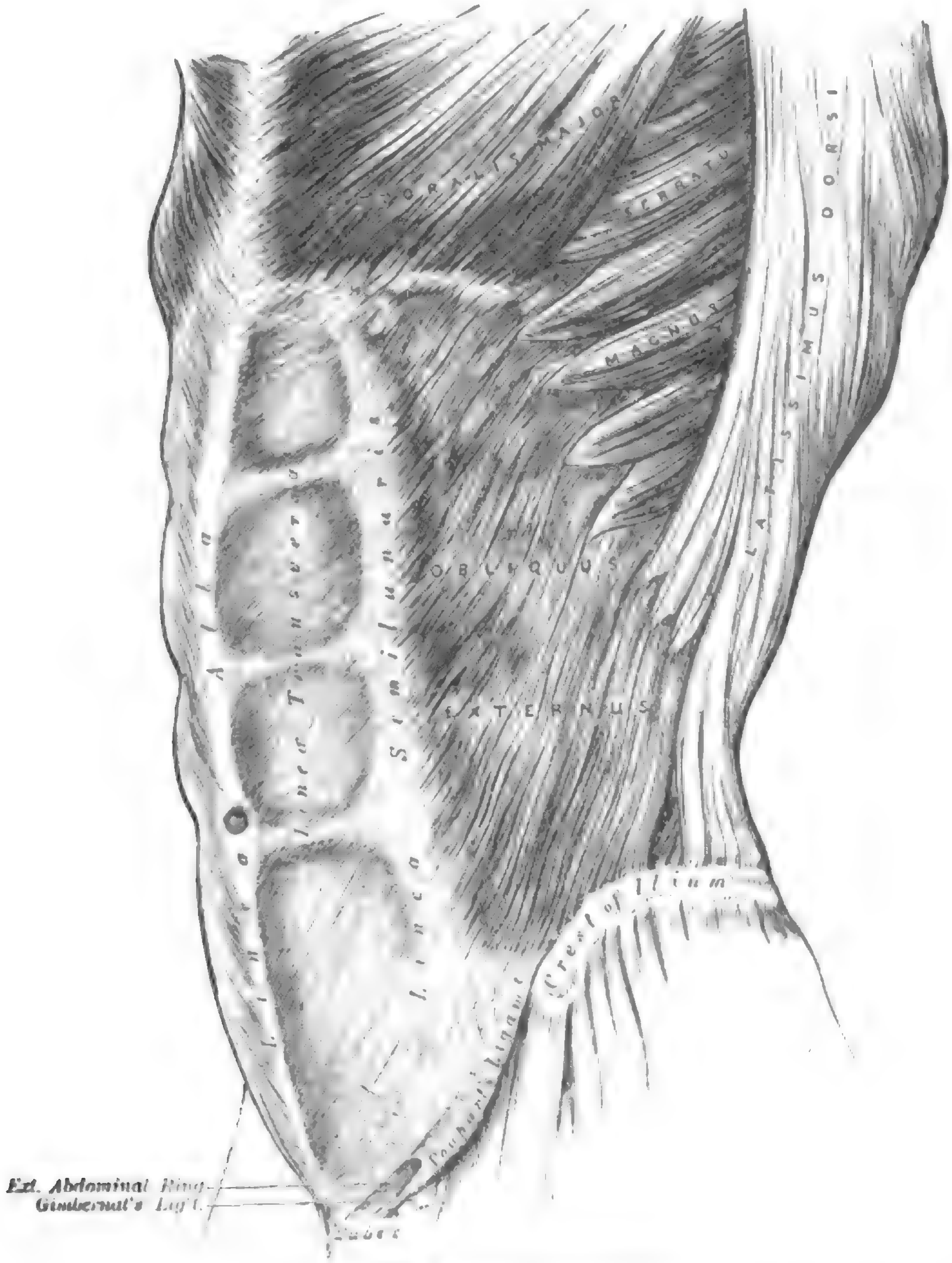
Pectoralis Major
Serratus Magnus
Latissimus Dorsi
Obliquus Externus
Linea Alba
Lineae Transversae
Linea Semilunaris
Crest of Ilium
Poupart's Ligament
Ext. Abdominal Ring
Gimbernat's Lig't.
Tuber

The External Oblique Muscle.

---

[1] All these parts will be found more particularly described hereafter, with the Surgical Anatomy of Hernia.

of the ring so as to increase its strength; and on either side by the margins of the aponeurosis, which are called the *pillars* [or *columns*] *of the ring*. Of these, the external—which is at the same time inferior, from the obliquity of its direction—is inserted into the spine of the os pubis. The internal or superior pillar is attached to the front of the pubes and symphysis pubis, and interlaces with the corresponding fibres of the opposite muscle, the fibres of the right muscle being superficial. To the margins of the pillars of the external abdominal ring is attached an exceedingly thin and delicate fascia, which is prolonged down over the outer surface of the cord and testis. This has received the name of *intercolumnar fascia*, from its attachment to the pillars of the ring. It is also called the *external spermatic fascia*, from being the most external of the fasciæ which cover the spermatic cord.

Relations.—By its *external surface* with the superficial fascia, superficial epigastric and circumflex iliac vessels, and some cutaneous nerves. By its *internal surface* with the Internal oblique, the lower part of the eight inferior ribs and Intercostal muscles, the cremaster, the spermatic cord in the male and the round ligament in the female. Its *posterior border* is occasionally overlapped by the Latissimus dorsi; generally an interval exists between the two muscles in which is seen a portion of the Internal oblique.

Dissection.—Detach the External oblique by dividing it across, just in front of its attachment to the ribs, as far as its posterior border, and separating it below from the crest of the ilium as far as the spine; then separate the muscle carefully from the Internal oblique, which lies beneath, and turn it toward the opposite side.

The **[Obliquus internus abdominis] Internal** or **Ascending Oblique Muscle** (Fig. 304), thinner and smaller than the preceding, beneath which it lies, is of an irregularly quadrilateral form and situated at the side and fore part of the abdomen. It arises by fleshy fibres from the outer half of Poupart's ligament, being attached to the groove on its upper surface, from the anterior two-thirds of the middle lip of the crest of the ilium, and from the posterior lamella of the lumbar fascia. From this origin the fibres diverge: those from Poupart's ligament, few in number and paler in color than the rest, arch downward and inward across the spermatic cord, to be inserted, conjointly with those of the Transversalis, into the crest of the os pubis and pectineal line to the extent of half an inch, forming what is known as the conjoined tendon of the Internal oblique and Transversalis; those from the anterior superior iliac spine are horizontal in their direction; whilst those which arise from the fore part of the crest of the ilium pass obliquely upward and inward, and terminate in an aponeurosis which is continued forward to the linea alba; the most posterior fibres pass almost vertically upward, to be inserted into the lower borders of the cartilages of the four lower ribs, being continuous with the Internal intercostal muscles.

The conjoined tendon of the Internal oblique and Transversalis is inserted into the crest of the os pubis and pectineal line, immediately behind the external abdominal ring, serving to protect what would otherwise be a weak point in the abdominal wall. Sometimes this tendon is insufficient to resist the pressure from within, and is carried forward in front of the protrusion through the external ring, forming one of the coverings of direct inguinal hernia.

The aponeurosis of the Internal oblique is continued forward to the middle line of the abdomen, where it joins with the aponeurosis of the opposite muscle at the linea alba and extends from the margin of the thorax to the pubes. At the outer margin of the Rectus muscle this aponeurosis, for the upper three-fourths of its extent, divides into two lamellæ, which pass, one in front and the other behind the muscle, enclosing it in a kind of sheath, and reuniting on its inner border at the linea alba; the anterior layer is blended with the aponeurosis of the External oblique muscle, the posterior layer with that of the Transversalis. Along the lower fourth the aponeurosis passes altogether in front of the Rectus without any separation.

Relations.—By its *external surface* with the External oblique, Latissimus dorsi, spermatic cord, and external ring; by its *internal surface* with the Transversalis mus-

Fig. 304.

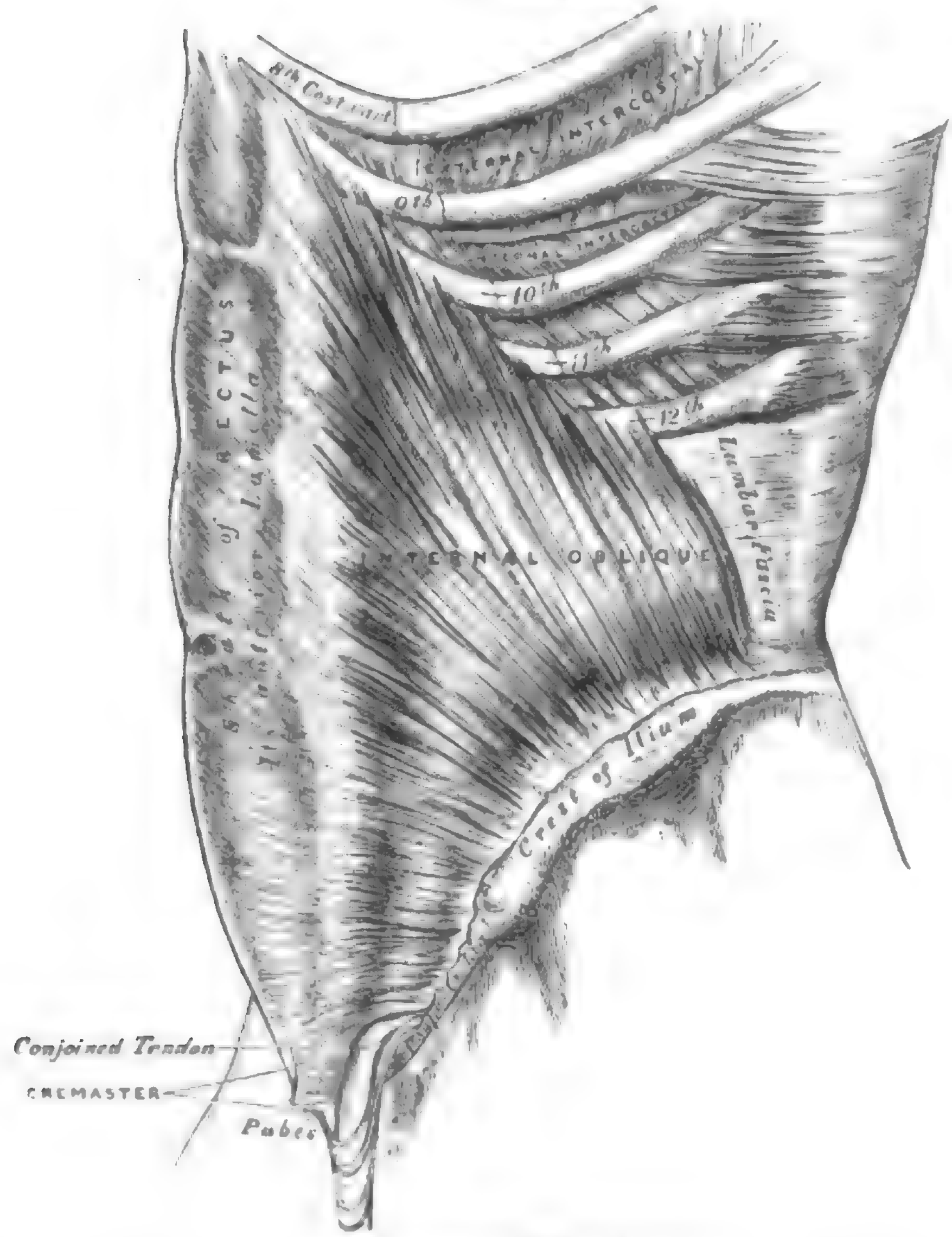

The Internal Oblique Muscle.

cle, fascia transversalis, internal ring, and spermatic cord. Its lower border forms the upper boundary of the spermatic canal.

Dissection.—Detach the Internal oblique in order to expose the Transversalis beneath. This may be effected by dividing the muscle above at its attachment to the ribs; below at its connection with Poupart's ligament and the crest of the ilium; and behind by a vertical incision extending from the last rib to the crest of the ilium. The muscle should previously be made tense by drawing upon it with the fingers of the left hand, and if its division is carefully effected the cellular interval between it and the Transversalis, as well as the direction of the fibres of the latter muscle, will afford a clear guide to their separation: along the crest of the ilium the circumflex iliac vessels are interposed between them, and form an important guide in separating them. The muscle should then be thrown forward toward the linea alba.

The **Transversalis Muscle** (Fig. 305), so called from the direction of its fibres, is the most internal flat muscle of the abdomen, being placed immediately beneath the Internal oblique. It arises by fleshy fibres from the outer third of Poupart's ligament, from the inner lip of the crest of the ilium, its anterior three-fourths, from the inner surface of the cartilages of the six lower ribs, interdigitating with the Diaphragm, and by a broad aponeurosis from the spinous and transverse processes of the lumbar vertebræ. The muscle terminates in front in a broad aponeurosis, the lower fibres of which curve downward, and are inserted, together with those of the internal oblique, into the crest of the os pubis and pectineal line, forming what was described above as the conjoined tendon of these muscles. Throughout the rest of its extent the aponeurosis passes horizontally inward, and is inserted into the linea alba; its upper three-fourths, passing behind the Rectus muscle, blending with the posterior lamella of the Internal oblique; its lower fourth passing in front of the Rectus.

Relations.—By its *external surface* with the Internal oblique, the inner surface of the lower ribs, and Internal intercostal muscles. Its *inner surface* is lined by the fascia transversalis, which separates it from the peritoneum. Its lower border forms the upper boundary of the spermatic canal.

Fig. 305.

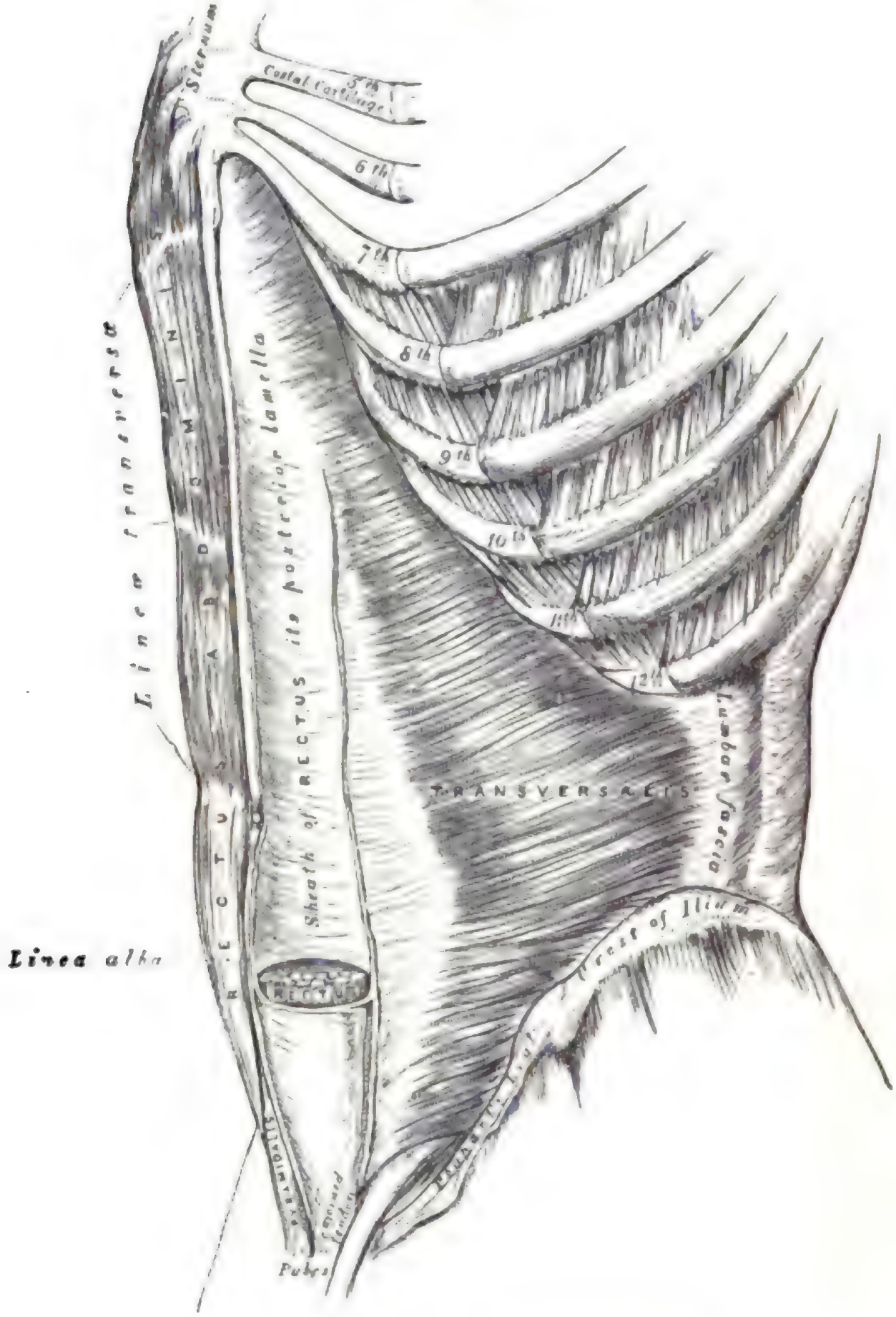
Sternum
Costal Cartilage
5th
6th
7th
8th
9th
10th
11th
12th
Linea transversa
R E C T U S A B D O M I N
Sheath of RECTUS its posterior lamella
TRANSVERSALIS
Lumbar fascia
Crest of Ilium
Linea alba
RECTUS
PYRAMIDALIS
Conjoined tendon
Pubes

The Transversalis, Rectus, and Pyramidalis Muscles.

Lumbar Fascia (Fig. 306).—The vertebral or posterior aponeurosis of the Transversalis, sometimes called the *lumbar fascia*, divides into three layers: an anterior, very thin, which is attached to the front part of the transverse processes of the lumbar vertebræ, and above to the lower margin of the last rib, where it forms the ligamentum arcuatum externum; a middle layer, much stronger, which is attached to the apices of the transverse processes; and a posterior layer, attached to the apices of the spinous processes. Between the anterior and middle layer is situated the Quadratus lumborum; between the middle and posterior, the Erector spinæ and Multifidus spinæ. The posterior lamella of this aponeurosis gives attachment to the Internal oblique; it is also blended with the aponeurosis of the Serratus posticus inferior and with that of the Latissimus dorsi, forming the lumbar fascia.

Fig. 306.

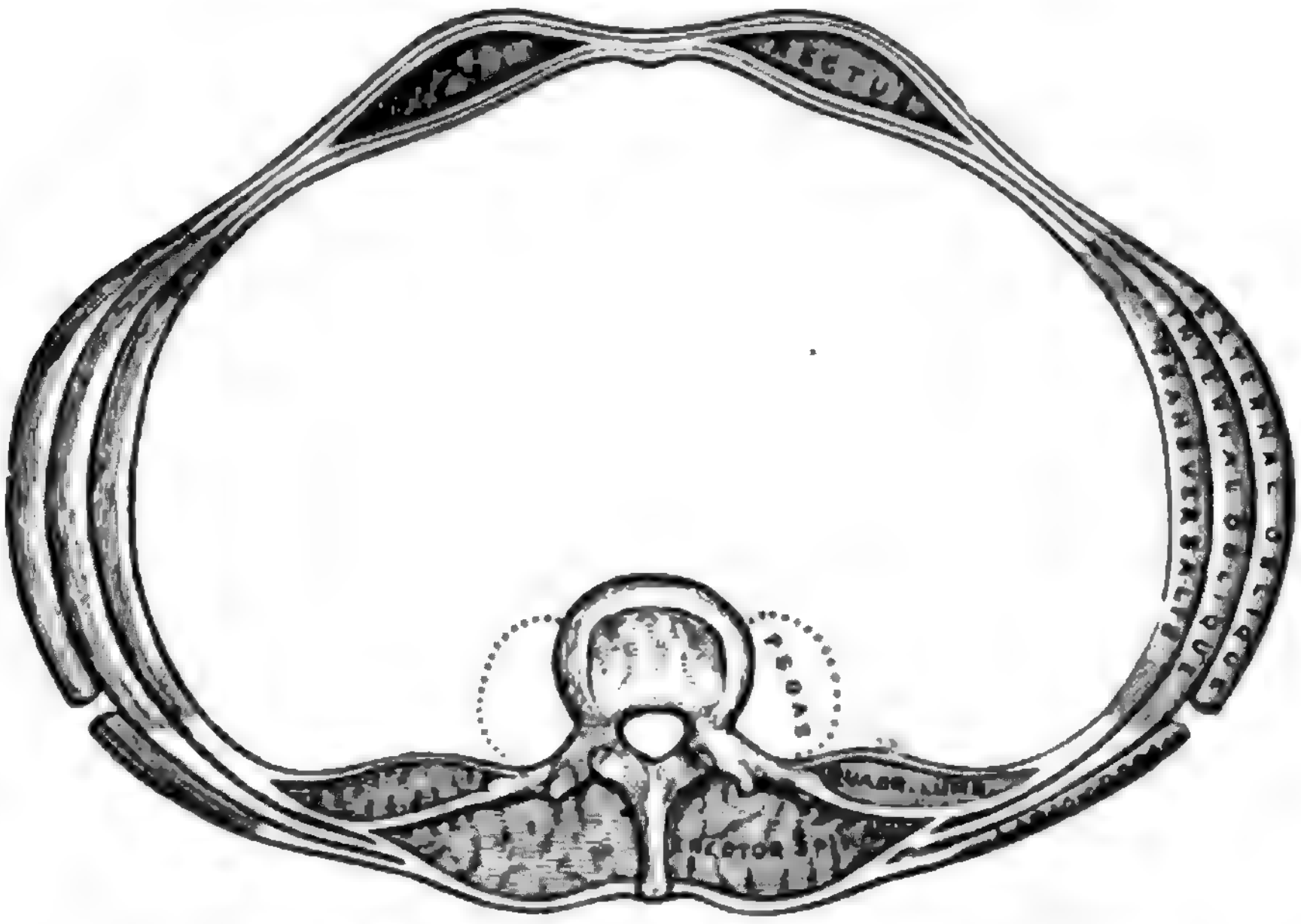

A Transverse Section of the Abdomen in the Lumbar Region.

Dissection.—To expose the Rectus muscle, open its sheath by a vertical incision extending from the margin of the thorax to the pubes, and then reflect the two portions from the surface of the muscle; which is easily done, excepting at the lineæ transversæ, where so close an adhesion exists that the greatest care is requisite in separating them. Now raise the outer edge of the muscle in order to examine the posterior layer of the sheath. By dividing the muscle in the centre, and turning its lower part downward, the point where the posterior wall of the sheath terminates in a thin curved margin will be seen.

The **Rectus abdominis** is a long flat muscle which extends along the whole length of the front of the abdomen, being separated from its fellow of the opposite side by the linea alba. It is much broader above than below, and arises by two tendons, the external or larger being attached to the crest of the os pubis, the internal, smaller portion interlacing with its fellow of the opposite side and being connected with the ligaments covering the symphysis pubis. The fibres ascend vertically, and the muscle, becoming broader and thinner at its upper part, is inserted by three portions of unequal size into the cartilages of the fifth, sixth, and seventh ribs. Some fibres are occasionally connected with the costo-xiphoid ligaments and side of the ensiform cartilage.

The Rectus muscle is traversed by a series of tendinous intersections which vary from two to five in number, and have received the name of *Lineæ transversæ.* One of these is usually situated opposite the umbilicus, and two above that point; of the latter, one corresponds to the extremity of the ensiform cartilage, and the other to the interval between the ensiform cartilage and the umbilicus; there is occasionally one below the umbilicus. These intersections pass transversely or obliquely across the muscle in a zigzag course; they rarely extend completely through its substance, sometimes pass only halfway across it, and are intimately adherent to the sheath in which the muscle is enclosed.

The Rectus is enclosed in a sheath (Fig. 306) formed by the aponeuroses of the Oblique and Transversalis muscles, which are arranged in the following manner: When the aponeurosis of the Internal oblique arrives at the outer margin of the Rectus, it divides into two lamellæ, one of which passes in front of the Rectus, blending with the aponeurosis of the External oblique, the other, behind it, blending with the aponeurosis of the Transversalis; and these, joining again at its inner border, are inserted into the linea alba. This arrangement of the fasciæ exists along the upper three-fourths of the muscle: at the commencement of the lower fourth the posterior wall of the sheath terminates in a thin curved margin, *the semilunar fold of Douglas*, the concavity of which looks downward toward the pubes, the aponeuroses of all three muscles passing in front of the Rectus without any separation. The Rectus muscle, in the situation where its sheath is deficient, is separated from the peritoneum by the transversalis fascia.

The **Pyramidalis** is a small muscle, triangular in shape, placed at the lower part of the abdomen in front of the Rectus, and contained in the same sheath with that muscle. It arises by tendinous fibres from the front of the os pubis and the anterior pubic ligament; the fleshy portion of the muscle passes upward, diminishing in size as it ascends, and terminates by a pointed extremity, which is inserted into the linea alba midway between the umbilicus and the os pubis. This muscle is sometimes found wanting on one or both sides; the lower end of the Rectus then becomes proportionately increased in size. Occasionally it has been found double on one side, or the muscles of the two sides are of unequal size. Sometimes its length exceeds what is stated above.

The **Quadratus lumborum** (Fig. 301, p. 407) is situated in the lumbar region; it is irregularly quadrilateral in shape, broader below than above, and consists of two portions. One portion arises by aponeurotic fibres from the ilio-lumbar ligament and the adjacent portion of the crest of the ilium for about two inches, and is inserted into the lower border of the last rib about half its length, and by four small tendons into the apices of the transverse processes of the four upper lumbar vertebræ. The other portion of the muscle, situated in front of the preceding, arises from the upper border of the transverse processes of the third, fourth, and fifth lumbar vertebræ, and is inserted into the lower margin of the last rib. This portion is not always found. The Quadratus lumborum is contained in a sheath formed by the anterior and middle lamellæ of the aponeurosis of origin of the Transversalis.

RELATIONS.—Its anterior surface (or rather the fascia which covers its anterior surface) is in relation with the colon, the kidney, the psoas muscle, and the diaphragm. Its posterior surface is in relation with the middle lamella of the lumbar fascia, which separates it from the Erector spinæ. The Quadratus lumborum extends, however, beyond the outer border of the Erector spinæ. [The relations of the Quadratus should be carefully studied, in view of the now frequent operations in this region on the colon and the kidney.]

NERVES.—The abdominal muscles are supplied by the lower intercostal, ilio-hypogastric, and ilio-inguinal nerves. The Quadratus lumborum receives filaments from the anterior branches of the lumbar nerves.

In the description of the abdominal muscles mention has frequently been made of the linea alba, lineæ semilunares, and lineæ transversæ: when the dissection of the muscles is completed these structures should be examined.

The **Linea alba** is a tendinous raphé or cord seen along the middle line of the abdomen, extending from the ensiform cartilage to the pubes. It is placed between the inner borders of the Recti muscles, and is formed by the blending of the aponeuroses of the Oblique and Transversalis muscles. It is narrow below, corresponding to the narrow interval existing between the Recti, but broader above, as these muscles diverge from one another in their ascent, becoming of considerable breadth after great distension of the abdomen from pregnancy or ascites. It presents numerous apertures for the passage of vessels and nerves; the largest of these is the **Umbilicus**, which in the fœtus transmits the umbilical vessels, but in the adult is obliterated, the cicatrix being stronger than the neighboring parts; hence umbilical hernia occurs in the adult *near* the umbilicus, whilst in the fœtus it occurs *at* the umbilicus. [The difference in the umbilicus in the two sexes is marked: in men it is small and narrow, in women wide and deep, irrespective of pregnancy. The best antique statues make the distinction accurately. At the umbilicus all the structures of the belly-wall are united. Hence when in laparotomy any doubt exists as to whether the peritoneal cavity has been opened, try to sweep the finger under the umbilicus. If it passes freely under it (after breaking up any adhesions that may exist), the belly-cavity is opened; if not, the finger is between two layers of the belly-wall.] The linea alba is in relation in front with the integument, to which it is adherent, especially at the umbilicus; behind, it is separated from the peritoneum by the transversalis fascia; and below, by the urachus and the bladder when that organ is distended.

The **Lineæ semilunares** are two curved tendinous lines placed one on each side of the linea alba. Each corresponds with the outer border of the Rectus muscle, extends from the cartilage of the eighth rib to the pubes, and is formed by the aponeurosis of the internal oblique at its point of division to enclose the Rectus, where it is reinforced in front and behind by the External oblique and Transversalis.

The **Lineæ transversæ** are three or four narrow transverse lines which intersect the Rectus muscle, as already mentioned; they connect the lineæ semilunares with the linea alba.

ACTIONS.—The abdominal muscles perform a threefold action:

When the pelvis and thorax are fixed they compress the abdominal viscera by constricting the cavity of the abdomen, in which action they are materially assisted by the descent of the diaphragm. By these means [in part] the fœtus is expelled from the uterus, the feces from the rectum, the urine from the bladder, and the contents of the stomach in vomiting.

If the pelvis and spine are fixed, these muscles compress the lower part of the thorax [and push up the diaphragm by compressing the viscera], materially assisting expiration. If the pelvis alone is fixed, the thorax is bent directly forward when the muscles of both sides act, or to either side when those of one side act alone, rotation of the trunk at the same time taking place toward the opposite side.

If the thorax is fixed, these muscles, acting together, draw the pelvis [forward and] upward, as in climbing; or, acting singly, they draw the pelvis upward and rotate the vertebral column to one side or the other. The Recti muscles, acting from below, depress the thorax, and consequently flex the vertebral column; when acting from above, they flex the pelvis upon the vertebral column. The Pyramidales are tensors of the linea alba.

The Quadratus lumborum by the portion inserted into the last rib draws down and fixes that bone, acting thereby as a muscle of forced expiration, but at the same time, by fixing the last rib, it opposes the tendency of the diaphragm to draw it upward, and thus it becomes an assistant to inspiration: by the portion inserted into the lumbar vertebræ it draws the spine toward the ilium, and thus inclines the trunk toward its own side; or, if the thorax and spine be fixed, it may act upon the pelvis, raising it toward its own side when only one muscle is put in action; and when both muscles act together, either from below or above, they flex the trunk.

[Several different actions will show these muscles well in the model. Folding the arms behind the back or placing them akimbo, and then bending backward, show the External oblique. Lying flat on the back and raising the head and shoulders a few inches will best show the Rectus and its lineæ transversæ. It is well that the different outline of the belly in the two sexes be noted. In the male the anterior line is in general a nearly uniform curve from the sternum to the pubes, slightly more marked below the navel. In women above the navel it is almost a straight line, but below it the anterior curve is very marked.]

MUSCLES AND FASCIÆ OF THE THORAX.

The muscles exclusively connected with the bones in this region are few in number. They are the

Intercostales externi.
Intercostales interni.
Infracostales.
Triangularis sterni.
Levatores costarum.

Intercostal Fasciæ.—A thin but firm layer of fascia covers the outer surface of the External intercostal and the inner surface of the Internal intercostal muscles, and a third layer, more delicate, is interposed between the two planes of muscular fibres. These are the intercostal fasciæ; they are best marked in those situations where the muscular fibres are deficient, as between the External intercostal muscles and sternum in front, and between the Internal intercostals and spine behind.

The **Intercostal Muscles** (Fig. 312, p. 431) are two thin planes of muscular and tendinous structure placed one over the other, filling up the intercostal spaces, and being directed obliquely between the margins of the adjacent ribs. They have received the name "external" and "internal," from the position they bear to one another. The Intercostal muscles consist of muscular and tendinous fibres, the latter being longer and more numerous than the former; hence the walls of the intercostal spaces possess very considerable strength, to which the crossing of the muscular fibres materially contributes.

The **External intercostals** are eleven in number on each side, being attached to the adjacent margins of each pair of ribs, and extending from the tubercles of the ribs behind to the commencement of the cartilages of the ribs in front, where they terminate in a thin membranous aponeurosis which is continued forward to the sternum. They arise from the outer lip of the groove on the lower border of each rib, and are inserted into the upper border of the rib below. In the two lowest spaces they extend to the end of the cartilages. Their fibres are directed obliquely downward and forward, in a similar direction with those of the External oblique muscle. They are thicker than the Internal intercostals.

RELATIONS.—By their *outer surface* with the muscles which immediately invest the chest—viz. the Pectoralis major and minor, Serratus magnus, and Rhomboideus major, Serratus posticus superior and inferior, Scalenus posticus, Sacro-lumbalis, Longissimus dorsi, Cervicalis ascendens, Transversalis colli, Levatores costarum, and the Obliquus externus abdominis; by their *internal surface* with a thin layer of fascia which separates them from the intercostal vessels and nerve and the Internal intercostal muscles, and behind from the pleura.

The **Internal intercostals**, also eleven in number on each side, are placed on the inner surface of the preceding, commencing anteriorly at the sternum in the interspaces between the cartilages of the true ribs, and from the anterior extremities of the cartilages of the false ribs. They extend backward as far as the angles of the ribs, whence they are continued to the vertebral column by a thin aponeurosis. They arise from the inner lip of the groove on the lower border of each rib, as well as from the corresponding costal cartilage, and are inserted into the upper border of the rib below. Their fibres are directed obliquely downward and backward, decussating with the fibres of the preceding.

RELATIONS.—By their *external surface* with the External intercostals and the intercostal vessels and nerves; by their *internal surface* with the pleura costalis, Triangularis sterni, and Diaphragm.

The **Infracostales** (subcostales) consist of muscular and aponeurotic fasciculi which vary in number and length; they arise from the inner surface of one rib, and are inserted into the inner surface of the first, second, or third rib below. Their direction is most usually oblique, like the Internal intercostals. They are most frequent between the lower ribs.

The **Triangularis sterni** is a thin plane of muscular and tendinous fibres situated upon the inner wall of the front of the chest. It arises from the lower part of the side of the sternum, from the inner surface of the ensiform cartilage, and from the sternal ends of the costal cartilages of the three or four lower true ribs. Its fibres diverge upward and outward, to be inserted by fleshy digitations into the lower border and inner surfaces of the costal cartilages of the second, third, fourth, and fifth ribs. The lowest fibres of this muscle are horizontal in their direction, and are continuous with those of the Transversalis; those which succeed are oblique, whilst the superior fibres are almost vertical. This muscle varies much in its attachment, not only in different bodies, but on opposite sides of the same body.

Relations.—*In front* with the sternum, ensiform cartilage, costal cartilages, Internal intercostal muscles, and internal mammary vessels; *behind* with the pleura, pericardium, and anterior mediastinum.

The **Levatores costarum** (Fig. 301, p. 407), twelve in number on each side, are small tendinous and fleshy bundles which arise from the extremities of the transverse processes of the seventh cervical and eleven upper dorsal vertebræ, and, passing obliquely downward and outward, are inserted into the upper rough surface of the rib below them, between the tubercle and the angle. That for the first rib arises from the transverse process of the last cervical vertebra, and that for the last from the eleventh dorsal. The Inferior levatores divide into two fasciculi, one of which is inserted as above described; the other fasciculus passes down to the second rib below its origin; thus each of the lower ribs receives fibres from the transverse processes of two vertebræ.

Nerves.—The muscles of this group are supplied by the intercostal nerves.

Actions.—The Intercostals are the chief agents in the movement of the ribs in ordinary respiration. The External intercostals raise the ribs, especially their fore part, and so increase the capacity of the chest from before backward; at the same time they evert their lower borders, and so enlarge the thoracic cavity transversely. The Internal intercostals at the side of the thorax depress the ribs and invert their lower borders, and so diminish the thoracic cavity; but at the fore part of the chest these muscles assist the External intercostals in raising the cartilages.[1] The Levatores costarum assist the External intercostals in raising the ribs. The Triangularis sterni draws down the costal cartilages; it is therefore an expiratory muscle. [From experiments by the American Editor upon a criminal executed by hanging (*Trans. Coll. Phys. Phila.*, Third Series, vol. i., 1875, p. 97), the conclusion was reached that the External intercostals were muscles of expiration, as they pulled the ribs down, while the Internal intercostals pulled the ribs up, and were muscles of inspiration.]

Muscles of Inspiration and Expiration.—The muscles which assist the action of the Diaphragm in ordinary tranquil inspiration are the Intercostals and the Levatores costarum, as above stated, and the Scaleni. When the need for more forcible action exists the shoulders and the base of the scapula are fixed, and then the powerful muscles of forced inspiration come into play: the chief of these are the Trapezius, the Pectoralis minor, the Serratus posticus superior and inferior, and the Rhomboidei. The lower fibres of the Serratus magnus may possibly assist slightly in dilating the chest by raising and everting the ribs. The Sterno-mastoid also, when the head is fixed, assists in forced inspiration by drawing up the sternum and by fixing the clavicle, and thus affording a fixed point for the action of the muscles of the chest.

The ordinary action of expiration is hardly effected by muscular force, but results from a return of the walls of the thorax to a condition of rest, owing to their own elasticity and to that of the lungs. Forced expiratory actions are performed mainly by the flat muscles (Obliqui and Transversalis) of the abdomen, assisted also by the Rectus. Other muscles of forced expiration are the Internal intercostals and Triangularis sterni (as above mentioned), the Quadratus lumborum, and the Sacro-lumbalis.

---

[1] The view of the action of the Intercostal muscles given in the text is that which is taught by Hutchinson (*Cycl. of Anat. and Phys.*, art. "Thorax"), and is usually adopted in our schools. It is, however, much disputed. Hamberger believed that the External intercostals act as elevators of the ribs or muscles of inspiration, while the Internal act in expiration. Haller taught that both sets of muscles act in common—viz. as muscles of inspiration; and this view is adopted by many of the best anatomists of the Continent, and appears supported by many observations made on the human subject under various conditions of disease, and on living animals in whom the muscles have been exposed under chloroform. The reader may consult an interesting paper by Dr. Cleland in the *Journal of Anat. and Phys.*, No. II., May, 1867, p. 209, "On the Hutchinsonian Theory of the Action of the Intercostal Muscles," who refers also to Henle, Luschka, Budge, and Bäumler, "Observations on the Actions of the Intercostal Muscles," Erlangen, 1860 (in *New Syd. Soc.'s Year-Book for 1861*, p. 69).

DIAPHRAGMATIC REGION.

Diaphragm.

The **Diaphragm** (*διάφραγμα*, a partition-wall) (Fig. 307) is a thin musculo-fibrous septum placed obliquely at the junction of the upper with the middle third of the trunk, and separating the thorax from the abdomen, forming the floor of the former cavity and the roof of the latter. It is elliptical, its longest diameter being from side to side, somewhat fan-shaped, the broad elliptical portion being horizontal; the narrow part, which represents the handle of the fan, vertical and joined at right angles to the former. It is from this circumstance that some anatomists describe it as consisting of two portions, the upper or great muscle of the Diaphragm, and the lower or lesser muscle. It arises from the whole of the internal circumference of the thorax, being attached in front by fleshy fibres to the ensiform cartilage; on either side, to the inner surface of the cartilages and bony portions of the six or seven inferior ribs, interdigitating with the Transversalis; and behind, to two aponeurotic arches named the *ligamentum arcuatum externum* and *internum* and to the lumbar vertebræ. The fibres from these sources vary in length; those arising from the ensiform appendix are very short and occasionally aponeurotic; those from the ligamenta arcuata, and more especially those from the ribs at the side of the chest, are longer, describe well-marked curves as they ascend, and finally converge to be inserted into the circumference of the central tendon. Between the sides of the muscular slip from the ensiform appendix and the cartilages of the adjoining ribs the fibres of the Diaphragm are deficient, the interval being filled by areolar tissue, covered on the thoracic side by the pleuræ; on the abdominal, by the peritoneum.

FIG. 307.

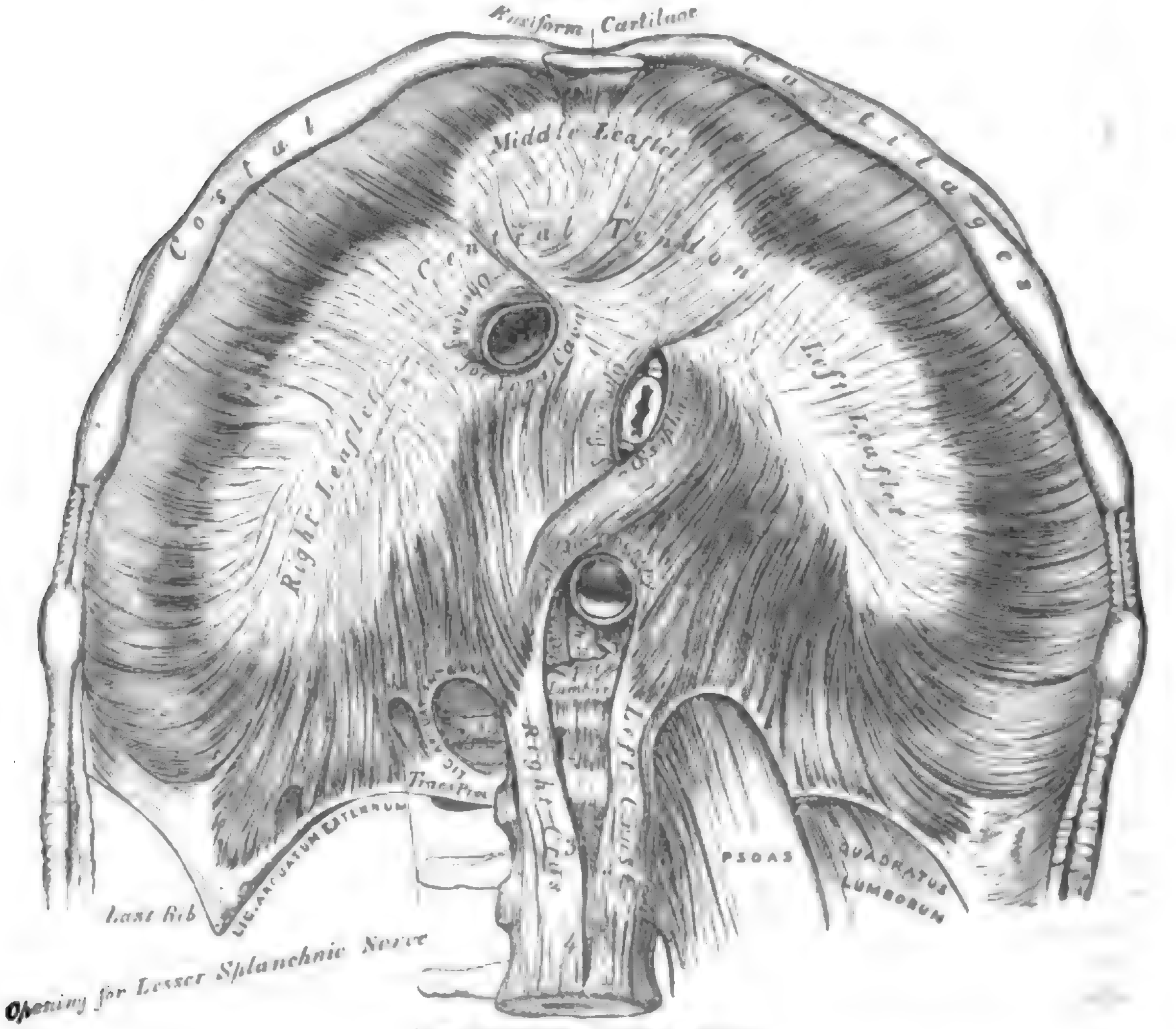
Ensiform Cartilage
Costal Cartilages
Middle Leaflet
Central Tendon
Opening for Vena Cava
Right Leaflet
Left Leaflet
Lumbar
Transv. Pro.
Right Crus
Left Crus
3
4
PSOAS
QUADRATUS LUMBORUM
LIG. ARCUATUM EXTERNUM
Last Rib
Opening for Lesser Splanchnic Nerve

The Diaphragm, under surface.

[Fig. 308.

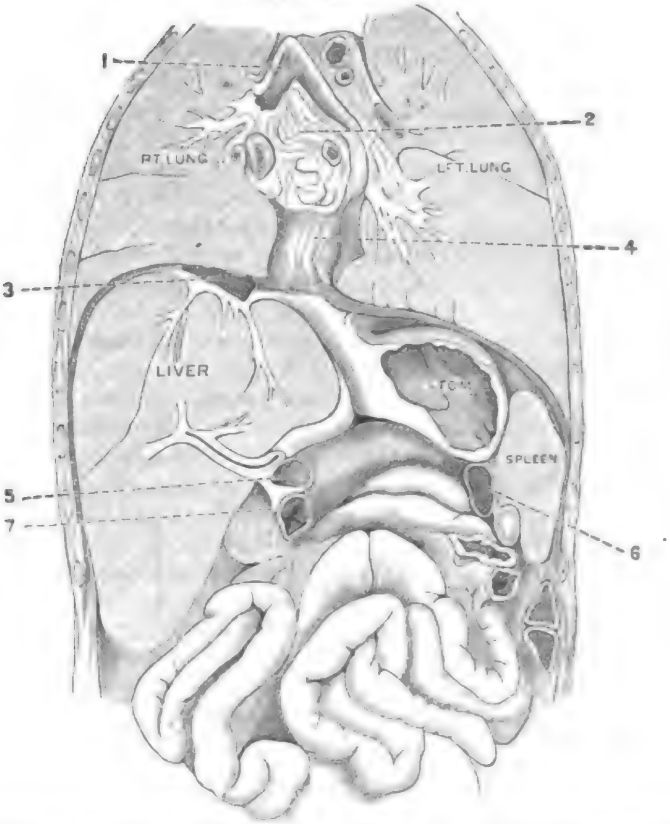

Coronal Section of the Trunk, at the end of the twelfth rib (all the ribs except the last show in section).

1. Trachea at its bifurcation;
2. Posterior wall of pericardium and the pulmonary veins;
3. Inferior vena cava as it passes through the diaphragm (the diaphragm is seen passing obliquely above the stomach and liver);
4. Œsophagus;
5. Duodenum;
6, 7. Transverse colon (Henle).]

This is consequently a weak point, and a portion of the contents of the abdomen may protrude into the chest, forming phrenic or diaphragmatic hernia, or a collection of pus in the mediastinum may descend through it, so as to point at the epigastrium.

The *ligamentum arcuatum internum* is a tendinous arch, thrown across the upper part of the Psoas magnus muscle on each side of the spine. It is connected by one end to the other side of the body of the first, and occasionally the second, lumbar vertebræ, being continuous with the outer side of the tendon of the corresponding crus; and by the other end to the front of the transverse process of the second lumbar vertebra.

The *ligamentum arcuatum externum* is a thickened upper margin of the anterior lamella of the transversalis aponeurosis; it arches across the upper part of the Quadratus lumborum, being attached by one extremity to the front of the transverse process of the second lumbar vertebra, and by the other to the apex and lower margin of the last rib.

[Fig. 309.

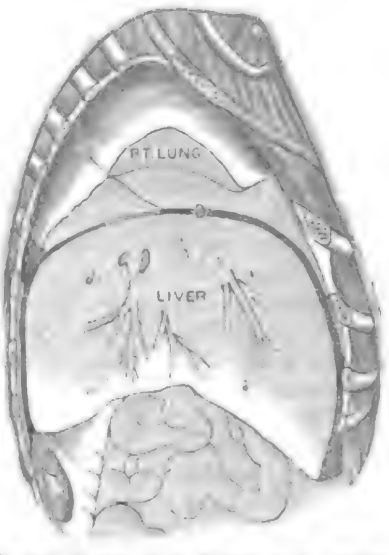

Sagittal Section of the Trunk, at the border of the right second rib: D, the diaphragm (Henle).]

To the spine the Diaphragm is connected by two crura, which are situated on the bodies of the lumbar vertebræ on each side of the aorta. The crura at their origin are tendinous in structure, the right crus, larger and longer than the left, arising from the anterior surface of the bodies and intervertebral substances of the second, third, and fourth lumbar vertebræ; the left, from the second and third, both blending with the anterior common ligament of the spine. A tendinous arch is thrown across the front of the vertebral column from the tendon of one crus to that of the other, beneath which pass the aorta, vena azygos major, and thoracic duct. The tendons terminate in two large fleshy bellies, which, with the tendinous portions above alluded to, are called the *crura*, or *pillars of the diaphragm*. The outer fasciculi of the two crura are directed upward and outward to the central tendon; but the inner fasciculi decussate in front of the aorta, and then diverge, so as to surround the œsophagus before ending in the central tendon. The anterior and larger of these fasciculi is formed by the right crus.

The *Central* or *Cordiform Tendon* of the Diaphragm is a thin but strong tendinous aponeurosis situated at the centre of the vault formed by the muscle, immediately below the pericardium, with which its circumference is blended. It is shaped somewhat like a trefoil leaf, consisting of three divisions or leaflets, separated from one another by slight indentations. The right leaflet is the largest, the middle one, directed toward the ensiform cartilage, the next in size, and the left the smallest. In structure the tendon is composed of several planes of fibres, which intersect one another at various angles and unite into straight or curved bundles—an arrangement which affords it additional strength.

The *Openings* connected with the Diaphragm are three large and several smaller apertures. The former are the aortic, the œsophageal, and the opening for the vena cava.

The *aortic opening* is the lowest and the most posterior of the three large apertures connected with this muscle. It is situated in the middle line, immediately in front of the bodies of the vertebræ, and is therefore *behind* the Diaphragm, not in it. It is an osseo-aponeurotic aperture formed by a tendinous arch thrown across the front of the bodies of the vertebræ, from the crus on one side to that on the other, and transmits the aorta, vena azygos major, thoracic duct, and occasionally the left sympathetic nerve.

The *œsophageal opening*, elliptical in form, muscular in structure, and formed by the two crura, is placed above, and at the same time anterior and a little to the left of, the preceding. It transmits the œsophagus and pneumogastric nerves. The anterior margin of this aperture is occasionally tendinous, being formed by the margin of the central tendon.

The *opening for the vena cava* (*foramen quadratum*) is the highest; it is quadrilateral in form, tendinous in structure, and placed at the junction of the right and middle leaflets of the central tendon, its margins being bounded by four bundles of tendinous fibres which meet at right angles.

The *right crus* transmits the sympathetic and the greater and lesser splanchnic nerves of the right side; the *left crus*, the greater and lesser splanchnic nerves of the left side and the vena azygos minor.

The *Serous Membranes* in relation with the Diaphragm are four in number, three lining its upper or thoracic surface, one its abdominal. The three serous membranes on its upper surface are the pleura on either side, and the serous layer of the pericardium, which covers the middle portion of the tendinous centre. The serous membrane covering its under surface is a portion of the general peritoneal membrane of the abdominal cavity.

The Diaphragm is arched, being convex toward the chest and concave to the abdomen. The *right portion* forms a complete arch from before backward, being accurately moulded over the convex surface of the liver and having resting upon it the concave base of the right lung. The *left portion* is arched from before backward in a similar manner, but the arch is narrower in front, being encroached upon by the pericardium, and lower than the right at its summit by about three-quarters of an inch. It supports the base of the left lung, and covers the great end of the stomach, the spleen, and left kidney. At its circumference the Diaphragm is higher in the mesial line of the body than at either side; but in the middle of the thorax the central portion, which supports the heart, is on a lower level than the two lateral portions.

The height of the Diaphragm is constantly varying during respiration, the muscle being carried upward or downward from the average level: its height also varies according to the degree of distension of the stomach and intestines and the size of the liver. After a forced expiration the right arch is on a level in front with the fourth costal cartilage, at the side with the fifth, sixth, and seventh ribs, and behind with the eighth rib, the left arch being usually from one to two ribs' breadth below the level of the right one. In a forced inspiration it descends from one to two inches; its slope would then be represented by a line drawn from the ensiform cartilage toward the tenth rib.

NERVES.—The Diaphragm is supplied by the phrenic nerves and phrenic plexus of the sympathetic.

ACTIONS.—The Diaphragm is the principal muscle of inspiration. When in a condition of rest the muscle presents a concave, domed surface toward the abdomen; when it contracts, this dome becomes much flatter, and as a consequence the level of the floor of the chest is lowered, and therefore the vertical diameter of the thoracic cavity increased, while the abdominal cavity is encroached upon and the abdominal viscera pushed down, so as to cause a projection of the flaccid abdominal wall. [In inspiration also, owing to the partial fixation of the central tendon, partly by its attachment to the pericardium, and partly by its finding a *point d'appui* on the abdominal viscera, contraction of the Diaphragm causes elevation of the lower ribs and their displacement externally, thus widening the chest laterally. Inspiration causes always a tendency to a vacuum in the chest, and so produces an inrush of air by the windpipe, and of blood through the veins—an effect which is reversed in expiration.] When at the end of inspiration the Diaphragm relaxes, the abdominal walls return to their natural position; they therefore push up the viscera again, and these, pressing on the Diaphragm, cause it to resume its ordinary position of rest.

In all expulsive acts the Diaphragm is called into action to give additional power to each expulsive effort. Thus, before sneezing, coughing, laughing, and crying, before vomiting, previous to the expulsion of the urine and feces or of the fœtus from the womb, a deep inspiration takes place.[1]

MUSCLES AND FASCIÆ OF THE UPPER EXTREMITY.

The Muscles of the Upper Extremity are divisible into groups, corresponding with the different regions of the limb:

OF THE SHOULDER.

Anterior Thoracic Region.

Pectoralis major.
Pectoralis minor.
Subclavius.

Lateral Thoracic Region.

Serratus magnum.

Acromial Region.

Deltoid.

Anterior Scapular Region.

Subscapularis.

Posterior Scapular Region.

Supraspinatus.
Infraspinatus.
Teres minor.
Teres major.

OF THE ARM.

Anterior Humeral Region.

Coraco-brachialis.
Biceps.
Brachialis anticus.

Posterior Humeral Region.

Triceps.
Subanconeus.

---

[1] For a detailed description of the general relations of the Diaphragm and its action refer to Dr. Sibson's *Medical Anatomy*.

Of the Forearm.

Anterior Brachial Region.

Superficial Layer.
- Pronator radii teres.
- Flexor carpi radialis.
- Palmaris longus.
- Flexor carpi ulnaris.
- Flexor sublimis digitorum.

Deep Layer.
- Flexor profundus digitorum.
- Flexor longus pollicis.
- Pronator quadratus.

Radial Region.

Supinator longus.
Extensor carpi radialis longior.
Extensor carpi radialis brevior.

Posterior Brachial Region.

Superficial Layer.
- Extensor communis digitorum.
- Extensor minimi digiti.
- Extensor carpi ulnaris.
- Anconeus.

Deep Layer.
- Supinator brevis.
- Extensor ossis metacarpi pollicis.
- Extensor primi internodii pollicis.
- Extensor secundi internodii pollicis.
- Extensor indicis.

Of the Hand.

Radial Region.

Abductor pollicis.
Flexor ossis metacarpi pollicis (opponens).
Flexor brevis pollicis.
Adductor pollicis.

Ulnar Region.

Palmaris brevis.
Abductor minimi digiti.
Flexor brevis minimi digiti.
Flexor ossis metacarpi minimi digiti (opponens).

Palmar Region.

Lumbricales.
Interossei palmares.
Interossei dorsales.

Dissection of Pectoral Region and Axilla (Fig. 310).—The arm being drawn away from the side nearly at right angles with the trunk and rotated outward, make a vertical incision through the integument in the median line of the chest from the upper to the lower part of the sternum; a second incision along the lower border of the Pectoral muscle from the ensiform cartilage to the inner side of the axilla; a third from the sternum along the clavicle as far as its centre; and a fourth from the middle of the clavicle obliquely downward, along the interspace between the Pectoral and Deltoid muscles, as low as the fold of the armpit. The flap of integument is then to be dissected off in the direction indicated in the figure, but not entirely removed, as it should be replaced on completing the dissection. If a transverse incision is now made from the lower end of the sternum to the side of the chest as far as the posterior fold of the armpit, and the integument reflected outward, the axillary space will be more completely exposed.

Fig. 310.

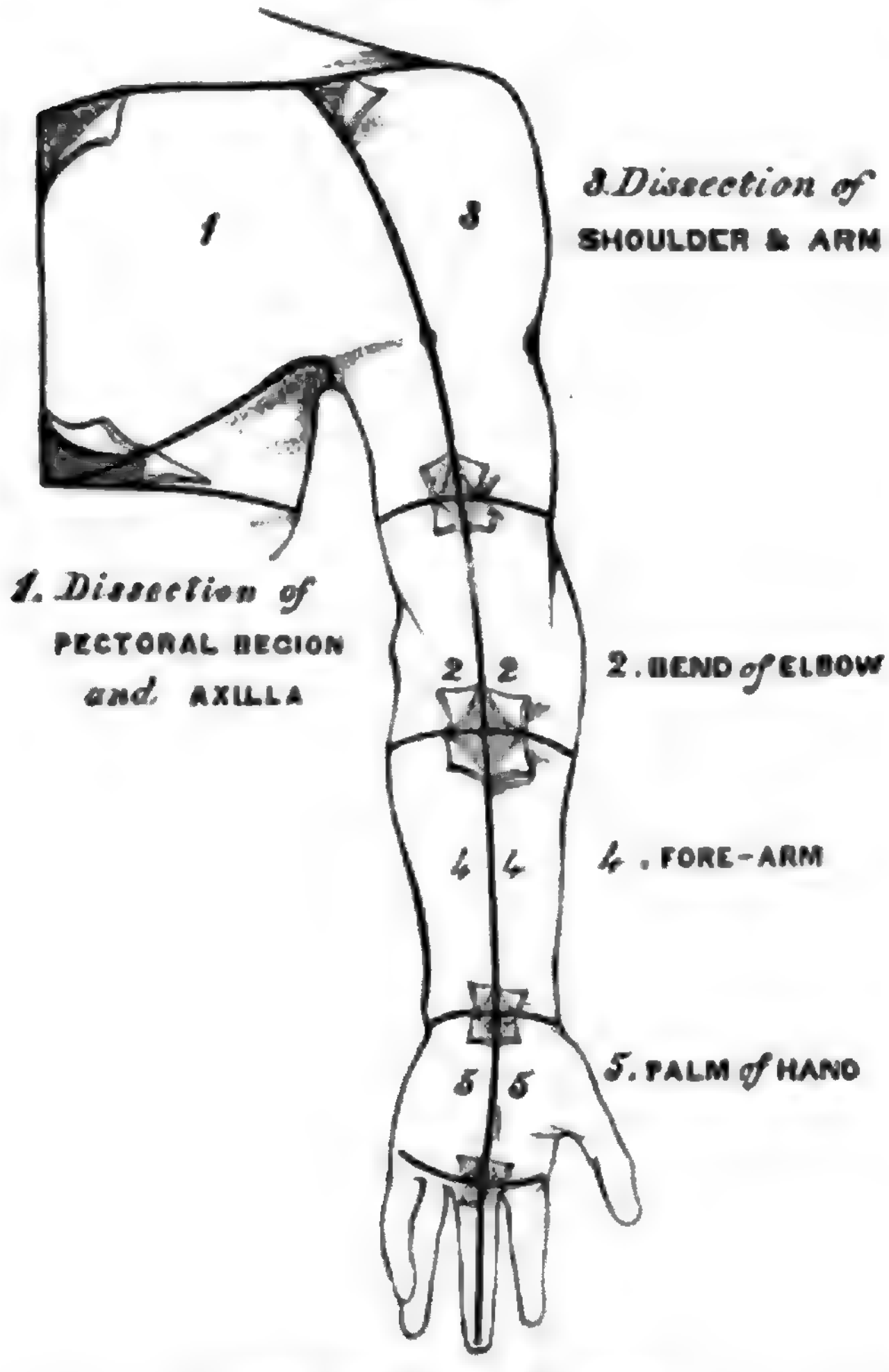
1
3
3. Dissection of SHOULDER & ARM
1. Dissection of PECTORAL REGION and AXILLA
2
2
2. BEND of ELBOW
4
4
4. FORE-ARM
5
5
5. PALM of HAND

Dissection of Upper Extremity.

Fasciæ of the Thorax.

The **Superficial Fascia** of the thoracic region is a loose cellulo-fibrous layer continuous with the superficial fascia of the neck and upper extremity above and of the abdomen below; opposite the mamma it subdivides into two layers, one of which passes in front, the other behind that gland; and from both of these layers numerous septa pass into its substance, supporting its various lobes: from the anterior layer, fibrous processes pass forward to the integument and nipple, enclosing in their areolæ masses of fat. These processes were called by Sir A. Cooper the *ligamenta suspensoria*, from the support they afford to the gland in this situation. On removing the superficial fascia with the mamma the **Deep Fascia** of the thoracic region is exposed: it is a thin aponeurotic lamina covering the surface of the great Pectoral muscle, and sending numerous prolongations between its fasciculi: it is attached in the middle line to the front of the sternum, and above to the clavicle: it is very thin over the upper part of the muscle, somewhat thicker in the interval between the Pectoralis major and Latissimus dorsi, where it closes in the axillary space, and divides at the outer margin of the latter muscle into two layers, one of which passes in front and the other behind it; these proceed as far as the spinous processes of the dorsal vertebræ, to which they are attached. At the lower part of the thoracic region this fascia is well developed, and is continuous with the fibrous sheath of the Recti muscles.

ANTERIOR THORACIC REGION.

Pectoralis major. Pectoralis minor.
Subclavius.

The **Pectoralis major** (Fig. 309) is a broad, thick, triangular muscle situated at the upper and fore part of the chest in front of the axilla. It arises from the anterior surface of the sternal half of the clavicle; from half the breadth of the anterior surface of the sternum as low down as the attachment of the cartilage of the sixth or seventh rib, its origin consisting of aponeurotic fibres which intersect with those of the opposite muscle; it also arises from the cartilages of all the true ribs, with the exception, frequently, of the first or of the seventh, or both; and from the aponeurosis of the External oblique muscle of the abdomen. The fibres from this extensive origin converge toward its insertion, giving to the muscle a radiated appearance. Those fibres which arise from the clavicle pass obliquely outward and downward, and are usually separated from the rest by a cellular interval: those from the lower part of the sternum and the cartilages of the lower true ribs pass upward and outward; whilst the middle fibres pass horizontally. As these three sets of fibres converge, they are so disposed that the upper overlap the middle and the middle the lower portion, the fibres of the lower portion being folded backward upon themselves, so that those fibres which are lowest in front become highest at their point of insertion. They all terminate in a flat tendon, about two inches broad, which is inserted into the anterior bicipital ridge of the humerus. This tendon consists of two laminæ, placed one in front of the other, and usually blended together below. The anterior, the thicker, receives the clavicular and upper half of the sternal portion of the muscle, the posterior lamina receiving the attachment of the lower half of the sternal portion. From this arrangement it results that the fibres of the upper and middle portions of the muscle are inserted into the lower part of the bicipital ridge, those of the lower portion into the upper part. The tendon at its insertion is connected with that of the Deltoid; it sends up an expansion over the bicipital groove toward the head of the humerus; another backward, which lines the groove; and a third to the fascia of the arm. [Mr. Wagstaffe (*Journ. Anat. and Phys.*, 1871) has described the insertion of the Pectoralis major more accurately, as follows: "The fibres of the clavicular portion are inserted in the same order as they arise: the outermost, and particularly the deeper, fibres of origin are inserted at the uppermost part of the tendon; the innermost fibres, or those nearest to the sterno-clavicular articulation, pass down to the lowermost part of the tendon. The sternal portion is peculiarly arranged. It will be seen, on turning aside the clavicular part, that the uppermost fibres of the sternal muscle—*i. e.* those from the first costal cartilage (if, as is perhaps most usual, there is attachment to that part), or from the neighborhood of the sterno-clavicular articulation—pass downward under cover of the clavicular muscle, and are inserted into the uppermost part of the second plane of attachment to the outer bicipital ridge. Fibres from the sternum opposite the first intercostal space, or sometimes a little lower, can be traced down to be inserted into the lowest part of the attachment to the humerus. Below these last-mentioned fibres the muscular bundles gradually pass under the previous ones, and ultimately the lowest fibres of origin from the aponeurosis of the external oblique pass to the highest part of the third plane of insertion; and it is these fibres which are connected with the fibrous band passing upward to the head of the humerus.

Fig. 311.

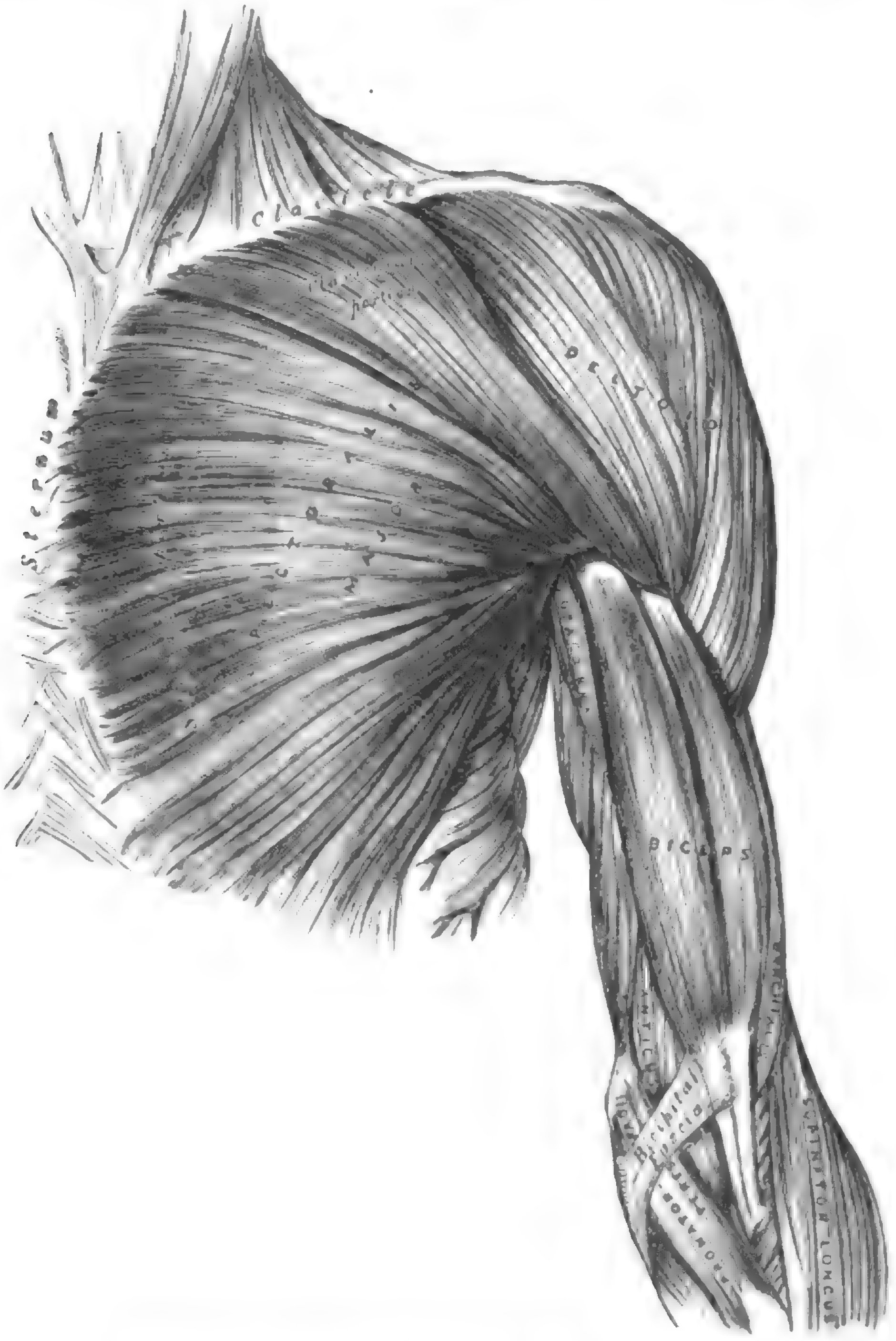

Muscles of the Chest and Front of the Arm, superficial view.

"It will thus be seen that the so-called tendon of the Pectoralis major is composed of three layers: 1, that of the clavicular portion, 2 and 3, those of the sternal portion, doubled upon itself below, but easily separable above. Of these layers, the first and second have usually about the same extent of attachment above and below, but the third passes considerably higher than the others."]

Relations.—By its *anterior surface* with the integument, the superficial fascia, the Platysma, and the mammary gland: by its *posterior surface*, its *thoracic portion*, with the sternum, the ribs and costal cartilages, the Subclavius, Pectoralis minor, Serratus magnus, and the Intercostals; its *axillary portion* forms the anterior wall of the axillary space and covers the axillary vessels and nerves. Its *upper border* lies parallel with the Deltoid, from which it is separated by the cephalic vein and descending branch of the thoracico-acromialis artery. Its *lower border* forms the anterior margin of the axilla, being at first separated from the Latissimus dorsi by a considerable interval, but both muscles gradually converge toward the outer part of the space.

Dissection.—Detach the Pectoralis major by dividing the muscle along its attachment to the clavicle, and by making a vertical incision through its substance a little external to its line of attachment to the sternum and costal cartilages. The muscle should then be reflected outward and its tendon carefully examined. The Pectoralis minor is now exposed, and immediately above it, in the interval between its upper border and the clavicle, a strong fascia, the costo-coracoid membrane.

The **Costo-coracoid Membrane** protects the axillary vessels and nerves. It is attached above to the edges of the Subclavian groove on the under surface of the clavicle, so as to enclose the Subclavius muscle; from this it passes down to the upper border of the Pectoralis minor. Externally it is very thick and dense, and forms a strong fibrous band which extends from the coracoid process to the first rib near to the origin of the Subclavius muscle. This portion is sometimes called the *costo-coracoid ligament.* Below it is thin, and at the upper border of the Pectoralis minor it splits into two layers to invest the muscle; from the lower border of the Pectoralis minor it is continued downward to join the axillary fascia, and outward to join the fascia over the short head of the Biceps. The costo-coracoid membrane is pierced by the cephalic vein, the thoracico-acromialis artery and vein, superior thoracic artery, and anterior thoracic nerves.

The **Pectoralis minor** (Fig. 312) is a thin, flat, triangular muscle situated at the upper part of the thorax, beneath the Pectoralis major. It arises by three tendinous digitations from the upper margin and outer surface of the third, fourth, and fifth ribs, near their cartilages, and from the aponeurosis covering the Intercostal muscles; the fibres pass upward and outward, and converge to form a flat tendon which is inserted into the anterior border of the coracoid process of the scapula.

RELATIONS.—By its *anterior surface* with the Pectoralis major and the superior thoracic vessels and nerves; by its *posterior surface* with the ribs, Intercostal muscles, Serratus magnus, the axillary space, and the axillary vessels and nerves. Its upper border is separated from the clavicle by a triangular interval, broad internally, narrow externally, bounded in front by the costo-coracoid membrane, and internally by the ribs. In this space are seen the axillary vessels and nerves.

The costo-coracoid membrane should now be removed, when the Subclavius muscle will be seen.

The **Subclavius** is a long, thin, spindle-shaped muscle placed in the interval between the clavicle and the first rib. It arises by a short, thick tendon from the cartilage of the first rib, in front of the rhomboid ligament; the fleshy fibres proceed obliquely upward and outward, to be inserted into a deep groove on the under surface of the middle third of the clavicle.

RELATIONS.—By its *upper surface* with the clavicle; by its *under surface* it is separated from the first rib by the subclavian vessels and brachial plexus of nerves. Its *anterior surface* is separated from the Pectoralis major by the costo-coracoid aponeurosis, which, with the clavicle, forms an osteo-fibrous sheath in which the muscle is enclosed.

If the costal attachment of the Pectoralis minor is divided across and the muscle reflected outward, the axillary vessels and nerves are brought fully into view, and should be examined.

NERVES.—The Pectoral muscles are supplied by the anterior thoracic nerves; the Subclavius, by a filament from the cord formed by the union of the fifth and sixth cervical nerves.

ACTIONS.—If the arm has been raised by the Deltoid, the Pectoralis major will, conjointly with the Latissimus dorsi and Teres major, depress it to the side of the chest, and, if acting singly, it will draw the arm across the front of the chest. [To show the action of the Pectoralis major on the model, let him place his arm on your shoulder or other similar obstacle about the same level, and press down. Notice especially how the axilla is then well defined. In muscular models the clavicular portion will sometimes form one distinct bundle, and the sternal be divided into several, and the groove between the sternal and clavicular heads will be well marked. The furrow between the Pectoralis major and the Deltoid is always well marked, though ill-limited when the muscles are at rest. Its upper end is a wide triangular depression, while the lower portion is linear. The marked difference in the appearance of the chest when the arm is hanging down and when raised should be observed. Simple raising of the arm stretches out the Pectoralis, effaces in great part its lower border, flattens the chest, and displaces the nipple of that side markedly upward. Letting the arm fall, the muscles are gathered again into a large mass with a curved lower border. Partial lifting of the arm makes the axilla more marked, but complete elevation nearly effaces it.] The Pectoralis minor depresses the point of the shoulder, drawing the scapula downward and inward to the thorax. The Subclavius depresses the shoulder, drawing the clavicle downward and forward. When the arms are fixed, all three muscles act upon the ribs, drawing them upward and expanding the chest, and thus becoming very important agents in forced inspiration. Asthmatic patients always assume an attitude which fixes the shoulders, so that all these muscles may be brought into action to assist in dilating the cavity of the chest.

LATERAL THORACIC REGION.

Serratus magnus.

The **Serratus magnus** (Fig. 312) is a broad, thin, and irregularly quadrilateral muscle situated at the upper part and side of the chest. It arises by nine fleshy digitations from the outer surface and upper border of the eight upper ribs (the second rib having two), and from the aponeurosis covering the upper intercostal spaces, and is inserted into the whole length of the anterior aspect of the posterior border of the scapula. This muscle has been divided into three portions—a superior, middle, and inferior—on account of the difference in the direction and in the extent of attachment of each part. The upper portion, separated from the rest by a cellular interval, is a narrow but thick fasciculus which arises by two digitations from the first and second ribs, and from the aponeurotic arch between them; its fibres proceed upward, outward, and backward, to be inserted into the triangular smooth surface on the anterior aspect of the superior angle of the scapula. The middle portion of the muscle arises by three digitations from the second, third, and fourth ribs; it forms a thin and broad muscular layer, which proceeds horizontally backward to be inserted into the posterior border of the scapula between the superior and inferior angles. The lower portion arises from the fifth, sixth, seventh, and eighth ribs by four digitations, in the intervals between which are received corresponding processes of the External oblique; the fibres pass upward, outward, and backward, to be inserted into the anterior surface of the inferior angle of the scapula by an attachment partly muscular, partly tendinous.

RELATIONS.—This muscle is covered in front by the Pectoral muscles; behind, by the Subscapularis; above, by the axillary vessels and nerves. Its *deep surface* rests upon the ribs and Intercostal muscles.

NERVES.—The Serratus magnus is supplied by the posterior thoracic nerve.

ACTIONS.—The Serratus magnus, as a whole, carries the scapula forward and at the same time raises the vertebral border of the bone. It is therefore concerned in the action of pushing. Its lower and stronger fibres move forward the lower angle and assist the Trapezius in rotating the bone round an axis through its centre, and thus assists this muscle in raising the acromion and supporting weights upon the shoulder. It is possible that when the shoulders are fixed the lower fibres may assist in raising and everting the ribs, but it is not the important inspiratory muscle which it was formerly believed to be. [To show its slips of origin on the living model, let him simply lift the arm and breathe deeply; or, better, let him cross his arms behind the back and bend backward.]

Fig. 312.

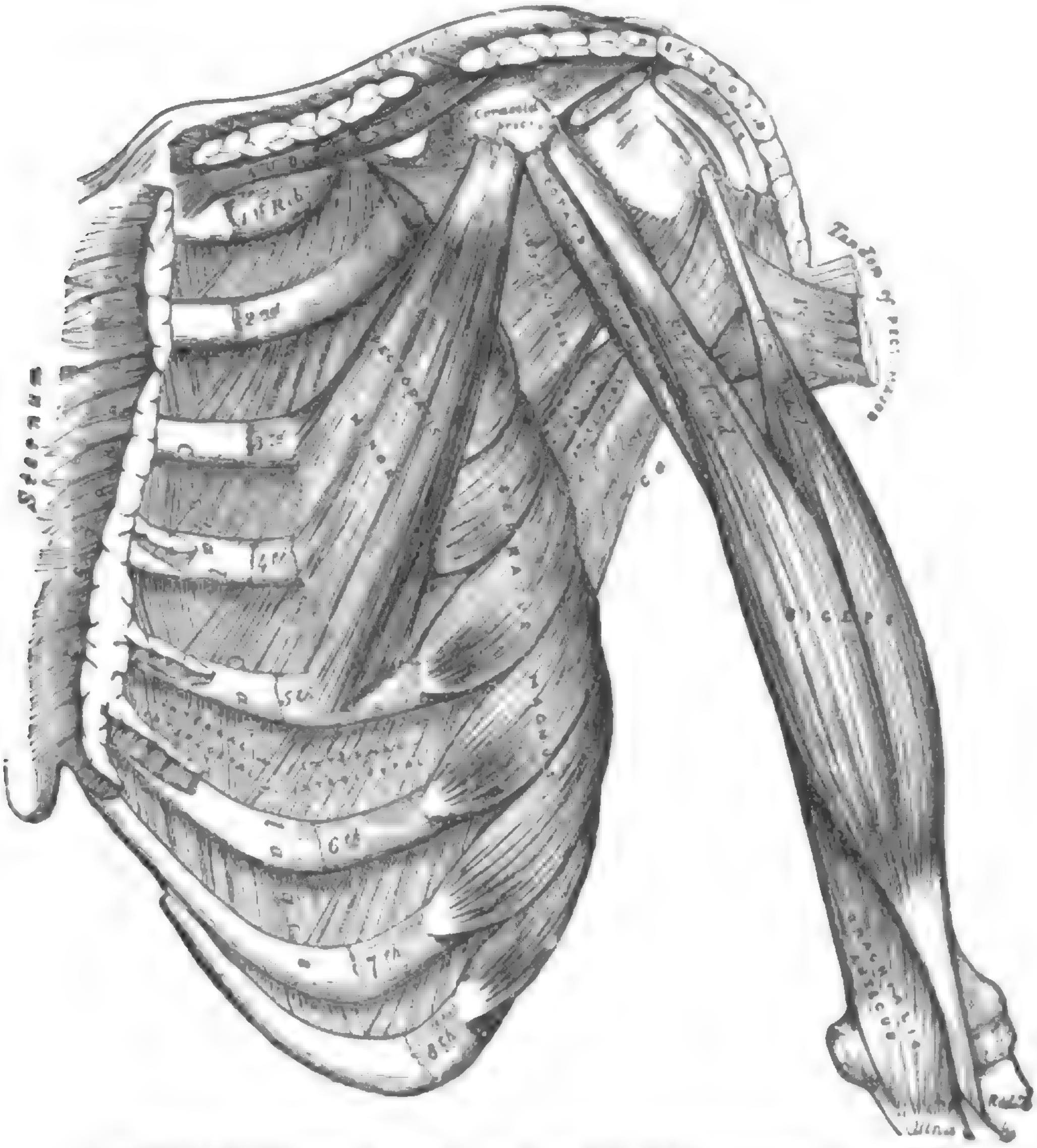

Muscles of the Chest and Front of the Arm, with the boundaries of the axilla.

Dissection.—After completing the dissection of the axilla, if the muscles of the back have been dissected the upper extremity should be separated from the trunk. Saw through the clavicle at its centre, and then cut through the muscles which connect the scapula and arm with the trunk—viz. the Pectoralis minor in front, Serratus magnus at the side, and the Levator anguli scapulæ, the Rhomboids, Trapezius, and Latissimus dorsi behind. These muscles should be cleaned and traced to their respective insertions. Then make an incision through the integument, commencing at the outer third of the clavicle and extending along the margin of that bone, the acromion process, and spine of the scapula; the integument should be dissected from above downward and outward, when the fascia covering the Deltoid is exposed (Fig. 310, No. 3).

The **Superficial Fascia** of the upper extremity is a thin cellulo-fibrous lamina containing between its layers the superficial veins and lymphatics and the cutaneous nerves. It is most distinct in front of the elbow, and contains very large superficial veins and nerves; in the hand it is hardly demonstrable, the integument being closely adherent to the deep fascia by dense fibrous bands. Small subcutaneous bursæ are found in this fascia, over the acromion, the olecranon, and the knuckles. The deep fascia of the upper extremity comprises the aponeurosis of the shoulder, arm, and forearm, the anterior and posterior annular ligaments of the carpus and the palmar fascia. These will be considered in the description of the muscles of the several regions.

ACROMIAL REGION.

Deltoid.

The **Deep Fascia** covering the Deltoid (deltoid aponeurosis) is a thick and strong fibrous layer which covers the outer surface of the muscle and sends down numerous prolongations between its fasciculi; it is continuous internally with the fascia covering the great Pectoral muscle; behind, with that covering the Infraspinatus and back of the arm: above, it is attached to the clavicle, the acromion, and spine of the scapula.

The **Deltoid** (Fig. 311) is a large, thick, triangular muscle which gives the rounded outline to the shoulder, and has received its name from its resemblance to the Greek letter Δ reversed. It surrounds the shoulder-joint in the greater part of its extent, covering it on its outer side and in front and behind. It arises from the outer third of the anterior border and upper surface of the clavicle, from the outer margin and upper surface of the acromion process, and from the whole length of the lower lip of the posterior border of the spine of the scapula. From this extensive origin the fibres converge toward their insertion, the middle passing vertically, the anterior obliquely backward, the posterior obliquely forward; they unite to form a thick tendon which is inserted into a rough prominence on the middle of the outer side of the shaft of the humerus. This muscle is remarkably coarse in texture, and the arrangement of its muscular fibres is somewhat peculiar: the central portion of the muscle—that is to say, the part arising from the acromion process—consists of oblique fibres which arise in a bipenniform manner from the sides of intramuscular aponeuroses or tendons, generally four in number, which are attached above to the acromion process and pass downward parallel to one another in the substance of the muscle. The oblique muscular fibres thus formed are inserted into similar tendinous insertions, generally three in number, which pass upward from the insertion of the muscle into the humerus and alternate with the descending septa. The lateral portions of the muscle—that is to say, the fibres arising from the clavicle and spine of the scapula—are not arranged in this manner, but consist of parallel fasciculi passing from their origin above to be inserted into the margins of the inferior tendon.

RELATIONS.—By its *superficial surface* with the integument, the superficial fascia, Platysma, and supra-acromial nerves. Its *deep surface* is separated from the head of the humerus by a large sacculated synovial bursa, and covers the coracoid process, coraco-acromial ligament, Pectoralis minor, Coraco-brachialis, both heads of the Biceps, tendon of the Pectoralis major, insertions of the Supraspinatus, Infraspinatus, and Teres minor, the scapular and external heads of the Triceps, the circumflex vessels and nerve, and the humerus. Its *anterior border* is separated from the Pectoralis major by a cellular interspace which lodges the cephalic vein and descending branch of the acromial thoracic artery. Its *posterior border* rests on the Infraspinatus and Triceps muscles.

NERVES.—The Deltoid is supplied by the circumflex nerve.

ACTIONS.—The Deltoid raises the arm directly from the side, so as to bring it at right angles with the trunk. Its anterior fibres, assisted by the Pectoralis major, draw the arm forward; and its posterior fibres, aided by the Teres major and Latissimus dorsi, draw it backward. [Show it on the model by resisting elevation of the arm directly outward, or by his lifting a heavy weight in the same direction. Its coarse texture in thin but muscular models is often thus well shown, even through the skin, and is a good illustration of this form of the structure of muscle. (See p. 362.) Its insertion is marked by a depression.]

Dissection.—Divide the Deltoid across near the upper part by an incision carried along the margin of the clavicle, the acromion process, and spine of the scapula, and reflect it downward: the bursa will be seen on its under surface, as well as the circumflex vessels and nerve. The insertion of the muscle should be carefully examined.

ANTERIOR SCAPULAR REGION.

Subscapularis.

The **Subscapular Fascia** is a thin membrane attached to the entire circumference of the subscapular fossa, and affording attachment by its inner surface to some of the fibres of the Subscapularis muscle: when this is removed the Subscapularis muscle is exposed.

The **Subscapularis** (Fig. 310) is a large triangular muscle which fills up the subscapular fossa, arising from its internal two-thirds, with the exception of a narrow margin along the posterior border and the surfaces at the superior and inferior angles which afford attachment to the Serratus magnus. Some fibres arise from tendinous laminæ which intersect the muscle and are attached to ridges on the bone, and others from an aponeurosis which separates the muscle from the Teres major and the long head of the Triceps. The fibres pass outward, and, gradually converging, terminate in a tendon which is inserted into the lesser tuberosity of the humerus. Those fibres which arise from the axillary border of the scapula are inserted into the neck of the humerus to the extent of an inch below the tuberosity. The tendon of the muscle is in close contact with the capsular ligament of the shoulder-joint, and glides over a large bursa which separates it from the base of the coracoid process. This bursa communicates with the cavity of the joint by an aperture in the capsular ligament.

RELATIONS.—By its *anterior surface* with the Serratus magnus, Coraco-brachialis, and Biceps, and the axillary vessels and nerves; by its *posterior surface* with the scapula, the subscapular vessels and nerves, and the capsular ligament of the shoulder-joint. Its *lower border* is contiguous with the Teres major and Latissimus dorsi.

NERVES.—It is supplied by the upper and lower subscapular nerves.

ACTIONS.—The Subscapularis rotates the head of the humerus inward; when the arm is raised it draws the humerus downward. It is a powerful defence to the front of the shoulder-joint, preventing displacement of the head of the bone forward.

POSTERIOR SCAPULAR REGION (Fig. 313).

Supraspinatus. Teres minor.
Infraspinatus. Teres major.

Dissection.—To expose these muscles, and to examine their mode of insertion into the humerus, detach the Deltoid and Trapezius from their attachment to the spine of the scapula and acromion process. Remove the clavicle by dividing the ligaments connecting it with the coracoid process, and separate it at its articulation with the scapula; divide the acromion process near its root with a saw. The fragments being removed, the tendons of the posterior Scapular muscles will be fully exposed, and can be examined. A block should be placed beneath the shoulder-joint, so as to make the muscles tense.

The **Supraspinous Fascia** is a thick and dense membranous layer, which completes the osseo-fibrous case in which the Supraspinatus muscle is contained, affording attachment by its inner surface to some of the fibres of the muscle. It is thick internally, but thinner externally under the coraco-acromial ligament. When this fascia is removed the Supraspinatus muscle is exposed.

The **Supraspinatus** muscle occupies the whole of the supraspinous fossa, arising from its internal two-thirds and from the strong fascia which covers its surface. The muscular fibres converge to a tendon which passes across the capsular ligament of the shoulder-joint, to which it is intimately adherent, and is inserted into the highest of the three facets on the great tuberosity of the humerus.

RELATIONS.—By its *upper surface* with the Trapezius, the clavicle, the acromion, the coraco-acromial ligament, and the Deltoid; by its *under surface* with the scapula, the suprascapular vessels and nerve, and upper part of the shoulder-joint.

The **Infraspinous Fascia** is a dense fibrous membrane covering in the Infraspinatus muscle, and attached to the circumference of the infraspinous fossa: it affords attachment by its inner surface to some fibres of that muscle. At the point where the infraspinatus ceases to be covered by the Deltoid this fascia gives off a strong process which divides into two to enclose the Deltoid muscle: one layer passes over the muscle forming the Deltoid fascia already described, the other passes beneath the deltoid to the shoulder-joint.

The **Infraspinatus** is a thick triangular muscle which occupies the chief part of the infraspinous fossa, arising by fleshy fibres from its internal two-thirds, and by tendinous fibres from the ridges on its surface: it also arises from a strong fascia which covers it externally and separates it from the Teres major and minor. The fibres converge to a tendon which glides over the external border of the spine of the scapula, and, passing across the capsular ligament of the shoulder-joint, is inserted into the middle facet on the great tuberosity of the humerus. The tendon of this muscle is occasionally separated from the spine of the scapula by a synovial bursa which communicates with the synovial membrane of the shoulder-joint.

FIG. 313.

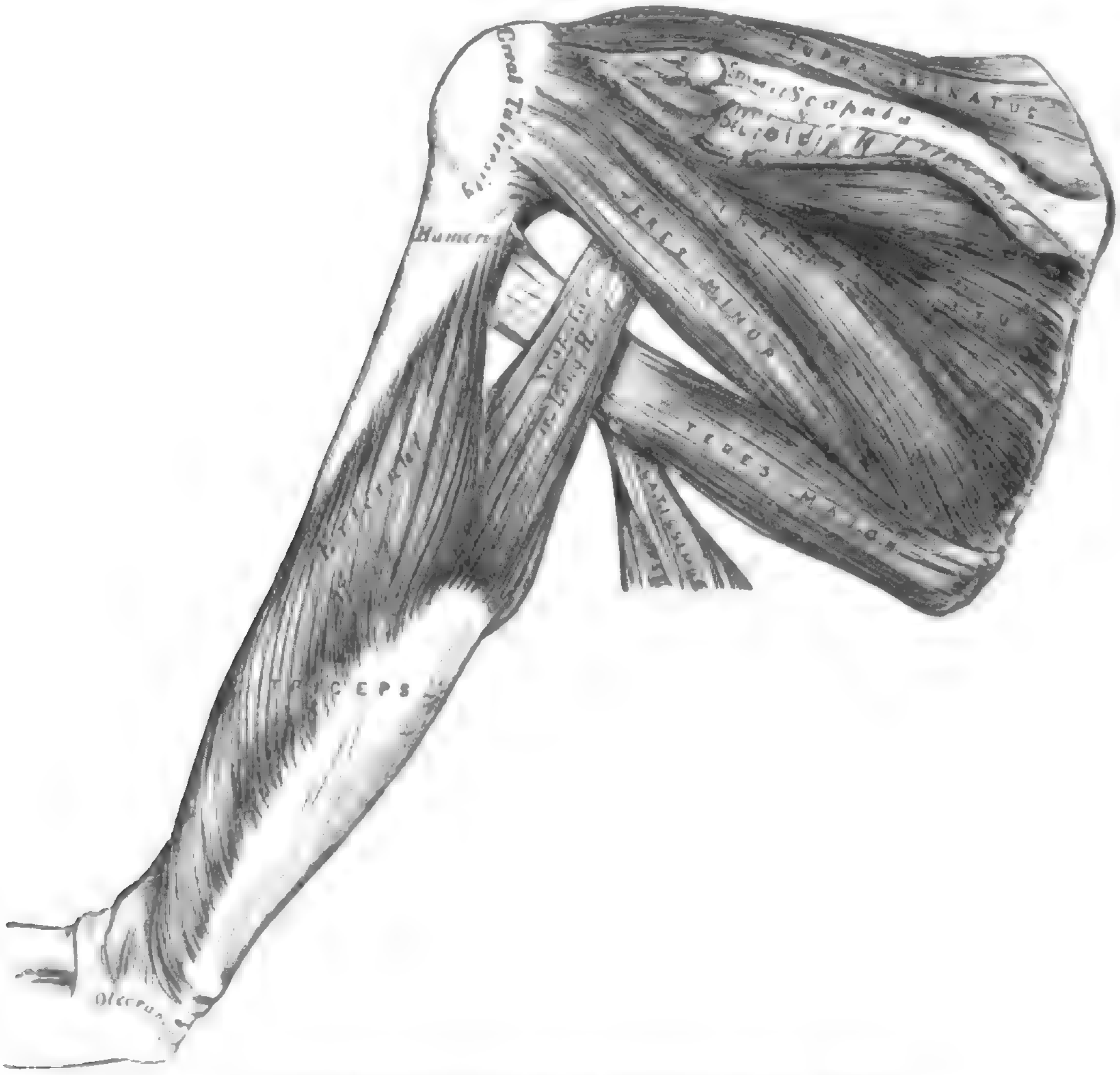

Muscles on the Dorsum of the Scapula and the Triceps.

RELATIONS.—By its *posterior surface* with the Deltoid, the Trapezius, Latissimus dorsi, and the integument; by its *anterior surface* with the scapula, from which it is separated by the suprascapular and dorsalis scapulæ vessels, and with the capsular ligament of the shoulder-joint. Its *lower border* is in contact with the Teres minor, and occasionally united with it, and with the Teres major.

The **Teres minor** is a narrow, elongated muscle which lies along the inferior border of the scapula. It arises from the dorsal surface of the axillary border of the scapula for the upper two-thirds of its extent, and from two aponeurotic laminæ, one of which separates this muscle from the Infraspinatus, the other from the Teres major; its fibres pass obliquely upward and outward, and terminate in a tendon which is inserted into the lowest of the three facets on the great tuberosity of the humerus, and by fleshy fibres into the humerus immediately below it. The tendon of this muscle passes across the capsular ligament of the shoulder-joint.

RELATIONS.—By its *posterior surface* with the Deltoid, the Latissimus dorsi, and the integument; by its *anterior surface* with the scapula, the dorsal branch of the subscapular artery, the long head of the Triceps, and the shoulder-joint; by its *upper border* with the Infraspinatus; by its *lower border* with the Teres major, from which it is separated anteriorly by the long head of the Triceps.

The **Teres major** is a broad and somewhat flattened muscle which arises from the dorsal aspect of the inferior angle of the scapula, from the fibrous septa interposed between it and the Teres minor and Infraspinatus; the fibres are directed upward and outward, and terminate in a flat tendon about two inches in length, which is inserted into the posterior bicipital ridge of the humerus. The tendon of this muscle at its insertion into the humerus lies behind that of the Latissimus dorsi, from which it is separated by a synovial bursa, the two tendons being, however, united along their lower borders for a short distance.

RELATIONS.—By its *posterior surface* with the integument, from which it is separated internally by the Latissimus dorsi, and externally by the long head of the Triceps; by its *anterior surface* with the Subscapularis, Latissimus dorsi, Coraco-brachialis, short head of the Biceps, the axillary vessels, and brachial plexus of nerves. Its *upper border* is at first in relation with the Teres minor, from which it is afterward separated by the long head of the Triceps. Its *lower border* forms, in conjunction with the Latissimus dorsi, part of the posterior boundary of the axilla.

NERVES.—The Supra- and Infra-spinatus muscles are supplied by the suprascapular nerve; the Teres minor, by the circumflex; and the Teres major, by the lower subscapular.

ACTIONS.—The Supraspinatus assists the Deltoid in raising the arm from the side, and fixes the head of the humerus in its socket. The Infraspinatus and Teres minor rotate the head of the humerus outward: when the arm is raised they assist in retaining it in that position and carrying it backward. One of the most important uses of these three muscles is the great protection they afford to the shoulder-joint, the Supraspinatus supporting it above and preventing displacement of the head of the humerus upward, whilst the Infraspinatus and Teres minor protect it behind and prevent dislocation backward. The Teres major assists the Latissimus dorsi in drawing the humerus downward and backward when previously raised, and rotating it inward: when the arm is fixed, it may assist the Pectoral and Latissimus dorsi muscles in drawing the trunk forward. [The Supra- and Infra-spinatus and Teres minor show rather obscurely on the model when elevation and external rotation of the arm are resisted. To show the Teres major excellently, let him hang by one arm from a ring, or with his hand to the belly and elbow to the side let him attempt external rotation of his arm while you resist it. Pressing down on an obstacle also shows it.]

ANTERIOR HUMERAL REGION (Fig. 312).

Coraco-brachialis. Biceps. Brachialis anticus.

Dissection.—The arm being placed on the table with the front surface uppermost, make a vertical incision through the integument along the middle line from the outer extremity of the anterior fold of the axilla to about two inches below the elbow-joint, where it should be joined by a transverse incision extending from the inner to the outer side of the forearm; the two flaps being reflected on either side, the fascia should be examined (Fig. 310).

The **Deep Fascia** of the arm, continuous with that covering the shoulder and front of the great Pectoral muscle, is attached above to the clavicle, acromion, and spine of the scapula; it forms a thin, loose, membranous sheath investing the muscles of the arm, sending down septa between them, and composed of fibres disposed in a circular or spiral direction and connected together by vertical and oblique fibres.

It differs in thickness at different parts, being thin over the Biceps, but thicker where it covers the Triceps and over the condyles of the humerus: it is strengthened by fibrous aponeuroses, derived from the Pectoralis major and Latissimus dorsi on the inner side, and from the Deltoid externally. On either side it gives off a strong *intermuscular septum* which is attached to the condyloid ridge and condyle of the humerus. These septa serve to separate the muscles of the anterior from those of the posterior brachial region. The external intermuscular septum extends from the lower part of the anterior bicipital ridge, along the external condyloid ridge, to the outer condyle; it is blended with the tendon of the Deltoid, gives attachment to the Triceps behind, to the Brachialis anticus, Supinator longus, and Extensor carpi radialis longior in front, and is perforated by the musculo-spiral nerve and superior profunda artery. The internal intermuscular septum, thicker than the preceding, extends from the lower part of the posterior lip of the bicipital groove below the Teres major, along the internal condyloid ridge to the inner condyle: it is blended with the tendon of the Coraco-brachialis, and affords attachment to the Triceps behind and the Brachialis anticus in front. It is perforated by the ulnar nerve and the inferior profunda and anastomotic arteries. At the elbow the deep fascia is attached to all the prominent points round the joint, and is continuous with the fascia of the forearm. On the removal of this fascia the muscles of the anterior humeral region are exposed.

The **Coraco-brachialis**, the smallest of the three muscles in this region, is situated at the upper and inner part of the arm. It arises by fleshy fibres from the apex of the coracoid process, in common with the short head of the Biceps, and from the intermuscular septum between the two muscles: the fibres pass downward, backward, and a little outward, to be inserted by means of a flat tendon into a rough ridge at the middle of the inner side of the shaft of the humerus between the origins of the Triceps and Brachialis anticus. It is perforated by the musculo-cutaneous nerve. The inner border of the muscle forms a guide to the position of the brachial artery in tying the vessel in the upper part of its course.

Relations.—By its *anterior surface* with the Deltoid and Pectoralis major above, and at its insertion with the brachial vessels and median nerve which cross it; by its *posterior* surface with the tendons of the Subscapularis, Latissimus dorsi, and Teres major, the short head of the Triceps, the humerus, and the anterior circumflex vessels; by its *inner border* with the brachial artery and the median and musculo-cutaneous nerves; by its *outer border* with the short head of the Biceps and Brachialis anticus.

The **Biceps [flexor cubiti]** is a long, fusiform muscle occupying the whole of the anterior surface of the arm, and divided above into two portions or heads, from which circumstance it has received its name. The short [or coracoid] head arises by a thick flattened tendon from the apex of the coracoid process, in common with the Coraco-brachialis. The long [or glenoid] head arises from the upper margin of the glenoid cavity by a long rounded tendon, which is continuous with the glenoid ligament. This tendon arches over the head of the humerus, being enclosed in a special sheath of the synovial membrane of the shoulder-joint; it then pierces the capsular ligament at its attachment to the humerus, and descends in the bicipital groove, in which it is retained by a fibrous prolongation from the tendon of the Pectoralis major. The fibres from this tendon form a rounded belly, and about the middle of the arm join with the portion of the muscle derived from the short head. The belly of the muscle, narrow and somewhat flattened, terminates above the elbow in a flattened tendon which is inserted into the back part of the tuberosity of the radius, a synovial bursa being interposed between the tendon and the front of the tuberosity. The tendon of the muscle is thin and broad; as it approaches the radius it becomes narrow and twisted upon itself, being applied by a flat surface to the back part of the tuberosity: opposite the bend of the elbow the tendon gives off from its inner side a broad aponeurosis, the *bicipital fascia* (*semilunar fascia*), which passes obliquely downward and inward across the brachial artery and is continuous with the fascia of the forearm (Fig. 311). The inner border of this muscle forms a guide to the position of the vessel in tying the brachial artery in the middle of the arm.[1]

Relations.—Its *anterior surface* is overlapped above by the Pectoralis major and Deltoid; in the rest of its extent it is covered by the superficial and deep fasciæ and the integument. Its *posterior surface* rests on the shoulder-joint and humerus, from which it is separated by the Subscapularis, Teres major, Latissimus dorsi, Brachialis anticus, and the musculo-cutaneous nerve. Its *inner border* is in relation with the Coraco-brachialis, the brachial vessels, and median nerve; its *outer border*, with the Deltoid and Supinator longus.

[Fig. 314.

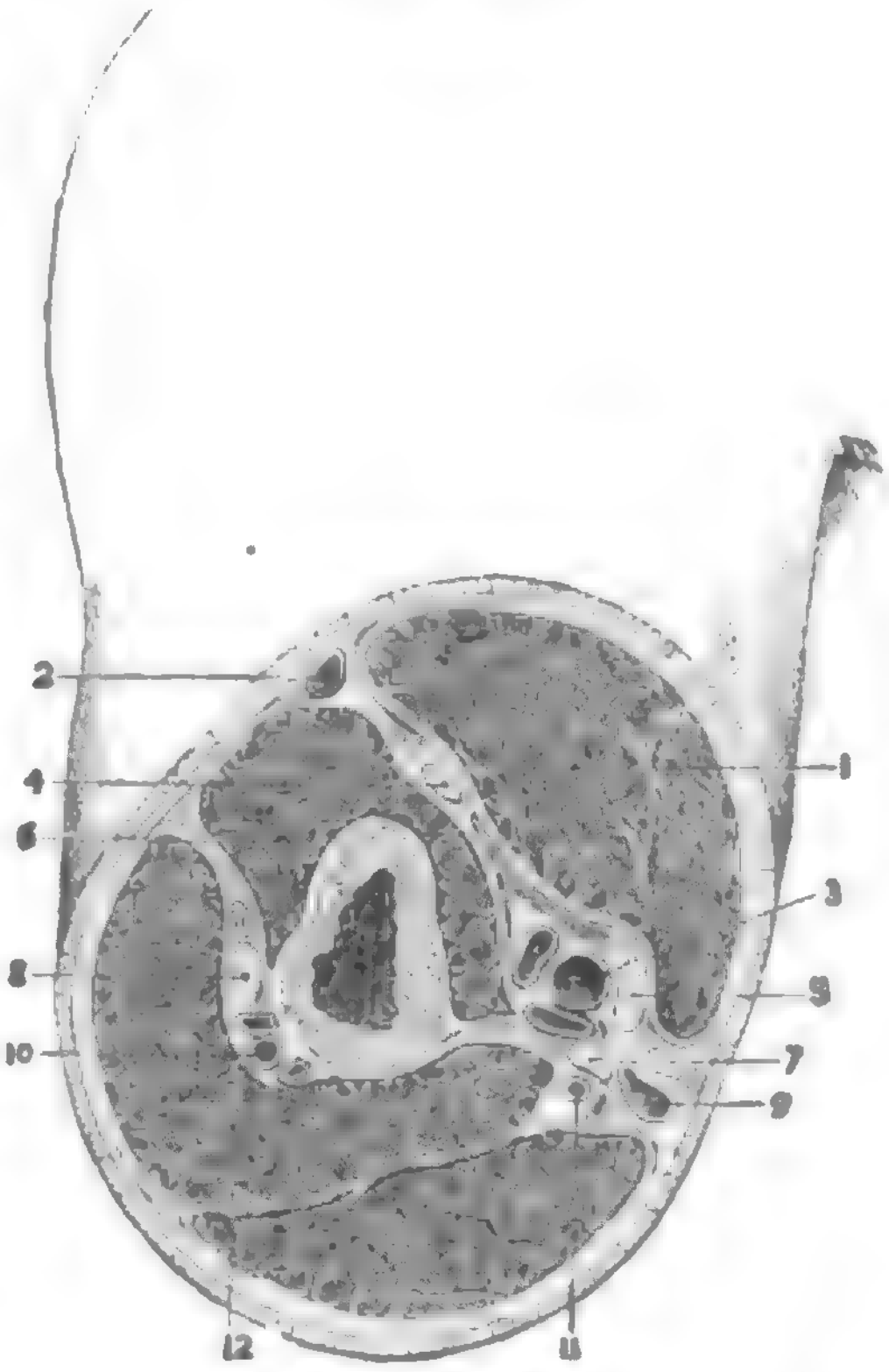

Section through the Middle of the Right Upper Arm (Heath, from Béraud): 1, biceps: 2, cephalic vein; 3, brachial vessels; 4, musculo-cutaneous nerve; 5, median nerve; 6, brachialis anticus; 7, ulnar nerve; 8, musculo-spiral nerve; 9, basilic vein with internal cutaneous nerves; 10, superior profunda vessels; 11, inferior profunda vessels; 12, triceps with intramuscular aponeurosis.]

The **Brachialis anticus** is a broad muscle which covers the elbow-joint and the lower half of the front of the humerus. It is somewhat compressed from before backward, and is broader in the middle than at either extremity. It arises from the lower half of the outer and inner surfaces of the shaft of the humerus, and commences above at the insertion of the Deltoid, which it embraces by two angular processes. Its origin extends below to within an inch of the margin of the articular surface, and is limited on each side by the external and internal borders of the shaft of the humerus. It also arises from the intermuscular septa on each side, but more extensively from the inner than the outer. Its fibres converge to a thick tendon, which is inserted into a rough depression on the anterior surface of the coronoid process of the ulna, being received into an interval between two fleshy slips of the Flexor digitorum profundus.

Relations.—By its *anterior surface* with the Biceps, the brachial vessels, musculo-cutaneous, and median nerves; by its *posterior surface* with the humerus and front of the elbow-joint; by its *inner border* with the Triceps, ulnar nerve, and Pronator radii teres, from which it is separated by the intermuscular septum; by its *outer border* with the musculo-spiral nerve, radial recurrent artery, the Supinator longus, and Extensor carpi radialis longior.

Nerves.—The muscles of this group are supplied by the musculo-cutaneous nerve. The Brachialis anticus usually receives an additional filament from the musculo-spiral.

Actions.—The Coraco-brachialis draws the humerus forward and inward, and at the same time assists in elevating it toward the scapula. The Biceps and Brachialis anticus are flexors of the forearm: the former muscle is also a supinator, and serves to render tense the fascia of the forearm by means of the broad aponeurosis given off from its tendon. When the forearm is fixed the Biceps and Brachialis anticus flex the arm upon the forearm, as is seen in efforts of climbing. The Brachialis anticus forms an important defence to the elbow-joint. [The Coraco-brachialis is well seen by resisting the model's folding his arms across the chest.

---

[1] A third head to the Biceps is occasionally found (Theile says as often as once in eight or nine subjects), arising at the upper and inner part of the Brachialis anticus, with the fibres of which it is continuous, and inserted into the bicipital fascia and inner side of the tendon of the Biceps. In most cases this additional slip passes behind the brachial artery in its course down the arm. Occasionally the third head consists of two slips, which pass down, one in front, the other behind the artery, concealing the vessel in the lower half of the arm.

The Biceps is shown by resisted flexion at the elbow or by lifting the body by seizing rings or a bar. Both when at rest and in action the triangular flat corresponding to its tendon should be observed. If the attempt be made to lift a heavy table, the arm being flexed at a right angle, the bicipital fascia will spring into relief, especially its crescentic internal border, and the finger can be thrust far under it. The Brachialis anticus, especially on the outside of the Biceps, shows by resisted flexion of the forearm.]

POSTERIOR HUMERAL REGION.

Triceps. Subanconeus.

The **Triceps [extensor cubiti]** (Fig. 313) is situated on the back of the arm, extending the entire length of the posterior surface of the humerus. It is of large size and divided above into three parts, hence its name. These three portions have been named—(1) the middle, scapular, or long head; (2) the external or long humeral; and (3) the internal or short humeral head.

The *middle* or *scapular head* arises by a flattened tendon from a rough triangular depression immediately below the glenoid cavity, being blended at its upper part with the capsular ligament; the muscular fibres pass downward between the two other portions of the muscle and join with them in the common tendon of insertion.

The *external head* arises from the posterior surface of the shaft of the humerus, between the insertion of the Teres minor and the upper part of the musculo-spiral groove, from the external border of the humerus and the external intermuscular septum: the fibres from this origin converge toward the common tendon of insertion.

The *internal head* arises from the posterior surface of the shaft of the humerus, below the groove for the musculo-spiral nerve, commencing above, narrow and pointed, below the insertion of the Teres major, and extending to within an inch of the trochlear surface: it also arises from the internal border of the humerus and internal intermuscular septum. The fibres of this portion of the muscle are directed, some downward to the olecranon, whilst others converge to the common tendon of insertion.

The *common tendon* of the Triceps commences about the middle of the back part of the muscle: it consists of two aponeurotic laminæ, one of which is subcutaneous and covers the posterior surface of the muscle for the lower half of its extent; the other is more deeply seated in the substance of the muscle: after receiving the attachment of the muscular fibres they join together above the elbow, and are inserted into the back part of the upper surface of the olecranon process, a small bursa, occasionally multilocular, being situated on the front part of this surface beneath the tendon.

The long head of the Triceps descends between the Teres minor and Teres major, dividing the triangular space between these two muscles and the humerus into two smaller spaces, one triangular, the other quadrangular (Fig. 313). The triangular space contains the dorsalis scapulæ vessels; it is bounded by the Teres minor above, the Teres major below, and the scapular head of the Triceps externally: the quadrangular space transmits the posterior circumflex vessels and nerve; it is bounded by the Teres minor above, the Teres major below, the scapular head of the Triceps internally, and the humerus externally.

RELATIONS.—By its *posterior surface* with the Deltoid above: in the rest of its extent it is subcutaneous; by its *anterior surface* with the humerus, musculo-spiral nerve, superior profunda vessels, and back part of the elbow-joint. Its *middle* or *long head* is in relation behind with the Deltoid and Teres minor; in front with the Subscapularis, Latissimus dorsi, and Teres major.

The **Subanconeus** is a small muscle distinct from the Triceps, and analogous to the Subcrureus in the lower limb. It may be exposed by removing the Triceps from the lower part of the humerus. It consists of one or two slender fasciculi which arise from the humerus immediately above the olecranon fossa, and are inserted into the posterior ligament of the elbow-joint.

NERVES.—The Triceps and Subanconeus are supplied by the musculo-spiral nerve.

ACTIONS.—The Triceps is the great Extensor muscle of the forearm, serving, when the forearm is flexed, to draw it into a right line with the arm. It is the direct antagonist of the Biceps and Brachialis anticus. When the arm is extended the long head of the muscle may assist the Teres major and Latissimus dorsi in drawing the humerus backward. The long head of the Triceps protects the under part of the shoulder-joint, and prevents displacement of the head of the humerus downward and backward. [Attempted over-extension of the forearm by the model well shows the Triceps. Notice especially the large roll of the external head. When at rest, but especially in action, the large flat corresponding to the tendon is well seen.]

MUSCLES OF THE FOREARM.

[The student should observe the difference between the shape of the arm and forearm. The arm in section is an oval flattened from side to side; the forearm, an oval flattened antero-posteriorly. The forearm on its internal border, in consequence of the structure of the Flexor carpi ulnaris, is one uniform curve from the internal condyle to the wrist; on its external border the curve begins well above the elbow over the Supinator longus, and at a considerable distance above the wrist terminates rather abruptly as a straight line, thus marking the transition from the muscular bellies of the radial group of muscles to their tendons.]

Dissection.—To dissect the forearm place the limb in the position indicated in Fig. 310; make a vertical incision along the middle line from the elbow to the wrist, and a transverse incision at each extremity of this: the flaps of integument being removed, the fascia of the forearm is exposed.

The **Deep Fascia** of the forearm, continuous above with that enclosing the arm, is a dense, highly glistening aponeurotic investment which forms a general sheath enclosing the muscles in this region; it is attached behind to the olecranon and posterior border of the ulna, and gives off from its inner surface numerous intermuscular septa which enclose each muscle separately. Below it is continuous in front with the anterior annular ligament, and forms a sheath for the tendon of the Palmaris longus muscle, which passes over the annular ligament to be inserted into the palmar fascia. Behind, near the wrist-joint, it becomes much thickened by the addition of many transverse fibres, and forms the posterior annular ligament. It consists of circular and oblique fibres connected together by numerous vertical fibres. It is much thicker on the dorsal than on the palmar surface, and at the lower than at the upper part of the forearm, and is strengthened by tendinous fibres derived from the Brachialis anticus and Biceps in front and from the Triceps behind. Its inner surface gives origin to muscular fibres, especially at the upper part of the inner and outer sides of the forearm, and forms the boundaries of a series of conical-shaped cavities in which the muscles are contained. Besides the vertical septa separating each muscle, transverse septa are given off both on the anterior and posterior surfaces of the forearm, separating the deep from the superficial layer of muscles. Numerous apertures exist in the fascia for the passage of vessels and nerves; one of these, of large size, situated at the front of the elbow, serves for the passage of a communicating branch between the superficial and deep veins.

The muscles of the forearm may be subdivided into groups corresponding to the region they occupy. One [the ulnar] group occupies the inner and anterior aspect of the forearm, and comprises the Flexor and Pronator muscles; another [the radial] group occupies its outer side; and a third [the posterior] its posterior aspect. The two latter groups include all the Extensor and Supinator muscles.

ANTERIOR BRACHIAL REGION.

Superficial Layer.

Pronator radii teres. Flexor carpi ulnaris.
Flexor carpi radialis. Flexor sublimis digitorum.
Palmaris longus.

These muscles take origin from the internal condyle of the humerus by a common tendon.

FIG. 315.

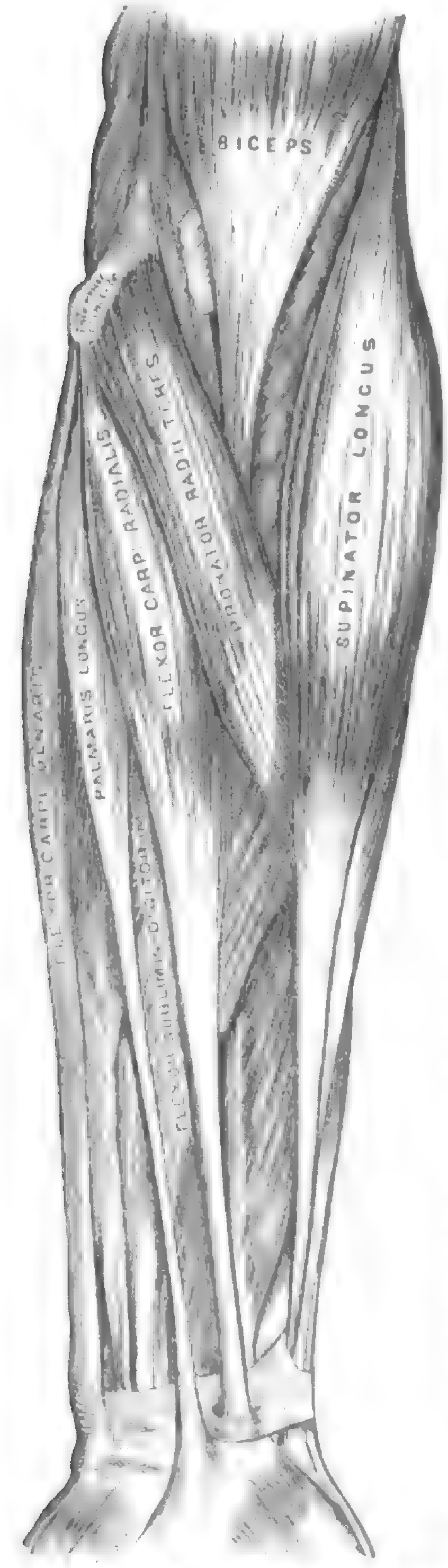

Front of the Left Forearm, superficial muscles.

The **Pronator radii teres** arises by two heads. One, the larger and more superficial, arises from the humerus immediately above the internal condyle, and from the tendon common to the origin of the other muscles; also from the fascia of the forearm and intermuscular septum between it and the Flexor carpi radialis. The other head is a thin fasciculus which arises from the inner side of the coronoid process of the ulna, joining the preceding at an acute angle. Between the two heads passes the median nerve. The muscle passes obliquely across the forearm from the inner to the outer side, and terminates in a flat tendon which turns over the outer margin of the radius and is inserted into a rough ridge at the middle of the outer surface of the shaft of that bone.

RELATIONS.—By its *anterior surface* with the deep fascia, the Supinator longus, and the radial vessels and nerve; by its *posterior surface* with the Brachialis anticus, Flexor sublimis digitorum, the median nerve, and ulnar artery, the small or deep head being interposed between the two latter structures. Its *outer border* forms the inner boundary of a triangular space in which is placed the brachial artery, median nerve, and tendon of the Biceps muscle. Its *inner border* is in contact with the Flexor carpi radialis.

The **Flexor carpi radialis** lies on the inner side of the preceding muscle. It arises from the internal condyle by the common tendon, from the fascia of the forearm, and from the intermuscular septa between it and the Pronator teres on the outside, the Palmaris longus internally, and the Flexor sublimis digitorum beneath. Slender and aponeurotic in structure at its commencement, it increases in size, and terminates in a tendon which forms the lower two-thirds of its length. This tendon passes through a canal on the outer side of the annular ligament, runs through a groove in the os trapezium (which is converted into a canal by a fibrous sheath and lined by a synovial membrane), and is inserted into the base of the metacarpal bone of the index finger. The radial artery lies between the tendon of this muscle and the Supinator longus, and may easily be tied in this situation.

RELATIONS.—By its *superficial surface* with the deep fascia and the integument; by its *deep surface* with the Flexor sublimis digitorum, Flexor longus pollicis, and wrist-joint; by its *outer border* with the Pronator radii teres and the radial vessels; by its *inner border* with the Palmaris longus above and the median nerve below.

The **Palmaris longus** is a slender, fusiform muscle lying on the inner side of the preceding. It arises from the inner condyle of the humerus by the common tendon, from the deep fascia and the intermuscular septa between it and the adjacent muscles. It terminates in a slender flattened tendon which passes over the annular ligament to end in the palmar fascia, frequently sending a tendinous slip to the short muscles of the thumb. This muscle is often absent.

Relations.—By its *superficial surface* with the deep fascia; by its *deep surface* with the Flexor digitorum sublimis; *internally* with the Flexor carpi ulnaris; *externally* with the Flexor carpi radialis. The median nerve lies close to the tendon just above the wrist, on its inner and posterior side.

The **Flexor carpi ulnaris** lies along the ulnar side of the forearm. It arises by two heads connected by a tendinous arch, beneath which pass the ulnar nerve and posterior ulnar recurrent artery. One head arises from the inner condyle of the humerus by the common tendon; the other, from the inner margin of the olecranon by an aponeurosis from the upper two-thirds of the posterior border of the ulna, in common with the Flexor profundus digitorum; and from the intermuscular septum between it and the Flexor sublimis digitorum. The fibres terminate in a tendon which occupies the anterior part of the lower half of the muscle, and is inserted into the pisiform bone, some fibres being prolonged to the annular ligament, to the unciform bone and base of the metacarpal bone of the little finger. The ulnar artery lies on the outer side of the tendon of this muscle, in the lower two-thirds of the forearm, the tendon forming a guide in tying the vessel in this situation.

Relations.—By its *superficial surface* with the deep fascia, with which it is intimately connected for a considerable extent; by its *deep surface* with the Flexor sublimis, the Flexor profundus, the Pronator quadratus, and the ulnar vessels and nerve; by its *outer* or *radial border* with the Palmaris longus above and the ulnar vessels and nerve below.

The **Flexor digitorum sublimis** (*perforatus*) is placed beneath the preceding muscles, which therefore must be removed in order to bring its attachment into view. It is the largest of the muscles of the superficial layer, and arises by three heads. One head arises from the internal condyle of the humerus by the common tendon, from the internal lateral ligament of the elbow-joint, and from the intermuscular septum common to it and the preceding muscles. The second head arises from the inner side of the coronoid process of the ulna, above the ulnar origin of the Pronator radii teres (Fig. 208, p. 244). The third head arises from the oblique line of the radius, extending from the tubercle to the insertion of the Pronator radii teres. The fibres pass vertically downward, forming a broad and thick muscle which divides into four tendons about the middle of the forearm; as these tendons pass beneath the annular ligament into the palm of the hand, they are arranged in pairs, the anterior pair corresponding to the middle and ring fingers, the posterior pair to the index and little fingers. The tendons diverge from one another as they pass onward, and are finally inserted into the lateral margins of the second phalanges about their middle. After leaving the palm [for the relation of the knuckle-joints and the palm, see p. 340] the tendons, accompanied by the deep flexor tendons, lie in osseo-aponeurotic canals formed by a strong fibrous band which arches across them and is attached on each side to the margins of the phalanges. Opposite the base of the first phalanges each tendon divides, so as to leave a fissured interval, through which passes one of the tendons of the Flexor profundus; the two portions of the tendon then unite and form a grooved channel into which the accompanying deep flexor tendon is received. Finally, they subdivide a second time, to be inserted into the sides of the second phalanges about their middle (Fig. 323). The tendons, whilst contained in the fibro-osseous canals, are connected to the phalanges by slender tendinous filaments, called *vincula accessoria tendinum*, and are invested by a synovial sheath.

Relations.—In the forearm, by its *superficial surface*, with the deep fascia and all the preceding superficial muscles; by its *deep surface* with the Flexor profundus digitorum, Flexor longus pollicis, the ulnar vessels and nerve, and the median nerve. In the hand its tendons are in relation, in *front*, with the palmar fascia, superficial palmar arch, and the branches of the median nerve; *behind* with the tendons of the deep flexor and the Lumbricales. [For the relations of the tendons to the palmar fascia and its prolongations, see p. 450.]

ANTERIOR BRACHIAL REGION.

Deep Layer.

Flexor profundus digitorum. Flexor longus pollicis.
Pronator quadratus.

Dissection.—Divide each of the superficial muscles at its centre [rather, at a different level for each muscle, so as to be able the better to identify them later], and turn either end aside; the deep layer of muscles, together with the median nerve and ulnar vessels, will then be exposed.

The **Flexor profundus digitorum (perforans)** (Fig. 317) is situated on the ulnar side of the forearm, immediately beneath the superficial Flexors. It arises from the upper two-thirds of the anterior and inner surfaces of the shaft of the ulna, embracing the insertion of the Brachialis anticus above, and extending below to within a short distance of the Pronator quadratus. It also arises from a depression on the inner side of the coronoid process; by an aponeurosis from the upper two-thirds of the posterior border of the ulna, in common with the Flexor carpi ulnaris; and from the ulnar half of the interosseous membrane. The fibres form a fleshy belly of considerable size which divides into four tendons: these pass under the annular ligament beneath the tendons of the Flexor sublimis. Opposite the first phalanges the tendons pass between the two slips of the tendons of the Flexor sublimis, and are finally inserted into the bases of the last phalanges. The tendon of the index finger is distinct; the rest are connected together by cellular tissue and tendinous slips as far as the palm of the hand. [If the fingers be placed on the posterior surface of the forearm to the inner side of the posterior border of the ulna, and the fingers of the arm that is grasped then be alternately flexed to make a fist and relaxed, the contraction of the muscular belly of this muscle can be well felt and appreciated.]

Four small muscles, the Lumbricales, are connected with the tendons of the Flexor profundus in the palm. They will be described with the muscles in that region.

RELATIONS.—By its *superficial surface*, in the forearm, with the Flexor sublimis digitorum, the Flexor carpi ulnaris, the ulnar vessels and nerve, and the median nerve, and in the hand with the tendons of the superficial Flexor; by its *deep surface*, in the forearm, with the ulna, the interosseous membrane, the Pronator quadratus, and in the hand with the Interossei, Adductor pollicis, and deep palmar arch; by its *ulnar border* with the Flexor carpi ulnaris; by its *radial border* with the Flexor longus pollicis, the anterior interosseous vessels and nerve being interposed.

The **Flexor longus pollicis** is situated on the radial side of the forearm, lying on the same plane as the preceding. It arises from the grooved anterior surface of the shaft of the radius, commencing above immediately below the tuberosity and oblique line, and extending below to within a short distance of the Pronator quadratus. It also arises from the adjacent part of the interosseous membrane, and occasionally by a fleshy slip from the base of the coronoid process. The fibres pass downward and terminate in a flattened tendon which, passing beneath the annular ligament, is then lodged in the interspace between the two heads of the Flexor brevis pollicis, and, entering an osseo-aponeurotic canal similar to those for the other flexor tendons, is inserted into the base of the last phalanx of the thumb.

RELATIONS.—By its *superficial surface* with the Flexor sublimis digitorum, Flexor carpi radialis, Supinator longus, and radial vessels; by its *deep surface* with the radius, interosseous membrane, and Pronator quadratus; by its *ulnar* *border* with the Flexor profundus digitorum, from which it is separated by the anterior interosseous vessels and nerve.

The **Pronator quadratus** is a small, flat, quadrilateral muscle extending transversely across the front of the radius and ulna above their carpal extremities. It arises from the oblique line on the lower fourth of the anterior surface of the shaft of the ulna and the surface of bone immediately below it; from the anterior border of the ulna; and from a strong aponeurosis which covers the inner third of the muscle. The fibres pass horizontally outward, to be inserted into the lower fourth of the anterior surface and external border of the shaft of the radius.

RELATIONS.—By its *superficial surface* with the Flexor profundus digitorum, the Flexor longus pollicis, Flexor carpi radialis, and the radial vessels; by its *deep surface* with the radius, ulna, and interosseous membrane.

NERVES.—All the muscles of the

[FIG. 316.

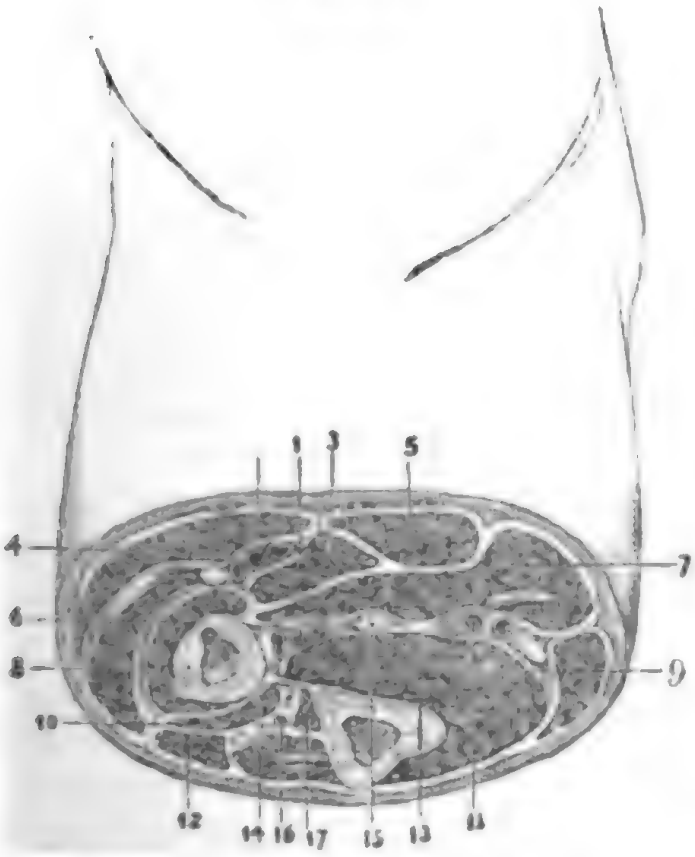
1
3
5
4
7
6
8
9
10
12
14
16
17
15
13
11

A Section through the Middle of the Right Forearm (Heath, altered from Béraud): 1, anterior interosseous vessels and nerve; 2, radial vessels and nerve; 3, Pronator teres; 4, Supinator longus; 5, Flexor carpi radialis; 6, Supinator brevis; 7, Flexor sublimis digitorum; 8, Extensores carpi radialis longior and brevior; 9, Flexor carpi ulnaris; 10, Extensor ossis metacarpi pollicis; 11, ulnar vessels and nerve; 12, Extensor communis digitorum; 13, Flexor profundus digitorum; 14, Extensor carpi ulnaris; 15, median nerve; 16, posterior interosseous vessels and nerve; 17, Extensor secundi internodii pollicis.]

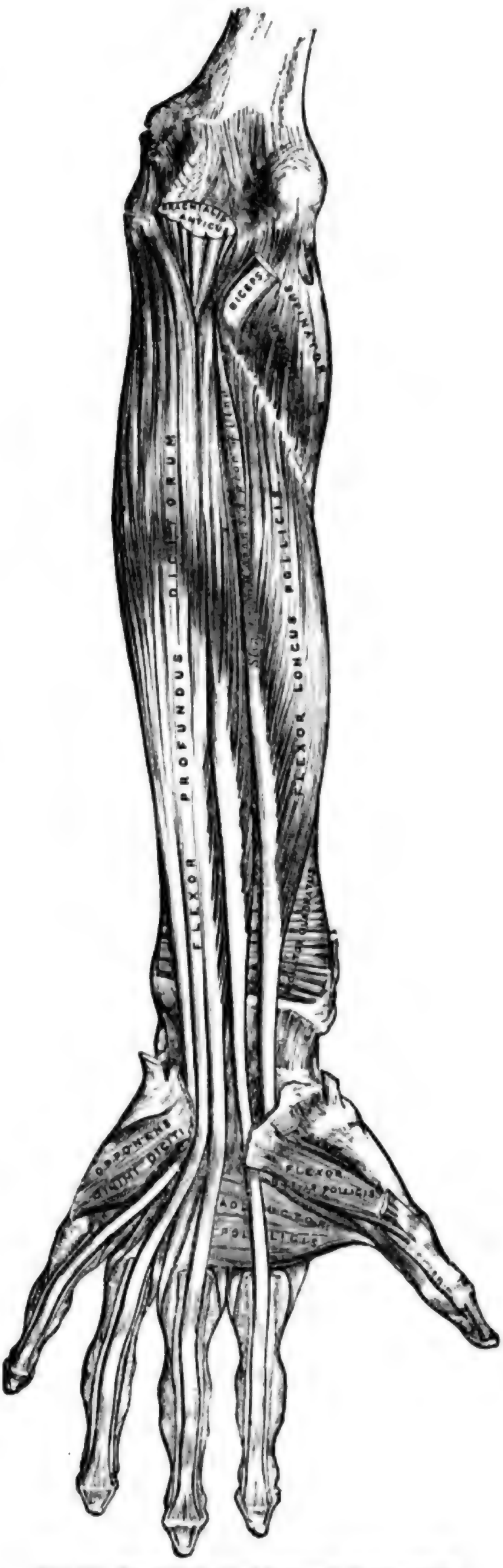
BRACHIALIS ANTICUS
BICEPS
SUPINATOR
FLEXOR PROFUNDUS DIGITORUM
FLEXOR LONGUS POLLICIS
QUADRATUS
OPPONENS MINIMI DIGITI
FLEXOR POLLICIS
ADDUCTOR POLLICIS

FIG. 317. Front of the Left Forearm, deep muscles.

superficial layer are supplied by the median nerve, excepting the Flexor carpi ulnaris, which is supplied by the ulnar. Of the deep layer, the Flexor profundus digitorum is supplied conjointly by the ulnar and by the median through its branch, the anterior interosseous nerve, which also supplies the Flexor longus pollicis and Pronator quadratus.

Actions.—These muscles act upon the forearm, the wrist, and hand. Those acting on the forearm are the Pronator radii teres and Pronator quadratus, which rotate the radius upon the ulna, rendering the hand prone; when pronation has been fully effected the Pronator radii teres assists the other muscles in flexing the forearm. The flexors of the wrist are the Flexor carpi ulnaris and radialis, and the flexors of the phalanges are the Flexor sublimis and profundus digitorum, the former flexing the second phalanges, and the latter the last. The Flexor longus pollicis flexes the last phalanx of the thumb. The three latter muscles, after flexing the phalanges, by continuing their action act upon the wrist, assisting the ordinary flexors of this joint; and all those which are attached to the humerus assist in flexing the forearm upon the arm. The Palmaris longus is a tensor of the palmar fascia; when this action has been fully effected it flexes the hand upon the forearm. [The bellies of these muscles cannot be well shown separately in the model, though the student should observe the influence of making a fist and of flexion of each finger on the flexor mass. At the wrist resisted flexion will show to the eye and touch, in the middle, the narrow prominent tendon of the Palmaris longus; to its radial side, that of the Flexor carpi radialis. Far to the ulnar side the tendon of the Flexor carpi ulnaris is well felt in tension when the wrist is flexed and carried to the ulnar border. Between the tendons of the Flexor ulnaris and Palmaris longus lie the tendons of the finger-flexors, which cannot be made to spring into relief because of the anterior annular ligament (see Fig. 315), but on flexing and extending the fingers they can be easily felt.

Of course these muscles, when the hand is fixed, act upon the forearm, and even upon the arm, but this is much less marked than is the similar reversed action from below of the muscles of the foot.]

Radial Region (Fig. 318).

Supinator longus. Extensor carpi radialis longior.
Extensor carpi radialis brevior.

Dissection.—Divide the integument in the same manner as in the dissection of the anterior brachial region, and after having examined the cutaneous vessels and nerves and deep fascia, remove all those structures. The muscles will then be exposed. The removal of the fascia will be considerably facilitated by detaching it from below upward. Great care should be taken to avoid cutting across the tendons of the muscles of the thumb, which cross obliquely the larger tendons running down the back of the radius.

The **Supinator longus** is the most superficial muscle on the radial side of the forearm: it is fleshy for the upper two-thirds of its extent, tendinous below. It arises from the upper two-thirds of the external condyloid ridge of the humerus and from the external intermuscular septum, being limited above by the musculo-spiral groove. The fibres terminate above the middle of the forearm in a flat tendon which is inserted into the outer side of the base of the styloid process of the radius. [The belly of this muscle at its origin is ribbon-like, its edge being turned externally, but soon it rotates to about a right angle with its first position, thus producing the graceful rounding of the arm over the radial border of the elbow.]

Relations.—By its *superficial surface* with the integument and fascia for the greater part of its extent: near its insertion it is crossed by the Extensor ossis metacarpi pollicis and the Extensor primi internodii pollicis; by its *deep surface* with the humerus, the Extensor carpi radialis longior and brevior, the insertion of the Pronator radii teres, and the Supinator brevis; by its *inner border* above the elbow with the Brachialis anticus, the musculo-spiral nerve, and radial recurrent artery, and in the forearm with the radial vessels and nerve.

The **Extensor carpi radialis longior** is placed partly beneath the preceding muscle. It arises from the lower third of the external condyloid ridge of the humerus, and from the external intermuscular septum. The fibres terminate at the upper third of the forearm in a flat tendon which runs along the outer border of the radius, beneath the extensor tendons of the thumb; it then passes through a groove common to it and the Extensor carpi radialis brevior immediately behind the styloid process, and is inserted into the base of the metacarpal bone of the index finger on its radial side.

Relations.—By its *superficial surface* with the Supinator longus and fascia of the forearm; its *outer side* is crossed obliquely by the extensor tendons of the thumb; by its *deep surface* with the elbow-joint, the Extensor carpi radialis brevior, and back part of the wrist.

The **Extensor carpi radialis brevior** is shorter, as its name implies, and thicker than the preceding muscle, beneath which it is placed. It arises from the external condyle of the humerus by a tendon common to it and the three following muscles; from the external lateral ligament of the elbow-joint; from a strong aponeurosis which covers its surface; and from the intermuscular septa between it and the adjacent muscles. The fibres terminate about the middle of the forearm in a flat tendon which is closely connected with that of the preceding muscle, accompanies it to the wrist, lying in the same groove on the posterior surface of the radius; passes beneath the annular ligament, and, diverging somewhat from its fellow, is inserted into the base of the metacarpal bone of the middle finger on its radial side.

The tendons of the two preceding muscles pass through the same compartment of the annular ligament, and are lubricated by a single synovial membrane, but are separated from each other by a small vertical ridge of bone as they lie in the groove at the back of the radius. [On forcibly extending the hand these tendons can be readily felt just to the ulnar side of the Extensor secundi internodii pollicis (Fig. 318), and, if the motion is resisted, be seen.]

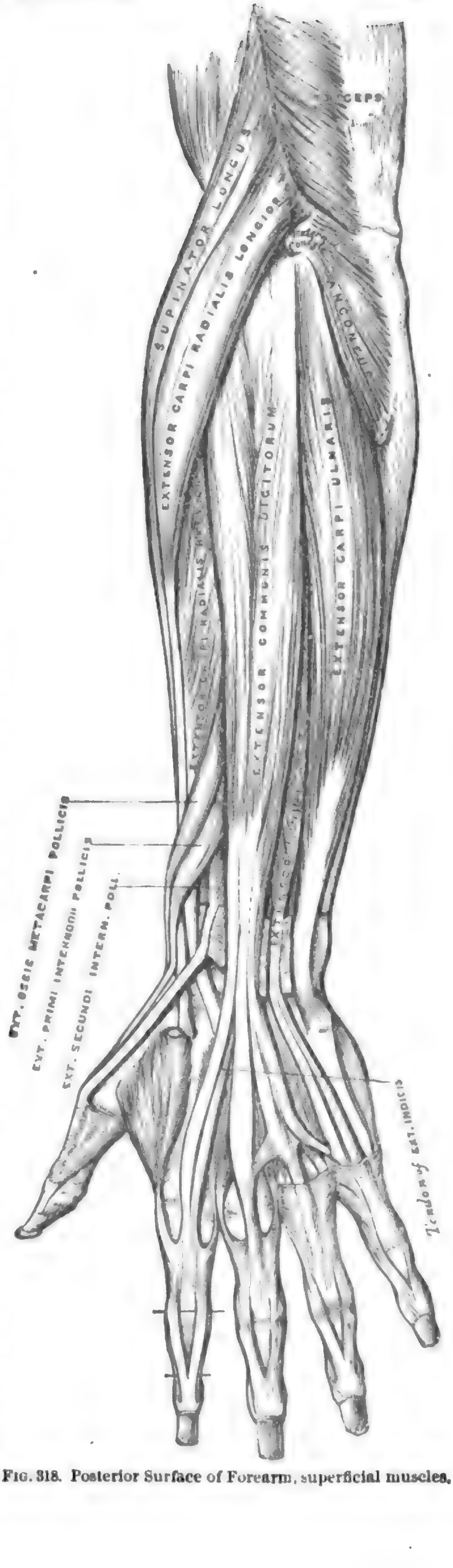
TRICEPS
SUPINATOR LONGUS
EXTENSOR CARPI RADIALIS LONGIOR
ANCONEUS
EXTENSOR CARPI ULNARIS
EXTENSOR COMMUNIS DIGITORUM
EXTENSOR CARPI RADIALIS BREVIOR
EXT. OSSIS METACARPI POLLICIS
EXT. PRIMI INTERNODII POLLICIS
EXT. SECUNDI INTERN. POLL.
Tendon of EXT. INDICIS

Fig. 318. Posterior Surface of Forearm, superficial muscles.

RELATIONS.—By its *superficial surface* with the Extensor carpi radialis longior and with the Extensor muscles of the thumb, which cross it; by its *deep surface* with the Supinator brevis, tendon of the Pronator radii teres, radius, and wrist-joint; by its *ulnar border* with the Extensor communis digitorum.

POSTERIOR BRACHIAL REGION (Fig. 318).

Superficial Layer.

Extensor communis digitorum.	Extensor carpi ulnaris.
Extensor minimi digiti.	Anconeus.

The **Extensor communis digitorum** is situated at the back part of the forearm. It arises from the external condyle of the humerus by the common tendon, from the deep fascia, and the intermuscular septa between it and the adjacent muscles. Just below the middle of the forearm it divides into three tendons, which pass, together with the Extensor indicis, through a separate compartment of the annular ligament, lubricated by a synovial membrane. The tendons then diverge, the innermost one dividing into two; and all, after passing across the back of the hand, are inserted into the second and third phalanges of the fingers in the following manner: each tendon becomes narrow and thickened opposite the metacarpo-phalangeal articulation, and gives off a thin fasciculus upon each side of the joint which serves as the posterior ligament; after having passed the joint it spreads out into a broad aponeurosis which covers the whole of the dorsal surface of the first phalanx, being reinforced in this situation by the tendons of the Interossei and Lumbricales. [Fig. 324, p. 456.] Opposite the first phalangeal joint this aponeurosis divides into three slips, a middle and two lateral: the former is inserted into the base of the second phalanx, and the two lateral, which are continued onward along the sides of the second phalanx, unite by their contiguous margins and are inserted into the dorsal surface of the last phalanx. As the tendons cross the phalangeal joints they furnish them with posterior ligaments. The tendons of the middle, ring, and little fingers are connected together, as they cross the hand, by small oblique tendinous slips, or *vinculæ;* those on each side of the ring finger are strong, and bind the tendon of this finger closely to those of the middle and little finger, so that it cannot, in general, be freely extended without moving the other two. There is also sometimes a thin slip between the tendons of the index and middle fingers. The tendons of the index and little fingers also receive, before their division, the special extensor tendons belonging to them. [The tendons of this muscle are easily seen on the back of the hand.]

RELATIONS.—By its *superficial surface* with the fascia of the forearm and hand, the posterior annular ligament, and integument; by its *deep surface* with the Supinator brevis, the Extensor muscles of the thumb and index finger, the posterior interosseous vessels and nerve, the wrist-joint, carpus, metacarpus, and phalanges; by its *radial border* with the Extensor carpi radialis brevior; by its *ulnar border* with the Extensor minimi digiti and Extensor carpi ulnaris.

The **Extensor minimi digiti** is a slender muscle placed on the inner side of the Extensor communis, with which it is generally connected. It arises from the common tendon by a thin tendinous slip, and from the intermuscular septa between it and the adjacent muscles. Its tendon runs through a separate compartment in the annular ligament behind the inferior radio-ulnar joint, then divides into two as it crosses the hand, one slip being united to the common extensor by a cross-piece at the metacarpo-phalangeal articulation. Both finally spread into a broad aponeurosis which blends with the common extensor to the finger and is inserted into the second and third phalanges. The tendon is situated on the ulnar side, and somewhat more superficial than the common extensor.

The **Extensor carpi ulnaris** is the most superficial muscle on the ulnar side of the forearm. It arises from the external condyle of the humerus by the common tendon, from the middle third of the posterior border of the ulna below the Anconeus, and from the fascia of the forearm. This muscle terminates in a tendon which runs through a groove behind the styloid process of the ulna, passes through a separate compartment in the annular ligament, and is inserted into the ulnar side of the base of the metacarpal bone of the little finger. [Its tendon can always be felt by making strong ulnar extension of the hand.]

RELATIONS.—By its *superficial surface* with the fascia of the forearm; by its *deep surface* with the ulna and the muscles of the deep layer.

The **Anconeus** is a small triangular muscle placed behind and below the elbow-joint, and appears to be a continuation of the external portion of the Triceps. It arises by a separate tendon from the back part of the outer condyle of the humerus, and is inserted into the side of the olecranon and upper fourth of the posterior surface of the shaft of the ulna; its fibres diverge from their origin, the upper ones being directed transversely, the lower obliquely inward.

RELATIONS.—By its *superficial surface* with a strong fascia derived from the Triceps; by its *deep surface* with the elbow-joint, the orbicular ligament, the ulna, and a small portion of the Supinator brevis.

POSTERIOR BRACHIAL REGION (Fig. 319).

Deep Layer.

Supinator brevis.
Extensor ossis metacarpi pollicis.
Extensor primi internodii pollicis.
Extensor secundi internodii pollicis.
Extensor indicis.

The **Supinator brevis** is a broad muscle, of a hollow, cylindrical form, curved round the upper third of the radius. It arises from the external condyle of the humerus, from the external lateral ligament of the elbow-joint and the orbicular ligament of the radius, from the ridge on the ulna which runs obliquely downward from the posterior extremity of the lesser sigmoid cavity, from the triangular depression in front of it, and from a tendinous expansion which covers the surface of the muscle. The muscle surrounds the upper part of the radius, the upper fibres forming a sling-like fasciculus which encircles the neck of the radius above the tuberosity and is attached to the back part of its inner surface; the middle fibres are attached to the outer edge of the bicipital tuberosity; the lower fibres to the oblique line of the radius as low down as the insertion of the Pronator radii teres. This muscle is pierced by the posterior interosseous nerve.

RELATIONS.—By its *superficial surface* with the superficial Extensor and Supinator muscles and the radial vessels and nerve; by its *deep surface* with the elbow-joint, the interosseous membrane, and the radius.

The **Extensor ossis metacarpi pollicis** is the most external and the largest of the deep Extensor muscles: it lies immediately below the Supinator brevis, with which it is sometimes united. It arises from the posterior surface of the shaft of the ulna below the insertion of the Anconeus, from the interosseous ligament, and from the middle third of the posterior surface of the shaft of the radius. Passing obliquely downward and outward, it terminates in a tendon which runs through a groove on the outer side of the styloid process of the radius, accompanied by the tendon of the Extensor primi internodii pollicis, and is inserted into the base of the metacarpal bone of the thumb.

RELATIONS.—By its *superficial surface* with the Extensor communis digitorum, Extensor minimi digiti, and fascia of the forearm, and with the branches of the posterior interosseous artery and nerve which cross it; by its *deep surface* with the ulna, interosseous membrane, radius, the tendons of the Extensor carpi radialis longior and brevior, which it crosses obliquely, and at the outer side of the wrist with the radial vessels; by its *upper border* with the Supinator brevis; by its *lower border* with the Extensor primi internodii pollicis.

The **Extensor primi internodii pollicis**, the smallest muscle of this group, lies on the inner side of the preceding. It arises from the posterior surface of the shaft of the radius, below the Extensor ossis metacarpi, and from the interosseous membrane. Its direction is similar to that of the Extensor ossis metacarpi, its tendon passing through the same groove on the outer side of the styloid process, to be inserted into the base of the first phalanx of the thumb.

Fig. 319.

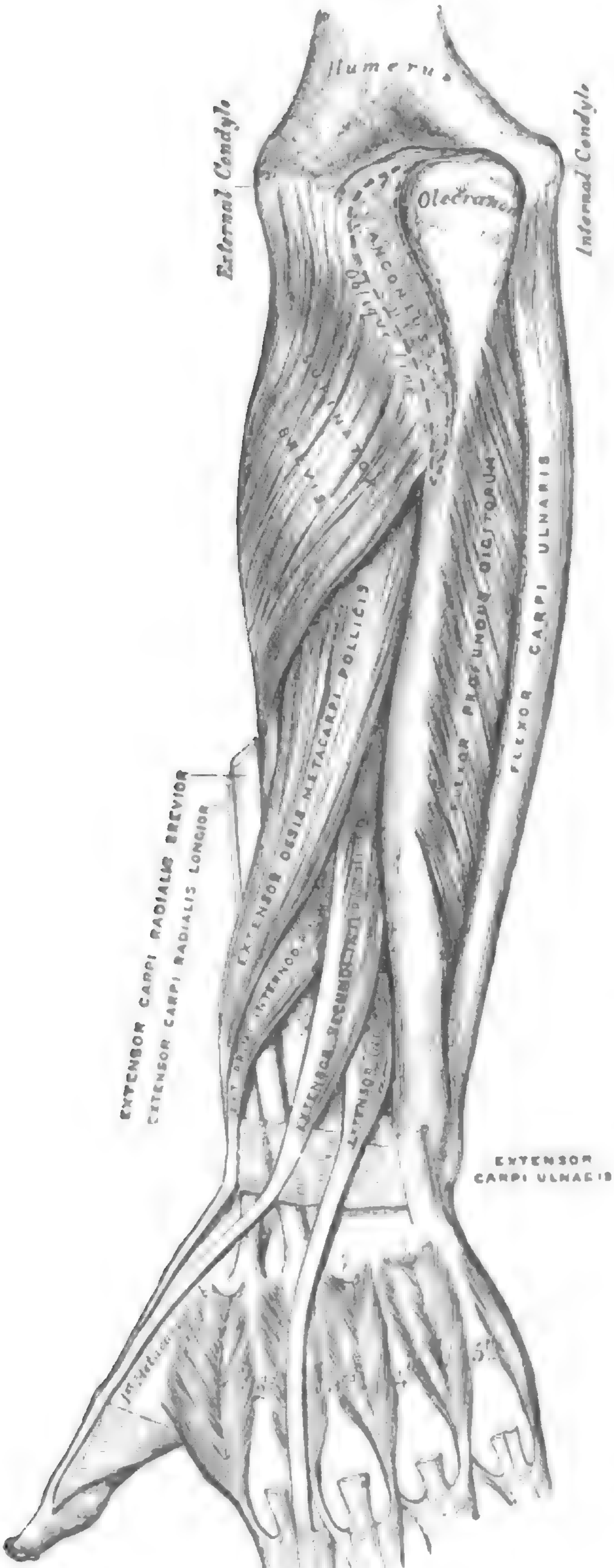
Humerus
External Condyle
Internal Condyle
Olecranon
ANCONEUS
FLEXOR CARPI ULNARIS
FLEXOR PROFUNDUS DIGITORUM
EXTENSOR OSSIS METACARPI POLLICIS
EXTENSOR CARPI RADIALIS BREVIOR
EXTENSOR CARPI RADIALIS LONGIOR
EXTENSOR SECUNDI
EXTENSOR
EXTENSOR CARPI ULNARIS
5th

Posterior Surface of the Forearm, deep muscles.

Relations.—The same as those of the Extensor ossis metacarpi pollicis.

The **Extensor secundi internodii pollicis** is much larger than the preceding muscle, the origin of which it partly covers in. It arises from the posterior surface of the shaft of the ulna, below the origin of the Extensor ossis metacarpi pollicis, and from the interosseous membrane. It terminates in a tendon which passes through a separate compartment in the annular ligament lying in a narrow oblique groove at the back part of the lower end of the radius. It then crosses obliquely the Extensor tendons of the carpus, being separated from the other Extensor tendons of the thumb by a triangular interval in which the radial artery is found; and is finally inserted into the base of the last phalanx of the thumb.

[The tendons of these three muscles are readily seen at the wrist on forcibly extending the thumb, the cord next the ulna being the Extensor secundi internodii; that on the radial border is the other two tendons, the styloid process of the radius being between the two cords.]

Relations.—By its *superficial surface* with the same parts as the Extensor ossis metacarpi pollicis; by its *deep surface* with the ulna, interosseous membrane, radius, the wrist, the radial vessels, and metacarpal bone of the thumb.

The **Extensor indicis** is a narrow, elongated muscle placed on the inner side of, and parallel with, the preceding. It arises from the posterior surface of the shaft of the ulna, below the origin of the Extensor secundi internodii pollicis, and from the interosseous membrane. Its tendon passes with the Extensor communis digitorum through the same canal in the annular ligament, and subsequently joins the tendon of the Extensor communis which belongs to the index finger, opposite the lower end of the corresponding metacarpal bone, lying to the ulnar side of the tendon from the common Extensor. It is finally inserted into the second and third phalanges of the index finger in the manner always described.

RELATIONS.—They are similar to those of the preceding muscles.

NERVES.—The Supinator longus, Extensor carpi radialis longior, and Anconeus are supplied by branches from the musculo-spiral nerve: the remaining muscles of the radial and posterior brachial regions by the posterior interosseous nerve.

ACTIONS.—The muscles of the radial and posterior brachial regions, which comprise all the Extensor and Supinator muscles, act upon the forearm, wrist, and hand; they are the direct antagonists of the Pronator and Flexor muscles. The Anconeus assists the Triceps in extending the forearm. The Supinator longus and brevis are the supinators of the forearm and hand, the former muscle more especially acting as a supinator when the limb is pronated. When supination has been produced, the Supinator longus, if still continuing to act, flexes the forearm. [In fact, flexion is its most marked and most important action. Its more advantageous leverage gives it three times the proportionate flexor power compared with the Biceps (Wight).] The Extensor carpi radialis longior and brevior and Extensor carpi ulnaris muscles are the extensors of the wrist; continuing their action, they serve to extend the forearm upon the arm; they are the direct antagonists of the Flexor carpi radialis and ulnaris. The common Extensor of the fingers, the Extensors of the thumb, and the Extensors of the index and little fingers serve to extend the phalanges into which they are inserted, and are the direct antagonists of the Flexors. [For the correct view of the action of the Extensors and Flexors see remarks on the action of the Interossei, p. 457.] By continuing their action they assist in extending the forearm. The Extensors of the thumb, in consequence of the oblique direction of their tendons, assist in supinating the forearm when the thumb has been drawn inward toward the palm [when it is most needed, as in using a screw-driver. These muscles also act from below upward, assisting in various movements, especially of the forearm, when the hand is fixed.

The Supinator longus is best shown by endeavoring to lift a heavy table, the forearm being flexed at a right angle, supination being at the same time attempted. The Anconeus shows well on extreme extension of the forearm.]

MUSCLES AND FASCIÆ OF THE HAND.

Dissection (Fig. 310).—Make a transverse incision across the front of the wrist, and a second across the heads of the metacarpal bones: connect the two by a vertical incision in the middle line, and continue it through the centre of the middle finger. The anterior and posterior annular ligaments and the palmar fascia should then be dissected.

The **Anterior Annular Ligament** is a strong fibrous band which arches over the carpus, converting the deep groove on the front of the carpal bones into a canal, beneath which pass the flexor tendons of the fingers. It is attached internally to the pisiform bone and unciform process of the unciform bone, and externally to the tuberosity of the scaphoid and to the inner part of the anterior surface and the ridge on the trapezium. It is continuous above with the deep fascia of the forearm, and below with the palmar fascia. It is crossed by the ulnar vessels and nerve and the cutaneous branches of the median and ulnar nerves. At its outer extremity is the tendon of the Flexor carpi radialis, which lies in the groove on the trapezium between the attachments of the annular ligament to the bone. It has inserted into its upper and inner part the tendon of the Palmaris longus and part of the tendon of the Flexor carpi ulnaris, and has arising from it below the small muscles of the thumb and little finger. Beneath it pass the tendons of the Flexor sublimis and profundus digitorum, the Flexor longus pollicis, and the median nerve. One large synovial membrane encloses all these tendons as they pass beneath this ligament. It surrounds the tendons for some distance in the forearm, and also in the palm of the hand. It presents two prolongations: one is continuous with the sheath of the tendon of the Flexor longus pollicis, the other with that of the little finger. [This extension of the synovial sheath on to these two fingers makes felons or other phlegmonous inflammations very important, since from these fingers the suppuration may readily extend into the palm, and even far up the forearm, by passing under the anterior annular ligament, whereas it is shut off from the palm on the other fingers.]

The **Posterior Annular Ligament** is a strong fibrous band extending transversely across the back of the wrist, and consisting of the deep fascia of the back of the forearm, strengthened by the addition of some transverse fibres. It forms a sheath for the extensor tendons in their passage to the fingers, being attached internally to the ulna, the cuneiform and pisiform bones, and palmar fascia; externally, to the margin of the radius, and, in its passage across the wrist, to the elevated ridges on the posterior surface of the radius. It presents six compartments for the passage of tendons, each of which is lined by a separate synovial membrane. These are, from without inward—1, On the outer side of the styloid process for the tendons of the Extensor ossis metacarpi and Extensor primi internodii pollicis; 2, behind the styloid process for the tendons of the Extensor carpi radialis longior and brevior; 3, opposite the outer side of the posterior surface of the radius for the tendon of the Extensor secundi internodii pollicis; 4, to the inner side of the latter for the tendons of the Extensor communis digitorum and Extensor indicis; 5, for the Extensor minimi digiti opposite the interval between the radius and ulna; 6, for the tendon of the Extensor carpi ulnaris grooving the back of the ulna. The synovial membranes lining these sheaths are usually very extensive, reaching from above the annular ligament down upon the tendons almost to their insertion.

FIG. 320.

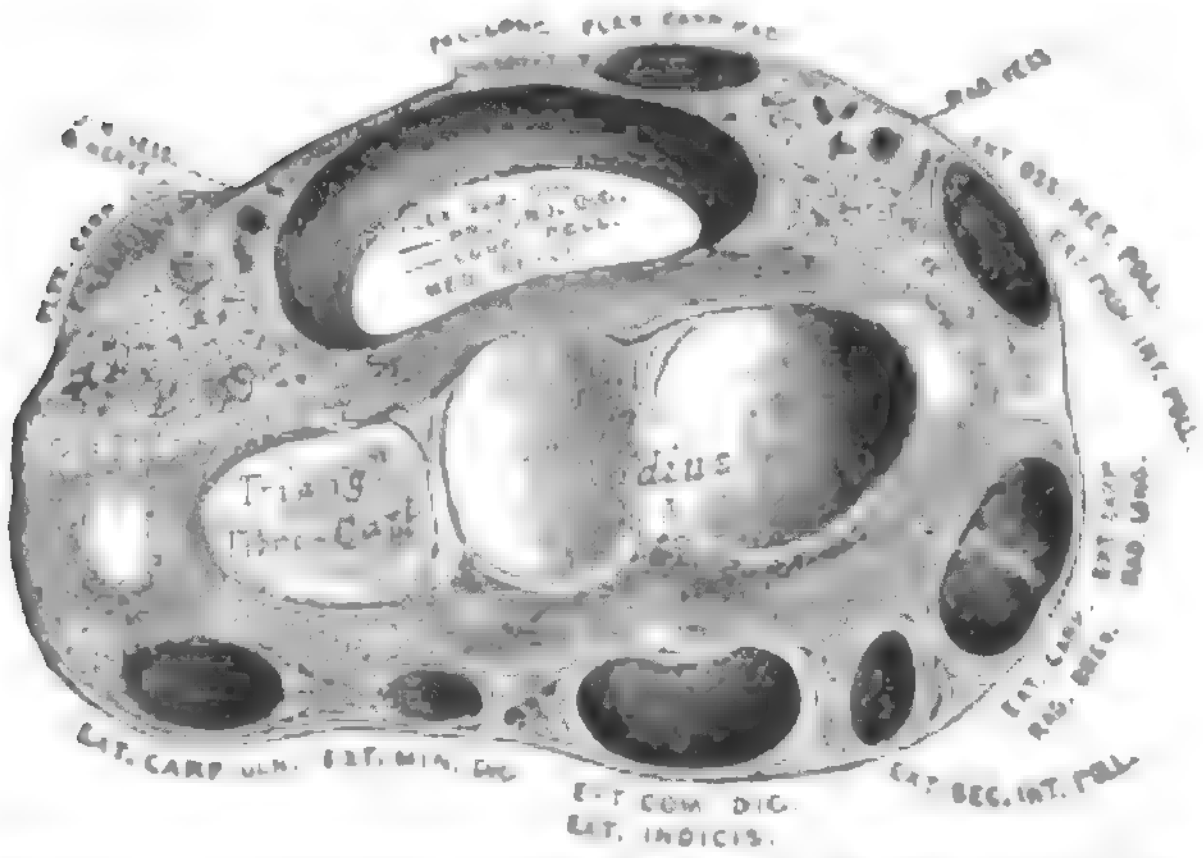

Transverse Section through the Wrist, showing the annular ligaments and the canals for the passage of the tendons.

The **Palmar Fascia** [Figs. 321, 322] forms a common sheath which invests the muscles of the hand. It consists of a central and two lateral portions.

The *central portion* occupies the middle of the palm, is triangular in shape, of great strength and thickness, and binds down the tendons in this situation. It is narrow above, being attached to the lower margin of the annular ligament, and receives the expanded tendon of the Palmaris longus muscle. Below it is broad and expanded, and opposite the heads of the metacarpal bones divides into four slips for the four fingers. Each slip subdivides into two processes which enclose the tendons of the Flexor muscles, blending with their sheath, and are attached laterally to the fibrous structures on either side of the metacarpo-phalangeal joint: by this arrangement four arches are formed, under which the Flexor tendons pass. The intervals left in the fascia between the four fibrous slips transmit the digital vessels and nerves and the tendons of the Lumbricales. At the points of division of the palmar fascia into the slips above mentioned numerous strong transverse fibres bind the separate processes together. The palmar fascia is intimately adherent to the integument by numerous fibrous bands, and gives origin by its inner margin to the Palmaris brevis; it covers the superficial palmar arch, the tendons of the flexor muscles, and the branches of the median and ulnar nerves; and on each side it gives off a vertical septum which is continuous with the interosseous aponeurosis and separates the lateral from the middle palmar group of muscles.

The *lateral portions* of the palmar fascia are thin fibrous layers which cover on the radial side the muscles of the ball of the thumb, and on the ulnar side the muscles of the little finger; they are continuous with the dorsal fascia, and in the palm with the middle portion of the palmar fascia.

[The palmar fascia lies under a layer of fibro-fatty tissue, which makes it difficult to dissect accurately. Some fibres of the fascia are attached to the skin both of the palm and the fingers, and can be best appreciated as they are divided in dissection. The four digital tongues begin above the level of the web of the thumb, and pass down to be inserted chiefly into the base of the first phalanges and the anterior ligaments of the knuckle-joints, while some fibres pass around even to the Extensor tendon, others to the sides of the first phalanges, and others reach to the second, and possibly even to the third phalanges. A fifth rather slender tongue passes to the thumb. The lower border of the fascia is distinctly marked, and is situated at the level of the transverse lines in the palm which correspond to the knuckle-joints (Fig. 261, p. 340.) This is just below the middle of the palm. Here there exists a strong band of transverse fibres, some of which also pass on to the thumb, but most of them pass to the radial side of the forefinger, under the longitudinal fibres. These fibres to the thumb have been denied or overlooked, but I have never failed to find them in the numerous hands I have dissected. Fig. 322 shows the attachments of the palmar fascia to the metacarpal bones, and the various partitions for the Flexor muscles, and separate ones for the Lumbrical muscles with the vessels and nerves. It also again shows the slips going to the thumb, one of longitudinal, the other of transverse fibres.

[Fig. 321.

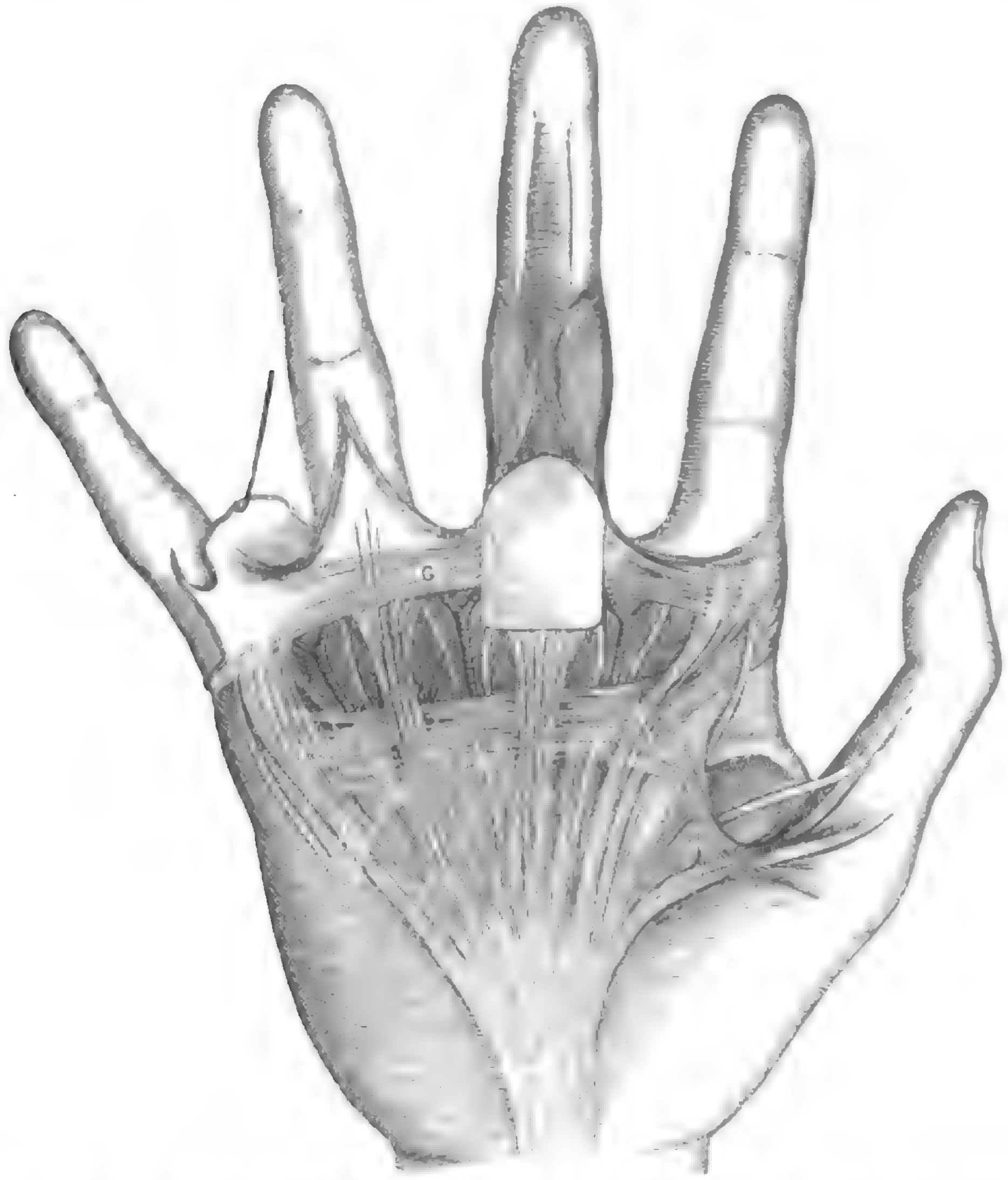

Palmar Fascia, seen from above, showing its longitudinal slips and transverse fibres and attachments to the thumb. G are the fibres of Gerdy forming the web of the fingers. The shield-like space to the right of G is a piece of skin left *in situ*. (Dissected by Dr. W. W. Keen; drawn by Dr. J. M. Taylor.)]

About an inch below the palmar fascia entirely, at the web of the fingers, exists another distinct strong band of transverse fibres, the so-called "fibres of Gerdy" (Fig. 321, G). They, in fact, give form and strength to the web of the fingers and support to the hand crosswise. Sometimes this band exists so low down as to unite the fingers in such a manner that one cannot be flexed without carrying its neighbors with it. The fibres pass, some entirely across the hand, others part way, and others simply arch over from one finger to another. These last pass down partly on the sides of the fingers, joining with the lateral digital fibres of the palmar fascia, while others pass directly down the middle line of the first phalanx, chiefly in the subcutaneous tissue, and on reaching the base of the second phalanx they split astride the Flexor sheath, and are inserted into the sides of the base of the second phalanx.

[Fig. 322.

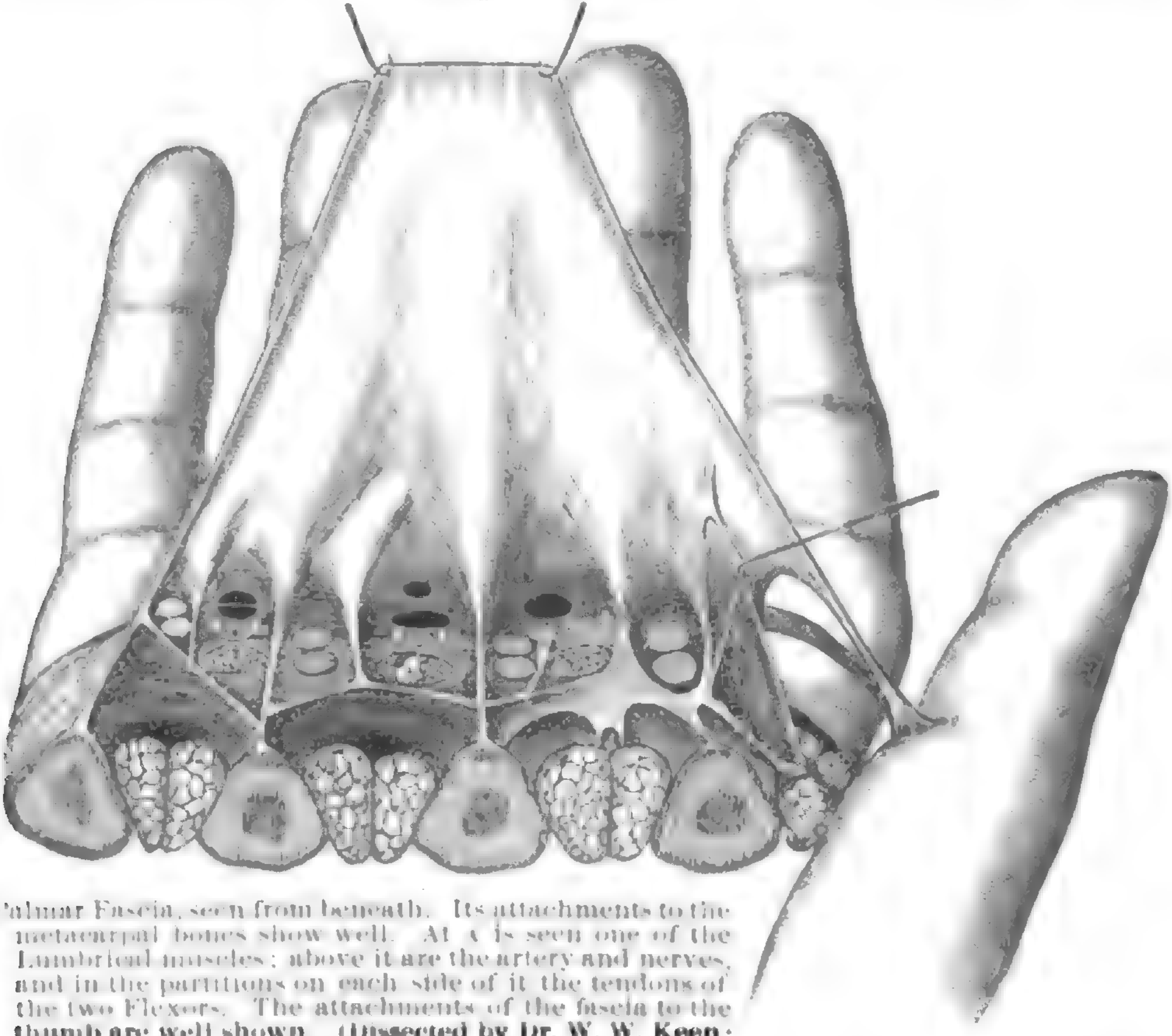

Palmar Fascia, seen from beneath. Its attachments to the metacarpal bones show well. At A is seen one of the Lumbrical muscles; above it are the artery and nerves, and in the partitions on each side of it the tendons of the two Flexors. The attachments of the fascia to the thumb are well shown. (Dissected by Dr. W. W. Keen; drawn by Dr. J. M. Taylor.)]

"Dupuytren's finger-contraction" is produced by contraction of the palmar fascia, though it is generally mistaken for contraction of the Flexor tendons. It affects preferably the three ulnar fingers, though the forefinger, and occasionally the thumb, are involved. It is readily amenable to operation.[1]]

MUSCLES OF THE HAND.

The Muscles of the Hand are subdivided into three groups: 1, Those of the thumb, which occupy the radial side [thenar eminence]; 2, those of the little finger, which occupy the ulnar side [hypothenar eminence]; 3, those in the middle portion of the palm and between the interosseous spaces.

RADIAL REGION (Fig. 323).

Muscles of the Thumb.

Abductor pollicis.
Opponens pollicis (or Flexor ossis metacarpi pollicis).
Flexor brevis pollicis.
Adductor pollicis.

The **Abductor pollicis** is a thin flat muscle placed immediately beneath the integument. It arises from the ridge of the os trapezium and annular ligament, and, passing outward and downward, is inserted by a thin flat tendon into the radial side of the base of the first phalanx of the thumb.

[[1] See a paper by the American Editor in the *Reference Handbook of the Medical Sciences*, vol. iii. p. 159.]

Relations.—By its *superficial surface* with the palmar fascia; by its *deep surface* with the Opponens pollicis, from which it is separated by a thin aponeurosis. Its *inner border* is separated from the Flexor brevis pollicis by a narrow cellular interval.

The **Opponens pollicis** [or **Flexor ossis metacarpi pollicis**] is a small triangular muscle placed beneath the preceding. It arises from the palmar surface of the trapezium and annular ligament, passes downward and outward, and is inserted into the whole length of the metacarpal bone of the thumb on its radial side.

Fig. 323.

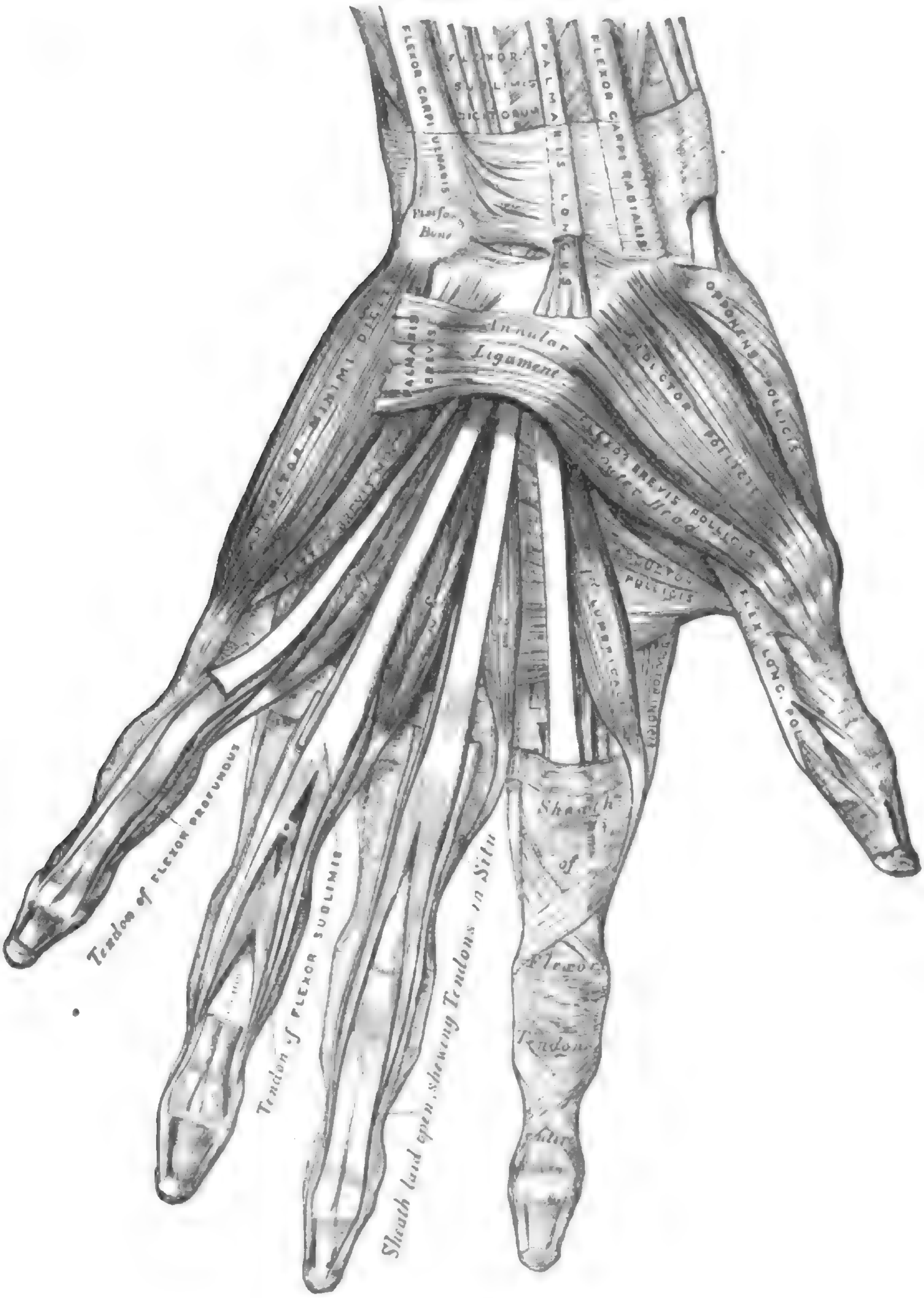
FLEXOR CARPI ULNARIS
FLEXOR SUBLIMIS DIGITORUM
PALMARIS LONGUS
FLEXOR CARPI RADIALIS
Pisiform Bone
Annular Ligament
PALMARIS BREVIS
ABDUCTOR MINIMI DIGITI
FLEXOR BREVIS MINIMI
OPPONENS POLLICIS
ABDUCTOR POLLICIS
FLEXOR BREVIS POLLICIS
Outer Head
ADDUCTOR POLLICIS
1st LUMBRICAL
FLEX. LONG. POL.
Tendon of FLEXOR PROFUNDUS
Tendon of FLEXOR SUBLIMIS
Sheath laid open, shewing Tendons in Situ
Sheath of Flexor Tendons entire

Muscles of the Left Hand, palmar surface.

RELATIONS.—By its *superficial surface* with the Abductor pollicis; by its *deep surface* with the trapezio-metacarpal articulation; by its *inner border* with the Flexor brevis pollicis.

The **Flexor brevis pollicis** is much larger than either of the two preceding muscles beneath which it is placed. It consists of two portions, in the interval between which lies the tendon of the Flexor longus pollicis. The anterior and more superficial portion arises from the trapezium and outer two-thirds of the annular ligament; the deeper portion, from the trapezoid, os magnum, bases of the second and third metacarpal bones, and sheath of the tendon of the Flexor carpi radialis. The two portions are united by a bundle of fibres which pass behind the long flexor and are inserted one on either side of the base of the first phalanx of the thumb, the outer portion being joined with the Abductor, and the inner with the Adductor. A sesamoid bone is developed in each tendon as it passes across the metacarpo-phalangeal joint.

RELATIONS.—By its *superficial surface* with the palmar fascia; by its *deep surface* with the Adductor pollicis and tendon of the Flexor carpi radialis; by its *external surface* with the Opponens pollicis; by its *internal surface* with the Adductor pollicis.

The **Adductor pollicis** (Figs. 317 and 323) is the most deeply seated of this group of muscles. It is of a triangular form, arising by its broad base from the lower two-thirds of the metacarpal bone of the middle finger on its palmar surface; the fibres, proceeding outward, converge, to be inserted, with the inner tendon of the Flexor brevis pollicis, into the ulnar side of the base of the first phalanx of the thumb and into the internal sesamoid bone.

[Duchenne[1] has recalled attention to the fact that the Abductor, Adductor, and Short Flexor of the thumb all have aponeurotic expansions at their insertions, connecting them with the tendon of the Extensor longus pollicis. They use this tendon as an indirect insertion, as well as their own direct insertion, the object of the arrangement being to produce flexion of the first phalanx and extension of the second, both at the same time. This anatomical arrangement and physiological use of the thumb find their analogue in the fingers (p. 457), as we might indeed expect, for the Ab- and Ad-ductor pollicis are the analogues of the Interosseous muscles.]

RELATIONS.—By its *superficial surface* with the Flexor brevis pollicis, the tendons of the Flexor profundus, and the Lumbricales. Its *deep surface* covers the first two interosseous spaces, from which it is separated by a strong aponeurosis.

NERVES.—The Abductor, Opponens, and outer head of the Flexor brevis pollicis are supplied by the median nerve: the inner head of the Flexor brevis and the Adductor pollicis, by the ulnar nerve.

ACTIONS.—The actions of the muscles of the thumb are almost sufficiently indicated by their names. This segment of the hand is provided with three Extensors —an Extensor of the metacarpal bone, an Extensor of the first, and an Extensor of the second phalanx; these occupy the dorsal surface of the forearm and hand. There are also three Flexors on the palmar surface—a Flexor of the metacarpal bone, the Flexor ossis metacarpi (Opponens pollicis), the Flexor brevis pollicis, and the Flexor longus pollicis. There is also an Abductor and an Adductor. These muscles give to the thumb its extensive range of motion.

ULNAR REGION (Fig. 323).

Muscles of the Little Finger.

Palmaris brevis.	Flexor brevis minimi digiti.
Abductor minimi digiti.	Opponens minimi digiti (or Flexor ossis metacarpi minimi digiti).

The **Palmaris brevis** is a thin quadrilateral muscle placed beneath the integument on the ulnar side of the hand. It arises by tendinous fasciculi from the

---

[[1] *Physiol. des Mouvements*, Paris, 1867, p. 299.]

annular ligament and palmar fascia; the fleshy fibres pass horizontally inward to be inserted into the skin on the inner border of the palm of the hand. [It can generally be very well shown by electricity, and the same means will differentiate admirably most of the muscles of the hand.]

RELATIONS.—By its *superficial surface* with the integument, to which it is intimately adherent, especially by its inner extremity; by its *deep surface* with the inner portion of the palmar fascia, which separates it from the ulnar vessels and nerve and from the muscles of the ulnar side of the hand.

The **Abductor minimi digiti** is situated on the ulnar border of the palm of the hand. It arises from the pisiform bone and from an expansion of the tendon of the Flexor carpi ulnaris, and terminates in a flat tendon which is inserted into the ulnar side of the base of the first phalanx of the little finger, sending an offset to the extensor tendon on the back of the phalanx.

RELATIONS.—By its *superficial surface* with the inner portion of the palmar fascia and the Palmaris brevis; by its *deep surface* with the Flexor ossis metacarpi; by its *inner border* with the Flexor brevis minimi digiti.

The **Flexor brevis minimi digiti** lies on the same plane as the preceding muscle, on its radial side. It arises from the tip of the unciform process of the unciform bone and anterior surface of the annular ligament, and is inserted into the base of the first phalanx of the little finger with the preceding. It is separated from the Abductor at its origin by the deep branches of the ulnar artery and nerve. This muscle is sometimes wanting; the Abductor is then usually of large size.

RELATIONS.—By its *superficial surface* with the internal portion of the palmar fascia and the Palmaris brevis; by its *deep surface* with the Opponens.

The **Opponens minimi digiti** [**or Flexor ossis metacarpi minimi digiti**] (Fig. 317, p. 443) is of a triangular form and placed immediately beneath the preceding muscles. It arises from the unciform process of the unciform bone and contiguous portion of the annular ligament; its fibres pass downward and inward to be inserted into the whole length of the metacarpal bone of the little finger along its ulnar margin.

RELATIONS.—By its *superficial surface* with the Flexor brevis and Abductor minimi digiti; by its *deep surface* with the Interosseous muscles in the fourth metacarpal space, the metacarpal bone, and the Flexor tendons of the little finger.

NERVES.—All the muscles of this group are supplied by the ulnar nerve.

ACTIONS.—The actions of the muscles of the little finger are expressed in their names. The Palmaris brevis corrugates the skin on the inner side of the palm of the hand.

MIDDLE PALMAR REGION.

Lumbricales. Interossei palmares.
Interossei dorsales.

The **Lumbricales** (Fig. 323) are four small fleshy fasciculi, accessories to the deep Flexor muscle. They arise by fleshy fibres from the tendons of the deep Flexor: the first and second from the radial side and palmar surface of the tendons of the index and middle fingers; the third from the contiguous sides of the tendons of the middle and ring fingers; and the fourth from the contiguous sides of the tendons of the ring and little fingers. They pass forward to the radial side of the corresponding fingers, and opposite the metacarpo-phalangeal articulation each tendon terminates in a broad aponeurosis which is inserted into the tendinous expansion from the Extensor communis digitorum covering the dorsal aspect of each finger.

The **Interosseous muscles** are so named from occupying the intervals between the metacarpal bones. They are divided into two sets, a dorsal and palmar: the former are four in number, one in each metacarpal space; the latter, three in number, lie upon the metacarpal bones.

The **Dorsal interossei** are four in number, larger than the palmar, and occupy the intervals between the metacarpal bones. They are bipenniform muscles, arising by two heads from the adjacent sides of the metacarpal bones, but more extensively from that side of the metacarpal bone which corresponds to the side of the finger in which the muscle is inserted. They are inserted into the base of the first phalanges and into the aponeurosis of the common Extensor tendon. Between the double origin of each of these muscles is a narrow triangular interval through which passes a perforating branch from the deep palmar arch.

[Fig. 324.

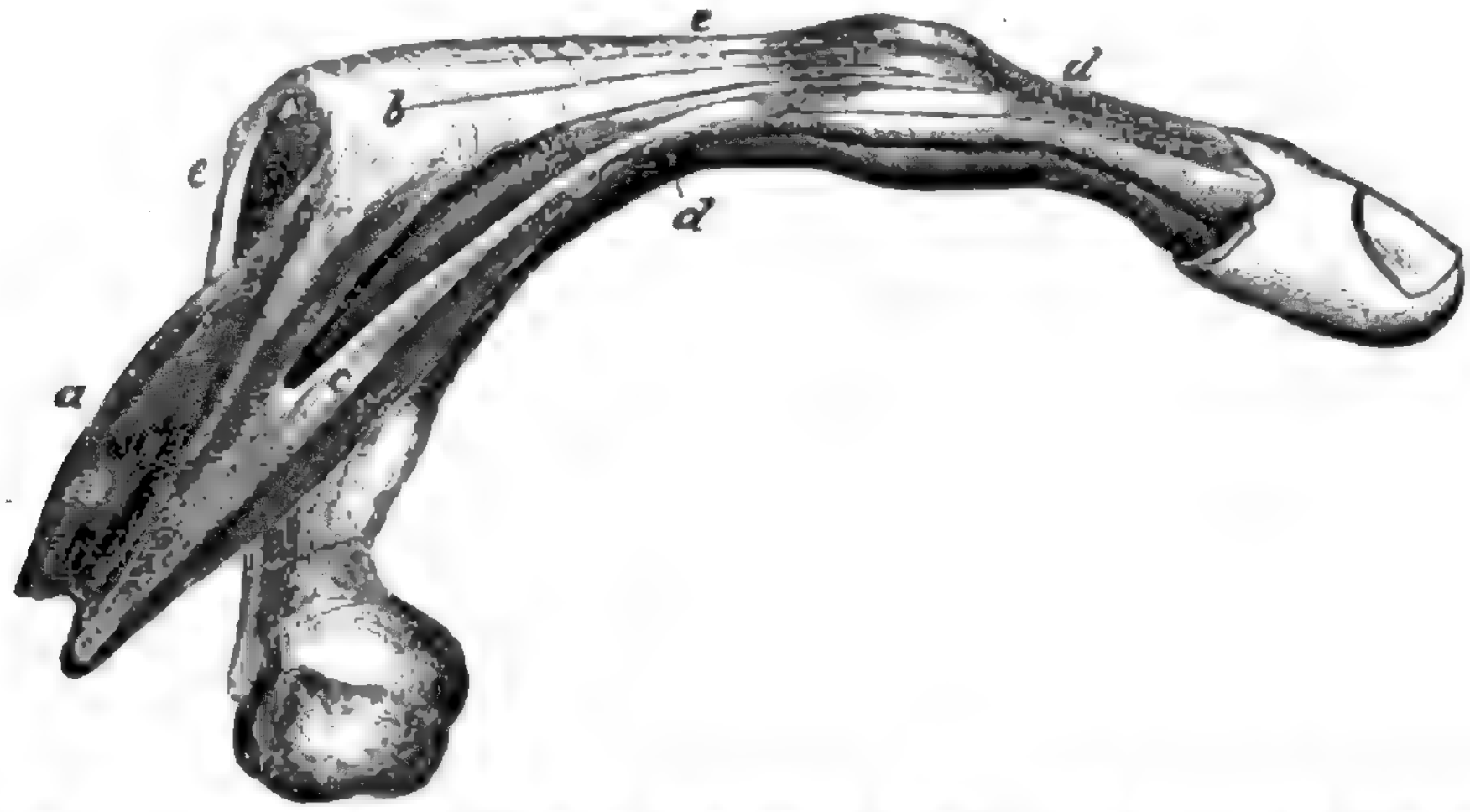

Ring Finger of the Right Hand, with its Adductor Interosseous Muscle: *a*, one belly of the Interosseous, attached at *b* to the first phalanx; *c*, the other belly of the Interosseous, attached by *d*, *d*, its tendon, to the posterior surface of the second and third phalanges, and joined to *e*, *e*, the tendon of the Extensor communis (Duchenne).]

The **First Dorsal interosseous** muscle, or **Abductor indicis**, is larger than the others. It is flat, triangular in form, and arises by two heads, separated by a fibrous arch for the passage of the radial artery from the dorsum to the palm of the hand. The outer head arises from the upper half of the ulnar border of the first metacarpal bone; the inner head, from almost the entire length of the radial border of the second metacarpal bone; the tendon is inserted into the radial side of the

Fig. 325.

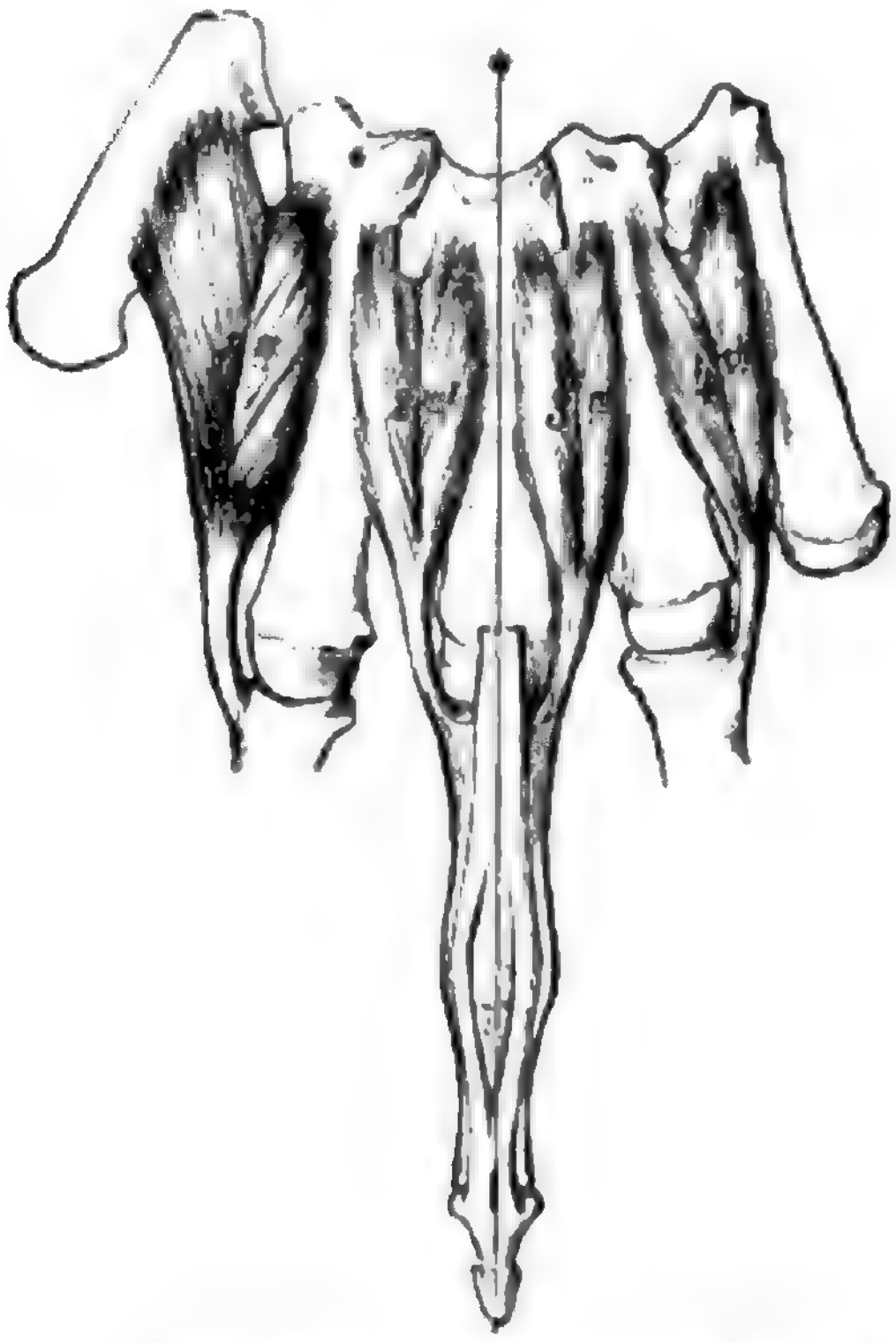

The Dorsal Interossei of Left Hand.

Fig. 326.

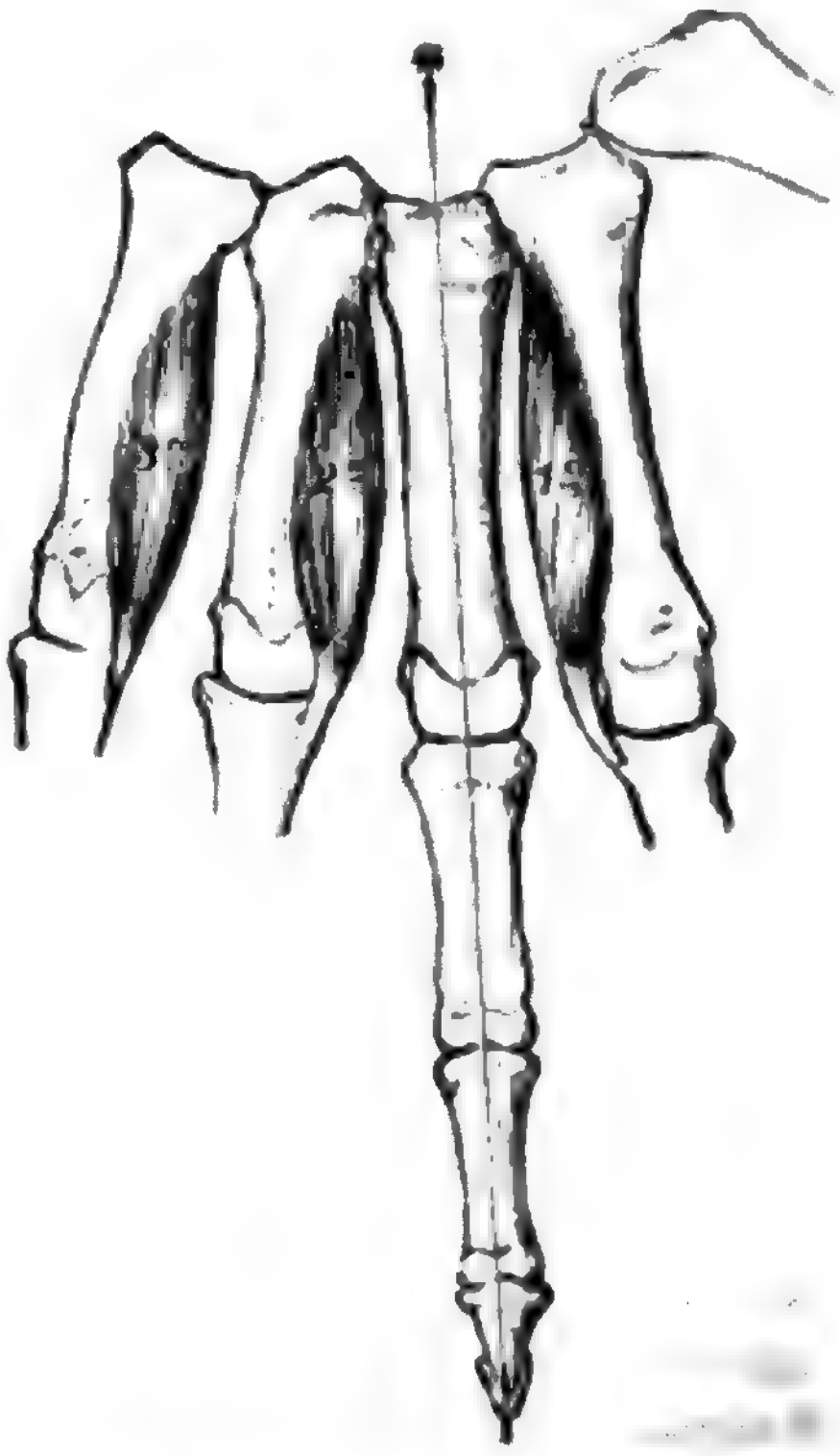

The Palmar Interossei of Left Hand.

index finger. The second and third Dorsal interossei are inserted into the middle finger, the former into its radial, the latter into its ulnar side. The fourth is inserted into the ulnar side of the ring finger.

The **Palmar interossei,** three in number, are smaller than the Dorsal, and placed upon the palmar surface of the metacarpal bones, rather than between them. They arise from the entire length of the metacarpal bone of one finger, and are inserted into the side of the base of the first phalanx and the aponeurotic expansion of the common Extensor tendon of the same finger..

The first arises from the ulnar side of the second metacarpal bone, and is inserted into the same side of the index finger. The second arises from the radial side of the fourth metacarpal bone, and is inserted into the same side of the ring finger. The third arises from the radial side of the fifth metacarpal bone, and is inserted into the same side of the little finger. From this account it may be seen that each finger is provided with two Interossei muscles, with the exception of the little finger, in which the Abductor muscle takes the place of one of the pair.

NERVES.—The two outer Lumbricales are supplied by the median nerve, the rest of the muscles of this group by the ulnar.

ACTIONS.—The Dorsal interossei muscles abduct the fingers from an imaginary line drawn longitudinally through the centre of the middle finger, and the Palmar interossei adduct the fingers toward that line. They usually assist the Extensor muscles, but when the fingers are slightly bent they assist in flexing them. The action of the Lumbricales and Internal or Dorsal interossei is said by Hunter to be to flex the first phalanges and extend the last two (*Works* by Palmer, iv. 237); and Cleland supports this (*Journ. of Anat. and Phys.*, Old Series, i. 85). M. Duchenne gives a different account of the mechanism of the extension of the fingers, and of the action of the Interossei muscles, from that usually accepted. According to him, the Extensor communis digitorum acts almost entirely on the first phalanges, extension of the second and third phalanges being effected by the Interossei muscles, which also act to a certain extent as flexors of the first phalanges. This action of the Interossei is additional to their action in abduction and adduction (*Physiologie des Mouvements*, pp. 261–298).[1]

[There is no question of the correctness of Hunter's and Duchenne's view. Electricity, many cases of paralysis of the ulnar nerve and of lead palsy which I have seen, all point the same way. To sum up: The first phalanges are flexed by the Interossei and Lumbricales, and extended by the Extensor communis; the last two phalanges are flexed by the Flexor sublimis and Flexor profundus respectively, and extended by the Extensor communis to a moderate degree, but chiefly by the Interossei and Lumbricales.]

SURGICAL ANATOMY.

The student, having completed the dissection of the muscles of the upper extremity, should consider the effects likely to be produced by the action of the various muscles in fracture of the bones.

In considering the actions of the various muscles upon fractures of the upper extremity I have selected the most common forms of injury both for illustration and description.

Fracture of the *clavicle* is an exceedingly common accident, and is usually caused by indirect violence, as a fall upon the shoulder [or hand]; it occasionally, however, occurs from direct force. Its more usual situation is just external to the centre of the bone, but it may occur at the sternal or acromial end.

Fracture of the *middle of the clavicle* (Fig. 327) is always attended with considerable displacement, the outer fragment being drawn downward, forward, and inward; the inner fragment slightly upward. The outer fragment is drawn down by the weight of the arm and the action of the Deltoid, and forward and inward by the Pectoralis minor and Subclavius muscles; the inner fragment is slightly raised by the Sterno-cleido-mastoid, but only to a very limited extent, as the attachment of the costo-clavicular ligament and Pectoralis major below and in front would prevent any very great displacement upward. The causes of displacement having been ascertained, it is easy to apply the appropriate treatment. The outer fragment is to be drawn outward, and, together with the scapula, raised upward to a level with the inner fragment, and retained in that position.

---

[1] M. Duchenne's view of the action of these muscles certainly derives support from the phenomena observed in lead palsy and from the results of galvanizing the common Extensor and the Interossei, as Dr. W. Ogle has been kind enough to point out to me. Thus also in a case related by Mr. Hutchinson, in which the ulnar nerve had been divided below the part from which the Extensor communis was supplied (and therefore the Interossei were paralyzed while the Extensor acted), "the first phalanges were bent backward on the metacarpal bones" (extended), "while the fingers were curved into the palm" (second and third phalanges flexed) (*London Hospital Reports*, vol. iii. p. 307).

Fig. 327.

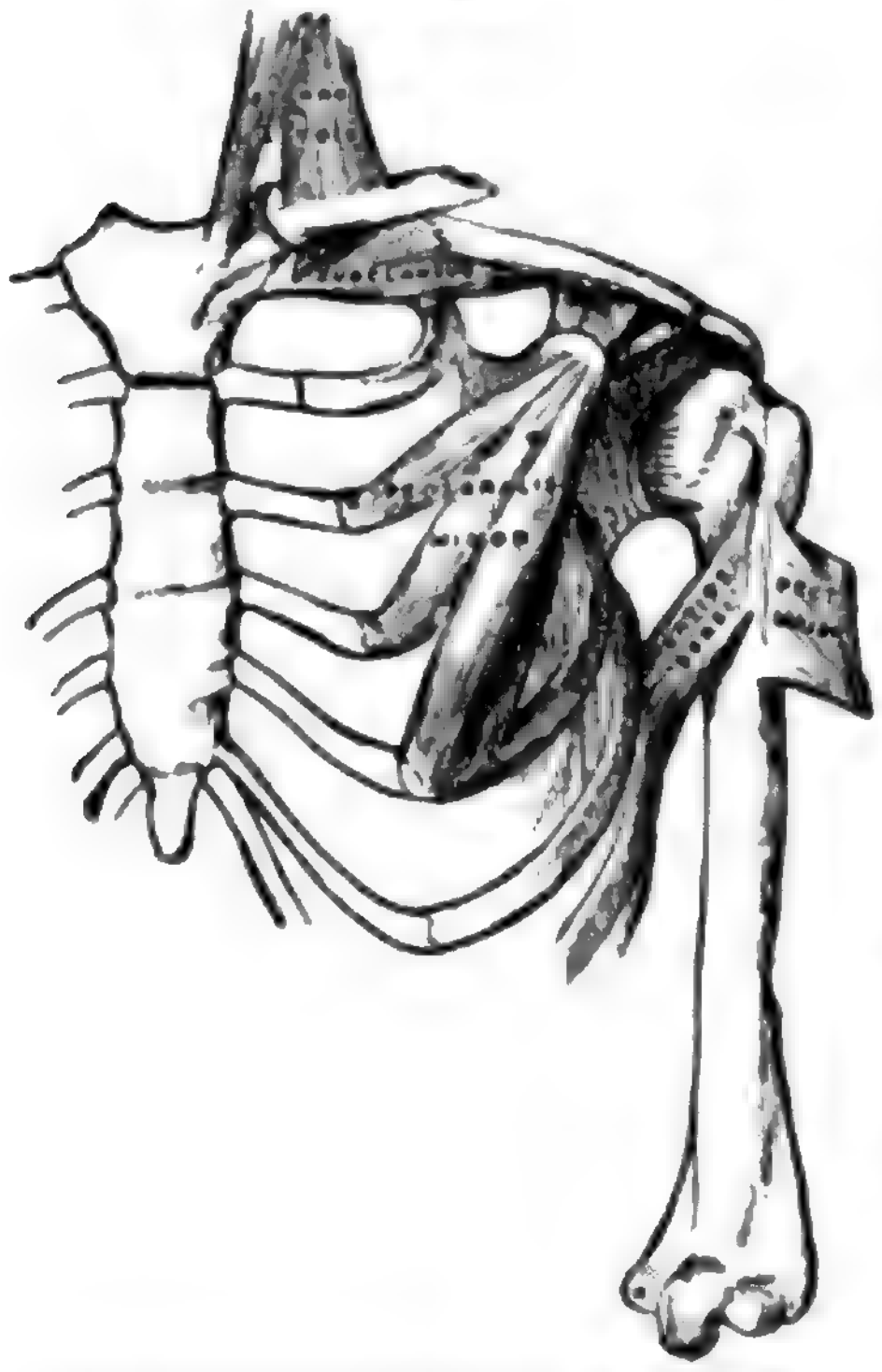

Fracture of the Middle of the Clavicle.

In fracture of the *acromial end of the clavicle*, between the conoid and trapezoid ligaments, only slight displacement occurs, as these ligaments, from their oblique insertion, serve to hold both portions of the bone in apposition. Fracture also of the *sternal end*, internal to the costo-clavicular ligament, is attended with only slight displacement, this ligament serving to retain the fragments in close apposition.

Fracture of the *acromion process* usually arises from violence applied to the upper and outer part of the shoulder; it is generally known by the rotundity of the shoulder being lost from the Deltoid drawing the fractured portion downward and forward; and the displacement may easily be discovered by tracing the margin of the clavicle outward, when the fragment will be found resting on the front and upper part of the head of the humerus. In order to relax the anterior and outer fibres of the Deltoid (the opposing muscle), the arm should be drawn forward across the chest and the elbow well raised, so that the head of the bone may press the acromion process upward and retain it in its position.

Fracture of the *coracoid process* is an extremely rare accident, and is usually caused by a sharp blow on the point of the shoulder. Displacement is here produced by the combined actions of the Pectoralis minor, short head of the Biceps, and Coraco-brachialis, the former muscle drawing the fragment inward, and the latter directly downward, the amount of displacement being limited by the connection of this process to the acromion by means of the coraco-acromial ligament. In order to relax these muscles and replace the fragments in close apposition, the forearm should be flexed, so as to relax the Biceps, and the arm drawn forward and inward across the chest, so as to relax the Coraco-brachialis; the humerus should then be pushed upward against the coraco-acromial ligament, and the arm retained in that position.

Fracture of the *anatomical neck of the humerus* within the capsular ligament is a rare accident, attended with very slight displacement, an impaired condition of the motions of the joint, and crepitus.

Fracture of the *surgical neck* (Fig. 328) is very common, is attended with considerable displacement, and its appearances correspond somewhat with those of dislocation of the head of the humerus into the axilla. The upper fragment is slightly elevated under the coraco-acromial ligament by the muscles attached to the greater and lesser tuberosities; the lower fragment is drawn inward by the Pectoralis major, Latissimus dorsi, and Teres major, and the humerus is thrown obliquely outward from the side by the Deltoid, and occasionally elevated so as to project beneath and in front of the coracoid process. The deformity is reduced by fixing the shoulder and drawing the arm outward and downward. To counteract the opposing muscles and to keep the fragments in position, the arm should be drawn from the side, and pasteboard splints applied on its four sides; a large conical-shaped pad should be placed in the axilla, with the base turned upward and the elbow approximated to the side, and retained there by a broad roller passed round the chest; the forearm should then be flexed, and the hand supported in a sling, care being taken not to raise the elbow, otherwise the lower fragment may be displaced upward.

Fig. 328.

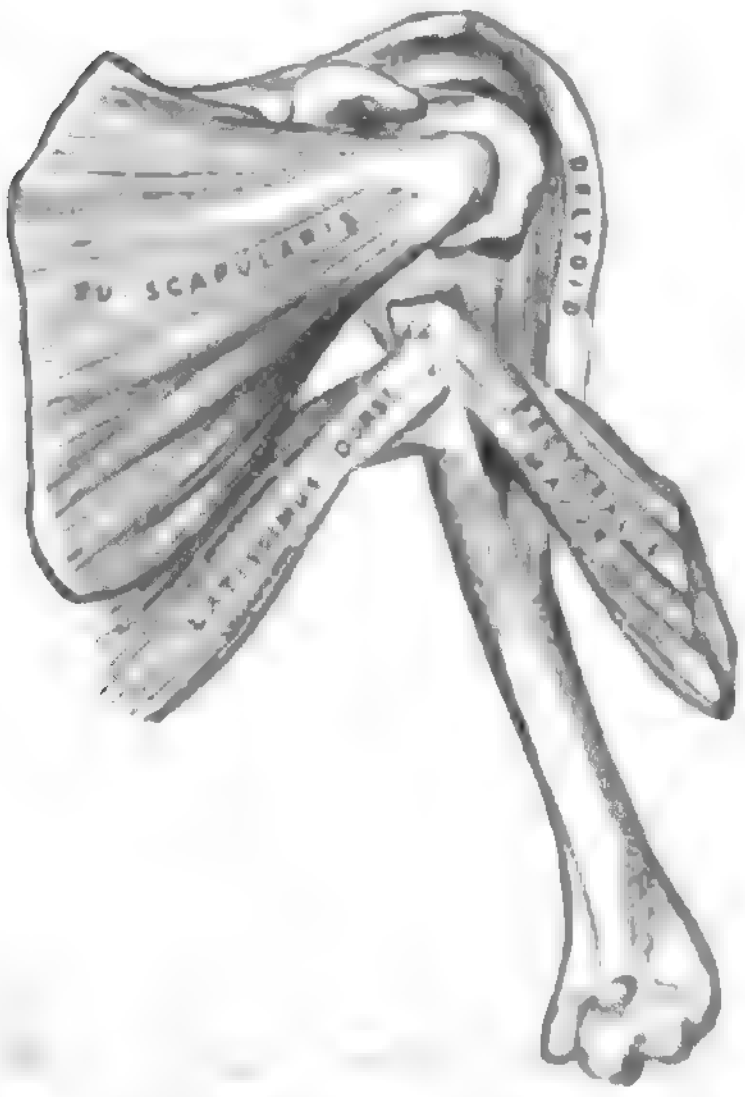

Fracture of the Surgical Neck of the Humerus.

In fracture of the *shaft of the humerus* below the insertion of the Pectoralis major, Latissimus dorsi, and Teres major, and above the insertion of the Deltoid, there is also considerable deformity, the upper fragment being drawn inward by the first-mentioned muscles, and the lower fragment upward and outward by the Deltoid, producing shortening of the limb and a considerable prominence at the seat of fracture from the fractured ends of the bone riding over each other, especially if the fracture takes place in an oblique direction. The fragments may be brought into apposition by extension from the elbow, and retained in that position by adopting the same means as in the preceding injury.

In fractures of the *shaft of the humerus* immediately below the insertion of the Deltoid the amount of deformity depends greatly upon the direction of the fracture. If the fracture occurs in a transverse direction, only slight displacement occurs, the upper fragment being drawn a little forward; but in oblique fracture the combined actions of the Biceps and Brachialis anticus muscles in front and the Triceps behind draw upward the lower fragment, causing it to glide over the upper fragment, either backward or forward according to the direction of the fracture. Simple extension reduces the deformity, and the application of splints on the four sides of the arm will retain the fragments in apposition. Care should be taken not to raise the elbow, but the forearm and hand may be supported in a sling.

Fracture of the *humerus* (Fig. 329) immediately above the condyles deserves very attentive consideration, as the general appearances correspond somewhat with those produced by separation of the epiphysis of the humerus and with those of dislocation of the radius and ulna backward. If the direction of the fracture is oblique from above, downward, and forward, the lower fragment is drawn upward and backward by the Brachialis anticus and Biceps in front and the Triceps behind. This injury may be diagnosticated from dislocation by the increased mobility in fracture, the existence of crepitus, and the fact of the deformity being remedied by extension, on the discontinuance of which it is reproduced. [In fracture there will be shortening from the acromion to the external condyle, while the measurements from the olecranon to the condyles will be unchanged. In dislocation the measurements from the olecranon to the condyles will be changed, while that from the acromion to the external condyle will be unchanged.] The age of the patient is of importance in distinguishing this form of injury from separation of the epiphysis. If fracture occurs in the opposite direction to that shown in the accompanying figure, the lower fragment is drawn upward and forward, causing a considerable prominence in front; and the upper fragment projects backward beneath the tendon of the Triceps muscle.

FIG. 329

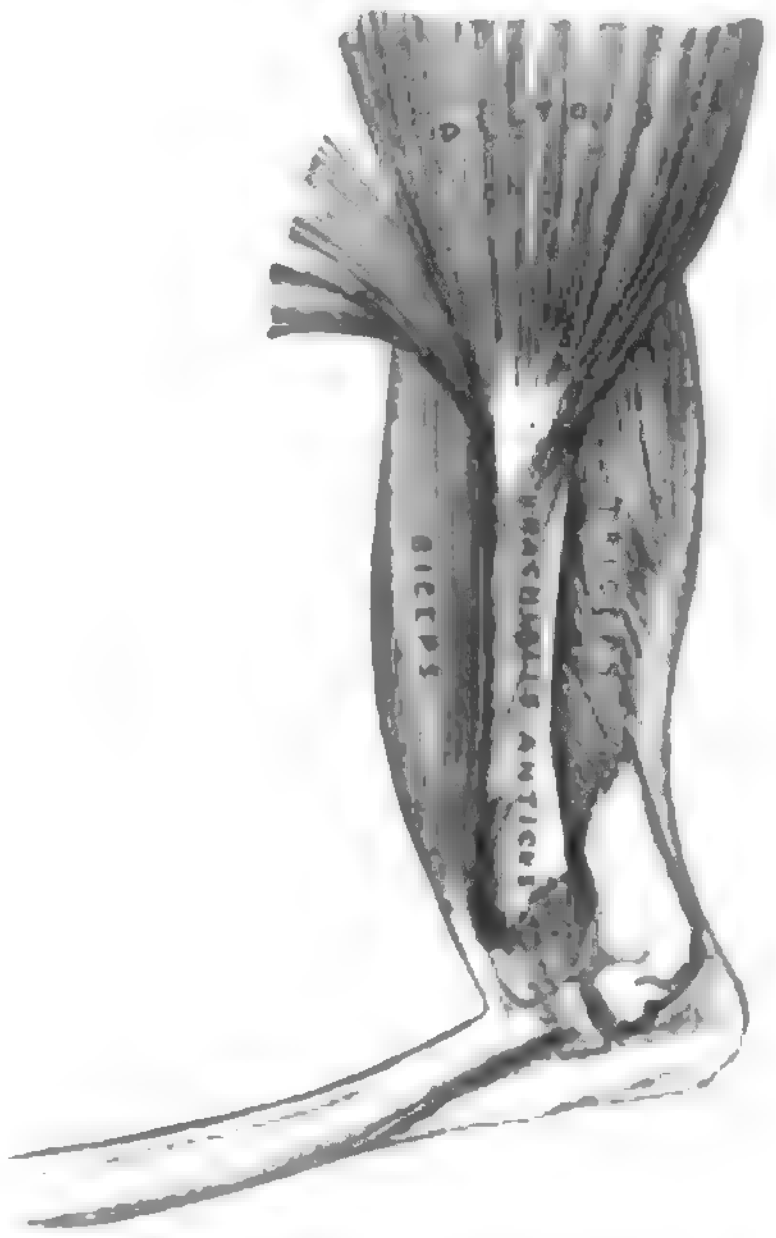

Fracture of the Humerus above the Condyles.

Fracture of the *coronoid process of the ulna* is an accident of rare occurrence, and is usually caused by violent action of the Brachialis anticus muscle. The amount of displacement varies according to the extent of the fracture. If the tip of the process only is broken off, the fragment is drawn upward by the Brachialis anticus on a level with the coronoid depression of the humerus, and the power of flexion is partially lost. If the process is broken off near its root, the fragment is still displaced by the same muscle; at the same time, on extending the forearm, partial dislocation backward of the ulna occurs from the action of the Triceps muscle. The appropriate treatment would be to relax the Brachialis anticus by flexing the forearm, and to retain the fragments in apposition by keeping the arm in this position. Union is generally ligamentous.

Fracture of the *olecranon process* (Fig. 330) is a more frequent accident, and is caused either by violent action of the Triceps muscle or by a fall or blow upon the point of the elbow. The detached fragment is displaced upward from half an inch to two inches by the action of the Triceps muscle; the prominence of the elbow is consequently lost, and a deep hollow is felt at the back part of the joint, which is much increased on flexing the limb. The patient at the same time loses, more or less, the power of extending the forearm. The treatment consists in relaxing the Triceps by extending the limb, and retaining it in the extended position by means of a long straight splint applied to the front of the arm: the fragments are thus brought into close apposition, and may be further approximated by drawing down the upper fragment. Union is generally ligamentous.

FIG. 330.

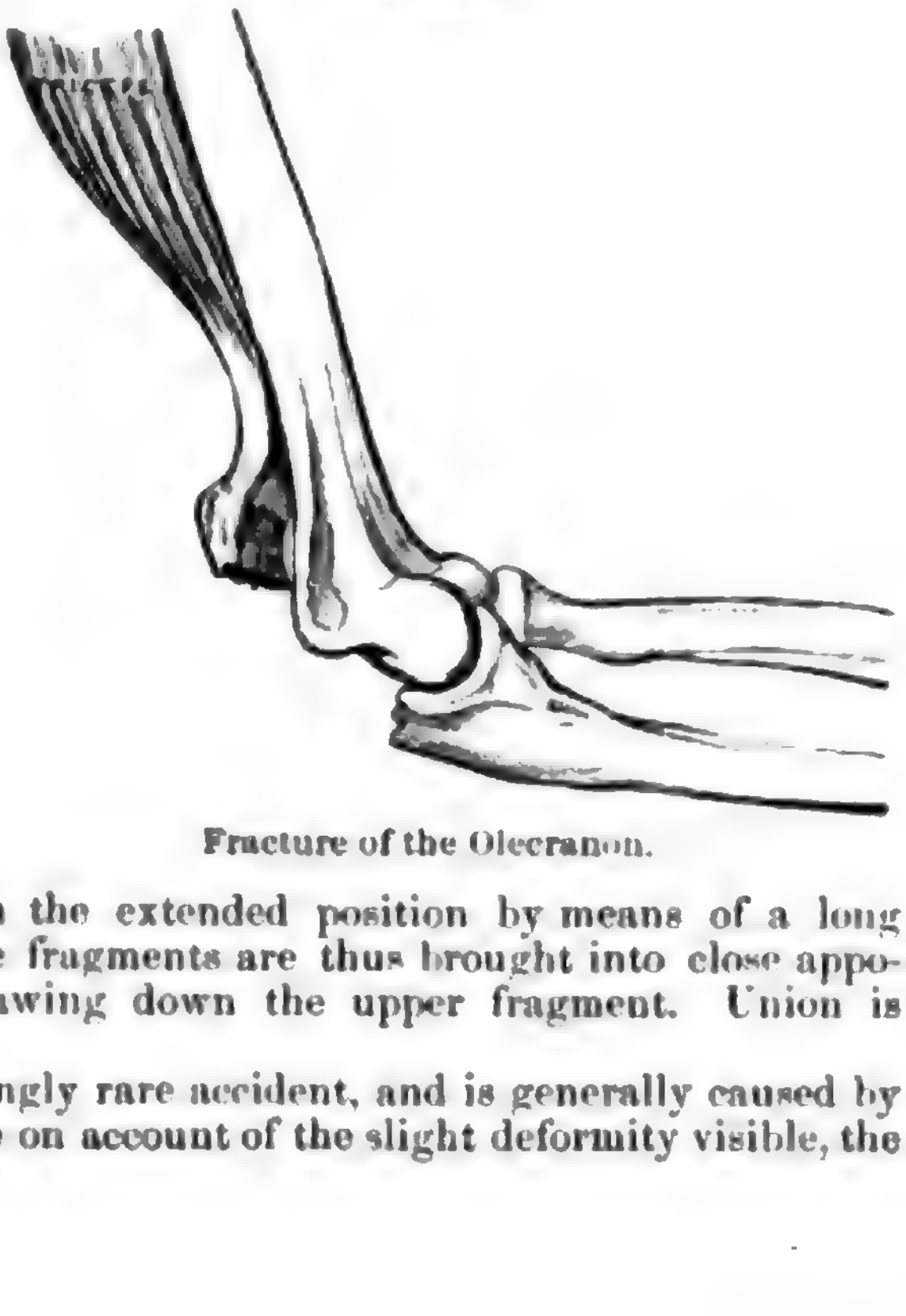

Fracture of the Olecranon.

Fracture of the *neck of the radius* is an exceedingly rare accident, and is generally caused by direct violence. Its diagnosis is somewhat obscure on account of the slight deformity visible, the injured part being surrounded by a large number of muscles; but the movements of pronation and supination are entirely lost. The upper fragment is drawn outward by the Supinator brevis, its extent of displacement being limited by the attachment of the orbicular ligament. The lower fragment is drawn forward and slightly upward by the Biceps, and inward by the Pronator radii teres, its displacement forward and upward being counteracted in some degree by the Supinator brevis. The treatment essentially consists in relaxing the Biceps, Supinator brevis, and Pronator radii teres muscles by flexing the forearm and placing it in a position midway between pronation and supination, extension having been previously made so as to bring the parts in apposition.

Fracture of the *radius* is [far] more common than fracture of the ulna, on account of the connection of the former bone with the wrist. Fracture of the *shaft of the radius* (Fig. 331) near its centre may occur from direct violence, but more frequently from a fall forward, the weight of the body being received on the wrist and hand. The upper fragment is drawn forward by the Biceps and inward by the Pronator radii teres, holding a position midway between pronation and supination, and a degree of fulness in the upper half of the forearm is thus produced: the lower fragment is drawn backward and inward toward the ulna by the Pronator quadratus, and thrown into a state of pronation by the same muscle; at the same time, the Supinator longus, by elevating the styloid process, into which it is inserted, will serve to displace the upper end of the lower fragment still more toward the ulna. In order to relax the opposing muscles, the forearm should be bent and the limb placed in a position midway between pronation and supination; the fracture is then easily reduced by extension from the wrist and elbow: well-padded splints should then be applied on both sides of the forearm from the elbow to the wrist; the hand, being allowed to fall, will by its own weight counteract the action of the Pronator quadratus and Supinator longus, and elevate the lower fragment to the level of the upper one.

FIG. 331.

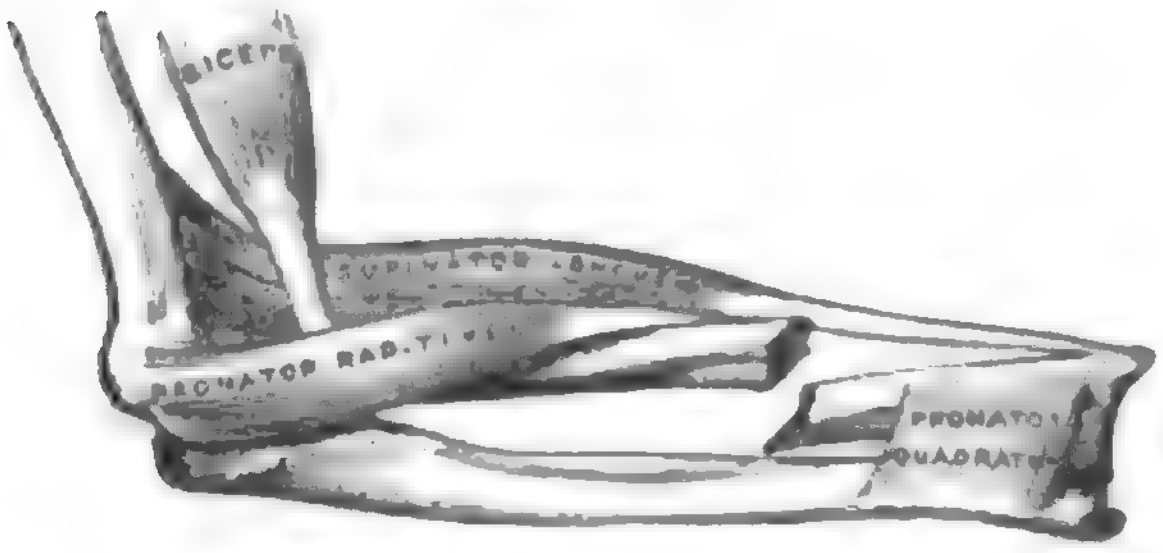

Fracture of the Shaft of the Radius.

Fracture of the *shaft of the ulna* is not a common accident: it is usually caused by direct violence. The more protected position of the ulna on the inner side of the limb, the greater strength of its shaft, and its indirect connection with the wrist render it less liable to injury than the radius. The fracture usually occurs a little below the middle, which is the weakest part of the bone. The upper fragment retains its usual position, but the lower fragment is drawn outward toward the radius by the Pronator quadratus, producing a well-marked depression at the seat of fracture and some fulness on the dorsal and palmar surfaces of the forearm. The fracture is easily reduced by extension from the wrist and forearm. The forearm should be flexed, and placed in a position midway between pronation and supination, and well-padded splints applied from the elbow to the ends of the fingers.

Fracture of the *shafts of the ulna and radius together* is not a very common accident; it may arise from a direct blow or from indirect violence. The lower fragments are drawn upward, sometimes forward, sometimes backward, according to the direction of the fracture, by the combined actions of the Flexor and Extensor muscles, producing a degree of fulness on the dorsal or palmar surfaces of the forearm; at the same time the two [lower] fragments are drawn into contact by the Pronator quadratus, the radius in a state of pronation: the upper fragment of the radius is drawn forward and inward by the Biceps and Pronator radii teres to a plane anterior to that of the ulna; the upper portion of the ulna is slightly flexed by the Brachialis anticus. The fracture may be reduced by extension from the wrist and elbow, and the forearm should be placed in the same position as in fracture of the ulna.

FIG. 332.

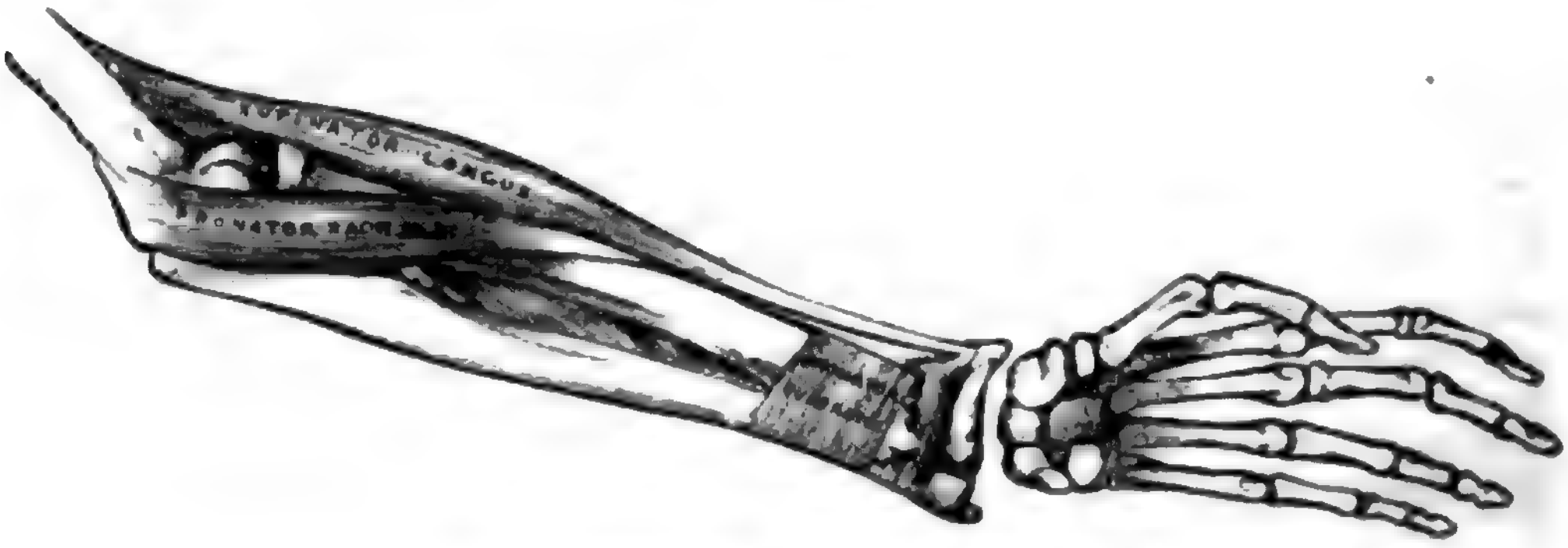

Fracture of the Lower End of the Radius.

In the treatment of all cases of fracture of the bones of the forearm the greatest care is requisite to prevent the ends of the bones from being drawn inward toward the interosseous space: if this point is not carefully attended to, the radius and ulna may become ankylosed and the movements of pronation and supination entirely lost. To obviate this, the splints applied to the limb should be well padded, so as to press the muscles down into their normal situation in the interosseous space, and thus prevent the approximation of the fragments [and, as a rule, the forearm should be midway between pro- and supi-nation, in which position the radius and ulna are separated by the widest interval].

Fracture of the *lower end of the radius* (Fig. 332) is usually called *Colles' fracture*, from the name of the eminent Dublin surgeon who first accurately described it. It is generally produced by the patient falling upon the hand, which receives the entire weight of the body [and fractures the bone by "cross-breaking strain" through the strong anterior radio-carpal ligament]. This fracture usually takes place from half an inch to an inch above the articular surface if it occurs in the adult, but in the child, before the age of sixteen, it is more frequently a separation of the epiphysis from the diaphysis. The displacement which is produced is very considerable, and bears some resemblance to dislocation of the carpus backward [a very rare accident], from which it should be carefully distinguished. The lower fragment is drawn upward and backward behind the upper fragment by the combined actions of the Supinator longus and the flexors and the extensors of the thumb and carpus, producing a well-marked prominence on the back of the wrist, with a deep depression above it. The upper fragment projects forward, often lacerating the substance of the Pronator quadratus, and is drawn by this muscle into close contact with the lower end of the ulna, causing a projection on the anterior surface of the forearm immediately above the carpus, from the flexor tendons being thrust forward. This fracture may be distinguished from dislocation by the deformity being removed on making sufficient extension, when crepitus may be occasionally detected; at the same time, on extension being discontinued, the parts immediately resume their deformed appearance. The age of the patient will also assist in determining whether the injury is fracture or separation of the epiphysis. The treatment consists in flexing the forearm and making powerful extension from the wrist and elbow, depressing at the same time the radial side of the hand, and retaining the parts in that position by well-padded *pistol-shaped* splints. [The better treatment is, first, by complete extension of the lower fragment to disengage it; next, by simultaneous traction and flexion to reduce it; and then to apply a splint, not pistol-shaped, but adapted to the forearm and the flexed hand, such as one made of plaster or Levis' copper splint.]

MUSCLES AND FASCIÆ OF THE LOWER EXTREMITY.

The Muscles of the Lower Extremity are subdivided into groups, corresponding with the different regions of the limb.

[The different uses of the upper and lower extremities produce a striking difference in the arrangement and action of their muscles and joints. In the arm, in which prehension is the chief function, all the flexors are placed anteriorly, and flexion of all the joints is in the same direction. In the leg, which is for station and locomotion, the arrangement is one of alternation. Thus, the flexors of the hip-joint are in front, the flexors of the knee behind; those of the ankle in front, those of the toes posteriorly; the joints, of course, being similarly arranged. Were this not so, stooping and similar vertical motions would be impossible, and station would be at least uncertain.]

Iliac Region.

Psoas magnus.
Psoas parvus.
Iliacus.

THIGH.

Anterior Femoral Region.

Tensor vaginæ femoris.
Sartorius.
Rectus.
Vastus externus.
Vastus internus.
Crureus.
Subcrureus.

Internal Femoral Region.

Gracilis.
Pectineus.
Adductor longus.
Adductor brevis.
Adductor magnus.

HIP.

Gluteal Region.

Gluteus maximus.
Gluteus medius.
Gluteus minimus.
Pyriformis.
Gemellus superior.
Obturator internus.
Gemellus inferior.
Obturator externus.
Quadratus femoris.

Posterior Femoral Region.

Biceps.
Semitendinosus.
Semimembranosus.

LEG.

Anterior Tibio-fibular Region.

Tibialis anticus.
Extensor longus digitorum.
Extensor proprius pollicis.
Peroneus tertius.

Posterior Tibio-fibular Region.

Superficial Layer.

Gastrocnemius.
Plantaris.
Soleus.

Deep Layer.

Popliteus.
Flexor longus pollicis.
Flexor longus digitorum.
Tibialis posticus.

Fibular Region.

Peroneus longus.
Peroneus brevis.

FOOT.

Dorsal Region.

Extensor brevis digitorum.

Plantar Region.

First Layer.

Abductor pollicis.
Flexor brevis digitorum.
Abductor minimi digiti.

Second Layer.

Flexor accessorius.
Lumbricales.

Third Layer.

Flexor brevis pollicis.
Adductor pollicis.
Flexor brevis minimi digiti.
Transversus pedis.

Fourth Layer.

The Interossei.

ILIAC REGION.

Psoas magnus. Psoas parvus. Iliacus.

Dissection.—No detailed description is required for the dissection of these muscles. On the removal of the viscera from the abdomen they are exposed, covered by the peritoneum and a thin layer of fascia, the iliac fascia.

The **Iliac Fascia**[1] is the aponeurotic layer which lines the back part of the abdominal cavity and covers the Psoas and Iliacus muscles throughout their whole extent. It is thin above, and becomes gradually thicker below as it approaches the femoral arch.

The *portion investing the Psoas* is attached above to the ligamentum arcuatum internum, internally to the sacrum, and by a series of arched processes to the intervertebral substances and prominent margins of the bodies of the vertebræ, the intervals so left, opposite the constricted portions of the bodies, transmitting the lumbar arteries and filaments of the sympathetic nerve. Externally, this portion of the iliac fascia is continuous with the anterior lamella of the posterior aponeurosis of the Transversalis muscle or lumbar fascia. (See p. 416.)

The *portion investing the Iliacus* is connected externally to the whole length of the inner border of the crest of the ilium, and internally to the brim of the true pelvis, where it is continuous with the periosteum and receives the tendon of insertion of the Psoas parvus when that muscle exists. External to the femoral vessels this fascia is intimately connected with Poupart's ligament, and is continuous with the fascia transversalis; but as the femoral vessels pass down into the thigh it is prolonged down behind them, and, passing under Poupart's ligament, it forms the posterior wall of the femoral sheath and rests on the pubic portion of the fascia lata, with which it is connected. [The femoral sheath is completed by a prolongation of the Transversalis fascia downward in front of the vessels.] Internal to the femoral vessels the iliac fascia, where it is continuous with the pubic portion of the fascia lata, sends a strong process backward between the psoas and pectineus to be attached to the ilio-pectineal eminence and the capsule of the hip-joint. The external iliac vessels lie in front of the iliac fascia, but all the branches of the lumbar plexus behind it; it is separated from the peritoneum by a quantity of loose areolar tissue. In abscess accompanying caries of the lower part of the spine the matter makes its way to the femoral arch, distending the sheath of the Psoas [and therefore usually "points" below Poupart's ligament]; and when it accumulates in considerable quantity this muscle becomes absorbed and the nervous cords contained in it are dissected out, and are exposed in the cavity of the abscess; the femoral vessels, however, remain intact, and the peritoneum seldom becomes implicated.

---

[1] The student must not confound this fascia with the *iliac portion of the fascia lata.* (See p. 466.)

Fig. 333.

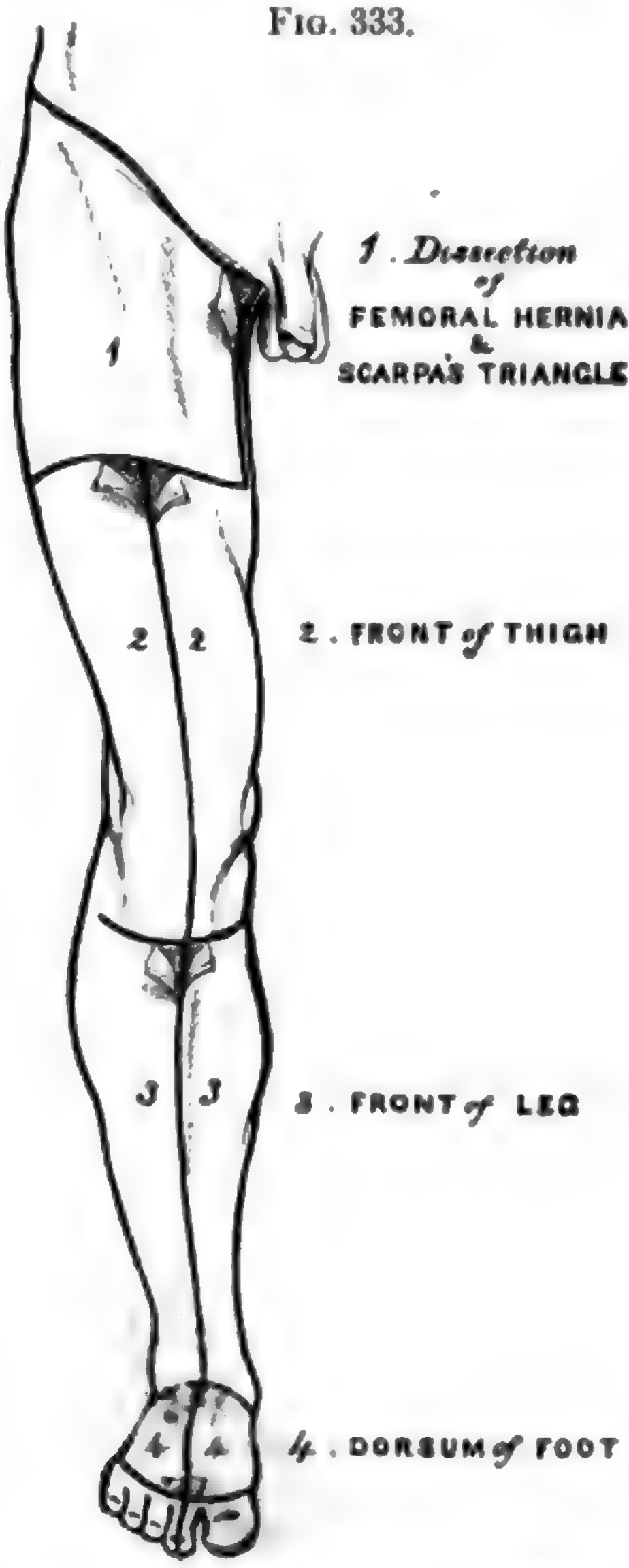
1
1. Dissection of FEMORAL HERNIA, & SCARPA'S TRIANGLE
2 2
2. FRONT of THIGH
3 3
3. FRONT of LEG
4 4
4. DORSUM of FOOT

Dissection of Lower Extremity, front view.

Remove this fascia, and the muscles of the iliac region will be exposed.

The **Psoas magnus** (Fig. 334) is a long fusiform muscle placed on the side of the lumbar region of the spine and margin of the pelvis. It

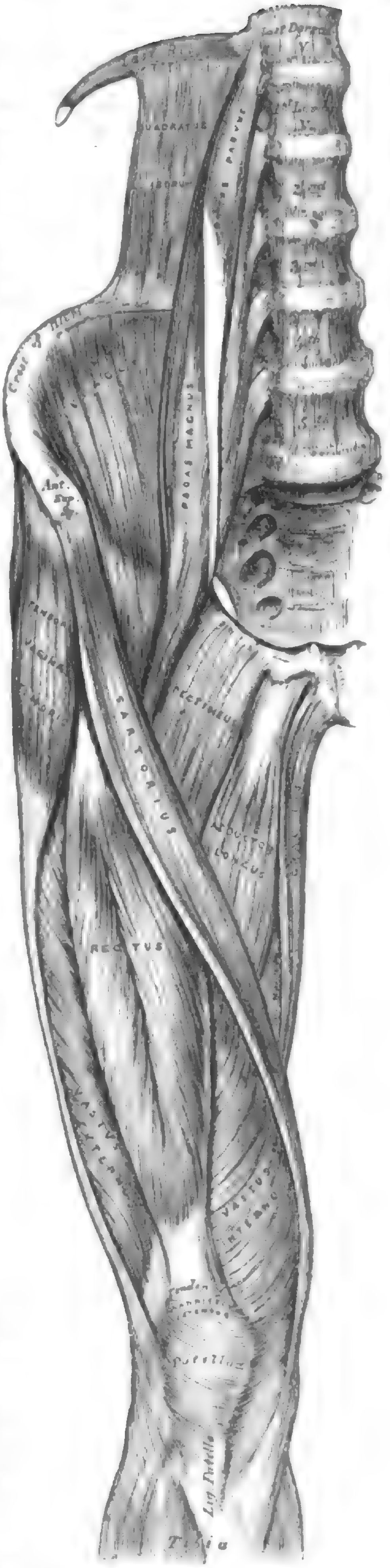
Last Dorsal
Quadratus
Lumborum
Psoas parvus
Crest of Ilium
Psoas magnus
Ant. Sup. Sp.
Tensor Vaginæ Femoris
Sartorius
Pectineus
Adductor Longus
Rectus
Vastus Externus
Vastus Internus
Tendon
Patella
Lig. Patellæ
Tibia

Fig. 334. Muscles of the Iliac and Anterior Femoral Regions.

arises from the sides of the bodies, from the corresponding intervertebral substances, and from the front of the bases of the transverse processes of the last dorsal and all the lumbar vertebræ. The muscle is connected to the bodies of the vertebræ by five slips: each slip is attached to the upper and lower margins of two vertebræ and to the intervertebral substance between them, the slips themselves being connected by the tendinous arches which extend across the constricted part of the bodies, and beneath which pass the lumbar arteries and sympathetic nerves. These tendinous arches also give origin to muscular fibres, and protect the blood-vessels and nerves from pressure during the action of the muscle. The first slip is attached to the contiguous margins of the last dorsal and first lumbar vertebræ, the last to the contiguous margins of the fourth and fifth lumbar and to the intervertebral substance. From these points the muscle passes down across the brim of the pelvis, and, diminishing gradually in size, passes beneath Poupart's ligament and terminates in a tendon, which, after receiving the fibres of the Iliacus, is inserted into the lesser trochanter of the femur.

RELATIONS IN THE LUMBAR REGION.—By its *anterior surface*, which is placed behind the peritoneum, with the iliac fascia, the ligamentum arcuatum internum, the kidney, Psoas parvus, renal vessels, ureter, spermatic vessels, genito-crural nerve, the colon, and along its pelvic border with the common and external iliac artery and vein; by its *posterior surface* with the transverse processes of the lumbar vertebræ and the Quadratus lumborum, from which it is separated by the anterior lamella of the aponeurosis of the Transversalis. The anterior crural nerve is first situated in the substance of the muscle, and emerges from its outer border at the lower part. The lumbar plexus is situated in the posterior part of the substance of the muscle. By its *inner side* the muscle is in relation with the bodies of the lumbar vertebræ, the lumbar arteries, the ganglia of the sympathetic nerve, and their branches of communication with the spinal nerves, the lumbar glands, the vena cava inferior on the right and the aorta on the left side. In the thigh it is in relation in front with the fascia lata, behind with the capsular ligament of the hip, from which it is separated by a synovial bursa which sometimes communicates with the cavity of the joint through an opening of variable size; by its *inner border* with the Pectineus and the femoral artery, which slightly overlaps it; by its *outer border* with the anterior crural nerve and Iliacus muscle.

The **Psoas parvus** is a long slender muscle placed in front of the preceding. It arises from the sides of the bodies of the last dorsal and first lumbar vertebræ, and from the intervertebral substance between them. It forms a small flat muscular bundle which terminates in a long flat tendon inserted into the ilio-pectineal eminence, and continuous, by its outer border, with the iliac fascia. This muscle is often absent, and, according to Cruveilhier, sometimes double.

RELATIONS.—It is covered by the peritoneum, and at its origin by the ligamentum arcuatum internum; it rests on the Psoas magnus.

The **Iliacus** is a flat radiated muscle which fills up the whole of the internal iliac fossa. It arises from the upper half of the iliac fossa and inner margin of the crest of the ilium; behind, from the ilio-lumbar ligament and base of the sacrum; in front, from the anterior superior and anterior inferior spinous processes of the ilium, from the notch between them, and by a few fibres from the capsule of the hip-joint. The fibres converge to be inserted into the outer side of the tendon of the Psoas, some of them being prolonged into the oblique line which extends from the lesser trochanter to the linea aspera. [These two muscles (Iliacus and Psoas magnus) are often spoken of as the "Ilio-psoas," a bicipital muscle. On bending well backward they can be felt just below Poupart's ligament, outside the femoral artery.]

RELATIONS WITHIN THE PELVIS.—By its *anterior surface* with the iliac fascia, which separates the muscle from the peritoneum, and with the external cutaneous nerve; on the right side with the cæcum; on the left side with the sigmoid flexure of the colon; by its *posterior surface* with the iliac fossa; by its *inner border* with the Psoas magnus and anterior crural nerve. In the thigh it is in relation, by its *anterior surface*, with the fascia lata, Rectus, and Sartorius; behind with the capsule of the hip-joint, a synovial bursa common to it and the Psoas magnus being interposed.

NERVES.—The Psoas magnus, and the Psoas parvus when it exists, are supplied by the anterior branches of the lumbar nerves, the Iliacus by the anterior crural.

ACTIONS.—The Psoas and Iliacus muscles, acting from above, flex the thigh upon the pelvis, and at the same time rotate the femur outward, from the obliquity of their insertion into the inner and back part of that bone. Acting from below, the femur being fixed, the muscles of both sides bend the lumbar portion of the spine and pelvis forward. They also serve to maintain the erect position by supporting the spine and pelvis upon the femur, and assist in raising the trunk when the body is in the recumbent posture.

The *Psoas parvus* is a tensor of the iliac fascia.

ANTERIOR FEMORAL REGION.

Tensor vaginæ femoris.	Vastus externus.
Sartorius.	Vastus internus.
Rectus.	Crureus.

Subcrureus.

Dissection.—To expose the muscles and fasciæ in this region, make an incision along Poupart's ligament from the spine of the ilium to the pubes; a vertical incision from the centre of this along the middle of the thigh to below the knee-joint; and a transverse incision from the inner to the outer side of the leg at the lower end of the vertical incision. The flaps of integument having been removed, the superficial and deep fasciæ should be examined. The more advanced student should commence the study of this region by an examination of the anatomy of femoral hernia and Scarpa's triangle, the incisions for the dissection of which are marked out in the accompanying figure.

FASCIÆ OF THE THIGH.

The **Superficial Fascia** forms a continuous layer over the whole of the lower extremity, consisting of areolar tissue, containing in its meshes much adipose matter, and capable of being separated into two or more layers, between which are found the superficial vessels and nerves. It varies in thickness in different parts of the limb: in the sole of the foot it is so thin as to be scarcely demonstrable, the integument being closely adherent to the deep fascia beneath, but in the groin it is thicker, and the two layers are separated from one another by the superficial inguinal glands, the internal saphenous vein, and several smaller vessels. One of these two layers, the superficial, is continuous above with the superficial fascia of the abdomen, the deep layer becoming blended with the fascia lata a little below Poupart's ligament. The deep layer of superficial fascia is intimately adherent to the margins of the saphenous opening in the fascia lata, and pierced in this situation by numerous small blood- and lymphatic vessels: hence the name *cribriform* [*cribrum*, a sieve] *fascia* which has been applied to it. Subcutaneous bursæ are found in the superficial fascia over the patella, point of the heel, and phalangeal articulations of the toes.

The **Deep Fascia** of the thigh is exposed on the removal of the superficial fascia, and is named, from its great extent, the **Fascia lata**; it forms a uniform investment for the whole of this region of the limb, but varies in thickness in different parts; thus it is thicker in the upper and outer part of the thigh, where it receives a fibrous expansion from the Gluteus maximus muscle, and the Tensor vaginæ femoris is inserted between its layers: it is very thin behind and at the upper and inner part, where it covers the Adductor muscles; and again becomes stronger around the knee, receiving fibrous expansions from the tendon of the Biceps externally, and from the Sartorius, Gracilis, Semitendinosus, and Quadriceps extensor cruris in front. The fascia lata is attached above and behind to the back of the sacrum and coccyx; externally, to the crest of the ilium; in front, to Poupart's ligament and to the body and ramus of the pubes; and internally, to the descending ramus of the pubes, to the ascending ramus and tuberosity of the ischium, and to the lower border of the great sacro-sciatic ligament. From its attachment to the crest of the ilium it passes down over the Gluteus medius muscle to the upper border of the Gluteus maximus, where it splits into two layers, one passing superficial to and the other beneath this muscle. At the lower border of the muscle the two layers unite, and externally, just behind the great trochanter, receive the greater part of the tendon of insertion of the Gluteus maximus, and become proportionally thickened. The portion of the fascia lata arising from the front part of the crest of the ilium, corresponding to the origin of the Tensor vaginæ femoris, passes down the outer side of the thigh as two layers, one superficial and the other beneath this muscle; these at its lower border become blended together into a thick and strong band, having first received the insertion of the muscle. This band is continued downward, under the name of the *ilio-tibial band*, to be inserted into the external tuberosity of the tibia and the head of the fibula. Below, the fascia lata is attached to all the prominent points around the knee-joint—viz. the condyles of the femur, tuberosities of the tibia, and head of the fibula. From the inner surface of the fascia lata are given off two strong intermuscular septa which are attached to the whole length of the linea aspera: the external and stronger one, which extends from the insertion of the Gluteus maximus to the outer condyle, separates the Vastus externus in front from the short head of the Biceps behind, and gives partial origin to those muscles; the internal one, the thinner of the two, separates the Vastus internus from the Adductor muscles. Besides these there are numerous smaller septa separating the individual muscles and enclosing each in a distinct sheath. At the upper and inner part of the thigh, a little below Poupart's ligament, a large oval-shaped aperture is observed after the superficial fascia has been cleared off: it transmits the internal saphenous vein and other smaller vessels, and is termed the *saphenous opening*. In order more correctly to consider the mode of formation of this aperture, the fascia lata is described as consisting, in this part of the thigh, of two portions, an iliac portion and a pubic portion.

The *iliac portion* is all that part of the fascia lata on the outer side of the saphenous opening. It is attached externally to the crest of the ilium, and its anterior superior spine to the whole length of Poupart's ligament as far internally as the spine of the pubes, and to the pectineal line in conjunction with Gimbernat's ligament. From the spine of the pubes it is reflected downward and outward, forming an arched margin, the *falciform border* [*falx*, a scythe] or outer boundary of the saphenous opening: this margin overlies and is adherent to the anterior layer of the sheath of the femoral vessels; to its edge is attached the cribriform fascia and below it is continuous with the pubic portion of the fascia lata.

The *pubic portion* is situated at the inner side of the saphenous opening; at the lower margin of this aperture it is continuous with the iliac portion [passing in front of the vessels]; traced upward, it is seen to cover the surface of the Pectineus muscle, and, passing behind the sheath of the femoral vessels, to which it is closely united, is continuous with the sheath of the Psoas and Iliacus muscles, and is attached above to the ilio-pectineal line and becomes continuous with the iliac fascia. From this description it may be observed that the iliac portion of the fascia lata passes in front of the femoral vessels, and the pubic portion behind them, so that an apparent aperture exists between the two, through which the internal saphenous joins the femoral vein.[1]

The fascia should now be removed from the surface of the muscles. This may be effected by pinching it up between the forceps, dividing it, and separating it from each muscle in the course of its fibres.

The Tensor vaginæ femoris arises from the anterior part of the outer lip of the crest of the ilium, and from the outer surface of the anterior superior spinous process between the Gluteus medius and Sartorius. It is inserted into the fascia lata about one-fourth down the outer side of the thigh. From the point of insertion the fascia is continued downward to the head of the tibia as a thickened band, the *ilio-tibial band.* [If the two hands are placed on these muscles, and the weight thrown on each leg alternately by a rocking motion, they can easily be felt. By standing on one leg the furrow of the ilio-tibial band can often be seen, especially in female models.]

---

[1] These parts will be again more particularly described with the anatomy of Hernia.

Relations.—By its *superficial surface* with the fascia lata and the integument; by its *deep surface* with the Gluteus medius, Rectus femoris, Vastus externus, and the ascending branches of the external circumflex artery: by its *anterior border* with the Sartorius, from which it is separated below by a triangular space in which is seen the Rectus femoris; by its *posterior border* with the Gluteus medius.

The **Sartorius** [*sartor*, a tailor], the longest muscle in the body, is flat, narrow, and ribbon-like: it arises by tendinous fibres from the anterior superior spinous process of the ilium and the upper half of the notch below it, passes obliquely across the upper and anterior part of the thigh from the outer to the inner side of the limb, then descends vertically as far as the inner side of the knee, passing behind the inner condyle of the femur, and terminates in a tendon which, curving obliquely forward, expands into a broad aponeurosis inserted into the upper part of the inner surface of the shaft of the tibia nearly as far forward as the crest. This expansion is inserted into the bone by an inverted U-shaped aponeurosis; part of it is inserted behind the attachment of the Gracilis and Semitendinosus, and another part, arching over the upper border of the tendon of the Gracilis, is inserted into the tibia in front of these muscles. An offset is derived from the upper margin of this aponeurosis which blends with the fibrous capsule of the knee-joint, and another, given off from its lower border, blends with the fascia on the inner side of the leg. [The muscle can be obscurely seen in outline. Its borders, especially the inner, are marked by furrows.] The relations of this muscle to the femoral artery should be carefully examined, as its inner border forms the chief guide in tying the artery. In the upper third of the thigh it forms the outer side of a triangular space, *Scarpa's triangle*, the inner side of which is formed by the Adductor longus, and the base, turned upward, by Poupart's ligament; the femoral artery passes perpendicularly through the middle of this space from its base to its apex. In the middle third of the thigh the femoral artery lies first along the inner border, and then behind the Sartorius.

Relations.—By its *superficial surface* with the fascia lata and integument; by its *deep surface* with the Iliacus, Psoas, Rectus, Vastus internus, anterior crural nerve, sheath of the femoral vessels, Adductor longus, Adductor magnus, Gracilis, long saphenous nerve, and internal lateral ligament of the knee-joint.

The **Quadriceps extensor** [**cruris**] includes the four remaining muscles on the front of the thigh. It is the great Extensor muscle of the leg, forming a large fleshy mass which covers the front and sides of the femur, being united below into a single tendon attached to the patella, and above subdividing into separate portions, which have received distinct names. Of these, one occupying the middle of the thigh, connected above with the ilium, is called the *Rectus femoris*, from its straight course. The other divisions lie in immediate connection with the shaft of the femur, which they cover from the condyles to the trochanters. The portion on the outer side of the femur is termed the *Vastus externus;* that covering the inner side, the *Vastus internus;* and that covering the front of the femur, the *Crureus.* The two latter portions are, however, so intimately blended as to form but one muscle.

The **Rectus femoris** is situated in the middle of the anterior region of the thigh; it is fusiform in shape, and its superficial fibres are arranged in a bipenniform manner, the deep fibres running straight down to the deep aponeurosis. It arises by two tendons: one, the straight tendon or short head, from the anterior inferior spinous process of the ilium; the other is flattened and curves outward to be attached to a groove above the brim of the acetabulum; this is the reflected tendon or long head of the Rectus; it unites with the straight tendon at an acute angle, and then spreads into an aponeurosis from which the muscular fibres arise.[1]

---

[1] Mr. W. R. Williams, in an interesting paper in the *Journ. of Anat. and Phys.*, vol. xiii. p. 204, points out that the reflected tendon is the real origin of the muscle, and is alone present in early

The muscle terminates in a broad and thick aponeurosis which occupies the lower two-thirds of its posterior surface, and, gradually becoming narrowed into a flattened tendon, is inserted into the patella in common with the Vasti and Crureus. [This tendon of the Rectus produces the very marked suprapatellar flat, especially well seen in the model when the muscle is called into vigorous action by attempted over-extension of the leg.]

Relations.—By its *superficial surface* with the anterior fibres of the Gluteus minimus, the Tensor vaginæ femoris, Sartorius, and the Psoas and Iliacus; by its lower three-fourths with the fascia lata; by its *posterior surface* with the hip-joint, the external circumflex vessels, and the Crureus and Vasti muscles.

The three remaining muscles have been described collectively by some anatomists, separate from the Rectus, under the name of the *Triceps extensor cruris*. In order to expose them divide the Sartorius and Rectus across the middle and turn them aside, when the muscles in question will be fully brought into view.

The **Vastus externus** is the largest part of the Quadriceps extensor. It arises by a broad aponeurosis which is attached to the tubercle of the femur, to the anterior border of the great trochanter, to a horizontal ridge on its outer surface, to a rough line leading from the trochanter major to the linea aspera, and to the whole length of the outer lip of the linea aspera: this aponeurosis covers the upper three-fourths of the muscle, and from its inner surface many fibres arise. A few additional fibres arise from the tendon of the Gluteus maximus and from the external intermuscular septum between the Vastus externus and short head of the Biceps. The fibres form a large fleshy mass which is attached to a strong aponeurosis placed on the under surface of the muscle at its lower part: this becomes contracted and thickened into a flat tendon, which is inserted into the outer border of the patella, blending with the great extensor tendon.

Relations.—By its *superficial surface* with the Rectus, the Tensor vaginæ femoris, the fascia lata, and the Gluteus maximus, from which it is separated by a synovial bursa; by its *deep surface* with the Crureus, some large branches of the external circumflex artery and anterior crural nerve being interposed.

[Fig. 335.

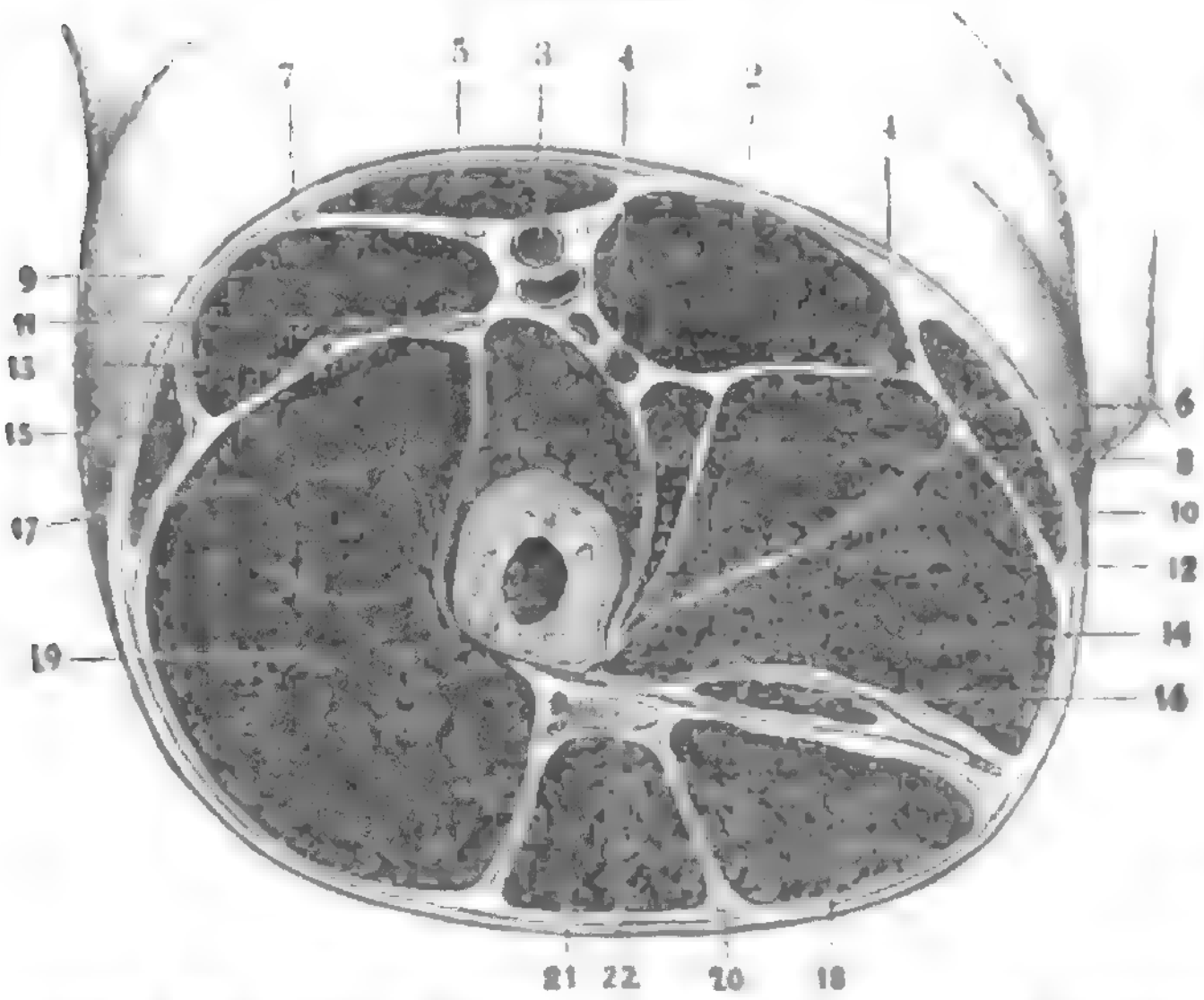

Section of the Right Thigh at the Apex of Scarpa's Triangle (drawn by G. E. Pearse): 1, profunda vessels; 2, Adductor longus; 3, femoral vessels; 4, superficial obturator nerve; 5, Sartorius; 6, Gracilis; 7, external cutaneous nerve; 8, Pectineus; 9, Rectus femoris; 10, Adductor brevis; 11, anterior crural nerve; 12, deep obturator nerve; 13, external circumflex vessels; 14, Adductor magnus; 15, Tensor vaginæ femoris; 16, Semimembranosus; 17, Vastus internus and crureus; 18, Semitendinosus; 19, Vastus externus; 20, small sciatic nerve; 21, Biceps femoris; 22, great sciatic nerve (Heath).]

The **Vastus internus** and the **Crureus** are so inseparably connected together as to form but one muscle, as which it will be accordingly described. It is the smallest portion of the Quadriceps extensor. The anterior portion of it, covered by the Rectus, is called the Crureus; the internal portion, which lies immediately beneath the fascia lata, the Vastus internus. It arises by an aponeurosis which is attached to the lower part of the line that extends from the inner side of the neck of the femur to the linea aspera, from the whole length of the inner lip of the linea aspera, from the ridge leading from the linea aspera to the internal condyle and internal intermuscular septum. It also arises from nearly the whole of the internal, anterior, and external surfaces of the shaft of the femur, limited above by the line between the two trochanters, and

---

fœtal life. The direct tendon is merely an accessory band of condensed fascia. The paper will well repay perusal, though in some particulars I think the description in the text more generally accurate.—Ed.

extending below to within the lower fourth of the bone. From these different origins the fibres converge to a broad aponeurosis which covers the anterior surface of the middle portion of the muscle (the Cruieus) and the deep surface of the inner division of the muscle (the Vastus internus), and which gradually narrows down to its insertion into the patella, where it blends with the other portions of the Quadriceps extensor. The muscular fibres of the Vastus internus extend lower down than those of the Vastus externus, so that the capsule of the joint is less covered with muscular fibres on the outer than on the inner side. [The structure of the Quadriceps muscles is an excellent illustration of adaptation for great strength and short range of action. (See p. 362.) The relation of the fibres to the patella is important. Those of the Vastus externus run down obliquely, and its belly terminates well above the patella. The belly of the Vastus internus extends almost to the lower border of the patella, its lower fibres running horizontally, and so directly opposing external dislocation, the very one to which the patella is most exposed by the angle at the knee. When the model attempts over-extension of the leg, and so calls the Quadriceps into violent action, the Vastus internus shows as a triangular roll between the Rectus and the Sartorius.]

Relations.—By its *superficial surface* with the Psoas and Iliacus, the Rectus, Sartorius, Pectineus, Adductors, and fascia lata, femoral vessels, and saphenous nerve; by its *deep surface* with the femur, Subcrureus, and synovial membrane of the knee-joint.

The student will observe the striking analogy that exists between the Quadriceps extensor and the Triceps muscle in the upper extremity. So close is this similarity that M. Cruveilhier has described it under the name of the *Triceps femoralis.* Like the Triceps extensor cubiti, it consists of three distinct divisions or heads: a middle or long head [the Rectus], analogous to the long head of the Triceps, attached to the ilium; and two other portions, which may be called the external and internal heads of the Triceps femoralis. These, it will be noticed, are strictly analogous to the outer and inner heads of the Triceps in the arm.

The *tendons* of the different portions of the Quadriceps extensor unite at the lower part of the thigh so as to form a single strong tendon, which is inserted into the upper part of the patella. More properly, the patella may be regarded as a sesamoid bone developed in the tendon of the Quadriceps, and the ligamentum patellæ, which is continued from the lower part of the patella to the tubercle of the tibia, as the proper tendon of insertion of the muscle. A synovial bursa [the *subpatellar bursa*] is interposed between the tendon and the upper part of the tubercle of the tibia [and another and more important one exists in front of the patella itself—the *prepatellar bursa*, which is involved in "housemaid's knee" (Fig. 273, p. 350)]. From the tendons corresponding to the Vasti a fibrous prolongation is derived, which is attached below to the upper extremities of the tibia and fibula, and which serves to protect the knee-joint, being strengthened on its outer side by the fascia lata.

The **Subcrureus** is a small muscle, usually distinct from the Crureus, but occasionally blended with it, which arises from the anterior surface of the lower part of the shaft of the femur, and is inserted into the upper part of the synovial pouch that extends upward from the knee-joint behind the patella. It sometimes consists of two separate muscular bundles.

Nerves.—The Tensor vaginæ femoris is supplied by the superior gluteal nerve, the other muscles of this region by branches from the anterior crural.

Actions.—The Tensor vaginæ femoris is a tensor of the fascia lata: continuing its action, the oblique direction of its fibres enables it to rotate the thigh inward. In the erect posture, acting from below, it will serve to steady the pelvis upon the head of the femur, and by means of the ilio-tibial band it steadies the condyles of the femur on the articular surfaces of the tibia, and assists the Gluteus maximus in supporting the knee in the extended position. The Sartorius flexes the leg upon the thigh, and, continuing to act, flexes the thigh upon the pelvis; it next rotates the thigh outward. It was formerly supposed to adduct the thigh so as to cross one leg over the other, and hence received its name of Sartorius, or tailor's muscle (*sartor*, a tailor), because it was supposed to assist in crossing the legs in the squatting position. When the knee is bent the Sartorius assists the Semitendinosus and Popliteus in rotating the tibia inward. Taking its fixed point from the leg, it flexes the pelvis upon the thigh, and, if one muscle acts, assists in rotating the pelvis. The Quadriceps extensor extends the leg upon the thigh. Taking its fixed point from the leg, as in standing, this muscle will act upon the femur, supporting it perpendicularly upon the head of the tibia, and thus maintaining the entire weight of the body. [In going up stairs it brings the flexed femur into a straight line with the tibia (extends the femur), and so lifts the body; and in going down stairs, stooping to make a courtesy, etc., it holds the femur, and lets it yield gradually in flexion instead of suddenly.] The Rectus muscle assists the Psoas and Iliacus in supporting the pelvis and trunk upon the femur or in bending it forward.

INTERNAL FEMORAL REGION.

Gracilis.	Adductor longus.
Pectineus.	Adductor brevis.

Adductor magnus.

Dissection.—These muscles are at once exposed by removing the fascia from the fore part and inner side of the thigh. The limb should be abducted, so as to render the muscles tense and easier of dissection.

The **Gracilis** (Figs. 334, 338) is the most superficial muscle on the inner side of the thigh. It is thin and flattened, broad above, narrow and tapering below. It arises by a thin aponeurosis between two and three inches in breadth from the inner margin of the ramus of the pubes and ischium. The fibres pass vertically downward, and terminate in a rounded tendon which passes behind the internal condyle of the femur, and, curving round the inner tuberosity of the tibia, becomes flattened, and is inserted into the upper part of the inner surface of the shaft of the tibia below the tuberosity. The tendon of this muscle is situated immediately above that of the Semitendinosus, and is surrounded by the tendon of the Sartorius, with which it is in part blended. As it passes across the internal lateral ligament of the knee-joint it is separated from it by a synovial bursa common to it and the Semitendinosus muscle.

RELATIONS.—By its *superficial surface* with the fascia lata and the Sartorius below; the internal saphenous vein crosses it obliquely near its lower part, lying superficial to the fascia lata. The internal saphenous nerve emerges between its tendon and that of the Sartorius. By its *deep surface* with the three Adductors and the internal lateral ligament of the knee-joint.

The **Pectineus** (Fig. 334) is a flat, quadrangular muscle situated at the anterior part of the upper and inner aspect of the thigh. It arises from the linea ilio-pectinea, from the surface of bone in front of it between the pectineal eminence and spine of the pubes, and from a tendinous prolongation of Gimbernat's ligament, which is attached to the crest of the pubes and is continuous with the fascia covering the anterior surface of the muscle; the fibres pass downward, backward, and outward to be inserted into a rough line leading from the trochanter minor to the linea aspera.

RELATIONS.—By its *anterior surface* with the pubic portion of the fascia lata, which separates it from the femoral vessels and internal saphenous vein; by its *posterior surface* with the hip-joint, the Adductor brevis and Obturator externus muscles, the obturator vessels and nerve being interposed; by its *outer border* with the Psoas, a cellular interval separating them, through which passes the internal circumflex artery; by its *inner border* with the margin of the Adductor longus.

The **Adductor longus**, the most superficial of the three Adductors, is a flat triangular muscle lying on the same plane as the Pectineus, with which it is often blended above. It arises by a flat narrow tendon from the front of the pubes, at the angle of junction of the crest with the symphysis, and soon expands into a broad fleshy belly, which, passing downward, backward, and outward, is inserted by an aponeurosis into the middle third of the linea aspera, between the Vastus internus and the Adductor magnus.

Relations.—By its *anterior surface* with the fascia lata, and near its insertion with the femoral artery and vein; by its *posterior surface* with the Adductor brevis and magnus, the anterior branches of the obturator vessels and nerve, and with the profunda artery and vein near its insertion; by its *outer border* with the Pectineus; by its *inner border* with the Gracilis.

The Pectineus and Abductor longus should now be divided near their origin and turned downward, when the Adductor brevis and Obturator externus will be exposed.

The **Adductor brevis** is situated immediately behind the two preceding muscles. It is somewhat triangular in form, and arises by a narrow origin from the outer surface of the descending ramus of the pubes, between the Gracilis and Obturator externus. Its fibres, passing backward, outward, and downward, are inserted by an aponeurosis into the lower part of the line leading from the lesser trochanter to the linea aspera and the upper part of the linea aspera, immediately behind the Pectineus and upper part of the Adductor longus. [The tendon of origin of these two Adductors can easily be felt and seen by putting them into action or by merely separating the thighs widely.]

Relations.—By its *anterior surface* with the Pectineus, Adductor longus, and anterior branches of the obturator vessels and nerve; by its *posterior surface* with the Adductor magnus and posterior branches of the obturator vessels and nerve; by its *outer border* with the Obturator externus and conjoined tendon of the Psoas and Iliacus; by its *inner border* with the Gracilis and Adductor magnus. This muscle is pierced near its insertion by the middle perforating branch of the profunda artery.

The Abductor brevis should now be cut away near its origin and turned outward, when the entire extent of the Abductor magnus will be exposed.

Fig. 336

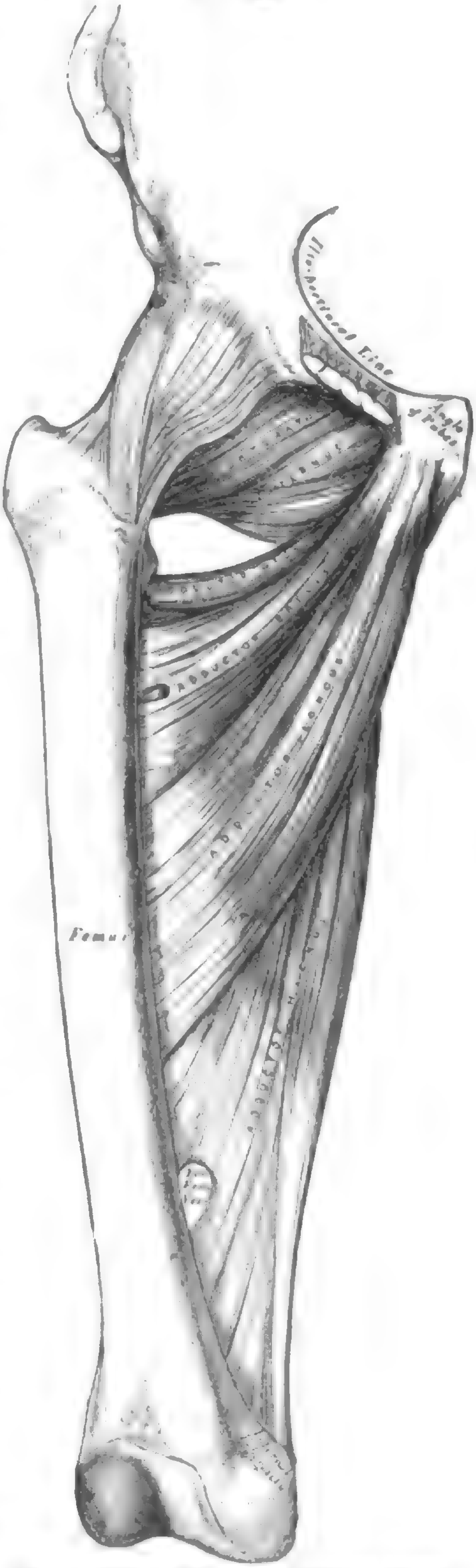

Deep Muscles of the Internal Femoral Region.

The **Adductor magnus** is a large triangular muscle forming a septum between the muscles on the inner and those on the back of the thigh. It arises from a small part of the descending ramus of the pubes, from the ascending ramus of the ischium, and from the outer margin and under surface of the tuberosity of the ischium. Those fibres which arise from the ramus of the pubes are very short, horizontal in direction, and are inserted into the rough line leading from the great trochanter to the linea aspera, internal to the Gluteus maximus; those from the ramus of the ischium are directed downward and outward with different degrees of obliquity, to be inserted, by means of a broad aponeurosis, into the whole length of the linea aspera and the upper part of its internal bifurcation below. The internal portion of the muscle, consisting principally of those fibres which arise from the tuberosity of the ischium, forms a thick fleshy mass consisting of coarse bundles which descend almost vertically, and terminate about the lower third of the thigh in a rounded tendon, which is inserted into the tubercle above the inner condyle of the femur, being connected by a fibrous expansion to the line leading upward from the tubercle to the linea aspera. Between the two portions of the muscle an angular interval is left, tendinous in front, fleshy behind, for the passage of the femoral vessels into the popliteal space. The external portion of the muscle at its attachment to the femur presents three or four osseo-aponeurotic openings formed by tendinous arches attached to the bone, from which muscular fibres arise. The three superior of these apertures are for the three perforating arteries, and the fourth, when it exists, for the terminal branch of the profunda. This muscle gives off an aponeurosis which passes in front of the femoral vessels and joins with the Vastus internus, forming the covering of Hunter's canal.

RELATIONS.—By its *anterior surface* with the Pectineus, Adductor brevis, Adductor longus, and the femoral vessels; by its *posterior surface* with the great sciatic nerve, the Gluteus maximus, Biceps, Semitendinosus, and Semimembranosus; by its *superior* or *shortest border* it lies parallel with the Quadratus femoris, the internal circumflex artery passing between them; by its *internal* or *longest border*, with the Gracilis, Sartorius, and fascia lata; by its *external* or *attached border* it is inserted into the femur behind the Adductor brevis and Adductor longus, which separate it from the Vastus internus, and in front of the Gluteus maximus and short head of the Biceps, which separate it from the Vastus externus.

NERVES.—All the muscles of this group are supplied by the obturator nerve. The Pectineus receives additional branches from the accessory obturator and anterior crural, and the Adductor magnus an additional branch from the great sciatic.

ACTIONS.—The Pectineus and three Adductors adduct the thigh powerfully; they are especially used in horse exercise, the sides of the horse being grasped between the knees by the action of these muscles. In consequence of the obliquity of their insertion into the linea aspera, they rotate the thigh outward, assisting the external Rotators, and when the limb has been abducted they draw it inward, carrying the thigh across that of the opposite side. The Pectineus and Adductor brevis and longus assist the Psoas and Iliacus in flexing the thigh upon the pelvis. In progression also all these muscles assist in drawing forward the hinder limb. The Gracilis assists the Sartorius in flexing the leg and rotating it inward; it is also an Adductor of the thigh. If the lower extremities are fixed, these muscles may take their fixed point from below and act upon the pelvis, serving to maintain the body in an erect posture, or, if their action is continued, to flex the pelvis forward upon the femur.

GLUTEAL REGION.

Gluteus maximus.
Gluteus medius.
Gluteus minimus.
Pyriformis.
Gemellus superior.
Obturator internus.
Gemellus inferior.
Obturator externus.
Quadratus femoris.

Dissection (Fig. 337).—The subject should be turned on its face, a block placed beneath the pelvis to make the buttocks tense, and the limbs allowed to hang over the end of the table with the foot inverted and the thigh abducted. Make an incision through the integument along the back part of the crest of the ilium and margin of the sacrum to the tip of the coccyx, and carry a second incision from that point obliquely downward and outward to the outer side of the thigh, four inches below the great trochanter. The portion of integument included between these incisions, together with the superficial fascia, is to be removed in the direction shown in the figure, when the Gluteus maximus and the dense fascia covering the Gluteus medius will be exposed.

FIG. 337.

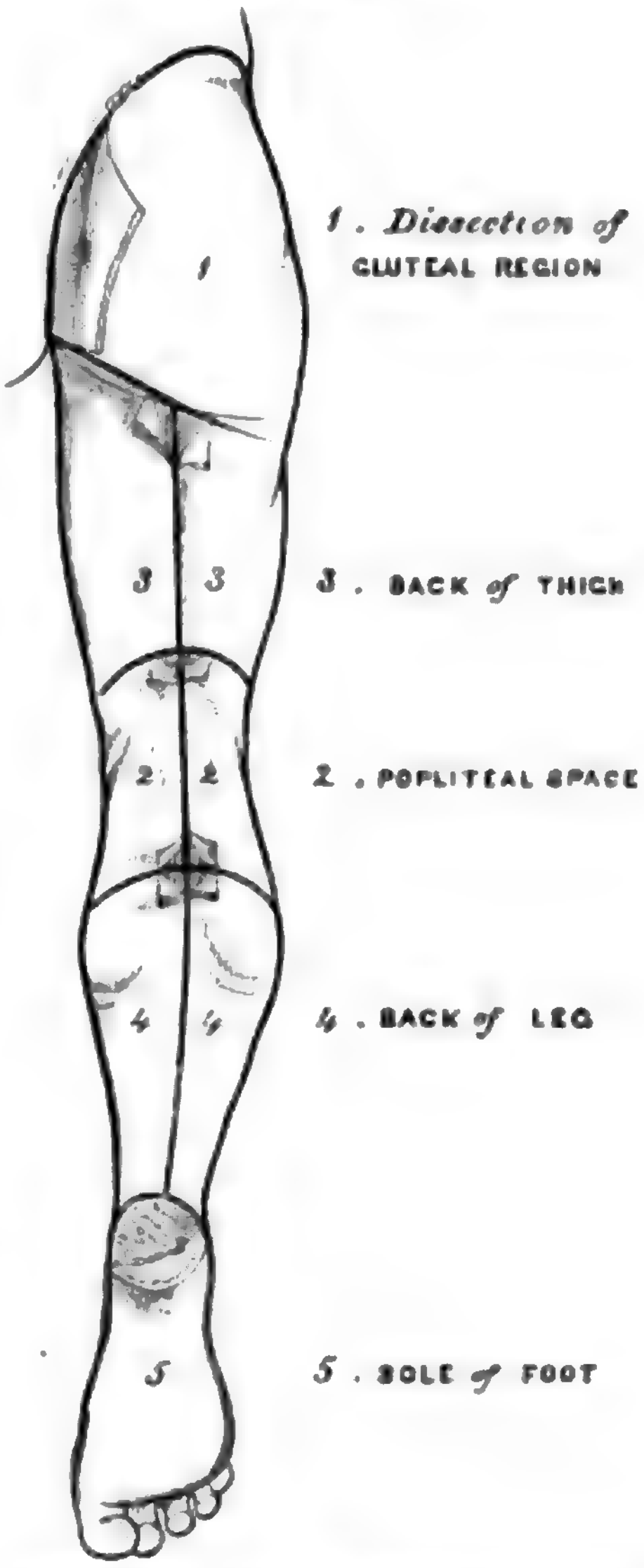

Dissection of Lower Extremity, posterior view.

The **Gluteus maximus** (Fig. 338), the most superficial muscle in the gluteal region, is a very broad and thick fleshy mass, of a quadrilateral shape, which forms the prominence of the nates. Its large size is one of the most characteristic points in the muscular system in man, connected as it is with the power he has of maintaining the trunk in the erect posture. In structure the muscle is remarkably coarse, being made up of muscular fasciculi lying parallel with each other and collected together into large bundles, separated by deep cellular intervals. It arises from the superior curved line of the ilium and the portion of bone, including the crest, immediately behind it—from the posterior surface of the lower part of the sacrum, the side of the coccyx, the aponeurosis of the Erector spinæ muscle, and the great sacro-sciatic ligament. The fibres are directed obliquely downward and outward: those forming the upper and larger portion of the muscle (after converging somewhat) terminate in a thick tendinous lamina, which passes across the great trochanter and is inserted into the fascia lata covering the outer side of the thigh, the lower portion of the muscle being inserted into the rough line leading from the great trochanter to the linea aspera between the Vastus externus and Adductor magnus.

[There is well seen in the living model, when this muscle is contracted, a great dimple or hollow corresponding to the tendon of the Gluteus maximus. At its anterior border the great trochanter is felt. The lower border of this muscle overhangs the thigh and forms the "*gluteo-femoral crease.*" This crease or groove undergoes marked modifications as the model changes the position of his leg, especially in flexion and extension. Hence its value in the diagnosis of coxalgia.]

Three *synovial bursæ* are usually found separating the under surface of this muscle from the eminences which it covers. One of these, of large size and generally multilocular, separates it from the great trochanter. A second, often wanting, is situated on the tuberosity of the ischium. A third is found between the tendon of this muscle and the Vastus externus.

RELATIONS.—By its *superficial surface* with a thin fascia which separates it from the subcutaneous tissue; by its *deep surface*, from above downward, with the ilium, sacrum, coccyx, and great sacro-sciatic ligament, part of the Gluteus medius, Pyriformis, Gemelli, Obturator internus, Quadratus femoris, the tuberosity of the ischium, great trochanter, the origin of the Biceps, Semitendinosus, Semimembranosus, and Adductor magnus muscles. The gluteal vessels and superior gluteal nerve are seen issuing from the pelvis above the Pyriformis muscle, the sciatic and internal pudic vessels and nerves, and the nerve to the Obturator internus muscle below it. Its *upper border* is thin, and connected with the Gluteus medius by the fascia lata. Its *lower border* is free and prominent.

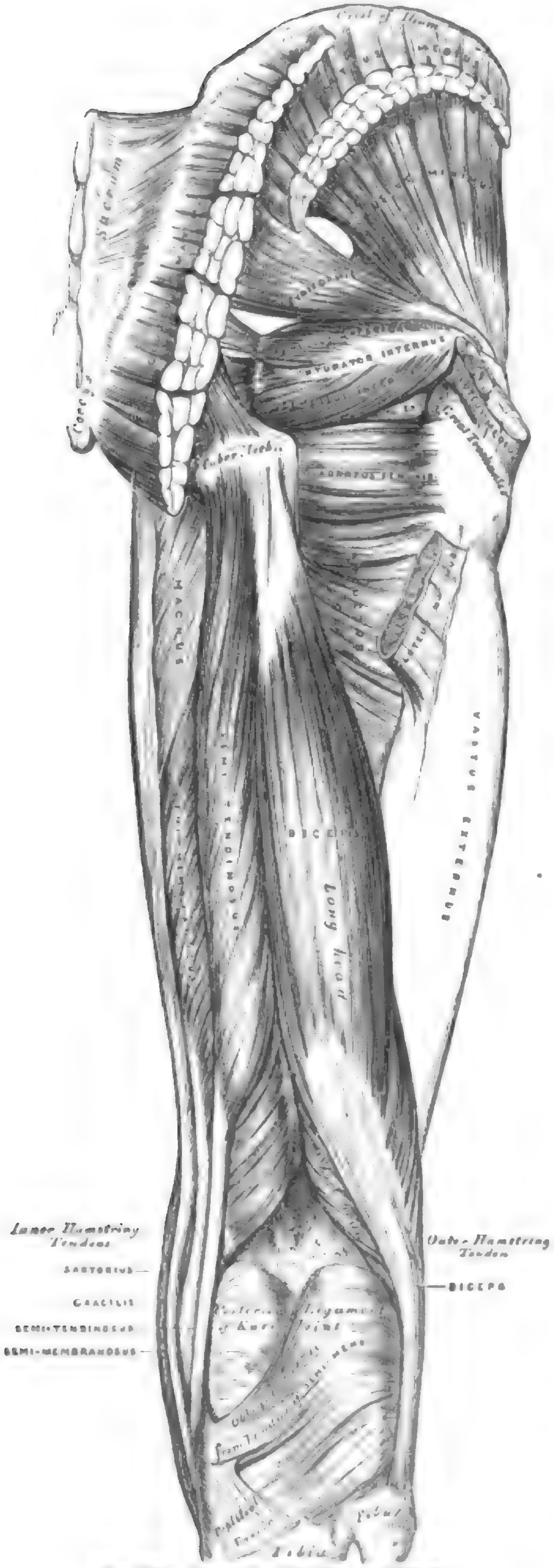
Crest of Ilium
Sacrum
Coccyx
Tuber. Isch.
OBTURATOR INTERNUS
MAGNUS
VASTUS EXTERNUS
SEMI-TENDINOSUS
BICEPS
Long head
Inner Hamstring Tendons
SARTORIUS
GRACILIS
SEMI-TENDINOSUS
SEMI-MEMBRANOSUS
Outer Hamstring Tendon
BICEPS
Posterior Ligament of Knee Joint
Tibia
Fibula

FIG. 338. Muscles of the Hip and Thigh.

Dissection.—Now divide the Gluteus maximus near its origin by a vertical incision carried from its upper to its lower border; a cellular interval will be exposed separating it from the Gluteus medius and External rotator muscles beneath. The upper portion of the muscle is to be altogether detached, and the lower portion turned outward: the loose areolar tissue filling up the interspace between the trochanter major and tuberosity of the ischium being removed, the parts already enumerated as exposed by the removal of this muscle will be seen.

The **Gluteus medius** is a broad, thick, radiated muscle situated on the outer surface of the pelvis. Its posterior third is covered by the Gluteus maximus, its anterior two-thirds by the fascia lata, which separates it from the integument. It arises from the outer surface of the ilium, between the superior and middle curved lines, and from the outer lip of that portion of the crest which is between them; it also arises from the dense fascia (gluteal aponeurosis) covering its anterior part. The fibres converge to a strong flattened tendon which is inserted into the oblique line which traverses the outer surface of the great trochanter. A synovial bursa separates the tendon of the muscle from the surface of the trochanter in front of its insertion.

RELATIONS.—By its *superficial surface* with the Gluteus maximus behind, the Tensor vaginæ femoris and deep fascia in front; by its *deep surface* with the Gluteus minimus and the gluteal vessels and superior gluteal nerve. Its *anterior border* is blended with the Gluteus minimus. Its *posterior border* lies parallel with the Pyriformis, the gluteal vessels intervening.

This muscle should now be divided near its insertion and turned upward, when the Gluteus minimus will be exposed.

The **Gluteus minimus**, the smallest of the three Glutei, is placed immediately beneath the preceding. It is fan-shaped, arising from the outer surface of the ilium between the middle and inferior curved lines, and behind from the margin of the great sacro-sciatic notch: the fibres converge to the deep surface of a radiated aponeurosis, which, terminating in a tendon, is inserted into an impression on the anterior border of the great trochanter. A synovial bursa is interposed between the tendon and the great trochanter.

Relations.—By its *superficial surface* with the Gluteus medius and the gluteal vessels and superior gluteal nerve; by its *deep surface* with the ilium, the reflected tendon of the Rectus femoris, and capsular ligament of the hip-joint. Its *anterior margin* is blended with the Gluteus medius. Its *posterior margin* is often joined with the tendon of the Pyriformis.

The **Pyriformis** is a flat muscle, pyramidal in shape, lying almost parallel with the posterior margin of the Gluteus medius. It is situated partly within the pelvis at its posterior part, and partly at the back of the hip-joint. It arises from the front of the sacrum by three fleshy digitations attached to the portions of bone between the first, second, third, and fourth anterior sacral foramina, and also from the grooves leading from the foramina: a few fibres also arise from the margin of the great sacro-sciatic foramen and from the anterior surface of the great sacro-sciatic ligament. The muscle passes out of the pelvis through the great sacro-sciatic foramen, the upper part of which it fills, and is inserted by a rounded tendon into the upper border of the great trochanter, being generally blended with the tendon of the Obturator internus.

Relations.—By its *anterior surface, within the pelvis*, with the Rectum (especially on the left side), the sacral plexus of nerves, and the internal iliac vessels; *external to the pelvis*, with the os innominatum and capsular ligament of the hip-joint; by its *posterior surface, within the pelvis*, with the sacrum, and *external to it* with the Gluteus maximus; by its *upper border*, with the Gluteus medius, from which it is separated by the gluteal vessels and superior gluteal nerve; by its *lower border* with the Gemellus superior and Coccygeus, the sciatic vessels and nerves, the internal pudic vessels and nerve, and muscular branches from the sacral plexus passing from the pelvis in the interval between the two muscles.

The **Obturator membrane** is a dense layer of interlacing fibres which completely closes the obturator foramen except at its upper and outer part, where a small oval canal is left for the obturator vessels and nerve. Each Obturator muscle is connected with this membrane.

Dissection.—The next muscle, as well as the origin of the Pyriformis, can only be seen when the pelvis is divided and the viscera removed.

The **Obturator internus**, like the preceding muscle, is situated partly within the cavity of the pelvis, partly at the back of the hip-joint. It arises from the inner surface of the anterior and external wall of the pelvis, around the inner side of the obturator foramen, being attached to the descending ramus of the pubes and the ascending ramus of the ischium, and at the side to the inner surface of the body of the ischium, between the margin of the obturator foramen in front, the great sacro-sciatic notch behind, and the brim of the true pelvis above. It also arises from the inner surface of the obturator membrane except at its lower part, and from the tendinous arch which completes the canal for the passage of the obturator vessels and nerve. The fibres are directed backward and downward, and terminate in four or five tendinous bands which are found on its deep surface; these bands are reflected at a right angle over the inner surface of the tuberosity of the ischium, which is grooved for their reception: the groove is covered with cartilage and lined with a synovial bursa. The muscle leaves the pelvis by the lesser sacro-sciatic notch, and the tendinous bands unite into a single flattened tendon, which passes horizontally outward, and, after receiving the attachment of the Gemelli, is inserted into the upper border of the great trochanter in front of the Pyriformis. A synovial bursa, narrow and elongated in form, is usually found between the tendon of this muscle and the capsular ligament of the hip: it occasionally communicates with the bursa between the tendon and the tuberosity of the ischium, the two forming a single sac.

In order to display the peculiar appearances presented by the tendon of this muscle, it must be divided near its insertion and reflected outward.

RELATIONS.—*Within the pelvis* this muscle is in relation, by its *anterior surface,* with the obturator membrane and inner surface of the anterior wall of the pelvis; by its *posterior surface* with the pelvic and obturator fasciæ, which separate it from the Levator ani; and it is crossed by the internal pudic vessels and nerve. This surface forms the outer boundary of the ischio-rectal fossa. *External to the pelvis* it is covered by the great sciatic nerve and Gluteus maximus, and rests on the back part of the hip-joint.

The **Gemelli** are two small muscular fasciculi accessories to the tendon of the Obturator internus, which is received into a groove between them. They are called *superior and inferior.*

The **Gemellus superior,** the smaller of the two, arises from the outer surface of the spine of the ischium, and, passing horizontally outward, becomes blended with the upper part of the tendon of the Obturator internus, and is inserted with it into the upper border of the great trochanter. This muscle is sometimes wanting.

RELATIONS.—By its *superficial surface* with the Gluteus maximus and the sciatic vessels and nerves; by its *deep surface* with the capsule of the hip-joint; by its *upper border* with the lower margin of the Pyriformis; by its *lower border* with the tendon of the Obturator internus.

The **Gemellus inferior** arises from the upper part of the outer border of the tuberosity of the ischium, and, passing horizontally outward, is blended with the lower part of the tendon of the Obturator internus, and inserted with it into the upper border of the great trochanter.

RELATIONS.—By its *superficial surface* with the Gluteus maximus and the sciatic vessels and nerves; by its *deep surface* with the capsular ligament of the hip-joint; by its *upper border* with the tendon of the Obturator internus; by its *lower border* with the tendon of the Obturator externus and Quadratus femoris.

The **Quadratus femoris** is a short, flat muscle, quadrilateral in shape (hence its name), situated between the Gemellus inferior and the upper margin of the Adductor magnus. It arises from the outer border of the tuberosity of the ischium, and, proceeding horizontally outward, is inserted into the upper part of the linea quadrati on the posterior surface of the trochanter major. A synovial bursa is often found between the under surface of this muscle and the lesser trochanter, which it covers.

RELATIONS.—By its *posterior surface* with the Gluteus maximus and the sciatic vessels and nerves; by its *anterior surface* with the tendon of the Obturator externus and trochanter minor and with the capsule of the hip-joint; by its *upper border* with the Gemellus inferior. Its *lower border* is separated from the Adductor magnus by the terminal branches of the internal circumflex vessels.

Dissection.—In order to expose the next muscle (the Obturator externus), it is necessary to remove the Psoas, Iliacus, Pectineus, and Adductor brevis and longus muscles from the front and inner side of the thigh, and the Gluteus maximus and Quadratus femoris from the back part. Its dissection should consequently be postponed until the muscles of the anterior and internal femoral regions have been examined.

The **Obturator externus** (Fig. 336) is a flat, triangular muscle which covers the outer surface of the anterior wall of the pelvis. It arises from the margin of bone immediately around the inner side of the obturator foramen—viz. from the body and ramus of the pubes and the ramus of the ischium; it also arises from the inner two-thirds of the outer surface of the obturator membrane, and from the tendinous arch which completes the canal for the passage of the obturator vessels and nerves. The fibres converging pass backward, outward, and upward, and terminate in a tendon which runs across the back part of the hip-joint and is inserted into the digital fossa of the femur.

RELATIONS.—By its *anterior surface* with the Psoas, Iliacus, Pectineus, Adductor magnus, Adductor brevis, and Gracilis, and more externally with the neck of the femur and capsule of the hip-joint; by its *posterior surface* with the obturator membrane and Quadratus femoris.

Nerves.—The Gluteus maximus is supplied by the small sciatic nerve and a branch from the sacral plexus; the Gluteus medius and minimis, by the superior gluteal; the Pyriformis, Gemelli, Obturator internus, and Quadratus femoris, by branches from the sacral plexus; and the Obturator externus, by the obturator nerve.

Actions.—The Glutei muscles, when they take their fixed point from the pelvis, are all abductors of the thigh. The Gluteus maximus and the posterior fibres of the Gluteus medius and minimus rotate the thigh outward; the anterior fibres of the Gluteus medius and the Gluteus minimus rotate it inward. The Gluteus maximus serves to extend the femur and bring the bent thigh into a line with the body. The anterior fibres of the Gluteus medius and minimus, on the other hand, flex the thigh by drawing the great trochanter forward. The Gluteus maximus is also a tensor of the fascia lata. Taking their fixed point from the femur, the Glutei muscles act upon the pelvis, supporting it and the whole trunk upon the head of the femur, which is specially obvious in standing on one leg. In order to gain the erect posture after the effort of stooping, these muscles draw the pelvis backward, assisted by the Biceps, Semitendinosus, and Semimembranosus muscles. By its connection with the ilio-tibial band the Gluteus maximus steadies the femur on the articular surface of the tibia during standing, when the Extensor muscles are relaxed. The remaining muscles are powerful rotators of the thigh outward. In the sitting posture, when the thigh is flexed upon the pelvis, their action as rotators ceases and they become abductors, with the exception of the Obturator externus, which still rotates the femur outward. When the femur is fixed the Pyriformis and Obturator muscles serve to draw the pelvis forward if it has been inclined backward, and assist in steadying it upon the head of the femur.

Posterior Femoral Region.

Biceps. Semitendinosus. Semimembranosus.

Dissection (Fig. 337).—Make a vertical incision along the middle of the thigh from the lower fold of the nates to about three inches below the back of the knee-joint, and there connect it with a transverse incision carried from the inner to the outer side of the leg. Make a third incision transversely at the junction of the middle with the lower third of the thigh. The integument having been removed from the back of the knee and the boundaries of the popliteal space examined, the removal of the integument from the remaining part of the thigh should be continued, when the fascia and muscles of this region will be exposed.

The **Biceps [flexor cruris]** (Fig. 338) is a large muscle, of considerable length, situated on the posterior and outer aspect of the thigh. It arises by two heads: one, the long head, arises from the lower and inner facet on the back part of the tuberosity of the ischium by a tendon common to it and the Semitendinosus; the femoral, or short head, arises from the whole length of the outer lip of the linea aspera, between the Adductor magnus and Vastus externus, and from the external supracondyloid line, to within two inches of the outer condyle; it also arises from the external intermuscular septum. The fibres of the long head form a fusiform belly, which, passing obliquely downward and a little outward, terminates in an aponeurosis which covers the posterior surface of the muscle and receives the fibres of the short head: this aponeurosis becomes gradually contracted into a tendon which is inserted into the outer side of the head of the fibula, and by a small slip into the lateral surface of the external tuberosity of the tibia. At its insertion the tendon divides into two portions, which embrace the long external lateral ligament of the knee-joint, a strong prolongation being sent forward to the outer tuberosity of the tibia, which gives off an expansion to the fascia of the leg. The tendon of this muscle forms the outer hamstring. [Resisted flexion of the leg shows this tendon very well.]

Relations.—By its *superficial surface* with the Gluteus maximus above, the fascia lata and integument in the rest of its extent; by its *deep surface* with the Semimembranosus, Adductor magnus, and Vastus externus, the great sciatic nerve, popliteal artery and vein, and near its insertion with the external head of the Gastrocnemius, Plantaris, the superior external articular artery, and the external popliteal nerve.

The **Semitendinosus**, remarkable for the great length of its tendon, is situated at the posterior and inner aspect of the thigh. It arises from the lower and inner facet on the tuberosity of the ischium by a tendon common to it and the long head of the Biceps; it also arises from an aponeurosis which connects the adjacent surfaces of the two muscles to the extent of about three inches after their origin. It forms a fusiform muscle, which, passing downward and inward, terminates a little below the middle of the thigh in a long round tendon which lies along the inner side of the popliteal space, then curves around the inner tuberosity of the tibia, and is inserted into the upper part of the inner surface of the shaft of that bone, nearly as far forward as its anterior border. This tendon is surrounded by the tendon of the Sartorius, and lies below that of the Gracilis, to which it is united. A tendinous intersection is usually observed about the middle of the muscle.

Relations.—By its *superficial surface* with the Gluteus maximus and fascia lata; by its *deep surface* with the Semimembranosus, Adductor magnus, inner head of the Gastrocnemius, and internal lateral ligament of the knee-joint.

The **Semimembranosus**, so called from the membranous expansion on its anterior and posterior surfaces, is situated at the back part and inner side of the thigh. It arises by a thick tendon from the upper and outer facet on the back part of the tuberosity of the ischium, above and to the outer side of the Biceps and Semitendinosus, and is inserted into the groove on the inner and back part of the inner tuberosity of the tibia, beneath the internal lateral ligament. The tendon of the muscle at its origin expands into an aponeurosis which covers the upper part of its anterior surface: from this aponeurosis muscular fibres arise and converge to another aponeurosis, which covers the lower part of its posterior surface and contracts into the tendon of insertion. The tendon of the muscle at its insertion divides into three portions: the middle and main portion is the fasciculus of insertion into the back part of the inner tuberosity; it sends down an expansion to cover the Popliteus muscle. The internal portion consists of a few fibres which join the internal lateral ligament of the joint. The posterior division passes upward and outward, to be inserted into the back part of the outer condyle of the femur, forming the chief part of the posterior ligament of the knee-joint.

The tendons of the two preceding muscles, with those of the Gracilis and Sartorius, form the inner hamstring. [Resisted flexion of the leg will show the inner hamstrings very well. The tendons of the Semitendinosus and Semimembranosus can be readily differentiated, but the others only obscurely. The study on the model of the different outlines of the knee posteriorly, and the differences in the popliteal space in varying degrees of flexion of the leg, will well repay the time spent on it.]

Relations.—By its *superficial surface* with the Semitendinosus, Biceps, and fascia lata; by its *deep surface* with the popliteal vessels, Adductor magnus, and inner head of the Gastrocnemius, from which it is separated by a synovial bursa; by its *inner border* with the Gracilis; by its *outer border* with the great sciatic nerve and its internal popliteal branch.

Nerves.—The muscles of this region are supplied by the great sciatic nerve.

Actions.—The hamstring muscles flex the leg upon the thigh. When the knee is semiflexed the Biceps, in consequence of its oblique direction downward and outward, rotates the leg slightly outward, and the Semitendinosus, and to a slight extent the Semimembranosus, rotate the leg inward, assisting the Popliteus. Taking their fixed point from below, these muscles serve to support the pelvis upon the head of the femur and to draw the trunk directly backward, as in feats of strength when the body is thrown backward in the form of an arch. [For the "ligamentous action" of these muscles see p. 301. To show it, stand with the back against the wall and keep the pelvis fixed. Flex the thigh, keeping the leg straight. When flexed to about one-third, further flexion is arrested by tension and pain at the knee.

Now, keeping the thigh fixed, flex the knee, thus relaxing the hamstrings, when the pain disappears and the thigh can be entirely flexed.]

Surgical Anatomy.—The tendons of these muscles occasionally require subcutaneous division in forms of spurious ankylosis of the knee-joint dependent upon permanent contraction and rigidity of the Flexor muscles, or from stiffening of the ligamentous and other tissues surrounding the joint, the result of disease. This is effected by putting the tendon upon the stretch, and inserting a narrow sharp-pointed knife between it and the skin: the cutting edge being then turned toward the tendon, it should be divided, taking care that the wound in the skin is not at the same time enlarged. The relation of the external popliteal nerve to the tendon of the Biceps must always be borne in mind in dividing this tendon.

MUSCLES AND FASCIÆ OF THE LEG.

Dissection (Fig. 333).—The knee should be bent, a block placed beneath it, and the foot kept in an extended position; then make an incision through the integument in the middle line of the leg to the ankle, and continue it along the dorsum of the foot to the toes. Make a second incision transversely across the ankle, and a third in the same direction across the bases of the toes; remove the flaps of integument included between these incisions in order to examine the deep fascia of the leg.

The **Deep Fascia of the Leg** forms a complete investment to the whole of this region of the limb, excepting to the inner surface of the tibia. It is continuous above with the fascia lata, receiving an expansion from the tendon of the Biceps on the outer side and from the tendons of the Sartorius, Gracilis, and Semitendinosus on the inner side; in front it blends with the periosteum covering the subcutaneous surface of the tibia, and with that covering the head and external malleolus of the fibula; below it is continuous with the annular ligaments of the ankle. It is thick and dense in the upper and anterior part of the leg, and gives attachment by its deep surface to the Tibialis anticus and Extensor longus digitorum muscles, but thinner behind, where it covers the Gastrocnemius and Soleus muscles. Over the popliteal space it is much strengthened by transverse fibres which stretch across from the inner to the outer hamstring muscles, and it is here perforated by the external saphena vein. Its deep surface gives off, on the outer side of the leg, two strong intermuscular septa, which enclose the Peronei muscles and separate them from the muscles on the anterior and posterior tibial regions, and several smaller and more slender processes, which enclose the individual muscles in each region; at the same time a broad transverse intermuscular septum, called the *deep transverse fascia of the leg*, intervenes between the superficial and deep muscles in the posterior tibio-fibular region.

Now remove the fascia by dividing it in the same direction as the integument, excepting opposite the ankle, where it should be left entire. Commence the removal of the fascia from below opposite the tendons, and detach it in the line of direction of the muscular fibres.

MUSCLES OF THE LEG.

These may be subdivided into three groups: those on the anterior, those on the posterior, and those on the outer side.

ANTERIOR TIBIO-FIBULAR REGION.

Tibialis anticus.
Extensor proprius pollicis.
Extensor longus digitorum.
Peroneus tertius.

The **Tibialis anticus** is situated on the outer side of the tibia; it is thick and fleshy at its upper part, tendinous below. It arises from the outer tuberosity and upper two-thirds of the external surface of the shaft of the tibia; from the adjoining part of the interosseous membrane; from the deep surface of the fascia; and from the intermuscular septum between it and the Extensor longus digitorum: the fibres pass vertically downward, and terminate in a tendon which is apparent on

FIG. 339.

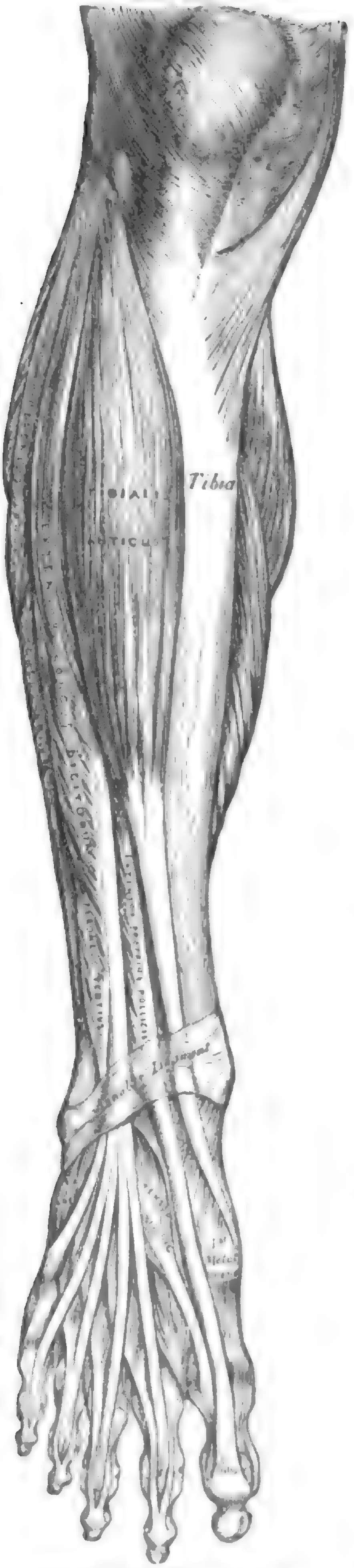

Muscles of the Front of the Leg.

the anterior surface of the muscle at the lower third of the leg. After passing through the innermost compartment of the anterior annular ligament, it is inserted into the inner and under surface of the internal cuneiform bone and base of the metatarsal bone of the great toe. [The annular ligament holds the tendon of this muscle very loosely, and so, if the model stands on one leg, the tendon constantly springs into strong relief at the ankle in the effort to maintain the equilibrium of the body. This reversed action from below upward is very marked in all the muscles extending from the leg to the foot, and should be noticed in the case of each one.]

RELATIONS.—By its *anterior surface* with the fascia and with the annular ligament; by its *posterior surface* with the interosseous membrane, tibia, ankle-joint, and inner side of the tarsus: this surface also overlaps the anterior tibial vessels and nerve in the upper part of the leg; by its *inner surface* with the tibia; by its *outer surface* with the Extensor longus digitorum and Extensor proprius pollicis, and the anterior tibial vessels and nerve.

The **Extensor proprius pollicis** is a thin, elongated, and flattened muscle situated between the Tibialis anticus and Extensor longus digitorum. It arises from the anterior surface of the fibula for about the middle two-fourths of its extent, its origin being internal to that of the Extensor longus digitorum; it also arises from the interosseous membrane to a similar extent. The fibres pass downward, and terminate in a tendon which occupies the anterior border of the muscle, passes through a distinct compartment in the horizontal portion of the annular ligament, crosses the anterior tibial vessels near the bend of the ankle, and is inserted into the base of the last phalanx of the great toe. Opposite the metatarso-phalangeal articulation the tendon gives off a thin prolongation on each side which covers the surface of the joint. [This tendon also can be easily perceived at the ankle and on the dorsum of the foot by strongly extending the great toe.]

RELATIONS.—By its *anterior border* with the fascia and the anterior annular ligament; by its *posterior border* with the interosseous membrane, fibula, tibia, ankle-joint, and Extensor brevis digitorum; by its *outer side* with the Extensor longus digitorum above, the dorsalis pedis vessels and anterior tibial nerve below; by its *inner side* with the Tibialis anticus and the anterior tibial vessels above.

The **Extensor longus digitorum** is an elongated, flattened, semipenniform muscle situated the most externally of all the muscles on the fore part of the leg. It arises from the outer tuberosity of the tibia, from the upper three-fourths of the anterior surface of the shaft of the fibula, from the interosseous membrane and deep surface of the fascia, and from the intermuscular septa between it and the Tibialis anticus on the inner and the Peronei on the outer side. The tendon enters a canal in the annular ligament; with the Peroneus tertius divides into four slips which run across the dorsum of the foot and are inserted into the second and third phalanges of the four lesser toes. The mode in which the tendons are inserted is the following: the three inner tendons opposite the metatarso-phalangeal articulation are joined on their outer side by a tendon of the Extensor brevis digitorum. They all receive a fibrous expansion from the Interossei and Lumbricales, and then spread out into a broad aponeurosis which covers the dorsal surface of the first phalanx: this aponeurosis at the articulation of the first with the second phalanx divides into three slips—a middle one, which is inserted into the base of the second phalanx, and two lateral slips, which, after uniting on the dorsal surface of the second phalanx, are continued onward, to be inserted into the base of the third. [Standing on one foot will show this tendon well.]

RELATIONS.—By its *anterior surface* with the fascia and the annular ligament; by its *posterior surface* with the fibula, interosseous membrane, ankle-joint, and Extensor brevis digitorum; by its *inner side* with the Tibialis anticus, Extensor proprius pollicis, and anterior tibial vessels and nerve; by its *outer side* with the Peroneus longus and brevis.

[FIG. 340.

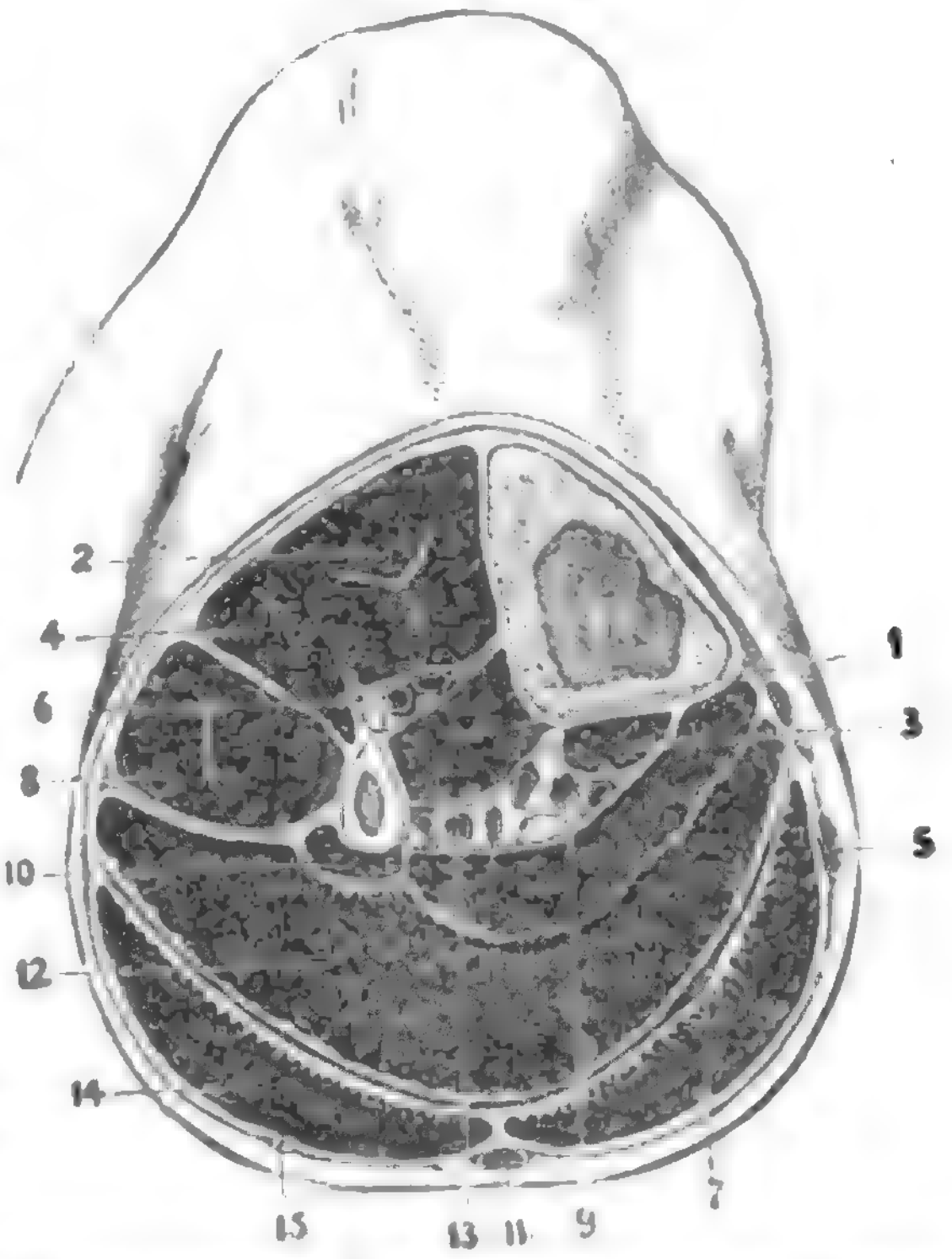

A Section of the Right Leg in the Upper Third (Heath, from Béraud): 1, Tibialis posticus; 2, Tibialis anticus; 3, Flexor longus digitorum; 4, Extensor longus digitorum; 5, internal saphenous vein; 6, anterior tibial vessels and nerve; 7, tendon of Plantaris; 8, Peroneus longus; 9, posterior tibial vessels and nerve; 10, Flexor longus pollicis; 11, external saphenous vein and nerve; 12, Soleus with fibrous intersection; 13, peroneal vessels; 14, Gastrocnemius (outer half); 15, communicans peronei nerve.]

The **Peroneus tertius** is a part of the Extensor longus digitorum, and might be described as its fifth tendon. The fibres belonging to this tendon arise from the lower fourth of the anterior surface of the fibula, from the lower part of the interosseous membrane, and from an intermuscular septum between it and the Peroneus brevis. The tendon, after passing through the same canal in the annular ligament as the Extensor longus digitorum, is inserted into the dorsal surface of the base of the metatarsal bone of the little toe on its inner side. This muscle is sometimes wanting.

NERVES.—These muscles are supplied by the anterior tibial nerve.

ACTIONS.—The Tibialis anticus and Peroneus tertius are the direct flexors of the tarsus upon the leg; the former muscle, from the obliquity in the direction of its tendon, raises the inner border of the foot [as in talipes varus]; and the latter, acting with the Peroneus brevis and longus, draws the outer border of the foot upward and the sole outward. The Extensor longus digitorum and Extensor proprius pollicis extend the phalanges of the toes, and, continuing their action, flex the tarsus upon the leg. Taking their fixed point from below in the erect posture, all these muscles serve to fix the bones of the leg in the perpendicular position and give increased strength to the ankle-joint.

POSTERIOR TIBIO-FIBULAR REGION.

Dissection (Fig. 337).—Make a vertical incision along the middle line of the back of the leg from the lower part of the popliteal space to the heel, connecting it below by a transverse incision extending between the two malleoli; the flaps of integument being removed, the fascia and muscles should be examined.

The muscles in this region of the leg are subdivided into two layers, superficial and deep. The superficial layer constitutes a powerful muscular mass, forming the calf of the leg. Their large size is one of the most characteristic features of the muscular apparatus in man, and bears a direct connection with his ordinary attitude and mode of progression.

FIG. 341.

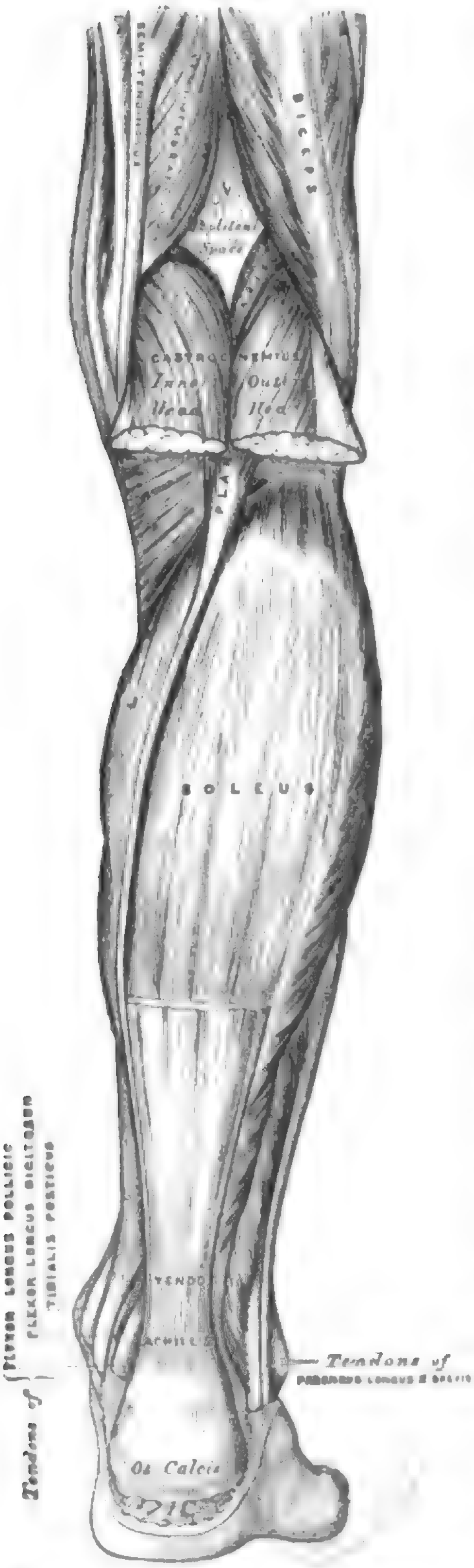

Muscles of the Back of the Leg, superficial layer.

Superficial Layer.

Gastrocnemius. Soleus. Plantaris.

The **Gastrocnemius** is the most superficial muscle and forms the greater part of the calf. It arises by two heads, which are connected to the condyles of the femur by two strong flat tendons. The inner head, the larger and a little the more posterior, arises from a depression at the upper and back part of the inner condyle. The outer head arises from the upper and back part of the external condyle immediately above the origin of the Popliteus. Both heads also arise by a few tendinous and fleshy fibres from the ridges which are continued upward from the condyles to the linea aspera. Each tendon spreads out into an aponeurosis, which covers the posterior surface of that portion of the muscle to which it belongs, that covering the inner head being longer and thicker than the outer. From the anterior surface of these tendinous expansions muscular fibres are given off. The fibres in the median line, which correspond to the accessory portions of the muscle derived from the bifurcations of the linea aspera, unite at an angle upon a median tendinous raphé below; the remaining fibres converge to the posterior surface of an aponeurosis which covers the under surface of the muscle, and this, gradually contracting, unites with the tendon of the Soleus and forms with it the tendo Achillis.

RELATIONS.—By its *superficial surface* with the fascia of the leg, which separates it from the external saphenous vein and nerve; by its *deep surface* with the posterior ligament of the knee-joint, the Popliteus, Soleus, Plantaris, popliteal vessels, and internal popliteal nerve. The tendon of the inner head corresponds with the back part of the inner condyle, from which it is separated by a synovial bursa which in some cases communicates with the cavity of the knee-joint. The tendon of the outer head contains a sesamoid fibro-cartilage (rarely osseous) where it plays over the corresponding outer condyle, and one is occasionally found in the tendon of the inner head.

The Gastrocnemius should be divided across just below its origin, and turned downward in order to expose the next muscles.

The **Soleus** is a broad flat muscle situated immediately beneath the preceding. It has received its name from its resemblance in shape to a sole-fish. It arises by tendinous fibres from the back part of the head of the fibula and from the upper third of the posterior surface of its shaft, from the oblique line of the tibia, and from the middle third of its internal border; some fibres also arise from a tendinous arch placed between the tibial and fibular origins of the muscle, beneath which the posterior tibial vessels and nerve pass. The fibres pass backward to an aponeurosis which covers the posterior surface of the muscle, and this, gradually becoming thicker and narrower, joins with the tendon of the Gastrocnemius and forms with it the tendo Achillis.

RELATIONS.—By its *superficial surface* with the Gastrocnemius and Plantaris; by its *deep surface* with the Flexor longus digitorum, Flexor longus pollicis, Tibialis posticus, and posterior tibial vessels and nerve, from which it is separated by the transverse intermuscular septum or deep transverse fascia of the leg.

The **Tendo Achillis**, the common tendon of the Gastrocnemius and Soleus, is the thickest and strongest tendon in the body. It is about six inches in length, and formed by the junction of the aponeurosis of the two preceding muscles. It commences about the middle of the leg, but receives fleshy fibres on its anterior surface nearly to its lower end. Gradually becoming contracted below, it is inserted into the lower part of the posterior surface of the os calcis, a synovial bursa [Fig. 277, p. 357] being interposed between the tendon and the upper part of the tuberosity. The tendon spreads out somewhat at its lower end, so that its narrowest part is usually about an inch and a half above its insertion. The tendon is covered by the fascia and the integument, and is separated from the deep muscles and vessels by a considerable interval filled up with areolar and adipose tissue. Along its outer side, but superficial to it, is the external saphenous vein. [This tendon can be well studied in almost any position of the leg: standing on tip-toe makes it most tense and prominent. It is made concave posteriorly by the posterior annular ligament. The model, standing on tip-toe, shows both the large muscles of the calf, so that they can be differentiated. The two bellies of the Gastrocnemius can be distinguished, and their difference of development and level well seen, the inner one being the stouter and longer. The Soleus shows on both sides, its fibres extending down far below those of the Gastrocnemius.]

The **Plantaris** is an extremely diminutive muscle placed between the Gastrocnemius and Soleus, and remarkable for its long and delicate tendon. It arises from the lower part of the outer bifurcation of the linea aspera and from the posterior ligament of the knee-joint. It forms a small fusiform belly about three or four inches in length, terminating in a long slender tendon which crosses obliquely between the two muscles of the calf, and, running along the inner border of the tendo Achillis, is inserted with it into the posterior part of the os calcis. This muscle is occasionally double, and is sometimes wanting. Occasionally, its tendon is lost in the internal annular ligament or in the fascia of the leg.

NERVES.—These muscles are supplied by the internal popliteal nerve.

ACTIONS.—The muscles of the calf possess great power, and are constantly called into use in standing, walking, dancing, and leaping; hence the large size they usually present. In walking, these muscles draw powerfully upon the os calcis, raising the heel, and with it the entire body, from the ground; the body being thus supported on the raised foot, the opposite limb can be carried forward. In standing, the Soleus, taking its fixed point from below, steadies the leg upon the foot and prevents the body from falling forward, to which there is a constant tendency from the superincumbent weight. The Gastrocnemius, acting from below, serves to flex the femur upon the tibia, assisted by the Popliteus. The Plantaris is the rudiment of a large muscle which exists in some of the lower animals and serves as a tensor of the plantar fascia.

Deep Layer.

Popliteus.
Flexor longus pollicis.
Flexor longus digitorum.
Tibialis posticus.

Dissection.—Detach the Soleus from its attachment to the fibula and tibia, and turn it downward, when the deep layer of muscles is exposed, covered by the deep transverse fascia of the leg.

FIG. 342.

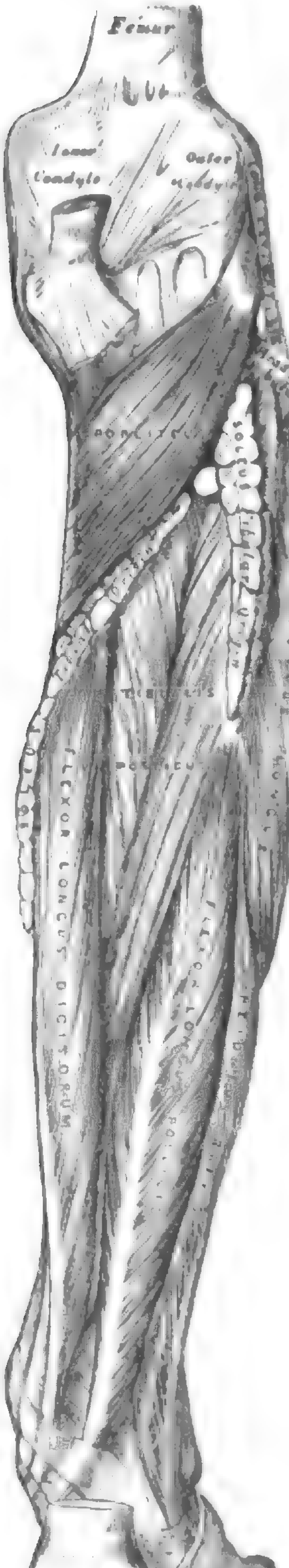

Muscles of the Back of the Leg, deep layers.

The **Deep Transverse Fascia** of the leg is a broad, transverse, intermuscular septum interposed between the superficial and deep muscles in the posterior tibio-fibular region. On each side it is connected to the margins of the tibia and fibula. Above, where it covers the Popliteus, it is thick and dense, and receives an expansion from the tendon of the Semimembranosus; it is thinner in the middle of the leg; but below, where it covers the tendons passing behind the malleoli, it is thickened. It is continued onward in the interval between the ankle and the heel, where it covers the vessels, and is blended with the internal annular ligament.

This fascia should now be removed, commencing from below opposite the tendons, and detaching it from the muscles in the direction of their fibres.

The **Popliteus** is a thin, flat, triangular muscle which forms part of the floor of the popliteal space, and is covered by a tendinous expansion derived from the Semimembranosus muscle. It arises by a strong flat tendon about an inch in length from a deep depression on the outer side of the external condyle of the femur and from the posterior ligament of the knee-joint, and is inserted into the inner two-thirds of the triangular surface above the oblique line on the posterior surface of the shaft of the tibia, and into the tendinous expansion covering the surface of the muscle. The tendon of the muscle is covered by that of the Biceps and the external lateral ligament of the knee-joint; it grooves the outer surface of the external semilunar cartilage, and is invested by the synovial membrane of the knee-joint.

RELATIONS.—By its *superficial surface* with the fascia above mentioned, which separates it from the Gastrocnemius, Plantaris, popliteal vessels, and internal popliteal nerve; by its *deep surface* with the superior tibio-fibular articulation and back of the tibia.

The **Flexor longus pollicis** is situated on the fibular side of the leg, and is the most superficial and largest of the three next muscles. It arises from the lower two-thirds of the posterior surface of the shaft of the fibula, with the exception of an inch at its lowest part; from the lower part of the interosseous membrane; from an intermuscular septum between it and the Peronei externally; and from the fascia covering the Tibialis posticus. The fibres pass obliquely downward and backward, and terminate round a tendon which occupies nearly the whole length of the posterior surface of the muscle. This tendon passes through a groove on the posterior surface of the tibia external to that for the Tibialis posticus and Flexor longus digitorum; it then passes through another groove on the posterior surface of the astragalus, and along a third groove, beneath the lesser process of the os calcis, into the sole of the foot, where it runs forward between the two heads of the Flexor brevis pollicis, and is inserted into the base of the last phalanx of the great toe. The grooves in the astragalus and os calcis which contain the tendon of the muscle are converted by tendinous fibres into distinct canals lined by synovial membrane; and as the tendon crosses the sole of the foot it is connected to the common flexor by a tendinous slip.

RELATIONS.—By its *superficial surface* with the Soleus and tendo Achillis, from which it is separated by the deep transverse fascia; by its *deep surface* with the fibula, Tibialis posticus, the peroneal vessels, the lower part of the interosseous membrane, and the ankle-joint; by its *outer border* with the Peronei; by its *inner border* with the Tibialis posticus and posterior tibial vessels and nerves.

The **Flexor longus digitorum** (*perforans*) is situated on the tibial side of the leg. At its origin it is thin and pointed, but gradually increases in size as it descends. It arises from the posterior surface of the shaft of the tibia, immediately below the oblique line, to within three inches of its extremity internal to the tibial origin of the Tibialis posticus; some fibres also arise from the intermuscular septum between it and the Tibialis posticus. The fibres terminate in a tendon which runs nearly the whole length of the posterior surface of the muscle. This tendon passes, behind the malleolus, in a groove common to it and the Tibialis posticus, but separated from the latter by a fibrous septum, each tendon being contained in a special sheath lined by a separate synovial membrane. It then passes obliquely forward and outward beneath the arch of the os calcis into the sole of the foot (Fig. 344, p. 491), where, crossing superficial to the tendon of the Flexor longus pollicis,[1] to which it is connected by a strong tendinous slip, it becomes expanded, is joined by the Flexor accessorius, and finally divides into four tendons, which are inserted into the bases of the last phalanges of the four lesser toes, each tendon passing through a fissure in the tendon of the Flexor brevis digitorum opposite the middle of the first phalanges.

RELATIONS.—*In the leg*, by its *superficial surface*, with the Soleus and the posterior tibial vessels and nerve, from which it is separated by the deep transverse fascia; by its *deep surface* with the tibia and Tibialis posticus. *In the foot* it is covered by the Abductor pollicis and Flexor brevis digitorum, and crosses superficial to the Flexor longus pollicis.

The **Tibialis posticus** lies between the two preceding muscles, and is the most deeply seated of all the muscles in the leg. It commences above by two pointed processes separated by an angular interval, through which the anterior tibial vessels pass forward to the front of the leg. It arises from the whole of the posterior surface of the interosseous membrane, excepting its lowest part; from the posterior surface of the shaft of the tibia, external to the Flexor longus digitorum, between the commencement of the oblique line above and the middle of the external border of the bone below; and from the upper two-thirds of the internal surface of the fibula; some fibres also arise from the deep transverse fascia and from the intermuscular septa separating it from the adjacent muscles on each side. This muscle, in the lower fourth of the leg, passes in front of the Flexor longus digitorum, terminates in a tendon which passes through a groove behind the inner malleolus with the tendon of that muscle, but enclosed in a separate sheath; it then passes through another sheath over the internal lateral ligament and beneath the inferior calcaneo-scaphoid ligament, and is inserted into the tuberosity of the scaphoid and internal cuneiform bones. The tendon of this muscle contains a sesamoid bone near its insertion, and gives off fibrous expansions, one of which passes backward to the sustentaculum tali of the os calcis, others outward to the middle and external cuneiform and cuboid, and some forward to the bases of the second, third, and fourth metatarsal bones (Fig. 345, p. 492). [The tendon of this muscle can be felt just above its insertion on strongly inverting the foot, especially if it be resisted.]

RELATIONS.—By its *superficial surface* with the Soleus and Flexor longus digitorum, the posterior tibial vessels and nerve, and the peroneal vessels, from which it is separated by the deep transverse fascia; by its *deep surface* with the interosseous ligament, the tibia, fibula, and ankle-joint.

---

[1] That is, in order of dissection of the sole of the foot.

Nerves.—The Popliteus is supplied by the internal popliteal nerve; the remaining muscles of this group by the posterior tibial nerve.

Actions.—The Popliteus assists in flexing the leg upon the thigh; when the leg is flexed it will rotate the tibia inward. The Tibialis posticus is a direct extensor of the tarsus upon the leg; acting in conjunction with the Tibialis anticus, it turns the sole of the foot inward [as in talipes varus], antagonizing the Peroneus longus, which turns it outward. The Flexor longus digitorum and Flexor longus pollicis are the direct flexors of the phalanges, and, continuing their action, extend the foot upon the leg; they assist the Gastrocnemius and Soleus in extending the foot, as in the act of walking or in standing on tiptoe. In consequence of the oblique direction of the tendon of the long flexor the toes would be drawn inward were it not for the Flexor accessorius muscle, which is inserted into the outer side of its tendon and draws it to the middle line of the foot during its action. Taking their fixed point from the foot, these muscles serve to maintain the upright posture by steadying the tibia and fibula perpendicularly upon the ankle-joint. They also serve to raise these bones from the oblique position they assume in the stooping posture.

FIBULAR REGION [Figs. 329, 342, 345 and 278, p 359]

Peroneus longus. Peroneus brevis.

Dissection.—These muscles are readily exposed by removing the fascia covering their surface, from below upward, in the line of direction of their fibres.

The **Peroneus longus** is situated at the upper part of the outer side of the leg, and is the more superficial of the two muscles. It arises from the head and upper two-thirds of the outer surface of the shaft of the fibula, from the deep surface of the fascia, and from the intermuscular septa between it and the muscles on the front and those on the back of the leg. It terminates in a long tendon which passes behind the outer malleolus in a groove common to it and the Peroneus brevis, the groove being converted into a canal by a fibrous band and the tendons invested by a common synovial membrane; it is then reflected obliquely forward across the outer side of the os calcis, being contained in a separate fibrous sheath lined by a prolongation of the synovial membrane from that which lines the groove behind the malleolus. Having reached the outer side of the cuboid bone, it runs in a groove on the under surface of that bone, which is converted into a canal by the long calcaneo-cuboid ligament, and is lined by a synovial membrane: the tendon then crosses obliquely the sole of the foot, and is inserted into the outer side of the base of the metatarsal bone of the great toe and the internal cuneiform bone. Occasionally it sends a slip to the base of the second metatarsal bone. The tendon changes its direction at two points: first, behind the external malleolus; secondly, on the outer side of the cuboid bone; in both of these situations the tendon is thickened, and in the latter a sesamoid bone is usually developed in its substance. [Standing on one leg, the tendon of this muscle can be seen springing into strong relief at the ankle as the model strives to maintain his equilibrium and hold the leg in position over the foot. Its action in eversion of the foot-sole can be especially well appreciated.]

Relations.—By its *superficial surface* with the fascia and integument: by its *deep surface* with the fibula and Peroneus brevis, os calcis, and cuboid bone: by its *anterior border* with an intermuscular septum which intervenes between it and the Extensor longus digitorum: by its *posterior border* with an intermuscular septum which separates it from the Soleus above and the Flexor longus pollicis below.

The **Peroneus brevis** lies beneath the Peroneus longus, and is shorter and smaller than it. It arises from the lower two-thirds of the external surface of the shaft of the fibula, internal to the Peroneus longus, and from the intermuscular septa separating it from the adjacent muscles on the front and back part of the leg. The fibres pass vertically downward and terminate in a tendon which runs in front of that of the preceding muscle through the same groove, behind the external malleolus, being contained in the same fibrous sheath and lubricated by the same synovial membrane; it then passes through a separate sheath on the outer side of the os calcis, above that for the tendon of the Peroneus longus, and is finally inserted into the dorsal surface of the base of the metatarsal bone of the little toe on its outer side.

RELATIONS.—By its *superficial surface* with the Peroneus longus and the fascia of the leg and foot; by its *deep surface* with the fibula and outer side of the os calcis.

NERVES.—The Peroneus longus and brevis are supplied by the musculo-cutaneous branch of the external popliteal nerve.

ACTIONS.—The Peroneus longus and brevis extend the foot upon the leg in conjunction with the Tibialis posticus, antagonizing the Tibialis anticus and Peroneus tertius, which are flexors of the foot. The Peroneus longus also everts the sole of the foot: hence the extreme eversion occasionally observed in fracture of the lower end of the fibula, where that bone offers no resistance to the action of this muscle. Taking their fixed point below, the Peronei serve to steady the leg upon the foot. This is especially the case in standing upon one leg, when the tendency of the superincumbent weight is to throw the leg inward: the Peroneus longus overcomes this tendency by drawing on the outer side of the leg, and thus maintains the perpendicular direction of the limb.

Surgical Anatomy.—The student should now consider the position of the tendons of the various muscles of the leg, their relation with the ankle-joint and surrounding blood-vessels, and especially their action upon the foot, as their rigidity and contraction give rise to one or other of the kinds of deformity known as *club-foot*. The most simple and common deformity, and one that is rarely if ever congenital, is the *talipes equinus*, the heel being raised by rigidity and contraction of the Gastrocnemius muscle, and the patient walking upon the ball of the foot. In the *talipes varus* the foot is forcibly adducted and the inner side of the sole raised, sometimes to a right angle with the ground, by the action of the Tibialis anticus and posticus. In the *talipes valgus* the outer edge of the foot is raised by the Peronei muscles, and the patient walks on the inner ankle. In the *talipes calcaneus* the toes are raised by the Extensor muscles, the heel is depressed, and the patient walks upon it. Other varieties of deformity are met with, as the *talipes equino-varus*, *equino-valgus*, and *calcaneo-valgus*, whose names sufficiently indicate their nature. Of these, the talipes equino-varus is the most common congenital form: the heel is raised by the tendo Achillis, the inner border of the foot drawn upward by the Tibialis anticus, the anterior two-thirds twisted inward by the Tibialis posticus, and the arch increased by the contraction of the plantar fascia, so that the patient walks on the middle of the outer border of the foot. Each of these deformities may be successfully relieved (after other remedies fail) by division of the opposing tendons and fascia: by this means the foot regains its proper position and the tendons heal by the organization of lymph thrown out between the divided ends. The operation is easily performed by putting the contracted tendon upon the stretch, and dividing it by means of a narrow sharp-pointed knife inserted between it and the skin.

MUSCLES AND FASCIÆ OF THE FOOT.

The fibrous bands which bind down the tendons in front of and behind the ankle in their passage to the foot should now be examined; they are termed the *annular ligaments*, and are three in number—anterior, internal, and external.

The **Anterior Annular Ligament** consists of a superior or vertical portion, which binds down the extensor tendons as they descend on the front of the tibia and fibula; and an inferior or horizontal portion, which retains them in connection with the tarsus, the two portions being connected by a thin intervening layer of fascia. The vertical portion is attached externally to the lower end of the fibula, internally to the tibia, and above is continuous with the fascia of the leg; it contains only one synovial sheath, for the tendon of the Tibialis anticus, the other tendons, and the anterior tibial vessel and nerve passing beneath it, but without any distinct sheath. The horizontal portion is attached externally to the upper surface of the os calcis, in front of the depression for the interosseous ligament; it passes inward, forming a strong band, which encloses the Peroneus tertius and Extensor longus digitorum, which are contained in a single synovial sheath, and then divides into two limbs, of which the upper is inserted into the internal malleolus, passing over the Extensor proprius pollicis and vessels and nerve, but enclosing the Tibialis anticus by a splitting of its fibres. The lower limb is inserted into the plantar fascia on the inner side of the foot, and passes over both the tendon of the Extensor proprius pollicis and Tibialis anticus and also the vessels and nerve. The tendons contained in the horizontal portion of the ligament are enclosed by separate synovial sheaths.

The **Internal Annular Ligament** is a strong fibrous band which extends from the inner malleolus above to the internal margin of the os calcis below, converting a series of bony grooves in this situation into osseo-fibrous canals for the passage of the tendons of the Flexor muscles and vessels into the sole of the foot. It is continuous above with the deep fascia of the leg, below with the plantar fascia and the fibres of origin of the Abductor pollicis muscle. The three canals which it forms transmit from within outward, first, the tendon of the Tibialis posticus; second, the tendon of the Flexor longus digitorum; then the posterior tibial vessels and nerve, which run through a broad space beneath the ligament; lastly, in a canal formed partly by the astragalus, the tendon of the Flexor longus pollicis. Each of these canals is lined by a separate synovial membrane.

The **External Annular Ligament** extends from the extremity of the outer malleolus to the outer surface of the os calcis: it binds down the tendons of the Peronei muscles in their passage beneath the outer ankle. The two tendons are enclosed in one synovial sac.

Dissection of the Sole of the Foot.—The foot should be placed on a high block with the sole uppermost, and firmly secured in that position. Carry an incision round the heel and along the inner and outer borders of the foot to the great and little toes. This incision should divide the integument and thick layer of granular fat beneath until the fascia is visible; the skin and fat should then be removed from the fascia in a direction from behind forward, as seen in Fig. 337.

The **Plantar Fascia**, the densest of all the fibrous membranes, is of great strength, and consists of dense pearly-white glistening fibres, disposed, for the most part, longitudinally: it is divided into a central and two lateral portions.

The *central portion*, the thickest, is narrow behind and attached to the inner tubercle of the os calcis, behind the origin of the Flexor brevis digitorum, and, becoming broader and thinner in front, divides near the heads of the metatarsal bones into five processes, one for each of the toes. Each of these processes divides opposite the metatarso-phalangeal articulation into two slips, which embrace the sides of the flexor tendons of the toes, and blends with the sheaths of the tendons and laterally with the transverse metatarsal ligament, thus forming a series of arches through which the tendons of the short and long flexors pass to the toes. The intervals left between the five processes allow the digital vessels and nerves and the tendons of the Lumbricales muscles to become superficial. At the point of division of the fascia into processes and slips numerous transverse fibres are superadded, which serve to increase the strength of the fascia at this part by binding the processes together and connecting them with the integument. The central portion of the plantar fascia is continuous with the lateral portions at each side, and sends upward into the foot, at their point of junction, two strong vertical intermuscular septa, broader in front than behind, which separate the middle from the external and internal plantar group of muscles; from these, again, thinner transverse septa are derived, which separate the various layers of muscles in this region. The upper surface of this fascia gives attachment behind to the Flexor brevis digitorum muscle.

The *lateral portions* of the plantar fascia are thinner than the central piece and cover the sides of the foot.

The *outer portion* covers the under surface of the Abductor minimi digiti; it is thick behind, thin in front, and extends from the os calcis forward to the base of the fifth metatarsal bone, into the outer side of which it is attached; it is continuous internally with the middle portion of the plantar fascia, and externally with the dorsal fascia.

The *inner portion* is very thin, and covers the Abductor pollicis muscle; it is attached behind to the internal annular ligament, and is continuous around the side of the foot with the dorsal fascia, and externally with the middle portion of the plantar fascia.

MUSCLES OF THE FOOT.

These are found in two regions: 1, On the dorsum; 2, on the plantar surface.

1. DORSAL REGION.

Extensor brevis digitorum.

The **Fascia** on the dorsum of the foot is a thin membranous layer, continuous above with the anterior margin of the annular ligament; it becomes gradually lost opposite the heads of the metatarsal bones, and on each side blends with the lateral portion of the plantar fascia; it forms a sheath for the tendons placed on the dorsum of the foot. On the removal of this fascia the muscles and tendons of the dorsal region of the foot are exposed.

The **Extensor brevis digitorum** (Fig. 340) is a broad thin muscle which arises from the outer side of the os calcis, in front of the groove for the Peroneus brevis; from the external calcaneo-astragaloid ligament; and from the horizontal portion of the anterior annular ligament. It passes obliquely across the dorsum of the foot, and terminates in four tendons. The innermost, which is the largest, is inserted into the first phalanx of the great toe, crossing the dorsalis pedis artery; the other three, into the outer sides of the long extensor tendons of the second, third, and fourth toes.

RELATIONS.—By its *superficial surface* with the fascia of the foot, the tendons of the Extensor longus digitorum and Extensor proprius pollicis; by its *deep surface* with the tarsal and metatarsal bones and the Dorsal interossei muscles.

NERVES.—It is supplied by the anterior tibial nerve.

ACTIONS.—The Extensor brevis digitorum is an accessory to the long Extensor, extending the phalanges of the four inner toes, but acting only on the first phalanx of the great toe. The obliquity of its direction counteracts the oblique movement given to the toes by the long Extensor, so that, both muscles acting together, the toes are evenly extended. [Its tendons can be seen and felt on extending the toes strongly.]

2. PLANTAR REGION.

The muscles in the plantar region of the foot may be divided into three groups, in a similar manner to those in the hand. Those of the internal plantar region are connected with the great toe, and correspond with those of the thumb; those of the external plantar region are connected with the little toe, and correspond with those of the little finger; and those of the middle plantar region are connected with the tendons intervening between the two former groups. But in order to facilitate the dissection of these muscles it will be found more convenient to divide them into four layers, as they present themselves, in the order in which they are successively exposed.

First Layer.

Abductor pollicis. Flexor brevis digitorum.
Abductor minimi digiti.

Dissection.—Remove the fascia on the inner and outer sides of the foot, commencing in front over the tendons and proceeding backward. The central portion should be divided transversely in the middle of the foot, and the two flaps dissected forward and backward.

The **Abductor pollicis** lies along the inner border of the foot. It arises from the inner tubercle on the under surface of the os calcis, from the internal annular ligament, from the plantar fascia, and from the intermuscular septum between it and the Flexor brevis digitorum. The fibres terminate in a tendon which is inserted, together with the innermost tendon of the Flexor brevis pollicis, into the inner side of the base of the first phalanx of the great toe.

Relations.—By its *superficial surface* with the plantar fascia; by its *deep surface* with the Flexor brevis pollicis, the Flexor accessorius, and the tendons of the Flexor longus digitorum and Flexor longus pollicis, the Tibialis anticus and posticus, the plantar vessels and nerves, and the articulations of the tarsus.

Fig. 343.

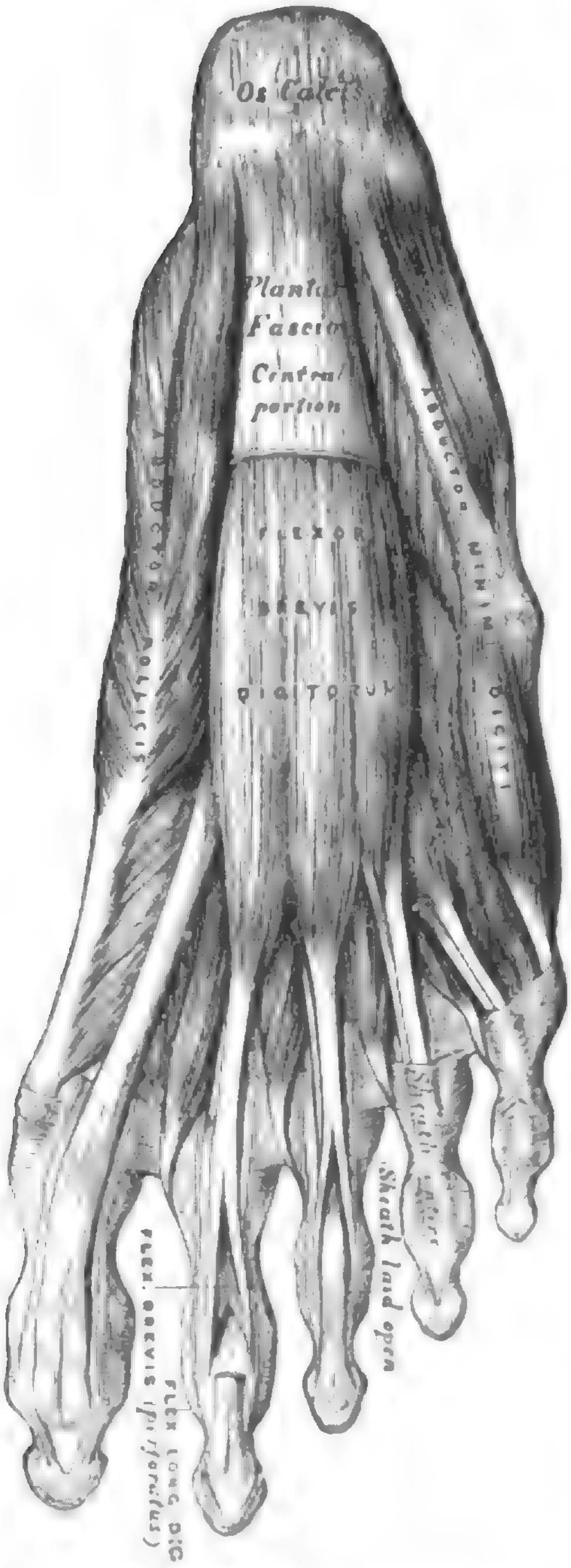

Muscles of the Sole of the Foot, first layer.

The **Flexor brevis digitorum** (*perforatus*) lies in the middle of the sole of the foot, immediately beneath[1] the plantar fascia, with which it is firmly united. It arises by a narrow tendinous process from the inner tubercle of the os calcis, from the central part of the plantar fascia, and from the intermuscular septa between it and the adjacent muscles. It passes forward and divides into four tendons. Opposite the middle of the first phalanges each tendon presents a longitudinal slit to allow of the passage of the corresponding tendon of the Flexor longus digitorum; the two portions form a groove for the reception of that tendon. The tendon of the short flexor then reunites, and immediately divides a second time into two processes, which are inserted into the sides of the second phalanges. The mode of division of the tendons of the Flexor brevis digitorum and their insertion into the phalanges is analogous to the Flexor sublimis in the hand.

Relations.—By its *superficial surface* with the plantar fascia; by its *deep surface* with the Flexor accessorius, the Lumbricales, the tendons of the Flexor longus digitorum, and the external plantar vessels and nerve, from which it is separated by a thin layer of fascia. The *outer* and *inner* borders are separated from the adjacent muscles by means of vertical prolongations of the plantar fascia.

The **Abductor minimi digiti** lies along the outer border of the foot. It arises by a very broad origin from the outer tubercle of the os calcis, from the under surface of the os calcis in front of both tubercles, from the fore part of the inner tubercle, from the plantar fascia and the intermuscular septum between it and the Flexor brevis digitorum. Its tendon, after gliding over a smooth facet on the under surface of the base of the fifth metatarsal bone, is inserted with the short Flexor of the little toe into the outer side of the base of the first phalanx of the little toe.

Relations.—By its *superficial surface* with the plantar fascia. By its *deep surface* with the Flexor accessorius, the Flexor brevis minimi digiti, the long plantar ligament, and the tendon of the Peroneus longus. On its *inner side* are the external plantar vessels and nerve, and it is separated from the Flexor brevis digitorum by a vertical septum of fascia.

[Actions.—The Abductor pollicis does abduct the great toe from the others, but its chief action is that of a flexor of the first phalanx, and at the same time it extends the second. It is practically the most internal Interosseous muscle. The Flexor brevis digitorum flexes the second phalanges on the first, and then the first on the metacarpal bone. The Abductor minimi digiti is the most external Interosseous muscle. It abducts the little toe, but chiefly flexes the first and extends the last two phalanges.]

---

[1] That is, in the order of dissection of the sole of the foot.

Dissection.—The muscles of the superficial layer should be divided at their origin, by inserting the knife beneath each and cutting obliquely backward, so as to detach them from the bone [it is better to divide their bellies and leave the attachments]; they should then be drawn forward in order to expose the second layer, but not cut away at their insertion. The two layers are separated by a thin membrane, the deep plantar fascia, on the removal of which is seen the tendon of the Flexor longus digitorum, the Flexor accessorius, the tendon of the Flexor longus pollicis, and the Lumbricales. The long flexor tendons cross each other at an acute angle, the Flexor longus pollicis running along the inner side of the foot on a plane superior to that of the Flexor longus digitorum, the direction of which is obliquely outward.

FIG. 344.

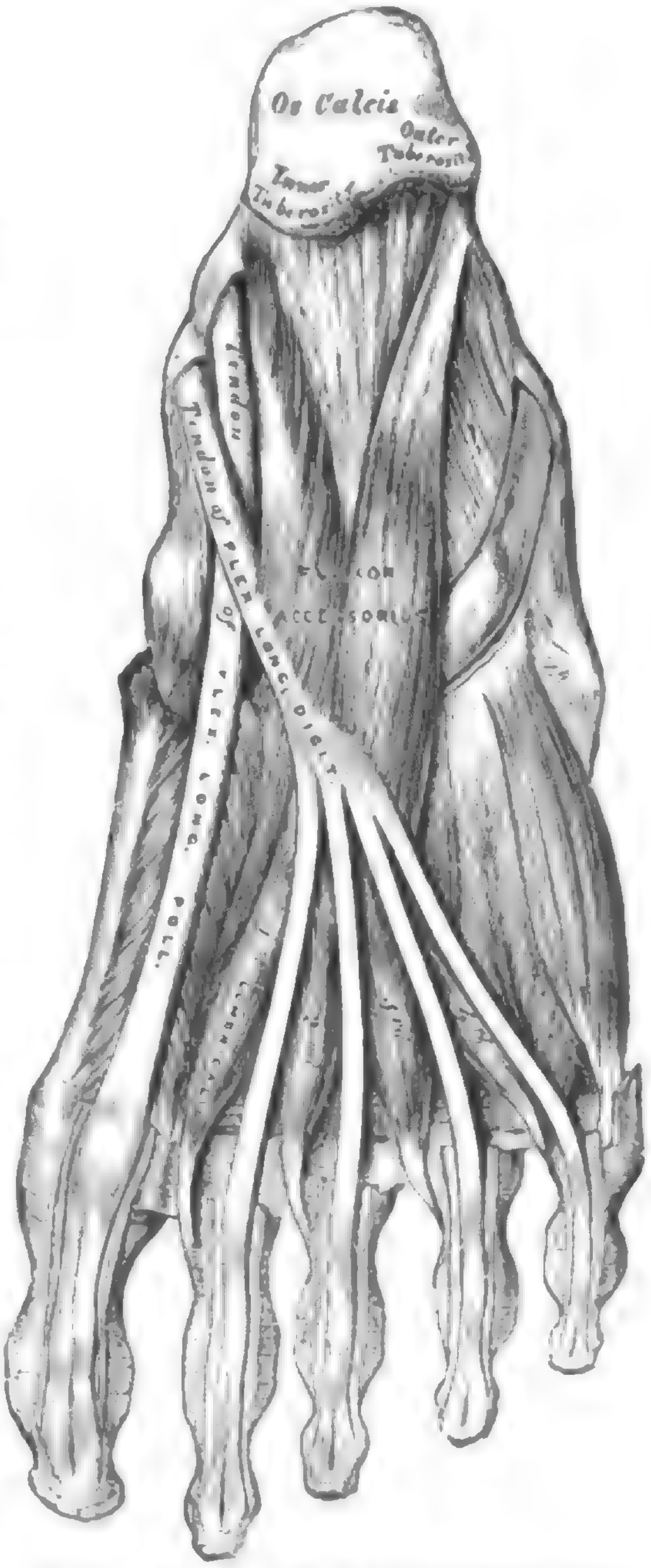

Muscles of the Sole of the Foot, second layer.

Second Layer.

Flexor accessorius.
Lumbricales.

The **Flexor accessorius** arises by two heads, the inner or larger, which is muscular, being attached to the inner concave surface of the os calcis and to the calcaneo-scaphoid ligament; the outer head, flat and tendinous, to the under surface of the os calcis in front of its outer tubercle and to the long plantar ligament: the two portions join at an acute angle, and are inserted into the outer margin and upper and under surfaces of the tendon of the Flexor longus digitorum, forming a kind of groove in which the tendon is lodged.[1]

RELATIONS.—By its *superficial surface* with the muscles of the superficial layer, from which it is separated by the external plantar vessels and nerves; by its *deep surface* with the os calcis and long calcaneo-cuboid ligament.

The **Lumbricales** are four small muscles accessory to the tendons of the Flexor longus digitorum: they arise from the tendons of the long Flexor as far back as their angle of division, each arising from two tendons except the internal one. Each muscle terminates in a tendon which passes forward on the inner side of each of the lesser toes, and is inserted into the expansion of the long Extensor and base of the first phalanx of the corresponding toe.

[ACTIONS.—The Flexor accessorius corrects the otherwise oblique action of the Flexor longus digitorum: this obliquity is a consequence of the heel's preventing the median position of the Flexor longus digitorum, as in the hand. The Lumbricales have the same action as in the hand (p. 457).]

---

[1] According to Turner, the fibres of the Flexor accessorius end in aponeurotic bands, which contribute slips to the second, third, and fourth digits.

Dissection.—The flexor tendons should be divided at the back part of the foot, and the Flexor accessorius at its origin and drawn forward, in order to expose the third layer.

Third Layer.

Flexor brevis pollicis.
Adductor pollicis.
Flexor brevis minimi digiti.
Transversus pedis.

FIG. 345.

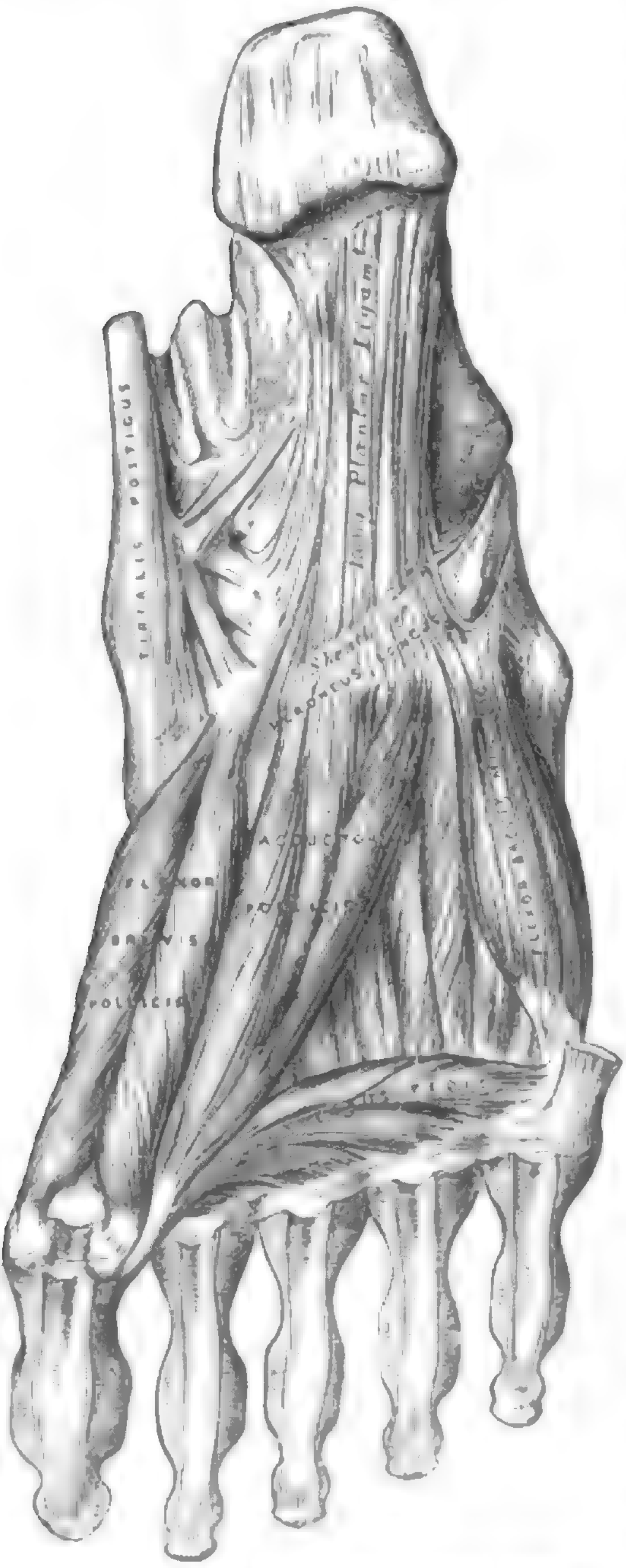

Muscles of the Sole of the Foot, third layer.

The **Flexor brevis pollicis** arises by a pointed tendinous process from the inner border of the cuboid bone, from the contiguous portion of the external cuneiform, and from the prolongation of the tendon of the Tibialis posticus, which is attached to that bone. The muscle divides in front into two portions, which are inserted into the inner and outer sides of the base of the first phalanx of the great toe, a sesamoid bone being developed in each tendon at its insertion. The inner portion of this muscle is blended with the Abductor pollicis previous to its insertion, the outer with the Adductor pollicis, and the tendon of the Flexor longus pollicis lies in a groove between them.

RELATIONS.—By its *superficial surface* with the Abductor pollicis, the tendon of the Flexor longus pollicis, and plantar fascia; by its *deep surface* with the tendon of the Peroneus longus and metatarsal bone of the great toe; by its *inner border* with the Abductor pollicis; by its *outer border* with the Adductor pollicis.

The **Adductor pollicis** is a large, thick, fleshy mass passing obliquely across the foot, and occupying the hollow space between the four inner metatarsal bones. It arises from the tarsal extremities of the second, third, and fourth metatarsal bones, and from the sheath of the tendon of the Peroneus longus, and is inserted, together with the outer portion of the Flexor brevis pollicis, into the outer side of the base of the first phalanx of the great toe.

The **Flexor brevis minimi digiti** lies on the metatarsal bone of the little toe, and much resembles one of the Interossei. It arises from the base of the metatarsal bone of the little toe and from the sheath of the Peroneus longus; its tendon is inserted into the base of the first phalanx of the little toe on its outer side.

RELATIONS.—By its *superficial surface* with the plantar fascia and tendon of the Abductor minimi digiti; by its *deep surface* with the fifth metatarsal bone.

The **Transversus pedis** is a narrow, flat, muscular fasciculus stretched transversely across the heads of the metatarsal bones, between them and the flexor tendons. It arises from the under surface of the head of the fifth metatarsal bone and from the transverse ligament of the metatarsus, and is inserted into the outer side of the first phalanx of the great toe, its fibres being blended with the tendon of insertion of the Adductor pollicis.

RELATIONS.—By its *under surface* with the tendons of the long and short Flexors and Lumbricales: by its *upper surface* with the Interossei.

[ACTIONS.—The Flexor brevis pollicis flexes the first phalanx and extends the second. The Adductor pollicis adducts the toe, but more especially, like the Abductor, is a flexor and extensor. The Flexor brevis minimi digiti flexes and extends the phalanges like the Flexor brevis pollicis. The Transversus pedis increases the lateral arch of the foot and abducts the great toe.]

Fourth Layer.

The Interossei.

The **Interossei** muscles in the foot are similar to those in the hand, with this exception, that they are grouped around the middle line of the second toe, instead of the middle line of the whole member, as in the hand. They are seven in number, and consist of two groups, dorsal and plantar.

The **Dorsal Interossei,** four in number, are situated between the metatarsal bones. They are bipenniform muscles, arising by two heads from the adjacent sides of the metatarsal bones, between which they are placed; their tendons are inserted into the bases of the first phalanges and into the aponeurosis of the common extensor tendon. In the angular interval left between the heads of each muscle at its posterior extremity the perforating arteries pass to the dorsum of the foot, except in the first Interosseous muscle, where the interval allows the passage of the communicating branch of the dorsalis pedis artery. The first Dorsal interosseous muscle is inserted into the inner side of the second toe; the other three are inserted into the outer sides of the second, third, and fourth toes. They are all abductors from the middle line of the second toe.

FIG. 346.

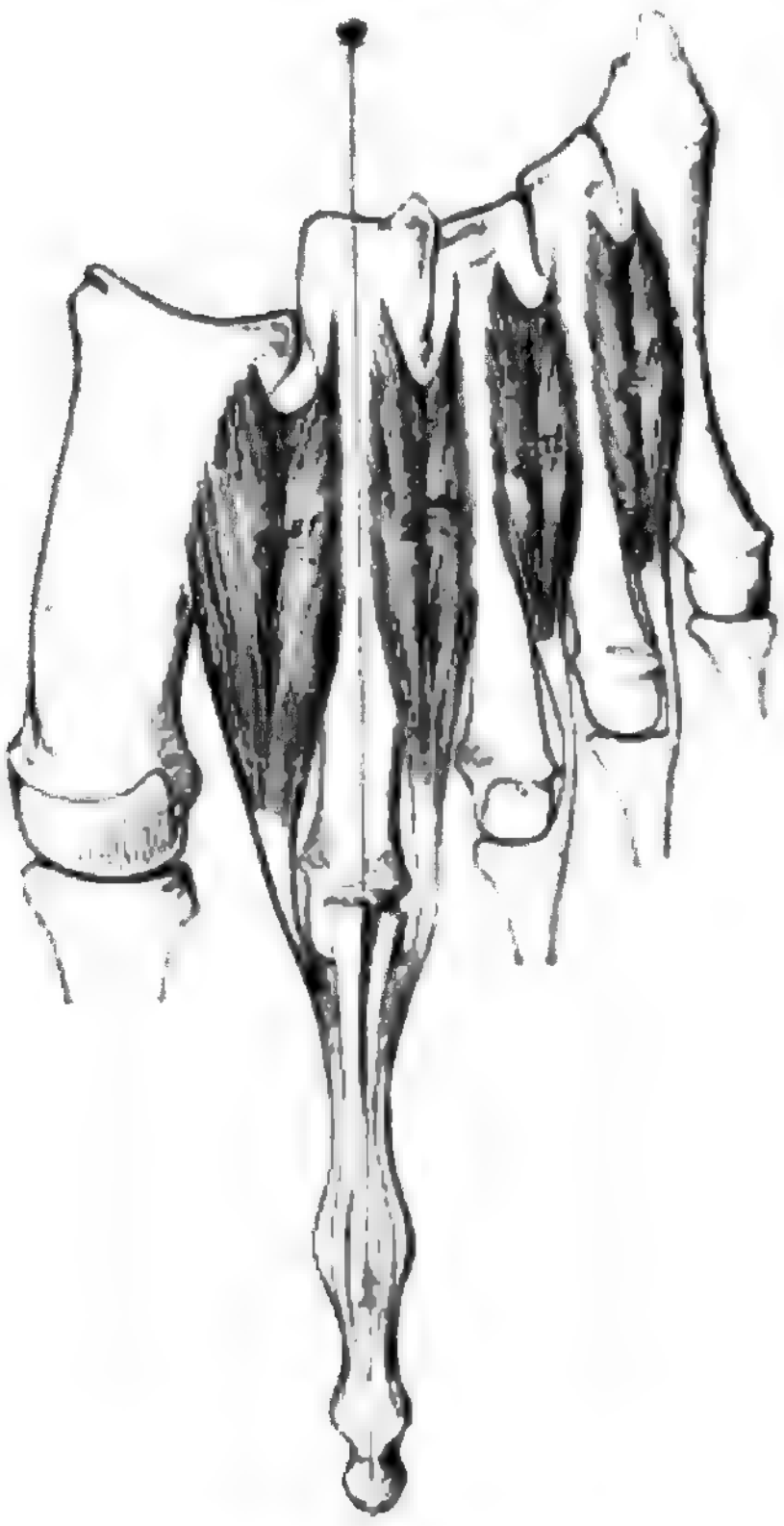

The Dorsal Interossei, left foot.

FIG. 347.

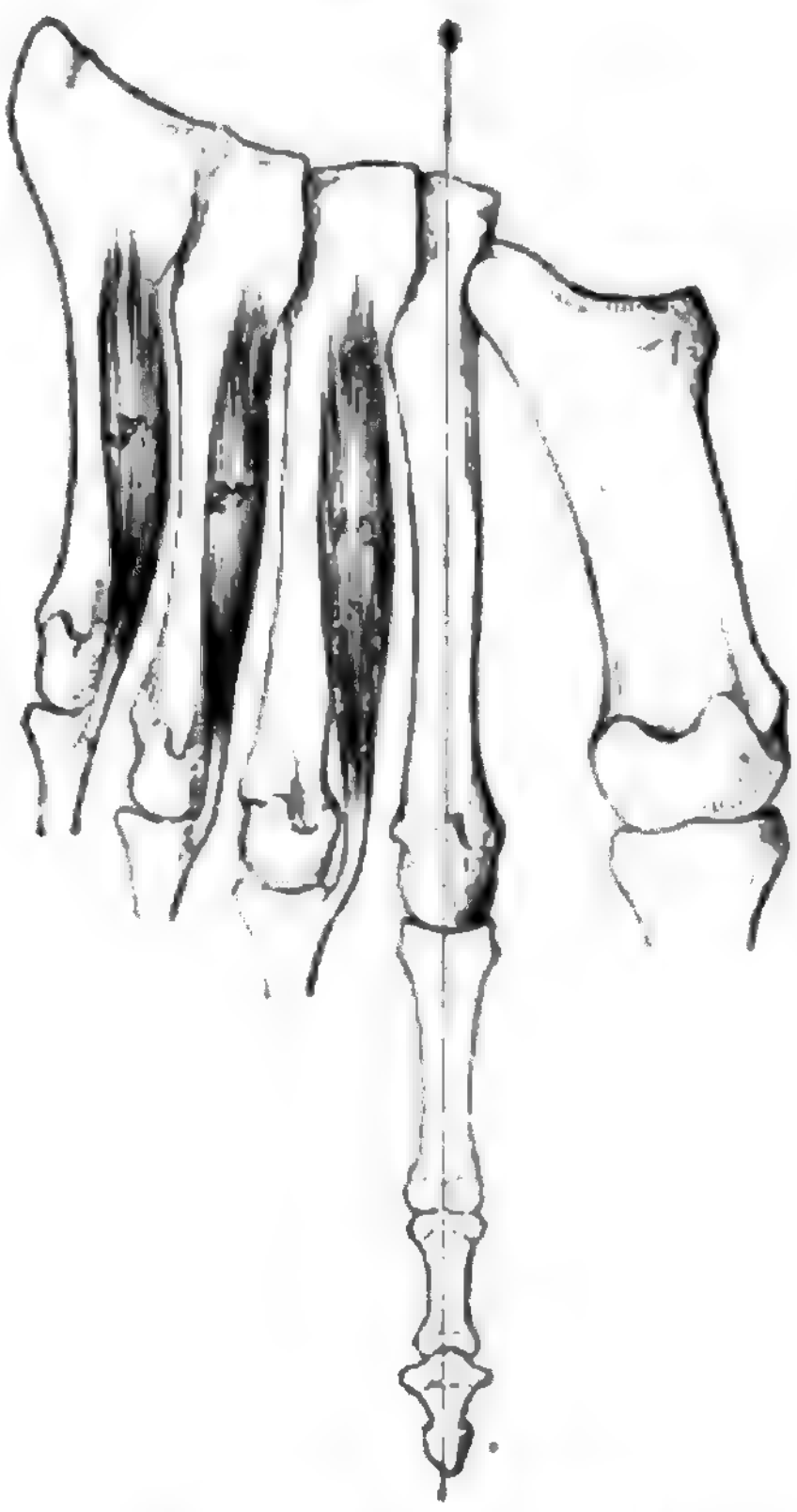

The Plantar Interossei, left foot.

The **Plantar Interossei,** three in number, lie beneath, rather than between, the metatarsal bones. They are single muscles, and are each connected with but one metatarsal bone. They arise from the base and inner sides of the shaft of the third, fourth, and fifth metatarsal bones, and are inserted into the inner sides of the bases of the first phalanges of the same toes, and into the aponeurosis of the common extensor tendon. These muscles are all adductors toward the middle line of the second toe.

Nervous Supply.—The Flexor brevis digitorum, the Flexor brevis and Abductor pollicis, and the two inner Lumbricales are supplied by the internal plantar nerve; all the other muscles in the sole of the foot by the external plantar.

[ACTIONS.—The action of the Interosseous muscles of the foot is precisely similar to those of the hands (p. 457). Many of these muscles of the foot act together, producing very complex results.

The student who desires to study the action of most of the muscles of the body exhaustively is especially referred to Duchenne's work, *Physiologie des Mouvements.*]

SURGICAL ANATOMY.

The student should now consider the effects produced by the action of the various muscles in fractures of the bones of the lower extremity. The more common forms of fracture are selected for illustration and description.

Fracture of the *neck of the femur internal to the capsular ligament* (Fig. 348) is a very common accident, and is most frequently caused by [slight] indirect violence, such as slipping off the edge of the curbstone [tripping on the carpet, etc.], the impetus and weight of the body falling upon the neck of the bone. It usually occurs in females, and seldom under fifty years of age. At this period of life the cancellous tissue of the neck of the bone not unfrequently is atrophied, becoming soft and infiltrated with fatty matter; the compact tissue is partially absorbed; hence the bone is more brittle and more liable to fracture. The characteristic marks of this accident are slight shortening of the limb and eversion of the foot, neither of which symptoms occurs, however, in some cases until some time after the injury. The eversion is caused by the combined action of the external rotator muscles, as well as by the Psoas and Iliacus, Pectineus, Adductors, and Glutei muscles. The shortening is produced by the action of the Glutei and by the Rectoris femoris in front, and the Biceps, Semitendinosus, and Semimembranosus behind.

FIG. 348.

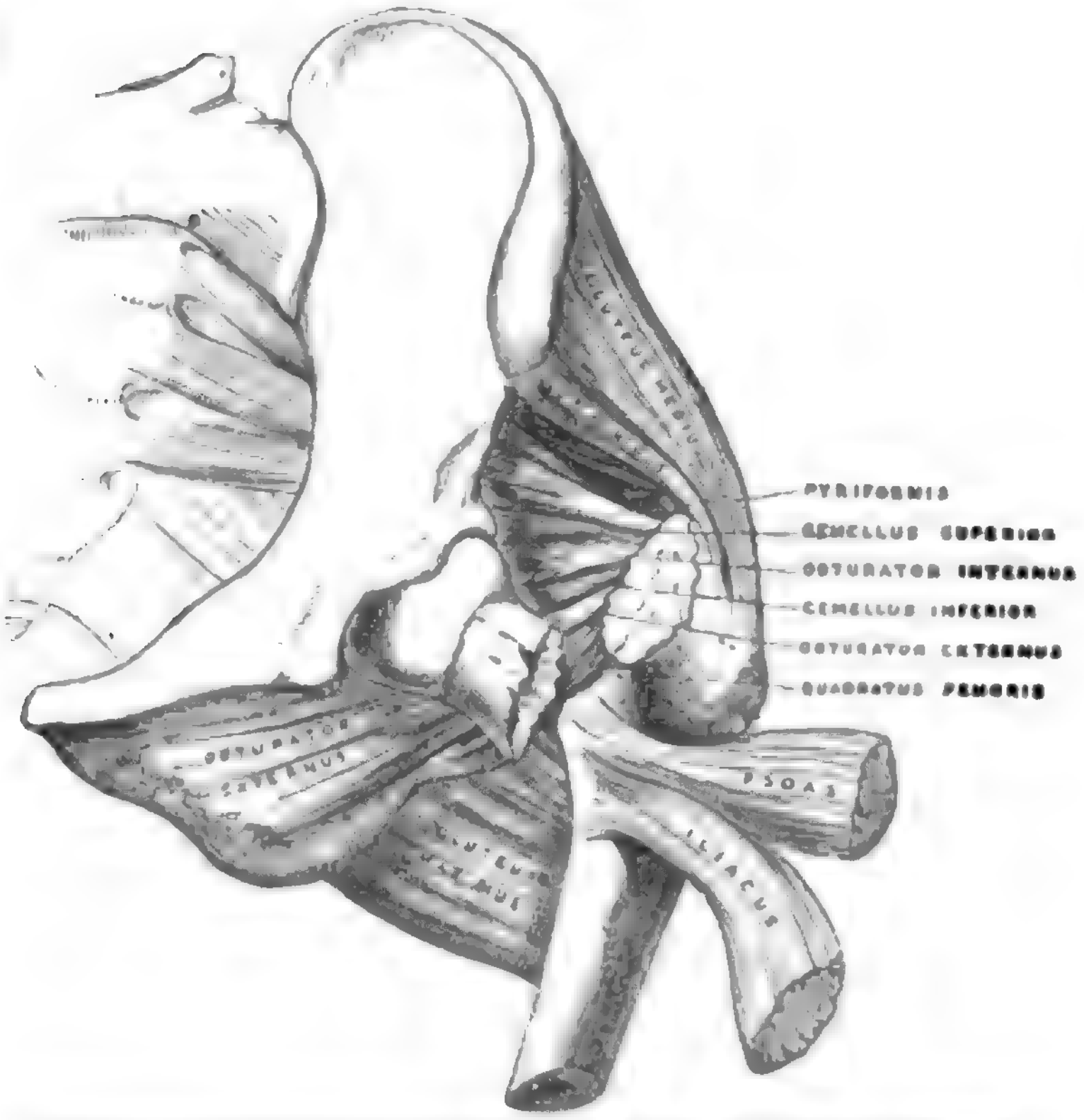

Fracture of the Neck of the Femur within the Capsular Ligament.

FIG. 349.



Fracture of the Femur below the Trochanters.

Fracture of the *femur just below the trochanters* (Fig. 349) is an accident of not unfrequent occurrence, and is attended with great displacement, producing considerable deformity. The upper fragment, the portion chiefly displaced, is tilted forward almost at right angles with the pelvis by the combined action of the Psoas and Iliacus. and at the same time everted and drawn outward by the External rotator and Glutei muscles, causing a marked prominence at the upper and outer side of the thigh, and much pain from the bruising and laceration of the muscles. The limb is shortened in consequence of the lower fragment being drawn upward by the Rectus in front and the Biceps, Semimembranosus, and Semitendinosus behind; at the same time the lower fragment is everted and its upper end thrown outward and its lower inward, by the Pectineus and Adductor [and inner hamstring] muscles. This fracture may be reduced in two different methods: either by direct relaxation of all the opposing muscles, to effect which the limb should be placed on a double inclined plane, or by overcoming the contraction of the muscles by continued extension, which may be effected by means of the long splint.

Oblique fracture of the femur *immediately above the condyles* (Fig. 350) is a formidable injury and attended with considerable displacement. On examination of the limb the lower fragment may be felt deep in the popliteal space, being drawn backward by the Gastrocnemius and Plantaris muscles, and upward by the Posterior femoral [*i. e.* hamstring] and Rectus muscles. The pointed end of the upper fragment is drawn inward by the Pectineus and Adductor muscles, and tilted forward by the Psoas and Iliacus, piercing the Rectus muscle, and occasionally the integument. Relaxation of these muscles and direct approximation of the broken fragments are effected by placing the limb on a double inclined plane. The greatest care is requisite in keeping the pointed extremity of the upper fragment in proper position; otherwise, after union of the fracture the power of extension of the limb is partially destroyed, from the Rectus muscle being held down by the fractured end of the bone, and from the patella, when elevated, being drawn upward against the projecting fragment.

Fracture of the *patella* (Fig. 351) may be produced by muscular action or by direct violence. When produced by muscular action, it occurs thus: A person in danger of falling forward attempts to recover himself by throwing the body backward, and the violent action of the Quadriceps extensor upon the patella fractures the bone transversely. The upper fragment is drawn up the thigh by the Quadriceps extensor, the lower fragment being retained in its position by the ligamentum patellæ, the extent of separation of the two fragments depending upon the degree of laceration of the ligamentous structures around the bone. The patient is totally unable to straighten the limb, the prominence of the patella is lost, and a marked but varying interval can be felt between the fragments. The treatment consists in relaxing the opposing muscles, which may be effected by raising the trunk and slightly elevating the limb, which should be kept in a straight position. Union is usually ligamentous. [The present trend of surgical experience is toward the view that in many cases operative interference by opening the joint and uniting the fragments by sutures is best, and gives true bony union. Malgaigne's hooks are also often used.] In fracture from direct violence the bone is generally comminuted or fractured obliquely or perpendicularly.

FIG. 350.

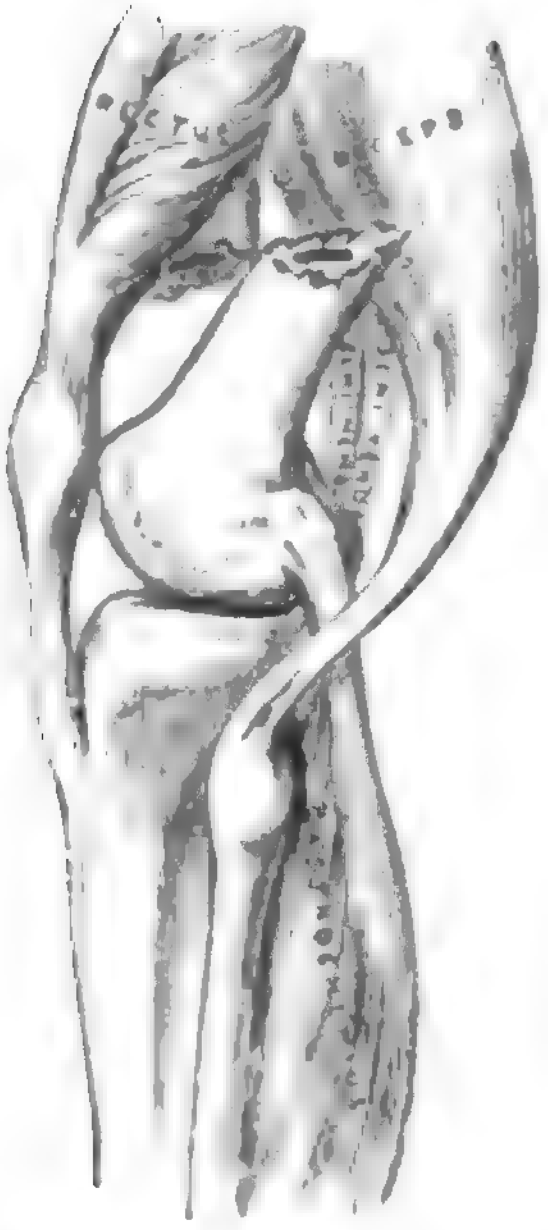

Fracture of the Femur above the Condyles.

FIG. 351.

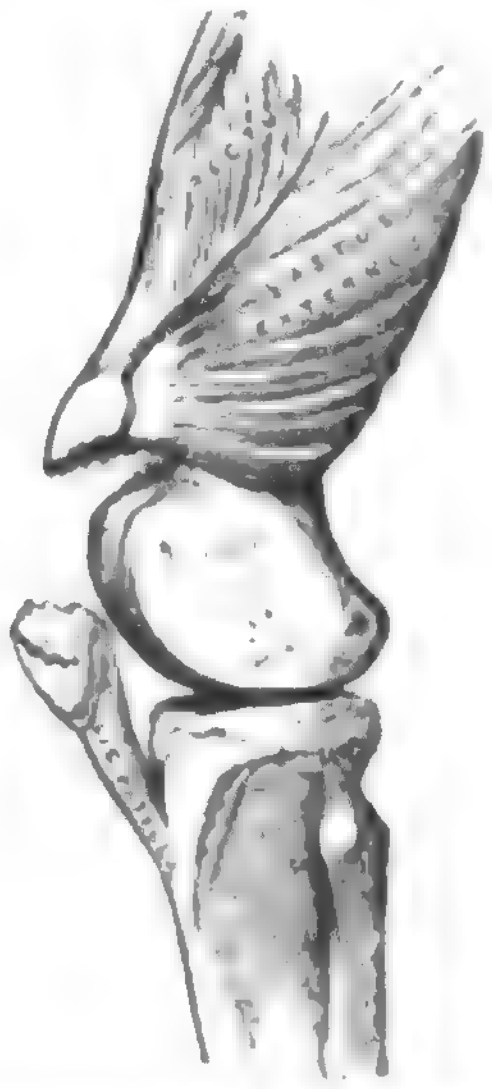

Fracture of the Patella.

Oblique fracture of the *shaft of the tibia* (Fig. 352) [is a very common accident, and] usually occurs at the lower fourth of the bone, this being the narrowest and weakest part, and is usually accompanied by fracture of the fibula. If the fracture has taken place obliquely from above, downward and forward, the fragments ride over one another, the lower fragments being drawn backward and upward by the powerful action of the muscles of the calf: the pointed extremity of the upper fragment projects forward immediately beneath the integument, often protruding through it and rendering the fracture a compound one. If the direction of the fracture is the reverse of that shown in the figure, the pointed extremity of the lower fragment projects forward, riding upon the lower end of the upper one. By bending the knee, which relaxes the opposing muscles, and making the extension from the knee and ankle, the fragments may be brought into apposition. It is often necessary, however, in compound fracture to remove a portion of the projecting bone with the saw before complete adaptation can be effected.

Fracture of the *fibula with dislocation of the foot outward* (Fig. 353), commonly known as "Pott's fracture," is one of the most frequent injuries of the ankle-joint. The end of the tibia is displaced from the corresponding surface of the astragalus, the internal lateral ligament is ruptured, and the inner malleolus projects inward beneath the integument, which is tightly stretched over it and in danger of bursting. The fibula is broken, usually from two to three inches above the ankle, and occasionally that portion of the tibia with which it is more directly connected below; the foot is everted by the action of the Peroneus longus, its inner border resting upon the ground, and at the same time the heel is drawn up by the muscles of the calf. This injury may be at once reduced by flexing the leg at right angles with the thigh, which relaxes all the opposing muscles, and by making slight extension from the knee and ankle. [In many cases comparatively little lateral displacement takes place, and the fracture is only to be diagnosticated by a widening of the intermalleolar space, and sometimes by crepitus. (See a paper by the American Editor in the *Phila. Med. Times*, Aug. 15, 1872).]

FIG. 352.



Oblique Fracture of the Shaft of the Tibia.

FIG. 353.

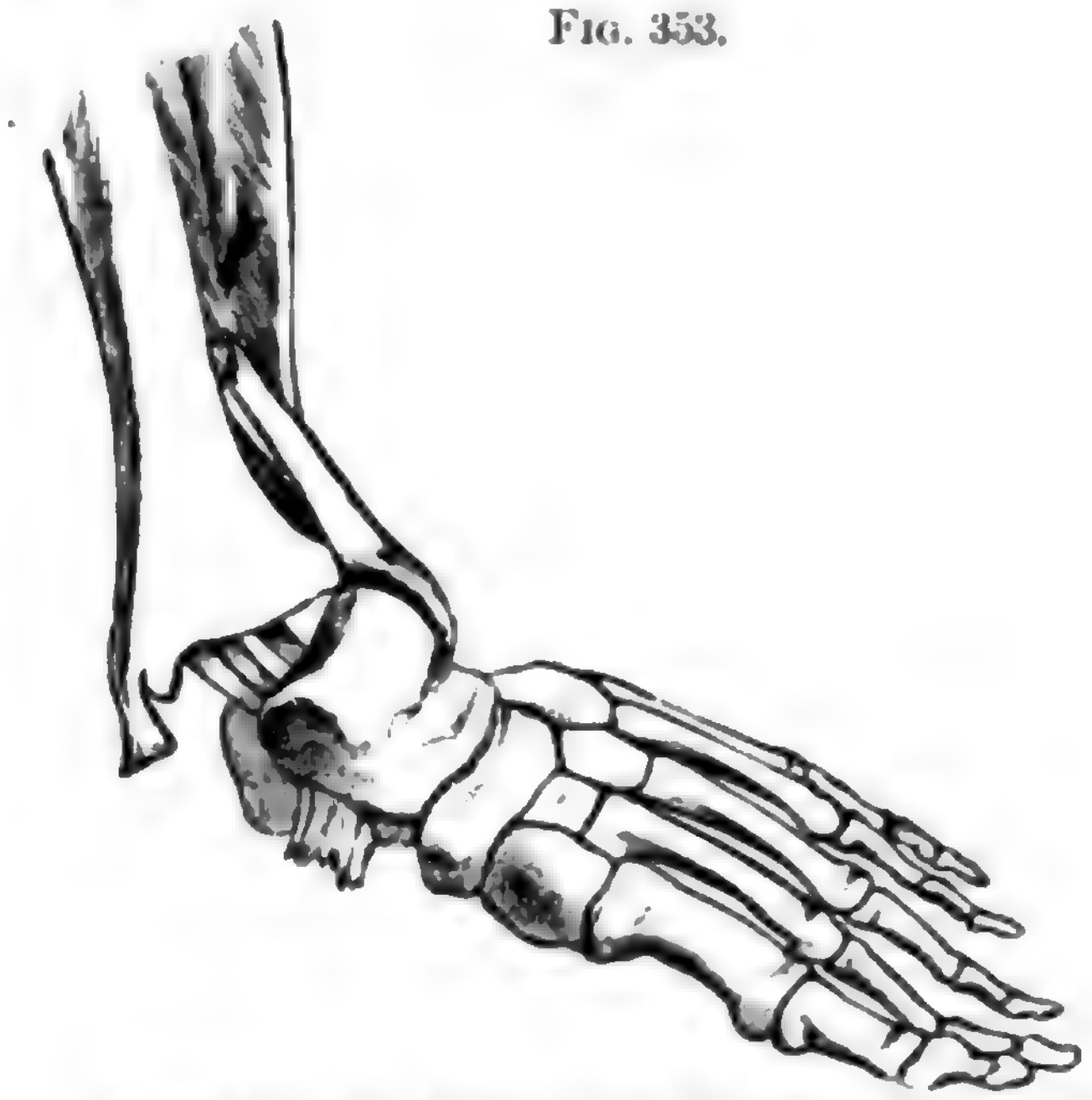

Fracture of the Fibula, with Dislocation of the Foot outward—"Pott's fracture."

[THE ACTION OF INDIVIDUAL MUSCLES, AS SHOWN BY ELECTRICITY.

The following figures from Von Ziemssen show the chief motor points at which an electrode should be applied in order to induce contraction of the various muscles.

[FIG. 354.]

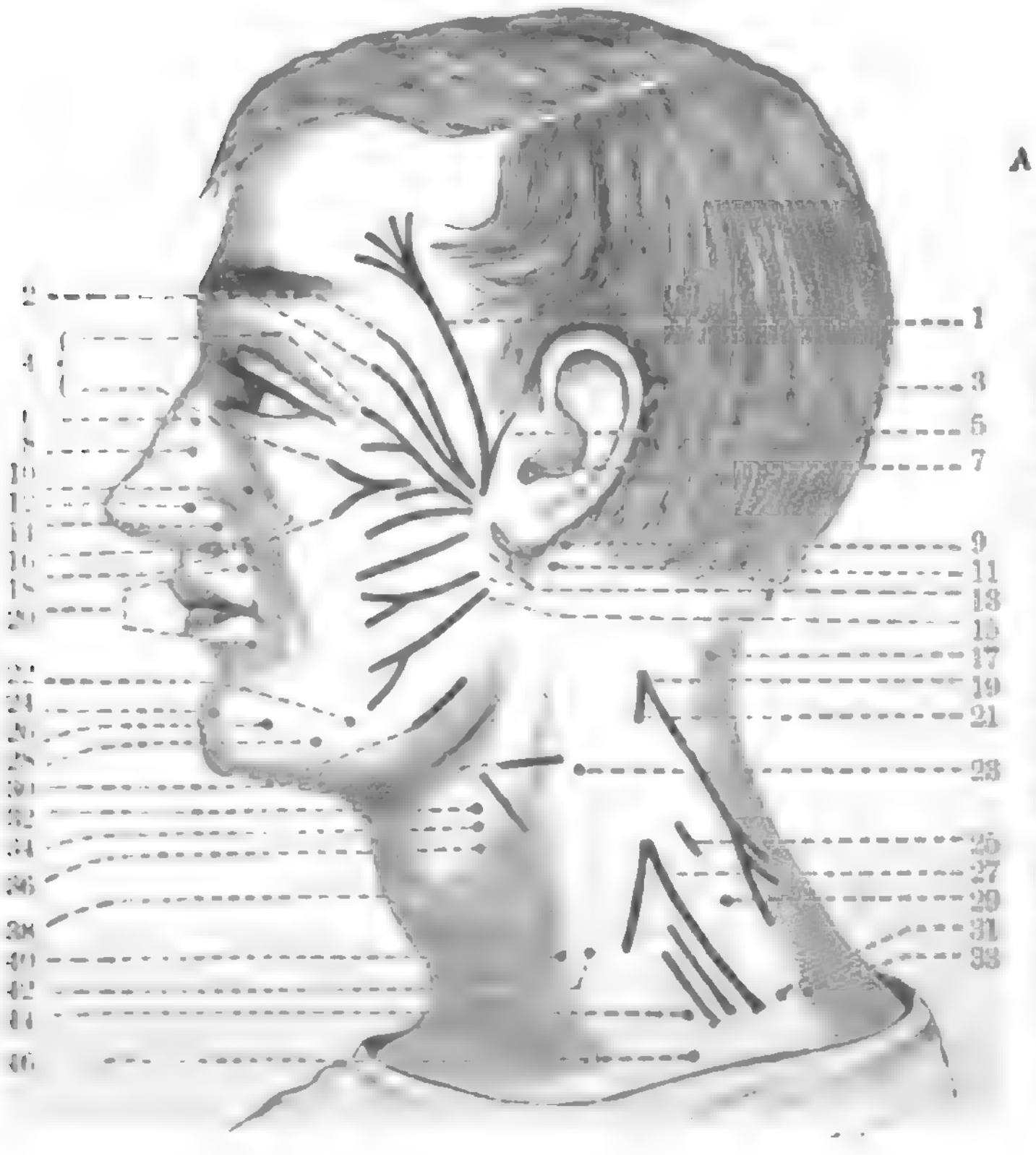

A Diagram of the Motor Points of the Face, showing the position of the electrodes during electrization of special muscles and nerves. The anode is supposed to be placed in the mastoid fossa, and the cathode upon the part indicated in the diagram: 1, Occipito frontalis (ant. belly); 2, Corrugator supercilii; 3, Occipito frontalis (post. belly); 4, Orbicularis palpebrarum; 5, Retrahens and Attolens aurem; 6, Pyramidalis nasi; 7, facial nerve; 8, Lev. lab. sup. et alæ nasi; 9, Stylohyoid; 10, Lev. lab. sup. propr.; 11, Digastric; 12, Dilator naris ant.; 13, Buccal branches of facial nerve; 14, Dilator naris post.; 15, subcutaneous branch of inferior maxillary nerve; 16, Zygomat. minor; 17, Splenius capitus; 18, Zygomat. major; 19, external branch of Spinal accessory nerve; 20, Orbicularis oris; 21, Sterno-mastoid; 22, branch for Levator menti and Dep. ang. oris; 23, Sterno-mastoid; 24, Levator menti; 25, Levator anguli scapulæ; 26, Dep. lab. infer.; 27, phrenic nerve; 28, Dep. ang. oris; 29, posterior thoracic nerve to Rhomboid muscles; 30, subcutaneous nerves of neck; 31, circumflex nerve; 32, Sternohyoid; 33, posterior thoracic nerve to Serratus magnus; 34, Omo-hyoid; 36, Sterno-thyroid; 38, branch for Platysma; 40, Sterno-hyoid; 42, Omo-hyoid; 44, 46, nerves to Pectoral muscles.]

[Fig. 355.]

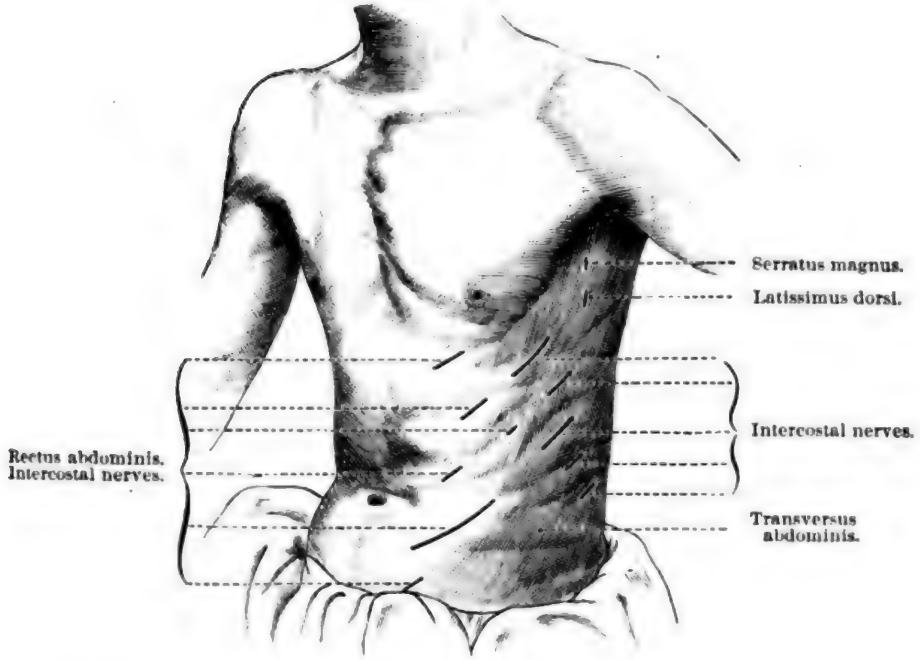
Serratus magnus.
Latissimus dorsi.
Intercostal nerves.
Rectus abdominis.
Intercostal nerves.
Transversus abdominis.

[Fig. 356.]

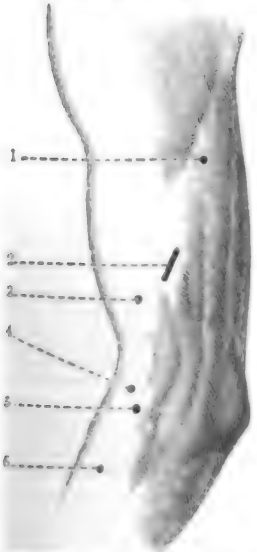

[Fig. 357.]

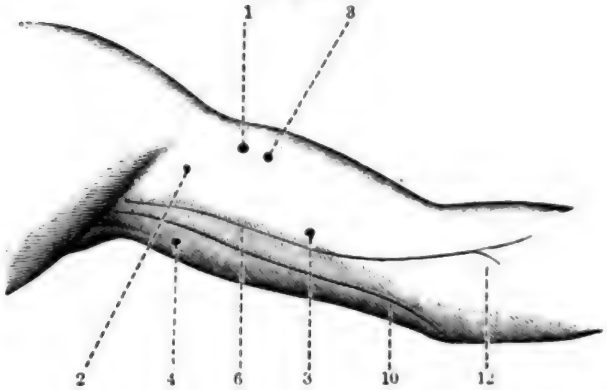
1
3
2
4
6
3
10
12

[Fig. 356.—1, External head of Triceps; 2, musculo-spiral nerve; 3, Brachialis anticus; 4, Supinator longus; 5, Extensor carpi radialis longior; 6, Extensor carpi radialis brevior.]

[Fig. 357.—1, Musculo-cutaneous nerve; 2, musculo-cutaneous nerve; 3, Biceps; 4, internal head of Triceps; 6, median nerve; 8, Brachialis anticus; 10, ulnar nerve; 12, branch of median nerve to the Pronator teres.]

[Fig. 358.]

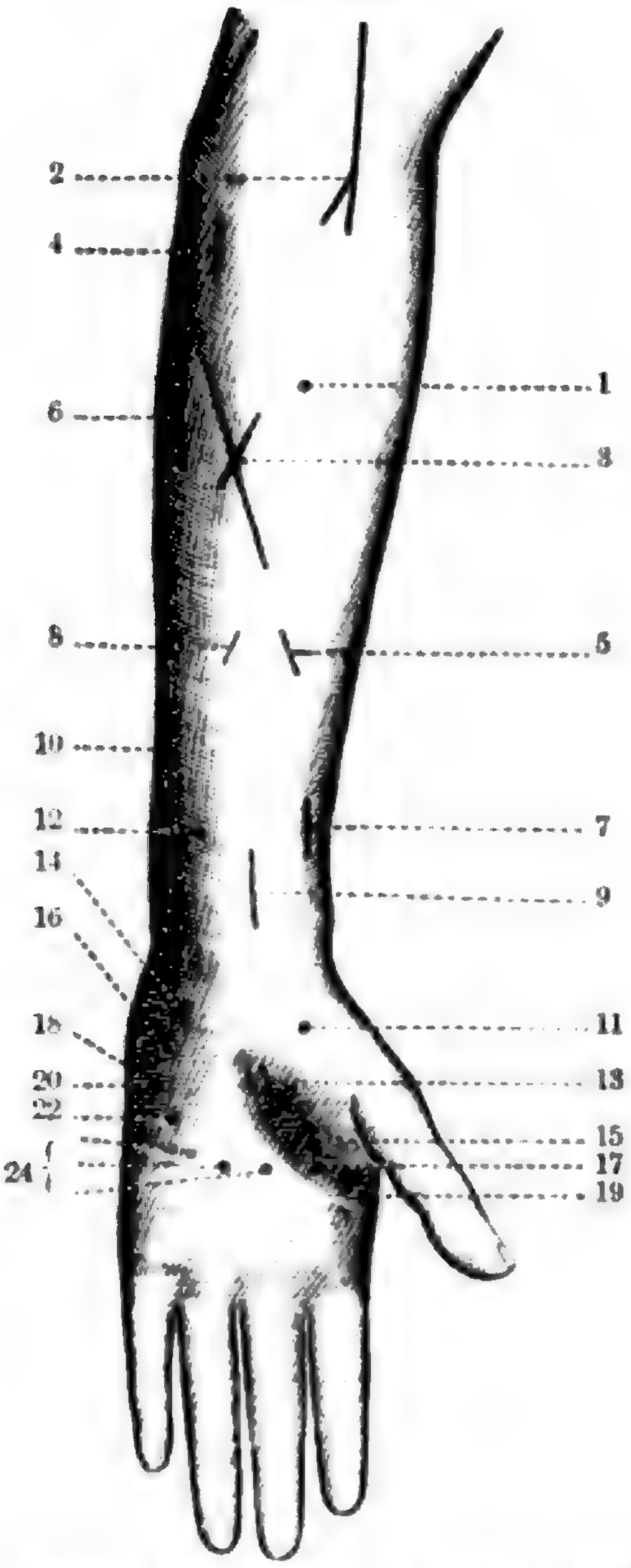

[Fig. 359.]

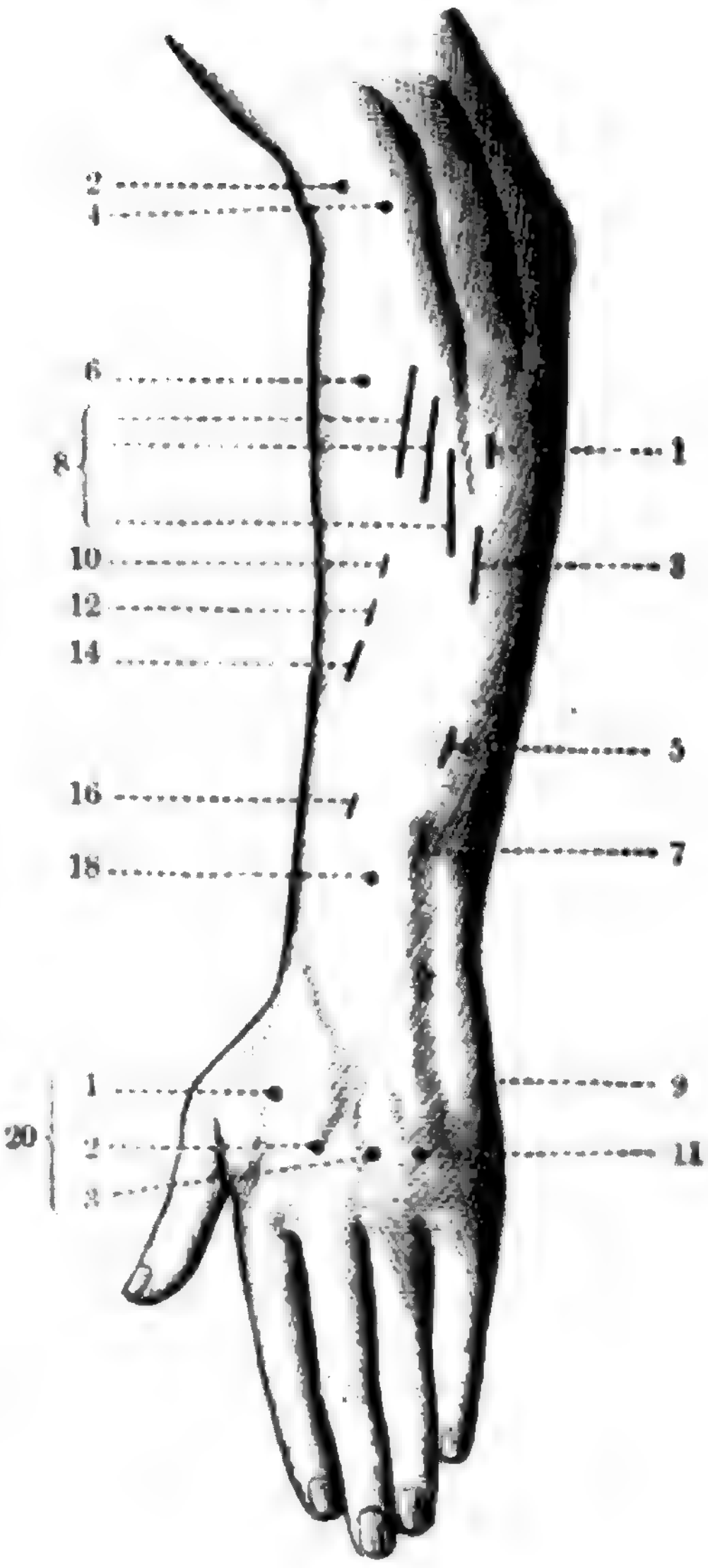

[Fig. 358.—1, Flexor carpi radialis; 2, branch of the median nerve for the Pronator teres; 3, Flexor profundus digitorum; 4, Palmaris longus; 5, Flexor sublimis digitorum; 6, Flexor carpi ulnaris; 7, Flexor longus pollicis; 8, Flexor sublimis digitorum (middle and ring fingers); 9, median nerve; 10, ulnar nerve; 11, Abductor pollicis; 12, Flexor sublimis digitorum (index and little finger); 13, Opponens pollicis; 14, deep branch of ulnar nerve; 15, Flexor brevis pollicis; 16, Palmaris brevis; 17, Adductor pollicis, 18, Abductor minimi digiti; 19, Lumbricalis (1st); 20, Flexor brevis minimi digiti; 22, Opponens minimi digiti; 24, Lumbricales (2, 3, and 4).]

[Fig. 359.—1, Extensor carpi ulnaris; 2, Supinator longus; 3, Extensor minimi digiti; 4, Extensor carpi radialis longior; 5, Extensor indicis; 6, Extensor carpi radialis brevior; 7, Extensor secundi internodii pollicis; 8, Extensor communis digitorum; 9, Abductor minimi digiti; 10, Extensor indicis; 11, Dorsal interosseus (4); 12, Extensor indicis and Extensor ossis metacarpi pollicis; 14, Extensor ossis metacarpi pollicis; 16, Extensor primi internodii pollicis; 18, Flexor longus pollicis; 20, dorsal Interossei.]

[Fig. 360.]

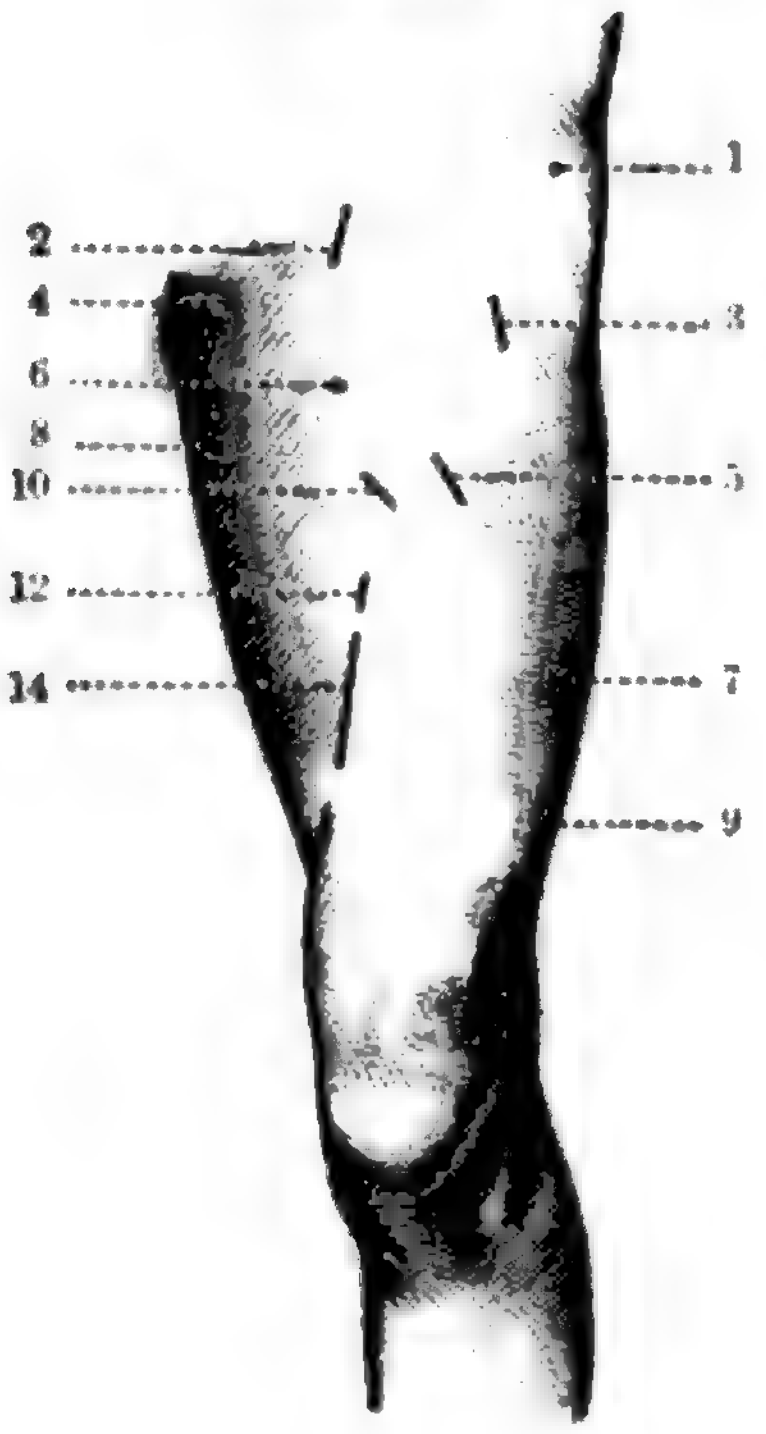

[Fig. 361.]

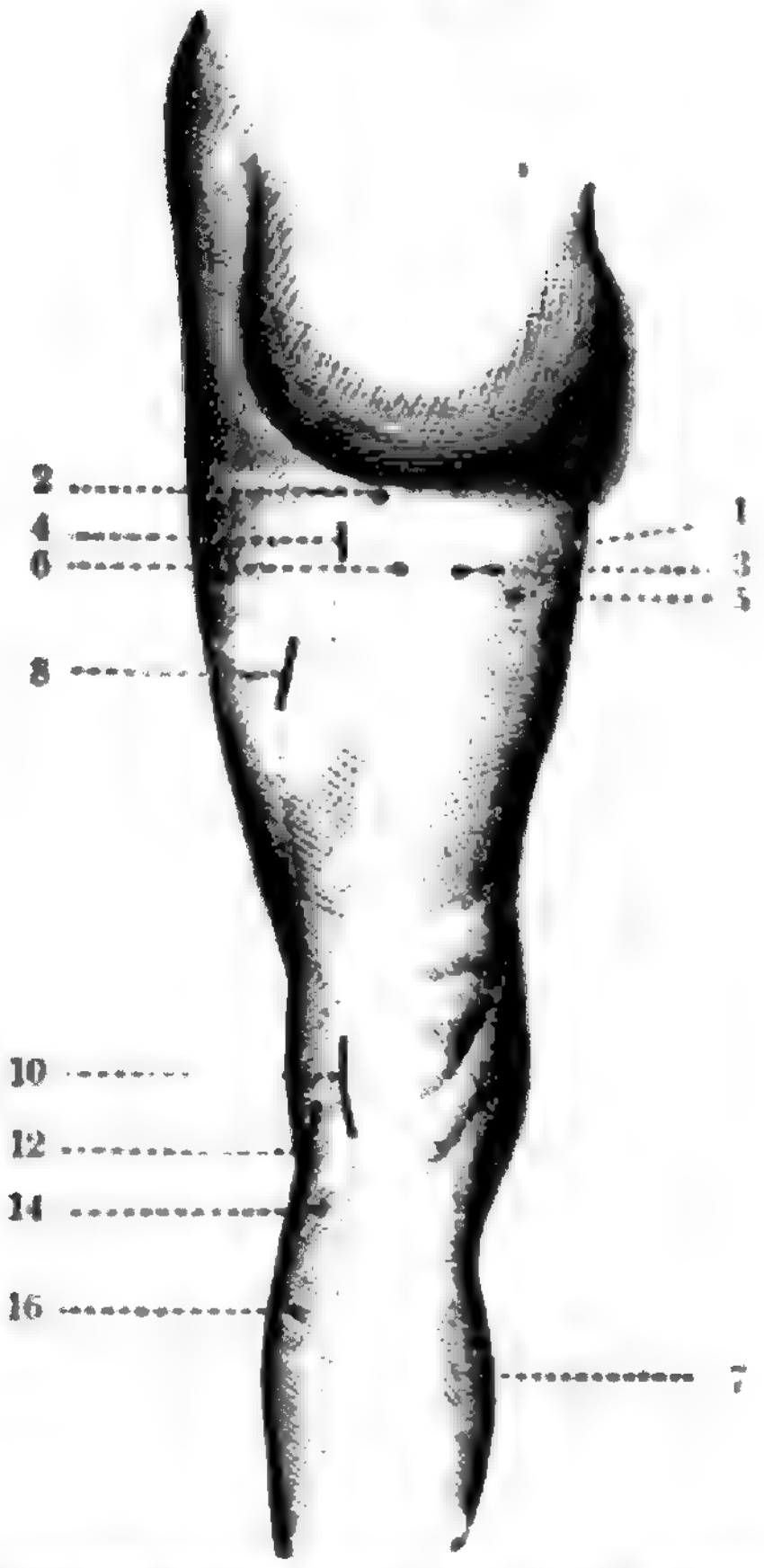

[Fig. 360.—1, Tensor vaginæ femoris (branch of superior gluteal nerve); 2, anterior crural nerve; 3, Tensor vaginæ femoris (branch of crural nerve); 4, obturator nerve; 5, Rectus femoris; 6, Sartorius; 7, Vastus externus; 8, Adductor longus; 9, Vastus externus; 10, branch of crural nerve to Quadriceps extensor cruris; 12, Cruræus; 14, branch of crural nerve, to Vastus externus.]

[Fig. 361.—1, Adductor magnus; 2, inferior gluteal nerve for Gluteus maximus; 3, Semitendinosus; 4, great sciatic nerve; 5, Semimembranosus; 6, long head of Biceps; 7, Gastrocnemius (internal head); 8, short head of Biceps; 10, posterior tibial nerve; 12, peroneal nerve; 14, Gastrocnemius (external head); 16, Soleus.]

[Fig. 362.]

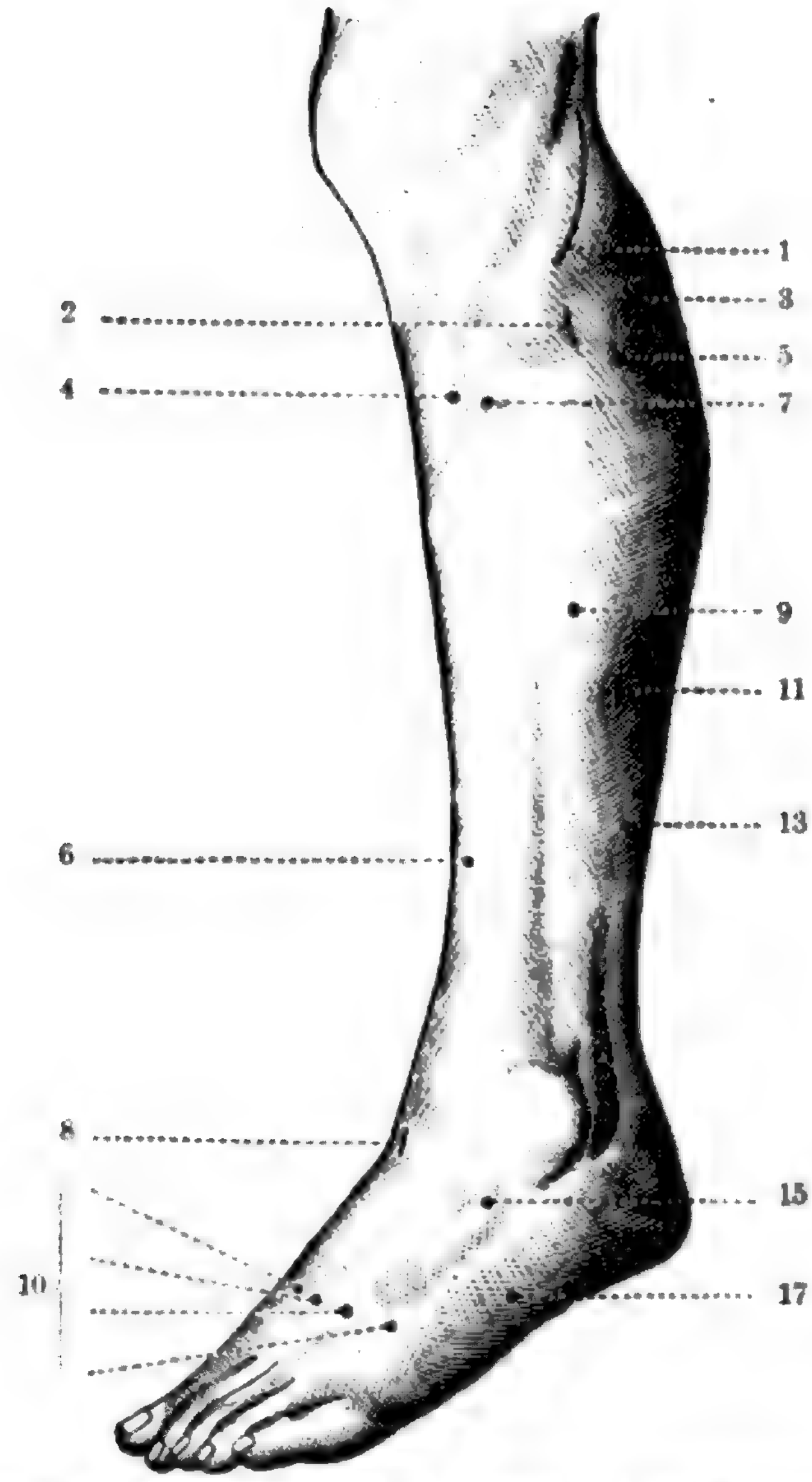

[Fig. 363.]

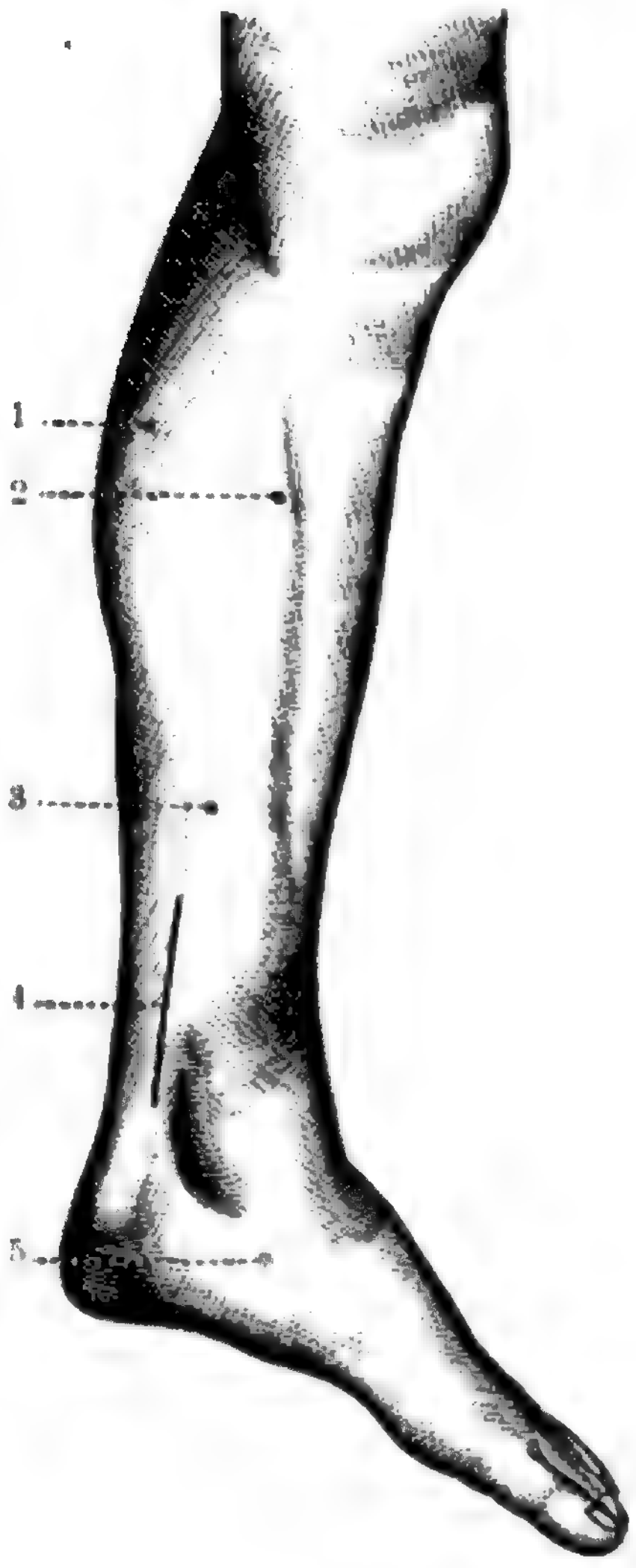

[Fig. 362.—1. Peroneal nerve; 2, Peroneus longus; 3, Gastrocnemius (external head); 4, Tibialis anticus; 5, Soleus; 6, Extensor longus pollicis; 7, Extensor communis digitorum longus; 8, branch of peroneal nerve for Extensor brevis digitorum; 9, Peroneus brevis; 10, dorsal Interossei; 11, Soleus; 13, Flexor longus pollicis. 15, Extensor brevis digitorum; 17, Abductor minimi digiti.]

[Fig. 363.—1, Gastrocnemius (internal head); 2, Soleus; 3, Flexor communis digitorum longus; 4, posterior tibial nerve; 5, Abductor pollicis.]

Of the Arteries.

THE **Arteries** are cylindrical tubular vessels which serve to convey blood from both ventricles of the heart to every part of the body. These vessels were named "arteries" (ἀήρ, air; τηρεῖν, to contain) from the belief entertained by the ancients that they contained air. To Galen is due the honor of refuting this opinion; he showed that these vessels, though for the most part empty after death, contain blood in the living body.

The pulmonary artery, which arises from the right ventricle of the heart, carries venous blood directly into the lungs, whence it is returned by the pulmonary veins into the left auricle. This constitutes the *lesser* or *pulmonic* circulation. The great artery, which arises from the left ventricle, the aorta, conveys arterial blood to the body generally, whence it is brought back to the right side of the heart by means of the veins. This constitutes the *greater* or *systemic* circulation.

The distribution of the systemic arteries is like a highly ramified tree, the common trunk of which, formed by the aorta, commences at the left ventricle of the heart, the smallest ramifications corresponding to the circumference of the body and the contained organs. The arteries are found in every part of the body with the exception of the hairs, nails, epidermis, cartilages, and cornea, and the larger trunks usually occupy the most protected situations, running in the limbs along the flexor side, where they are less exposed to injury.

There is considerable variation in the mode of division of the arteries: occasionally a short trunk subdivides into several branches at the same point, as we observe in the cœliac and thyroid axes; or the vessel may give off several branches in succession, and still continue as the main trunk, as is seen in the arteries of the limbs; but the usual division is dichotomous—as, for instance, the aorta, dividing into the two common iliacs; and the common carotid, into the external and internal.

The branches of arteries arise at very variable angles: some, as the superior intercostal arteries from the aorta, arise at an obtuse angle; others, as the lumbar arteries, at a right angle; or, as the spermatic, at an acute angle. An artery from which a branch is given off is smaller in size, but retains a uniform diameter until a second branch is derived from it. A branch of an artery is smaller than the trunk from which it arises, but if an artery divides into two branches, the combined area of the two vessels is in nearly every instance somewhat greater than that of the trunk, and the combined area of all the arterial branches greatly exceeds the area of the aorta; so that the arteries collectively may be regarded as a cone, the apex of which corresponds to the aorta, the base to the capillary system.

The arteries in their distribution communicate freely with one another, forming what is is called an *anastomosis* (ἀνά, between; στόμα, mouth) or inosculation; and this communication is very free between the large as well as between the smaller branches. The anastomosis between trunks of equal size is found where great freedom and activity of the circulation are requisite, as in the brain; here the two vertebral arteries unite to form the basilar, and the two internal carotid arteries are connected by a short communicating trunk; it is also found in the abdomen, the intestinal arteries having very free anastomoses between their larger branches. In the limbs the anastomoses are most frequent and of largest size around the joints, the branches of an artery above freely inosculating with branches from the vessels below: these anastomoses are of considerable interest to the surgeon, as it is by their enlargement that a *collateral circulation* is established after the application of a ligature to an artery for the cure of aneurism. The smaller branches of arteries anastomose more frequently than the larger, and between the smallest twigs these inosculations become so numerous as to constitute a close network that pervades nearly every tissue of the body.

Throughout the body generally the larger arterial branches pursue a perfectly straight course, but in certain situations they are tortuous: thus, the facial artery in its course over the face, and the arteries of the lips, are extremely tortuous in their course to accommodate themselves to the movements of the parts. The uterine arteries are also tortuous, to accommodate themselves to the increase of size which the organ undergoes during pregnancy. Again, the internal carotid and vertebral arteries previous to their entering the cavity of the skull describe a series of curves which are evidently intended to diminish the velocity of the current of blood by increasing the extent of surface over which it moves and adding to the amount of impediment which is produced by friction.

The arteries are dense in structure, of considerable strength, highly elastic, and when divided they preserve, although empty, their cylindrical form.

The minute structure of these vessels is described in the chapter on General Anatomy [p. 78].

In the description of the arteries we shall first consider the efferent trunk of the pulmonic circulation, the pulmonary artery, and then the efferent trunk of the systemic circulation, the aorta and its branches.

Pulmonary Artery (Fig. 364).

The **Pulmonary Artery** conveys the venous blood from the right side of the heart to the lungs. It is a short wide vessel, about two inches in length, arising from the left side of the base of the right ventricle in front of the aorta. It ascends obliquely upward, backward, and to the left side, winding spirally in front of and then to the left of the ascending part of the arch of the aorta as far as the under surface of the transverse portion of the arch, where it divides into two branches of nearly equal size, the *right and left pulmonary* arteries.

Relations.—The greater part of this vessel is contained, together with the ascending part of the arch of the aorta, in the pericardium, being enclosed with it in a tube of serous membrane continued upward from the base of the heart, and has attached to it above the fibrous layer of the membrane. Behind it rests at first upon the ascending aorta, and higher up lies in front of the left auricle. On either side of its origin is the appendix of the corresponding auricle and a coronary artery, and higher up it passes to the left side of the ascending aorta.

A little to the left of its point of bifurcation it is connected to the under surface of the arch of the aorta by a short fibrous cord, the remains of a vessel peculiar to fœtal life, the *ductus arteriosus.*

The **Right Pulmonary Artery,** longer and larger than the left, runs horizontally outward, behind the ascending aorta and superior vena cava, to the root of the right lung, where it divides into two branches, of which the lower, which is the larger, supplies the lower lobe, the upper giving a branch to the middle lobe.

The **Left Pulmonary Artery,** shorter and somewhat smaller than the right, passes horizontally in front of the descending aorta and left bronchus to the root of the left lung, where it divides into two branches for the two lobes.

The terminal branches of the pulmonary artery will be described with the anatomy of the Lung.

The Aorta.

The **Aorta** (*ἀορτή*, arteria magna) is the main trunk of a series of vessels which, arising from the heart, convey the red oxygenated blood to every part of the body for its nutrition. This vessel commences at the upper part of the left ventricle, and, after ascending for a short distance, arches backward and to the left side over the root of the left lung, descends within the thorax on the left side of the vertebral column, passes through the aortic opening in the Diaphragm, and, entering the abdominal cavity, terminates, considerably diminished in size, opposite the fourth lumbar vertebra, where it divides into the right and left common iliac arteries. Hence its subdivision, from the direction or position of its parts, into the *arch* of the aorta, [and] the *descending* [aorta, which last is again divided into the] *thoracic* aorta and the *abdominal* aorta.[1]

FIG. 364.

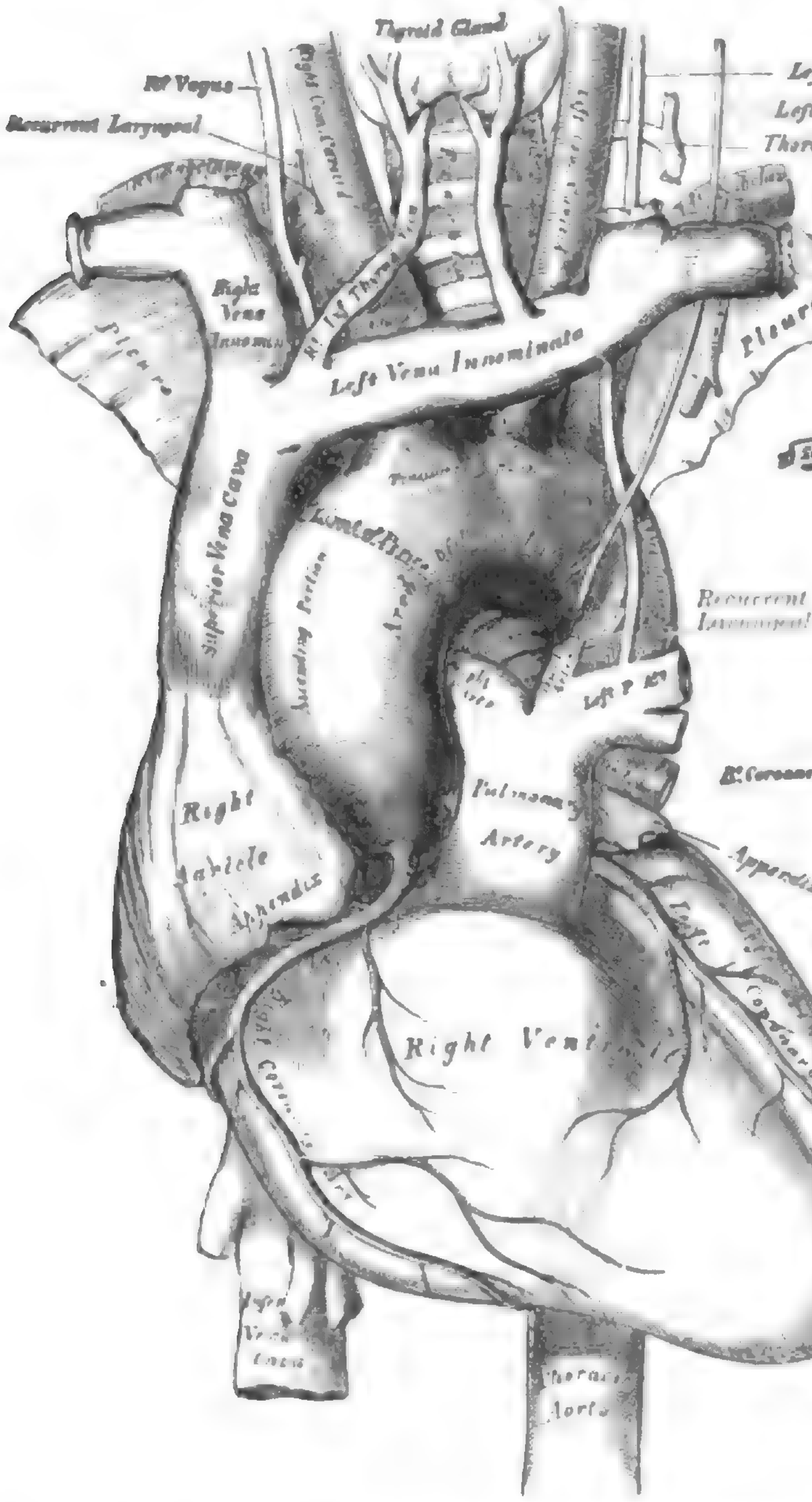
Thyroid Gland
Rt Vagus
Recurrent Laryngeal
Right Com. Carotid
Left Vagus
Left Phrenic
Thoracic Duct
Right Vena Innom.
Left Vena Innominata
Pleura
Pleura
Superior Vena Cava
Ascending Portion
Arch of Aorta
Recurrent Laryngeal
Left P. A.
Pulmonary Artery
Right Auricle
Appendix
Appendix of Left Auricle
Left Ventricle
Left Coronary
Right Ventricle
Right Coronary
Infer. Vena Cava
Thoracic Aorta

The Arch of the Aorta and its Branches.

FIG. 365.

Plan of the Branches.

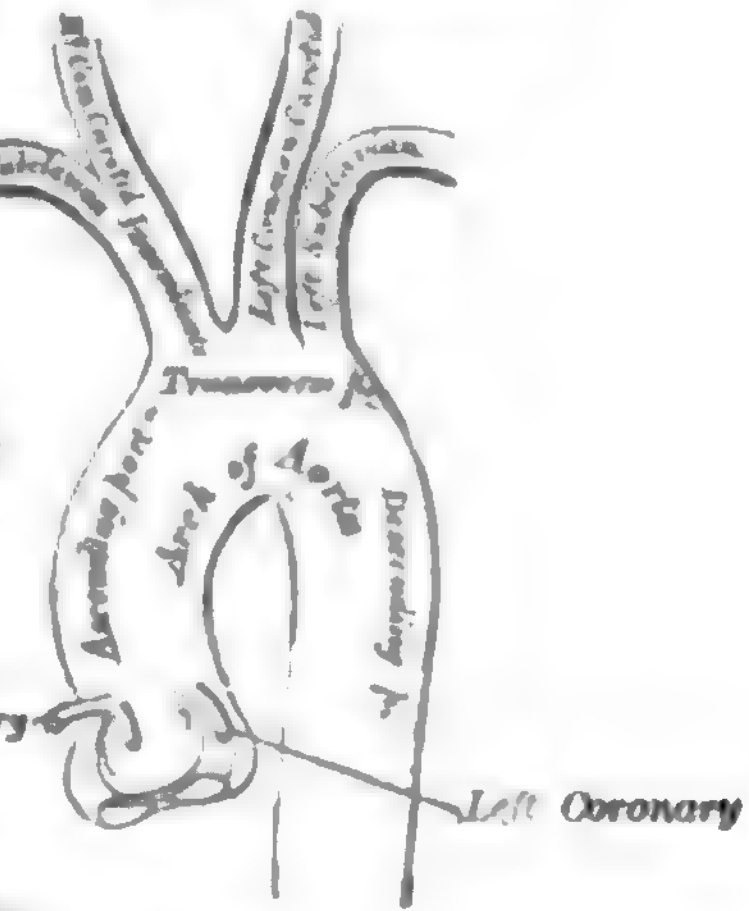
Rt Subclavian
Rt Com. Carotid
Left Common Carotid
Left Subclavian
Transverse P.
Ascending portion
Arch of Aorta
Descending P.
Rt Coronary
Left Coronary

ARCH OF THE AORTA.

Dissection.—In order to examine the arch of the aorta, open the thorax by dividing the cartilages of the ribs on each side of the sternum, raising this bone from below upward, and then sawing through the sternum on a level with its articulation with the clavicle. By this means the relations of the large vessels to the upper border of the sternum and root of the neck are kept in view.

The **Arch of the Aorta** extends from the origin of the vessel at the upper part of the left ventricle to the lower border of the body of the fifth dorsal vertebra. At its commencement it ascends behind the sternum obliquely upward and forward toward the right side, and opposite the upper border of the second costal cartilage of the right side passes transversely, from right to left and from before backward, to the left side of the lower border of the fourth dorsal vertebra; it then descends upon the left side of the body of the fifth dorsal vertebra, at the lower border of which it takes the name of thoracic aorta. The arch of the aorta describes a curve, the convexity of which is directed upward and to the right side, and it is subdivided at the points where it changes its direction so as to be described in three portions—the ascending, transverse, and descending portions of the arch of the aorta.

---

[1] These portions of the aorta would be better named transverse aorta, dorsal aorta, and abdominal or lumbar aorta; but I hesitate to introduce new names in place of those in universal use.

ASCENDING PART OF THE ARCH.

The **ascending portion** of the arch of the aorta is about two inches in length. It commences at the upper part of the left ventricle, in front of the left auriculo-ventricular orifice, and on a level with the lower border of the third costal cartilage behind the centre of the sternum; it passes obliquely upward, in the direction of the heart's axis, to the right side, as high as the upper border of the second right costal cartilage, describing a slight curve in its course, and being situated, when distended, about a quarter of an inch behind the posterior surface of the sternum. A little above its commencement it is somewhat enlarged, and presents three small dilatations, called the *sinuses of the aorta* (sinuses of Valsalva), opposite to which are attached the three semilunar valves, which serve the purpose of preventing any regurgitation of blood into the cavity of the ventricle. A section of the aorta opposite this part has a somewhat triangular figure, but below the attachment of the valves it is circular. This portion of the aorta is contained in the cavity of the pericardium, and, together with the pulmonary artery, is invested in a tube of serous membrane continued on to them from the surface of the heart.

RELATIONS.—The ascending part of the arch is covered at its commencement by the trunk of the pulmonary artery and the right appendix auriculæ, and higher up is separated from the sternum by the pericardium, some loose areolar tissue, and the remains of the thymus gland; *behind* it rests upon the right pulmonary vessels and root of the right lung. On the *right side* it is in relation with the superior vena cava and right auricle; on the *left side*, with the pulmonary artery.

PLAN OF THE RELATIONS OF THE ASCENDING PART OF THE ARCH.

In Front.

Pulmonary artery.
Right appendix auriculæ.
Pericardium.
Remains of thymus gland.

Right Side.

Superior cava.
Right auricle.

Arch of Aorta.
Ascending
Portion.

Left Side.

Pulmonary artery.

Behind.

Right pulmonary vessels.
Root of right lung.

TRANSVERSE PART OF THE ARCH.

The **second or transverse portion** of the arch commences at the upper border of the second chondro-sternal articulation of the right side, and passes from right to left and from before backward, to the left side of the lower border of the fourth dorsal vertebra behind.[1] Its upper border is usually about an inch below the upper margin of the sternum.

---

[1] Mr. J. Wood gives the following account of the relations and extent of the arch of the aorta, as the result of his observations on thirty-two subjects, fourteen male and eighteen female, in whom an antero-posterior vertical section of the spinal column from top to bottom had been made, with the viscera *in situ:*

The cardiac opening of the aorta lies in a horizontal plane drawn through the centre of the third bone of the sternum, passing midway between the third and fourth rib-cartilages, and emerging behind

RELATIONS.—Its *anterior surface* is covered by the left pleura and lung and remains of the thymus gland, and crossed toward the left side by the left pneumogastric and phrenic nerves and superficial cardiac branches of the left sympathetic, and by the left superior intercostal vein. Its *posterior surface* lies on the trachea, just above its bifurcation, on the great or deep cardiac plexus, the œsophagus, thoracic duct, and left recurrent laryngeal nerve. Its *upper border* is in relation with the left innominate vein, and from its upper part are given off the innominate, left common carotid, and left subclavian arteries. Its *lower border* is in relation with the bifurcation of the pulmonary artery and the remains of the ductus arteriosus, which is connected with the left division of that vessel; the left recurrent laryngeal nerve winds round it from before backward, whilst the left bronchus passes below it.

PLAN OF THE RELATIONS OF THE TRANSVERSE PART OF THE ARCH.

Above.
Left innominate vein.
Arteria innominata.
Left carotid.
Left subclavian.

In Front.
Left pleura and lung.
Remains of thymus gland.
Left pneumogastric nerve.
Left phrenic nerve.
Superficial cardiac nerves.
Left superior intercostal vein.

Arch of Aorta.
Transverse
Portion.

Behind.
Trachea.
Deep cardiac plexus.
Œsophagus.
Thoracic duct.
Left recurrent nerve.

Below.
Bifurcation of pulmonary artery.
Remains of ductus arteriosus.
Left recurrent nerve.
Left bronchus.

DESCENDING PART OF THE ARCH.

The **descending portion** of the arch has a straight direction, inclining downward on the left side of the body of the fifth dorsal vertebra, at the lower border of which it takes the name of descending thoracic aorta.

RELATIONS.—Its *anterior surface* is covered by the pleura and root of the left lung; *behind* it lies on the left side of the body of the fifth dorsal vertebra. On its *right side* are the œsophagus and thoracic duct; on its *left side* it is covered by the pleura.

PLAN OF THE RELATIONS OF THE DESCENDING PART OF THE ARCH.

In Front.
Pleura.
Root of left lung.

Right Side.
Œsophagus.
Thoracic duct.

Arch of Aorta.
Descending
Portion.

Left Side.
Pleura.

Behind.
Left side of body of fifth dorsal vertebra.

---

about the tip of the sixth dorsal spinous process. The highest point of the aortic arch lies from three-quarters of an inch to an inch from the posterior surface of the second bone of the sternum, close to its right border and to the inner side of the joint between the second right rib-cartilage and the sternum. It approaches the lower border of the left side of the fourth dorsal vertebra, and first touches the spine usually about the intervertebral substance between the fourth and fifth vertebræ. It then assumes a more vertical direction, and lies against the left side of the body of the fifth dorsal vertebra, which is, in fact, the uppermost vertebra which shows on its body the impression or flattening produced by contact with the aorta (*Journ. of Anat. and Phys.*, vol. iii.).

This description is the one usually accepted, and is supported by the observations of Pirogoff, but some anatomists put the two lower portions of the arch one vertebra higher.

The ascending, transverse, and descending portions of the arch vary in position according to the movements of respiration, being lowered, together with the trachea, bronchi, and pulmonary vessels, during inspiration by the descent of the Diaphragm, and elevated during expiration, when the Diaphragm ascends. These movements are greater in the ascending than the transverse, and in the latter than the descending part.

Peculiarities.—The height to which the aorta rises in the chest is usually about an inch below the upper border of the sternum, but it may ascend nearly to the top of that bone. Occasionally it is found an inch and a half, more rarely two or even three inches, below this point.

In Direction.—Sometimes the aorta arches over the root of the right instead of the left lung, as in birds, and passes down on the right side of the spine. In such cases all the viscera of the thoracic and abdominal cavities are transposed. Less frequently, the aorta, after arching over the root of the right lung, is directed to its usual position on the left side of the spine, this peculiarity not being accompanied by any transposition of the viscera.

In Conformation.—The aorta occasionally divides, as in some quadrupeds, into an ascending and a descending trunk, the former of which is directed vertically upward, and subdivides into three branches to supply the head and upper extremities. Sometimes the aorta subdivides soon after its origin into two branches, which soon reunite. In one of these cases the œsophagus and trachea were found to pass through the interval left by their division; this is the normal condition of the vessel in the Reptilia.

Surgical Anatomy.—Of all the vessels of the arterial system, the aorta, and more especially its arch, is most frequently the seat of disease; hence it is important to consider some of the consequences that may ensue from aneurism of this part.

It will be remembered that the ascending part of the arch is contained in the pericardium, just behind the sternum, being crossed at its commencement by the pulmonary artery and right auricular appendix, and having the root of the right lung behind, the vena cava on the right side, and the pulmonary artery and left auricle on the left side.

Aneurism of the ascending aorta, in the situation of the aortic sinuses, in the great majority of cases affects the right anterior sinus; this is mainly owing to the fact that the regurgitation of blood upon the sinuses takes place chiefly on the right anterior aspect of the vessel. As the aneurismal sac enlarges it may compress any or all of the structures in immediate proximity with it, but chiefly projects toward the right anterior side, and consequently interferes mainly with those structures that have a corresponding relation with the vessel. In the majority of cases it bursts into the cavity of the pericardium, the patient suddenly drops down dead, and upon a post-mortem examination the pericardial sac is found full of blood; or it may compress the right auricle or the pulmonary artery and adjoining part of the right ventricle, and open into one or the other of these parts, or may press upon the superior cava.

Aneurism of the ascending aorta, originating above the sinuses, most frequently implicates the right anterior wall of the vessel; this is probably mainly owing to the blood being impelled against this part. The direction of the aneurism is also chiefly toward the right of the median line. If it attains a large size and projects forward, it may absorb the sternum and the cartilages of the ribs, usually on the right side, and appear as a pulsating tumor on the front of the chest, just below the manubrium; or it may burst into the pericardium, or may compress or open into the right lung, the trachea, bronchi, or œsophagus.

Regarding the transverse part of the arch, the student is reminded that the vessel lies on the trachea, the œsophagus, and thoracic duct; that the recurrent laryngeal nerve winds around it; and that from its upper part are given off three large trunks, which supply the head, neck, and upper extremities. Now, an aneurismal tumor taking origin from the posterior part or right aspect of the vessel, its most usual site, may press upon the trachea, impede the breathing, or produce cough, hæmoptysis, or stridulous breathing, or it may ultimately burst into that tube, producing fatal hemorrhage. Again, its pressure on the laryngeal nerves may give rise to symptoms which so accurately resemble those of laryngitis that the operation of tracheotomy has in some cases been resorted to, from the supposition that disease existed in the larynx; or it may press upon the thoracic duct and destroy life by inanition; or it may involve the œsophagus, producing dysphagia; or it may burst into the œsophagus, when fatal hemorrhage will occur. Again, the innominate artery or the left carotid or subclavian may be so obstructed by clots as to produce a weakness, or even a disappearance, of the pulse in one or the other wrist; or the tumor may present itself at or above the manubrium, generally either in the median line or to the right of the sternum, and may simulate an aneurism of one of the arteries of the neck.

Aneurism affecting the descending part of the arch is usually directed backward and to the left side, causing absorption of the vertebræ and corresponding ribs, or it may press upon the trachea, left bronchus, œsophagus, and the right and left lungs, generally the latter. When rupture of the sac occurs, it usually takes place into the left pleural cavity; less frequently into the left bronchus, the right pleura, or into the substance of the lungs or trachea. In this form of aneurism pain is an almost constant and characteristic symptom, referred to either the back or chest, and usually radiating from the spine around the left side. This symptom depends upon the aneurismal sac compressing the intercostal nerves against the bone.

BRANCHES OF THE ARCH OF THE AORTA (Figs. 364, 365).

The branches given off from the arch of the aorta are five in number: two of small size, from the ascending portion, the right and left coronary; and three of large size, from the transverse portion, the innominate artery, the left common carotid, and the left subclavian.

Peculiarities.—Position of the Branches.—The branches, instead of arising from the highest part of the arch (their usual position), may be moved more to the right, arising from the commencement of the transverse or upper part of the ascending portion; or the distance from one another at their origin may be increased or diminished, the most frequent change in this respect being the approximation of the left carotid toward the innominate artery.

The number of the primary branches may be reduced to two: the left carotid, arising from the innominate artery, or (more rarely) the carotid and subclavian arteries of the left side, arising from a left innominate artery. But the number may be increased to four, from the right carotid and subclavian arteries arising directly from the aorta, the innominate being absent. In most of these latter cases the right subclavian has been found to arise from the left end of the arch; in other cases it was the second or third branch given off instead of the first. Lastly, the number of trunks from the arch may be increased to five or six; in these instances the external and internal carotids arise separately from the arch, the common carotid being absent on one or both sides.

Number Usual, Arrangement Different.—When the aorta arches over to the right side, the three branches have an arrangement the reverse of what is usual, the innominate supplying the left side, and the carotid and subclavian (which arises separately) the right side. In other cases, where the aorta takes its usual course, the two carotids may be joined in a common trunk, and the subclavians arise separately from the arch, the right subclavian generally arising from the left end of the arch.

Secondary branches sometimes arise from the arch; most commonly such a secondary branch is the left vertebral, which usually takes origin between the left carotid and left subclavian, or beyond them. Sometimes a thyroid branch is derived from the arch or the right internal mammary or right vertebral, or, more rarely, both vertebral.[1]

THE CORONARY ARTERIES.

The **Coronary Arteries** supply the heart: they are two in number, right and left, arising near the commencement of the aorta immediately above the free margin of the semilunar valves.

The **Right Coronary Artery,** about the size of a crow's quill, arises from the aorta immediately above the free margin of the right semilunar valve, between the pulmonary artery and the right appendix auriculæ. It passes forward to the right side in the groove between the right auricle and ventricle, and, curving around the right border of the heart, runs along its posterior surface as far as the posterior interventricular groove, where it divides into two branches, one of which continues onward in the groove between the left auricle and ventricle and anastomoses with the left coronary; the other descends along the posterior interventricular furrow, supplying branches to both ventricles and to the septum, and anastomosing at the apex of the heart with the descending branches of the left coronary.

This vessel sends a large branch along the thin margin of the right ventricle to the apex, and numerous small branches to the right auricle and ventricle and the commencement of the pulmonary artery.

The **Left Coronary,** larger than the former, arises immediately above the free edge of the left semilunar valve, a little higher than the right; it passes forward between the pulmonary artery and the left appendix auriculæ, and descends obliquely toward the anterior interventricular groove, where it divides into two branches. Of these, one passes transversely outward in the left auriculo-ventricular groove, and winds around the left border of the heart to its posterior surface, where it anastomoses with the transverse branch of the right coronary; the other descends along the anterior interventricular groove to the apex of the heart, where it anastomoses with the descending branches of the right coronary. The left coronary supplies the left auricle and its appendix, both ventricles, and numerous small branches to the pulmonary artery and commencement of the aorta.[1]

---

[1] The anomalies of the aorta and its branches are minutely described by Krause in Henle's *Anatomy* (Brunswick, 1876), vol. iii. p. 210 *et seq.*).

Peculiarities.—These vessels occasionally arise by a common trunk, or their number may be increased to three, the additional branch being of small size. More rarely, there are two additional branches.

ARTERIA INNOMINATA.

The **Innominate Artery** (**brachio-cephalic**) is the largest branch given off from the arch of the aorta. It arises from the commencement of the transverse portion in front of the left carotid, and, ascending obliquely to the upper border of the right sterno-clavicular articulation, divides into the right common carotid and right subclavian arteries. This vessel varies from an inch and a half to two inches in length.

RELATIONS.—*In front* it is separated from the first bone of the sternum by the Sterno-hyoid and Sterno-thyroid muscles, the remains of the thymus gland, the left innominate and right inferior thyroid veins, which cross its root, and sometimes the inferior cervical cardiac branch of the right pneumogastric. *Behind* it lies upon the trachea, which it crosses obliquely. On the *right side* is the right vena innominata, right pneumogastric nerve, and the pleura; and on the *left side* the remains of the thymus gland and origin of the left carotid artery.

PLAN OF THE RELATIONS OF THE INNOMINATE ARTERY.

In Front.

Sternum.
Sterno-hyoid and Sterno-thyroid muscles.
Remains of thymus gland.
Left innominate and right inferior thyroid veins.
Inferior cervical cardiac branch from right pneumogastric nerve.

Right Side.

Right vena innominata.
Right pneumogastric nerve.
Pleura.

Innominate
Artery.

Left Side.

Remains of thymus.
Left carotid.

Behind.

Trachea.

Branches.—The innominate usually gives off no branches, but occasionally a small branch, the *thyroidea ima*, is given off from this vessel. It ascends in front of the trachea to the lower part of the thyroid body, which it supplies. It varies greatly in size, and appears to compensate for deficiency or absence of one of the other thyroid vessels. It occasionally is found to arise from the subclavian or internal mammary vessel. The innominate artery also sometimes gives off a *thymic* or *bronchial* branch.

Peculiarities in Point of Division.—When the bifurcation of the innominate artery varies from the point above mentioned, it sometimes ascends a considerable distance above the sternal end of the clavicle; less frequently it divides below it. In the former class of cases its length may exceed two inches, and in the latter be reduced to an inch or less. These are points of considerable interest for the surgeon to remember in connection with the operation of tying this vessel.

Position.—When the aorta arches over to the right side the innominate is directed to the left side of the neck instead of the right.

Collateral Circulation.—Allan Burns demonstrated on the dead subject the possibility of the establishment of the collateral circulation after ligature of the innominate artery, by tying and dividing that artery, after which, he says, "even coarse injection impelled into the aorta passed freely by the anastomosing branches into the arteries of the right arm, filling them and all the vessels of the head completely" (*Surgical Anatomy of the Head and Neck*, p. 62). The branches by which this circulation would be carried on are very numerous; thus, all the communications across the middle line between the branches of the carotid arteries of opposite sides would be available for the supply of blood to the right side of the head and neck, while the anastomosis between the superior intercostal of the subclavian and the first aortic intercostal (see *infra* on the collateral circulation after obliteration of the thoracic aorta) would bring the blood, by a free and direct course, into the right subclavian: the numerous connections also between the lower intercostal arteries and the branches of the axillary and internal mammary arteries would doubtless assist in the supply of blood to the right arm, while the epigastric, from the external iliac, would, by means of its anastomosis with the internal mammary, compensate for any deficiency in the vascularity of the wall of the chest.

---

[1] According to Dr. Samuel West, there is a very free and complete anastomosis between the two coronary arteries (*Lancet*, June 2, 1883, p. 945).

Surgical Anatomy.—Although the operation of tying the innominate artery has been performed by several surgeons for aneurism of the right subclavian extending inward as far as the Scalenus, in only one instance has it been attended with success.[1] Mott's patient, however, on whom the operation was first performed, lived nearly four weeks, and Graefe's more than two months. The main obstacles to the operation are, as the student will perceive from his dissection of this vessel, the deep situation of the artery behind and beneath the sternum, and the number of important structures which surround it in every part.

In order to apply a ligature to this vessel the patient is to be placed upon his back, with the shoulders raised and the head bent a little backward, so as to draw out the artery from behind the sternum into the neck. An incision two inches long is then made along the anterior border of the Sterno-mastoid muscle, terminating at the sternal end of the clavicle. From this point a second incision is carried about the same length along the upper border of the clavicle. The skin is then dissected back and the Platysma divided on a director: the sternal end of the Sterno-mastoid is now brought into view, and a director being passed beneath it and close to its under surface, so as to avoid any small vessels, the muscle is to be divided transversely throughout the greater part of its attachment. By pressing aside any loose cellular tissue or vessels that may now appear the Sterno-hyoid and Sterno-thyroid muscles will be exposed, and must be divided, a director being previously passed beneath them. The inferior thyroid veins may come into view, and must be carefully drawn either upward or downward by means of a blunt hook. On no account should these vessels be divided, as it would add much to the difficulty of the operation and endanger its ultimate success. After tearing through a strong fibro-cellular lamina the right carotid is brought into view, and, being traced downward, the arteria innominata is arrived at. The left vena innominata should now be depressed; the right vena innominata, the internal jugular vein, the pneumogastric nerve drawn to the right side; and a curved aneurism-needle may then be passed around the vessel close to its surface and in a direction from below upward and inward, care being taken to avoid the right pleural sac, the trachea, and cardiac nerves. The ligature should be applied to the artery as high as possible, in order to allow room between it and the aorta for the formation of the coagulum. The importance of avoiding the thyroid plexus of veins during the primary steps of the operation, and the pleural sac whilst including the vessel in the ligature, should be most carefully borne in mind, since secondary hemorrhage or pleurisy has been the cause of death in all the fatal cases hitherto recorded.

COMMON CAROTID ARTERIES.

The **Common Carotid Arteries**, although occupying a nearly similar position in the neck, differ in position, and consequently in their relations at their origin. The right carotid arises from the arteria innominata behind the right sterno-clavicular articulation; the left, from the highest part of the arch of the aorta. The left carotid is consequently longer and placed more deeply in the thorax. It will therefore be more convenient to describe first the course and relations of that portion of the left carotid which intervenes between the arch of the aorta and the left sterno-clavicular articulation. (See Fig. 364.)

The left carotid within the thorax ascends obliquely outward from the arch of the aorta to the root of the neck. *In front* it is separated from the first piece of the sternum by the Sterno-hyoid and Sterno-thyroid muscles, the left innominate vein, and the remains of the thymus gland; *behind* it lies on the trachea, œsophagus, and thoracic duct. *Internally* it is in relation with the arteria innominata; *externally*, with the left pneumogastric nerve and left subclavian artery.

---

[1] The operation was performed by Dr. Smyth of New Orleans. (See the New Sydenham Society's *Biennial Retrospect* for 1865-66, p. 346.)

PLAN OF THE RELATIONS OF THE LEFT COMMON CAROTID, THORACIC PORTION.

In Front.

Sternum.
Sterno-hyoid and Sterno-thyroid muscles.
Left innominate vein.
Remains of thymus gland.

Internally.
Arteria innominata.

Left Common
Carotid.
Thoracic
Portion.

Externally.
Left pneumogastric nerve.
Left subclavian artery.

Behind.

Trachea.
Œsophagus.
Thoracic duct.

In the neck the two common carotids resemble each other so closely that one description will apply to both. Each vessel passes obliquely upward from behind the sterno-clavicular articulation to a level with the upper border of the thyroid cartilage, where it divides into the external and internal carotid, these names being derived from the distribution of the arteries to the external parts of the head and face and to the internal parts of the cranium respectively. The course of the common carotid is indicated by a line drawn from the sternal end of the clavicle below to a point midway between the angle of the jaw and the mastoid process above. [As it lies just under the anterior border of the Sterno-cleido-mastoid, this muscle forms an excellent guide to its position.]

At the lower part of the neck the two common carotid arteries are separated from each other by a very small interval, which contains the trachea; but at the upper part, the thyroid body, the larynx, and pharynx project forward between the two vessels, and give the appearance of their being placed farther back in that situation. The common carotid artery is contained in a sheath derived from the deep cervical fascia, which also encloses the internal jugular vein and pneumogastric nerve, the vein lying on the outer side of the artery and the nerve between the artery and vein, on a plane posterior to both. On opening the sheath these three structures are seen to be separated from one another, each being enclosed in a separate fibrous investment.

RELATIONS.—At the lower part of the neck the common carotid artery is very deeply seated, being covered by the superficial fascia, Platysma, and deep fascia, the Sterno-mastoid, Sterno-hyoid, and Sterno-thyroid muscles, and by the Omo-hyoid opposite the cricoid cartilage; but in the upper part of its course, near its termination, it is more superficial, being covered merely by the integument, the superficial fascia, Platysma, deep fascia, and inner margin of the Sterno-mastoid, and is contained in a triangular space bounded behind by the Sterno-mastoid, above by the posterior belly of the Digastric, and below by the anterior belly of the Omo-hyoid. This part of the artery is crossed obliquely from within outward by the sterno-mastoid artery; it is crossed also by one, or sometimes two superior thyroid veins, which terminate in the internal jugular, and descending on its sheath in front is seen the descendens noni nerve, this filament being joined by one or two branches from the cervical nerves, which cross the vessel from without inward. Sometimes the descendens noni is contained within the sheath. The middle thyroid vein crosses the artery about its middle, and the anterior jugular vein below. ***Behind,*** the artery lies in front of the cervical portion of the spine, resting first on the Longus colli muscle, then on the Rectus capitis anticus major, from which it is separated by the sympathetic nerve. The recurrent laryngeal nerve and inferior thyroid artery cross behind the vessel at its lower part. *Internally,* it is in relation with the trachea and thyroid gland, the inferior thyroid artery and recurrent laryngeal nerve being interposed; higher up, with the larynx and pharynx. On its *outer side* are placed the internal jugular vein and pneumogastric nerve.

At the lower part of the neck the internal jugular vein on the right side diverges from the artery, but on the left side it approaches it, and often crosses its lower part. This is an important fact to bear in mind during the performance of any operation on the lower part of the left common carotid artery.

PLAN OF THE RELATIONS OF THE COMMON CAROTID ARTERY [CERVICAL PORTION].

In Front.

Integument and fascia.
Platysma.
Sterno-mastoid.
Sterno-hyoid.
Sterno-thyroid.

Omo-hyoid.
Descendens and Communicans noni nerves.
Sterno-mastoid artery.
Superior and middle thyroid veins.
Anterior jugular vein.

Externally.

Internal jugular vein.
Pneumogastric nerve.

Common
Carotid.

Internally.

Trachea.
Thyroid gland.
Recurrent laryngeal nerve.
Inferior thyroid artery.
Larynx.
Pharynx.

Behind.

Longus colli.
Rectus capitis anticus major.
Sympathetic nerve.
Inferior thyroid artery.
Recurrent laryngeal nerve.

Peculiarities as to Origin.—The *right common carotid* may arise above or below its usual point, the upper border of the sterno-clavicular articulation. This variation occurs in one out of about eight cases and a half, and the origin is more frequently above than below the usual point; or the artery may arise as a separate branch from the arch of the aorta or in conjunction with the left carotid. The *left common carotid* varies more frequently in its origin than the right. In the majority of abnormal cases it arises with the innominate artery, or if the innominate artery is absent the two carotids arise usually by a single trunk. The left carotid has a tendency toward the right side of the arch of the aorta, being occasionally the first branch given off from the transverse portion. It rarely joins with the left subclavian, except in cases of transposition of the arch.

Peculiarities as to Point of Division.—The most important peculiarities of this vessel in a surgical point of view relate to its place of division in the neck. In the majority of abnormal cases this occurs higher than usual, the artery dividing into two branches opposite the hyoid bone, or even higher; more rarely, it occurs below its usual place, opposite the middle of the larynx or the lower border of the cricoid cartilage; and one case is related by Morgagni where the common carotid, only an inch and a half in length, divided at the root of the neck. Very rarely the common carotid ascends in the neck without any subdivision, the internal carotid being wanting; and in two cases the common carotid has been found to be absent, the external and internal carotids arising directly from the arch of the aorta. This peculiarity existed on both sides in one subject, on one side in the other.

Occasional Branches.—The common carotid usually gives off no branch previous to its bifurcation; but it occasionally gives origin to the superior thyroid, or a laryngeal branch, the inferior thyroid, or, more rarely, the vertebral artery.

Surgical Anatomy. [See the Triangles of the Neck, p. 525.]—The operation of tying the common carotid artery may be necessary in a case of wound of that vessel or its branches, in aneurism, or in a case of pulsating tumor of the orbit or skull. If the wound involves the trunk of the common carotid, it will be necessary to tie the artery above and below the wounded part. But in cases of aneurism, or where one of the branches of the common carotid is wounded in an inaccessible situation, it may be judged necessary to tie the trunk. In such cases the whole of the artery is accessible, and any part may be tied, except close to either end. When the case is such as to allow of a choice being made, the lower part of the carotid should never be selected as the spot upon which to place a ligature, for not only is the artery in this situation placed very deeply in the neck, but it is covered by three layers of muscles, and on the left side the jugular vein, in the great majority of cases, passes obliquely in front of it. Neither should the upper end be selected, for here the superior thyroid vein and its tributaries would give rise to very considerable difficulty in the application of a ligature. The point most favorable for the operation is that part of the vessel which bisects the angle formed by the anterior edge of the Sterno-mastoid with the Omo-hyoid muscle, at the level of the cricoid cartilage. It occasionally happens that the carotid artery bifurcates below its usual position: if the artery be exposed at its point of bifurcation, both divisions of the vessel should be tied near their origin, in preference to tying the trunk of the artery near its termination; and if, in consequence of the entire absence of the common carotid or from its early division, two arteries, the external and internal carotids, are met with, the ligature should be placed on that vessel which is found on compression to be connected with the disease.

In this operation the direction of the vessel and the inner margin of the Sterno-mastoid are the chief guides to its performance. The patient should be placed on his back with the head thrown back: an incision is to be made, three inches long, along the anterior border of the Sterno-mastoid, so that the centre corresponds to the level of the cricoid cartilage: after dividing the integument, superficial fascia, and Platysma, the deep fascia must be cut through on a director, so as to avoid wounding numerous small veins that are usually found beneath. The head may now be brought forward so as to relax the parts somewhat, and the margins of the wound held asunder by retractors. The descendens noni nerve is now exposed, and must be avoided, and the sheath of the vessel, having been raised by forceps, is to be opened to a small extent over the artery at its inner side. The internal jugular vein may present itself alternately distended and relaxed; this should be compressed both above and below, and drawn outward, in order to facilitate the operation. The aneurism-needle is passed from the outside, care being taken to keep the needle in close contact with the artery, and thus avoid the risk of injuring the jugular vein or including the vagus nerve. Before the ligature is tied it should be ascertained that nothing but the artery is included in it.

Ligature of the Common Carotid at the Lower Part of the Neck.—This operation is sometimes required in cases of aneurism of the upper part of the carotid, especially if the sac is of large size. It is best performed by dividing the sternal origin of the Sterno-mastoid muscle, but may be done in some cases, if the aneurism is not of very large size, by an incision along the anterior border of the Sterno-mastoid, extending down to the sterno-clavicular articulation, and by then retracting the muscle. The easiest and best plan, however, is to make an incision two or three inches long down the lower part of the anterior border of the Sterno-mastoid muscle to the sterno-clavicular joint, and a second incision, starting from the termination of the first, along the upper border of the clavicle for about two inches. This incision is made through the superficial and deep fascia, and the sternal origin of the muscle exposed. This is to be divided on a director and turned up with the superficial structures as a triangular flap. Some loose connective tissue is now to be divided or torn through, and the outer border of the Sterno-hyoid muscle exposed. In doing this care must be taken not to wound the anterior jugular vein, which crosses the muscle to reach the external jugular or subclavian vein. The Sterno-hyoid, and with it the Sterno thyroid, are now to be drawn inward by means of a retractor, and the sheath of the vessel is exposed. This must be opened with great care on its inner or tracheal side, so as to avoid the internal jugular vein. This is especially necessary on the left side, where the artery is commonly overlapped by the vein. On the right side there is usually an interval between the artery and the vein, and not the same risk of wounding the latter.

Collateral Circulation.—After ligature of the common carotid the collateral circulation can be perfectly established by the free communication which exists between the carotid arteries of opposite sides, both without and within the cranium, and by enlargement of the branches of the subclavian artery on the side corresponding to that on which the vessel has been tied, the chief communication outside the skull taking place between the superior and inferior thyroid arteries and the profunda cervicis and arteria princeps cervicis of the occipital, the vertebral taking the place of the internal carotid within the cranium.

Sir A. Cooper had an opportunity of dissecting, thirteen years after the operation, the case in which he first successfully tied the common carotid—the second case in which he performed the operation (*Guy's Hospital Reports*, i. 56). The injection, however, does not seem to have been a successful one. It showed merely that the arteries at the base of the brain (circle of Willis) were much enlarged on the side of the tied artery, and that the anastomosis between the branches of the external carotid on the affected side and those of the same artery on the sound side was free, so that the external carotid was pervious throughout.

EXTERNAL CAROTID ARTERY.

The **External Carotid Artery** (Fig. 366) commences opposite the upper border of the thyroid cartilage, and, taking a slightly curved course, ascends upward and forward, and then inclines backward, to the space between the neck of the condyle of the lower jaw and the external meatus, where it divides into the temporal and internal maxillary arteries. It rapidly diminishes in size in its course up the neck, owing to the number and large size of the branches given off from it. In the child it is somewhat smaller than the internal carotid, but in the adult the two vessels are of nearly equal size. At its commencement this artery is more superficial and placed nearer the middle line than the internal carotid, and is contained in the triangular space bounded by the Sterno-mastoid behind, the Omo-hyoid below, and the posterior belly of the Digastric and Stylo-hyoid above; it is covered by the skin, Platysma, deep fascia, and anterior margin of the Sterno-mastoid, crossed by the hypoglossal nerve and by the lingual and facial veins; it is afterward crossed by the Digastric and Stylo-hyoid muscles, and higher up passes deeply into the substance of the parotid gland, where it lies beneath the facial nerve and the junction of the temporal and internal maxillary veins.

Internally is the hyoid bone, the wall of the pharynx, the superior laryngeal nerve, and the ramus of the jaw, from which it is separated by a portion of the parotid gland. *Behind* it, near its origin, is the superior laryngeal nerve, and higher up it is separated from the internal carotid by the Stylo-glossus and Stylo-pharyngeus muscles, the glosso-pharyngeal nerve, and part of the parotid gland.

Fig. 366.

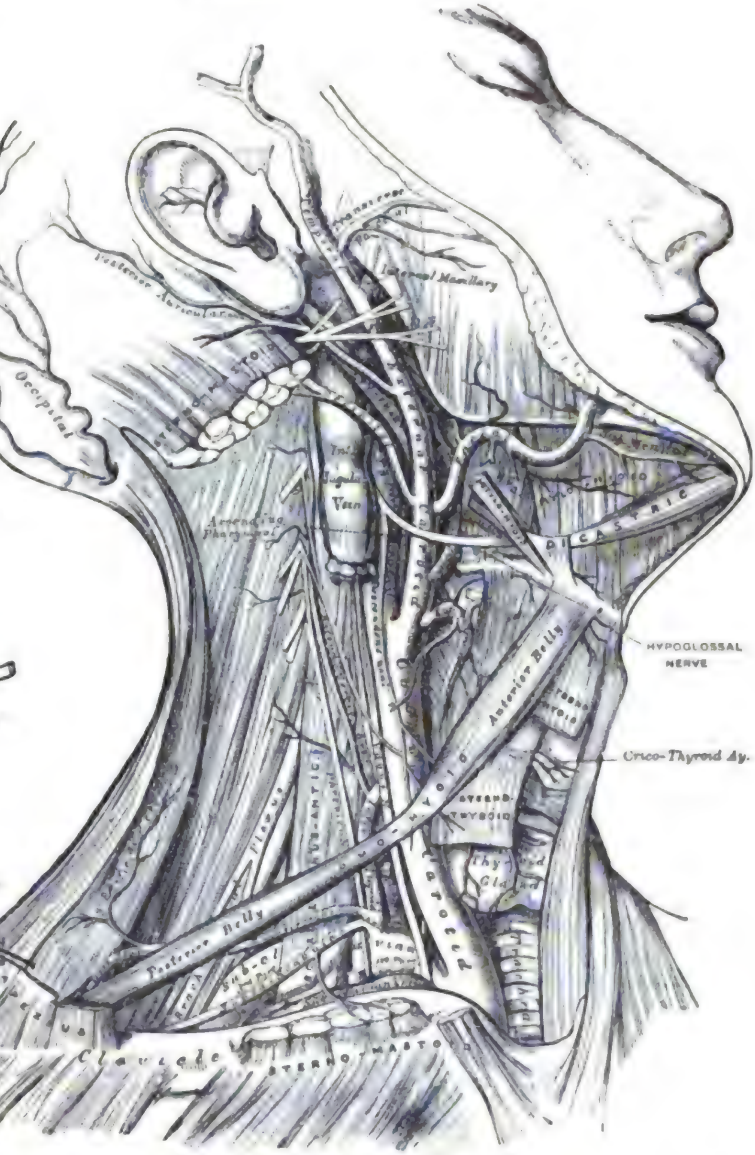
Posterior Auricular
Internal Maxillary
Occipital
Internal Jugular Vein
Ascending Pharyngeal
Digastric
HYPOGLOSSAL NERVE
Anterior Belly
Crico-Thyroid Ay.
Sterno-Thyroid
Omo-hyoid
Carotid
Posterior Belly
Clavicle

Surgical Anatomy of the Arteries of the Neck, right side. [The hypoglossal nerve is not rightly placed in this drawing. It forms the upper side of a triangle the two lower sides of which are the two bellies of the Digastric. The lingual artery would then run under the Hyo-glossus muscle, *below* the hypoglossal nerve.]

Fig. 367.

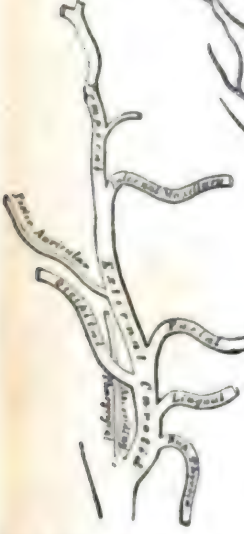
Temporal
Internal Maxillary
Poster. Auricular
Occipital
External Carotid
Facial
Lingual
Ascending Pharyngeal
Sup. Thyroid

Plan of the Branches of the External Carotid.

PLAN OF THE RELATIONS OF THE EXTERNAL CAROTID.

In Front.

Integument, superficial fascia.
Platysma and deep fascia.
Hypoglossal nerve.
Lingual and facial veins.
Digastric and Stylo-hyoid muscles.
Parotid gland, with facial nerve and temporo-maxillary vein in its substance.

External Carotid.

Behind.

Superior laryngeal nerve.
Stylo-glossus.
Stylo-pharyngeus.
Glosso-pharyngeal nerve.
Parotid gland.

Internally.

Hyoid bone.
Pharynx.
Superior laryngeal nerve.
Parotid gland.
Ramus of jaw.

Surgical Anatomy.—The application of a ligature to the external carotid may be required in cases of wounds of this vessel or of its branches (when these cannot be tied) and in some cases of pulsating tumor of the scalp or face; the operation, however, is very rarely performed, ligature of the common carotid being preferable on account of the number of branches given off from the external. To tie this vessel near its origin, below the point where it is crossed by the Digastric, an incision about three inches in length should be made along the margin of the Sterno-mastoid from the angle of the jaw to the cricoid cartilage. To tie the vessel above the Digastric, between it and the parotid gland, an incision should be made from the lobe of the ear to the great cornu of the os hyoides, dividing successively the skin, Platysma, and fascia. By separating the posterior belly of the Digastric and Stylo-hyoid muscles, which are seen at the lower part of the wound, from the parotid gland, the vessel will be exposed and a ligature may be applied to it. The circulation is at once re-established by the free communication between most of the large branches of the artery (facial, lingual, superior thyroid, occipital) and the corresponding arteries of the opposite side, and by the free anastomosis of the facial with branches from the internal carotid, of the occipital with branches of the subclavian, etc.

Branches.—The external carotid artery gives off eight branches, which, for convenience of description, may be divided into four sets. (See Fig. 367, Plan of the Branches.)

Anterior.	*Posterior.*	*Ascending.*	*Terminal.*
Superior Thyroid.	Occipital.	Ascending Pharyngeal.	Temporal.
Lingual.	Posterior Auricular.		Internal Maxillary.
Facial.			

The student is here reminded that many variations are met with in the number, origin, and course of these branches in different subjects, but the above arrangement is that which found in the great majority of cases.

The **Superior Thyroid Artery** (Fig. 366, and Fig. 372, p. 529) is the first branch given off from the external carotid, being derived from that vessel just below the great cornu of the hyoid bone. At its commencement it is quite superficial, being covered by the integument, fascia, and Platysma, and is contained in the triangular space bounded by the Sterno-mastoid, Digastric, and Omo-hyoid muscles. After running upward and inward for a short distance, it curves downward and forward in an arched and tortuous manner to the upper part of the thyroid gland, passing beneath the Omo-hyoid, Sterno-hyoid, and Sterno-thyroid muscles, and distributes numerous branches to the anterior surface of the gland, anastomosing with its fellow of the opposite side and with the inferior thyroid arteries. Besides the arteries distributed to the muscles by which it is covered and the substance of the gland, the branches of the superior thyroid are the following:

Hyoid.
Superficial Descending Branch (Sterno-mastoid).
Superior Laryngeal.
Crico-thyroid.

The **hyoid** is a small branch which runs along the lower border of the os hyoides beneath the Thyro-hyoid muscle; after supplying the muscles connected to that bone it forms an arch by anastomosing with the vessels of the opposite side.

The **superficial descending branch** runs downward and outward across the sheath of the common carotid artery, and supplies the Sterno-mastoid and neighboring muscles and integument. It is of importance that the situation of this vessel be remembered in the operation for tying the common carotid artery. There is often a distinct branch from the external carotid distributed to the Sterno-mastoid muscle.

The **superior laryngeal,** larger than either of the preceding, accompanies the superior laryngeal nerve beneath the Thyro-hyoid muscle; it pierces the thyro-hyoid membrane, and supplies the muscles, mucous membrane, and glands of the larynx and epiglottis, anastomosing with the branch from the opposite side.

The **crico-thyroid** is a small branch which runs transversely across the crico-thyroid membrane, communicating with the artery of the opposite side. The position of this vessel should be remembered, as it may prove the source of troublesome hemorrhage during the operation of laryngotomy.

Surgical Anatomy.—The superior thyroid or some of its branches are often divided in cases of cut throat, giving rise to considerable hemorrhage. In such cases the artery should be secured, the wound being enlarged for that purpose if necessary. The operation may be easily performed, the position of the artery being very superficial and the only structures of importance covering it being a few small veins. The operation of tying the superior thyroid artery in bronchocele has been performed in numerous instances with partial or temporary success. When, however, the collateral circulation between this vessel and the artery of the opposite side and the inferior thyroid is completely re-established, the tumor usually regains its former size.

The **Lingual Artery** (Fig. 372 p. 529) arises from the external carotid between the superior thyroid and facial; it runs obliquely upward and inward to the great cornu of the hyoid bone, then passes horizontally forward parallel with the great cornu, and, ascending perpendicularly to the under surface of the tongue, turns forward on its under surface as far as the tip of that organ, under the name of the *ranine* artery.

Relations.—Its first or oblique portion is superficial, being contained in the triangular space already described, resting upon the middle constrictor of the pharynx, and covered by the Platysma and fascia of the neck. Its second or horizontal portion also lies upon the Middle constrictor, being covered at first by the tendon of the Digastric and the Stylo-hyoid muscle, and afterward by the Hyo-glossus, the latter muscle separating it from the hypoglossal nerve. [This portion lies in a triangle, the two lower sides of which are the two bellies of the Digastric, and the upper side is the hypoglossal nerve (Fig. 366 is incorrect in this portion). The artery lies below the hypoglossal nerve, above the Digastric, and beneath the Hyo-glossus.] Its third or ascending portion lies between the Hyo-glossus and Genio-hyo-glossus muscles. The fourth or terminal part under the name of the *ranine* runs along the under surface of the tongue to its tip: it is very superficial, being covered only by the mucous membrane, and rests on the Lingualis on the outer side of the Genio-hyo-glossus. The hypoglossal nerve crosses the lingual artery, and then becomes separated from it, in the second part of its course, by the Hyo-glossus muscle.

The branches of the lingual artery are the

Hyoid.	Sublingual.
Dorsalis linguæ.	Ranine.

The **hyoid branch** runs along the upper border of the hyoid bone, supplying the muscles attached to it and anastomosing with its fellow of the opposite side.

The **dorsalis linguæ** (Fig. 372) arises from the lingual artery beneath the Hyo-glossus muscle (which in the figure has been partly cut away to show the vessel); ascending to the dorsum of the tongue, it supplies the mucous membrane, the tonsil, soft palate, the epiglottis, anastomosing with its fellow from the opposite side.

The **sublingual,** which may be described as a branch of bifurcation of the lingual artery, arises at the anterior margin of the Hyo-glossus muscle, and, running forward and outward on the Genio-hyo-glossus to the sublingual gland, supplies its substance, giving branches to the Mylo-hyoid and neighboring muscles, the mucous membrane of the mouth and gums. One branch continues behind the alveolar process of the lower jaw in the substance of the gum to anastomose with a similar artery from the other side.

The **ranine** may be regarded as the other branch of bifurcation, or, as is more usual, as the continuation of the lingual artery; it runs along the under surface of the tongue, resting on the Lingualis and covered by the mucous membrane of the mouth; it lies on the outer side of the Genio-hyo-glossus, accompanied by the gustatory nerve. On arriving at the tip of the tongue it has been said to anastomose with the artery of the opposite side, but this is denied by Hyrtl. These vessels in the mouth are placed one on each side of the frænum.

Surgical Anatomy.—The lingual artery may be divided near its origin in cases of cut throat, a complication that not unfrequently happens in this class of wounds, or severe hemorrhage, which cannot be restrained by ordinary means, may ensue from a wound or deep ulcer of the tongue. In the former case the primary wound may be enlarged if necessary, and the bleeding vessel secured. In the latter case it has been suggested that the lingual artery should be tied near its origin. Ligature of the lingual artery is also occasionally practised as a palliative measure in cases of cancer of the tongue, in order to check the progress of the disease by starving the growth. The operation is a difficult one, on account of the depth of the artery, the number of important parts by which it is surrounded, the loose and yielding nature of the parts upon which it is supported, and its occasional irregularity of origin. An incision is to be made in a curved direction from a finger's breadth external to the symphysis of the jaw downward to the cornu of the hyoid bone, and then upward to near the angle of the jaw. Care must be taken not to carry this incision too far backward, for fear of endangering the facial vein. In the first incision the skin, superficial fascia, and Platysma will be divided and the deep fascia exposed. This is then to be incised and the submaxillary gland exposed and pulled upward by retractors. A triangular space is now exposed, bounded internally by the posterior border of the Mylo-hyoid muscle, below and externally by the tendon of the Digastric, and above by the hypoglossal nerve. The floor of the space is formed by the Hyo-glossus muscle, beneath which the artery lies. The fibres of this muscle are now to be cut through horizontally and the vessel exposed, care being taken while near the vessel not to open the pharynx. [There need be no trouble in finding and ligating this artery. After the submaxillary gland is raised up, find the hyoid bone and the triangle formed by the Digastric tendons and the hypoglossal nerve, and if the Hyo-glossus muscle be then divided in this triangle between the bone and the nerve, the artery will readily be found under it.]

Troublesome hemorrhage may occur in the division of the frænum in children if the ranine artery, which lies on each side of it, is wounded. The student should remember that the operation is always to be performed with a pair of blunt-pointed scissors, and the mucous membrane only is to be divided by a very superficial cut, which cannot endanger any vessel. The scissors also should be directed away from the tongue. Any further liberation of the tongue which may be necessary can be effected by tearing.

The **Facial Artery** (Fig. 368) arises a little above the lingual, and ascends obliquely forward and upward, beneath the body of the lower jaw, to the submaxillary gland, in which it lies imbedded in a groove on its posterior and upper border; this may be called the cervical part of the artery. It then curves upward over the body of the jaw at the anterior inferior angle of the Masseter muscle, ascends forward and upward across the cheek to the angle of the mouth, passes up along the side of the nose, and terminates at the inner canthus of the eye, under the name of the *angular* artery. This vessel, both in the neck and on the face, is remarkably tortuous—in the former situation, to accommodate itself to the movements of the pharynx in deglutition; and in the latter, to the movements of the jaw and the lips and cheeks.

RELATIONS.—*In the neck* its origin is superficial, being covered by the integument, Platysma, and fascia; it then passes beneath the Digastric and Stylo-hyoid muscles and the submaxillary gland. *On the face*, where it passes over the body of the lower jaw, it is comparatively superficial, lying immediately beneath the Platysma. In this situation its pulsation may be distinctly felt, and compression of the vessel effectually made against the bone. In its course over the face it is covered by the integument, the fat of the cheek, and, near the angle of the mouth, by the Platysma, Risorius, and Zygomatic muscles. It rests on the Buccinator, the Levator anguli oris, and the Levator labii superioris (sometimes piercing or else passing under this last muscle). It is accompanied by the facial vein throughout its entire course; the vein is not tortuous like the artery, and on the face is separated from that vessel by a considerable interval, lying to its outer side. The branches of the facial nerve cross the artery, and the infraorbital nerve lies beneath it.

FIG. 368.

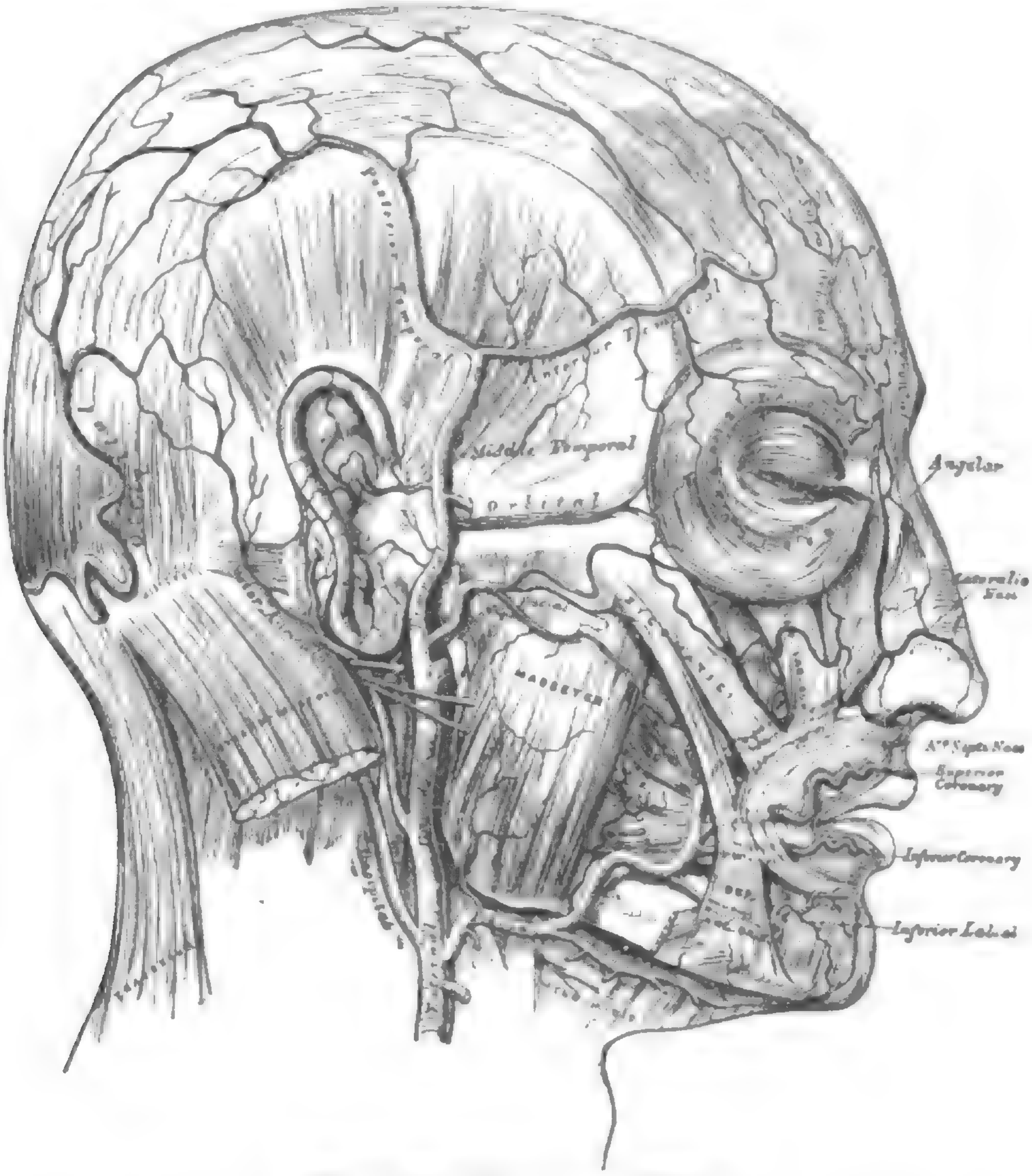
Posterior Temporal
Anterior Temporal
Middle Temporal
Orbital
Masseter
Angular
Lateralis Nasi
Art. Septi Nasi
Superior Coronary
Inferior Coronary
Inferior Labial

The Arteries of the Face and Scalp.[1]

The branches of this vessel may be divided into two sets—those given off below the jaw (cervical), and those on the face (facial):

Cervical Branches.	*Facial Branches.*
Inferior or Ascending Palatine.	Muscular.
Tonsillar.	Inferior Labial.
Submaxillary.	Inferior Coronary.
Submental.	Superior Coronary.
Muscular.	Lateralis nasi.
	Angular.

The **inferior or ascending palatine** (Fig. 372, p. 529) passes up between the Stylo-glossus and Stylo-pharyngeus to the outer side of the pharynx. After supplying these muscles, the tonsil, and Eustachian tube, it divides, near the Levator palati, into two branches: one follows the course of the Levator palati, and, winding over the upper border of the Superior constrictor, supplies the soft palate and the palatine glands; the other pierces the Superior constrictor and supplies the tonsil, anastomosing with the tonsillar artery. These vessels inosculate with the posterior palatine branch of the internal maxillary artery.

---

[1] The muscular tissue of the lips must be supposed to have been cut away in order to show the course of the coronary arteries.

The **tonsillar** branch (Fig. 374, p. 533) passes between the Internal pterygoid and Stylo-glossus, and ascends along the side of the pharynx, perforating the Superior constrictor, to ramify in the substance of the tonsil and root of the tongue.

The **submaxillary** consist of three or four large branches, which supply the submaxillary gland, some being prolonged to the neighboring muscles, lymphatic glands, and integument.

The **submental,** the largest of the cervical branches, is given off from the facial artery just as that vessel quits the submaxillary gland; it runs forward upon the Mylo-hyoid muscle just below the body of the jaw and beneath the Digastric; after supplying the muscles attached to the jaw, and anastomosing with the sublingual artery by branches which perforate the Mylo-hyoid muscle, it arrives at the symphysis of the chin, where it turns over the border of the jaw and divides into a superficial and deep branch; the former passes between the integument and Depressor labii inferioris, supplies both, and anastomoses with the inferior labial. The deep branch passes between the latter muscle and the bone, supplies the lip, and anastomoses with the inferior labial and mental arteries.

The **muscular** branches are distributed to the Internal pterygoid and Stylohyoid in the neck, and to the Masseter and Buccinator on the face.

The **inferior labial** passes beneath the Depressor anguli oris to supply the muscles and integument of the lower lip, anastomosing with the inferior coronary and submental branches of the facial and with the mental branch of the inferior dental artery.

The **inferior coronary** is derived from the facial artery near the angle of the mouth; it passes upward and inward beneath the Depressor anguli oris, and, penetrating the Orbicularis muscle, runs in a tortuous course along the edge of the lower lip between this muscle and the mucous membrane, inosculating with the artery of the opposite side. This artery supplies the labial glands, the mucous membrane, and muscles of the lower lip, and anastomoses with the inferior labial and mental branch of the inferior dental artery.

The **superior coronary** is larger and more tortuous in its course than the preceding. It follows the same course along the edge of the upper lip, lying between the mucous membrane and the Orbicularis, and anastomoses with the artery of the opposite side. It supplies the textures of the upper lip, and gives off in its course two or three vessels which ascend to the nose. One, named the *artery of the septum*, ramifies on the septum of the nares as far as the point of the nose; another supplies the ala of the nose.

The **lateralis nasi** is derived from the facial as that vessel is ascending along the side of the nose; it supplies the ala and dorsum of the nose, anastomosing with its fellow, the nasal branch of the ophthalmic, the artery of the septum, and the infraorbital.

The **angular artery** is the termination of the trunk of the facial; it ascends to the inner angle of the orbit, imbedded in the fibres of the Levator labii superioris alæque nasi, and accompanied by a large vein, the *angular;* it distributes some branches on the cheek which anastomose with the infraorbital, and, after supplying the lachrymal sac and Orbicularis muscle, terminates by anastomosing with the nasal branch of the ophthalmic artery.

The anastomoses of the facial artery are very numerous, not only with the vessel of the opposite side, but with other vessels from different sources—viz. with the sublingual branch of the lingual, with the mental branch of the inferior dental as it emerges from the mental foramen, with the ascending pharyngeal and posterior palatine, and with the ophthalmic, a branch of the internal carotid; it also inosculates with the transverse facial and with the infraorbital.

Peculiarities.—The facial artery not unfrequently arises by a common trunk with the lingual. This vessel also is subject to some variations in its size and in the extent to which it supplies the face. It occasionally terminates as the submental, and not unfrequently supplies the face only as high as the angle of the mouth or nose. The deficiency is then supplied by enlargement of one of the neighboring arteries.

Surgical Anatomy.—The passage of the facial artery over the body of the jaw would appear to afford a favorable position for the application of pressure in cases of hemorrhage from the lips, the result either of an accidental wound or from an operation; but its application is useless, except for a very short time, on account of the free communication of this vessel with its fellow and with numerous branches from different sources. In a wound involving the lip it is better to seize the part between the fingers and evert it, when the bleeding vessel may be at once secured with artery-forceps. In order to prevent hemorrhage in cases of excision or in the removal of diseased growths from the part, the lip should be compressed on each side between the finger and thumb whilst the surgeon excises the diseased part. In order to stop hemorrhage where the lip has been divided in an operation, it is necessary, in uniting the edges of the wound, to pass the sutures through the cut edges almost as deep as its mucous surface [since the coronary arteries run next the mucous membrane, where the moistened finger can feel them]: by these means not only are the cut surfaces more neatly and securely adapted to each other, but the possibility of hemorrhage is prevented by including in the suture the divided artery. If the suture is, on the contrary, passed through merely the cutaneous portion of the wound, hemorrhage occurs into the cavity of the mouth. The student should, lastly, observe the relation of the angular artery to the lachrymal sac, and it will be seen that as the vessel passes up along the inner margin of the orbit it ascends on its nasal side. In operating for fistula lachrymalis the sac should always be opened on its outer side, in order that this vessel may be avoided.

The **Occipital Artery** (Fig. 368) arises from the posterior part of the external carotid opposite the facial, near the lower margin of the Digastric muscle. At its origin it is covered by the posterior belly of the Digastric and Stylo-hyoid muscles and part of the parotid gland, the hypoglossal nerve winding around it from behind forward; higher up it passes across the internal carotid artery, the internal jugular vein, and the pneumogastric and spinal accessory nerves; it then ascends to the interval between the transverse process of the atlas and the mastoid process of the temporal bone, and passes horizontally backward, grooving the surface of the latter bone, being covered by the Sterno-mastoid, Splenius, Trachelo-mastoid, and Digastric muscles, and resting upon the Superior oblique and Complexus muscles; it then changes its course and passes vertically upward, pierces the cranial attachment of the Trapezius, and ascends in a tortuous course over the occiput as high as the vertex, where it divides into numerous branches. It is accompanied in the latter part of its course by the great occipital and a cutaneous filament from the suboccipital nerve.

The branches given off from this vessel are the

Muscular.
Sterno-mastoid.
Auricular.
Meningeal.
Arteria princeps cervicis.

The **muscular branches** supply the Digastric, Stylo-hyoid, Splenius, and Trachelo-mastoid muscles.

The **sterno-mastoid** is a large and constant branch, generally arising from the artery close to its commencement. It first ascends upward and backward, and then turns downward over the hypoglossal nerve, and enters the substance of the muscle, frequently in company with the spinal accessory nerve.

The **auricular branch** supplies the back part of the concha. It frequently gives off a branch which enters the skull through the mastoid foramen and supplies the dura mater.

The **meningeal branch** ascends with the internal jugular vein, and enters the skull through the foramen lacerum posterius, to supply the dura mater in the posterior fossa.

The **arteria princeps cervicis** (Fig. 372, p. 529) is a large branch which descends along the back part of the neck and divides into a superficial and deep branch. The former runs beneath the Splenius, giving off branches which perforate that muscle to supply the Trapezius, anastomosing with the superficial cervical artery: the latter passes beneath the Complexus, between it and the Semispinalis colli, and anastomoses with the vertebral and deep cervical branch of the superior intercostal. The anastomosis between these vessels serves mainly to establish the collateral circulation after ligature of the carotid or subclavian artery.

The cranial branches of the occipital artery are distributed upon the occiput; they are very tortuous, and lie between the integument and Occipito-frontalis, anastomosing with the artery of the opposite side, the posterior auricular, and temporal arteries. They supply the back part of the Occipito-frontalis muscle, the integument, and pericranium.

The **Posterior Auricular Artery** (Fig. 368) is a small vessel which arises from the external carotid above the Digastric and Stylo-hyoid muscles, opposite the apex of the styloid process. It ascends, under cover of the parotid gland, to the groove between the cartilage of the ear and the mastoid process, immediately above which it divides into two branches—an interior, passing forward to supply the back of the auricle and anastomose with the posterior division of the temporal; and a posterior, to the scalp above and behind the ear, communicating with the occipital. Just before arriving at the mastoid process this artery is crossed by the portio dura, and has beneath it the spinal accessory nerve.

Besides several small branches to the Digastric, Stylo-hyoid, and Sterno-mastoid muscles and to the parotid gland, this vessel gives off two branches:

Stylo-mastoid. Auricular.

The **stylo-mastoid branch** enters the stylo-mastoid foramen and supplies the tympanum, mastoid cells, and semicircular canals. In the young subject a branch from this vessel forms, with the tympanic branch from the internal maxillary, a vascular circle which surrounds the auditory meatus, and from which delicate vessels ramify on the membrana tympani. It anastomoses with the petrosal branch of the middle meningeal artery by a twig which enters the hiatus Fallopii.

The **auricular branch** is distributed to the back part of the cartilage of the ear, upon which it ramifies minutely, some branches curving round the margin of the fibro-cartilage, others perforating it to supply its anterior surface. It anastomoses with the anterior auricular branches of the temporal.

The **Ascending Pharyngeal Artery** (Fig. 372), the smallest branch of the external carotid, is a long slender vessel deeply seated in the neck, beneath the other branches of the external carotid and the Stylo-pharyngeus muscle. It arises from the back part of the external carotid, near the commencement of that vessel, and ascends vertically, between the internal carotid and the side of the pharynx, to the under surface of the base of the skull, lying on the Rectus capitis anticus major. Its branches may be subdivided into three sets: 1, Those directed outward to supply muscles and nerves; 2, those directed inward to the pharynx; 3, meningeal branches.

The **external branches** are numerous small vessels which supply the Recti capitis antici and Longus colli muscles, the sympathetic, hypoglossal, and pneumogastric nerves, and the lymphatic glands of the neck, anastomosing with the ascending cervical artery.

The **pharyngeal branches** are three or four in number. Two of these descend to supply the Middle and Inferior constrictors and the Stylo-pharyngeus, ramifying in their substance and in the mucous membrane lining them. The largest of the pharyngeal branches passes inward, running upon the Superior constrictor, and sends ramifications to the soft palate and tonsil, which take the place of the ascending palatine branch of the facial artery when that vessel is of small size. A twig from this branch passes up the Eustachian tube to supply the tympanum.

The **meningeal branches** consist of several small vessels which pass through foramina in the base of the skull to supply the dura mater. One, the posterior meningeal, enters the cranium through the foramen lacerum posterius with the internal jugular vein. A second passes through the foramen lacerum medium, and occasionally a third through the anterior condyloid foramen. They are all distributed to the dura mater.

The **Temporal Artery** (Fig. 368), the smaller of the two terminal branches of the external carotid, appears, from its direction, to be the continuation of that vessel. It commences in the substance of the parotid gland, in the interspace between the neck of the condyle of the lower jaw and the external meatus, crosses over the root of the zygoma immediately beneath the integument, and divides about two inches above the zygomatic arch into two branches, an anterior and a posterior.

The **anterior temporal** inclines forward over the forehead, supplying the muscles, integument, and pericranium in this region, and anastomoses with the supraorbital and frontal arteries. [This can easily be felt, and may be used to count the pulse in sleeping children and in etherizing.]

The **posterior temporal,** larger than the anterior, curves upward and backward along the side of the head, lying above the temporal fascia, and inosculates with its fellow of the opposite side and with the posterior auricular and occipital arteries.

The temporal artery, as it crosses the zygoma, is covered by the Attrahens aurem muscle and by a dense fascia given off from the parotid gland; it is also usually crossed by one or two veins and accompanied by branches of the facial and auriculo-temporal nerves. Besides some twigs to the parotid gland, the articulation of the jaw, and the Masseter muscle, its branches are the

Transverse Facial. Middle Temporal.
Anterior Auricular.

The **transverse facial** is given off from the temporal before that vessel quits the parotid gland; running forward through its substance, it passes transversely across the face, between Stenson's duct and the lower border of the zygoma, and divides on the side of the face into numerous branches, which supply the parotid gland, the Masseter muscle, and the integument, anastomosing with the facial, masseteric, and infraorbital arteries. This vessel rests on the Masseter, and is accompanied by one or two branches of the facial nerve. It is sometimes a branch of the external carotid.

The **middle temporal artery** arises immediately above the zygomatic arch, and, perforating the temporal fascia, supplies the Temporal muscle, anastomosing with the deep temporal branches of the internal maxillary. It occasionally gives off an orbital branch which runs along the upper border of the zygoma, between the two layers of the temporal fascia, to the outer angle of the orbit. This branch supplies the Orbicularis palpebrarum, and anastomoses with the lachrymal and palpebral branches of the ophthalmic artery.

The **anterior auricular branches** are distributed to the anterior portion of the pinna, the lobule, and part of the external meatus, anastomosing with branches of the posterior auricular.

Surgical Anatomy.—It occasionally happens that the surgeon is called upon to perform the operation of arteriotomy upon this vessel in cases of inflammation of the eye or brain. Under these circumstances the anterior branch is the one usually selected. If the student will consider the relations of the trunk of this vessel, as it crosses the zygomatic arch, with the surrounding structures, he will observe that it is covered by a thick and dense fascia, crossed by one or two veins, and accompanied by branches of the facial and auriculo-temporal nerves. Bleeding should not be performed in this situation, as much difficulty may arise from the dense fascia over the vessel preventing a free flow of blood, and considerable pressure is requisite afterward to repress the hemorrhage. Again, a varicose aneurism may be formed by the accidental opening of one of the veins in front of the artery, or severe neuralgic pain may arise from the operation, implicating one of the nervous filaments in the neighborhood.

The anterior branch, on the contrary, is subcutaneous, is a large vessel, and is as readily compressed as any other portion of the artery; it should consequently always be selected for the operation.

The **Internal Maxillary** (Fig. 369), the larger of the two terminal branches of the external carotid, passes inward, at right angles from that vessel, to the inner side of the neck of the condyle of the lower jaw, to supply the deep structures of the face. At its origin it is imbedded in the substance of the parotid gland, being on a level with the lower extremity of the lobe of the ear.

In the first part of its course (*maxillary portion*) the artery passes horizontally forward and inward between the ramus of the jaw and the internal lateral ligament. The artery here lies parallel with the auriculo-temporal nerve; it crosses the inferior dental nerve and lies beneath the narrow portion of the External pterygoid muscle.

FIG. 369.

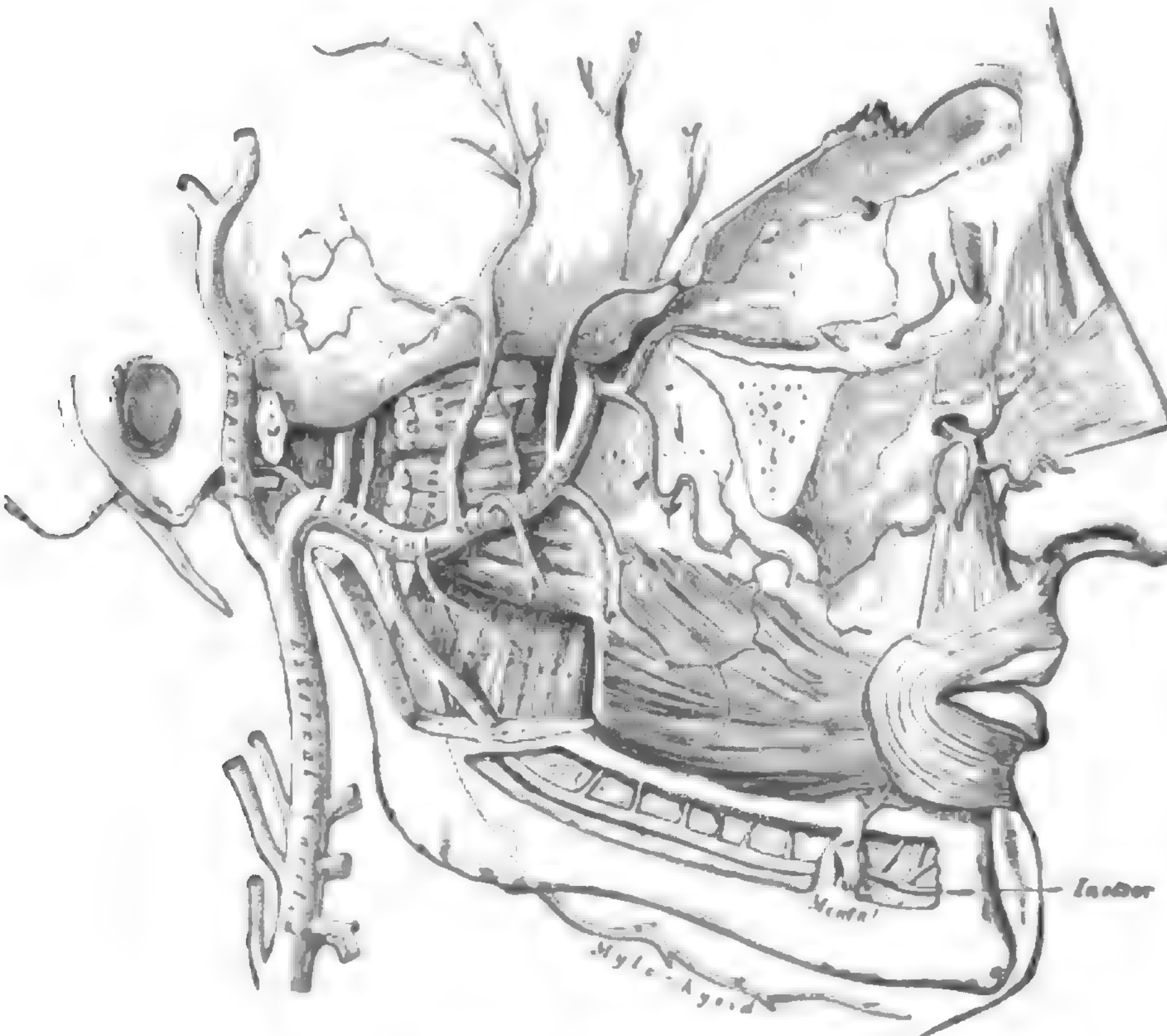
Incisor
Mental
Mylo-hyoid

FIG. 370.

Plan of the Branches.

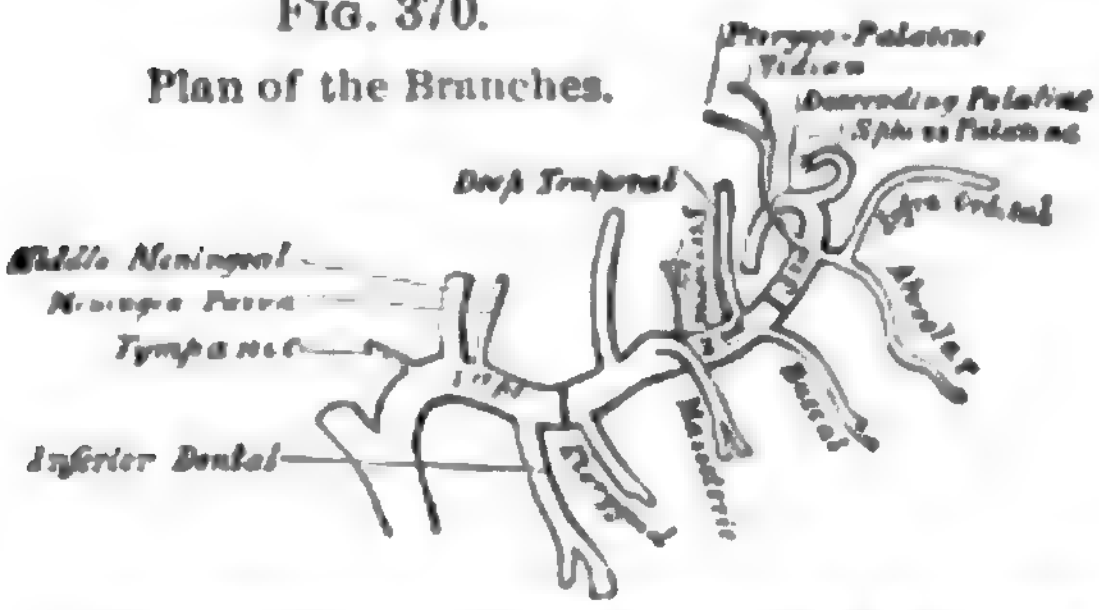
Pterygo-Palatine
Vidian
Descending Palatine
Spheno-Palatine
Deep Temporal
Infra Orbital
Middle Meningeal
Meningea Parva
Tympanic
Alveolar
Buccal
Masseteric
Pterygoid
Inferior Dental

The Internal Maxillary Artery and its Branches.

In the second part of its course (*pterygoid portion*) it runs obliquely forward and upward upon the outer surface of the External pterygoid muscle, being covered by the ramus of the lower jaw and lower part of the Temporal muscle.

In the third part of its course (*spheno-maxillary portion*) it approaches the superior maxillary bone, and enters the spheno-maxillary fossa in the interval between the processes of origin of the External pterygoid, where it lies in relation with Meckel's ganglion and gives off its terminal branches.

Peculiarities.—Occasionally this artery passes between the two Pterygoid muscles. The vessel in this case passes forward to the interval between the processes of origin of the External pterygoid, in order to reach the superior maxillary bone. Sometimes the vessel escapes from beneath the External pterygoid by perforating the middle of that muscle.

The branches of this vessel may be divided into three groups, corresponding with its three divisions.

BRANCHES FROM THE MAXILLARY PORTION (Fig. 370).

Tympanic (anterior).
Middle Meningeal.
Small Meningeal.
Inferior Dental.

The **tympanic branch** passes upward behind the articulation of the lower jaw, enters the tympanum through the fissure of Glaser, and ramifies upon the membrana tympani, forming a vascular circle around the membrane with the stylomastoid artery and anastomosing with the Vidian and tympanic branch from the internal carotid. It gives off an auricular branch to the external meatus, supplying its cuticular lining and the outer surface of the membrana tympani.

The **middle meningeal** [**meningea magna**] is the largest of the branches which supply the dura mater. It arises from the internal maxillary between the internal lateral ligament and the neck of the jaw, and passes vertically upward between the two roots of the auriculo-temporal nerve to the foramen spinosum of the sphenoid bone. On entering the cranium it divides into two branches, anterior and posterior. The anterior branch, the larger, crosses the great ala of the sphenoid and reaches the groove or canal in the anterior inferior angle of the parietal bone: it then divides into branches which spread out between the dura mater and internal surface of the cranium, some passing upward over the parietal bone as far as the vertex, and others backward to the occipital bone. The posterior branch crosses the squamous portion of the temporal, and on the inner surface of the parietal bone divides into branches which supply the posterior part of the dura mater and cranium. The branches of this vessel are distributed partly to the dura mater, but chiefly to the bones; they anastomose with the arteries of the opposite side and with the anterior and posterior meningeal.

The middle meningeal, on entering the cranium, gives off the following collateral branches: 1, Numerous small vessels to the ganglion of the fifth nerve and to the dura mater in this situation; 2, a branch to the facial nerve (*petrosal branch*), which enters the hiatus Fallopii, supplies the facial nerve, and anastomoses with the stylo-mastoid branch of the posterior auricular artery; 3, orbital branches, which pass through the sphenoidal fissure, or through separate canals in the great wing of the sphenoid, to anastomose with the lachrymal or other branches of the ophthalmic artery; 4, temporal branches, which pass through foramina in the great wing of the sphenoid and anastomose in the temporal fossa with the deep temporal arteries.

The **small meningeal** [**meningea parva**] is sometimes derived from the preceding. It enters the skull through the foramen ovale and supplies the Gasserian ganglion and dura mater. Before entering the cranium it gives off a branch to the nasal fossa, soft palate, and tonsil.

The **inferior dental** descends with the dental nerve to the foramen on the inner side of the ramus of the jaw. It runs along the dental canal in the substance of the bone accompanied by the nerve, and opposite the first bicuspid tooth divides into two branches, incisor and mental: the former is continued forward beneath the incisor teeth as far as the symphysis, where it anastomoses with the artery of the opposite side; the mental branch escapes with the nerve at the mental foramen, supplies the structures composing the chin, and anastomoses with the submental, inferior labial, and inferior coronary arteries. As the dental artery enters the foramen it gives off a *mylo-hyoid branch*, which runs in the mylo-hyoid groove and ramifies on the under surface of the Mylo-hyoid muscle. The dental and incisor arteries during their course through the substance of the bone give off a few twigs which are lost in the cancellous tissue, and a series of branches which correspond in number to the roots of the teeth: these enter the minute apertures at the extremities of the fangs and supply the pulp of the teeth.

BRANCHES OF THE SECOND OR PTERYGOID PORTION.

Deep Temporal.
Pterygoid.
Masseteric.
Buccal.

These branches are distributed, as their names imply, to the muscles in the maxillary region.

The **deep temporal branches**, two in number, anterior and posterior, each occupies that part of the temporal fossa indicated by its name. Ascending between the temporal muscle and pericranium, they supply that muscle and anastomose with the other temporal arteries, the anterior branch communicating with the lachrymal through small branches which perforate the malar bone and great wing of the sphenoid.

The **pterygoid branches**, irregular in their number and origin, supply the Pterygoid muscles.

The **masseteric** is a small branch which passes outward above the sigmoid notch of the lower jaw to the deep surface of the Masseter. It supplies that muscle and anastomoses with the masseteric branches of the facial and with the transverse facial artery.

The **buccal** is a small branch which runs obliquely forward between the Internal pterygoid and the ramus of the jaw to the outer surface of the Buccinator, to which it is distributed, anastomosing with branches of the facial artery.

BRANCHES OF THE THIRD OR SPHENO-MAXILLARY PORTION.

Alveolar.	Vidian.
Infraorbital.	Pterygo-palatine.
Posterior or Descending Palatine.	Nasal or Spheno-palatine.

The **alveolar** or **posterior dental branch** is given off from the internal maxillary by a common branch with the infraorbital, and just as the trunk of the vessel is passing into the spheno-maxillary fossa. Descending upon the tuberosity of the superior maxillary bone, it divides into numerous branches, some of which enter the posterior dental canals to supply the molar and bicuspid teeth and the lining of the antrum, and others are continued forward on the alveolar process to supply the gums.

The **infraorbital** appears, from its direction, to be the continuation of the trunk of the internal maxillary. It arises from that vessel by a common trunk with the preceding branch, and runs along the infraorbital canal with the superior maxillary nerve, emerging upon the face at the infraorbital foramen beneath the Levator labii superioris. Whilst contained in the canal it gives off branches which ascend into the orbit and supply the Inferior rectus and Inferior oblique muscles and the lachrymal gland. Other branches (*anterior dental*) descend through canals in the bone to supply the mucous membrane of the antrum and the front teeth of the upper jaw. On the face it supplies the lachrymal sac and inner angle of the orbit, anastomosing with the facial artery and nasal branch of the ophthalmic; and other branches descend beneath the Levator labii superioris and anastomose with the transverse facial and buccal branches.

The four remaining branches arise from that portion of the internal maxillary which is contained in the spheno-maxillary fossa.

The **descending palatine** passes down along the posterior palatine canal with the anterior and middle palatine branches of Meckel's ganglion, and, emerging from the posterior palatine foramen, runs forward in a groove on the inner side of the alveolar border of the hard palate to the anterior palatine canal, where the terminal branch of the artery passes upward through the foramen of Stenson to anastomose with the naso-palatine artery. Its branches are distributed to the gums, the mucous membrane of the hard palate, and the palatine glands. Whilst it is contained in the palatine canal, it gives off branches which descend in the accessory palatine canals to supply the soft palate and tonsil, anastomosing with the ascending palatine artery.

The **Vidian branch** passes backward along the Vidian canal with the Vidian nerve. It is distributed to the upper part of the pharynx and Eustachian tube, sending a small branch into the tympanum which anastomoses with the anterior tympanic.

The **pterygo-palatine** is also a very small branch, which passes backward through the pterygo-palatine canal with the pharyngeal nerve, and is distributed to the upper part of the pharynx and Eustachian tube.

The **nasal** or **spheno-palatine** passes through the spheno-palatine foramen into the cavity of the nose at the back part of the superior meatus, and divides into two branches: one, internal, the artery of the septum, passes obliquely downward and forward along the septum nasi, supplies the mucous membrane, and anastomoses in front with the terminal branch of the descending palatine. The external branches, two or three in number, supply the mucous membrane covering the lateral wall of the nose, the antrum, and the ethmoid and sphenoid cells.

SURGICAL ANATOMY OF THE TRIANGLES OF THE NECK.

The student having considered the relative anatomy of the large arteries of the neck and their branches, and the relations they bear to the veins and nerves, should now examine these structures collectively as they present themselves in certain regions of the neck, in each of which important operations are constantly being performed.

For this purpose the Sterno-mastoid or any other muscles that have been divided in the dissection of the vessels should be replaced in their normal position; the head should be supported by placing a block at the back of the neck, and the face turned to the side opposite to that which is being examined.

The side of the neck presents a somewhat quadrilateral outline, limited above by the lower border of the body of the jaw and an imaginary line extending from the angle of the jaw to the mastoid process; below, by the prominent upper border of the clavicle; in front, by the median line of the neck; behind, by the anterior margin of the Trapezius muscle. This space is subdivided into two large triangles by the Sterno-mastoid muscle, which passes obliquely across the neck from the sternum and clavicle below to the mastoid process above. The triangular space in front of this muscle is called the *anterior triangle*, and that behind it the *posterior triangle*.

[FIG. 371.

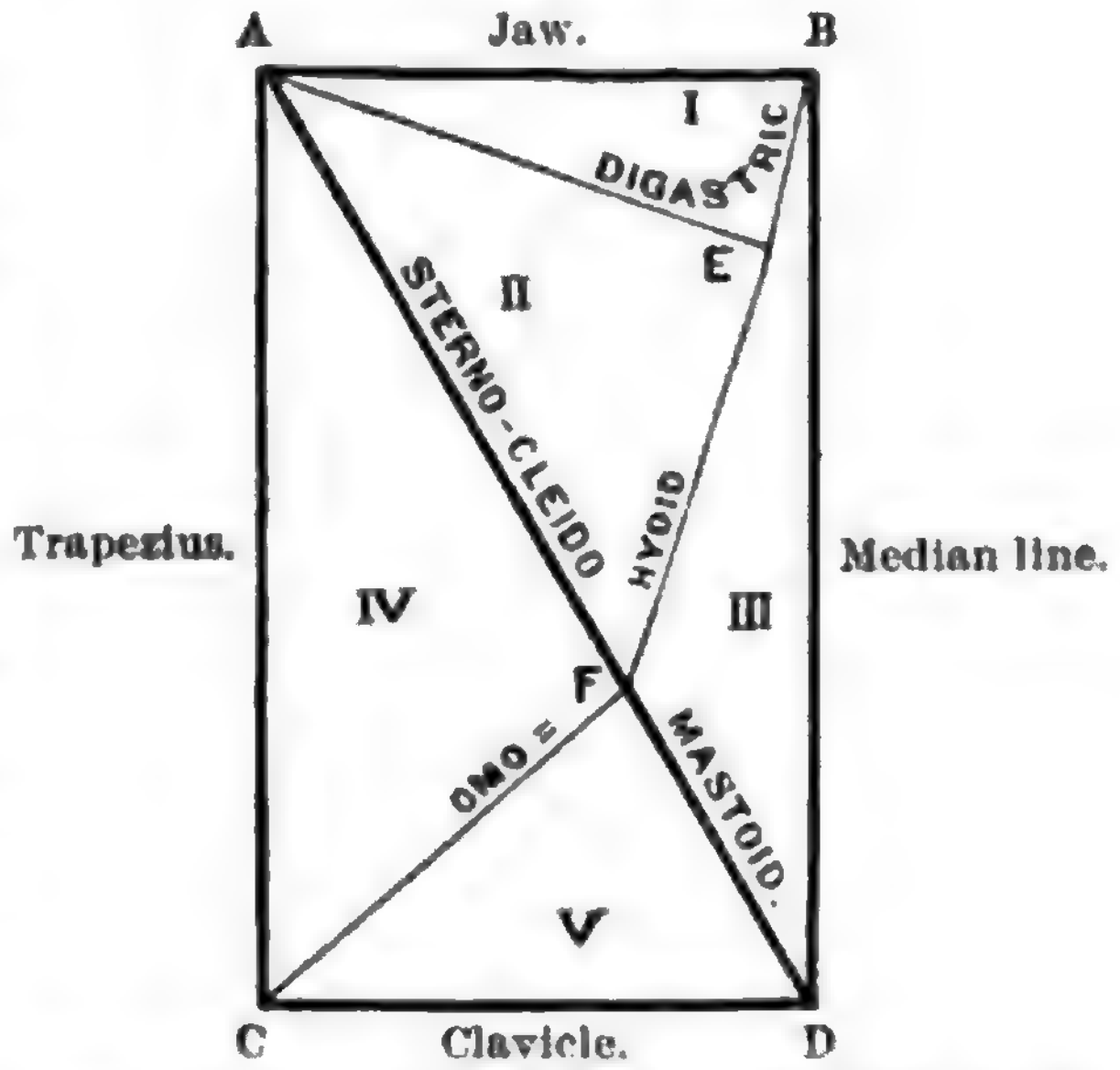

Diagram of the Triangles of the Right Side of the Neck: I, digastric or submaxillary triangle; II, superior carotid triangle, or triangle of election; III, inferior carotid triangle, or triangle of necessity; IV, suboccipital triangle; V, subclavian triangle.—W. W. K.]

ANTERIOR TRIANGULAR SPACE.

The **Anterior Triangle** is bounded in front by a line extending from the chin to the sternum; behind, by the anterior margin of the Sterno-mastoid; its base, directed upward, is formed by the lower border of the body of the jaw and a line extending from the angle of the jaw to the mastoid process; its apex is below, at the sternum. The space is covered by the integument, superficial fascia, Platysma, and deep fascia; it is crossed by branches of the facial and superficial cervical nerves, and is subdivided into three smaller triangles by the Digastric muscle above and the anterior belly of the Omo-hyoid below. These smaller triangles are named, from below upward, the inferior carotid, the superior carotid, and the submaxillary triangle.

The Inferior Carotid Triangle [or "*triangle of necessity*," in which we *must* tie the carotid if it is impossible to do so in the triangle of election] is bounded in front by the median line of the neck; behind, by the anterior margin of the Sterno-mastoid; above, by the anterior belly of the Omo-hyoid; and is covered by the integument, superficial fascia, Platysma, and deep fascia, ramifying between which is seen the descending branch of the superficialis colli nerve. Beneath these superficial structures are the Sterno-hyoid and Sterno-thyroid muscles, which, together with the anterior margin of the Sterno-mastoid, conceal the lower part of the common carotid artery.[1]

This vessel is enclosed within its sheath, together with the internal jugular vein and pneumogastric nerve; the vein lying on the outer side of the artery on the right side of the neck, but overlapping it or passing directly across it on the left side; the nerve lying between the artery and vein, on a plane posterior to both. In front of the sheath are a few filaments descending from the loop of communication between the descendens and communicans noni; behind the sheath are seen the inferior thyroid artery, the recurrent laryngeal nerve, and the sympathetic nerve; and on its inner side, the trachea, the thyroid gland, much more prominent in the female than in the male, and the lower part of the larynx. By cutting into the upper part of this space and slightly displacing the Sterno-mastoid muscle the common carotid artery may be tied below the Omo-hyoid muscle.

The floor of the inferior carotid triangle is formed by the Longus colli muscle below and by the Scalenus anticus above (see Fig. 290, p. 384, and Fig. 297, p. 397), between which muscles the vertebral artery and vein will be found passing into the foramen in the sixth transverse process; a small portion of the origin of the Rectus capitis anticus major may also be seen in the floor of the space.

The **Superior Carotid Triangle** [or "*triangle of election,*" in which we *elect* to tie the carotid if we have the choice] is bounded behind by the Sterno-mastoid; below, by the anterior belly of the Omo-hyoid; and above, by the posterior belly of the Digastric muscle. Its floor is formed by parts of the Thyro-hyoid, Hyo-glossus, and the inferior and middle Constrictor muscles of the pharynx, and it is covered by the integument, superficial fascia, Platysma, and deep fascia, ramifying between which are branches of the facial and superficialis colli nerves. This space contains the upper part of the common carotid artery, which bifurcates opposite the upper border of the thyroid cartilage into the external and internal carotid. These vessels are occasionally somewhat concealed from view by the anterior margin of the Sterno-mastoid muscle, which overlaps them. The external and internal carotids lie side by side, the external being the more anterior of the two. The following branches of the external carotid are also met with in this space: the superior thyroid, running forward and downward; the lingual, directly forward; the facial, forward and upward; the occipital, backward; and the ascending pharyngeal, directly upward on the inner side of the internal carotid. The veins met with are—the internal jugular, which lies on the outer side of the common and internal carotid arteries, and veins corresponding to the above-mentioned branches of the external carotid—viz. the superior thyroid, the lingual, facial, ascending pharyngeal, and sometimes the occipital; all of which accompany their corresponding arteries and terminate in the internal jugular. The nerves in this space are the following: In front of the sheath of the common carotid is the descendens noni. The hypoglossal nerve crosses both carotids above, curving round the occipital artery at its origin. Within the sheath, between the artery and vein and behind both, is the pneumogastric nerve; behind the sheath, the sympathetic. On the outer side of the vessels the spinal accessory nerve runs for a short distance before it pierces the Sterno-mastoid muscle; and on the inner side of the internal carotid, just below the hyoid bone, may be seen the superior laryngeal nerve, and, still more inferiorly, the external laryngeal nerve. The upper part of the larynx and lower part of the pharynx are also found in the front part of this space.

The **Submaxillary Triangle** corresponds to the part of the neck immediately beneath the body of the jaw. It is bounded above by the lower border of the body of the jaw and a line drawn from its angle to the mastoid process; below, by the posterior belly of the Digastric and Stylo-hyoid muscles; in front, by the middle line of the neck. The floor of this space is formed by the anterior belly of the Digastric, the Mylo-hyoid, and Hyo-glossus muscles, and it is covered by the integument, superficial fascia, Platysma, and deep fascia, ramifying between which are branches of the facial and ascending filaments of the superficial cervical nerve. This space contains in front the submaxillary gland, imbedded in the substance of which are the facial artery and vein and their glandular branches; beneath this gland, on the surface of the Mylo-hyoid muscle, are the submental artery and the mylo-hyoid artery and nerve. The back part of this space is separated from the front part by the stylo-maxillary ligament; it contains the external carotid artery, ascending deeply in the substance of the parotid gland; this vessel here lies in front of, and superficial to, the internal carotid, being crossed by the facial nerve, and gives off in its course the posterior auricular, temporal, and internal maxillary branches; more deeply is the internal carotid, the internal jugular vein, and the pneumogastric nerve separated from the external carotid by the Stylo-glossus and Stylo-pharyngeus muscles and the glosso-pharyngeal nerve.[1]

---

[1] Therefore the carotid artery and jugular vein are not, strictly speaking, contained in this triangle, since they are covered by the Sterno-mastoid muscle; that is to say, lie behind the anterior border of that muscle, which forms the posterior border of the triangle. But as they lie very close to the structures which are really contained in the triangle, and whose position it is essential to remember in operating on this part of the artery, it has seemed expedient to study the relations of all these parts together.

POSTERIOR TRIANGULAR SPACE.

The posterior triangular space is bounded in front by the Sterno-mastoid muscle, behind by the anterior margin of the Trapezius; its base corresponds to the upper border of the clavicle, its apex to the occiput. The space is crossed about an inch above the clavicle by the posterior belly of the Omo-hyoid, which divides it unequally into two—an upper or occipital, and a lower or subclavian triangle.

The **Occipital**, the larger of the two posterior triangles, is bounded in front by the Sterno-mastoid, behind by the Trapezius, below by the Omo-hyoid. Its floor is formed from above downward by the Splenius, Levator anguli scapulæ, and the middle and posterior Scaleni muscles. It is covered by the integument, the Platysma below, the superficial and deep fasciæ, and crossed above by the ascending branches of the cervical plexus; the spinal accessory nerve is directed obliquely across the space from the Sterno-mastoid, which it pierces, to the under surface of the Trapezius; below, the descending branches of the cervical plexus and the transversalis colli artery and vein cross the space. A chain of lymphatic glands is also found running along the posterior border of the Sterno-mastoid from the mastoid process to the root of the neck.

The **Subclavian**, the smaller of the two posterior triangles, is bounded above by the posterior belly of the Omo-hyoid, below by the clavicle, its base, directed forward, being formed by the Sterno-mastoid. The size of the subclavian triangle varies according to the extent of attachment of the clavicular portion of the Sterno-mastoid and Trapezius muscles, and also according to the height at which the Omo-hyoid crosses the neck above the clavicle. Its height also varies much according to the position of the arm, being much diminished by raising the limb, on account of the ascent of the clavicle, and increased by drawing the arm downward, when that bone is depressed. This space is covered by the integument, superficial and deep fasciæ, and crossed by the descending branches of the cervical plexus. Just above the level of the clavicle the third portion of the subclavian artery curves outward and downward from the outer margin of the Scalenus anticus, across the first rib to the axilla. Sometimes this vessel rises as high as an inch and a half above the clavicle or to any point intermediate between this and its usual level. Occasionally it passes in front of the Scalenus anticus or pierces the fibres of that muscle. The subclavian vein lies behind the clavicle, and is usually not seen in this space; but it occasionally rises as high up as the artery, and has even been seen to pass with that vessel behind the Scalenus anticus. The brachial plexus of nerves lies above the artery and in close contact with it. Passing transversely across the clavicular margin of the space are the suprascapular vessels, and, traversing its upper angle in the same direction, the transversalis colli artery and vein. The external jugular vein runs vertically downward behind the posterior border of the Sterno-mastoid, to terminate in the subclavian vein; it receives the transverse cervical and suprascapular veins, which occasionally form a plexus in front of the artery, and a small vein which crosses the clavicle from the cephalic. The small nerve to the Subclavius also crosses this triangle about its middle. A lymphatic gland is also found in the space. Its floor is formed by the first rib with the first digitation of the Serratus magnus.

---

[1] The same remark will apply to this triangle as was made about the inferior carotid triangle. The structures enumerated, as contained in the back part of the space, lie, strictly speaking, beneath the muscles which form the posterior boundary of the triangle; but as it is very important to bear in mind their close relation to the parotid gland and its boundaries (on account of the frequency of surgical operations on this gland), all these parts are spoken of together.

INTERNAL CAROTID ARTERY.

The **Internal Carotid Artery** commences at the bifurcation of the common carotid, opposite the upper border of the thyroid cartilage, and runs perpendicularly upward, in front of the transverse processes of the three upper cervical vertebræ, to the carotid foramen in the petrous portion of the temporal bone. After ascending in it for a short distance it passes forward and inward through the carotid canal and enters the skull. It then ascends to the posterior clinoid process, curves forward through the cavernous sinus, and at the anterior clinoid process again turns upward, pierces the dura mater, and divides into its terminal branches.

This vessel supplies the anterior part of the brain, the eye and its appendages, and sends branches to the forehead and nose. Its size in the adult is equal to that of the external carotid; in the child it is larger than that vessel. It is remarkable for the number of curvatures that it presents in different parts of its course. In its cervical portion it occasionally presents one or two flexures near the base of the skull, whilst through the rest of its extent it describes a double curvature which resembles the italic letter *s* placed horizontally. These curvatures most probably diminish the velocity of the current of blood by increasing the extent of surface over which it moves and adding to the amount of impediment produced from friction. In considering the course and relations of this vessel it may be conveniently divided into four portions—a cervical, petrous, cavernous, and cerebral.

Cervical Portion.—This portion of the internal carotid is superficial at its commencement, being contained in the superior carotid triangle, and lying on the same level as the external carotid, but behind that artery, overlapped by the Sterno-mastoid and covered by the Platysma, deep fascia, and integument: it then passes beneath the parotid gland, being crossed by the hypoglossal nerve, the Digastric and Stylo-hyoid muscles, and the external carotid and occipital arteries. Higher up it is separated from the external carotid by the Stylo-glossus and Stylo-pharyngeus muscles, the glosso-pharyngeal nerve, and pharyngeal branch of the pneumogastric. It is in relation *behind* with the Rectus capitis anticus major, the superior cervical ganglion of the sympathetic, and superior laryngeal nerve; *externally*, with the internal jugular vein and pneumogastric nerve; *internally*, with the pharynx, tonsil, the superior laryngeal nerve, and ascending pharyngeal artery.

Petrous Portion.—When the internal carotid artery enters the canal in the petrous portion of the temporal bone, it first ascends a short distance, then curves forward and inward, and again ascends as it leaves the canal to enter the cavity of the skull. In this canal the artery lies at first anterior to the tympanum, from which it is separated by a thin bony lamella which is cribriform in the young subject, and often absorbed in old age. It is separated from the bony wall of the carotid canal by a prolongation of dura mater, and is surrounded by filaments of the carotid plexus.

Cavernous Portion.—The internal carotid artery in this part of its course at first ascends to the posterior clinoid process, then passes forward by the side of the body of the sphenoid bone, being situated on the inner wall of the cavernous sinus, in relation externally with the sixth nerve, surrounded by filaments of the sympathetic, and covered by the lining membrane of the sinus.

Cerebral Portion.—On the inner side of the anterior clinoid process the internal carotid curves upward, perforates the dura mater bounding the sinus, and is received into a sheath of the arachnoid. This portion of the artery is on the outer side of the optic nerve; it lies at the inner extremity of the fissure of Sylvius, having the third nerve externally.

Fig. 372.

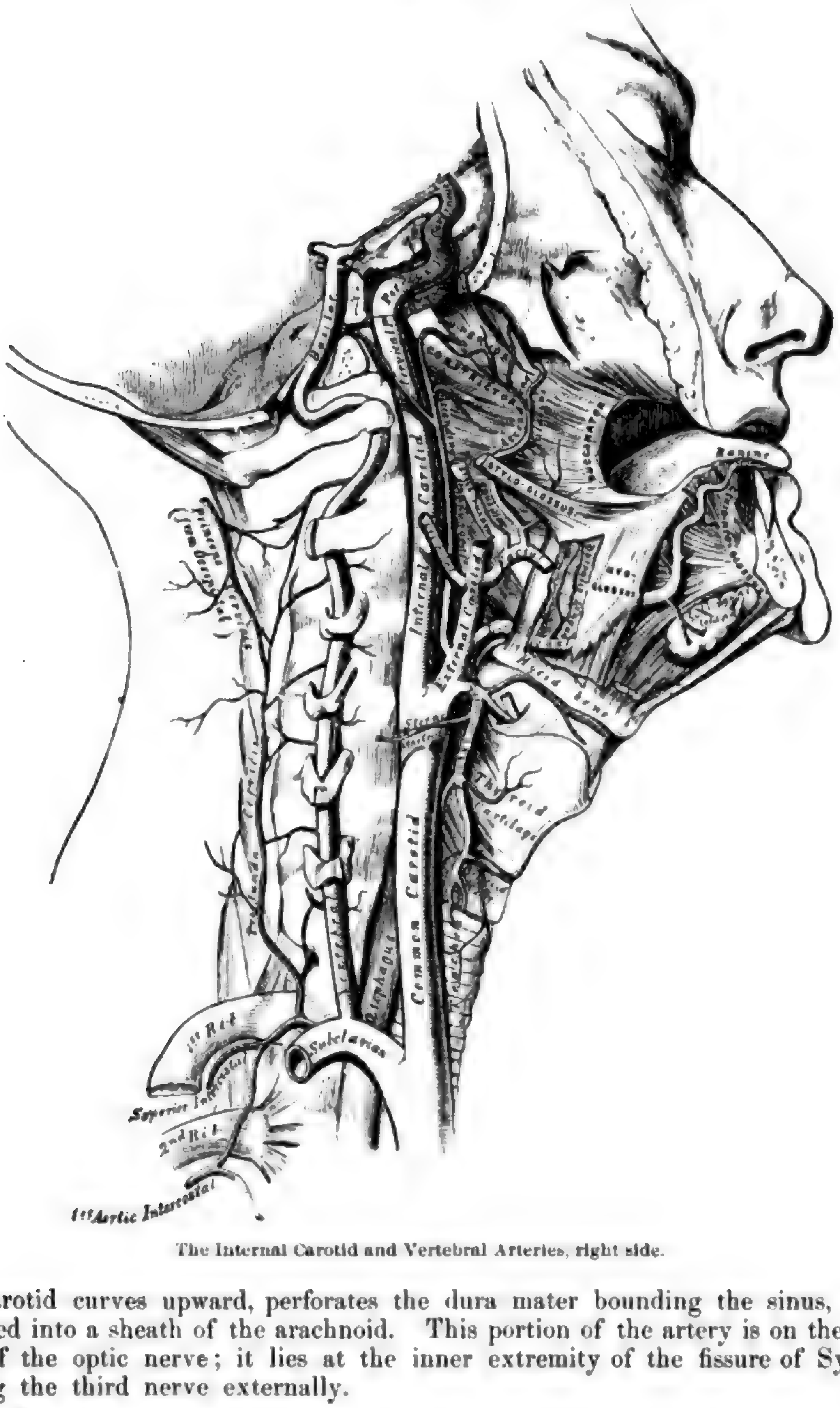
Basilar
Vertebral
Constrictor
Internal Carotid
External Carotid
Stylo-glossus
Buccinator
Hyoid bone
Princeps Cervicis
Profunda Cervicis
Thyroid cartilage
Vertebral
Œsophagus
Common Carotid
Trachea
1st Rib
Subclavian
Superior Intercostal
2nd Rib
1st Aortic Intercostal

The Internal Carotid and Vertebral Arteries, right side.

Plan of the Relations of the Internal Carotid Artery in the Neck.

In Front.

Skin, superficial and deep fasciæ.
Parotid gland.
Stylo-glossus and Stylo-pharyngeus muscles.
Glosso-pharyngeal nerve.

Externally.

Internal jugular vein.
Pneumogastric nerve.

Internal Carotid Artery.

Internally.

Pharynx.
Superior laryngeal nerve.
Ascending pharyngeal artery.
Tonsil.

Behind.

Rectus capitis anticus major.
Sympathetic.
Superior laryngeal nerve.

Peculiarities.—The length of the internal carotid varies according to the length of the neck, and also according to the point of bifurcation of the common carotid. Its origin sometimes takes place from the arch of the aorta; in such rare instances this vessel has been found to be placed nearer the middle line of the neck than the external carotid, as far upward as the larynx when the latter vessel crossed the internal carotid. The course of the vessel, instead of being straight, may be very tortuous. A few instances are recorded in which this vessel was altogether absent: in one of these the common carotid passed up the neck and gave off the usual branches of the external carotid, the cranial portion of the internal carotid being replaced by two branches of the internal maxillary, which entered the skull through the foramen rotundum and ovale and joined to form a single vessel.

Surgical Anatomy.—The cervical part of the internal carotid is sometimes wounded by a stab or gunshot wound in the neck, or even occasionally by a stab from within the mouth, as when a person receives a thrust from the end of a parasol or falls down with a tobacco-pipe in his mouth. In such cases a ligature should be applied to the common carotid. The relation of the internal carotid with the tonsil should be especially remembered, as instances have occurred in which the artery has been wounded during the operation of scarifying the tonsil, and fatal hemorrhage has supervened.

The branches given off from the internal carotid are—

From the Petrous Portion .	Tympanic (internal or deep).
From the Cavernous Portion	Arteriæ receptaculi. Anterior Meningeal. Ophthalmic.
From the Cerebral Portion	Anterior Cerebral. Middle Cerebral. Posterior Communicating. Anterior Choroid.

The cervical portion of the internal carotid gives off no branches.

The **tympanic** is a small branch which enters the cavity of the tympanum through a minute foramen in the carotid canal, and anastomoses with the tympanic branch of the internal maxillary and with the stylo-mastoid artery.

The **arteriæ receptaculi** are numerous small vessels derived from the internal carotid in the cavernous sinus; they supply the pituitary body, the Gasserian ganglion, and the walls of the cavernous and inferior petrosal sinuses. One of these branches, distributed to the dura mater, is called the **anterior meningeal**; it anastomoses with the middle meningeal.

The **Ophthalmic Artery** arises from the internal carotid just as that vessel is emerging from the cavernous sinus, on the inner side of the anterior clinoid process, and enters the orbit through the optic foramen below and on the outer side of the optic nerve. It then passes over the nerve to the inner wall of the orbit, and thence horizontally forward, beneath the lower border of the Superior oblique muscle, to the inner angle of the eye, where it divides into two terminal branches, the *frontal* and *nasal.*

Branches.—The branches of this vessel may be divided into an *orbital* group,

FIG. 373.

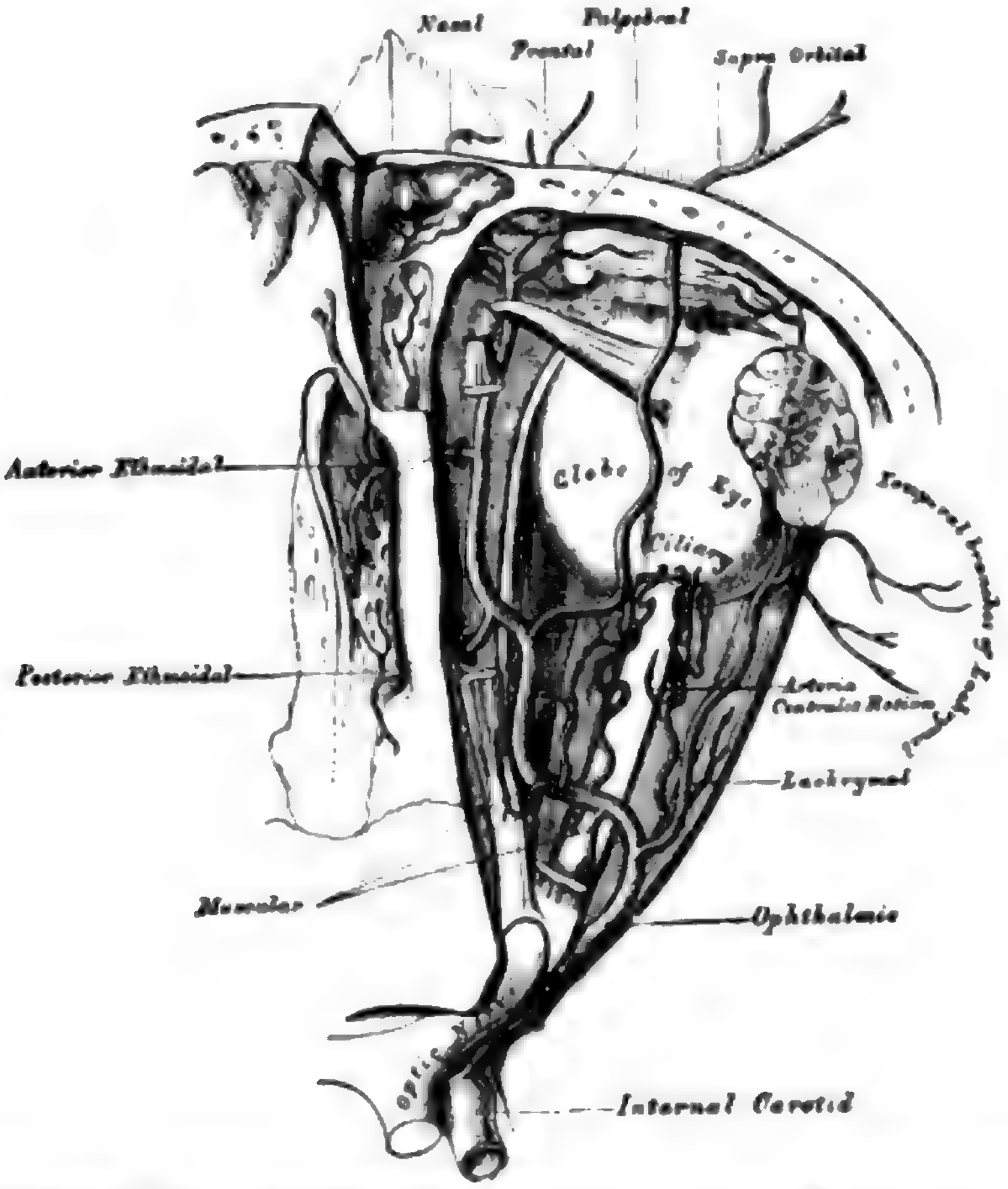
Nasal
Frontal
Palpebral
Supra Orbital
Anterior Ethmoidal
Posterior Ethmoidal
Globe of Eye
Ciliary
Temporal branches of Lachrymal
Arteria Centralis Retinæ
Lachrymal
Muscular
Ophthalmic
Optic
Internal Carotid

The Ophthalmic Artery and its Branches, the Roof of the Orbit having been removed.

which are distributed to the orbit and surrounding parts; and an *ocular* group, which supply the muscles and globe of the eye.

Orbital Group.	*Ocular Group.*
Lachrymal.	Muscular.
Supraorbital.	Anterior Ciliary.
Posterior Ethmoidal.	Short Ciliary.
Anterior Ethmoidal.	Long Ciliary.
Palpebral.	Arteria centralis retinæ.
Frontal.	
Nasal.	

The **lachrymal** is the first, and one of the largest, branches derived from the ophthalmic, arising close to the optic foramen: not unfrequently it is given off from the artery before it enters the orbit. It accompanies the lachrymal nerve along the upper border of the External rectus muscle, and is distributed to the lachrymal gland. Its terminal branches, escaping from the gland, are distributed to the upper eyelid and conjunctiva, anastomosing with the palpebral arteries. The lachrymal artery gives off one or two *malar* branches, one of which passes through a foramen in the malar bone to reach the temporal fossa, and anastomoses with the deep temporal arteries. The other appears on the cheek, and anastomoses with the transverse facial. A branch is also sent backward, through the sphenoidal fissure, to the dura mater, which anastomoses with a branch of the middle meningeal artery.

Peculiarities.—The lachrymal artery is sometimes derived from one of the anterior branches of the middle meningeal artery.

The **supraorbital artery,** the largest branch of the ophthalmic, arises from that vessel above the optic nerve. Ascending so as to rise above all the muscles of the orbit, it passes forward with the frontal nerve, between the periosteum and Levator palpebræ, and, passing through the supraorbital foramen, divides into a superficial and a deep branch, which supply the muscles and integument of the forehead and pericranium, anastomosing with the temporal, the angular branch of the facial, and the artery of the opposite side. This artery in the orbit supplies the Superior rectus and the Levator palpebræ, sends a branch inward, across the pulley of the Superior oblique muscle, to supply the parts at the inner canthus, and at the supraorbital foramen frequently transmits a branch to the diploë.

The **ethmoidal branches** are two in number, posterior and anterior. The former, which is the smaller, passes through the posterior ethmoidal foramen, supplies the posterior ethmoidal cells, and, entering the cranium, gives off a meningeal branch which supplies the adjacent dura mater and nasal branches, which descend into the nose through apertures in the cribriform plate, anastomosing with branches of the spheno-palatine. The anterior ethmoidal artery accompanies the nasal nerve through the anterior ethmoidal foramen, supplies the anterior ethmoidal cells and frontal sinuses, and, entering the cranium, divides into a meningeal branch which supplies the adjacent dura mater, and a nasal branch which descends into the nose through an aperture in the cribriform plate.

The **palpebral arteries**, two in number, superior and inferior, arise from the ophthalmic, opposite the pulley of the Superior oblique muscle; they encircle the eyelids near their free margin, forming a superior and an inferior arch, which lie between the Orbicularis muscle and tarsal cartilages, the superior palpebral inosculating at the outer angle of the orbit with the orbital branch of the temporal artery, the inferior palpebral with the orbital branch of the infraorbital artery at the inner side of the lid. From this anastomosis a branch passes to the nasal duct, ramifying in its mucous membrane, as far as the inferior meatus.

The **frontal artery**, one of the terminal branches of the ophthalmic, passes from the orbit at its inner angle, and, ascending on the forehead, supplies the muscles, integument, and pericranium, anastomosing with the supraorbital artery.

The **nasal artery**, the other terminal branch of the ophthalmic, emerges from the orbit above the tendo oculi, and, after giving a branch to the lachrymal sac, divides into two, one of which anastomoses with the angular artery; the other branch, the *dorsalis nasi*, runs along the dorsum of the nose, supplies its entire surface, and anastomoses with the artery of the opposite side.

The **ciliary arteries** are divisible into three groups—the short, long, and anterior. The *short ciliary arteries*, from twelve to fifteen in number, arise from the ophthalmic or some of its branches; they surround the optic nerve as they pass forward to the posterior part of the eyeball, pierce the sclerotic coat around the entrance of the nerve, and supply the choroid coat and ciliary processes. The *long ciliary arteries*, two in number, also pierce the posterior part of the sclerotic, and run forward along each side of the eyeball, between the sclerotic and choroid, to the ciliary ligament, where they divide into two branches; these form an arterial circle around the circumference of the iris, from which numerous radiating branches pass forward in its substance to its free margin, where they form a second arterial circle around its pupillary margin. The *anterior ciliary arteries* are derived from the muscular branches; they pierce the sclerotic a short distance from the cornea and terminate in the great arterial circle of the iris.

The **arteria centralis retinæ** is one of the smallest branches of the ophthalmic artery. It arises near the optic foramen, pierces the optic nerve obliquely, and runs forward, in the centre of its substance, to the retina, in which its branches are distributed as far forward as the ciliary processes. [See the description of the Eye.] In the human fœtus a small vessel passes forward, through the vitreous humor, to the posterior surface of the capsule of the lens.

The **muscular branches**, two in number, superior and inferior, supply the muscles of the eyeball. The superior, the smaller (often wanting), supplies the Levator palpebræ, Superior rectus, and Superior oblique. The inferior, more constant in its existence, passes forward between the optic nerve and Inferior rectus, and is distributed to the External, Internal, and Inferior recti, and Inferior oblique. This vessel gives off most of the anterior ciliary arteries.

FIG. 374.

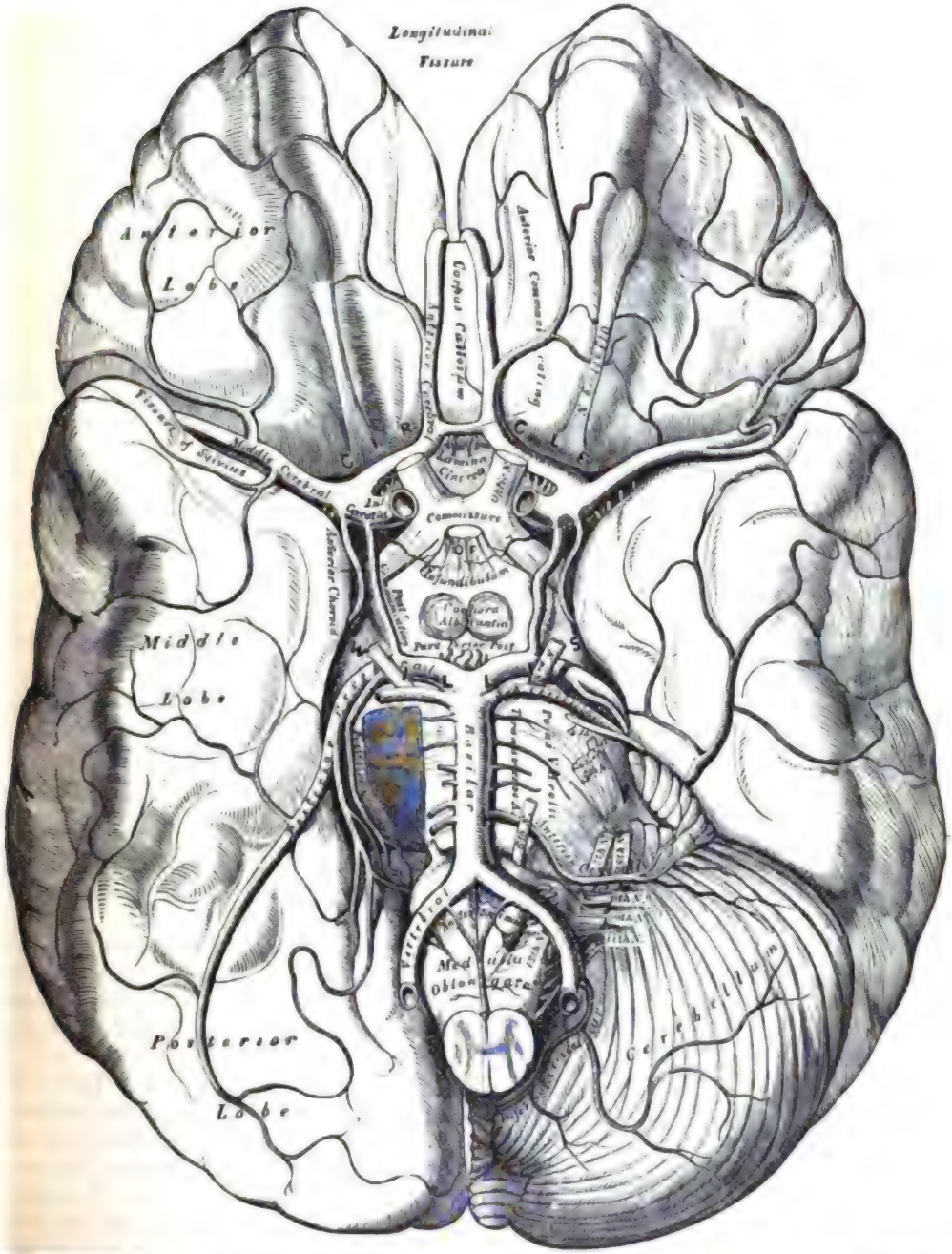
Longitudinal Fissure
Anterior Lobe
Corpus Callosum
Anterior Cerebral
Anterior Communicating
Fissure of Sylvius
Middle Cerebral
Lamina Cinerea
Int. Carotid
Commissure
Infundibulum
Anterior Choroid
Post. Communicating
Corpora Albicantia
Middle Lobe
Basilar
Transverse A.
Pons Varolii
Anterior Cerebellar
Vertebral
Medulla Oblongata
Cerebellum
Posterior Lobe

The Arteries of the Base of the Brain. The right half of the Cerebellum and Pons have been removed. N. B.—It will be noticed that in the illustration the two anterior cerebral arteries have been drawn at a considerable distance from each other; this makes the anterior communicating artery appear very much longer than it really is.

The cerebral branches of the internal carotid are—the anterior cerebral, the middle cerebral, the posterior communicating, and the anterior choroid.

The anterior cerebral arises from the internal carotid at the inner extremity of the fissure of Sylvius. It passes forward in the great longitudinal fissure between the two anterior lobes of the brain, being connected soon after its origin with the vessel of the opposite side by a short anastomosing trunk about two lines in length, the *anterior communicating*. The two anterior cerebral arteries, lying side by side, curve round the anterior border of the corpus callosum and run along its upper surface to its posterior part, where they terminate by anastomosing with the posterior cerebral arteries. They supply the olfactory and optic nerves, the under surface of the anterior lobes, the third ventricle, the anterior perforated space, the corpus callosum, and the internal surface of the hemispheres.

The **anterior communicating artery** is a short branch, about two lines in length, but of moderate size, connecting together the two anterior cerebral arteries across the longitudinal fissure. Sometimes this vessel is wanting, the two arteries joining together to form a single trunk which afterward subdivides; or the vessel may be wholly or partially subdivided into two; frequently it is longer and smaller than usual.

The **middle cerebral** [or **Sylvian**] **artery**, the largest branch of the internal carotid, passes obliquely outward along the fissure of Sylvius, within which it divides into three branches: an anterior, which supplies the pia mater, investing the surface of the anterior lobe; a posterior, which supplies the middle lobe; and a median branch, which supplies the small lobe at the outer extremity of the Sylvian fissure. Near its origin this vessel gives off numerous small branches which enter the locus perforatus anticus to be distributed to the corpus striatum.

The **posterior communicating artery** arises from the back part of the internal carotid, runs directly backward, and anastomoses with the posterior cerebral, a branch of the basilar. This artery varies considerably in size, being sometimes small, and occasionally so large that the posterior cerebral may be considered as arising from the internal carotid rather than from the basilar. It is frequently larger on one side than on the other side.

The **anterior choroid** is a small but constant branch which arises from the back part of the internal carotid, near the posterior communicating artery. Passing backward and outward, it enters the descending horn of the lateral ventricle beneath the edge of the middle lobe of the brain. It is distributed to the hippocampus major, corpus fimbriatum, velum interpositum, and choroid plexus.

[THE BLOOD-VESSELS OF THE BRAIN.

[The cerebral circulation is of such importance that a more detailed description of it seems desirable, especially in view of modern researches both in anatomy and pathology.

The arteries of the brain are derived from the internal carotid and the vertebral. On the left side these vessels arise at such an angle that the blood-current is much more direct than on the right (Fig. 364, p. 503). Hence, probably, the larger size and development of the left hemisphere and the greater frequency of embolism and hemorrhage upon that side.

At the base of the brain these four vessels form the *circle of Willis*. This consists of two sets of vessels: the anterior or carotid set, from which arise the anterior and middle cerebral arteries; and the posterior or vertebral set, consisting of the basilar and posterior cerebral arteries. Each set has the freest possible anastomosis from side to side, thus providing an abundant blood-supply in case of sudden blocking of one of its vessels. This is the more important since, as will be seen later, the peripheral arteries to the cortex and the ganglia have no anastomosis whatever.

Antero-posteriorly, it is quite different. The anterior set of vessels are connected with the posterior by the two posterior communicating arteries, which are small anastomotic branches quite variable in their development. When of very small size or absent, the collateral circulation after ligature of the carotid is not uncommonly insufficient to supply the brain, and cerebral softening follows.

Derived from the circle of Willis and its branches are two independent systems of nutrient arteries for the cerebrum, as demonstrated by Duret[1] and Heubner[2] simultaneously. These are—(1) those arising from the circle of Willis and about an inch beyond it (the vessels arising within the dotted line in Fig. 375), which supply the series of great ganglia at the base of the brain, and are known as the *central* or *ganglionic arterial system;* and (2) the branches distributed to the gray cortex of the cerebrum and the white medulla under it, which are called the *cortical arterial system.*

These two systems, although they have a common origin from the same main trunks, are perfectly independent of each other, having no peripheral communication whatever. Their final branches are "terminal arteries" (Endarterien of Cohnheim), ending independently and without anastomosis. Hence the dangers of vascular obstruction, especially beyond the circle of Willis, as there can be no compensatory collateral circulation established, and local wedge-shaped infarcts must arise. Similar terminal arteries exist in the kidney, spleen, lung, and retina, with similar dangers. This is in

[Fig. 375.

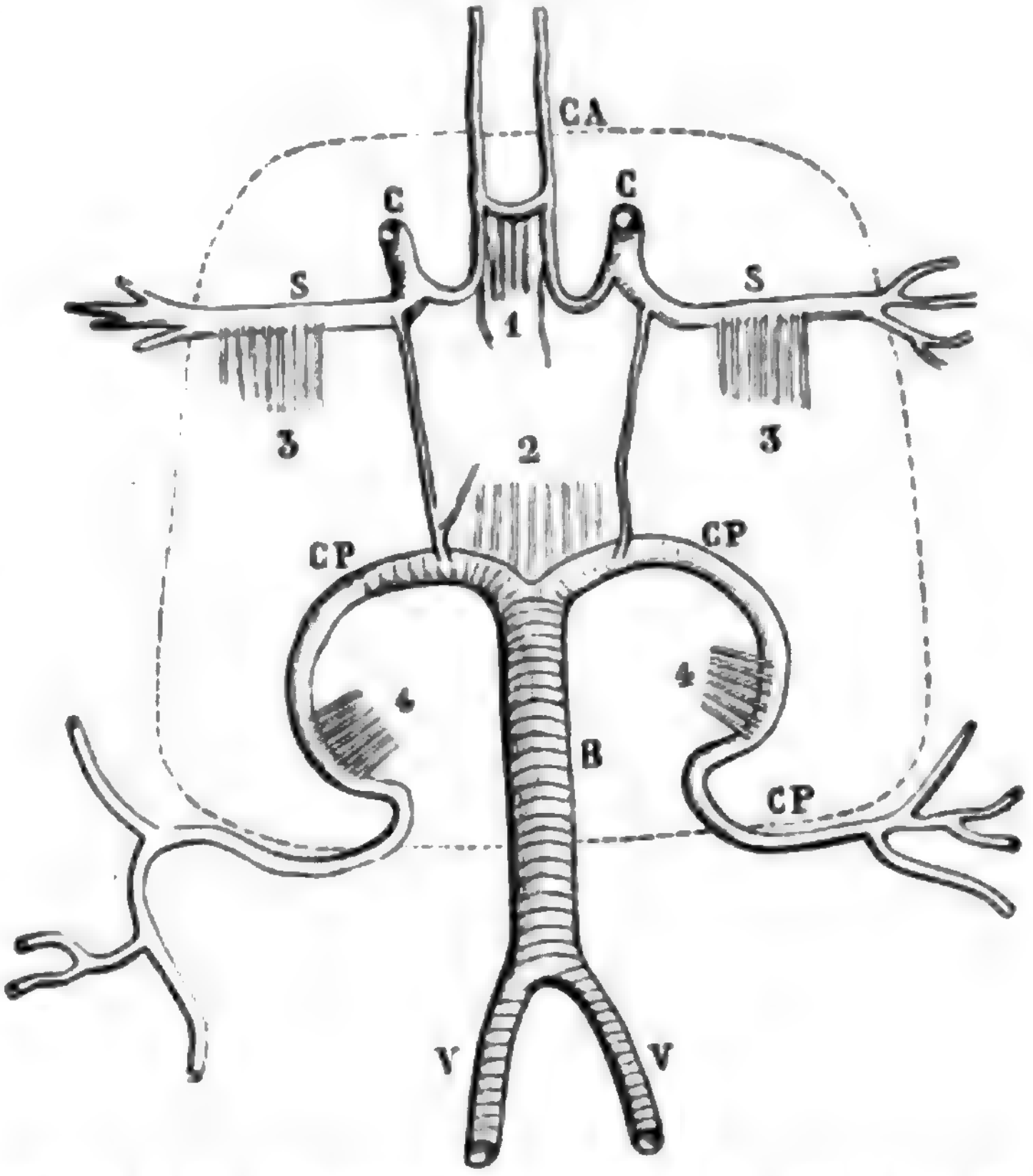

Diagram of the Distribution of the Vessels at the Base of the Cerebrum: CA, anterior cerebral artery; S, S, sylvian arteries; V, V, vertebral arteries; B, basilar; CP, CP, posterior cerebral arteries; 1, 2, 3, 3, 4, 4, groups of nutritive arteries. The line (------) limits the ganglionic vascular area (Charcot).]

[Fig. 376.

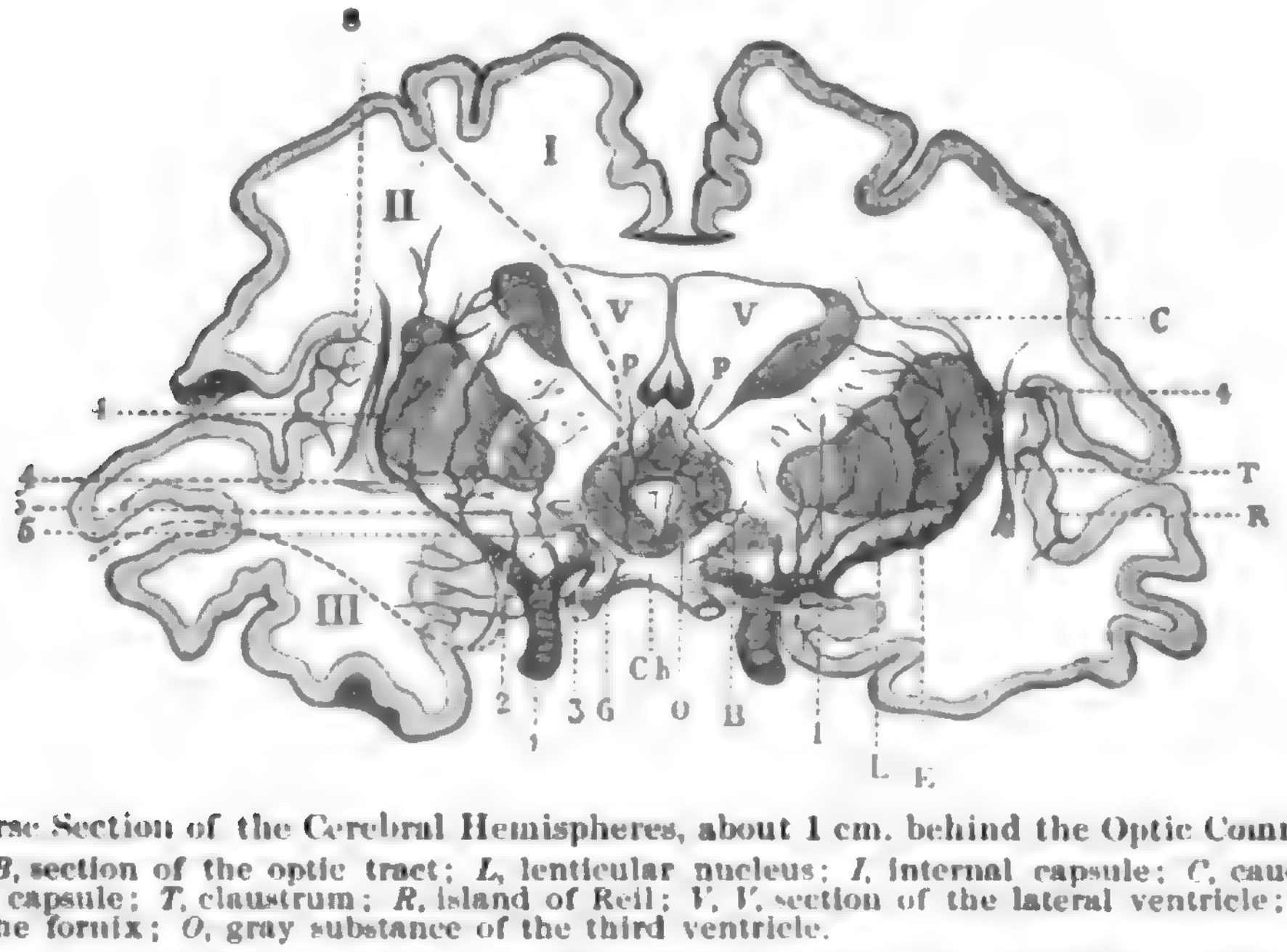

Transverse Section of the Cerebral Hemispheres, about 1 cm. behind the Optic Commissure.

Ch, Chiasma; *B*, section of the optic tract; *L*, lenticular nucleus; *I*, internal capsule; *C*, caudate nucleus; *E*, external capsule; *T*, claustrum; *R*, island of Reil; *V*, *V*, section of the lateral ventricle; *P*, *P*, anterior pillars of the fornix; *O*, gray substance of the third ventricle.

Vascular Areas: I, anterior cerebral artery; II, middle cerebral artery; III, posterior cerebral artery.—1, Internal carotid artery; 2, Sylvian artery; 3, anterior cerebral artery; 4, 4, external arteries of the corpus striatum (lenticulo-striate artery); 5, 5, internal arteries of the corpus striatum (lenticular arteries); 6, arteries of the chiasma; 7, arteries of the commissure and anterior pillars of the fornix; 8, arteries of the convolutions of the insula and claustrum. The opto-striate artery is not represented in the figure (Duret).]

---

[1] *Archives de Physiol. norm. et pathol.*, 1874.

[2] *Centralb. medic. Wissensch.*, 1872.

marked contrast to the cerebral veins, for the veins of the surface and the sinuses at the base have a free anastomosis.

1. The Ganglionic Arterial System.—The nutrient arteries of this system arise in four principal groups (Fig. 375): 1, The antero-median group, from the anterior communicating and anterior cerebrals, penetrating the lamina cinerea and supplying the head of the caudate nucleus. 2, The postero-median group, from the posterior communicating and posterior cerebrals, passing through the posterior perforated space and supplying the walls of the third ventricle. 3, 3, The antero-lateral group on each side, from the middle cerebral or Sylvian artery, penetrating the anterior perforated space and supplying the corpora striata and anterior part of the optic thalamus. This is the most important group. They are the most frequent seat of cerebral hemorrhage, especially one branch, the lenticulo-striate, which penetrates the third segment of the lenticular nucleus and extends to the caudate nucleus (Fig. 376, 4), and which, from the frequency with which hemorrhage occurs from it, Charcot calls "the artery of cerebral hemorrhage." 4, 4, The postero-lateral group, from the posterior cerebrals of each side, after they have wound round the crura cere-

[Fig. 377.

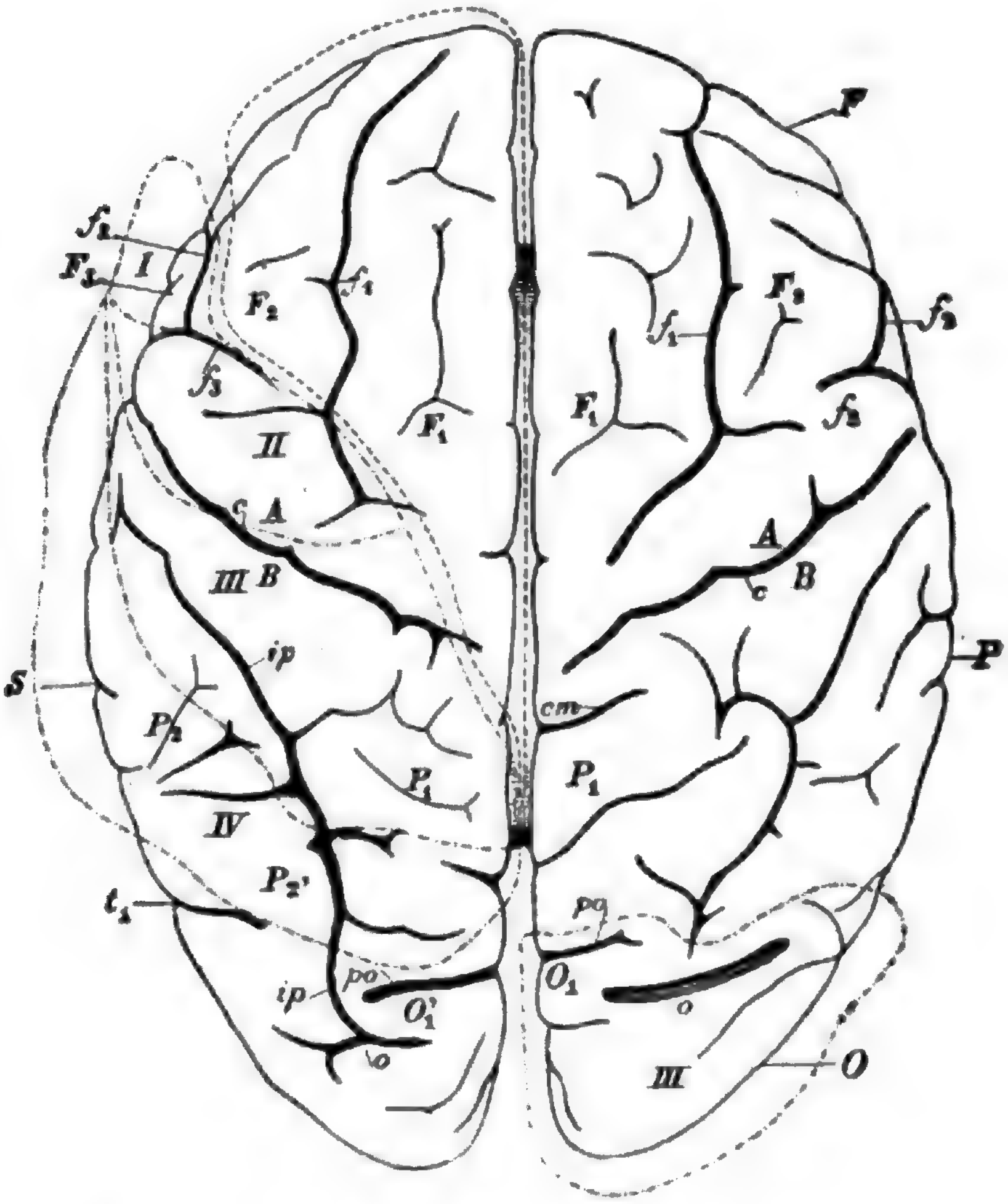

Vascular Areas of the Upper Surface of the Cerebrum.

F, frontal lobe; P, parietal lobe; O, occipital lobe; *s*, end of the horizontal ramus of the fissure of Sylvius; *c*, central sulcus (fissure of Rolando); A, anterior central (ascending frontal) convolution; B, posterior central (ascending parietal) convolution; F_1, F_2, F_3, superior, middle, and inferior frontal convolutions; f_1, f_2, superior and inferior frontal sulci; f_3, vertical or transverse frontal fissure (sulcus praecentralis); P_1, superior temporal lobule; P_2, inferior temporal lobule, or gyrus supra-marginalis; P_2', gyrus angularis; *ip*, intra-parietal fissure; *cm*, calloso-marginal fissure; *po*, *po*, parieto-occipital fissures; t_1, superior temporal fissure; O_1, first occipital convolution; *o*, transverse occipital sulcus.

Arteries: The line (................) marks the limits of the distribution of the anterior cerebral; the line (—·—·—·—·—·) on the left side of the figure limits the distribution of the Sylvian artery; I, external and inferior frontal artery; II, anterior parietal artery; III, posterior parietal artery; IV, parieto-sphenoidal artery. The line (—·—·—·—·) on the right side of the figure limits the distribution of the posterior cerebral (Duret.)]

bri, supplying the outer and posterior parts of the optic thalami and the corpora quadrigemina and part of the crura cerebri.

2. **The Cortical Arterial System.**—The three cerebral arteries (anterior, middle, and posterior) supply each its own region, the middle or Sylvian artery being the most important. They run from the base of the brain to the sides and top, ramifying in the pia mater, and finally supply the gray cortex and underlying white matter.

The **anterior cerebral** arises from the internal carotid. It runs forward and then upward around the anterior extremity of the corpus callosum in the great longitudinal fissure. To see it well the two hemispheres of the cerebrum must be well separated. It has three main sets of branches (Figs. 377 and 378)—the first, the anterior and internal frontal, supplying the second and third frontal convolutions on their under and inner surfaces; the second, the middle and internal frontal, supplying the gyrus fornicatus, corpus callosum, first frontal convolution, the paracentral lobule, the upper surface of the frontal lobe, and the upper part of the ascending frontal convolution; and the third, supplying the lobus quadratus.

[Fig. 378.

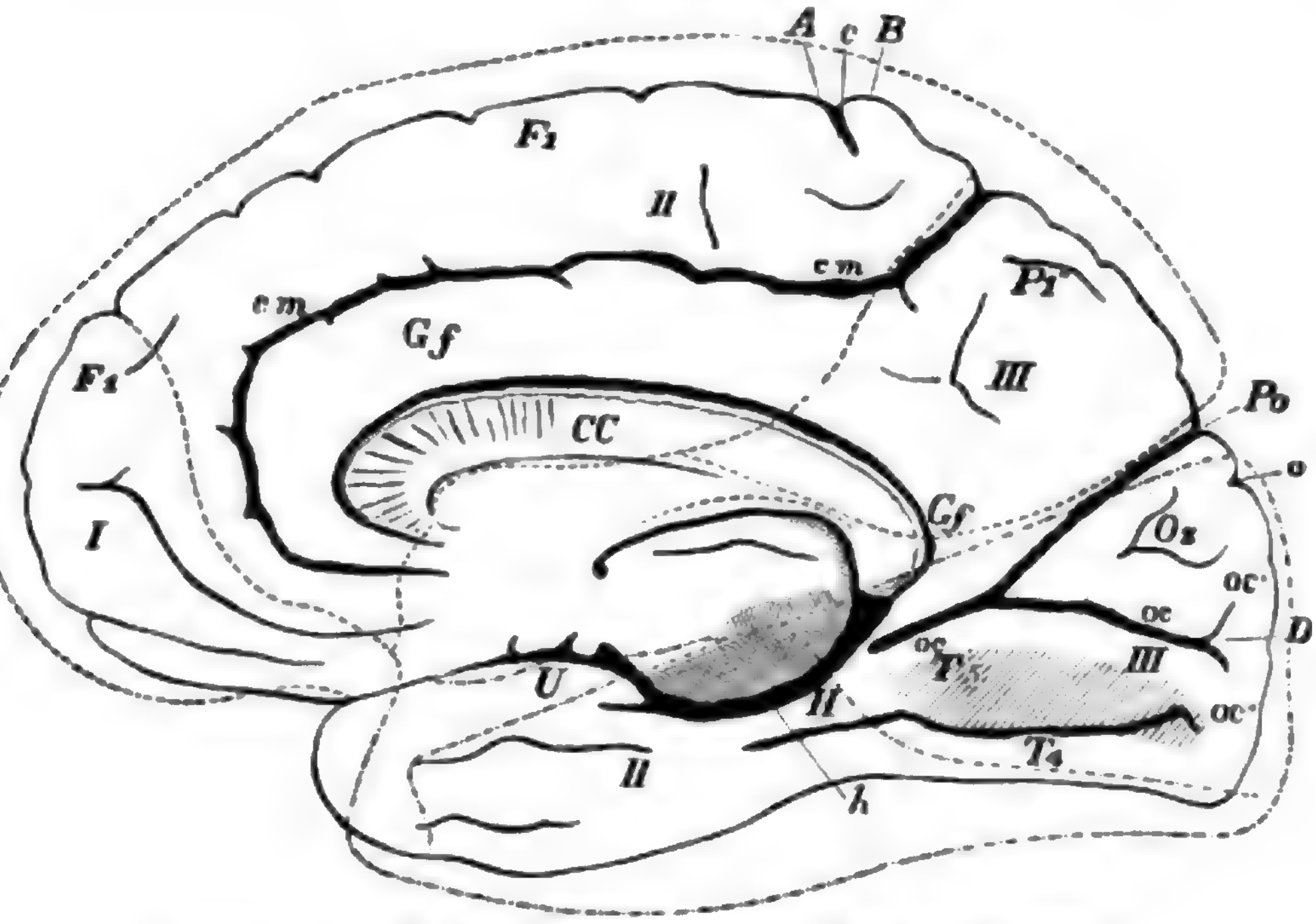

Inner Surface of Right Hemisphere (after Ecker and Duret).

Distribution of Vessels.

The regions bounded by the line (------) represents the territories over which the branches of the Anterior Cerebral Artery are distributed.
I. Is the territory of the Interior and Anterior Frontal Artery.
II. " " Internal and Middle " "
III. " " Internal and Posterior " "

The regions bounded by the line (—·—·—·—·—) represent the territories over which the branches of the Posterior Cerebral Artery are distributed.
II. Is the territory of the Posterior Temporal Artery.
III. " " Occipital Artery.

Fissures and Convolutions.

CC, corpus callosum, longitudinally divided; *Gf*, gyrus fornicatus; H, gyrus hippocampi; *h*, sulcus hippocampi; U, uncinate gyrus; *cm*, sulcus calloso-marginalis; F_1, median aspect of the first frontal convolution; c, terminal portion of the sulcus centralis, or fissure of Rolando; A, ascending frontal; B, ascending parietal convolution; P_1'', precuneus; *oz*, cuneus; *po*, parieto-occipital fissure; *o*, sulcus occipitalis transversus; *oc*, calcarine fissure; *oc'*, superior, *oc''*, inferior ramus of the same; D, gyrus descendens; T_4, gyrus occipito-temporalis lateralis (lobulis fusiformis); T_5, gyrus occipito-temporalis medialis (lobulus lingualis); *ot*, collateral or occipito-temporal fissure.]

The **middle cerebral** or Sylvian artery arises also from the internal carotid, and is indeed its direct continuation. It is by far the largest and most important of the cerebral arteries. The edges of the fissure of Sylvius in which it runs must be separated to expose it well. A large number of smaller branches are first given off (Fig. 380, *P*, and Fig. 375, 3) in the anterior perforated space, which pass at once into the corpus striatum and anterior part of the optic thalamus. These belong to the ganglionic system of vessels supplying the ganglia at the base of the brain (p. 536). One of them, the lenticulo-striate artery, has already been especially referred to as the frequent source of cerebral hemorrhage. Opposite the island of Reil (or Insula) the Sylvian artery divides into four principal branches, which belong to the cortical system. They run outward and upward and supply the sides and top of the cerebrum. The first, the inferior frontal (Fig. 380, 1), or the artery of Broca's convolution, supplies the third frontal convolution, and if obstructed (on the left side especially) produces local softening of this convolution and aphasia, or, as it is often called, "Broca's disease." The second (Fig. 380, 2) is the artery of the ascending frontal convolution. The third (Fig. 380, 3) is the artery of the ascending parietal convolution, and also supplies the precuneus. These two arteries run in front of and behind the fissure of Rolando, and supply the chief motor regions of the brain. The fourth (Fig. 380, 4, 5) supplies the supramarginal, angular, and first temporal convolutions.

[Fig. 379.

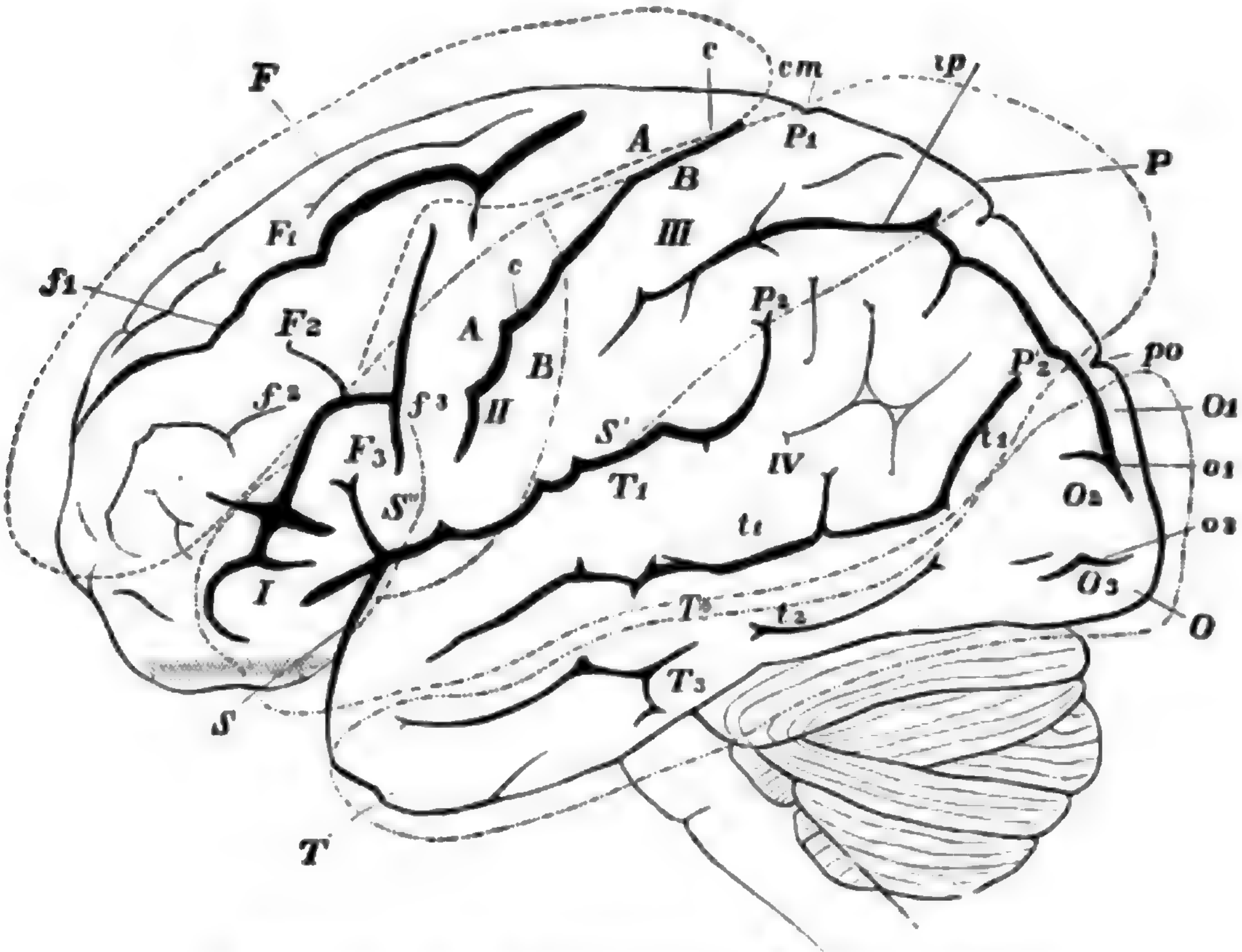

Outer Surface of the Left Hemisphere (after Ecker and Duret).

Distribution of Vessels.

The region bounded by the line (- - - - - -) represents the territory over which branches of the Anterior Cerebral Artery are distributed.

The anterior regions bounded by the line (— - — - — - — - —) represent the territories over which branches of the Middle Cerebral Artery are distributed.

I. Is the region of the External and Inferior Frontal Artery.
II. " " Anterior Parietal Artery.
III. " " Posterior Parietal Artery.
IV. " " Parieto-sphenoidal Artery.

The posterior and inferior region bounded by the line (— - - — - - — - - — - - —) represents the territory over which branches of the Posterior Cerebral Artery are distributed.

Fissures and Convolutions.

F, Frontal lobe; P, parietal lobe; O, occipital lobe; T, temporo-sphenoidal lobe; S, fissure of Sylvius, S', horizontal, S'', ascending ramus of the same; *c*, sulcus centralis or fissure of Rolando; A, anterior central or ascending frontal convolution; B, posterior central or ascending parietal convolution; F_1, superior, F_2, middle, and F_3, inferior frontal convolutions; f_1, superior, and f_2, inferior frontal sulcus; f_3, sulcus præcentralis; P_1, superior parietal or postero-parietal lobule; P_2, inferior parietal lobule, viz.: P_2, gyrus supra-marginalis; P_2', gyrus angularis; *ip*, sulcus intra-parietalis; *cm*, termination of the calloso-marginal fissure; O_1, first, O_2, second, O_3, third occipital convolutions; *po*, parieto-occipital fissure; o_1, sulcus occipitalis transversus; o_2, sulcus occipitalis longitudinalis inferior; T_1, first, T_2, second, T_3, third temporo-sphenoidal convolutions; t_1, first, t_2, second temporo-sphenoidal fissures.]

The **posterior cerebral** is the terminal branch of the basilar artery. It passes along the under surface of the occipital iobes of the cerebrum. It first gives off a number of small branches which pass into the posterior perforated space (Fig. 375, 2), and after winding round the crura cerebri another set of small vessels (Fig. 375, 4). Both these sets of vessels belong to the ganglionic system already described. After this it divides into three main branches (Figs. 378 and 381), which belong to the cortical system of vessels—the first, the uncinate (or anterior temporal), distributed to the gyrus uncinatus, the second to the temporo-sphenoidal lobe, and the third to the lingual lobule, the cuneus, and the occipital lobe.

The *nutrient branches* from the arteries of the cortical system are distributed as follows: The large trunks do not divide into smaller, and these again farther on into still smaller, and so on, as in the rest of the body. The brain needs immediate nourishment by small arteries even where the main large trunks run. Hence even the largest trunks give rise directly to very minute arteries, as well as to branches, which themselves quickly give rise to other very minute branches (Fig. 382).

[Fig. 380.

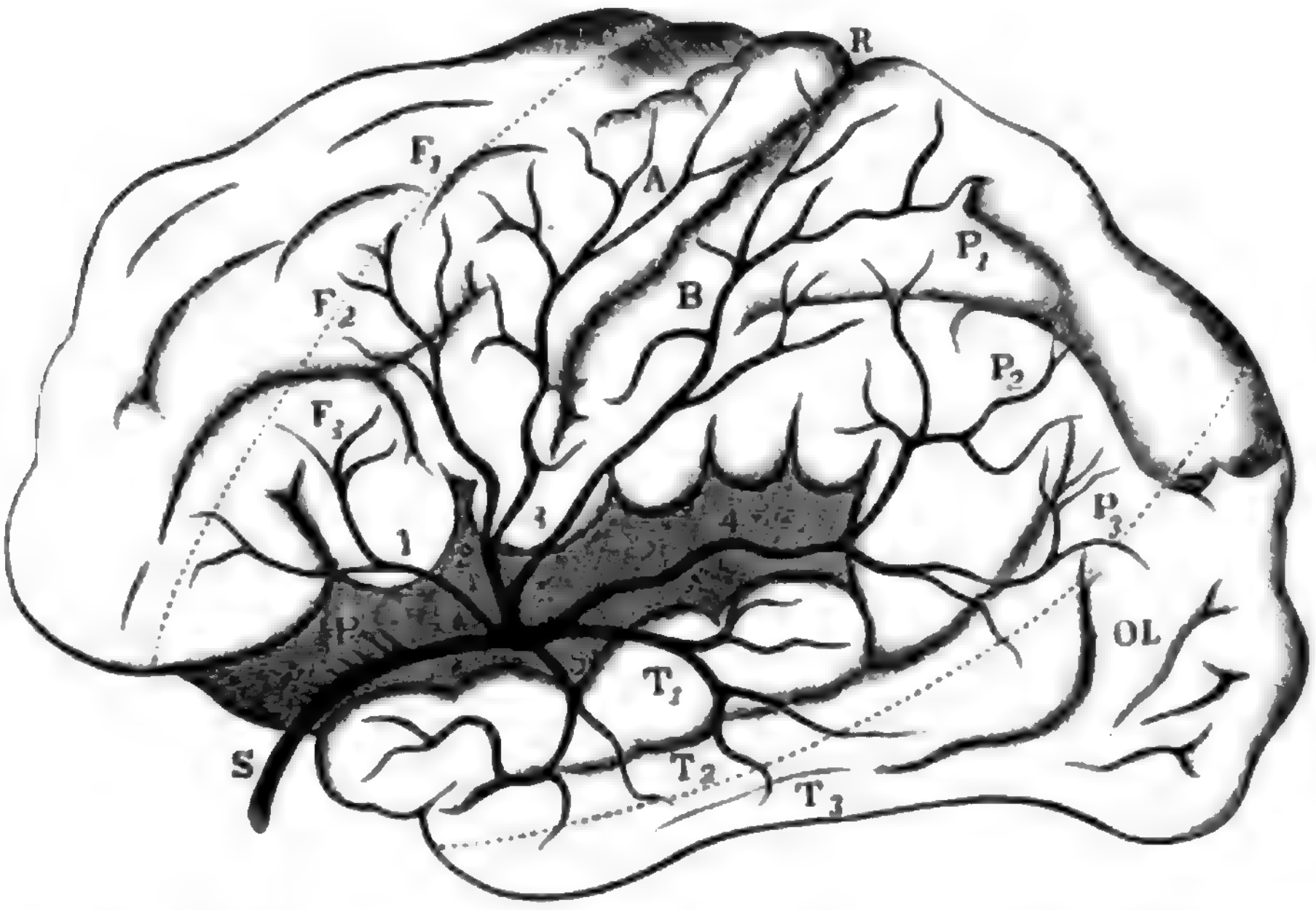

Diagram showing the Area of Distribution of the Middle Cerebral Artery (semi-diagrammatic).

S, Sylvian or middle cerebral artery; P, perforating (ganglionic) branches; 1, inferior frontal branch to Broca's convolution; 2, ascending frontal branch; 3, ascending parietal branch; 4 and 5, parieto-sphenoidal and sphenoidal branches; A, ascending frontal convolution; B, ascending parietal convolution; F_1, F_2, F_3, first, second, and third frontal convolutions; P_1, P_2, P_3, first, second, and third parietal convolutions; T_1, T_2, T_3, first, second, and third temporo-sphenoidal convolutions; OL, occipital lobe; R, fissure of Rolando (Charcot).]

Some of these minute arteries, the larger and longer ones, pass through the gray layer to the white medullary matter of the brain, penetrating the centrum ovale to the depth of about one to two inches, and are therefore known as the *medullary branches* (Fig. 383, 1). The arteries on the summit of a convolution, as they pass through the gray matter on their way to the white, are vertical; those on the sides, oblique; those at the bottom, again, nearly vertical. The capillaries in the white medullary matter are in general vertical, and are excellent illustrations of "terminal arteries." At their termination the descending branches of this, the cortical, system approach the ascending branches of the central or ganglionic system from the base of the brain, but the two systems do not anastomose. Between the two sets of vessels there is, as it were, a poorly-nourished neutral zone, in which lacunar softenings therefore often occur in old age, when the nutrition of the brain is impaired.

The other, shorter branches, go entirely to the thin gray layer on the cortex of the cerebrum, and are known as the *cortical branches* (Fig. 383, 2). They form meshes which supply the middle zone of the gray cortex very richly with blood (Fig. 383), but the inner and outer layers much less abundantly.

The fact that all these cerebral arteries and branches are so independent of each other as "terminal arteries" explains many cases of localized lesions[1] which are especially apt to arise from obstruction to the blood-current by emboli followed by necrosis of that part of the cerebrum supplied by the obstructed vessel. This may readily be limited to one convolution or a group of convolutions, in which is located a special function, the abolition of which can be readily recognized during life. This is especially true of the Sylvian artery and its branches, for it supplies the region in which lie the motor centres (see Cerebral Localization and Topography, p. 681) and the faculty of speech (left third frontal or Broca's convolution).

[FIG. 381.

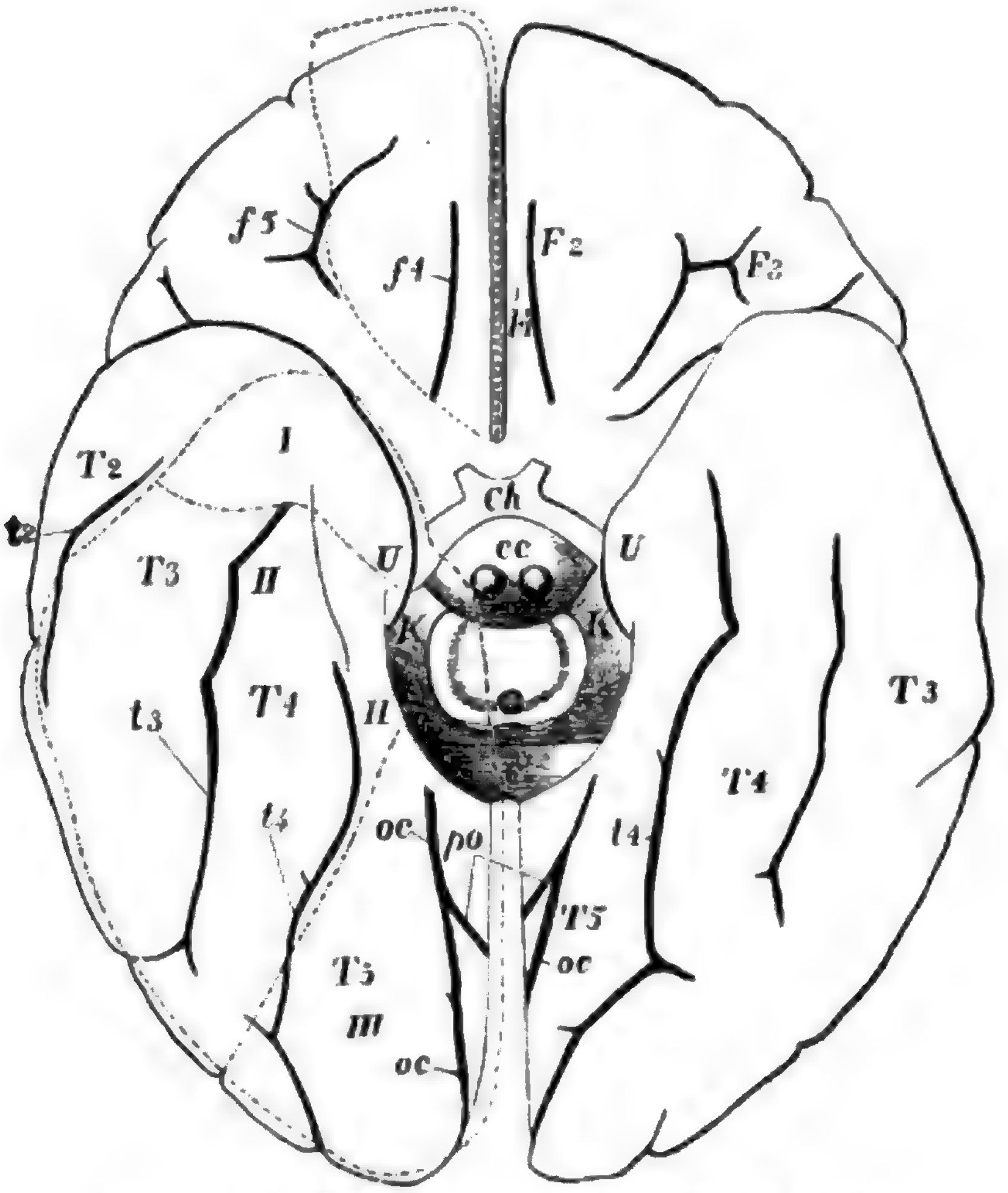

View of the Brain from below (after Ecker and Duret).

Distribution of Vessels.

The region bounded by the line (------) represents the territory over which the Internal and Inferior Fronta. Branches of the Anterior Cerebral Artery are distributed.

The regions bounded by the line (—·—·—·—·—) represent the territories over which the branches of the Posterior Cerebral Artery are distributed.

I. Is the region of the Anterior Temporal Artery.
II. " " Posterior Temporal Artery.
III. " " Occipital Artery.

Fissures and Convolutions: F^1, gyrus rectus; F^2, middle frontal convolution; F^3, inferior frontal convolution; f^4, sulcus olfactorius; f^5, sulcus orbitalis; T^2, second or middle temporo-sphenoidal convolution; T^3, third or inferior temporo-sphenoidal convolution; T^4, gyrus occipito-temporalis lateralis (lobulus fusiformis); T^5, gyrus occipito-temporalis medialis (lobulus lingualis); t^4, sulcus occipito-temporalis inferior; t^3, sulcus temporo-sphenoidalis inferior; t^2, sulcus temporo-sphenoidalis medialis; *po*, parieto-occipital fissure; *oc*, calcarine fissure; *H*, gyrus hippocampi; *U*, gyrus uncinatus; *Ch*, optic chiasma; *cc*, corpora albicantia; *KK*, crura cerebri; *C*, corpus callosum.]

The arteries of the cerebellum are described on p. 549.

The cerebral veins are described later (p. 618).]

---

[1] See Charcot, *Localization of Cerebral and Spinal Diseases*, for some excellent illustrations.

[Fig. 382.

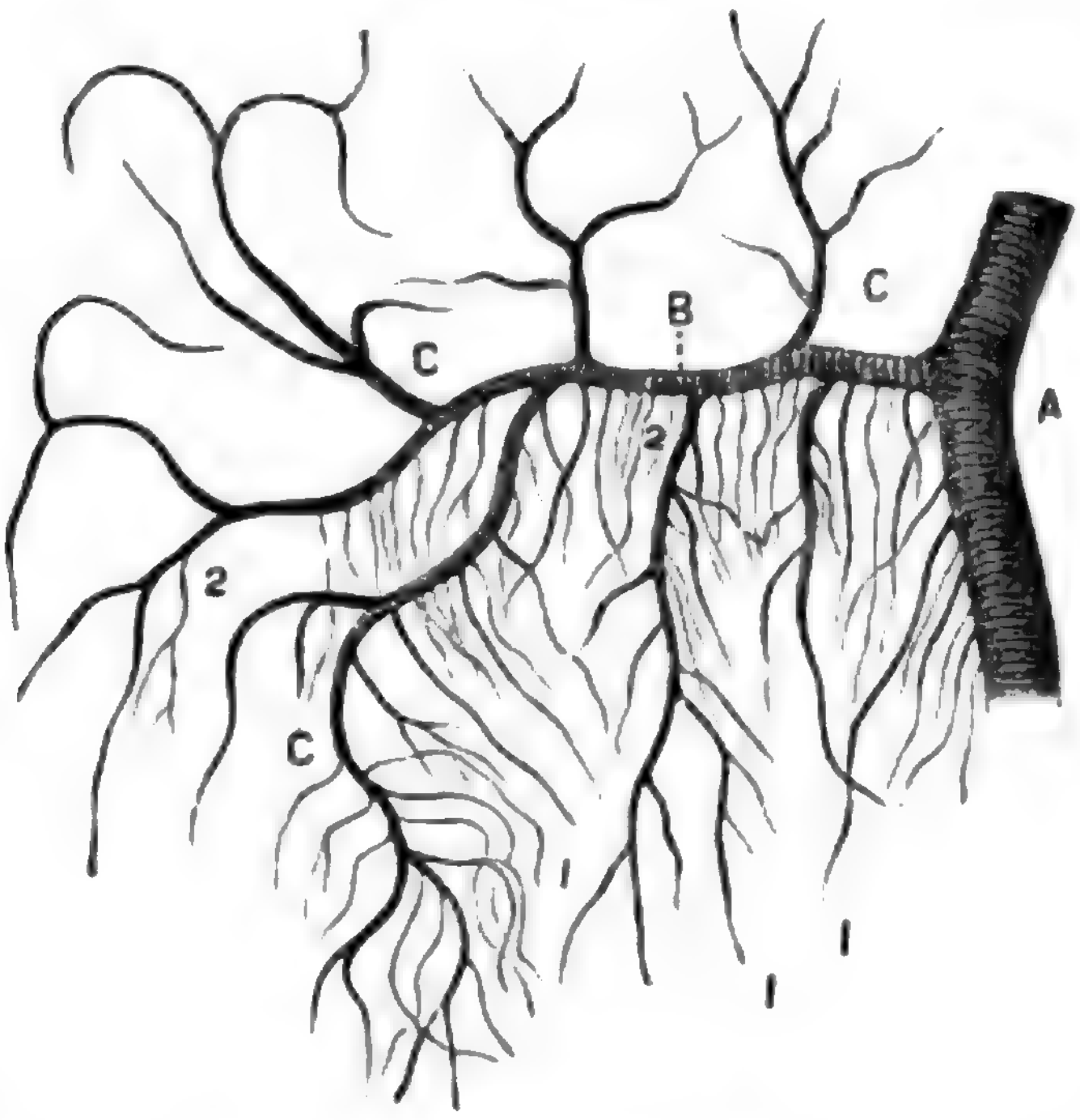

Mode of Division of the Cerebral Arteries: A, principal artery; B, primary branch; C, C, secondary branches; 1, 1, medullary arteries; 2, 2, cortical arteries (Duret).]

[Fig. 383.

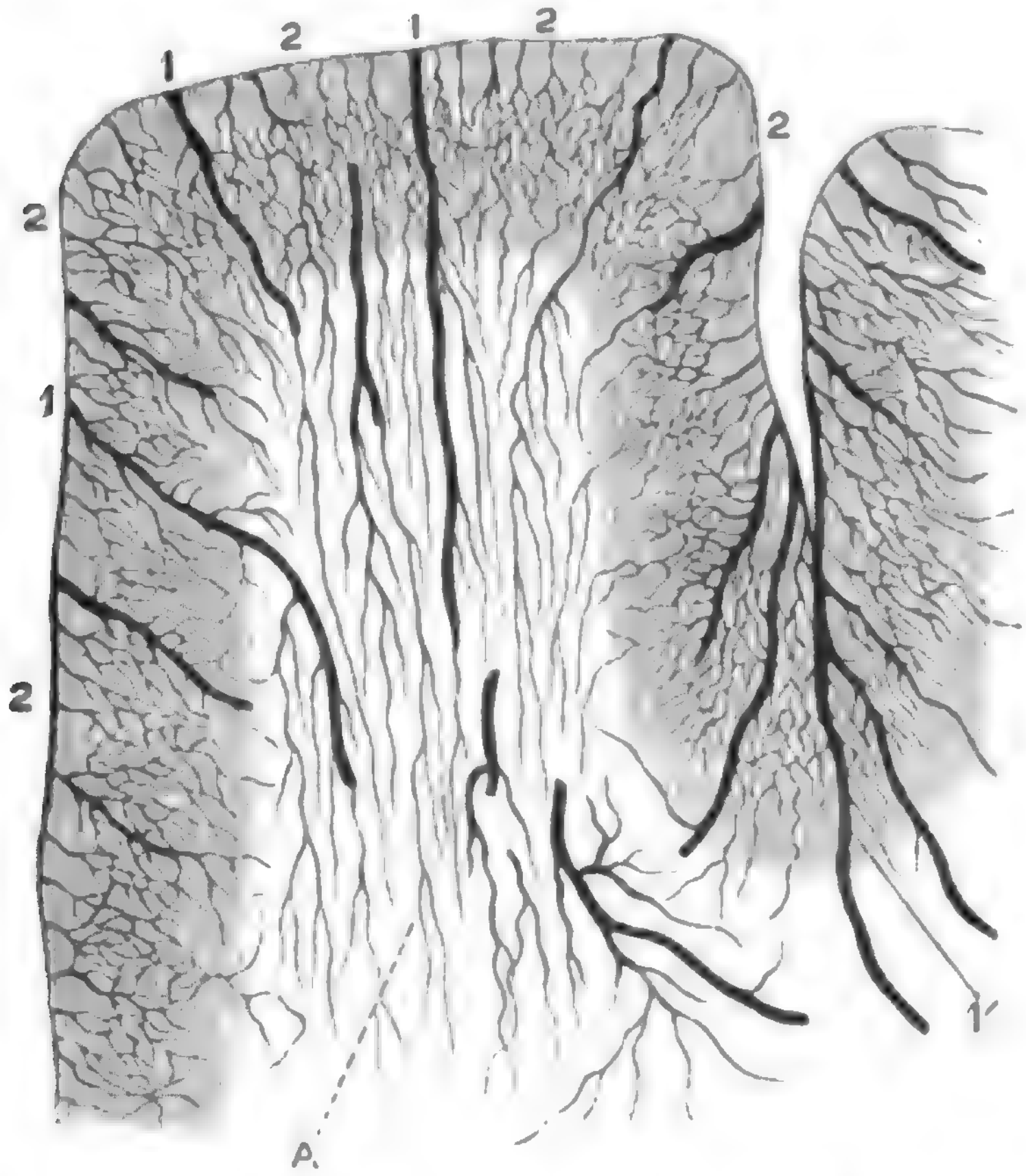

Distribution of Arteries to Gray and White Matter: 1, 1, medullary branches passing directly through the gray matter to the white matter, and then terminating in branches that do not anastomose with their neighbors ("terminal arteries"); 1′, medullary arteries in the sulcus between two convolutions; 2, 2, cortical arteries (Duret).]

ARTERIES OF THE UPPER EXTREMITY.

The artery which supplies the upper extremity continues as a single trunk from its commencement down to the elbow, but different portions of it have received different names, according to the region through which it passes. That part of the vessel which extends from its origin to the lower border of the first rib is termed the subclavian; beyond this point to the lower border of the axilla it is termed the axillary; and from the lower margin of the axillary space to the bend of the elbow it is termed brachial: here the single trunk terminates by dividing into two branches, the radial and ulnar—an arrangement precisely similar to what occurs in the lower limb.

SUBCLAVIAN ARTERIES.

The **Subclavian Artery** on the right side arises from the arteria innominata opposite the right sterno-clavicular articulation; on the left side it arises from the arch of the aorta. It follows, therefore, that these two vessels must, in the first part of their course, differ in their length, their direction, and their relation with neighboring parts.

In order to facilitate the description of these vessels, more especially in a surgical point of view, each subclavian artery has been divided into three parts. The first portion, on the right side, ascends obliquely outward from the origin of the vessel to the inner border of the Scalenus anticus; on the left side it ascends vertically to gain the inner border of that muscle; the second part passes outward behind the Scalenus anticus; and the third part passes from the outer margin of that muscle, beneath the clavicle, to the lower border of the first rib, where it becomes the axillary artery. The first portions of these two vessels differ so much in their course and in their relation with neighboring parts that they will be described separately. The second and third parts are precisely alike on both sides.

FIRST PART OF THE RIGHT SUBCLAVIAN ARTERY (Figs. 364, 366, pp. 503, 513).

The **Right Subclavian Artery** arises from the arteria innominata, opposite the right sterno-clavicular articulation, passes upward and outward across the root of the neck, and terminates at the inner margin of the Scalenus anticus muscle. In this part of its course it ascends a little above the clavicle, the extent to which it does so varying in different cases. It is covered *in front* by the integument, superficial fascia, Platysma, deep fascia, the clavicular origin of the Sterno-mastoid, the Sterno-hyoid, and Sterno-thyroid muscles, and another layer of the deep fascia. It is crossed by the internal jugular and vertebral veins, and by the pneumogastric, the cardiac branches of the sympathetic, and the phrenic nerve. *Beneath*, the artery is invested by the pleura, and *behind*, it is separated by a cellular interval from the Longus colli, the transverse process of the seventh cervical or first dorsal vertebra, and the sympathetic, the recurrent laryngeal nerve winding around the lower and back part of the vessel. The subclavian vein lies below the subclavian artery immediately behind the clavicle.

PLAN OF RELATIONS OF FIRST PORTION OF RIGHT SUBCLAVIAN ARTERY.

In Front.

Clavicular origin of Sterno-mastoid.
Sterno-hyoid and Sterno-thyroid.
Internal jugular and vertebral veins.
Pneumogastric, cardiac, and phrenic nerves.

Right
Subclavian
Artery.
First Portion.

Beneath.
Pleura.

Behind.

Recurrent laryngeal nerve.
Sympathetic.
Longus colli.
Transverse process of seventh cervical or first dorsal vertebra.[1]

---

[1] In five cases recently examined successively the artery was found to lie on the transverse process of the first dorsal.

FIRST PART OF THE LEFT SUBCLAVIAN ARTERY (Fig. 364, p. 503).

The **Left Subclavian Artery** arises from the end of the transverse portion of the arch of the aorta, opposite the fourth dorsal vertebra, and ascends to the inner margin of the first rib, behind the insertion of the Scalenus anticus muscle. This vessel is therefore longer than the right, situated more deeply in the cavity of the chest, and directed almost vertically upward, instead of arching outward like the vessel of the opposite side.

It is in relation *in front* with the pleura, the left lung, the pneumogastric, cardiac, and phrenic nerves, which lie parallel with it, the left carotid artery, left internal jugular and innominate veins, and is covered by the Sterno-thyroid, Sterno-hyoid, and Sterno-mastoid muscles; *behind*, it is in relation with the œsophagus, thoracic duct, inferior cervical ganglion of the sympathetic, Longus colli, and vertebral column. To its *inner side* are the œsophagus, trachea, and thoracic duct; to its *outer side*, the pleura.

PLAN OF RELATIONS OF FIRST PORTION OF LEFT SUBCLAVIAN ARTERY.

In Front.

Pleura and left lung.
Pneumogastric, cardiac, and phrenic nerves.
Left carotid artery.
Left internal jugular and innominate veins.
Sterno-thyroid, Sterno-hyoid, and Sterno-mastoid muscles.

Inner Side.
Trachea.
Œsophagus.
Thoracic duct.

Left
Subclavian
Artery.

Outer Side.
Pleura.

Behind.

Œsophagus and thoracic duct.
Inferior cervical ganglion of sympathetic.
Longus colli and vertebral column.

SECOND AND THIRD PARTS OF THE SUBCLAVIAN ARTERY (Fig. 366, p. 513).

The **Second Portion of the Subclavian Artery** lies behind the Scalenus anticus muscle; it is very short, and forms the highest part of the arch described by that vessel.

RELATIONS.—It is covered *in front* by the integument, Platysma, Sterno-mastoid, cervical fascia, and by the phrenic nerve, which is separated from the artery by the Scalenus anticus muscle; *behind*, it is in relation with the middle Scalenus; *above*, with the brachial plexus of nerves; *below*, with the pleura. The subclavian vein lies below and in front of the artery, separated from it by the Scalenus anticus.

PLAN OF RELATIONS OF SECOND PORTION OF SUBCLAVIAN ARTERY.

In Front.

Scalenus anticus.
Phrenic nerve.
Subclavian vein.

Above.
Brachial plexus.

Subclavian
Artery.
Second
portion.

Below.
Pleura.

Behind.

Pleura and middle Scalenus.

The **Third Portion of the Subclavian Artery** passes downward and outward from the outer margin of the Scalenus anticus to the lower border of the first rib, where it becomes the axillary artery. This portion of the vessel is the most superficial, and is contained in a triangular space the base of which is formed in front by the Sterno-mastoid, and the two sides by the Omo-hyoid above and the clavicle below.

RELATIONS.—It is covered *in front* by the integument, the superficial fascia, the Platysma, deep fascia, and by the clavicle, the Subclavius muscle, and the suprascapular artery and vein; the clavicular descending branches of the cervical plexus and the nerve to the subclavius pass vertically downward in front of the artery. The external jugular vein crosses it at its inner side, and receives the suprascapular and transverse cervical veins, which occasionally form a plexus in front of it. The subclavian vein is below the artery, lying close behind the clavicle. *Behind*, it lies on the middle Scalenus muscle; *above* it and to its outer side is the brachial plexus and Omo-hyoid muscle; *below*, it rests on the outer surface of the first rib.

PLAN OF RELATIONS OF THIRD PORTION OF SUBCLAVIAN ARTERY.

In Front.

Cervical fascia.
External jugular, suprascapular, and transverse cervical veins.
Descending branches of cervical plexus; nerve to Subclavius muscle.
Subclavius muscle, suprascapular artery, and clavicle.

Above.
Brachial plexus.
Omo-hyoid.

Subclavian Artery. Third portion.

Below.
First rib.

Behind.
Scalenus medius.

Peculiarities.—The subclavian arteries vary in their origin, their course, and the height to which they rise in the neck.

The origin of the right subclavian from the innominate takes place, in some cases, above the sterno-clavicular articulation, and occasionally, but less frequently, in the cavity of the thorax below that joint; or the artery may arise as a separate trunk from the arch of the aorta. In such cases it may be either the first, second, third, or even the last, branch derived from that vessel; in the majority of cases it is the first or last, rarely the second or third. When it is the first branch it occupies the ordinary position of the innominate artery; when the second or third, it gains its usual position by passing behind the right carotid; and when the last branch, it arises from the left extremity of the arch at its upper or back part, and passes obliquely toward the right side, usually behind the œsophagus and right carotid, sometimes between the œsophagus and trachea, to the upper border of the first rib, whence it follows its ordinary course. In very rare instances this vessel arises from the thoracic aorta as low down as the fourth dorsal vertebra. Occasionally it perforates the anterior Scalenus; more rarely it passes in front of that muscle; sometimes the subclavian vein passes with the artery behind the Scalenus. The artery sometimes ascends as high as an inch and a half above the clavicle or any intermediate point between this and the upper border of the bone, the right subclavian usually ascending higher than the left.

The left subclavian is occasionally joined at its origin with the left carotid.

Surgical Anatomy.—The relations of the subclavian arteries of the two sides having been examined, the student should direct his attention to a consideration of the best position in which compression of the vessel may be effected, or in what situation a ligature may be best applied in cases of aneurism or wound.

Compression of the subclavian artery is required in cases of operations about the shoulder, in the axilla, or at the upper part of the arm; and the student will observe that there is only one situation in which it can be effectually applied—viz. where the artery passes across the outer surface of the first rib. In order to compress the vessel in this situation the shoulder should be depressed, and the surgeon, grasping the side of the neck, should press with his thumb, in the angle formed by the posterior border of the Sterno-mastoid with the upper border of the clavicle, downward, backward, and inward against the rib; if from any cause the shoulder cannot be sufficiently depressed, pressure may be made from before backward, so as to compress the artery against the middle Scalenus and transverse process of the seventh cervical vertebra. In appropriate cases a preliminary incision may be made through the cervical fascia, and the finger may be pressed down directly upon the artery.

Ligature of the subclavian artery may be required in cases of wounds or of aneurism in the axilla or in cases of aneurism on the cardiac side of the point of ligature; and the third part of the artery is that which is most favorable for an operation, on account of its being comparatively superficial and most remote from the origin of the large branches. In those cases where the clavicle is not displaced this operation may be performed with comparative facility; but where the clavicle is pushed up by a large aneurismal tumor in the axilla the artery is placed at a great depth from the surface, which materially increases the difficulty of the operation. Under these circumstances it becomes a matter of importance to consider the height to which this vessel reaches above the bone. In ordinary cases its arch is about half an inch above the clavicle, occasionally as high as an inch and a half, and sometimes so low as to be on a level with its upper border. If the clavicle is displaced, these variations will necessarily make the operation more or less difficult according as the vessel is more or less accessible.

The chief points in the operation of tying the third portion of the subclavian artery are as follows: The patient being placed on a table in the horizontal position and the shoulder depressed as much as possible, the integument should be drawn downward upon the clavicle, and an incision made through it upon that bone from the anterior border of the Trapezius to the posterior border of the Sterno-mastoid, to which may be added a short vertical incision meeting the preceding in its centre. The object in drawing the skin downward is to avoid any risk of wounding the external jugular vein, for as it perforates the deep fascia above the clavicle it cannot be drawn downward with the skin. The Platysma and the cervical fascia should be divided upon a director, and if the interval between the Trapezius and Sterno-mastoid muscles be insufficient for the performance of the operation, a portion of one or both may be divided. The external jugular vein will now be seen toward the inner side of the wound: this and the suprascapular and transverse cervical veins which terminate in it should be held aside. If the external jugular vein is at all in the way and exposed to injury, it should be tied in two places and divided. The suprascapular artery should be avoided, and the Omo-hyoid muscle must now be looked for and held aside if necessary. In the space beneath this muscle careful search must be made for the vessel: the deep fascia having been divided with the finger-nail or silver scalpel, the outer margin of the Scalenus anticus muscle must be felt for, and, the finger being guided by it to the first rib, the pulsation of the subclavian artery will be felt as it passes over the rib. The aneurism-needle may then be passed around the vessel from above downward and inward, so as to avoid including any of the branches of the brachial plexus. If the clavicle is so raised by the tumor that the application of the ligature cannot be effected in this situation, the artery may be tied above the first rib, or even behind the Scalenus muscle; the difficulties of the operation in such a case will be materially increased on account of the greater depth of the artery and the alteration in position of the surrounding parts.

The second part of the subclavian artery, from being that portion which rises highest in the neck, has been considered favorable for the application of the ligature when it is difficult to tie the artery in the third part of its course. There are, however, many objections to the operation in this situation. It is necessary to divide the Scalenus anticus muscle, upon which lies the phrenic nerve, and at the inner side of which is situated the internal jugular vein, and a wound of either of these structures might lead to the most dangerous consequences. Again, the artery is in contact below with the pleura, which must also be avoided; and lastly, the proximity of so many of its larger branches arising internal to this point must be a still further objection to the operation. In cases, however, where the sac of an axillary aneurism encroaches on the neck it may be necessary to divide the outer half or two-thirds of the anterior Scalenus muscle, so as to place the ligature on the vessel at a greater distance from the sac. The operation is performed exactly in the same way as ligature of the third portion until the Scalenus anticus is exposed, when it is to be divided on a director (never to a greater extent than its outer two-thirds), and it immediately retracts. The operation is therefore merely an extension of ligature of the third portion of the vessel.

In those cases of aneurism of the axillary or subclavian artery which encroach upon the outer portion of the Scalenus muscle to such an extent that a ligature cannot be applied in that situation, it may be deemed advisable, as a last resource, to tie the first portion of the subclavian artery. On the left side this operation is almost impracticable; the great depth of the artery from the surface, its intimate relation with the pleura, and its close proximity to the thoracic duct and to so many important veins and nerves, present a series of difficulties which it is next to impossible to overcome.[1] On the right side the operation is practicable, and has been performed, though never with success. The main objection to the operation in this situation is the smallness of the interval which usually exists between the commencement of the vessel and the origin of the nearest branch. This operation may be performed in the following manner: The patient being placed on the table in the horizontal position with the neck extended, an incision should be made parallel with the posterior border of the inner part of the clavicle, and a second along the inner border of the Sterno-mastoid, meeting the former at an angle. The sternal attachment of the Sterno-mastoid may now be divided on a director and turned outward; a few small arteries and veins, and occasionally the anterior jugular, must be avoided, and the Sterno-hyoid and Sterno-thyroid muscles divided in the same manner as the preceding muscle. After tearing through the deep fascia with the finger-nail, the internal jugular vein will be seen crossing the subclavian artery: this should be pressed aside and the artery secured by passing the needle from below upward, by which the pleura is more effectually avoided. The exact position of the vagus nerve, the recurrent laryngeal, the phrenic and sympathetic nerves should be remembered, and the ligature should be applied near the origin of the vertebral, in order to afford as much room as possible for the formation of a coagulum between the ligature and the origin of the vessel. It should be remembered that the right subclavian artery is occasionally deeply placed in the first part of its course, when it arises from the left side of the aortic arch, and passes in such cases behind the œsophagus or between it and the trachea.

---

[1] The operation was, however, performed in New York by Dr. J. K. Rodgers, and the case is related in *A System of Surgery*, edited by T. Holmes, 2d ed. vol. iii. pp. 620, etc.

Collateral Circulation.—After ligature of the third part of the subclavian artery the collateral circulation is mainly established by three sets of vessels, thus described in a dissection:

"1. A posterior set, consisting of the suprascapular and posterior scapular branches of the subclavian, which anastomosed with the median branch from the subscapular from the axillary.

"2. An internal set, produced by the connection of the internal mammary on the one hand with the short and long thoracic arteries and the median branch from the subscapular on the other.

"A middle or axillary set, which consisted of a number of small vessels derived from branches of the subclavian above, and passing through the axilla, to terminate either in the main trunk or some of the branches of the axillary below. This last set presented most conspicuously the peculiar character of newly-formed—or, rather, dilated—arteries, being excessively tortuous and forming a complete plexus.

"The chief agent in the restoration of the axillary artery below the tumor was the subscapular artery, which communicated most freely with the internal mammary, suprascapular, and posterior scapular branches of the subclavian, from all of which it received so great an influx of blood as to dilate it to three times its natural size."[1]

BRANCHES OF THE SUBCLAVIAN ARTERY.

These are four in number: three arising from the first portion of the vessel, the *vertebral*, the *internal mammary*, and the *thyroid axis*, and one from the second portion, the *superior intercostal*. The vertebral arises from the upper and back part of the first portion of the artery; the thyroid axis, from the front; and the internal mammary, from the under part of this vessel. The superior intercostal is given off from the upper and back part of the second portion of the artery. On the left side the second portion usually gives off no branch, the superior intercostal arising from the first portion of the vessel. On both sides of the body the first three branches arise close together at the inner margin of the Scalenus anticus, in the majority of cases a free interval of half an inch to an inch existing between the commencement of the artery and the origin of the nearest branch; in a smaller number of cases an interval of more than an inch exists, never exceeding an inch and three-quarters. In a very few instances the interval had been found to be less than half an inch.

FIG. 384.

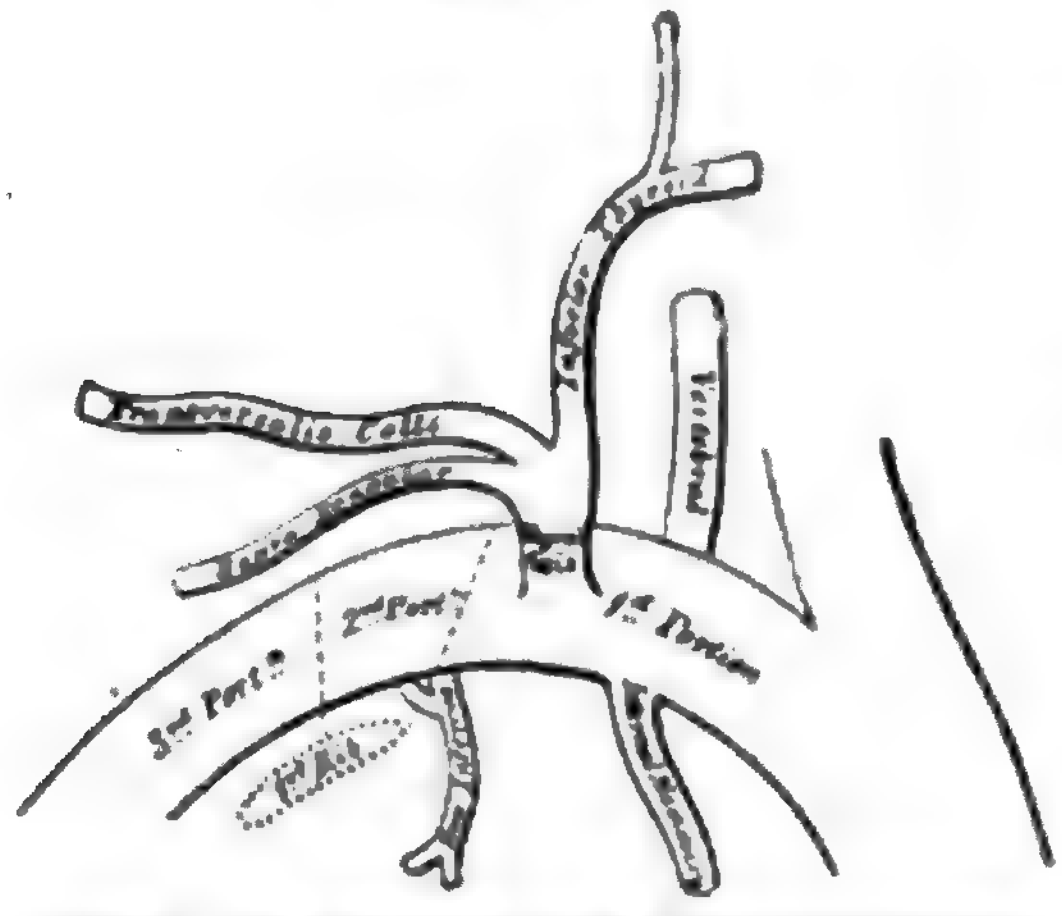

Plan of the Branches of the Right Subclavian Artery.

The **Vertebral Artery** (Fig. 372, p. 529) is generally the first and largest branch of the subclavian; it arises from the upper and back part of the first portion of the vessel, and, passing upward, enters the foramen in the transverse process of the sixth cervical vertebra,[2] and ascends through the foramina in the transverse processes of all the vertebræ above this. Above the upper border of the axis it inclines outward and upward to the foramen in the transverse process of the atlas, through which it passes; it then winds backward behind its articular process, runs in a deep groove on the upper surface of the posterior arch of this bone, and, piercing the posterior occipito-atloid ligament and dura mater, enters the skull through the foramen magnum. It then passes forward and upward to the front of the medulla oblongata, and unites with the vessel of the opposite side at the lower border of the pons Varolii to form the *basilar* artery.

---

[1] *Guy's Hospital Reports*, vol. i., 1836, case of axillary aneurism, in which Mr. Aston Key had tied the subclavian artery on the outer edge of the Scalenus muscle twelve years previously.

[2] The vertebral artery sometimes enters the foramen in the transverse process of the fifth vertebra. Dr. Smyth, who tied this artery in the living subject, found it, in one of his dissections, passing into the foramen in the seventh vertebra. [Very rarely it may enter the fourth.]

At its origin it is situated behind the internal jugular vein and inferior thyroid artery, and near the spine lies between the Longus colli and Scalenus anticus muscles, having the thoracic duct in front of it on the left side. Within the foramina formed by the transverse processes of the vertebræ it is accompanied by a plexus of nerves from the sympathetic, and lies between the vertebral vein, which is in front, and the cervical nerves, which issue from the intervertebral foramina behind it. Whilst winding round the articular process of the atlas it is contained in a triangular space (*suboccipital triangle*) formed by the Rectus capitis posticus major, the Superior and the Inferior oblique muscles, and at this point is covered by the Complexus muscles. Within the skull, as it winds round the medulla oblongata, it is placed between the hypoglossal nerve and the anterior root of the suboccipital nerve, and finally lies between the dura mater covering the basilar process of the occipital bone and the anterior surface of the medulla oblongata.

Branches.—These may be divided into two sets—those given off in the neck, and those within the cranium.

Cervical Branches.	*Cranial Branches.*
Lateral Spinal.	Posterior Meningeal.
Muscular.	Anterior Spinal.
	Posterior Spinal.
	Posterior Inferior Cerebellar.

The lateral spinal branches enter the spinal canal through the intervertebral foramina, each dividing into two branches. Of these, one passes along the roots of the nerves to supply the spinal cord and its membranes, anastomosing with the other spinal arteries; the other is distributed to the posterior surface of the bodies of the vertebræ.

[Fig. 385.

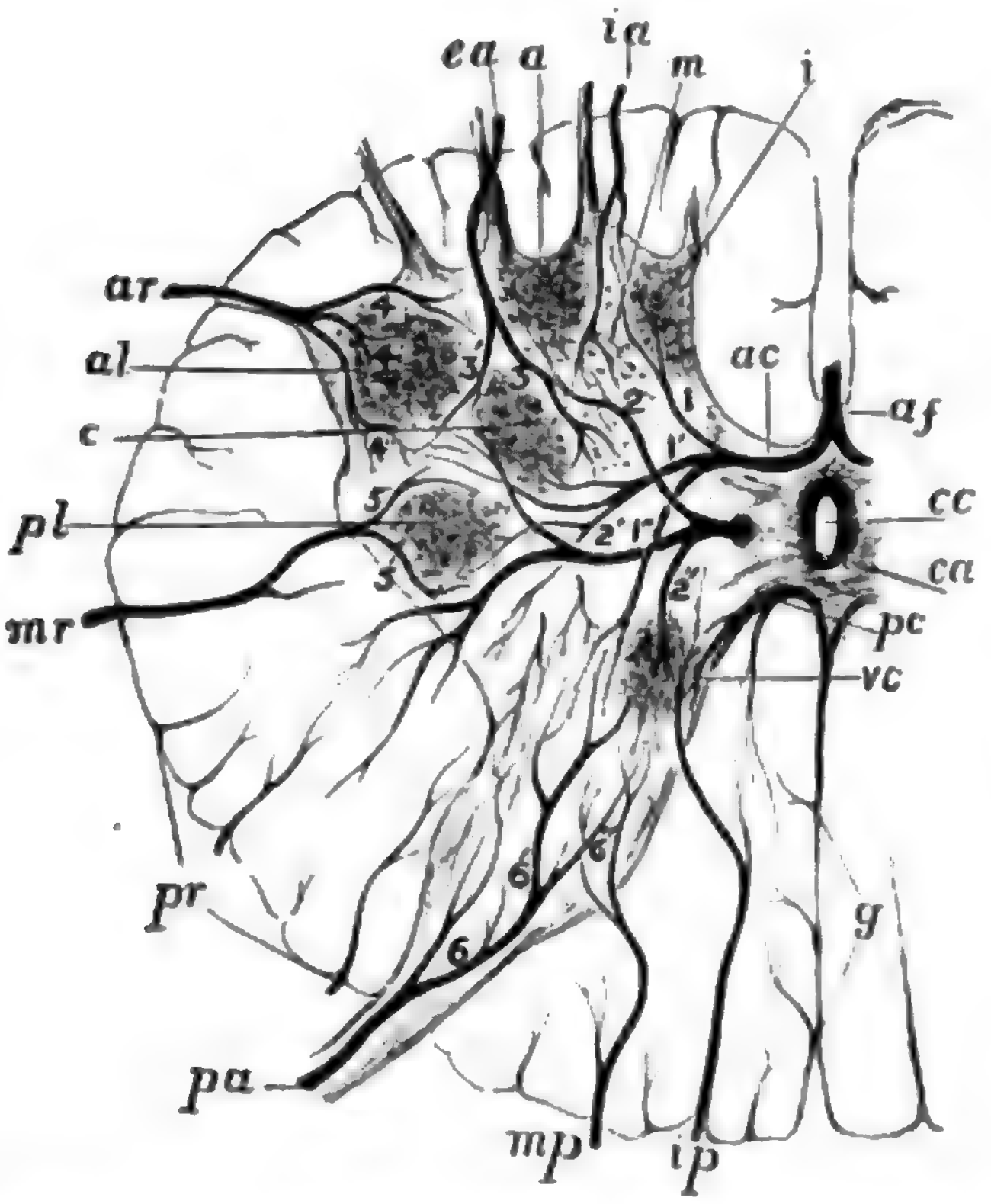

Anterior median artery:

af, Arteries of the anterior median fissure.

ac, Artery of the anterior commissure.

1, 1', 1'', Anterior, median, and posterior branches.

i, Internal group of cells.

m, Median area.

ia, Internal anterior root-artery.

a, Anterior group of cells.

ea, External anterior root-artery.

3, 3', Internal and external branches.

ar, Antero-lateral artery.

4, 4', 4'', Anterior, median, and posterior branches.

al, Antero-lateral group of cells.

c, Central group of cells.

pl, Postero-lateral group of cells.

mr, Median lateral artery.

5, 5', Anterior and posterior branches.

pr, Posterior lateral arteries

pa, Posterior root-arteries.

6, 6', 6', Arteries of posterior horns.

mp, External posterior artery.

ip, Internal posterior artery.

g, Arteries of the column of Goll.

vc, Vesicular column of Clarke.

pc, Artery of the posterior commissure.

ca, Central artery.

2, 2', 2'', Anterior, median, and posterior branches.

cc, Central canal or "ventricle of the cord."

Diagram of the Distribution of the Blood-vessels and grouping of Ganglion-cells in the Spinal Cord (Young).]

Muscular branches are given off to the deep muscles of the neck, where the vertebral artery curves round the articular process of the atlas. They anastomose with the occipital and deep cervical arteries.

The **posterior meningeal** are one or two small branches given off from the vertebral opposite the foramen magnum. They ramify between the bone and dura mater in the cerebellar fossæ and supply the falx cerebelli.

[Fig. 386.

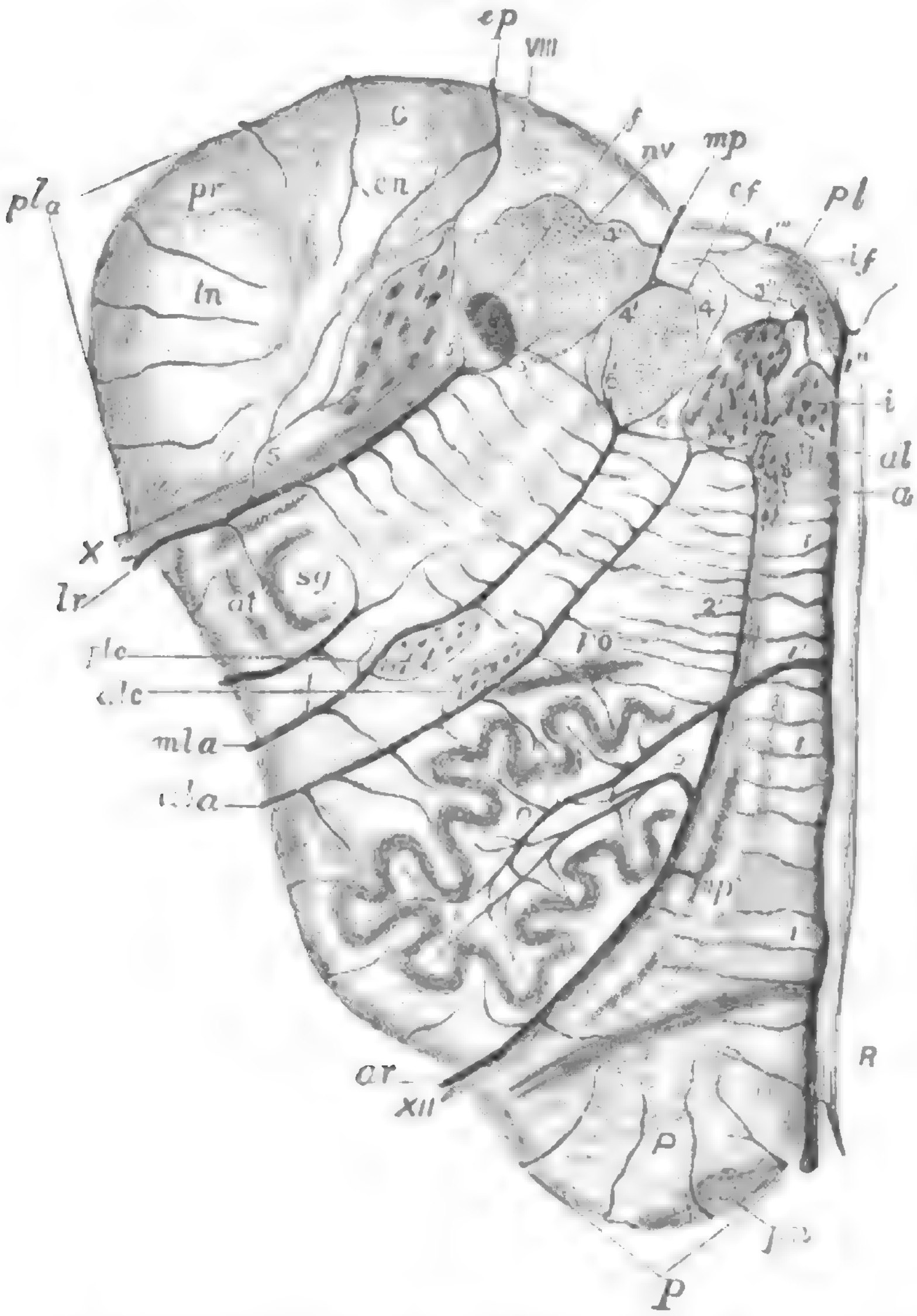

Section of the Medulla Oblongata, showing the Distribution of the Vessels.

a, **Anterior** group of cells of the hypoglossal nucleus.
al, Antero-lateral group of the same.
i, Internal group of the same.
if, Internal accessory facial nuclei.
c, Central artery.
3, 3', 3'', Branches to the hypoglossal and external accessory facial nuclei.
pl, Postero-lateral group of cells of the hypoglossal nucleus.
cf, External accessory facial nucleus.
mp, Median posterior artery.
4, 4', 4'', Branches to the external accessory facial and pneumogastric nuclei.
nv, Nucleus of the vagus.
f, Fasciculus rotundus.
VIII, Inferior portion of the posterior median acoustic nucleus.
ep, External posterior artery.
G, Column of Goll.
cn, Clavate nucleus.
pr, Posterior root-zone. The direct cerebellar tract forms a thin band lying external to the column of Goll and posterior root-zone.
pla, The posterior lateral arteries of the medulla oblongata.
tn, Triangular nucleus.
X, Pneumogastric nerve.
lr, Lateral root-artery (vagus).
5, Branch to the restiform body and the inner division of the inferior cerebellar peduncle.
5', 5'', Branches to the nucleus of the vagus.
at, Ascending root of the trigeminus.
sg, The substantia gelatinosa.
plc, Posterior nucleus of the lateral column.
alc, Anterior " " " "
mla, The middle lateral artery of the medulla oblongata.
ala, Anterior lateral artery of the same.
po, Parolivary body.
O, Olivary body.
ar, Anterior root-artery (hypoglossal).
2', Branch to the olivary body.
2'', Branches to the *formatio reticularis.*
XII, Hypoglossal nerve.
p, Pyramidal arteries.
P, Anterior pyramid.
pn, Nucleus of the arciform fibres.
R, Artery of the median raphé.
1, 1, 1, Branches to the *formatio reticularis.*
1', Branch to the olivary body (O).
1'', Branches to the hypoglossal nucleus.
1''', Branches to the floor of the fourth ventricle and to the internal inferior nuclei of the facial (*if*)
np, Nucleus of the pyramid (Ross).]

The **anterior spinal** is a small branch, larger than the posterior spinal, which arises near the termination of the vertebral, and, descending in front of the medulla oblongata, unites with its fellow of the opposite side at about the level of the foramen magnum. The single trunk thus formed descends a short distance on the front of the spinal cord, and joins with a succession of small branches which enter the spinal canal through some of the intervertebral foramina; these branches are derived from the vertebral and ascending cervical of the inferior thyroid in the neck; from the intercostal in the dorsal region; and from the lumbar, ilio-lumbar, and lateral sacral arteries in the lower part of the spine. They unite, by means of ascending and descending branches, to form a single anterior median artery, which extends as far as the lower part of the spinal cord. This vessel is placed beneath the pia mater along the anterior median fissure; it supplies that membrane and the substance of the cord, and sends off branches at its lower part to be distributed to the cauda equina.

The **posterior spinal** arises from the vertebral at the side of the medulla oblongata; passing backward to the posterior aspect of the spinal cord, it descends on either side, lying behind the posterior roots of the spinal nerves, and is reinforced by a succession of small branches which enter the spinal canal through the intervertebral foramina, and by which it is continued to the lower part of the cord and to the cauda equina. Branches from these vessels form a free anastomosis round the posterior roots of the spinal nerves, and communicate by means of very tortuous transverse branches with the vessel of the opposite side. At its commencement it gives off an ascending branch which terminates on the side of the fourth ventricle.

The **posterior inferior cerebellar artery** (Fig. 374, p. 533), the largest branch of the vertebral, winds backward round the upper part of the medulla oblongata, passing between the origin of the pneumogastric and spinal accessory nerves over the restiform body to the under surface of the cerebellum, where it divides into two branches: an internal one, which is continued backward to the notch between the two hemispheres of the cerebellum; and an external one, which supplies the under surface of the cerebellum as far as its outer border, where it anastomoses with the superior cerebellar. Branches from this artery supply the choroid plexus of the fourth ventricle.

The **Basilar Artery**, so named from its position at the base of the skull, is a single trunk formed by the junction of the two vertebral arteries; it extends from the posterior to the anterior border of the pons Varolii, where it divides into two terminal branches, the *posterior cerebral* arteries. Its branches are, on each side, the following:

Transverse.	Superior Cerebellar.
Anterior Inferior Cerebellar.	Posterior Cerebral.

The **transverse** branches supply the pons Varolii and adjacent parts of the brain; one (*internal auditory*) accompanies the auditory nerve into the internal auditory meatus; and another, of larger size, passes along the crus cerebelli, to be distributed to the anterior border of the under surface of the cerebellum. It is called the *anterior inferior cerebellar artery.*

The **superior cerebellar arteries** arise near the termination of the basilar. They wind round the crus cerebri close to the fourth nerve, and, arriving at the upper surface of the cerebellum, divide into branches which ramify in the pia mater and anastomose with the inferior cerebellar. Several branches are given to the pineal gland and also to the velum interpositum.

The **posterior cerebral arteries**, the two terminal branches of the basilar, are larger than the preceding, from which they are separated near their origin by the third nerve. Winding round the crus cerebri, they pass to the under surface of the posterior lobes of the cerebrum, which they supply, anastomosing with the anterior and middle cerebral arteries. Near their origin they receive the posterior communicating arteries from the internal carotid, and give off numerous branches which enter the posterior perforated space: they also give off a branch, the *posterior cho-*

roid, which supplies the velum interpositum and choroid plexus, entering the interior of the brain beneath the posterior border of the corpus callosum.

Circle of Willis.—The remarkable anastomosis which exists between the branches of the internal carotid and vertebral arteries at the base of the brain constitutes the *circle of Willis*. It is formed in front by the anterior cerebral arteries, branches of the internal carotid, which are connected together by the anterior communicating: behind, by the two posterior cerebrals, branches of the basilar, which are connected to the internal carotid by the posterior communicating (Fig. 372, p. 529). It is by this anastomosis that the cerebral circulation is equalized and provision made for effectually carrying it on if one or more of the branches are obliterated. The parts of the brain included within this arterial circle are—the lamina cinerea, the commissure of the optic nerves, the infundibulum, the tuber cinereum, the corpora albicantia, and the posterior perforated space.

The **Thyroid Axis** (Fig. 364, p. 503) is a short thick trunk which arises from the fore part of the first portion of the subclavian artery, close to the inner border of the Scalenus anticus muscle, and divides, almost immediately after its origin, into three branches—the *inferior thyroid*, *suprascapular*, and *transversalis colli*.

The **Inferior Thyroid Artery** passes upward, in a serpentine course, behind the sheath of the common carotid vessel and sympathetic nerve (the middle cervical ganglion resting upon it), and is distributed to the under surface of the thyroid gland, anastomosing with the superior thyroid and with the corresponding artery of the opposite side. Its branches are the

Laryngeal.
Tracheal.
Œsophageal.
Ascending Cervical.
Muscular.

The **laryngeal** branch (inferior laryngeal) ascends upon the trachea to the back part of the larynx, in company with the recurrent laryngeal nerve, and supplies the muscles and mucous membrane of this part.

The **tracheal** branches are distributed upon the trachea, anastomosing below with the bronchial arteries.

The **œsophageal** branches are distributed to the œsophagus.

The **ascending cervical** is a small branch which arises from the inferior thyroid just where that vessel is passing behind the common carotid artery, and runs up on the anterior tubercles of the transverse processes of the cervical vertebræ in the interval between the Scalenus anticus and Rectus capitis anticus major. It gives branches to the muscles of the neck, which communicate with those sent out from the vertebral, and sends one or two through the intervertebral foramina, along the cervical nerves, to supply the bodies of the vertebræ, the spinal cord, and its membranes. It anastomoses with the ascending pharyngeal artery.

The **muscular** branches supply the depressors of the hyoid bone, the Longus colli, the Scalenus anticus, and the Inferior constrictor of the pharynx.

The **Suprascapular Artery (transversalis humeri)**, smaller than the transversalis colli, passes obliquely from within outward across the root of the neck. It at first lies on the lower part of the Scalenus anticus, being covered by the Sterno-mastoid; it then crosses the subclavian artery, and runs outward behind and parallel with the clavicle and Subclavius muscle, and beneath the posterior belly of the Omo-hyoid, to the superior border of the scapula, where it passes over the transverse ligament of the scapula to the supraspinous fossa. In this situation it lies close to the bone, and ramifies between it and the Supraspinatus muscle, to which it is mainly distributed, giving off a communicating branch which crosses the neck of the scapula to reach the infraspinous fossa, where it anastomoses with the dorsal branch of the subscapular artery. Besides distributing branches to the Sterno-mastoid and neighboring muscles, it gives off a *supra-acromial branch*, which, piercing the Trapezius muscle, supplies the cutaneous surface of the acromion, anastomosing with the acromial thoracic and posterior circumflex arteries. As the artery passes over the transverse ligament of the scapula a branch descends into the subscapular fossa, ramifies beneath that muscle, and anastomoses with the posterior and subscapular arteries. It also supplies the shoulder-joint.

The **Transversalis colli** passes transversely outward, across the upper part of the subclavian triangle, to the anterior margin of the Trapezius muscle beneath, which it divides into two branches, the *superficial cervical* and the *posterior scapular*. In its passage across the neck it crosses in front of the Scaleni muscles and the brachial plexus, between the divisions of which it sometimes passes, and is covered by the Platysma, Sterno-mastoid, Omo-hyoid, and Trapezius muscles.

The **superficial cervical** ascends beneath the anterior margin of the Trapezius, distributing branches to it and to the neighboring muscles and glands in the neck, and anastomoses with the superficial branch of the arteria princeps cervicis.

The **posterior scapular**, the continuation of the transversalis colli, passes beneath the Levator anguli scapulæ to the superior angle of the scapula, and descends along the posterior border of that bone as far as the inferior angle, where it anastomoses with the subscapular branch of the axillary. In its course it is covered by the Rhomboid muscles, supplying these, the Latissimus dorsi, and [the] Trapezius, and anastomosing with the suprascapular and subscapular arteries and with the posterior branches of some of the intercostal arteries.

FIG. 387.

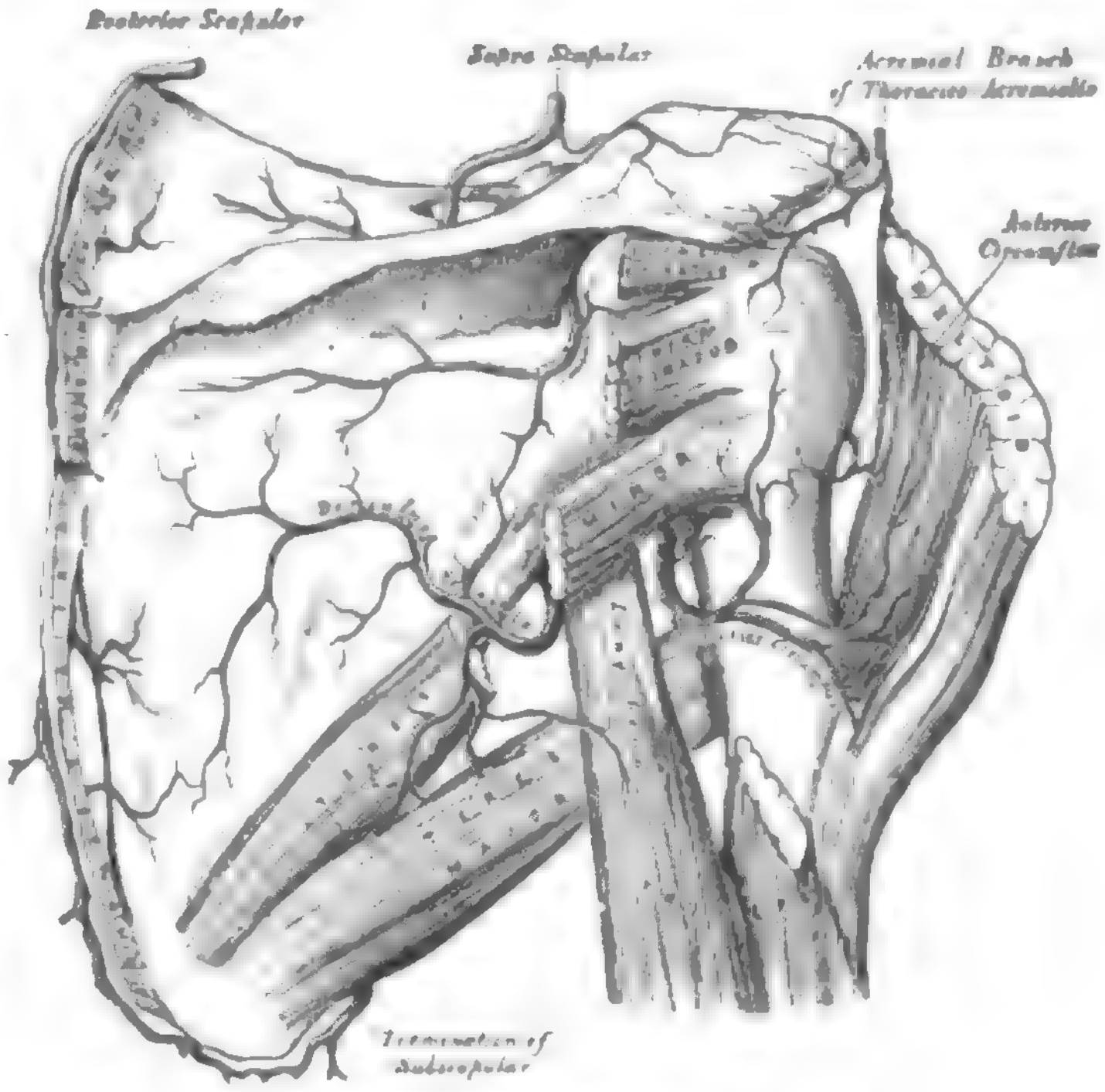
Posterior Scapular
Supra Scapular
Acromial Branch of Thoracico Acromialis
Anterior Circumflex
Termination of Subscapular

The Scapular and Circumflex Arteries.

Peculiarities.—The *superficial cervical* frequently arises as a separate branch from the thyroid axis, and the posterior scapular from the third, more rarely from the second, part of the subclavian.

The **Internal Mammary** arises from the under surface of the first portion of the subclavian artery, opposite the thyroid axis. It descends behind the clavicle to the inner surface of the anterior wall of the chest, resting against the costal cartilages a short distance from the margin of the sternum, and at the interval between the sixth and seventh cartilages divides into two branches, the *musculo-phrenic* and *superior epigastric*.

At its origin it is covered by the internal jugular and subclavian veins and crossed by the phrenic nerve. In the upper part of the thorax it lies against the costal cartilages and internal Intercostal muscles in front, and is covered by the pleura behind. At the lower part of the thorax the Triangularis sterni separates the artery from the pleura. It is accompanied by two veins, which join at the upper part of the thorax into a single trunk.

The branches of the internal mammary are the

Comes nervi phrenici (superior phrenic).
Mediastinal.
Pericardiac.
Sternal.
Anterior Intercostal.
Perforating.
Musculo-phrenic.
Superior Epigastric.

The **comes nervi phrenici (superior phrenic)** is a long slender branch which accompanies the phrenic nerve, between the pleura and pericardium, to the Diaphragm, to which it is distributed, anastomosing with the other phrenic arteries from the internal mammary and abdominal aorta.

The **mediastinal branches** are small vessels which are distributed to the areolar tissue in the anterior mediastinum and the remains of the thymus gland.

The **pericardiac branches** supply the upper part of the pericardium, the lower part receiving branches from the musculo-phrenic artery.

The **sternal** branches are distributed to the Triangularis sterni and to the posterior surface of the sternum.

The mediastinal, pericardiac, and sternal branches, together with some twigs from the comes nervi phrenici, anastomose with branches from the intercostal and bronchial arteries, and form a minute plexus beneath the pleura which has been named by Turner the *subpleural mediastinal plexus.*

The **anterior intercostal arteries** supply the five or six upper intercostal spaces. The branch corresponding to each space passes outward, and soon divides into two, which run along the opposite border of the ribs and inosculate with the intercostal arteries from the aorta. They are at first situated between the pleura and the internal Intercostal muscles, and then between the internal and external Intercostal muscles. They supply the Intercostal and Pectoral muscles and the mammary gland.

The **perforating arteries** correspond to the five or six upper intercostal spaces. They arise from the internal mammary, pass forward through the intercostal spaces, and, curving outward, supply the Pectoralis major and the integument. Those which correspond to the first three spaces are distributed to the mammary gland. In females during lactation these branches are of large size.

The **musculo-phrenic artery** is directed obliquely downward and outward, behind the cartilages of the false ribs, perforating the Diaphragm at the eighth or ninth rib, and terminating, considerably reduced in size, opposite the last intercostal space. It gives off anterior intercostal arteries to each of the intercostal spaces across which it passes; these diminish in size as the spaces decrease in length, and are distributed in a manner precisely similar to the anterior intercostals from the internal mammary. The musculo-phrenic also gives branches to the lower part of the pericardium and others which run backward to the Diaphragm and downward to the abdominal muscles.

The **superior epigastric** continues in the original direction of the internal mammary, descends behind the Rectus muscle, and, perforating its sheath, divides into branches which supply the Rectus, anastomosing with the epigastric artery from the external iliac. Some vessels perforate the sheath of the Rectus and supply the muscles of the abdomen and the integument, and a small branch which passes inward upon the side of the ensiform appendix anastomoses in front of that cartilage with the artery of the opposite side.

The **Superior Intercostal** (Fig. 372, p. 529) arises from the upper and back part of the subclavian artery, behind the anterior Scalenus on the right side and to the inner side of the muscle on the left side. Passing backward, it gives off the *deep cervical* branch, and then descends behind the pleura in front of the necks of the first two ribs and inosculates with the first aortic intercostal.[1] In the first intercostal space it gives off a branch which is distributed in a manner similar to the distribution of the aortic intercostals. The branch for the second intercostal space usually joins with one from the aortic intercostal. Each intercostal gives off a branch to the posterior spinal muscles, and a small one which passes through the corresponding intervertebral foramen to the spinal cord and its membranes.

The **deep cervical branch (profunda cervicis)** arises in most cases from the superior intercostal, and is analogous to the posterior branch of an aortic intercostal artery. Passing backward, between the transverse process of the seventh cervical vertebra and the first rib, it runs up the back part of the neck, between the Complexus and Semispinalis colli muscles, as high as the axis, supplying these and adjacent muscles, and anastomosing with the deep branch of the arteria princeps cervicis of the occipital and with branches which pass outward from the vertebral.

---

[1] See foot-note, p. 571.

SURGICAL ANATOMY OF THE AXILLA.

The **Axilla** is a pyramidal space situated between the upper and lateral part of the chest and the inner side of the arm. [It should be studied in the living model in various postures of the arm. Its boundaries are best shown when the arm is abducted, and especially if the arm of the model be placed on the shoulder of the observer, and then pressed down.]

Boundaries.—Its *apex*, which is directed upward toward the root of the neck, corresponds to the interval between the two Scaleni muscles on the first rib. The *base*, directed downward, is formed by the integument and a thick layer of fascia extending between the lower border of the Pectoralis major in front and the lower border of the Latissimus dorsi behind; it is broad internally at the chest, but narrow and pointed externally at the arm. The *anterior boundary* is formed by the Pectoralis major and minor muscles, the former covering the whole of the anterior wall of the axilla, the latter covering only its central part. The *posterior boundary*, which extends somewhat lower than the anterior, is formed by the Subscapularis above, the Teres major and Latissimus dorsi below. On the *inner side* are the first four ribs with their corresponding Intercostal muscles and part of the Serratus magnus. On the *outer side*, where the anterior and posterior boundaries converge, the space is narrow, and bounded by the humerus, the Coraco-brachialis, and Biceps muscles.

Contents.—This space contains the axillary vessels and brachial plexus of nerves, with their branches, some branches of the intercostal nerves, and a large number of lymphatic glands, all connected together by a quantity of fat and loose areolar tissue.

Their Position.—The axillary artery and vein, with the brachial plexus of nerves, extend obliquely along the outer boundary of the axillary space from its apex to its base, and are placed much nearer the anterior than the posterior wall [at the junction of the anterior and middle thirds], the vein lying to the inner or thoracic side of the artery and partially concealing it. At the fore part of the axillary space, in contact with the Pectoral muscles, are the thoracic branches of the axillary artery, and along the anterior margin of the axilla the long thoracic artery extends to the side of the chest. At the back part, in contact with the lower margin of the Subscapularis muscle, are the subscapular vessels and nerves; winding around the lower border of this muscle is the dorsalis scapulæ artery and veins; and toward the outer extremity of the muscle the posterior circumflex vessels and the circumflex nerve are seen curving backward to the shoulder.

Along the inner or thoracic side no vessel of any importance exists, the upper part of the space being crossed merely by a few small branches from the superior thoracic artery. There are some important nerves, however, in this situation—viz. the posterior thoracic or external respiratory nerve [of Bell], descending on the surface of the Serratus magnus, to which it is distributed; and, perforating the upper and anterior part of this wall, the intercosto-humeral nerve or nerves, passing across the axilla to the inner side of the arm.

The cavity of the axilla is filled by a quantity of loose areolar tissue, a large number of small arteries and veins, all of which are, however, of inconsiderable size, and numerous lymphatic glands; these are from ten to twelve in number, and situated chiefly on the thoracic side and lower and back part of this space.

The student should attentively consider the relation of the vessels and nerves in the several parts of the axilla, for it not unfrequently happens that the surgeon is called upon to extirpate diseased glands or to remove a tumor from this situation. In performing such an operation it will be necessary to proceed with much caution in the direction of the outer wall and apex of the space, as here the axillary vessels will be in danger of being wounded. Toward the posterior wall it will be necessary to avoid the subscapular, dorsalis scapulæ, and posterior circumflex vessels, and along the anterior wall the thoracic branches. It is only along the inner or thoracic wall and in the centre of the axillary cavity that there are no vessels of any importance—a fortunate circumstance, for it is in this situation more especially that tumors requiring removal are usually situated.

THE AXILLARY ARTERY.

The **Axillary Artery**, the continuation of the subclavian, commences at the lower border of the first rib and terminates at the lower border of the tendon of the Teres major muscle, where it takes the name of brachial. Its direction varies with the position of the limb: when the arm lies by the side of the chest, the vessel forms a gentle curve, the convexity being upward and outward; when it is directed at right angles with the trunk, the vessel is nearly straight; and when it is elevated still higher, the artery describes a curve, the concavity of which is directed upward. At its commencement the artery is very deeply situated, but near its termination is superficial, being covered only by the skin and fascia. The description of the relations of this vessel is facilitated by its division into three portions, the first portion being that above the Pectoralis minor, the second portion behind, and the third below, that muscle.

The **first portion** of the axillary artery is in relation *in front* with the clavicular portion of the Pectoralis major, the costo-coracoid membrane, the Subclavius, the external anterior thoracic nerve, and the acromio-thoracic and cephalic veins; *behind*, with the first intercostal space, the corresponding Intercostal muscle, the first serration of the Serratus magnus, and the posterior thoracic nerve; on its *outer side*, with the brachial plexus, from which it is separated by a little cellular interval; on its *inner* or thoracic side, with the axillary vein.

RELATIONS OF THE FIRST PORTION OF THE AXILLARY ARTERY.

In Front.

Pectoralis major.
Costo-coracoid membrane.
Subclavius.
External anterior thoracic nerve.
Acromio-thoracic and cephalic veins.

Outer Side.
Brachial plexus.

Axillary
Artery.
First portion.

Inner Side.
Axillary vein.

Behind.

First intercostal space and intercostal muscle.
First serration of Serratus magnus.
Posterior thoracic nerve.

The **second portion** of the axillary artery lies behind the Pectoralis minor. It is covered *in front* by the Pectoralis major and minor muscles; *behind* it is separated from the Subscapularis by a cellular interval; on the *inner side* is the axillary vein. The brachial plexus of nerves surrounds the artery, and separates it from direct contact with the vein and adjacent muscles.

RELATIONS OF THE SECOND PORTION OF THE AXILLARY ARTERY.

In Front.

Pectoralis major and minor.

Outer Side.
Outer cord of plexus.

Axillary
Artery.
Second
portion.

Inner Side.
Axillary vein.
Inner cord of plexus.

Behind.

Subscapularis.
Posterior cord of plexus.

The **third portion** of the axillary artery lies below the Pectoralis minor. It is in relation *in front* with the lower part of the Pectoralis major above, being covered only by the integument and fascia below, where it is crossed by the inner head of the median nerve; *behind*, with the lower part of the Subscapularis and the tendons of the Latissimus dorsi and Teres major; on its *outer side*, with the Coraco-brachialis; on its *inner* or thoracic side, with the axillary vein. The nerves of the brachial plexus bear the following relation to the artery in this part of its course: on the *outer side* are the median nerve and the musculo-cutaneous for a short distance; on the *inner side*, the ulnar, the internal, and lesser internal cutaneous nerves; and *behind*, the musculo-spiral and circumflex, the latter extending only to the lower border of the Subscapularis muscle.

RELATIONS OF THE THIRD PORTION OF THE AXILLARY ARTERY.

In Front.

Integument and fascia.
Pectoralis major.
Inner head of median nerve.

Outer Side.

Coraco-brachialis.
Median nerve.
Musculo-cutaneous nerve.

Axillary
Artery.
Third portion.

Inner Side.

Ulnar nerve.
Internal cutaneous nerves.
Axillary veins.

Behind.

Subscapularis.
Tendons of Latissimus dorsi and Teres major.
Musculo-spiral and circumflex nerves.

Peculiarities.—The axillary artery, in about one case out of every ten, gives off a large branch, which forms either one of the arteries of the forearm or a large muscular trunk. In the first set of cases this artery is most frequently the radial (1 in 33), sometimes the ulnar (1 in 72), and very rarely the interosseous (1 in 506). In the second set of cases the trunk has been found to give origin to the subscapular, circumflex, and profunda arteries of the arm. Sometimes only one of the circumflex or one of the profunda arteries arose from the trunk. In these cases the brachial plexus surrounded the trunk of the branches, and not the main vessel.

Surgical Anatomy.—The student, having carefully examined the relations of the axillary artery in its various parts, should now consider in what situation compression of this vessel may be most easily effected, and the best position for the application of a ligature to it when necessary.

Compression of the vessel is required in the removal of tumors or in amputation of the upper part of the arm; and the only situation in which this can be effectually made is in the lower part of its course: by pressing on it in this situation from within outward against the humerus the circulation may be effectually arrested.

The **application of a ligature to the axillary artery** may be required in cases of aneurism of the upper part of the brachial; and there are only two situations in which it can be secured—viz. in the first and in the third parts of its course—for the axillary artery at its central part is so deeply seated, and at the same time so closely surrounded with large nervous trunks, that the application of a ligature to it in that situation would be almost impracticable.

In the **third part** of its course the operation is most simple, and may be performed in the following manner: The patient being placed on a bed, and the arm separated from the side, with the hand supinated, the head of the humerus is felt for, and an incision made through the integument over it about two inches in length, a little nearer to the anterior than the posterior fold of the axilla. After carefully dissecting through the areolar tissue and fascia, the median nerve and axillary vein are exposed: the former having been displaced to the outer and the latter to the inner side of the arm, the elbow being at the same time bent, so as to relax the structures and facilitate their separation, the ligature may be passed round the artery from the ulnar to the radial side. This portion of the artery is occasionally crossed by a muscular slip derived from the Latissimus dorsi, which may mislead the surgeon during an operation. The occasional existence of this muscular fasciculus was spoken of in the description of the muscles. It may easily be recognized by the transverse direction of its fibres.

The **first portion** of the axillary artery may be tied in cases of aneurism encroaching so far upward that a ligature cannot be applied in the lower part of its course. Notwithstanding that this operation has been performed in some few cases, and with success, its performance is attended with much difficulty and danger. The student will remark that in this situation it would be necessary to divide a thick muscle, and, after separating the costo-coracoid membrane, the artery would be exposed at the bottom of a more or less deep space, with the cephalic and axillary veins in such relation with it as must render the application of a ligature to this part of the vessel particularly hazardous. Under such circumstances it is an easier and, at the same time, more advisable operation to tie the subclavian artery in the third part of its course.

In a case of wound of the vessel the general practice of cutting down upon and tying it above and below the wounded point should be adopted in all cases.

Collateral Circulation after Ligature of the Axillary Artery.—If the artery be tied above the origin of the acromial thoracic, the collateral circulation will be carried on by the same branches as after the ligature of the subclavian; if at a lower point, between the acromial thoracic and subscapular arteries, the latter vessel, by its free anastomoses with the other scapular arteries, branches of the subclavian, will become the chief agent in carrying on the circulation, to which the long thoracic, if it be below the ligature, will materially contribute by its anastomoses with the intercostal and internal mammary arteries. If the point included in the ligature be below the origin of the subscapular artery, the anastomoses are less free. The chief agents in restoring the circulation will be the posterior circumflex by its anastomoses with the suprascapular and acromial thoracic and with the superior profunda, and the communications between the subscapular and superior profunda, which will be afterward referred to as performing the same office after ligature of the brachial. The cases in which the operation has been performed are few in number, and no published account of dissection of the collateral circulation appears to exist.

The branches of the axillary artery are

From 1st Part	Superior Thoracic. Acromial Thoracic.
From 2d Part	Long Thoracic. Alar Thoracic.
From 3d Part	Subscapular. Anterior Circumflex. Posterior Circumflex.

The **superior thoracic** is a small artery which arises from the axillary separately, or by a common trunk with the acromial thoracic. Running forward and inward along the upper border of the Pectoralis minor, it passes between it and the Pectoralis major to the side of the chest. It supplies these muscles and the parietes of the thorax, anastomosing with the internal mammary and intercostal arteries.

The **acromial thoracic** is a short trunk which arises from the fore part of the axillary artery. Projecting forward to the upper border of the Pectoralis minor, it divides into three sets of branches—*thoracic*, *acromial*, and *descending*. The *thoracic* branches, two or three in number, are distributed to the Serratus magnus and Pectoral muscles, anastomosing with the intercostal branches of the internal mammary. The *acromial* branches are directed outward toward the acromion, supplying the Deltoid muscle, and anastomosing on the surface of the acromion with the suprascapular and posterior circumflex arteries. The *descending* branch passes in the interspace between the Pectoralis major and Deltoid, accompanying the cephalic vein and supplying both muscles.

The **long thoracic** passes downward and inward along the lower border of the Pectoralis minor to the side of the chest, supplying the Serratus magnus, the Pectoral muscles, and the mammary gland, and sending branches across the axilla to the axillary glands and subscapularis, which anastomose with the internal mammary and intercostal arteries.

The **alar thoracic** is a small branch which supplies the glands and areolar tissue of the axilla. Its place is frequently supplied by branches from some of the other thoracic arteries.

The **subscapular,** the largest branch of the axillary artery, arises opposite the lower border of the Subscapularis muscle, and passes downward and backward along its lower margin to the inferior angle of the scapula, where it anastomoses with the posterior scapular, a branch of the transversalis colli from the thyroid axis of the subclavian. It distributes branches to the muscles in its neighborhood, and gives off, about an inch and a half from its origin, a large branch, the *dorsalis scapulæ* [Fig. 387, p. 551], which curves round the inferior border of the scapula, leaving the axilla in the interspace between the Teres minor above, the Teres major below, and the long head of the Triceps in front. Three branches or sets of branches arise from the dorsalis scapulæ: the *first* enters the subscapular fossa beneath the Subscapularis, which it supplies, anastomosing with the posterior scapular and suprascapular arteries; the *second*, the trunk of the artery (*dorsalis scapulæ*), turns round the axillary border of the scapula and enters the infraspinous fossa, where it anastomoses with the suprascapular and posterior scapular arteries; and a *third* or median branch is continued along the axillary border of the scapula, between the Teres major and minor, and at the dorsal surface of the inferior angle of the bone anastomoses with the posterior scapular.

The **circumflex arteries** wind round the neck of the humerus. The *posterior circumflex* (Fig. 387), the larger of the two, arises from the back part of the axillary opposite the lower border of the Subscapularis muscle, and, passing backward with the circumflex veins and nerve through the quadrangular space bounded by the Teres major and minor, the scapular head of the Triceps, and the humerus, winds round the neck of that bone and is distributed to the Deltoid muscle and shoulder-joint, anastomosing with the anterior circumflex and acromial thoracic arteries and with the superior profunda branch of the brachial artery. The *anterior circumflex* (Figs. 387, 388), considerably smaller than the preceding, arises just below that vessel from the outer side of the axillary artery. It passes horizontally outward beneath the Coraco-brachialis and short head of the Biceps, lying upon the fore part of the neck of the humerus, and on reaching the bicipital groove gives off an ascending branch which passes upward along the groove to supply the head of the bone and the shoulder-joint. The trunk of the vessel is then continued outward beneath the Deltoid, which it supplies, and anastomoses with the posterior circumflex and acromial thoracic arteries.

FIG. 388.

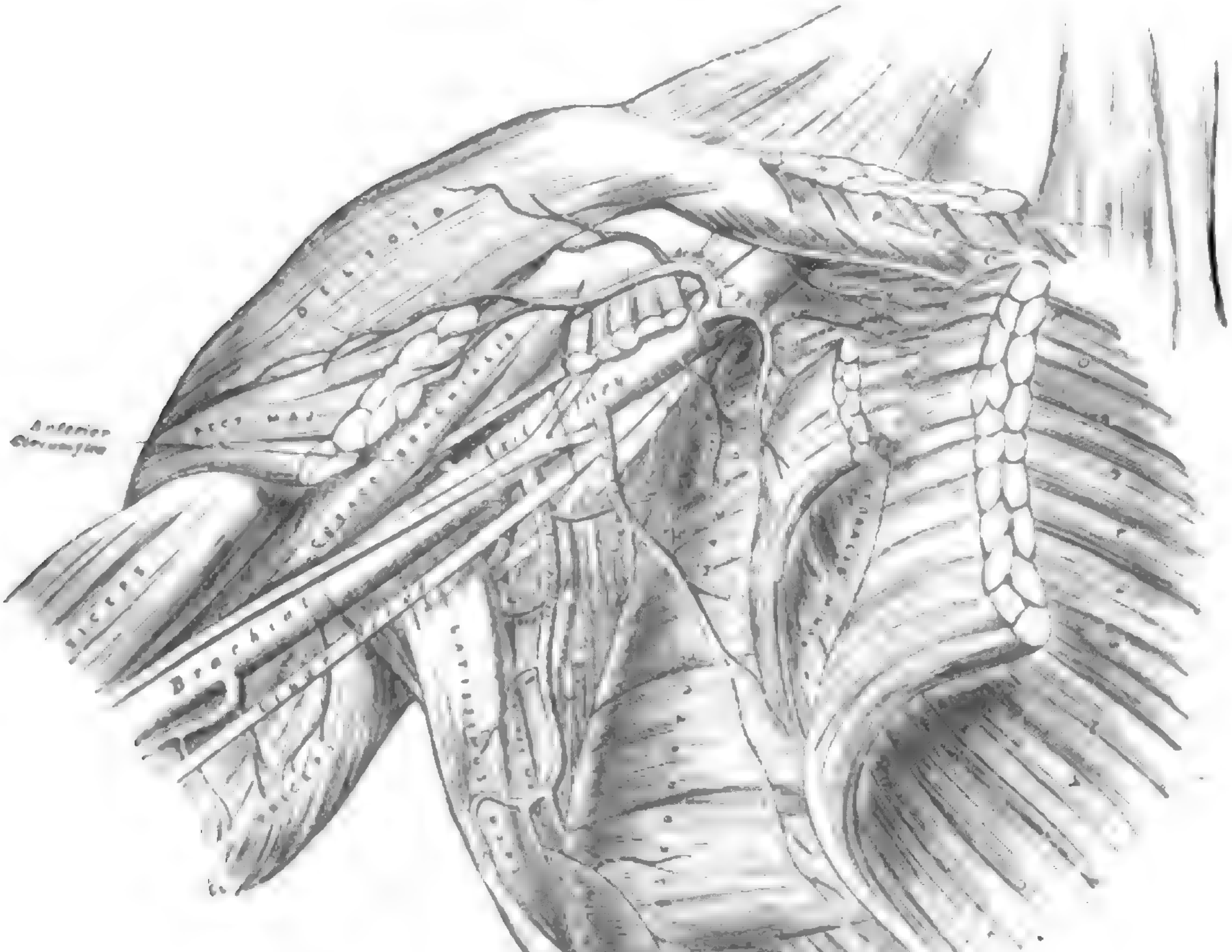

The Axillary Artery and its Branches.

BRACHIAL ARTERY (Fig. 389).

The **Brachial Artery** commences at the lower margin of the tendon of the Teres major, and, passing down the inner and anterior aspect of the arm, terminates about half an inch below the bend of the elbow, where it divides into the *radial* and *ulnar* arteries.

FIG. 389.

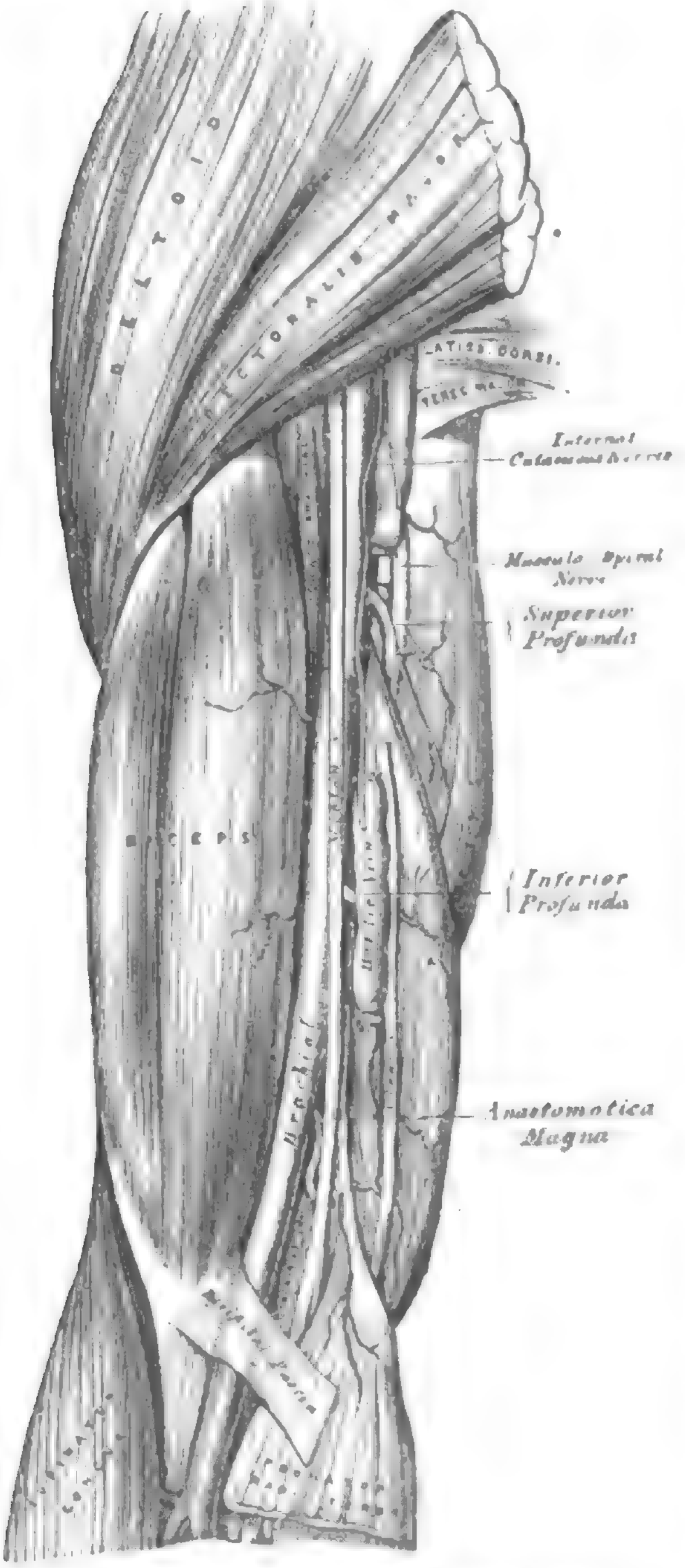

The Surgical Anatomy of the Brachial Artery.

The direction of this vessel is marked by a line drawn from the outer side of the axillary space between the folds of the axilla [better, from the junction of the anterior and middle thirds of the axilla] to a point midway between the condyles of the humerus which corresponds to the depression along the inner border of the Coraco-brachialis and Biceps muscles. In the upper part of its course the artery lies internal to the humerus, but below it is in front of that bone. [It very frequently presents a high bifurcation—a very important fact. (See next page.)]

RELATIONS.—This artery is superficial throughout its entire extent, being covered *in front* by the integument, the superficial and deep fascia; the bicipital fascia separates it opposite the elbow from the median basilic vein; the median nerve crosses it at its middle. *Behind*, it is separated from the inner side of the humerus above by the long and inner heads of the Triceps, the musculo-spiral nerve and superior profunda artery intervening, and from the front of the bone below by the insertion of the Coraco-brachialis muscle and by the Brachialis anticus. By its *outer side* it is in relation with the commencement of the median nerve and the Coraco-brachialis and Biceps muscles, which slightly overlap the artery. By its *inner side* its upper half is in relation with the internal cutaneous and ulnar nerves, its lower half with the median nerve. The basilic vein lies on the inner side of the artery, but is separated from it in the lower part of the arm by the deep fascia. It is accompanied by two venæ comites, which lie in close contact with the artery, being connected together at intervals by short transverse communicating branches.

PLAN OF THE RELATIONS OF THE BRACHIAL ARTERY.

In Front.

Integument and fasciæ.
Bicipital fascia, median basilic vein.
Median nerve.

Outer Side.

Median nerve (above).
Coraco-brachialis.
Biceps.

Brachial
Artery.

Inner Side.

Internal cutaneous and ulnar nerve.
Median nerve (below).
Basilic vein.

Behind.

Triceps.
Musculo-spiral nerve.
Superior profunda artery.
Coraco-brachialis.
Brachialis anticus.

BEND OF THE ELBOW.

At the bend of the elbow the brachial artery sinks deeply into a triangular interval, the base of which is directed upward toward the humerus, and the sides of which are bounded externally by the Supinator longus, internally by the Pronator radii teres; its floor is formed by the Brachialis anticus and Supinator brevis. This space contains the brachial artery with its accompanying veins, the radial and ulnar arteries, the median and musculo-spiral nerves, and the tendon of the Biceps. The brachial artery occupies the middle line of this space, and divides opposite the neck of the radius into the radial and ulnar arteries; it is covered *in front* by the integument, the superficial fascia, and the median basilic vein, the vein being separated from direct contact with the artery by the bicipital fascia; *behind*, it lies on the Brachialis anticus, which separates it from the elbow-joint. The median nerve lies on the inner side of the artery, but separated from it below by an interval of half an inch and by the coronoid head of the Pronator radii teres. The tendon of the Biceps lies to the outer side of the space, and the musculo-spiral nerve still more externally lying upon the Supinator brevis and partly concealed by the Supinator longus.

Peculiarities of the Artery as regards its Course.—The brachial artery, accompanied by the median nerve, may leave the inner border of the Biceps and descend toward the inner condyle of the humerus, where it usually curves round a prominence of bone, to which it is connected by a fibrous band; it then inclines outward, beneath or through the substance of the Pronator teres muscle, to the bend of the elbow. The variation bears considerable analogy with the normal condition of the artery in some of the Carnivora: it has been referred to above in the description of the humerus (p. 240).

As regards its Division.—Occasionally the artery is divided for a short distance at its upper part into two trunks, which are united above and below. A similar peculiarity occurs in the main vessel of the lower limb.

The point of bifurcation may be above or below the usual point, the former condition being by far the most frequent. Out of 481 examinations recorded by Mr. Quain, some made on the right, and some on the left side of the body, in 386 the artery bifurcated in its normal position. In 1 case only was the place of division lower than usual, being two or three inches below the elbow-joint. "In 94 cases out of 481, or about 1 in 5⅛, there were two arteries instead of one in some part or in the whole of the arm."

There appears, however, to be no correspondence between the arteries of the two arms with respect to their irregular division, for in 61 bodies it occurred on one side only in 43; on both sides in different positions in 13; on both sides in the same position in 5.

The point of bifurcation takes place at different parts of the arm, being most frequent in the upper part, less so in the lower part, and least so in the middle, the most usual point for the application of a ligature; under any of these circumstances two large arteries would be found in the arm instead of one. The most frequent (in three out of four) of these peculiarities is the high division of the radial. That artery often arises from the inner side of the brachial and runs parallel with the main trunk to the elbow, where it crosses it, lying beneath the fascia; or it may perforate the fascia and pass over the artery immediately beneath the integument.

The ulnar sometimes arises from the brachial high up, and then occasionally leaves that vessel at the lower part of the arm and descends toward the inner condyle. In the forearm it generally lies beneath the deep fascia, superficial to the Flexor muscles, occasionally between the integument and deep fascia, and very rarely beneath the Flexor muscles.

The interosseous artery sometimes arises from the upper part of the brachial or axillary: as it passes down the arm it lies behind the main trunk, and at the bend of the elbow regains its usual position.

In some cases of high division of the radial the remaining trunk (ulnar interosseous) occasionally passes, together with the median nerve, along the inner margin of the arm to the inner condyle, and then, passing from within outward, beneath or through the Pronator teres, regains its usual position at the bend of the elbow.

Occasionally the two arteries representing the brachial are connected at the bend of the elbow by a short transverse branch, and are even sometimes reunited.

Sometimes long slender vessels, *vasa aberrantia*, connect the brachial or axillary arteries with one of the arteries of the forearm or a branch from them. These vessels usually join the radial.

Varieties in Muscular Relations.[1]—The brachial artery is occasionally concealed, in some part of its course, by muscular or tendinous slips derived from the Coraco-brachialis, Biceps, Brachialis anticus, and Pronator radii teres muscles.

Surgical Anatomy.—Compression of the brachial artery is required in cases of amputation and some other operations in the arm and forearm; and it will be observed that it may be effected in almost any part of the course of the artery. If pressure is made in the upper part of the limb, it should be directed from within outward; and if in the lower part, from before backward, as the artery lies on the inner side of the humerus above and in front of it below. The most favorable situation is near the insertion of the Coraco-brachialis.

The application of a ligature to the brachial artery may be required in cases of wound of the vessel and in some cases of wound of the palmar arch. It is also sometimes necessary in cases of aneurism of the brachial, the radial, ulnar, or interosseous arteries. The artery may be secured in any part of its course. The chief guides in determining its position are the surface-markings produced by the inner margin of the Coraco-brachialis and Biceps, the known course of the vessel, and its pulsation, which should be carefully felt for before any operation is performed, as the vessel occasionally deviates from its usual position in the arm. In whatever situation the operation is performed, great care is necessary, on account of the extreme thinness of the parts covering the artery and the intimate connection which the vessel has throughout its whole course with important nerves and veins. Sometimes a thin layer of muscular fibre is met with concealing the artery; if such is the case, it must be cut across in order to expose the vessel.

In the upper third of the arm the artery may be exposed in the following manner: The patient being placed horizontally upon a table, the affected limb should be raised from the side and the hand supinated. An incision about two inches in length should be made on the ulnar side of the Coraco-brachialis muscle, and the subjacent fascia cautiously divided, so as to avoid wounding the internal cutaneous nerve or basilic vein, which sometimes runs on the surface of the artery as high as the axilla. The fascia having been divided, it should be remembered that the ulnar and internal cutaneous nerves lie on the inner side of the artery, the median on the outer side, the latter nerve being occasionally superficial to the artery in this situation, and that the venæ comites are also in relation with the vessel, one on either side. These being carefully separated, the aneurism-needle should be passed round the artery from the ulnar to the radial side.

If two arteries are present in the arm in consequence of a high division, they are usually placed side by side; and if they are exposed in an operation, the surgeon should endeavor to ascertain, by alternately pressing on each vessel, which of the two communicates with the wound or aneurism, when a ligature may be applied accordingly; or if pulsation or hemorrhage ceases only when both vessels are compressed, both vessels may be tied, as it may be concluded that the two communicate above the seat of disease or are reunited.

It should also be remembered that two arteries may be present in the arm in a case of high division, and that one of these may be found along the inner intermuscular septum, in a line toward the inner condyle of the humerus or in the usual position of the brachial, but deeply placed beneath the common trunk: a knowledge of these facts will suggest the precautions necessary in every case and indicate the measures to be adopted when anomalies are met with.

In the middle of the arm the brachial artery may be exposed by making an incision along the inner margin of the Biceps muscle. The forearm being bent so as to relax the muscle, it should be drawn slightly aside, and, the fascia being carefully divided, the median nerve will be exposed lying upon the artery (sometimes beneath); this being drawn inward and the muscle outward, the artery should be separated from its accompanying veins and secured. In this situation the inferior profunda may be mistaken for the main trunk, especially if enlarged, from the collateral circulation having become established; this may be avoided by directing the incision externally toward the Biceps, rather than inward or backward toward the Triceps.

The lower part of the brachial artery is of extreme interest in a surgical point of view, on account of the relation which it bears to the veins most commonly opened in venesection. Of these vessels, the median basilic is the largest and most prominent, and consequently the one usually selected for the operation. It should be remembered that this vein runs parallel with the brachial artery, from which it is separated by the bicipital fascia, and that care should be taken in opening the vein not to carry the incision too deeply, so as to endanger the artery.

---

[1] See Struthers's *Anatomical and Physiological Observations.*

Collateral Circulation.—After the application of a ligature to the brachial artery in the upper third of the arm, the circulation is carried on by branches from the circumflex and subscapular arteries, anastomosing with ascending branches from the superior profunda. If the brachial is tied *below* the origin of the profunda arteries, the circulation is maintained by the branches of the profundæ anastomosing with the recurrent radial, ulnar, and interosseous arteries. In two cases described by Mr. South,[1] in which the brachial artery had been tied some time previously, in one "a long portion of the artery had been obliterated, and sets of vessels are descending on either side from above the obliteration, to be received into others, which ascend in a similar manner from below it. In the other the operation is less extensive, and a single curved artery about as big as a crow-quill passes from the upper to the lower open part of the artery."

The branches of the brachial artery are the

Superior Profunda. Inferior Profunda.
Nutrient Artery. Anastomotica magna.
Muscular.

The **superior profunda** arises from the inner and back part of the brachial, just below the lower border of the Teres major, and passes backward to the interval between the outer and inner heads of the Triceps muscle, accompanied by the musculo-spiral nerve; it winds round the back part of the shaft of the humerus in the spiral groove between the Triceps and the bone, pierces the external intermuscular septum, and descends to the space between the Brachialis anticus and Supinator longus, where it anastomoses with the recurrent branch of the radial artery. It supplies the Deltoid, Coraco-brachialis, and Triceps muscles. Near its commencement it sends off a branch which passes upward between the external and long heads of the Triceps muscle to anastomose with the posterior circumflex; and whilst in the groove between the Triceps and the bone it gives off the posterior articular artery, which descends perpendicularly between the Triceps and the bone, accompanied by the nerve to the Anconeus muscle, to the back part of the elbow-joint, where it anastomoses with the interosseous recurrent branch, and on the inner side of the arm with the posterior ulnar recurrent and with the anastomotica magna and inferior profunda (Fig. 392).

The **nutrient artery** of the shaft of the humerus arises from the brachial about the middle of the arm. Passing downward, it enters the nutrient canal of that bone near the insertion of the Coraco-brachialis muscle.

The **inferior profunda,** of small size, arises from the brachial a little below the middle of the arm; piercing the internal intermuscular septum, it descends on the surface of the inner head of the Triceps muscle to the space between the inner condyle and olecranon, accompanied by the ulnar nerve, and terminates by anastomosing with the posterior ulnar recurrent and anastomotica magna. It also supplies a branch to the front of the internal condyle, which anastomoses with the anterior ulnar recurrent.

The **anastomotica magna** arises from the brachial about two inches above the elbow-joint. It passes transversely inward upon the Brachialis anticus, and, piercing the internal intermuscular septum, winds round the back part of the humerus between the Triceps and the bone, forming an arch above the olecranon fossa by its junction with the posterior articular branch of the superior profunda. As this vessel lies on the Brachialis anticus, branches ascend to join the inferior profunda, and some descend in front of the inner condyle to anastomose with the anterior ulnar recurrent. Behind the internal condyle an offset is given off which anastomoses with the inferior profunda and posterior ulnar recurrent arteries and supplies the Triceps.

The **muscular** are three or four large branches which are distributed to the muscles in the course of the artery. They supply the Coraco-brachialis, Biceps, and Brachialis anticus muscles.

---

[1] *Chelius's Surgery,* vol. ii. p. 254. See also White's engraving, referred to by Mr. South, of the anastomosing branches after ligature of the brachial, in White's *Cases in Surgery.* Porta also gives a case (with drawings) of the circulation after ligature of both brachial and radial (*Alterazioni Patologiche delle Arterie*).

The Anastomosis around the Elbow-joint (Fig. 392, p. 568).—The vessels engaged in this anastomosis may be conveniently divided into those situated *in front* and *behind* the internal and external condyles. The branches anastomosing *in front* of the internal condyle are the anastomotica magna, the anterior ulnar recurrent, and the anterior terminal branch of the inferior profunda. Those *behind* the internal condyle are the anastomotica magna, the posterior ulnar recurrent, and the posterior terminal branch of the inferior profunda. The branches anastomosing *in front* of the external condyle are the radial recurrent and the termination of the superior profunda. Those behind the external condyle (perhaps more properly described as being situated between the external condyle and the olecranon) are the anastomotica magna, the interosseous recurrent, and the posterior articular branch of the superior profunda. There is also a large arch of anastomosis above the olecranon formed by the interosseous recurrent joining with the anastomotica magna and posterior ulnar recurrent (Fig. 392).

From this description it will be observed that the anastomotica magna is the vessel most engaged, the only part of the anastomosis in which it is not employed being that *in front* of the external condyle.

RADIAL ARTERY.

The **Radial Artery** appears, from its direction, to be the continuation of the brachial, but in size it is smaller than the ulnar. It commences at the bifurcation of the brachial, just below the bend of the elbow, and passes along the radial side of the forearm to the wrist; it then winds backward, round the outer side of the carpus, beneath the extensor tendons of the thumb, and finally passes forward, between the two heads of the first Dorsal interosseous muscle, into the palm of the hand, where it crosses the metacarpal bones to the ulnar border of the hand to form the deep palmar arch. At its termination it inosculates with the deep branch of the ulnar artery. The relations of this vessel may thus be conveniently divided into three parts—viz. in the forearm, at the back of the wrist, and in the hand.

RELATIONS.—*In the forearm* this vessel extends from opposite the neck of the radius to the fore part of the styloid process, being placed to the inner side of the shaft of the bone above, and in front of it below. It is superficial throughout its entire extent, being covered by the integument, the superficial and deep fasciæ, and slightly overlapped above by the Supinator longus. In its course downward it lies upon the tendon of the Biceps, the Supinator brevis, the radial origin of the Flexor sublimis digitorum, the Pronator radii teres, the Flexor longus pollicis, the Pronator quadratus, and the lower extremity of the radius. In the upper third of its course it lies between the Supinator longus and the Pronator radii teres; in in its lower two-thirds, between the tendons of the Supinator longus and the Flexor carpi radialis. The radial nerve lies along the outer side of the artery in the middle third of its course, and some filaments of the musculo-cutaneous nerve, after piercing the deep fascia, run along the lower part of the artery as it winds around the wrist. The vessel is accompanied by venæ comites throughout its whole course. [An easy rule by which to remember the relations of the arteries and nerves of the forearm and leg is this: The *radial nerve* lies to the *radial side* of the *radial artery*; the *ulnar nerve* lies to the *ulnar side* of the *ulnar artery*; the *tibial nerves* (anterior and posterior) lie to the *fibular side* of the *tibial arteries—i. e.* reverse the extremity (if this expression be allowable), and the rule is reversed. In the lower part of the anterior tibial and the extreme upper part of the posterior tibial the rule is not reversed.]

PLAN OF THE RELATIONS OF THE RADIAL ARTERY IN THE FOREARM.

In Front.

Integument, superficial and deep fasciæ.
Supinator longus.

Inner Side.

Pronator radii teres.
Flexor carpi radialis.

Radial Artery in Forearm.

Outer Side.

Supinator longus.
Radial nerve (middle third).

Behind.

Tendon of Biceps.
Supinator brevis.
Flexor sublimis digitorum.
Pronator radii teres.
Flexor longus pollicis.
Pronator quadratus.
Radius.

At the wrist, as it winds around the outer side of the carpus from the styloid process to the first interosseous space, it lies upon the external lateral ligament, and then upon the scaphoid bone and trapezium, being covered by the extensor tendons of the thumb, subcutaneous veins, some filaments of the radial nerve, and the integument. It is accompanied by two veins and a filament of the musculocutaneous nerve.

In the hand it passes from the upper end of the first interosseous space, between the heads of the Abductor indicis or first Dorsal interosseous muscle, transversely across the palm to the base of the metacarpal bone of the little finger, where it inosculates with the communicating branch from the ulnar artery, forming the *deep palmar arch.* It lies upon the carpal extremities of the metacarpal bones and the Interossei muscles, being covered by the flexor tendons of the fingers, the Lumbricales, the Opponens and Flexor brevis minimi digiti, and the Flexor brevis pollicis. Alongside of it is the deep branch of the ulnar nerve, but running in the opposite direction; that is to say, from within outward.

Peculiarities.—The origin of the radial artery, according to Quinn, is, in nearly one case in eight, higher than usual, more frequently arising from the axillary or upper part of the brachial than from the lower part of this vessel. The variations in the position of this vessel in the arm and at the bend of the elbow have been already mentioned. In the forearm it deviates less frequently from its position than the ulnar. It has been found lying over the fascia, instead of beneath it. It has also been observed on the surface of the Supinator longus, instead of along its inner border: and in turning round the wrist it has been seen lying over instead of beneath the extensor tendons.

Surgical Anatomy.—The operation of tying the radial artery is required in cases of wounds either of its trunk or in some of its branches or for aneurism; and it will be observed that the vessel may be exposed in any part of its course through the forearm without the division of any muscular fibres. The operation in the middle or inferior third of the forearm is easily performed; but in the upper third, near the elbow, it is attended with some difficulty, from the greater depth of the vessel and from its being overlapped by the Supinator longus muscle.

To tie the artery in the upper third, an incision three inches in length should be made through the integument in a line drawn from the centre of the bend of the elbow to the front of the styloid process of the radius, avoiding the branches of the median vein; the fascia of the arm being divided and the Supinator longus drawn a little outward, the artery will be exposed. The venæ comites should be carefully separated from the vessel and the ligature passed from the radial to the ulnar side.

In the middle third of the forearm the artery may be exposed by making an incision of similar length on the inner margin of the Supinator longus. In this situation the radial nerve lies in close relation with the outer side of the artery, and should, as well as the veins, be carefully avoided.

In the lower third the artery is easily secured by dividing the integument and fascia in the interval between the tendons of the Supinator longus and Flexor carpi radialis muscles.

The branches of the radial artery may be divided into three groups, corresponding with the three regions in which the vessel is situated:

In the Forearm.
- Radial Recurrent.
- Muscular.
- Superficialis volæ.
- Anterior Carpal.

Wrist.
- Posterior Carpal.
- Metacarpal.
- Dorsales pollicis.
- Dorsalis indicis.

Hand.
- Princeps pollicis.
- Radialis indicis.
- Perforating.
- Interosseous.

The **radial recurrent** is given off immediately below the elbow. It ascends between the branches of the musculo-spiral nerve lying on the Supinator brevis, and then between the Supinator longus and Brachialis anticus, supplying these muscles and the elbow-joint and anastomosing with the terminal branches of the superior profunda.

The **muscular branches** are distributed to the muscles on the radial side of the forearm.

The **superficialis volæ** arises from the radial artery just where this vessel is about to wind round the wrist. Running forward, it passes between the muscles of the thumb, which it supplies, and sometimes anastomoses with the termination of the ulnar artery, completing the superficial palmar arch. This vessel varies considerably in size; usually it is very small, and terminates in the muscles of the thumb; sometimes it is as large as the continuation of the radial.

The **carpal branches** supply the joints of the wrist. The *anterior carpal* is a small vessel which arises from the radial artery near the lower border of the Pronator quadratus, and, running inward in front of the radius, anastomoses with the anterior carpal branch of the ulnar artery. From the arch thus formed branches descend to supply the articulations of the wrist.

The **posterior carpal** is a small vessel which arises from the radial artery beneath the extensor tendons of the thumb; crossing the carpus transversely to the inner border of the hand, it anastomoses with the posterior carpal branch of the ulnar, forming the posterior carpal arch. From this arch are given off descending branches —the *dorsal interosseous* arteries for the third and fourth interosseous space, which anastomose with the posterior perforating branches from the deep palmar arch, and ascending branches to anastomose with the termination of the anterior interosseous artery.

The **metacarpal (first dorsal interosseous branch)** arises beneath the extensor tendons of the thumb, sometimes with the posterior carpal artery; running forward on the second dorsal interosseous muscle, it communicates behind with the corresponding perforating branch of the deep palmar arch, and in front inosculates with the digital branch of the superficial palmar arch, and, dividing into two *dorsal digital* branches, supplies the adjoining sides of the index and middle fingers.

The **dorsales pollicis** are two small vessels which run along the sides of the dorsal aspect of the thumb. They arise separately, or occasionally by a common trunk near the base of the first metacarpal bone.

The **dorsalis indicis**, also a small branch, runs along the radial sides of the back of the index finger, sending a few branches to the Abductor indicis.

The **princeps pollicis** arises from the radial just as it turns inward to the deep part of the hand; it descends between the Abductor indicis and Flexor brevis pollicis, then between the Adductor and Flexor brevis pollicis, along the ulnar side of the metacarpal bone of the thumb, to the base of the first phalanx, where it divides into two branches, which run along the sides of the palmar aspect of the thumb and form an arch on the under surface of the last phalanx, from which branches are distributed to the integument and pulp of the thumb.

The **radialis indicis** arises close to the preceding, descends between the Abductor indicis and Adductor pollicis, and runs along the radial side of the index finger to its extremity, where it anastomoses with the collateral digital artery from the

FIG. 390.

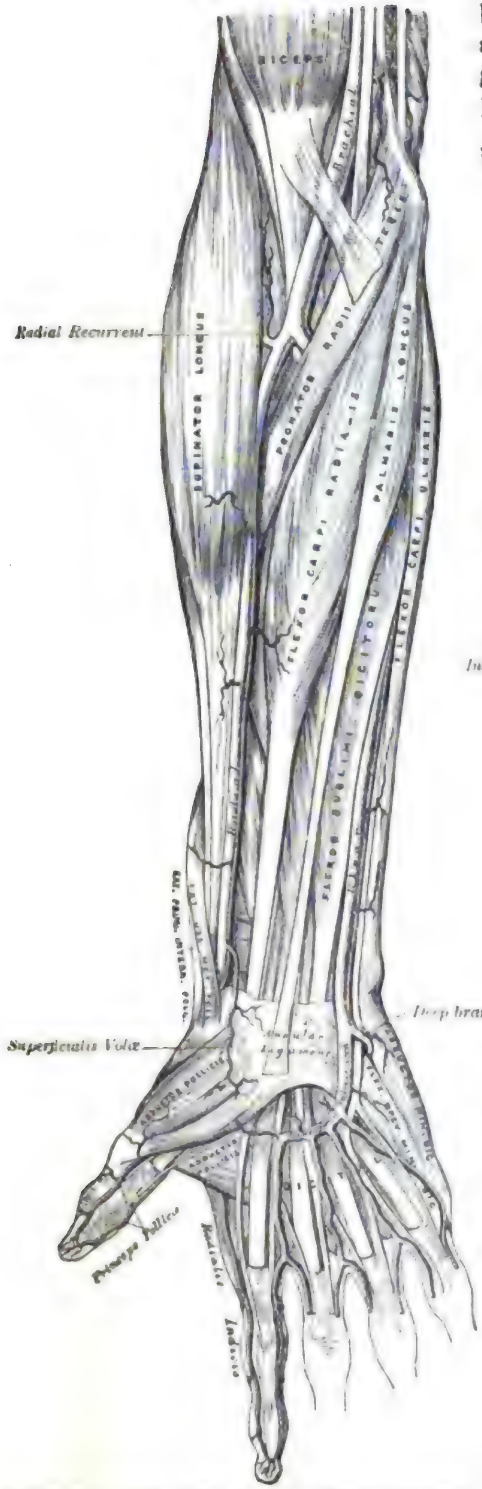
BICEPS
Brachial
TERES
Radial Recurrent
SUPINATOR LONGUS
PRONATOR RADII
FLEXOR CARPI RADIALIS
PALMARIS LONGUS
FLEXOR CARPI ULNARIS
FLEXOR SUBLIMIS DIGITORUM
Radial
Ulnar
EXT. PRIM. INTERN. POLL.
Annular Ligament
Deep branch of Ulnar
Superficialis Volæ
ABDUCTOR POLLICIS
ADDUCTOR POLLICIS
Princeps Pollicis
Radialis
Indicis

Surgical Anatomy of the Radial and Ulnar Arteries.

superficial palmar arch. At the lower border of the Adductor pollicis this vessel anastomoses with the princeps pollicis and gives a communicating branch to the superficial palmar arch.

FIG. 391.

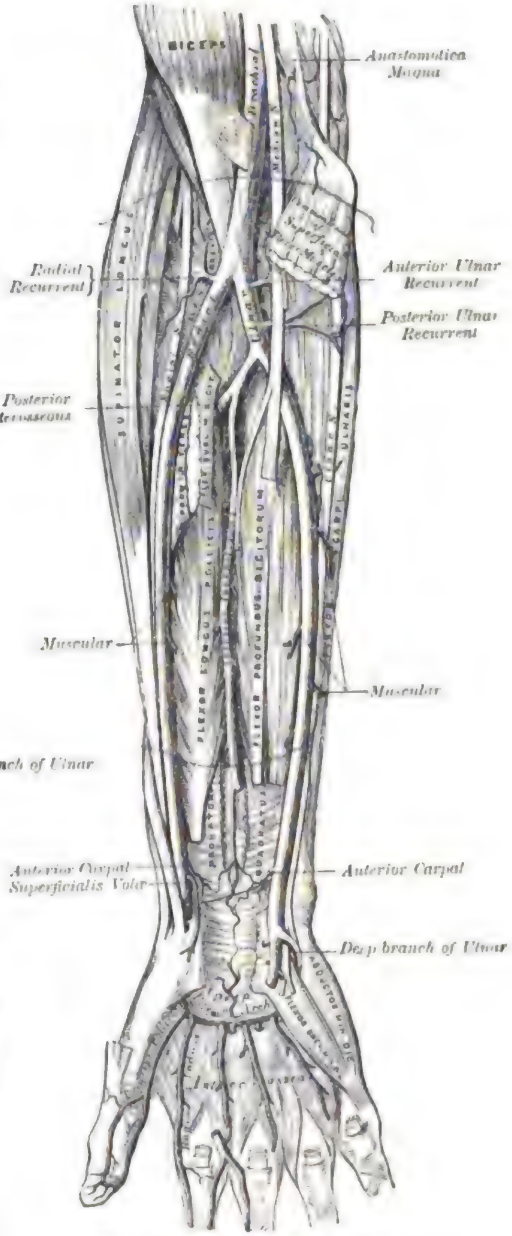
BICEPS
Brachial
Median N.
Anastomotica Magna
Radial Recurrent
SUPINATOR LONGUS
Anterior Ulnar Recurrent
Posterior Ulnar Recurrent
Posterior Interosseous
FLEXOR CARPI ULNARIS
FLEXOR LONGUS POLLICIS
FLEXOR PROFUNDUS DIGITORUM
Muscular
Muscular
PRONATOR QUADRATUS
Anterior Carpal
Superficialis Volæ
Anterior Carpal
Deep branch of Ulnar
ABDUCTOR MIN. DIG.
Interossei

Ulnar and Radial Arteries, deep view.

The **perforating arteries**, three in number, pass backward between the heads of the last three Dorsal interossei muscles to inosculate with the dorsal interosseous arteries.

The **palmar interosseous**, three or four in number, are branches of the deep palmar arch; they run forward upon the Interossei muscles and anastomose at the clefts of the fingers with the digital branches of the superficial arch.

ULNAR ARTERY.

The **Ulnar Artery**, the larger of the two subdivisions of the brachial, commences a little below the bend of the elbow, and crosses the inner side of the forearm obliquely inward to the commencement of its lower half; it then runs along its ulnar border to the wrist, crosses the annular ligament on the radial side of the pisiform bone, and passes across the palm of the hand, forming the superficial palmar arch, which sometimes terminates by inosculating with the superficialis volæ, but more frequently by anastomosing with a branch of the radialis indicis.

RELATIONS IN THE FOREARM.—In its *upper half* it is deeply seated, being covered by all the superficial Flexor muscles, excepting the Flexor carpi ulnaris; it is crossed by the median nerve, which lies to its inner side for about an inch, and it lies upon the Brachialis anticus and Flexor profundus digitorum muscles. In the *lower half* of the forearm it lies upon the Flexor profundus, being covered by the integument, the superficial and deep fasciæ, and is placed between the Flexor carpi ulnaris and Flexor sublimis digitorum muscles. It is accompanied by two venæ comites: the ulnar nerve lies on its inner side for the lower two-thirds of its extent, and a small branch from the nerve descends on the lower part of the vessel to the palm of the hand. [See Rule, p. 562.]

PLAN OF RELATIONS OF THE ULNAR ARTERY IN THE FOREARM.

In Front.

Superficial layer of flexor muscles. } Upper half.
Median nerve. }
Superficial and deep fasciæ. Lower half.

Inner Side.
Flexor carpi ulnaris.
Ulnar nerve (lower two-thirds).

Ulnar
Artery in
Forearm.

Outer Side.
Flexor sublimis digitorum.

Behind.
Brachialis anticus.
Flexor profundis digitorum.

At the wrist (Fig. 390) the ulnar artery is covered by the integument and fascia, and lies upon the anterior annular ligament. On its inner side is the pisiform bone. The ulnar nerve lies at the inner side and somewhat behind the artery.

In the palm of the hand the continuation of the ulnar artery is called the *superficial palmar arch;* it passes outward, describing a curve with its convexity to the fingers, to the interspace between the ball of the thumb and the index finger, where it occasionally anastomoses with the superficialis volæ, more frequently with a branch from the radialis indicis, thus completing the arch. If the thumb be put at right angles to the hand, the position of the superficial palmar arch will be roughly indicated by a line drawn along the lower margin of the thumb across the palm of the hand: the deep palmar arch is situated about a finger's breadth nearer to the carpus.

The superficial palmar arch is covered by the Palmaris brevis, the palmar fascia, and integument, and lies upon the annular ligament, the muscles of the little finger, the tendons of the superficial flexor, and the divisions of the median and ulnar nerves, the latter accompanying the artery a short part of its course.

Relations of the Superficial Palmar Arch.

In Front.	Ulnar Artery in Hand.	*Behind.*
Integument.		Annular ligament.
Palmaris brevis.		Origin of muscles of little finger.
Palmar fascia.		Superficial flexor tendons.
		Divisions of median and ulnar nerves.

Peculiarities.—The ulnar artery has been found to vary in its origin nearly in the proportion of one in thirteen cases, in one case arising lower than usual, about two or three inches below the elbow, and in all other cases much higher, the brachial being a more frequent source of origin than the axillary.

Variations in the position of this vessel are more frequent than in the radial. When its origin is normal the course of the vessel is rarely changed. When it arises high up, it is almost invariably superficial to the Flexor muscles in the forearm, lying commonly beneath the fascia, more rarely between the fascia and integument. In a few cases its position was subcutaneous in the upper part of the forearm, subaponeurotic in the lower part.

Surgical Anatomy.—The application of a ligature to this vessel is required in cases of wound of the artery or of its branches, or in consequence of aneurism. In the upper half of the forearm the artery is deeply seated beneath the superficial flexor muscles, and the application of a ligature in this situation is attended with some difficulty. An incision is to be made in the course of a line drawn from the front of the internal condyle of the humerus to the outer side of the pisiform bone, so that the centre of the incision is three fingers' breadth below the internal condyle. The skin and superficial fascia having been divided and the deep fascia exposed, the white line which separates the Flexor carpi ulnaris from the other flexor muscles is to be sought for, and the fascia incised in this line. The Flexor carpi ulnaris is now to be carefully separated from the other muscles, when the ulnar nerve will be exposed and must be drawn aside. Some little distance below the nerve the artery will be found accompanied by its venæ comites, and may be ligatured by passing the needle from within outward. In the middle and lower third of the forearm this vessel may be easily secured by making an incision on the radial side of the tendon of the Flexor carpi ulnaris: the deep fascia being divided, and the Flexor carpi ulnaris and its companion muscle, the Flexor sublimis, being separated from each other, the vessel will be exposed, accompanied by its venæ comites, the ulnar nerve lying on its inner side. The veins being separated from the artery, the ligature should be passed from the ulnar to the radial side, taking care to avoid the ulnar nerve.

The branches of the ulnar artery may be arranged in the following groups:

- *Forearm.*
  - Anterior Ulnar Recurrent.
  - Posterior Ulnar Recurrent.
  - Interosseous
    - Anterior Interosseous.
    - Posterior Interosseous.
  - Muscular.
- *Wrist.*
  - Anterior Carpal.
  - Posterior Carpal.
- *Hand.*
  - Deep or Communicating Branch.
  - Digital.

The **anterior ulnar recurrent** (Fig. 391) arises immediately below the elbow-joint, passes upward and inward between the Brachialis anticus and Pronator radii teres, supplies those muscles, and in front of the inner condyle anastomoses with the anastomotica magna and inferior profunda.

The **posterior ulnar recurrent** is much larger, and arises somewhat lower than the preceding. It passes backward and inward beneath the Flexor sublimis, and ascends behind the inner condyle of the humerus. In the interval between this process and the olecranon it lies beneath the Flexor carpi ulnaris, ascending between the heads of that muscle, beneath the ulnar nerve; it supplies the neighboring muscles and joint, and anastomoses with the inferior profunda, anastomotica magna, and interosseous recurrent arteries (Fig. 392).

The **interosseous artery** (Fig. 391) is a short trunk, about an inch in length and of considerable size, which arises immediately below the tuberosity of the radius, and, passing backward to the upper border of the interosseous membrane, divides into two branches, the *anterior* and *posterior interosseous*.

The **anterior interosseous** passes down the forearm on the anterior surface of the interosseous membrane, to which it is connected by a thin aponeurotic arch. It is accompanied by the interosseous branch of the median nerve, and overlapped by the contiguous margins of the Flexor profundus digitorum and Flexor longus pollicis muscles, giving off in this situation muscular branches and the nutrient arteries of the radius and ulna. At the upper border of the Pronator quadratus a branch descends beneath the muscle to anastomose in front of the carpus with branches from the anterior carpal and deep palmar arch. The continuation of the artery passes behind the Pronator quadratus (Fig. 392), and, piercing the interosseous membrane, anastomoses with the posterior interosseous artery. It then descends to the back of the wrist to join the posterior carpal arch. The anterior interosseous gives off a long, slender branch which accompanies the median nerve and gives offsets to its substance. This, the *median artery*, is sometimes much enlarged.

FIG. 392.

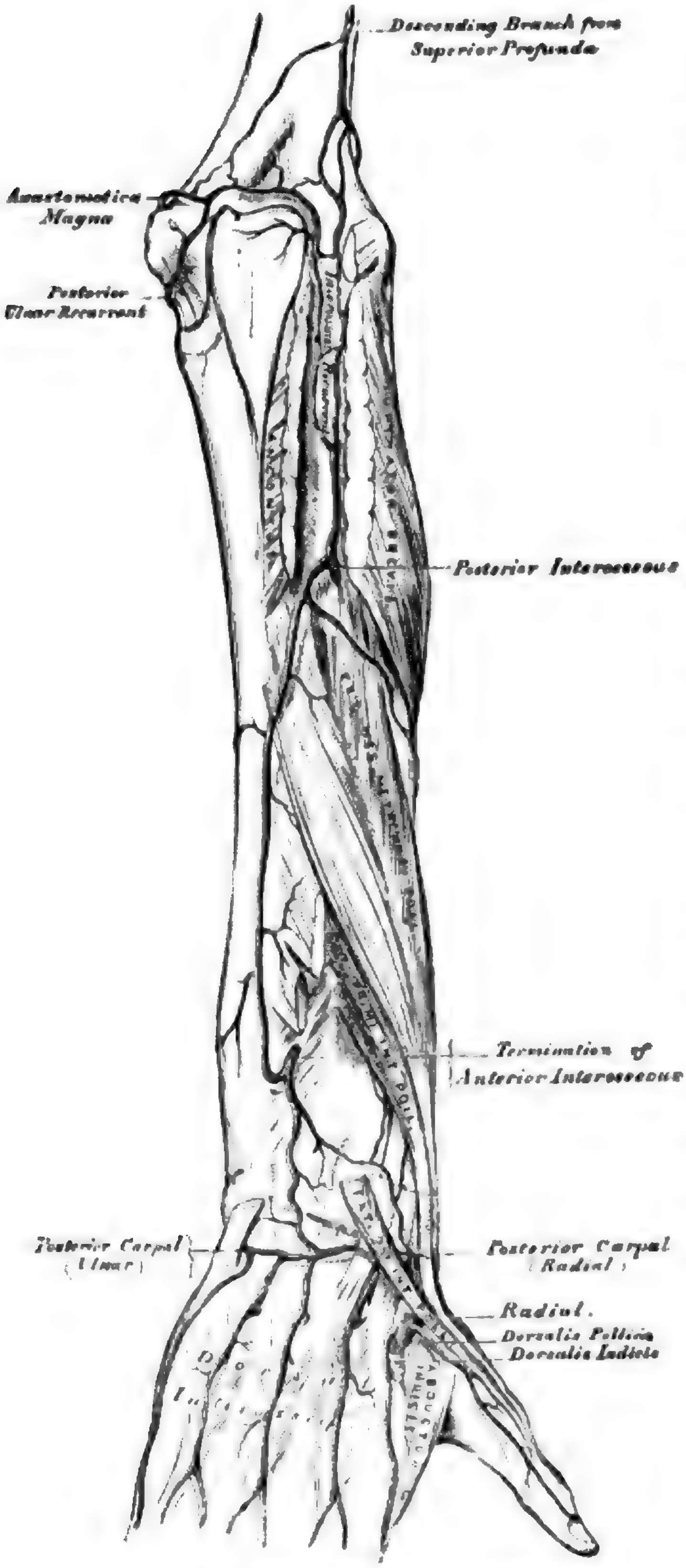
Descending Branch from Superior Profunda
Anastomotica Magna
Posterior Ulnar Recurrent
Posterior Interosseous
Termination of Anterior Interosseous
Posterior Carpal (Ulnar)
Posterior Carpal (Radial)
Radial.
Dorsalis Pollicis
Dorsalis Indicis

Arteries of the Back of the Forearm and Hand.

The **posterior interosseous artery** passes backward through the interval between the oblique ligament and the upper border of the interosseous membrane. It appears between the contiguous borders of the Supinator brevis and the Extensor ossis metacarpi pollicis, and runs down the back part of the forearm between the superficial and deep layer of muscles, to both of which it distributes branches. Descending to the back of the wrist, it anastomoses with the termination of the anterior interosseous and with the posterior carpal branches of the radial and ulnar arteries. This artery gives off near its origin the *interosseous recurrent* branch, a large vessel which ascends to the interval between the external condyle and olecranon on or through the fibres of the Supinator brevis, but beneath the Anconeus, anastomosing with a branch from the superior profunda and with the posterior ulnar recurrent and anastomotica magna.

The **muscular branches** are distributed to the muscles along the ulnar side of the forearm.

The **carpal branches** are intended for the supply of the wrist-joint.

The **anterior carpal** is a small vessel which crosses the front of the carpus beneath the tendons of the Flexor profundus, and inosculates with a corresponding branch of the radial artery.

The **posterior carpal** arises immediately above the pisiform bone, and winds backward beneath the tendon of the Flexor carpi ulnaris; it passes across the dorsal surface of the carpus beneath the extensor tendons, anastomosing with a corresponding branch of the radial artery and forming the *posterior carpal arch.* Immediately after its origin it gives off a small branch which runs along the ulnar side of the metacarpal bone of the little finger, forming one of the *metacarpal* arteries, and supplies the ulnar side of the dorsal surface of the little finger.

The **deep or communicating branch** (Fig. 391, p. 565) arises at the commencement of the palmar arch, and passes deeply inward between the Abductor minimi digiti and Flexor brevis minimi digiti near their origins; it anastomoses with the termination of the radial artery, completing the deep palmar arch.

The **digital branches** (Fig. 390, p. 565), four in number, are given off from the convexity of the superficial palmar arch. They supply the ulnar side of the little finger and the adjoining sides of the little, ring, middle, and index fingers, the radial side of the index finger and thumb being supplied from the radial artery. The digital arteries at first lie superficial to the flexor tendons, but as they pass forward with the digital nerves to the clefts between the fingers, they lie between them, and are there joined by the interosseous branches from the deep palmar arch. The digital arteries on the sides of the fingers lie beneath the digital nerves, and about the middle of the last phalanx the two branches for each finger form an arch, from the convexity of which branches pass to supply the matrix of the nail.

THE DESCENDING AORTA.

The **Descending Aorta** is divided into two portions, the *thoracic* and *abdominal*, in correspondence with the two great cavities of the trunk in which it is situated.

The **Thoracic Aorta** commences at the lower border of the fifth dorsal vertebra, on the left side, and terminates at the aortic opening in the Diaphragm, in front of the last dorsal vertebra. At its commencement it is situated on the left side of the spine; it approaches the median line as it descends, and at its termination lies directly in front of the column. The direction of this vessel being influenced by the spine, upon which it rests, it describes a curve which is concave forward in the dorsal region. As the branches given off from it are small, the diminution in the size of the vessel is inconsiderable. It is contained in the back part of the posterior mediastinum, being in relation *in front*, from above downward, with the left pulmonary artery, the left bronchus, the pericardium, and the œsophagus; *behind*, with the vertebral column and the vena azygos minor; on the *right side*, with the vena azygos major and thoracic duct; on the *left side*, with the left pleura and lung. The œsophagus, with its accompanying nerves, lies on the right side of the aorta *above*, but at the lower part of the thorax it gets in front of the aorta, and close to the Diaphragm is situated to its left side.

PLAN OF THE RELATIONS OF THE THORACIC AORTA.

In Front.
Left pulmonary artery.
Left bronchus.
Pericardium.
Œsophagus.

Right Side.
Œsophagus (above).
Vena azygos major.
Thoracic duct.

Thoracic
Aorta.

Left Side.
Pleura.
Left lung.
Œsophagus (below).

Behind.
Vertebral column.
Vena azygos minor.

Surgical Anatomy.—The student should now consider the effects likely to be produced by aneurism of the thoracic aorta, a disease of common occurrence. When we consider the great depth of the vessel from the surface and the number of important structures which surround it on every side, it may easily be conceived what a variety of obscure symptoms may arise from disease of this part of the arterial system, and how they may be liable to be mistaken for those of other affections. Aneurism of the thoracic aorta most usually extends backward along the left side of the spine, producing absorption of the bodies of the vertebræ, with curvature of the spine, whilst the irritation or pressure on the cord will give rise to pain either in the chest, back, or loins, with radiating pain in the left upper intercostal spaces from pressure on the intercostal nerves: at the same time, the tumor may project backward on each side of the spine, beneath the integument, as a pulsating swelling, simulating abscesses connected with diseased bone, or it may displace the œsophagus and compress the lung on one or the other side. If the tumor extend forward, it may press upon and displace the heart, giving rise to palpitation and other symptoms of disease of that organ; or it may displace, or even compress, the œsophagus, causing pain and difficulty of swallowing, as in stricture of that tube, and ultimately even open into it by ulceration, producing fatal hemorrhage. If the disease extends to the right side, it may press upon the thoracic duct, or it may burst into the pleural cavity or into the trachea or lung, and, lastly, it may open into the posterior mediastinum.

The aorta is comparatively often found to be obliterated at a particular spot—viz. at the junction of the arch with the thoracic aorta, just below the ductus arteriosus. Whether this is the result of disease or of congenital malformation is immaterial to our present purpose; it affords an interesting opportunity of observing the resources of the collateral circulation. The course of the anastomosing vessels by which the blood is brought from the upper to the lower part of the artery will be found well described in an account of two cases in the *Pathological Transactions*, vols. viii. and x. In the former (p. 162), Mr. Sydney Jones thus sums up the detailed description of the anastomosing vessels: "The principal communications by which the circulation was carried on, were—Firstly, the internal mammary, anastomosing with the intercostal arteries, with the phrenic of the abdominal aorta by means of the musculo-phrenic and comes nervi phrenici, and largely with the deep epigastric. Secondly, the superior intercostal, anastomosing anteriorly by means of a large branch with the first aortic intercostal, and posteriorly with the posterior branch of the same artery. Thirdly, the inferior thyroid, by means of a branch about the size of an ordinary radial, formed a communication with the first aortic intercostal. Fourthly, the transversalis colli, by means of very large communications with the posterior branches of the intercostals. Fifthly, the branches (of the subclavian and axillary) going to the side of the chest were large, and anastomosed freely with the lateral branches of the intercostals." In the second case also (vol. x. p. 97), Mr. Wood describes the anastomoses in a somewhat similar manner, adding the remark, that "the blood which was brought into the aorta through the anastomoses of the intercostal arteries appeared to be expended principally in supplying the abdomen and pelvis, while the supply to the lower extremities had passed through the internal mammary and epigastric."

BRANCHES OF THE THORACIC AORTA.

Pericardiac.
Bronchial.
Œsophageal.
Posterior Mediastinal.
Intercostal.

The **pericardiac** are a few small vessels, irregular in their origin, distributed to the pericardium.

The **bronchial** arteries are the nutrient vessels of the lungs, and vary in number, size, and origin. That of the right side arises from the first aortic intercostal, or by a common trunk with the left bronchial, from the front of the thoracic aorta. Those of the left side, usually two in number, arise from the thoracic aorta, one a little lower than the other. Each vessel is directed to the back part of the corresponding bronchus, along which they run, dividing and subdividing upon the bronchial tube, supplying them, the cellular tissue of the lungs, the bronchial glands, and the œsophagus.

The **œsophageal** arteries, usually four or five in number, arise from the front of the aorta and pass obliquely downward to the œsophagus, forming a chain of anastomoses along that tube, anastomosing with the œsophageal branches of the inferior thyroid arteries above and with ascending branches from the phrenic and gastric arteries below.

The **posterior mediastinal** arteries are numerous small vessels which supply the glands and loose areolar tissue in the mediastinum.

The **intercostal** arteries arise from the back part of the aorta. They are usually ten in number on each side, the superior intercostal space (and occasionally the second one) being supplied by the superior intercostal, a branch of the subclavian. The right intercostals are longer than the left, on account of the position of the aorta on the left side of the spine; they pass outward, across the bodies of the vertebræ, to the intercostal spaces, being covered by the pleura, the œsophagus, thoracic duct, sympathetic nerve, and the vena azygos major; the left passing beneath the superior intercostal vein, the vena azygos minor, and sympathetic. In the intercostal spaces each artery divides into two branches—an anterior or proper intercostal branch, and a posterior or dorsal branch.[1]

The **anterior branch** passes outward, at first lying upon the External intercostal muscle, covered in front by the pleura and a thin fascia. It then passes between the two layers of Intercostal muscles, and, having ascended obliquely to the lower border of the rib above, divides near the angle of that bone into two branches: of these, the larger runs in the groove on the lower border of the rib above, the smaller branch along the upper border of the rib below; passing forward, they supply the Intercostal muscles and anastomose with the anterior intercostal branches of the internal mammary and with the thoracic branches of the axillary artery. The first aortic intercostal anastomoses with the superior intercostal, and the last three pass between the abdominal muscles, inosculating with the epigastric in front and with the lumbar arteries. Each intercostal artery is accompanied by a vein and nerve, the former being above and the latter below, except in the upper intercostal spaces, where the nerve is at first above the artery. The arteries are protected from pressure during the action of the Intercostal muscles by fibrous arches thrown across and attached by each extremity to the bone.

The **posterior** or **dorsal branch** of each intercostal artery passes backward to the inner side of the anterior costo-transverse ligament, and divides into a spinal branch, which supplies the vertebræ, the spinal cord, and its membranes; and a muscular branch, which is distributed to the muscles and integument of the back.

THE ABDOMINAL AORTA (Fig. 393).

The **Abdominal Aorta** commences at the aortic opening of the Diaphragm, in front of the body of the last dorsal vertebra, and, descending a little to the left side of the vertebral column, terminates on the body of the fourth lumbar vertebra, commonly a little to the left of the middle line,[2] where it divides into the two common iliac arteries. It diminishes rapidly in size in consequence of the many large branches which it gives off. As it lies upon the bodies of the vertebræ the curve which it describes is convex forward, the greatest convexity corresponding to the third lumbar vertebra, which is a little above and to the left side of the umbilicus.

---

[1] Mr. W. J. Walsham describes a small twig as being given off from each intercostal close to their origin. He states that they can be traced running between the neck of the rib and the transverse process of the corresponding vertebra; they anastomose with similar twigs given off from the intercostal artery next below. In the first and second spaces similar anastomosing twigs are given off from the superior intercostal (*Journal of Anatomy and Physiology*, vol. xvi. part iii. p. 443).

[2] Sir Joseph Lister, having accurately examined 30 bodies in order to ascertain the exact point of termination of this vessel, found it "either absolutely or almost absolutely mesial in 15, while in 13 it deviated more or less to the left, and in 2 was slightly to the right" (*Syst. of Surg.*, edited by T. Holmes, 2d ed., vol. v. p. 652).

Relations.—It is covered *in front* by the lesser omentum and stomach, behind which are the branches of the cœliac axis and the solar plexus; below these, by the splenic vein, the pancreas, the left renal vein, the transverse portion of the duodenum, the mesentery, and aortic plexus. *Behind* it is separated from the lumbar vertebræ by the left lumbar veins, the receptaculum chyli, and thoracic duct. On the *right side* it is in relation with the inferior vena cava (the right crus of the Diaphragm being interposed above), the vena azygos, thoracic duct, and right semilunar ganglion; on the *left side*, with the sympathetic nerve and left semilunar ganglion.

Fig. 393.

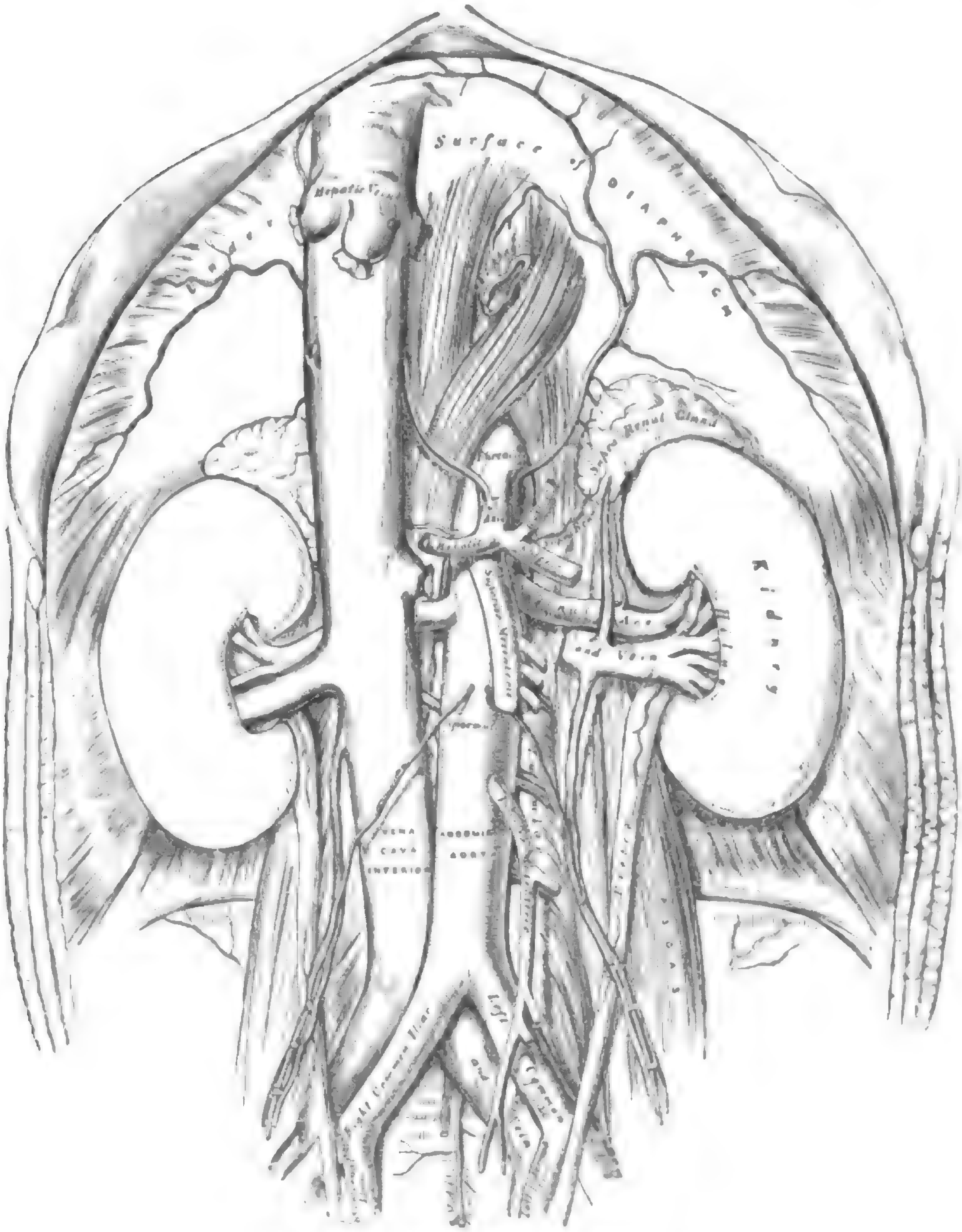

The Abdominal Aorta and its Branches.

PLAN OF THE RELATIONS OF THE ABDOMINAL AORTA.

In Front.

Lesser omentum and stomach.
Branches of the cœliac axis and solar plexus.
Splenic vein.
Pancreas.
Left renal vein.
Transverse duodenum.
Mesentery.
Aortic plexus.

Right Side.

Right crus of diaphragm.
Inferior vena cava.
Vena azygos.
Thoracic duct.
Right semilunar ganglion.

Abdominal Aorta.

Left Side.

Sympathetic nerve.
Left semilunar ganglion.

Behind.

Left lumbar veins.
Receptaculum chyli.
Thoracic duct.
Vertebral column.

Surgical Anatomy.—Aneurisms of the abdominal aorta near the cœliac axis communicate in nearly equal proportion with the anterior and posterior parts of the artery.

When an aneurismal sac is connected with the back part of the abdominal aorta, it usually produces absorption of the bodies of the vertebræ, and forms a pulsating tumor that presents itself in the left hypochondriac or epigastric regions, accompanied by symptoms of disturbance in the alimentary canal. Pain is invariably present, and is usually of two kinds—a fixed and constant pain in the back, caused by the tumor pressing on or displacing the branches of the solar plexus and splanchnic nerves, and a sharp lancinating pain radiating along those branches of the lumbar nerves which are pressed on by the tumor; hence the pain in the loins, the testes, the hypogastrium, and in the lower limb (usually of the left side). This form of aneurism usually bursts into the peritoneal cavity or behind the peritoneum in the left hypochondriac region; or it may form a large aneurismal sac extending down as low as Poupart's ligament, hemorrhage in these cases being generally very extensive, but slowly produced and not rapidly fatal.

When an aneurismal sac is connected with the front of the aorta near the cœliac axis, it forms a pulsating tumor in the left hypochondriac or epigastric regions, usually attended with symptoms of disturbance of the alimentary canal, as sickness, dyspepsia, or constipation, and accompanied by pain, which is constant, but nearly always fixed in the loins, epigastrium, or some part of the abdomen, the radiating pain being rare, as the lumbar nerves are seldom implicated. This form of aneurism may burst into the peritoneal cavity or behind the peritoneum, between the layers of the mesentery, or more rarely into the duodenum; it rarely extends backward, so as to affect the spine.

The abdominal aorta has been tied several times, and although none of the patients permanently recovered, still, as one of them lived as long as ten days, the possibility of the re-establishment of the circulation may be considered to be proved. In the lower animals this artery is often successfully tied. The vessel may be reached in several ways. In the original operation, performed by Sir A. Cooper, an incision was made in the linea alba, the peritoneum opened in front, the finger carried down amongst the intestines toward the spine, the peritoneum again opened behind by scratching through the mesentery, and the vessel thus reached. Or either of the operations described below for securing the common iliac artery may, by extending the dissection a sufficent distance upward, be made use of to expose the aorta. The chief difficulty in the dead subject consists in isolating the artery, in consequence of its great depth; but in the living subject the embarrassment resulting from the proximity of the aneurismal tumor and the great probability of disease in the vessel itself add to the dangers and difficulties of this formidable operation so greatly that it is very doubtful whether it ought ever to be performed. [For the most recent investigations and operations for the cure of aortic aneurism by the introduction of catgut or wire, and the use of electricity therewith, see Dr. Robert Abbe's paper in the *Medical News*, April 9, 1887.]

The collateral circulation would be carried on by the anastomosis between the internal mammary and the epigastric, by the free communication between the superior and inferior mesenterics if the ligature were placed above the latter vessel, or by the anastomosis between the inferior mesenteric and the internal pudic when (as is more common) the point of ligature is below the origin of the inferior mesenteric, and possibly by the anastomoses of the lumbar arteries with the branches of the internal iliac.

The circulation through the abdominal aorta may be commanded in thin persons by firm pressure with the fingers. A tourniquet has been invented for this purpose which is of the greatest use in amputation at the hip-joint and some other operations. [See p. 584.]

Branches of the Abdominal Aorta.

- Phrenic.
- Cœliac Axis.
  - Gastric.
  - Hepatic.
  - Splenic.
- Superior Mesenteric.
- Suprarenal.
- Renal.
- Spermatic.
- Inferior Mesenteric.
- Lumbar.
- Sacra media.

The branches may be divided into two sets: 1, those supplying the viscera; 2, those distributed to the walls of the abdomen.

Visceral Branches.

- Cœliac Axis.
  - Gastric.
  - Hepatic.
  - Splenic.
- Superior Mesenteric.
- Inferior Mesenteric.
- Suprarenal.
- Renal.
- Spermatic.

Parietal Branches.

- Phrenic.
- Lumbar.
- Sacra media.

Cœliac Axis (Fig. 395).

To expose this artery, raise the liver, draw down the stomach, and then tear through the layers of the lesser omentum.

The **Cœliac Axis** is a short thick trunk, about half an inch in length, which arises from the aorta opposite the margin of the Diaphragm, and, passing nearly horizontally forward (in the erect posture), divides into three large branches—the *gastric*, *hepatic*, and *splenic*—occasionally giving off one of the phrenic arteries.

[Fig. 394.

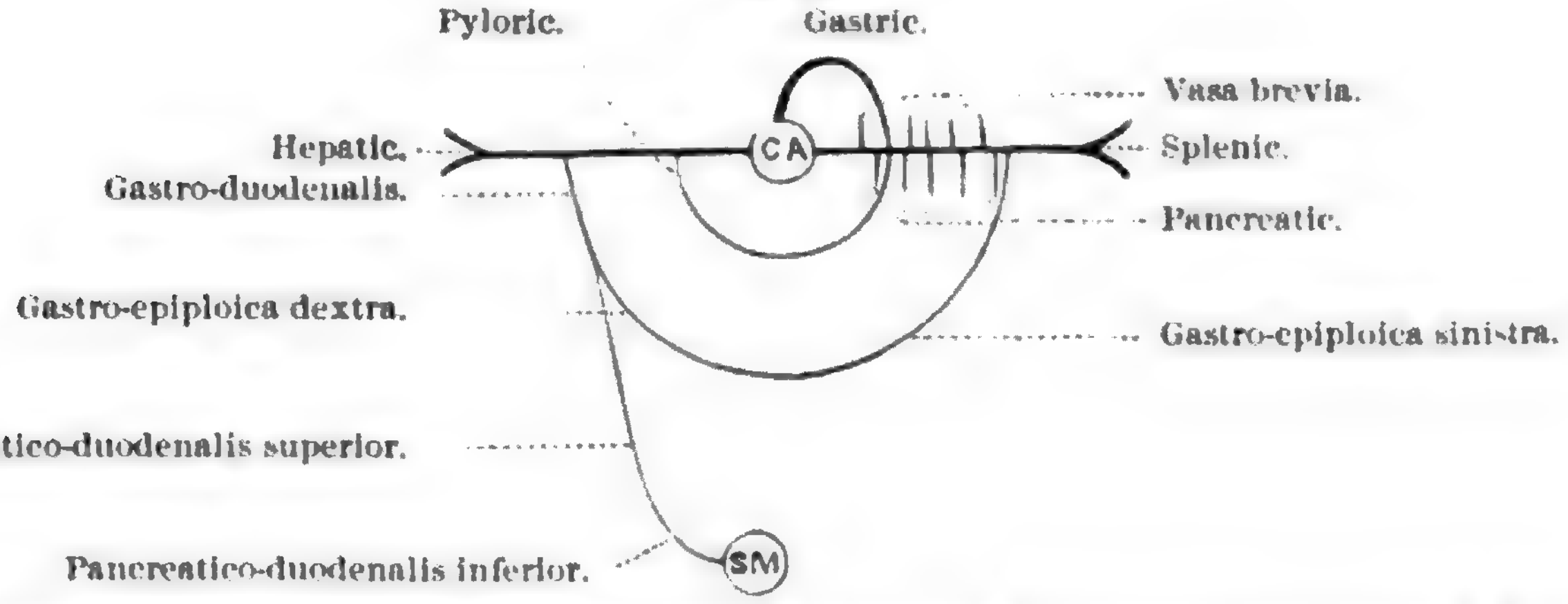

Diagram of the Branches of the Cœliac Axis: CA, cœliac axis; SM, superior mesenteric.—W. W. K.]

Relations.—It is covered by the lesser omentum. On the *right side* it is in relation with the right semilunar ganglion and the lobus Spigelii; on the *left side*, with the left semilunar ganglion and cardiac end of the stomach. *Below* it rests upon the upper border of the pancreas.

The **Gastric Artery** (*coronaria ventriculi*), the smallest of the three branches of the cœliac axis, passes upward and to the left side, to the cardiac orifice of the stomach, distributing branches to the œsophagus which anastomose with the aortic œsophageal arteries; others supply the cardiac end of the stomach, inosculating with branches of the splenic artery: it then passes from left to right along the lesser curvature of the stomach to the pylorus, lying in its course between the layers of the lesser omentum, and giving branches to both surfaces of the organ: at its termination it anastomoses with the pyloric branch of the hepatic.

The **Hepatic Artery** in the adult is intermediate in size between the gastric and splenic; in the fœtus it is the largest of the three branches of the cœliac axis. It is first directed forward and to the right, to the upper margin of the pyloric orifice of the stomach, forming the lower boundary of the foramen of Winslow. It then passes upward between the layers of the lesser omentum and in front of the foramen of Winslow to the transverse fissure of the liver, where it divides into two branches, right and left, which supply the corresponding lobes of that organ, accompanying the ramifications of the vena portæ and hepatic duct. The hepatic artery, in its course along the right border of the lesser omentum, is in relation with the ductus communis choledochus and portal veins, the duct lying to the right of the artery and the vena portæ behind.

Fig. 395.

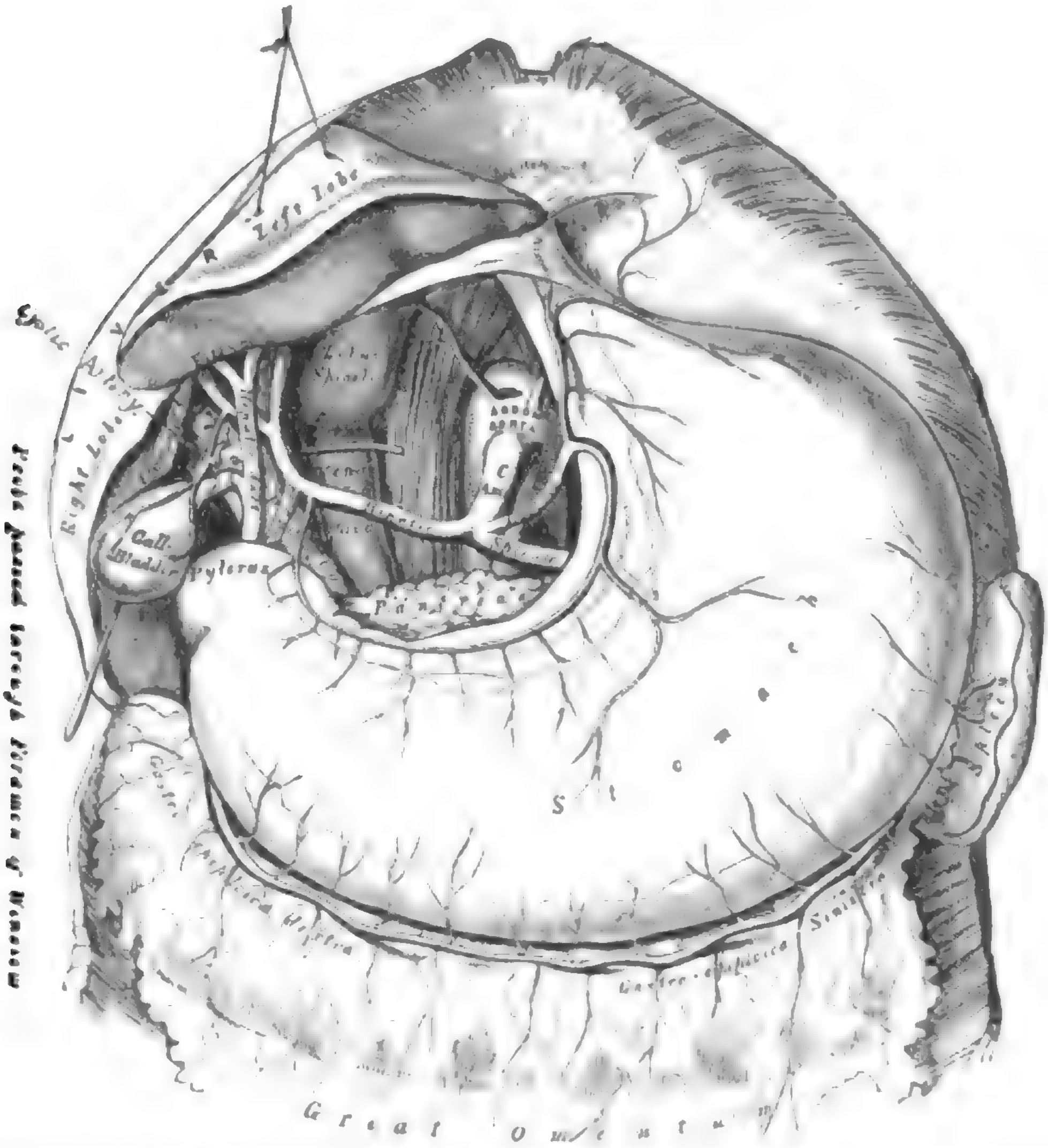
Left lobe
Hepatic Artery
Right Lobe
Probe passed through foramen of Winslow
Gall Bladder
Pylorus
Pancreas
Gastro-epiploica Dextra
Gastro-epiploica Sinistra
Spleen
S t o
Great Omentum

The Cœliac Axis and its Branches, the liver having been raised and the lesser omentum removed.

Its branches are the

Pyloric.
Gastro-duodenalis. { Gastro-epiploica dextra. / Pancreatico-duodenalis superior.
Cystic.

The **pyloric branch** arises from the hepatic above the pylorus, descends to the pyloric end of the stomach, and passes from right to left along its lesser curvature, supplying it with branches and inosculating with the gastric artery.

The **gastro-duodenalis** (Fig. 396) is a short but large branch which descends behind the duodenum near the pylorus, and divides at the lower border of the stomach into two branches—the *gastro-epiploica dextra* and the *pancreatico-duo-*

denalis superior. Previous to its division it gives off two or three small inferior pyloric branches to the pyloric end of the stomach and pancreas.

The **gastro-epiploica dextra** runs from right to left along the greater curvature of the stomach, between the layers of the great omentum, anastomosing about the middle of the lower border of the stomach with the gastro-epiploica sinistra from the splenic artery. This vessel gives off numerous branches, some of which ascend to supply both surfaces of the stomach, whilst others descend to supply the great omentum.

The **pancreatico-duodenalis superior** descends between the contiguous margins of the duodenum and pancreas. It supplies both these organs, and anastomoses with the inferior pancreatico-duodenal branch of the superior mesenteric artery, and with the pancreatic branches of the splenic.

FIG. 396.

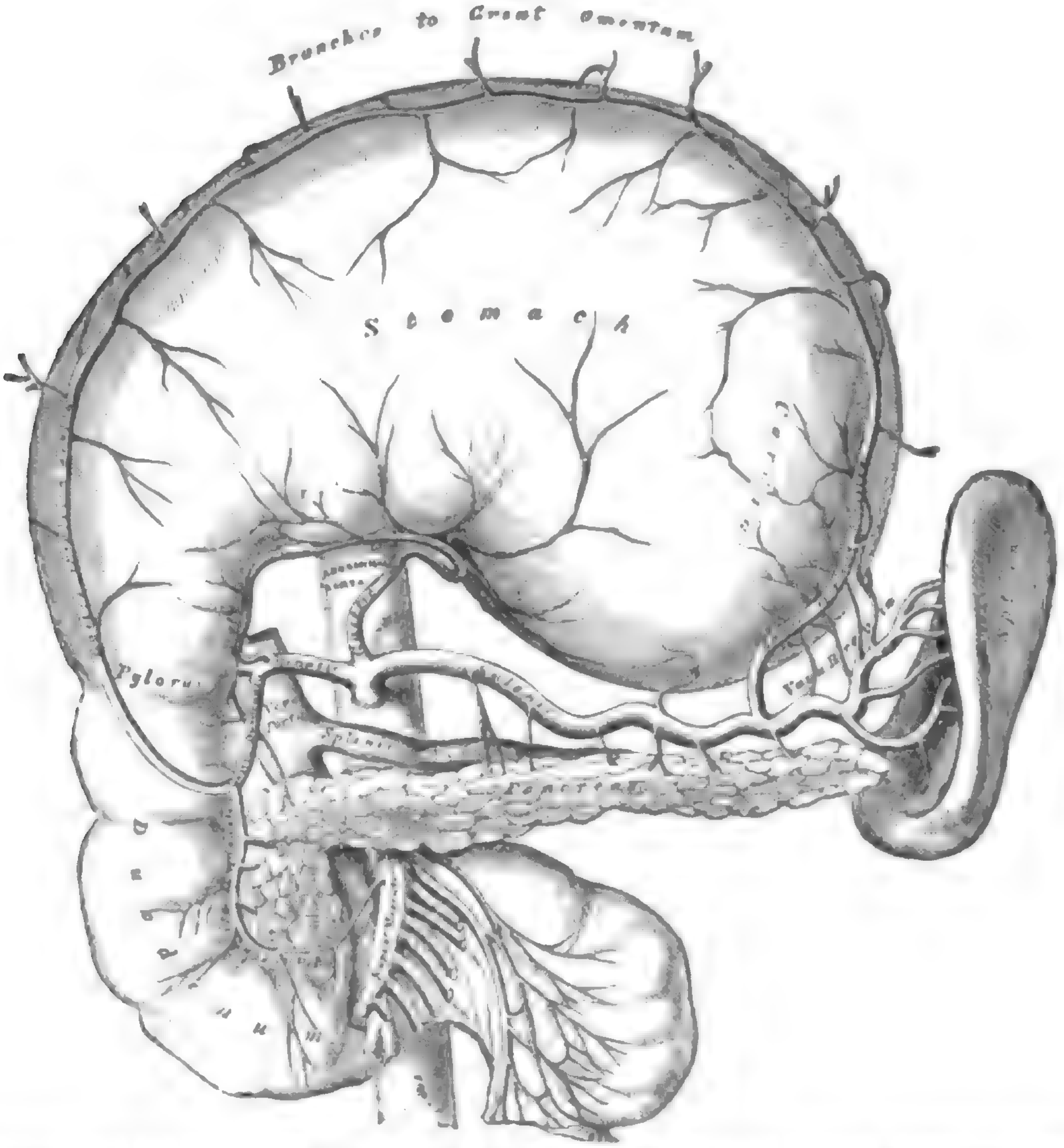

The Cœliac Axis and its Branches, the stomach having been raised and the transverse mesocolon removed.

In ulceration of the duodenum, which frequently occurs in connection with severe burns, this artery may be involved, and death may occur from hemorrhage into the intestinal canal.

The **Cystic Artery** (Fig. 395), usually a branch of the right hepatic, passes upward and forward along the neck of the gall-bladder, and divides into two branches, one of which ramifies on its free surface, the other between it and the substance of the liver.

The **Splenic Artery**, in the adult, is the largest of the three branches of the cœliac axis, and is remarkable for the extreme tortuosity of its course. It passes horizontally to the left side along the upper border of the pancreas, accompanied by the splenic vein, which lies below it, and on arriving near the spleen divides into branches, some of which enter the hilum of that organ to be distributed to its structure, whilst others are distributed to the great end of the stomach.

Pancreaticæ parvæ.	Gastric (Vasa brevia).
Pancreatica magna.	Gastro-epiploica sinistra.

The **pancreatic** are numerous small branches derived from the splenic as it runs behind the upper border of the pancreas, supplying its middle and left parts. One of these, larger than the rest, is given off from the splenic near the left extremity of the pancreas; it runs from left to right near the posterior surface of the gland, following the course of the pancreatic duct, and is called the *pancreatica magna.* These vessels anastomose with the pancreatic branches of the pancreatico-duodenal arteries, derived from the hepatic on the one hand and superior mesenteric on the other.

The **gastric (vasa brevia)** consist of from five to seven small branches, which arise either from the termination of the splenic artery or from its terminal branches, and, passing from left to right between the layers of the gastro-splenic omentum, are distributed to the great curvature of the stomach, anastomosing with branches of the gastric and gastro-epiploica sinistra arteries.

The **gastro-epiploica sinistra,** the largest branch of the splenic, runs from left to right along the great curvature of the stomach, between the layers of the great omentum, and anastomoses with the gastro-epiploica dextra. In its course it distributes several branches to the stomach, which ascend upon both surfaces; others descend to supply the omentum.

SUPERIOR MESENTERIC ARTERY (Fig. 397).

In order to expose this vessel raise the great omentum and transverse colon, draw down the small intestines, and cut through the peritoneum where the transverse mesocolon and mesentery join: the artery will then be exposed just as it issues from beneath the lower border of the pancreas.

The **Superior Mesenteric Artery** supplies the whole length of the small intestine, except the first part of the duodenum; it also supplies the cæcum, ascending and transverse colon; it is a vessel of large size, arising from the fore part of the aorta about a quarter of an inch below the cœliac axis, being covered at its origin by the splenic vein and pancreas. It passes forward between the pancreas and transverse portion of the duodenum, crosses in front of this portion of the intestine, and descends between the layers of the mesentery to the right iliac fossa, where it terminates, considerably diminished in size. In its course it forms an arch, the convexity of which is directed forward and downward to the left side, the concavity backward and upward to the right. It is accompanied by the superior mesenteric vein and is surrounded by the superior mesenteric plexus of nerves. Its branches are the

Inferior Pancreatico-duodenal.	Ileo-colic.
Vasa intestini tenuis.	Colica dextra.
Colica media.	

The **inferior pancreatico-duodenal** is given off from the superior mesenteric behind the pancreas, and is distributed to the head of the pancreas with the transverse and descending portions of the duodenum, anastomosing with the superior pancreatico-duodenal artery.

The **vasa intestini tenuis** [*i. e.* vessels of the small intestine] arise from the convex side of the superior mesenteric artery. They are usually from twelve to fifteen in number, and are distributed to the jejunum and ileum. They run parallel with one another between the layers of the mesentery, each vessel dividing into two branches, which unite with a similar branch on each side, forming a series of arches, the convexities of which are directed toward the intestine. From this

Fig. 397.

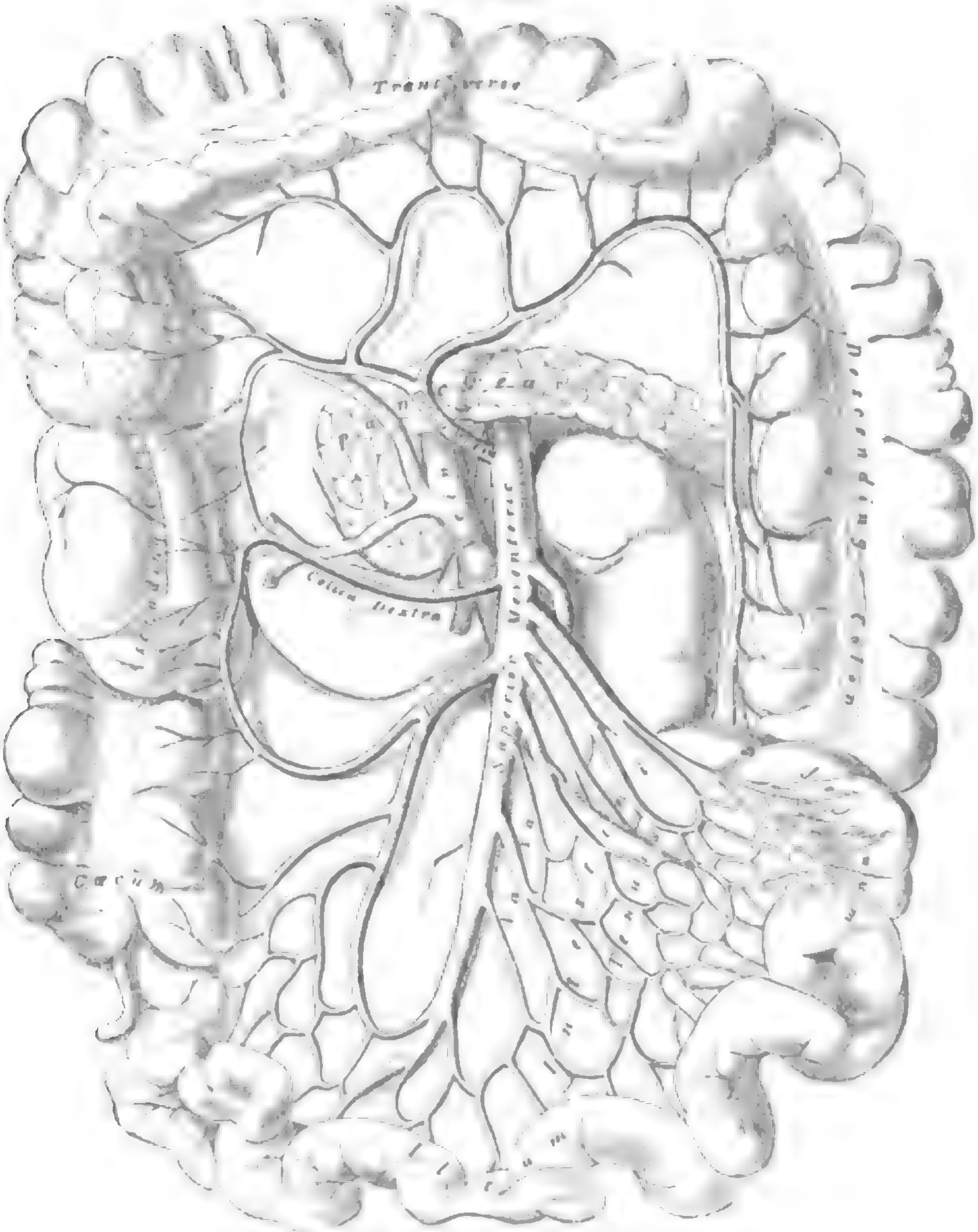
Transverse
Descending Colon
Colica Dextra
Superior Mesenteric
Cæcum

The Superior Mesenteric Artery and its Branches.

first set of arches branches arise, which again unite with similar branches from either side, and thus a second series of arches is formed; and from these latter a

[Fig. 398.

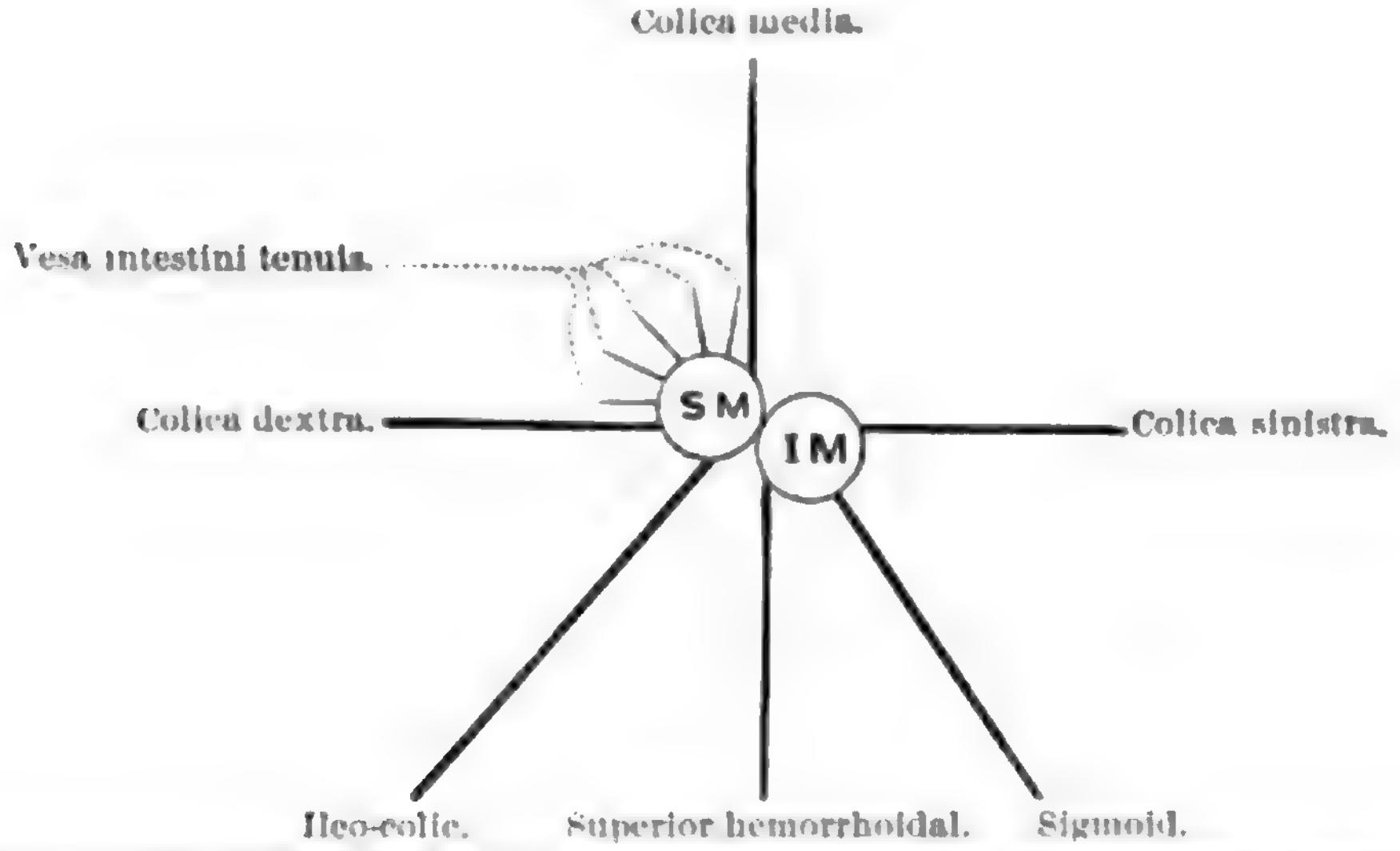
Colica media.
Vasa intestini tenuis.
Colica dextra.
SM
IM
Colica sinistra.
Ileo-colic.
Superior hemorrhoidal.
Sigmoid.

Diagram of the Mesenteric Arteries: SM, superior mesenteric artery; IM, inferior mesenteric artery.—W. W. K.]

third and a fourth, or even a fifth, series of arches are constituted, diminishing in size the nearer they approach the intestine. From the terminal arches numerous small straight vessels arise which encircle the intestine, upon which they are distributed, ramifying thickly between its coats.

The **ileo-colic artery** is the lowest branch given off from the concavity of the superior mesenteric artery. It descends between the layers of the mesentery to the right iliac fossa, where it divides into two branches. Of these, the inferior one inosculates with the lowest branches of the vasa intestini tenuis, from the convexity of which branches proceed to supply the termination of the ileum, the cæcum and appendix cæci, and the ileo-cæcal valve. The superior division inosculates with the colica dextra and supplies the commencement of the colon.

The **colica dextra** arises from about the middle of the concavity of the superior mesenteric artery, and, passing beneath the peritoneum to the middle of the ascending colon, divides into two branches—a descending branch, which inosculates with the ileo-colic; and an ascending branch, which anastomoses with the colica media. These branches form arches, from the convexity of which vessels are distributed to the ascending colon. The branches of this vessel are covered with peritoneum only on their anterior aspect.

The **colica media** arises from the upper part of the concavity of the superior mesenteric, and, passing forward between the layers of the transverse mesocolon, divides into two branches, the one on the right side inosculating with the colica dextra, that on the left side with the colica sinistra, a branch of the inferior mesenteric. From the arches formed by their inosculation branches are distributed to the transverse colon. The branches of this vessel lie between two layers of peritoneum.

INFERIOR MESENTERIC ARTERY (Fig. 399).

In order to expose this vessel draw the small intestines and mesentery over to the right side of the abdomen, raise the transverse colon toward the thorax, and divide the peritoneum covering the left side of the aorta.

The **inferior mesenteric artery** supplies the descending and sigmoid flexure of the colon and the greater part of the rectum. It is smaller than the superior mesenteric, and arises from the left side of the aorta, between one and two inches above its division into the common iliacs. It passes downward to the left iliac fossa, and then descends between the layers of the mesorectum into the pelvis, under the name of the *superior hemorrhoidal artery*. It lies at first in close relation with the left side of the aorta, and then passes as the superior hemorrhoidal in front of the left common iliac artery. Its branches are the

Colica sinistra. Sigmoid.
Superior Hemorrhoidal.

The **colica sinistra** passes behind the peritoneum, in front of the left kidney, to reach the descending colon, and divides into two branches—an ascending branch, which inosculates with the colica media, and a descending branch, which anastomoses with the sigmoid artery. From the arches formed by these inosculations branches are distributed to the descending colon.

The **sigmoid artery** runs obliquely downward across the Psoas muscle to the sigmoid flexure of the colon, and divides into branches which supply that part of the intestine, anastomosing above with the colica sinistra, and below with the superior hemorrhoidal artery. This vessel is sometimes replaced by three or four small branches.

The **superior hemorrhoidal artery**, the continuation of the inferior mesenteric, descends into the pelvis between the layers of the mesorectum, crossing in its course the ureter and left common iliac vessels. Opposite the middle of the sacrum it divides into two branches, which descend one on each side of the rectum, where they divide into several small branches, which are distributed between the mucous and muscular coats of that tube nearly as far as its lower end, anastomosing with each other, with the middle hemorrhoidal arteries, branches of the internal iliac, and with the inferior hemorrhoidal branches of the internal pudic.

The student should especially remark that the trunk of the vessel descends along the back part of the rectum as far as the middle of the sacrum before it divides; this is about a finger's length, or four inches, from the anus. In disease of this tube the rectum should never be divided beyond this point in that direction, for fear of involving this artery.

The **Suprarenal Arteries** (Fig. 393, p. 572) are two small vessels which arise, one on each side of the aorta, opposite the superior mesenteric artery. They pass obliquely upward and outward to the under surface of the suprarenal capsules, to which they are distributed, anastomosing with capsular branches from the phrenic and renal arteries. In the adult these arteries are of small size; in the fœtus they are as large as the renal arteries.

FIG. 399.

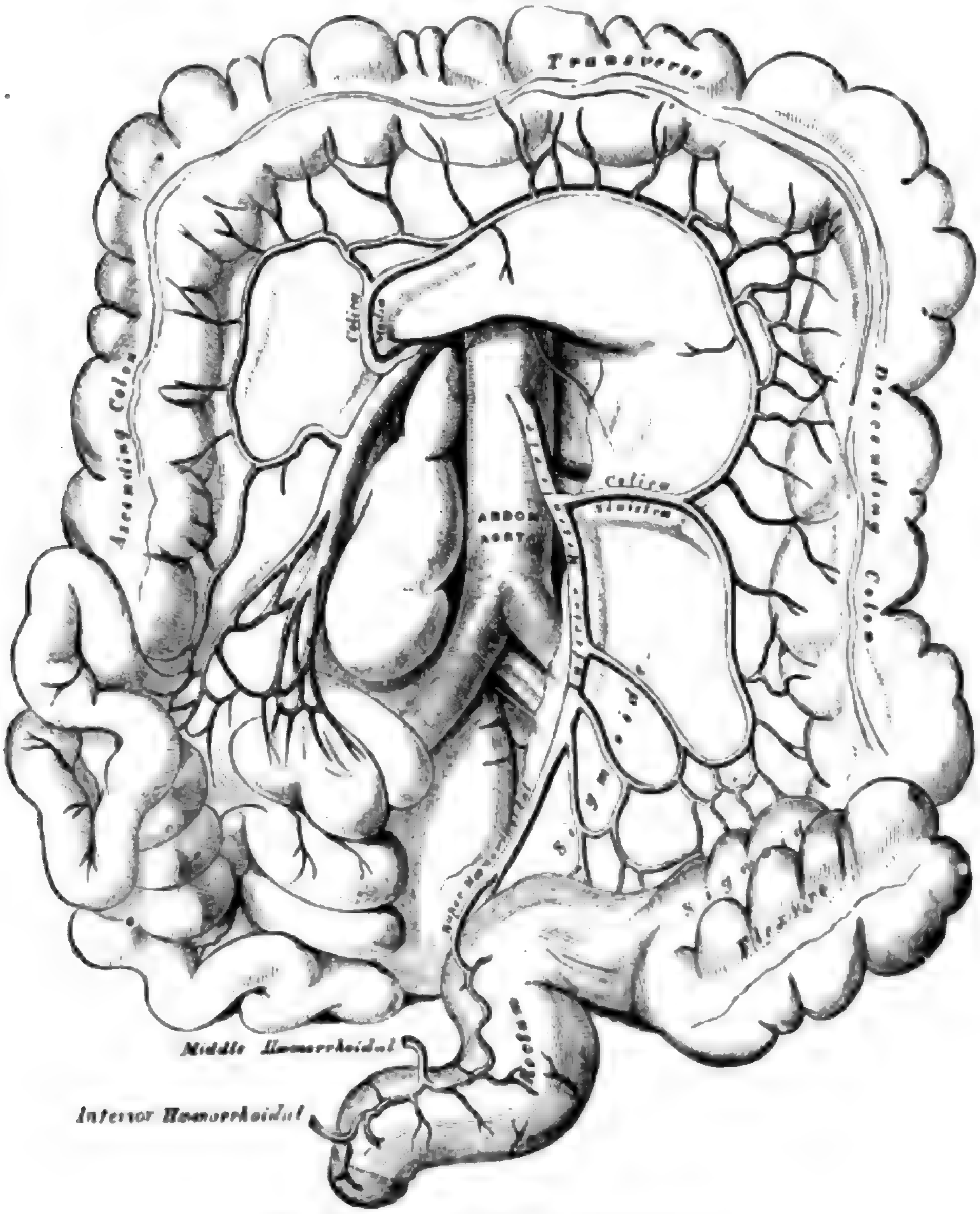
Transverse
Colica
Media
Ascending Colon
Descending Colon
ABDOM. AORTA
Colica
Sinistra
Sigmoid
Sigmoid Flexure
Super. Hæmorrhoidal
Rectum
Middle Hæmorrhoidal
Inferior Hæmorrhoidal

The Inferior Mesenteric and its Branches.

The **Renal Arteries** are two large trunks which arise from the sides of the aorta, immediately below the superior mesenteric artery. Each is directed outward, so as to form nearly a right angle with the aorta. The right is longer than the left, on account of the position of the aorta; it passes behind the inferior vena cava. The left is somewhat higher than the right. Previously to entering the kidney each artery divides into four or five branches, which are distributed to its substance. At the hilum these branches lie between the renal vein and ureter, the vein being usually in front, the ureter behind. Each vessel gives off some small branches to the suprarenal capsules, the ureter, and the surrounding cellular membrane and muscles.

The **Spermatic Arteries** are distributed to the testes in the male and to the ovaria in the female. They are two slender vessels, of considerable length, which arise from the front of the aorta a little below the renal arteries. Each artery passes obliquely outward and downward, behind the peritoneum, crossing the ureter and resting on the Psoas muscle, the right spermatic lying in front of the inferior vena cava, the left behind the sigmoid flexure of the colon. On reaching the margin of the pelvis each vessel passes in front of the corresponding external iliac artery, and takes a different course in the two sexes.

In the male it is directed outward to the internal abdominal ring, and accompanies the other constituents of the spermatic cord along the spermatic canal to the testis, where it becomes tortuous and divides into several branches, two or three of which accompany the vas deferens and supply the epididymis, anastomosing with the artery of the vas deferens; others pierce the back part of the tunica albuginea and supply the substance of the testis.

In the female the spermatic arteries (*ovarian*) are shorter than in the male, and do not pass out of the abdominal cavity. On arriving at the margins of the pelvis each artery passes inward, between the two laminæ of the broad ligament of the uterus, to be distributed to the ovary. One or two small branches supply the Fallopian tube; another passes on to the side of the uterus and anastomoses with the uterine arteries. Other offsets are continued along the round ligament, through the inguinal canal, to the integument of the labium and groin.

At an early period of fœtal life, when the testes lie by the side of the spine below the kidneys, the spermatic arteries are short; but as these organs descend from the abdomen into the scrotum the arteries become gradually lengthened.

The **Phrenic Arteries** are two small vessels which present much variety in their origin. They may arise separately from the front of the aorta, immediately above the cœliac axis, or by a common trunk, which may spring either from the aorta or from the cœliac axis. Sometimes one is derived from the aorta, and the other from one of the renal arteries. In only one out of thirty-six cases examined did these arteries arise as two separate vessels from the aorta. They diverge from one another across the crura of the Diaphragm, and then pass obliquely upward and outward upon its under surface. The left phrenic passes behind the œsophagus and runs forward on the left side of the œsophageal opening. The right phrenic passes behind the inferior vena cava, and ascends along the right side of the aperture for transmitting that vein. Near the back part of the central tendon each vessel divides into two branches. The internal branch runs forward to the front of the thorax, supplying the Diaphragm and anastomosing with its fellow of the opposite side and with the musculo-phrenic and comes nervi phrenici, branches of the internal mammary. The external branch passes toward the side of the thorax and inosculates with the intercostal arteries. The internal branch of the right phrenic gives off a few vessels to the inferior vena cava; and the left one, some branches to the œsophagus. Each vessel also sends capsular branches to the suprarenal capsule of its own side. The spleen on the left side and the liver on the right also receive a few branches from these vessels.

The **Lumbar Arteries** are analogous to the intercostal. They are usually four in number on each side, and arise from the back part of the aorta, nearly at right angles with that vessel. They pass outward and backward, around the sides of the body of the lumbar vertebra, behind the sympathetic nerve and the Psoas magnus muscle, those on the right side being covered by the inferior vena cava, and the two upper ones on each side by the crura of the Diaphragm. In the interval between the transverse processes of the vertebræ each artery divides into a *dorsal* and an *abdominal* branch.

The **dorsal branch** gives off, immediately after its origin, a spinal branch, which enters the spinal canal; it then continues its course backward, between the transverse processes, and is distributed to the muscles and integument of the back, anastomosing with the similar branches of the adjacent lumbar arteries and with the posterior branches of the intercostal arteries.

The **spinal branch,** besides supplying offsets which run along the nerves to the dura mater and cauda equina, anastomosing with the other spinal arteries, divides into two branches, one of which ascends on the posterior surface of the body of the vertebra above, and the other descends on the posterior surface of the body of the vertebra below, both vessels anastomosing with similar branches from neighboring spinal arteries. The inosculations of these vessels on each side, throughout the whole length of the spine, form a series of arterial arches behind the bodies of the vertebræ which are connected with each other, and with a median longitudinal vessel extending along the middle of the posterior surface of the bodies of the vertebræ, by transverse branches. From these vessels offsets are distributed to the periosteum and bones.

The **abdominal branches** pass outward, behind the Quadratus lumborum, the lowest branch occasionally in front of that muscle, and, being continued between the abdominal muscles, anastomose with branches of the epigastric and internal mammary *in front*, the intercostals *above*, and those of the ilio-lumbar and circumflex iliac *below*.

The **Middle Sacral Artery** is a small vessel, about the size of a crow-quill, which arises from the back part of the aorta, just at its bifurcation. It descends upon the last lumbar vertebra and along the middle line of the front of the sacrum to the upper part of the coccyx, where it anastomoses with the lateral sacral arteries, and terminates in a minute branch which runs down to the situation of the body presently to be described as "Luschka's gland." From it branches arise which run through the mesorectum to supply the posterior surface of the rectum. Other branches are given off on each side which anastomose with the lateral sacral arteries, and send off small offsets which enter the anterior sacral foramina.

Coccygeal Gland, or Luschka's Gland.—Lying near the tip of the coccyx, in a small tendinous interval formed by the union of the Levator ani muscles of either side, and just above the coccygeal attachment of the Sphincter ani, is a small conglobate body about as large as a lentil or a pea, first described by Luschka[1] and named by him *the coccygeal gland*, but the real nature and uses of which are doubtful, nor does it seem at present certain that it always exists. Its most obvious connections are with the arteries of the part. It consists of a congeries of small arteries derived from the middle sacral and freely communicating with each other. These vessels are enclosed in one or more layers of polyhedral granular cells, and the whole structure is invested in a capsule of connective tissue which sends in trabeculæ dividing the interior into a number of spaces in which the vessels and cells are contained. Nerves pass into this little body from the sympathetic, but their mode of termination is unknown.

COMMON ILIAC ARTERIES [Fig. 393, p. 572].

The abdominal aorta divides into the two **Common Iliac Arteries.** The bifurcation usually takes place on the left side of the body of the fourth lumbar vertebra. This point corresponds to the left side of the umbilicus, and is on a level with a line drawn from the highest point of one iliac crest to the other. The common iliac arteries are about two inches in length; diverging from the termination of the aorta, they pass downward and outward to the margin of the pelvis, and divide opposite the intervertebral substance, between the last lumbar vertebra and the sacrum, into two branches—the *external and internal iliac arteries*, the former supplying the lower extremity, the latter the viscera and parietes of the pelvis.

The **right common iliac** is somewhat larger than the left, and passes more obliquely across the body of the last lumbar vertebra. In front of it are the peritoneum, the ileum, branches of the sympathetic nerve, and, at its point of division, the ureter. *Behind* it is separated from the last lumbar vertebra by the two common iliac veins. On its *outer side* it is in relation with the inferior vena cava and the right common iliac vein above, and the Psoas magnus muscle below.

---

[1] *Der Hirnanhang und die Steissdrüse des Menschen*, Berlin, 1860; *Anatomie des Menschen*, Tübingen, 1864, vol. ii. pt. 2, p. 187.

The **left common iliac** is in relation in front with the peritoneum, branches of the sympathetic nerve, and the superior hemorrhoidal artery, and is crossed at its point of bifurcation by the ureter. The left common iliac vein lies partly on the inner side and partly beneath the artery; on its outer side the artery is in relation with the Psoas magnus.

Branches.—The common iliac arteries give off small branches to the peritoneum, Psoas magnus, ureters, and the surrounding cellular tissue, and occasionally give origin to the ilio-lumbar or renal arteries.

PLAN OF THE RELATIONS OF THE COMMON ILIAC ARTERIES.

In Front.
Peritoneum.
Small intestines.
Sympathetic nerves.
Ureter.

Right
Common
Iliac.

Outer Side.
Vena cava.
Right common iliac vein.
Psoas muscle.

Behind.
Right and left common iliac veins.

In Front.
Peritoneum.
Sympathetic nerves.
Superior hemorrhoidal artery.
Ureter.

Inner Side.
Left common iliac vein.

Left
Common
Iliac.

Outer Side.
Psoas muscle.

Behind.
Left common iliac vein.

Peculiarities.—The *point of origin* varies according to the bifurcation of the aorta. In three-fourths of a large number of cases the aorta bifurcated either upon the fourth lumbar vertebra or upon the intervertebral disk between it and the fifth, the bifurcation being in one case out of nine below, and in one out of eleven above, this point. In ten out of every thirteen cases the vessel bifurcated within half an inch above or below the level of the crest of the ilium; more frequently below than above.

The **point of division** is subject to great variety. In two-thirds of a large number of cases it was between the last lumbar vertebra and the upper border of the sacrum, being above that point in one case out of eight, and below it in one case out of six. The left common iliac artery divides lower down more frequently than the right.

The **relative length** also of the two common iliac arteries varies. The right common iliac was the longer in 63 cases; the left, in 52; whilst they were both equal in 53. The length of the arteries varied, in five-sevenths of the cases examined, from an inch and a half to three inches; in about half of the remaining cases the artery was longer, and in the other half, shorter, the minimum length being less than half an inch, the maximum four and a half inches. In one instance the right common iliac was found wanting, the external and internal iliacs arising directly from the aorta.

Surgical Anatomy.—The application of a ligature to the common iliac artery may be required on account of aneurism or hemorrhage implicating the external or internal iliacs, or on account of secondary hemorrhage after amputation of the thigh high up. It has been seen that the origin of this vessel corresponds to the left side of the umbilicus on a level with a line drawn from the highest point of one iliac crest to the opposite one, and its course to a line extending from the left side of the umbilicus downward toward the middle of Poupart's ligament. The line of incision required in the first steps of an operation for securing this vessel would materially depend upon the nature of the disease. If the surgeon select the iliac region, a curved incision about five inches in length may be made, commencing on the left side of the umbilicus, carried outward toward the anterior superior iliac spine, and then along the upper border of Poupart's ligament as far as its middle. But if the aneurismal tumor should extend high up in the abdomen along the external iliac, it is better to select the side of the abdomen, approaching the artery from above by making an incision from four to five inches in length from about two inches above and to the left of the umbilicus, carried outward in a curved direction toward the lumbar region, and terminating a little below the anterior superior iliac spine. The abdominal muscles (in either case) having been cautiously divided in succession, the transversalis fascia must be carefully cut through, and the peritoneum, together with the ureter, separated from the artery and pushed aside; the sacro-iliac articulation must then be felt for, and upon it the vessel will be felt pulsating, and may be fully exposed in close connection with its accompanying vein. On the right side both common iliac veins, as well as the inferior vena cava, are in close connection with the artery, and must be carefully avoided. On the left side the vein usually lies on the inner side and behind the artery, but it occasionally happens that the two common iliac veins are joined on the left instead of the right side, which would add much to the difficulty of an operation in such a case. The common iliac artery may be so short that danger may be apprehended from secondary hemorrhage if a ligature is applied to it. It would be preferable in such a case to tie both the external and internal iliacs near their origin.

[Davy of England has devised a "rectal lever," which is introduced into the rectum and placed over the common iliac of the side to be operated on. By its elevation the artery can be compressed to prevent hemorrhage in hip-joint amputation. Lloyd of Birmingham has devised another excellent method to attain the same end, by compression of the external iliac and the branches of the internal iliac going to the thigh, by passing an elastic bandage around half of the pelvis above the iliac crest in front and between the anus and tuber ischii behind. A roller bandage should be placed over the external iliac.]

Collateral Circulation.—The principal agents in carrying on the collateral circulation after the application of a ligature to the common iliac are the anastomoses of the hemorrhoidal branches of the internal iliac with the superior hemorrhoidal from the inferior mesenteric; the anastomoses of the uterine and ovarian arteries and of the vesical arteries of opposite sides; of the lateral sacral with the middle sacral artery; of the epigastric with the internal mammary, inferior intercostal, and lumbar arteries; of the circumflex iliac with the lumbar arteries; of the ilio-lumbar with the last lumbar artery; of the obturator artery, by means of its pubic branch, with the vessel of the opposite side and with the internal epigastric; and of the gluteal with the posterior branches of the sacral arteries.

INTERNAL ILIAC ARTERY (Fig. 400).

The **Internal Iliac Artery** supplies the walls and viscera of the pelvis, the generative organs, and the inner side of the thigh. It is a short, thick vessel—smaller in the adult than the external iliac, and about an inch and a half in length—which arises at the point of bifurcation of the common iliac, and, passing downward to the upper margin of the great sacro-sciatic foramen, divides into two large trunks, an *anterior* and a *posterior;* a partially obliterated cord, the hypogastric artery, extending from the extremity of the vessel forward to the bladder.

RELATIONS.—In *front* with the ureter, which separates it from the peritoneum; *behind*, with the internal iliac vein, the lumbo-sacral nerve, and Pyriformis muscle; by its *outer side* near its origin, with the Psoas magnus muscle.

PLAN OF THE RELATIONS OF THE INTERNAL ILIAC ARTERY.

In Front.
Peritoneum.
Ureter.

Outer Side.
Psoas magnus.

Internal
Iliac.

Behind.
Internal iliac vein.
Lumbo-sacral nerve.
Pyriformis muscle.

In the fœtus the internal iliac artery (*hypogastric*) is twice as large as the external iliac, and appears to be the continuation of the common iliac. Passing forward to the bladder, it ascends along the sides of that viscus to its summit, to which it gives branches; it then passes upward along the back part of the anterior wall of the abdomen to the umbilicus, converging toward its fellow of the opposite side. Having passed through the umbilical opening, the two arteries twine round the umbilical vein, forming with it the umbilical cord, and ultimately ramify in the placenta. The portion of the vessel within the abdomen is called the *hypogastric* artery, and that external to that cavity the *umbilical* artery.

At birth, when the placental circulation ceases, the upper portion of the hypogastric artery, extending from the summit of the bladder upward to the umbilicus, contracts, and ultimately dwindles to a solid fibrous cord; but the lower portion, extending from its origin (in what is now the internal iliac artery) for about an inch and a half to the wall of the bladder, and thence to the summit of that organ, is not totally impervious, though it becomes considerably reduced in size, and serves to convey blood to the bladder under the name of the *superior vesical* artery.

Fig. 400.

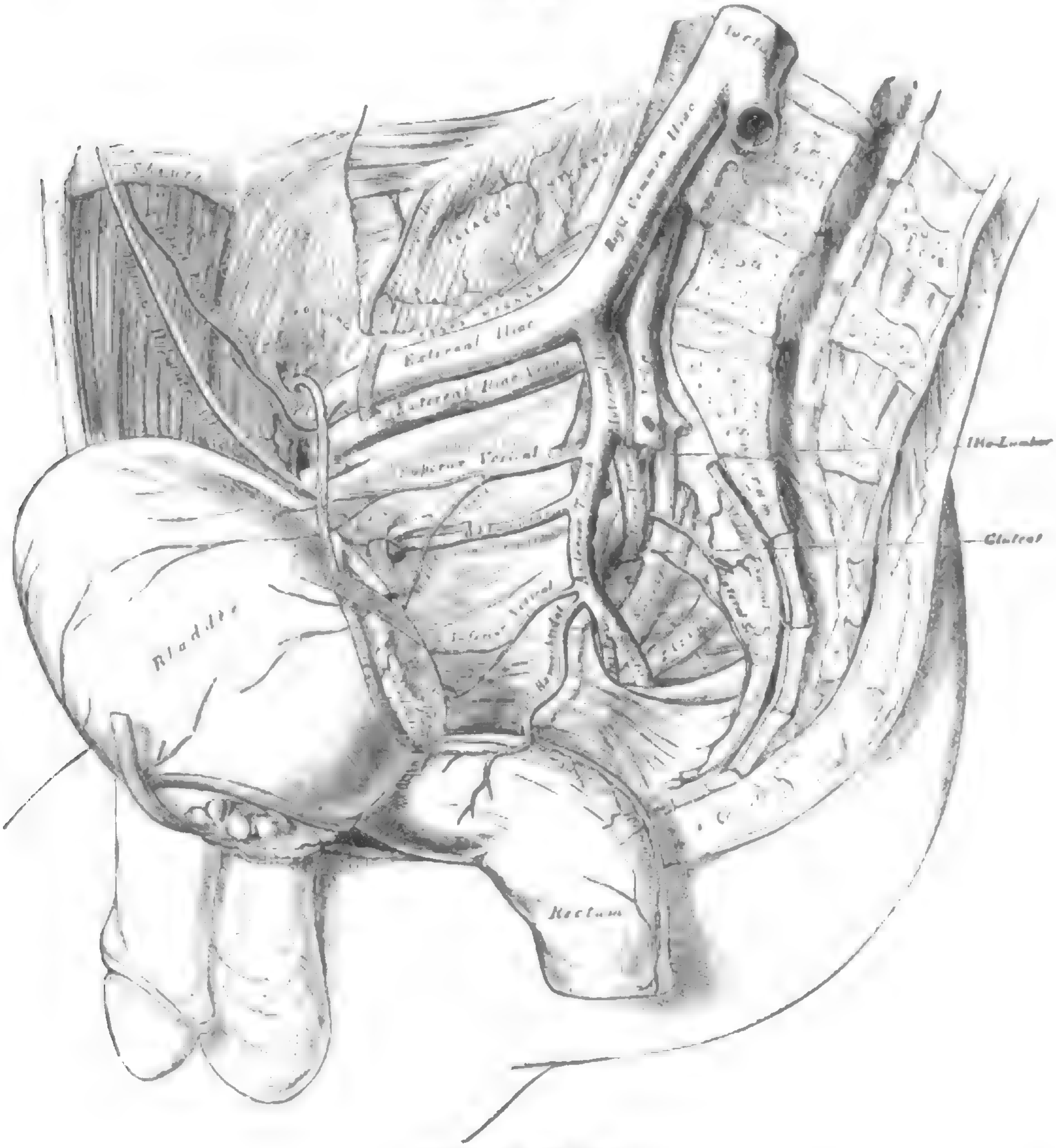

Arteries of the Pelvis.

Peculiarities as regards Length.—In two-thirds of a large number of cases the length of the internal iliac varied between an inch and an inch and a half; in the remaining third it was more frequently longer than shorter, the maximum length being three inches, the minimum half an inch.

The lengths of the common and internal iliac arteries bear an inverse proportion to each other, the internal iliac artery being long when the common iliac is short, and *vice versâ*.

As regards its Place of Division.—The place of division of the internal iliac varies between the upper margin of the sacrum and the upper border of the sacro-sciatic foramen.

The arteries of the two sides in a series of cases often differed in length, but neither seemed constantly to exceed the other.

Surgical Anatomy.—The application of a ligature to the internal iliac artery may be required in cases of aneurism or hemorrhage affecting one of its branches. The vessel may be secured by making an incision through the abdominal parietes in the iliac region, in a direction and to an extent similar to that for securing the common iliac: the transversalis fascia having been cautiously divided, and the peritoneum pushed inward from the iliac fossa toward the pelvis, the finger may feel the pulsation of the external iliac at the bottom of the wound, and by tracing this vessel upward the internal iliac is arrived at, opposite the sacro-iliac articulation. It should be remembered that the vein lies behind and on the right side, a little external to the artery and in close contact with it; the ureter and peritoneum, which lie in front, must also be avoided. The degree of facility in applying a ligature to this vessel will mainly depend upon its length. It has been seen that in the great majority of the cases examined the artery was short, varying from an inch to an inch and a half; in these cases the artery is deeply seated in the pelvis: when, on the contrary, the vessel is longer, it is found partly above that cavity. If the artery is very short, as occasionally happens, it would be preferable to apply a ligature to the common iliac or upon the external and internal iliacs at their origin.

Collateral Circulation.—In Prof. Owen's dissection of a case in which the internal iliac artery had been tied by Stevens ten years before death for aneurism of the sciatic artery, the internal iliac was found impervious for about an inch above the point where the ligature had been applied; but the obliteration did not extend to the origin of the external iliac, as the ilio-lumbar artery arose just above this point. Below the point of obliteration the artery resumed its natural diameter, and continued so for half an inch, the obturator, lateral sacral, and gluteal arising in succession from the latter portion. The obturator artery was entirely obliterated. The lateral sacral artery was as large as a crow's quill, and had a very free anastomosis with the artery of the opposite side and with the middle sacral artery. The sciatic artery was entirely obliterated as far as its point of connection with the aneurismal tumor, but on the distal side of the sac it was continued down along the back of the thigh nearly as large in size as the femoral, being pervious about an inch below the sac by receiving an anastomosing vessel from the profunda.[1] The circulation was carried on by the anastomoses of the uterine and ovarian arteries; of the opposite vesical arteries; of the hemorrhoidal branches of the internal iliac with those from the inferior mesenteric; of the obturator artery, by means of its pubic branch, with the vessel of the opposite side and with the epigastric and internal circumflex; of the circumflex and perforating branches of the profunda femoral with the sciatic; of the gluteal with the posterior branches of the sacral arteries; of the ilio-lumbar with the last lumbar; of the lateral sacral with the middle sacral; and of the circumflex iliac with the ilio-lumbar and gluteal.

BRANCHES OF THE INTERNAL ILIAC.

From the Anterior Trunk.

Superior Vesical.
Middle Vesical.
Inferior Vesical.
Middle Hemorrhoidal.
Obturator.
Internal Pudic.
Sciatic.
In female. { Uterine.
Vaginal.

From the Posterior Trunk.

Ilio-lumbar.
Lateral Sacral.
Gluteal.

The **superior vesical** is that part of the fœtal hypogastric artery which remains pervious after birth. It extends to the side of the bladder, distributing numerous branches to the apex and body of the organ. From one of these a slender vessel is derived which accompanies the vas deferens in its course to the testis, where it anastomoses with the spermatic artery. This is the *artery of the vas deferens*. Other branches supply the ureter.

The **middle vesical**, usually a branch of the superior, is distributed to the base of the bladder and the under surface of the vesiculæ seminales.

The **inferior vesical** arises from the anterior division of the internal iliac, frequently in common with the middle hemorrhoidal, and is distributed to the base of the bladder, the prostate gland, and vesiculæ seminales. The branches distributed to the prostate communicate with the corresponding vessel of the opposite side.

The **middle hemorrhoidal artery** usually arises together with the preceding vessel. It supplies the rectum, anastomosing with the other hemorrhoidal arteries.

The **uterine artery** passes downward from the anterior trunk of the internal iliac to the neck of the uterus. Ascending in a tortuous course on the side of this viscus between the layers of the broad ligament, it distributes branches to its substance, anastomosing near its termination with a branch from the ovarian artery. Branches from this vessel are also distributed to the bladder and ureter.

The **vaginal artery** is analogous to the inferior vesical in the male; it descends upon the vagina, supplying its mucous membrane and sending branches to the neck of the bladder and contiguous part of the rectum.

---

[1] *Medico-Chirurgical Trans.*, vol. xvi.

The **obturator artery** [Fig. 400] usually arises from the anterior trunk of the internal iliac, frequently from the posterior. It passes forward below the brim of the pelvis to the canal in the upper border of the obturator foramen, and, escaping from the pelvic cavity through this aperture, divides into an internal and an external branch. In the pelvic cavity this vessel lies upon the pelvic fascia, beneath the peritoneum and a little below the obturator nerve, and whilst passing through the obturator foramen is contained in an oblique canal formed by the horizontal branch of the pubes above and the arched border of the obturator membrane below.

Branches.—*Within the pelvis* the obturator artery gives off an *iliac branch* to the iliac fossa, which supplies the bone and the Iliacus muscle, and anastomoses with the ilio-lumbar artery; a *vesical branch*, which runs backward to supply the bladder; and a *pubic branch*, which is given off from the vessel just before it leaves the pelvic cavity. This branch ascends upon the back of the pubes, communicating with offsets from the epigastric artery and with the corresponding vessel of the opposite side. This branch is placed on the inner side of the femoral ring. *External to the pelvis* the obturator artery divides into an *external* and an *internal* branch, which are deeply situated beneath the Obturator externus muscle; skirting the circumference of the obturator foramen, they anastomose at the lower part of this aperture with each other and with branches of the internal circumflex artery.

The **internal branch** curves downward along the inner margin of the obturator foramen, distributing branches to the Obturator externus muscle, Pectineus, Abductors, and Gracilis, and anastomoses with the external branch and with the internal circumflex artery.

The **external branch** curves round the outer margin of the foramen to the space between the Gemellus inferior and Quadratus femoris, where it anastomoses with the sciatic artery. It supplies the Obturator muscles, anastomoses, as it passes backward, with the internal branch and with the internal circumflex, and sends a branch to the hip-joint through the cotyloid notch, which ramifies on the round ligament as far as the head of the femur.

Peculiarities.—In two out of every three cases the obturator arises from the internal iliac; in one case in three and a half from the epigastric; and in about one in seventy-two cases by two roots from both vessels. It arises in about the same proportion from the external iliac artery. The origin of the obturator from the epigastric is not commonly found on both sides of the same body.

When the obturator artery arises at the front of the pelvis from the epigastric, it descends almost vertically to the upper part of the obturator foramen. The artery in this course usually lies in contact with the external iliac vein and on the outer side of the femoral ring (Fig. 401, A); in such cases it would not be endangered in the operation for femoral hernia. Occasionally, however, it curves inward along the free margin of Gimbernat's ligament (Fig. 401, B), and under such circumstances would almost completely encircle the neck of a hernial sac (supposing a hernia to exist in such a case), and would be in great danger of being wounded if an operation was performed.

FIG. 401.



Variations in Origin and Course of Obturator Artery.

The **internal pudic** is the smaller of the two terminal branches of the anterior trunk of the internal iliac, and supplies the external organs of generation. It passes downward and outward to the lower border of the great sacro-sciatic foramen, and emerges from the pelvis between the Pyriformis and Coccygeus muscles; it then crosses the spine of the ischium and re-enters the pelvis through the lesser sacro-sciatic foramen. The artery now crosses the Obturator internus muscle along the outer wall of the ischio-rectal fossa, being situated about an inch and a half above the lower margin of the ischial tuberosity. It is here contained in a sheath of the obturator fascia, and gradually approaches the margin of the ramus of the ischium, along which it ascends forward and upward, pierces the posterior layer of the deep perineal fascia, and runs forward along the inner margin of the ramus of the pubes; finally, it perforates the anterior layer of the deep perineal fascia and divides into its two terminal branches, the *dorsal artery of the penis* and the *artery of the corpus cavernosum.*

FIG. 402.

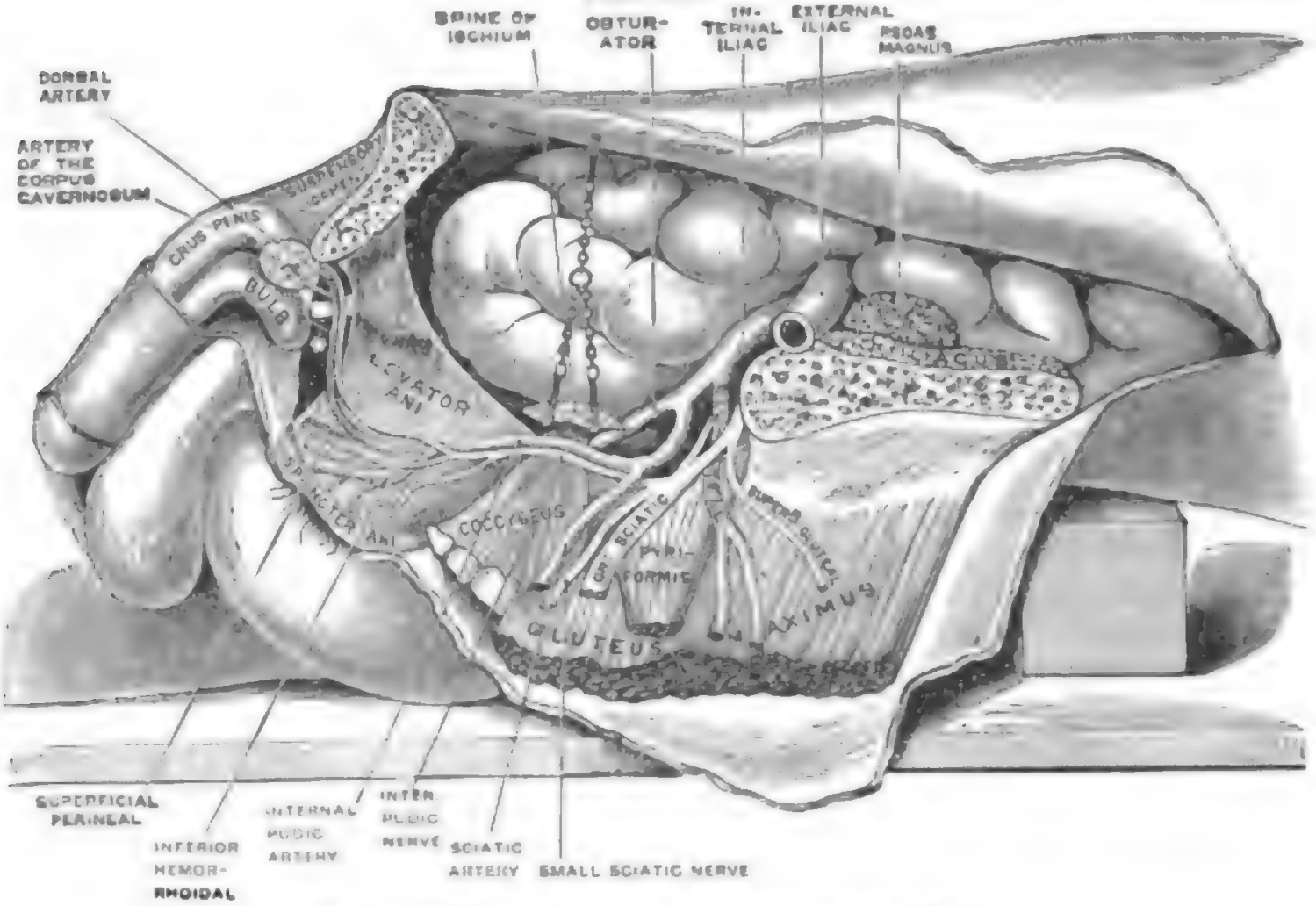
SPINE OF ISCHIUM
OBTURATOR
INTERNAL ILIAC
EXTERNAL ILIAC
PSOAS MAGNUS
DORSAL ARTERY
ARTERY OF THE CORPUS CAVERNOSUM
CRUS PENIS
BULB
LEVATOR ANI
SPHINCTER ANI
COCCYGEUS
GR. SCIATIC
PYRIFORMIS
GLUTEUS MAXIMUS
SUPERFICIAL PERINEAL
INFERIOR HEMORRHOIDAL
INTERNAL PUDIC ARTERY
INTER. PUDIC NERVE
SCIATIC ARTERY
SMALL SCIATIC NERVE

The Internal Pudic Artery and its Branches in the Male.

RELATIONS.—In the first part of its course, within the pelvis, it lies in front of the Pyriformis muscle and sacral plexus of nerves and on the outer side of the rectum (on the left side). As it crosses the spine of the ischium it is covered by the Gluteus maximus. In the pelvis it lies on the outer side of the ischio-rectal fossa, upon the surface of the Obturator internus muscle, contained in a fibrous canal formed by the obturator fascia and the falciform process of the great sacro-sciatic ligament. It is accompanied by the pudic veins and the internal pudic nerve.

Peculiarities.—The internal pudic is sometimes smaller than usual, or fails to give off one or two of its usual branches; in such cases the deficiency is supplied by branches derived from an additional vessel, the *accessory pudic*, which generally arises from the pudic artery before its exit from the great sacro-sciatic foramen, and passes forward near the base of the bladder, on the upper part of the prostate gland, to the perineum; it then perforates the triangular ligament and gives off the branches usually derived from the pudic artery. The deficiency most frequently met with is that in which the internal pudic ends as the artery of the bulb, the artery of the corpus cavernosum and arteria dorsalis penis being derived from the accessory pudic. Or the pudic may terminate as the superficial perineal, the artery of the bulb being derived, with the other two branches, from the accessory vessel.

The relation of the accessory pudic to the prostate gland and urethra is of the greatest interest in a surgical point of view, as this vessel is in danger of being wounded in the lateral operation of lithotomy. The student should also study the position of the internal pudic artery and its branches, when running a normal course, with regard to the same operation. The superficial arteries of the perineum and the transverse perineal are, of necessity, divided in this operation, but the hemorrhage from these vessels is seldom excessive; should a ligature be required, it can readily be applied on account of their superficial position. The artery of the bulb may be divided if the incision be carried too far forward, and wound of this vessel may be attended with serious or even fatal consequences. The main trunk of the internal pudic artery stands a risk of being wounded if the incision be carried too far outward; but being bound down by the strong obturator fascia and under cover of the ramus of the ischium, the accident is not very likely to occur unless the vessel runs an anomalous course.

Branches.—*Within the pelvis* the internal pudic gives off several small branches which supply the muscles, sacral nerves, and pelvic viscera. *In the perineum* the following branches are given off:

Inferior Hemorrhoidal.	Artery of the Bulb.
Superficial Perineal.	Artery of the Corpus Cavernosum.
Transverse Perineal.	Dorsal Artery of the Penis.

The **inferior hemorrhoidal** are two or three small arteries which arise from the internal pudic as it passes above the tuberosity of the ischium. Crossing the ischio-rectal fossa, they are distributed to the muscles and integument of the anal region.

The **superficial perineal artery** supplies the scrotum and muscles and integument of the perineum. It arises from the internal pudic, in front of the preceding branches, and turns upward, crossing either over or under the Transversus perinæi muscle and runs forward, parallel to the pudic arch, in the interspace between the Accelerator urinæ and Erector penis muscles, both of which it supplies, and is finally distributed to the skin of the dartos and scrotum. In its passage through the perineum it lies beneath the superficial perineal fascia.

The **transverse perineal** is a small branch which arises either from the internal pudic or from the superficial perineal artery as it crosses the Transversus perinæi muscle. It runs transversely inward along the cutaneous surface of the Transversus perinæi muscle, which it supplies, as well as the structures between the anus and bulb of the urethra, and anastomoses with the one of the opposite side.

The **artery of the bulb** is a large but very short vessel which arises from the internal pudic between the two layers of the deep perineal fascia, and, passing nearly transversely inward, pierces the bulb of the urethra, in which it ramifies. It gives off a small branch which descends to supply Cowper's gland. This artery is of considerable importance in a surgical point of view, as it is in danger of being wounded in the lateral operation of lithotomy—an accident usually attended in the adult with alarming hemorrhage. The vessel is sometimes very small, occasionally wanting, or even double. It sometimes arises from the internal pudic earlier than usual, and crosses the perineum to reach the back part of the bulb. In such a case the vessel could hardly fail to be wounded in the performance of the lateral operation for lithotomy. If, on the contrary, it should arise from an accessory pudic, it lies more forward than usual and is out of danger in the operation.

The **artery of the corpus cavernosum,** one of the terminal branches of the internal pudic, arises from that vessel while it is situated between the crus penis and the ramus of the pubes: piercing the crus penis obliquely, it runs forward in the centre of the corpus cavernosum, to which its branches are distributed.

The **dorsal artery of the penis** ascends between the crus and pubic symphysis, and, piercing the suspensory ligament, runs forward on the dorsum of the penis to the glans, where it divides into two branches, which supply the glans and prepuce. On the dorsum of the penis it lies immediately beneath the integument, parallel with the dorsal vein and the corresponding artery of the opposite side. It supplies the integument and fibrous sheath of the corpus cavernosum, sending branches through the sheath to anastomose with the preceding vessel.

The **internal pudic artery** in the female is smaller than in the male. Its origin and course are similar, and there is considerable analogy in the distribution of its branches. The superficial artery supplies the labia pudendi; the artery of the bulb supplies the erectile tissue of the bulb of the vagina, whilst the two terminal branches supply the clitoris; the artery of the corpus cavernosum, the cavernous body of the clitoris; and the arteria dorsalis clitoridis, the dorsum of that organ.

FIG. 403.

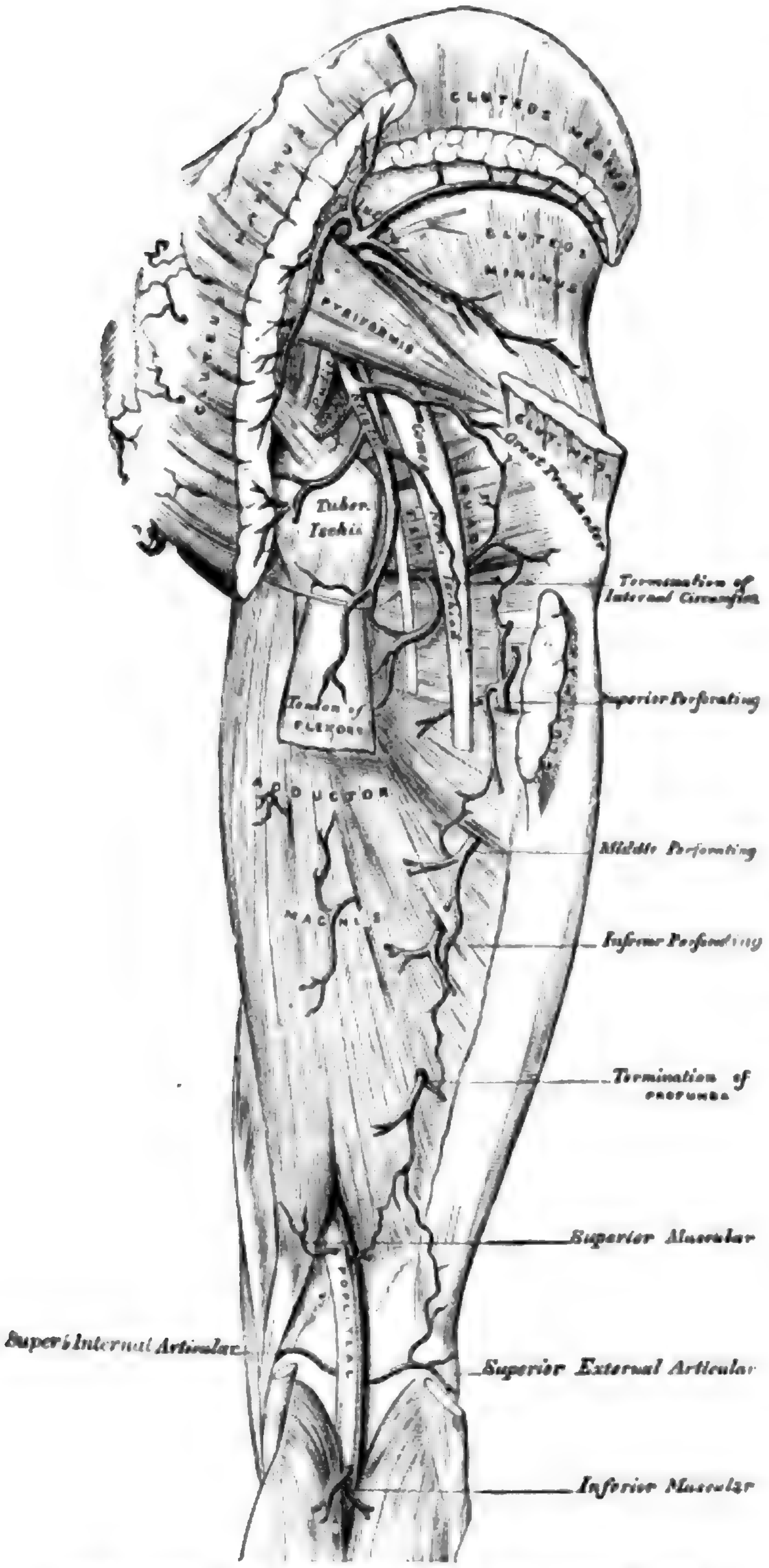
GLUTEUS MEDIUS
GLUTEUS MINIMUS
PYRIFORMIS
GLUTEUS MAXIMUS
Tuber. Ischii
Great Trochanter
Tendon of FLEXORS
ADDUCTOR MAGNUS
POPLITEAL
Termination of Internal Circumflex
Superior Perforating
Middle Perforating
Inferior Perforating
Termination of Profunda
Superior Muscular
Superi Internal Articular
Superior External Articular
Inferior Muscular

The Arteries of the Gluteal and Posterior Femoral Regions.

The **Sciatic Artery** (Fig. 403), the larger of the two terminal branches of the anterior trunk of the internal iliac, is distributed to the muscles on the back of the pelvis. It passes down to the lower part of the great sacro-sciatic foramen, behind the internal pudic, resting on the sacral plexus of nerves and Pyriformis muscle, and escapes from the pelvis between the Pyriformis and Coccygeus. It then descends in the interval between the trochanter major and tuberosity of the ischium, accompanied by the sciatic nerves and covered by the Gluteus maximus, and divides into branches which supply the deep muscles at the back of the hip.

Within the pelvis it distributes branches to the Pyriformis, Coccygeus, and Levator ani muscles; some hemorrhoidal branches, which supply the rectum, and occasionally take the place of the middle hemorrhoidal artery; and vesical branches to the base and neck of the bladder, vesiculæ seminales, and prostate gland. *External to the pelvis* it gives off the following branches:

Coccygeal.
Inferior Gluteal.
Comes nervi ischiadici.
Muscular.
Articular.

The **coccygeal branch** runs inward, pierces the great sacro-sciatic ligament, and supplies the Gluteus maximus, the integument, and other structures on the back of the coccyx.

The branches of the **inferior gluteal,** three or four in number, supply the Gluteus maximus muscle, anastomosing with the gluteal artery in the substance of the muscle.

The **comes nervi ischiadici** is a long slender vessel which accompanies the great sciatic nerve for a short distance; it then penetrates it, and runs in its substance to the lower part of the thigh.

The **muscular branches** supply the muscles on the back part of the hip, anastomosing with the gluteal, external branch of the obturator, internal and external circumflex, and superior perforating arteries.

Some **articular branches** are distributed to the capsule of the hip-joint.

[From the posterior trunk of the internal iliac arise the *ilio-lumbar*, the *lateral sacral*, and the *gluteal* arteries (Fig. 400, p. 585).]

The **Ilio-lumbar Artery** ascends beneath the Psoas muscle and external iliac vessels to the upper part of the iliac fossa, where it divides into a lumbar and an iliac branch.

The **lumbar branch** supplies the Psoas and Quadratus lumborum muscles, anastomosing with the last lumbar artery, and sends a small spinal branch through the intervertebral foramen, between the last lumbar vertebra and the sacrum, into the spinal canal, to supply the spinal cord and its membranes.

The **iliac branch** descends to supply the Iliacus muscle, some offsets, running between the muscle and the bone, anastomosing with the iliac branch of the obturator: one of these enters an oblique canal to supply the diploë, whilst others run along the crest of the ilium, distributing branches to the Gluteal and Abdominal muscles, and anastomosing in their course with the gluteal, circumflex iliac, external circumflex, and epigastric arteries.

The **Lateral Sacral Arteries** are usually two in number on each side, superior and inferior.

The **superior,** which is of large size, passes inward, and, after anastomosing with branches from the middle sacral, enters the first or second sacral foramen, is distributed to the contents of the sacral canal, and, escaping by the corresponding posterior sacral foramen, supplies the skin and muscles on the dorsum of the sacrum, anastomosing with the gluteal.

The **inferior** passes obliquely across the front of the Pyriformis muscle and sacral nerves to the inner side of the anterior sacral foramina, descends on the front of the sacrum, and anastomoses over the coccyx with the sacra media and opposite lateral sacral arteries. In its course it gives off branches which enter the anterior sacral foramina: these, after supplying the bones and membranes of the interior of the spinal canal, escape by the posterior sacral foramina, and are distributed to the muscles and skin on the dorsal surface of the sacrum, anastomosing with the gluteal.

The **Gluteal Artery** [Fig. 403, p. 590] is the largest branch of the internal iliac, and appears to be the continuation of the posterior division of that vessel. It is a short, thick trunk which passes out of the pelvis above the upper border of the Pyriformis muscle, and immediately divides into a *superficial* and *deep* branch. Within the pelvis it gives off a few muscular branches to the Iliacus, Pyriformis, and Obturator internus, and just previous to quitting that cavity a nutrient artery which enters the ilium.

The **superficial branch** passes beneath the Gluteus maximus, and divides into numerous branches, some of which supply that muscle, whilst others perforate its tendinous origin and supply the integument covering the posterior surface of the sacrum, anastomosing with the posterior branches of the sacral arteries.

The **deep branch** runs between the Gluteus medius and minimus, and subdivides into two. Of these, the superior division, continuing the original course of the vessel, passes along the upper border of the Gluteus minimus to the anterior superior spine of the ilium, anastomosing with the circumflex iliac and ascending branches of the external circumflex artery. The inferior division crosses the Gluteus minimus obliquely to the trochanter major, distributing branches to the Glutei muscles, and inosculates with the external circumflex artery. Some branches pierce the Gluteus minimus to supply the hip-joint.

External Iliac Artery (Fig. 400, p. 585).

The **External Iliac Artery** is the chief vessel which supplies the lower limb. It is larger in the adult than the internal iliac, and passes obliquely downward and outward along the inner border of the Psoas muscle, from the bifurcation of the common iliac to Poupart's ligament, where it enters the thigh and becomes the femoral artery. The course of this vessel would be indicated by that portion of a line drawn from the left side of the umbilicus to a point midway between the anterior superior spinous process of the ilium and the symphysis pubis, which lies below the level of the anterior superior processes.

Relations.—*In front* with the peritoneum, subperitoneal areolar tissue, the intestines, and a thin layer of fascia derived from the iliac fascia, which surrounds the artery and vein. At its origin it is occasionally crossed by the ureter. The spermatic vessels descend for some distance upon it near its termination, and it is crossed in this situation by the genital branch of the genito-crural nerve and the circumflex iliac vein; the vas deferens curves down along the inner side. *Behind* it is in relation with the external iliac vein, which at the femoral arch lies at its inner side; on the left side the vein is altogether internal to the artery. *Externally* it rests against the Psoas muscle, from which it is separated by the iliac fascia. The artery rests upon this muscle, near Poupart's ligament. Numerous lymphatic vessels and glands are found lying on the front and inner side of the vessel.

Plan of the Relations of the External Iliac Artery.

In Front.

Peritoneum, intestines, and fascia.

Near Poupart's Ligament.
- Spermatic vessels.
- Genito-crural nerve (genital branch).
- Circumflex iliac vein.
- Lymphatic vessels and glands.

Outer Side.

Psoas magnus.
Iliac fascia.

External Iliac.

Inner Side.

External iliac vein and vas deferens at femoral arch.

Behind.

External iliac vein.
Psoas magnus.

Surgical Anatomy.—The application of a ligature to the external iliac may be required in cases of aneurism of the femoral artery, or in cases of secondary hemorrhage after the latter vessel has been tied for popliteal aneurism. This vessel may be secured in any part of its course, excepting near its upper end, which is to be avoided on account of the proximity of the great stream of blood in the internal iliac, and near its lower end, which should also be avoided on account of the proximity of the epigastric and circumflex iliac vessels. One of the chief points in the performance of the operation is to secure the vessel without injury to the peritoneum. The patient having been placed in the recumbent position, an incision should be made, commencing below at a point about three-quarters of an inch above Poupart's ligament and a little external to its middle, and running upward and outward, parallel to Poupart's ligament, to a point above the anterior superior spine of the ilium. When the artery is deeply seated more room will be required, and may be obtained by curving the incision from the point last named inward toward the umbilicus for a short distance; or if the lower part of the artery is to be reached, the surgeon may adopt the plan advocated by Sir Astley Cooper, by making an incision close to Poupart's ligament from about half an inch outside the external abdominal ring to an inch internal to the anterior superior spine of the ilium. This incision being made in the course of the fibres of the aponeurosis of the external oblique, is less likely to be followed by a ventral hernia, but there is danger of wounding the epigastric artery. Abernethy, who first tied this artery, made his incision in the course of the vessel. The abdominal muscles and transversalis fascia having been cautiously divided, the peritoneum should be separated from the iliac fossa and pushed toward the pelvis, and on introducing the finger to the bottom of the wound the artery may be felt pulsating along the inner border of the Psoas muscle. The external iliac vein is generally found on the inner side of the artery, and must be cautiously separated from it by the finger-nail or handle of the knife, and the aneurism-needle should be introduced on the inner side between the artery and vein.

Collateral Circulation.—The principal anastomoses in carrying on the collateral circulation, after the application of a ligature to the external iliac, are—the ilio-lumbar with the circumflex iliac; the gluteal with the external circumflex; the obturator with the internal circumflex; the sciatic with the superior perforating and circumflex branches of the profunda artery; the internal pudic with the external pudic and with the internal circumflex. When the obturator arises from the epigastric, it is supplied with blood by branches either from the internal iliac, the lateral sacral, or the internal pudic. The epigastric receives its supply from the internal mammary and inferior intercostal arteries and from the internal iliac by the anastomoses of its branches with the obturator.

In the dissection of a limb eighteen years after the successful ligature of the external iliac artery by Sir A. Cooper, which is to be found in *Guy's Hospital Reports*, vol. i. p. 50, the anastomosing branches are described in three sets: *An anterior set:* 1, a very large branch from the ilio-lumbar artery to the circumflex iliac; 2, another branch from the ilio-lumbar, joined by one from the obturator, and breaking up into numerous tortuous branches to anastomose with the external circumflex; 3, two other branches from the obturator, which passed over the brim of the pelvis, communicated with the epigastric, and then broke up into a plexus to anastomose with the internal circumflex. *An internal set:* branches given off from the obturator after quitting the pelvis, which ramified among the Adductor muscles on the inner side of the hip-joint and joined most freely with branches of the internal circumflex. *A posterior set:* 1, three large branches from the gluteal to the external circumflex; 2, several branches from the sciatic around the great sciatic notch to the internal and external circumflex and the perforating branches of the profunda.

Branches.—Besides several small branches to the Psoas muscles and the neighboring lymphatic glands, the external iliac gives off two branches of considerable size, the

Deep Epigastric and Deep Circumflex Iliac.

The **deep epigastric artery** arises from the external iliac a few lines above Poupart's ligament. It at first descends to reach this ligament, and then ascends obliquely along the inner margin of the internal abdominal ring, lying between the transversalis fascia and peritoneum, and, passing upward, enters the sheath of the Rectus muscle over the semilunar fold of Douglas, having first perforated the transversalis fascia. It then ascends on the posterior surface of the muscle, and finally divides into numerous branches which anastomose above the umbilicus with the terminal branches of the internal mammary and inferior intercostal arteries. It is accompanied by two veins, which usually unite into a single trunk before their termination in the external iliac vein. As it winds round the internal abdominal ring it is crossed on its outer side by the vas deferens in the male and the round ligament in the female.

Branches.—The branches of this vessel are the following: the *cremasteric*, which accompanies the spermatic cord and supplies the Cremaster muscle, anastomosing with the spermatic artery; a *pubic branch*, which runs across Poupart's ligament, and then descends behind the pubes to the inner side of the femoral ring, and anastomoses with offsets from the obturator artery; *muscular branches*, some of which are distributed to the abdominal muscles and peritoneum, anastomosing with the lumbar and circumflex iliac arteries; others perforate the tendon of the External oblique and supply the integument, anastomosing with branches of the external epigastric.

Peculiarities.—The origin of the epigastric may take place from any part of the external iliac between Poupart's ligament and two inches and a half above it, or it may arise below this ligament from the femoral or from the deep femoral.

Union with Branches.—It frequently arises from the external iliac by a common trunk with the obturator. Sometimes the epigastric arises from the obturator, the latter vessel being furnished by the internal iliac, or the epigastric may be formed of two branches, one derived from the external iliac, the others from the internal iliac.

The **deep circumflex iliac artery** arises from the outer side of the external iliac nearly opposite the epigastric artery. It ascends obliquely outward behind Poupart's ligament contained in a fibrous sheath formed by the junction of the transversalis and iliac fasciæ to the anterior superior spinous process of the ilium. It then runs along the inner surface of the crest of the ilium to about its middle, where it pierces the Transversalis and runs backward between that muscle and the Internal oblique, to anastomose with the ilio-lumbar and gluteal arteries. Opposite the anterior superior spine of the ilium it gives off a large branch which ascends between the Internal oblique and Transversalis muscles, supplying them and anastomosing with the lumbar and epigastric arteries. The circumflex iliac artery is accompanied by two veins. These unite into a single trunk, which crosses the external iliac artery just above Poupart's ligament and enters the external iliac vein.

Femoral Artery (Fig. 404.)

The **Femoral Artery**[1] is the continuation of the external iliac. It commences immediately behind Poupart's ligament, midway between the anterior superior spine of the ilium and the symphysis pubis [or, rather, the spine of the pubes], and, passing down the fore part and inner side of the thigh, terminates at the opening in the Adductor magnus at the junction of the middle with the lower third of the thigh, where it becomes the popliteal artery. The upper two-thirds of a line drawn from a point midway between the anterior superior spine of the ilium and the symphysis pubis [or, rather, the spine of the pubes] to the inner side of the inner condyle of the femur, with the thigh abducted and rotated outward, will indicate the course of the artery. This vessel at the upper part of the thigh lies a little internal to the head of the femur; in the lower part of its course, on the inner side of the shaft of the bone, and between these two parts, the vessel is far away from the bone.

Fig. 404.

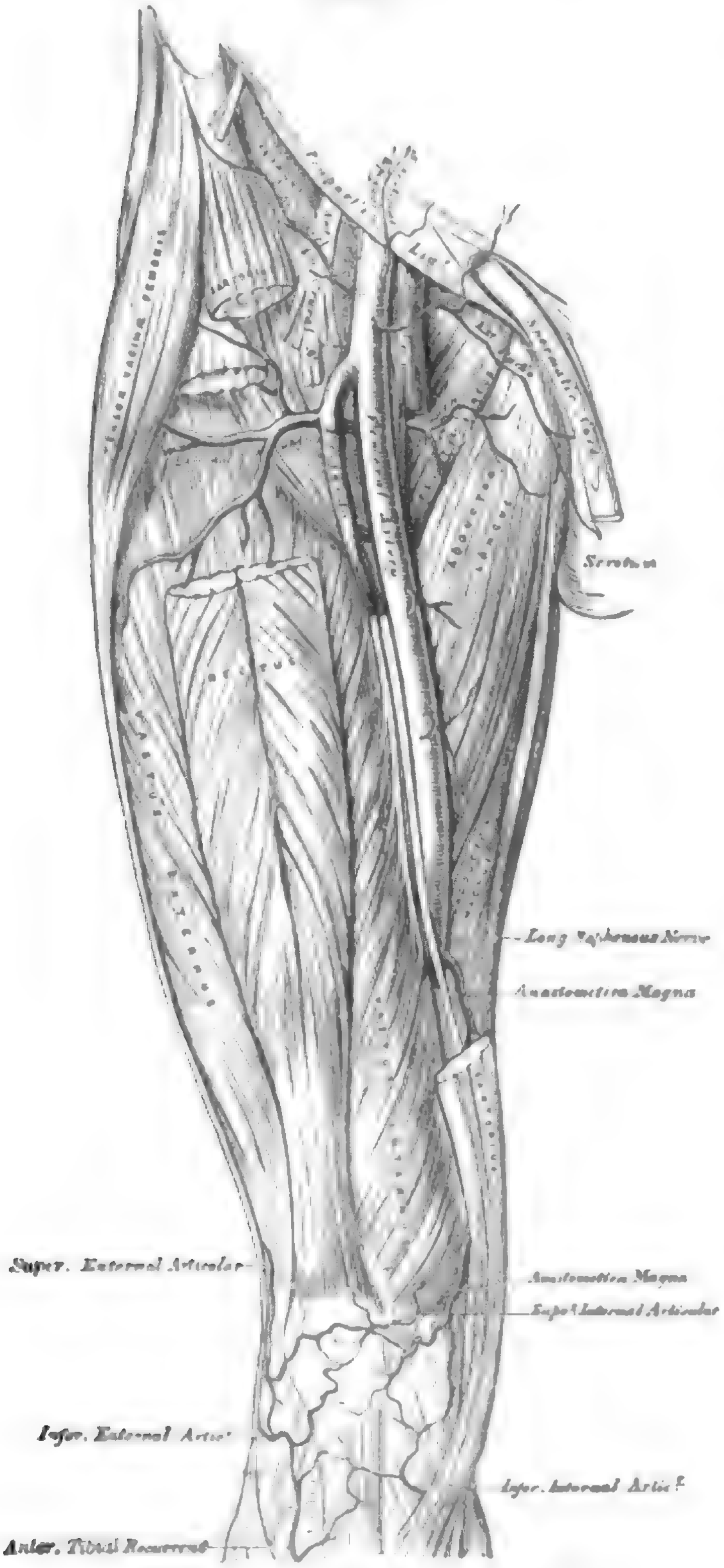
Poupart's
Lig.
Spermatic Cord
Scrotum
Long Saphenous Nerve
Anastomotica Magna
Super. External Articular
Anastomotica Magna
Supe^r Internal Articular
Infer. External Artic^r
Infer. Internal Artic^r
Anter. Tibial Recurrent

Surgical Anatomy of the Femoral Artery.

In the upper third of the thigh the femoral artery is very superficial, being covered by the integument, inguinal glands, and the superficial and deep fasciæ, and is contained in a triangular space called "Scarpa's triangle."

Scarpa's Triangle.—Scarpa's triangle corresponds to the depression seen immediately below the fold of the groin. It is a triangular space, the apex of which is directed downward, and the sides are formed externally by the Sartorius, internally by the Adductor longus, and [the base] above by Poupart's ligament. The floor of this space is formed from without inward by the Iliacus, Psoas, Pectineus, Adductor longus, and a small part of the Adductor brevis muscles, and it is divided into two nearly equal parts by the femoral vessels, which extend from the middle of its base to its apex, the artery giving off in this situation its cutaneous and profunda branches, the vein receiving the deep femoral and internal saphenous veins. In this space the femoral artery rests on the inner margin of the Psoas muscle, which separates it from the capsular ligament of the hip-joint. The artery in this situation has in front of it filaments from the crural branch of the genito-crural nerve and branches from the anterior crural, one of which is usually of considerable size; behind the artery is the branch to the Pectineus from the anterior crural. The femoral vein lies at its inner side, between the margins of the Pectineus and Psoas muscles [but quickly passes behind the artery as we go downward]. The anterior crural nerve lies about half an inch to the outer side of the femoral artery, deeply imbedded between the Iliacus and Psoas muscles. The femoral artery and vein are enclosed in a strong fibrous sheath formed by fibrous and cellular tissue, and by a process of fascia sent inward from the fascia lata: the vessels are separated, however, from one another by a thin fibrous partition.

---

[1] [Very often the name "common femoral" is given to the artery from Poupart's ligament to the origin of the profunda; "superficial femoral," to the direct continuation of the artery down the thigh; and "deep femoral" to the profunda.]

In the middle third of the thigh the femoral artery is more deeply seated, being covered by the integument, the superficial and deep fasciæ, and the Sartorius, and is contained in an aponeurotic canal (Hunter's canal). This canal is a depression between the Vastus internus externally and the Adductor longus and magnus internally, covered over by a dense fibrous band which extends transversely from the Vastus internus to the tendons of the Adductor longus and magnus muscles. The femoral vein lies on the outer side of the artery, in close apposition with it, and still more externally is the internal (long) saphenous nerve.

RELATIONS.—*From above downward* the femoral artery rests upon the Psoas muscle, which separates it from the margin of the pelvis and capsular ligament of the hip; it is next separated from the Pectineus by the profunda vessels and femoral vein; it then lies upon the Adductor longus; and, lastly, upon the tendon of the Adductor magnus, the femoral vein being interposed. To its *inner side* it is in relation above with the femoral vein, and lower down with the Adductor longus and Sartorius. To its *outer side* the Vastus internus separates it from the femur in the lower part of its course.

The *femoral vein* at Poupart's ligament lies close to the inner side of the artery, separated from it by a thin fibrous partition, but as it descends [very soon] gets behind it, and then to its outer side.

The *internal saphenous nerve* is situated on the outer side of the artery, in the middle third of the thigh, beneath the aponeurotic covering, but not usually within the sheath of the vessels. Small cutaneous nerves cross the front of the sheath.

PLAN OF THE RELATIONS OF THE FEMORAL ARTERY.

In Front.

Fascia lata.
Branch of anterior crural nerve to vastus internus.
Sartorius.
Long saphenous nerve.
Aponeurotic covering of Hunter's canal.

Inner Side.

Femoral vein (at upper part).
Adductor longus.
Sartorius.

Femoral Artery.

Outer Side.

Vastus internus.
Femoral vein (at lower part).

Behind.

Psoas magnus.
Profunda vein.
Pectineus.
Adductor longus.
Femoral vein.
Adductor magnus.

Peculiarities.—*Double Femoral reunited.*—Four cases are at present recorded in which the femoral artery divided into two trunks below the origin of the profunda, and became reunited near the opening in the Adductor magnus so as to form a single popliteal artery. One of them occurred in a patient operated upon for popliteal aneurism.

Change of Position.—A similar number of cases have been recorded in which the femoral artery was situated at the back of the thigh, the vessel being continuous above with the internal iliac, escaping from the pelvis through the great sacro-sciatic foramen, and accompanying the great sciatic nerve to the popliteal space, where its division occurred in the usual manner. The external iliac in these cases was small and terminated in the profunda.

Position of the Vein.—The femoral vein is occasionally placed along the inner side of the artery throughout the entire extent of Scarpa's triangle, or it may be slit, so that a large vein is placed on each side of the artery for a greater or less extent.

Origin of the Profunda.—This vessel occasionally arises from the inner side, and more rarely from the back, of the common trunk; but the more important peculiarity, in a surgical point of view, is that which relates to the height at which the vessel arises from the femoral. In three-fourths of a large number of cases it arose between one or two inches below Poupart's ligament; in a few cases the distance was less than an inch; more rarely, opposite the ligament; and in one case, above Poupart's ligament from the external iliac. Occasionally the distance between the origin of the vessel and Poupart's ligament exceeds two inches, and in one case it was found to be as much as four inches.

Surgical Anatomy.—*Compression* of the femoral artery, which is constantly requisite in amputations and other operations on the lower limb, and also for the cure of popliteal aneurisms, is most effectually made *immediately* below Poupart's ligament. In this situation the artery is very superficial, and is merely separated from the margin of the acetabulum and front of the head of the femur by the Psoas muscle; so that the surgeon, by means of his thumb or a compressor, may effectually control the circulation through it. [At this point, where the artery is so easily compressed, partial compression should be tried by the student in order to produce the "aneurismal thrill" by narrowing the vessel, and so he may make himself familiar with the feeling. By partial compression on the living model by a stethoscope the "aneurismal bruit" may be heard. The same can be done in the abdominal aorta, and might give rise to the erroneous diagnosis of aneurism.] This vessel may also be compressed in the middle third of the thigh by placing a compress over the artery beneath the tourniquet, and directing the pressure from within outward, so as to compress the vessel against the inner side of the shaft of the femur.

The **application of a ligature** to the femoral artery may be required in cases of wound or aneurism of the arteries of the leg, of the popliteal or femoral, and the vessel may be exposed and tied in any part of its course. The great depth of this vessel at its lower part, its close connection with important structures, and the density of its sheath render the operation in this situation one of much greater difficulty than the application of a ligature at its upper part, where it is more superficial.

Ligature of the femoral artery within two inches of its origin [*i. e.* of the "common femoral"] is usually considered unsafe, on account of the connection of large branches with it, the epigastric and deep circumflex iliac arising just above its origin; the profunda, from one to inches below; occasionally also one of the circumflex arteries arises from the vessel in the interspace between these. The profunda sometimes arises higher than the point above mentioned, and rarely between two and three inches (in one case four) below Poupart's ligament. It would appear, then, that the most favorable situation for the application of a ligature to the femoral is between four and five inches from its point of origin. In order to expose the artery in this situation, an incision between two and three inches long should be made in the course of the vessel, the patient lying in the recumbent position with the limb slightly flexed and abducted. A large vein is frequently met with, passing in the course of the artery to join the saphena; this must be avoided, and, the fascia lata having been cautiously divided and the Sartorius exposed, that muscle must be drawn outward in order to fully expose the sheath of the vessels. The finger being introduced into the wound and the pulsation of the artery felt, the sheath should be divided over the artery to a sufficient extent to allow of the introduction of the ligature, but no farther; otherwise the nutrition of the coats of the vessel may be interfered with, or muscular branches which arise from the vessel at irregular intervals may be divided. In this part of the operation a small nerve which crosses the sheath should be avoided. The aneurism-needle must be carefully introduced and kept close to the artery to avoid the femoral vein, which lies behind the vessel in this part of its course.

To expose the artery in Hunter's canal an incision should be made through the integument between three and four inches in length, a finger's breadth internal to the line of the artery in the middle of the thigh—*i. e.* midway between the groin and the knee. The fascia lata having been divided and the Sartorius muscle exposed, it should be drawn inward, when the strong fascia which is stretched across from the Adductors to the Vastus internus will be exposed, and must be freely divided; the sheath of the vessels is now seen, and must be opened, and the artery secured by passing the aneurism-needle between the vein and artery in the direction from without inward. The femoral vein in this situation lies on the outer side of the artery, the long saphenous nerve on its anterior and outer side.

It has been seen that the femoral artery occasionally divides into two trunks below the origin of the profunda. If in the operation for tying the femoral two vessels are met with, the surgeon should alternately compress each, in order to ascertain which vessel is connected with the aneurismal tumor or with the bleeding from the wound, and that one only should be tied which controls the pulsation or hemorrhage. If, however, it is necessary to compress both vessels before the circulation in the tumor is controlled, both should be tied, as it would be probable that they became reunited, as in the four instances referred to above.

Collateral Circulation.—When the common femoral is tied the main channels for carrying on the circulation are the anastomoses of the gluteal and circumflex iliac arteries above with the external circumflex below; of the obturator and sciatic above with the internal circumflex below: of the ilio-lumbar with the external circumflex; and of the comes nervi ischiadici with the arteries in the ham.

The principal agents in carrying on the collateral circulation after ligature of the superficial femoral artery are, according to Sir A. Cooper, as follows:[1]

"The arteria profunda formed the new channel for the blood." "The first artery sent off passed down close to the back of the thigh-bone, and entered the two superior articular branches of the popliteal artery."

"The second new large vessel arising from the profunda at the same part with the former passed down by the inner side of the Biceps muscle to a branch of the popliteal which was distributed to the Gastrocnemius muscle; whilst a third artery, dividing into several branches, passed down with the sciatic nerve behind the knee-joint, and some of its branches united themselves with the inferior articular arteries of the popliteal, with some recurrent branches of those arteries, with arteries passing to the Gastrocnemii, and, lastly, with the origin of the anterior and posterior tibial arteries."

"It appears, then, that it is those branches of the profunda which accompany the sciatic nerve that are the principal supporters of the new circulation."

In Porta's work[2] (Tab. xii., xiii.) is a good representation of the collateral circulation after the ligature of the femoral artery. The patient had survived the operation three years. The lower part of the artery is at least as large as the upper; about two inches of the vessel appear to have been obliterated. The external and internal circumflex arteries are seen anastomosing by a great number of branches with the lower branches of the femoral (muscular and anastomotica magna) and with the articular branches of the popliteal. The branches from the external circumflex are extremely large and numerous. One very distinct anastomosis can be traced between this artery on the outside and the anastomotica magna on the inside through the intervention of the superior external articular artery, with which they both anastomose; and blood reaches even the anterior tibial recurrent from the external circumflex by means of anastomosis with the same external articular artery. The perforating branches of the profunda are also seen bringing blood round the obliterated portion of the artery into long branches (muscular) which have been given off just below that portion. The termination of the profunda itself anastomoses most freely with the superior external articular. A long branch of anastomosis is also traced down from the internal iliac by means of the comes nervi ischiadici of the sciatic, which anastomoses on the popliteal nerves with branches from the popliteal and posterior tibial arteries. In this case the anastomosis had been too free, since the pulsation and growth of the aneurism recurred, and the patient died after ligature of the external iliac.

There is an interesting preparation in the Museum of the Royal College of Surgeons of a limb on which John Hunter had tied the femoral artery fifty years before the patient's death. The whole of the superficial femoral and popliteal artery seems to have been obliterated. The anastomosis by means of the comes nervi ischiadici, which is shown in Porta's plate, is distinctly seen: the external circumflex and the termination of the profunda artery seem to have been the chief channels of anastomosis; but the injection has not been a very successful one.

Branches.—The branches of the femoral artery are the

Superficial Epigastric.
Superficial Circumflex Iliac.
Superficial External Pudic.
Deep External Pudic.
Profunda. { External Circumflex.
Internal Circumflex.
Three Perforating. }
Muscular.
Anastomotica magna.

The **superficial epigastric** arises from the femoral about half an inch below Poupart's ligament, and, passing through the saphenous opening in the fascia lata, ascends on to the abdomen, in the superficial fascia covering the External oblique muscle, nearly as high as the umbilicus. It distributes branches to the inguinal glands, the superficial fascia, and the integument, anastomosing with branches of the deep epigastric and internal mammary arteries.

The **superficial circumflex iliac,** the smallest of the cutaneous branches, arises close to the preceding, and, piercing the fascia lata, runs outward, parallel with Poupart's ligament, as far as the crest of the ilium, dividing into branches which supply the integument of the groin, the superficial fascia, and the inguinal glands, anastomosing with the circumflex iliac and with the gluteal and external circumflex arteries.

---

[1] *Med.-Chir. Trans.*, vol. ii. 1811.

[2] *Alterazioni patologiche delle Arterie.*

The **superficial external pudic** (superior) arises from the inner side of the femoral artery close to the preceding vessels, and, after passing through the saphenous opening, courses inward across the spermatic cord, to be distributed to the integument on the lower part of the abdomen, the penis and scrotum in the male, and the labium in the female, anastomosing with branches of the internal pudic.

The **deep external pudic** (inferior), more deeply seated than the preceding, passes inward on the Pectineus muscle, covered by the fascia lata, which it pierces at the inner border of the thigh, its branches being distributed in the male to the integument of the scrotum and perineum, and in the female to the labium, anastomosing with branches of the superficial perineal artery.

The **Profunda Femoris** (*deep femoral artery*) nearly equals the size of the superficial femoral. It arises from the outer and back part of the femoral artery from one to two inches below Poupart's ligament. It at first lies on the outer side of the superficial femoral, and then passes behind it and the femoral vein to the inner side of the femur, and, passing downward beneath the Adductor longus, terminates at the lower third of the thigh in a small branch which pierces the Adductor magnus (and from this circumstance is sometimes called the fourth perforating artery), to be distributed to the flexor muscles on the back of the thigh, anastomosing with branches of the popliteal and inferior perforating arteries.

RELATIONS.—*Behind*, it lies first upon the Iliacus, and then on the Pectineus, Adductor brevis, and Adductor magnus muscles. *In front* it is separated from the femoral artery, above by the femoral and profunda veins, and below by the Adductor longus. On its *outer side* the origin of the Vastus internus separates it from the femur.

PLAN OF THE RELATIONS OF THE PROFUNDA ARTERY.

In Front.

Femoral and profunda veins.
Adductor longus.

Outer Side.
Vastus internus.

Behind.

Iliacus.
Pectineus.
Adductor brevis.
Adductor magnus.

The **External Circumflex Artery** supplies the muscles on the front of the thigh. It arises from the outer side of the profunda, passes horizontally outward between the divisions of the anterior crural nerve, and behind the Sartorius and Rectus muscles, and divides into three sets of branches—ascending, transverse, and descending.

The **ascending branches** pass upward, beneath the Tensor vaginæ femoris muscle, to the outer side of the hip, anastomosing with the terminal branches of the gluteal and circumflex iliac arteries.

The **descending branches**, three or four in number, pass downward, behind the Rectus, upon the Vasti muscles, to which they are distributed, one or two passing beneath the Vastus externus as far as the knee, anastomosing with the superior articular branches of the popliteal artery. These are accompanied by the branch of the anterior crural nerve to the Vastus externus.

The **transverse branches**, the smallest and least numerous, pass outward over the Crureus, pierce the Vastus externus, and wind round the femur to its back part just below the great trochanter, anastomosing at the back of the thigh with the internal circumflex, sciatic, and superior perforating arteries.

The **Internal Circumflex Artery** [Fig. 403, p. 590], smaller than the external, arises from the inner and back part of the profunda, and winds round the inner side of the femur, between the Pectineus and Psoas muscles. On reaching the upper border of the Adductor brevis it gives off two branches, one of which passes inward to be distributed to the Adductor muscles, the Gracilis, and Obturator externus, anastomosing with the obturator artery; the other descends, and passes beneath the Adductor brevis to supply it and the great Adductor; while the continuation of the vessel passes backward between the Quadratus femoris and upper border of the Adductor magnus, anastomosing with the sciatic, external circumflex, and superior perforating arteries ("the *crucial anastomosis*"). Opposite the hip-joint this branch gives off an articular vessel which enters the joint beneath the transverse ligament, and, after supplying the adipose tissue, passes along the round ligament to the head of the bone.

The **Perforating Arteries** (Fig. 403), usually three in number, are so called from their perforating the tendons of the Adductor brevis and magnus muscles to reach the back of the thigh. The first is given off above the Adductor brevis, the second in front of that muscle, and the third immediately below it.

The **first** or **superior perforating artery** passes backward between the Pectineus and Adductor brevis (sometimes perforates the latter); it then pierces the Adductor magnus close to the linea aspera, and divides into branches which supply both Adductors, the Biceps, and Gluteus maximus muscles, anastomosing with the sciatic, internal and external circumflex, and middle perforating arteries.

The **second** or **middle perforating artery**, larger than the first, pierces the tendons of the Adductor brevis and Adductor magnus muscles, and divides into ascending and descending branches, which supply the flexor muscles of the thigh, anastomosing with the superior and inferior perforating. The nutrient artery of the femur is usually given off from this branch.

The **third** or **inferior perforating artery** is given off below the Adductor brevis; it pierces the Adductor magnus and divides into branches which supply the flexor muscles of the thigh, anastomosing above with the perforating arteries, and below with the terminal branches of the profunda and the muscular branches of the popliteal.

[The **fourth perforating artery** is the termination of the profunda femoris.]

Muscular branches are given off from the superficial femoral throughout its entire course. They vary from two to seven in number, and supply chiefly the Sartorius and Vastus internus.

The **anastomotica magna** arises from the femoral artery just before it passes through the tendinous opening in the Adductor magnus muscle, and divides into a superficial and deep branch.

The **superficial branch** accompanies the long saphenous nerve beneath the Sartorius, and, piercing the fascia lata, is distributed to the integument.

The **deep branch** descends in the substance of the Vastus internus, lying in front of the tendon of the Adductor magnus, to the inner side of the knee, where it anastomoses with the superior internal articular artery and recurrent branch of the anterior tibial. A branch from this vessel crosses outward above the articular surface of the femur, forming an anastomotic arch with the superior external articular artery, and supplies branches to the knee-joint.

POPLITEAL ARTERY.

The **Popliteal Artery** commences at the termination of the femoral at the opening in the Adductor magnus, and, passing obliquely downward and outward behind the knee-joint to the lower border of the Popliteus muscle, divides into the *anterior* and *posterior tibial* arteries. Through the whole of this extent the artery lies in the popliteal space.

THE POPLITEAL SPACE (Fig. 405, p. 604).

Dissection.—A vertical incision about eight inches in length should be made along the back part of the knee-joint, connected above and below by a transverse incision from the inner to the outer side of the limb. The flaps of integument included between these incisions should be reflected in the direction shown in Fig. 337, p. 473.

On removing the integument the superficial fascia is exposed, and ramifying in it along the middle line are found some filaments of the small sciatic nerve, and toward the inner part some offsets from the internal cutaneous nerve.

The superficial fascia having been removed, the fascia lata is brought into view. In this region it is strong and dense, being strengthened by transverse fibres and firmly attached to the tendons on the inner and outer sides of the space. It is sometimes perforated below by the external saphenous vein. This fascia having been reflected back in the same direction as the integment, the small sciatic nerve and external saphenous vein are seen immediately beneath it in the middle line. If the loose adipose tissue is now removed, the boundaries and contents of the space may be examined.

Boundaries.—The **popliteal space,** or the **ham,** occupies the lower third of the thigh and the upper fifth of the leg, extending from the aperture in the Adductor magnus to the lower border of the Popliteus muscle. It is a lozenge-shaped space, being widest at the back part of the knee-joint and deepest above the articular end of the femur. It is bounded externally, above the joint, by the Biceps, and below the joint by the Plantaris and external head of the Gastrocnemius; internally, above the joint, by the Semitendinosus, Semimembranosus, Gracilis, and Sartorius; below the joint, by the inner head of the Gastrocnemius.

Above, it is limited by the apposition of the inner and outer hamstring muscles; below, by the junction of the two heads of the Gastrocnemius. The floor is formed by the lower part of the posterior surface of the shaft of the femur, the posterior ligament of the knee-joint, the upper end of the tibia, and the fascia covering the Popliteus muscle, and the space is covered in by the fascia lata. [It will well repay the student to notice closely the boundaries of the popliteal space on the living model, both at rest and in action (and especially resisted action) and in varying degrees of flexion. The thin tendon of the Semitendinosus can always be differentiated from its thicker neighbor, the Semimembranosus, the tendon of which lies farther from the middle line of the ham, though higher up its belly is the inner border of the space. The tendons of the Gracilis and Sartorius are usually obscure, unless strongly contracted. The Biceps tendon is easily felt. The different degrees of tension of the deep fascia are very important. In extension it is tense, and nothing can be felt beneath it; in complete flexion the parts are inaccessible, the thigh and the leg being apposed; in partial flexion the artery can be felt and compressed. The nerve is obscurely felt.]

Contents.—It contains the popliteal vessels and their branches, together with the termination of the external saphenous vein, the internal and external popliteal nerves and their branches, the small sciatic nerve, the articular branch from the obturator nerve, a few small lymphatic glands, and a considerable quantity of loose adipose tissue.

Position of Contained Parts.—The internal popliteal nerve descends in the middle line of the space, lying superficial and crossing the artery from without inward. The external popliteal nerve descends on the outer side of the space, lying close to the tendon of the Biceps muscle. More deeply at the bottom of the space are the popliteal vessels, the vein lying superficial and a little external to the artery, to which it is closely united by dense areolar tissue; sometimes the vein is placed on the inner instead of the outer side of the artery; or the vein may be double, the artery lying between the two venæ comites, which are usually connected by short transverse branches. More deeply and close to the surface of the bone is the popliteal artery, and passing off from it at right angles are its articular branches. The articular branch from the obturator nerve descends upon the popliteal artery to supply the knee, and occasionally there is found deep in the space an articular filament from the great sciatic nerve. The popliteal lymphatic glands, four or five in number, are found surrounding the artery; one usually lies superficial to the vessel, another is situated between it and the bone, and the rest are placed on either side of it. The bursæ usually found in this place are: 1. On the outer side one beneath the outer head of the Gastrocnemius (which sometimes communicates with the joint), and one beneath the tendon of the Popliteus, which is almost always an extension of the synovial membrane. Sometimes also there is a bursa above the tendon of the Popliteus, between it and the external lateral ligament. 2. On the inner side of the joint there is a large bursa between the inner head of the Gastrocnemius and the femur, which sends a prolongation between the tendons of the Gastrocnemius and Semimembranosus, and lies in contact with the ligament of Winslow. This bursa often communicates with the joint. There is a second bursa between the tendon of the Semimembranosus and the head of the tibia, and sometimes a bursa between the tendons of the Semitendinosus and Semimembranosus.

The **Popliteal Artery,** in its course downward from the aperture in the Adductor magnus to the lower border of the Popliteus muscle, rests first on the inner and then on the posterior surface of the femur; in the middle of its course, on the posterior ligament of the knee-joint; and below, on the fascia covering the Popliteus muscle. *Superficially,* it is covered above by the Semimembranosus; in the middle of its course, by a quantity of fat which separates it from the deep fascia and integument; and below, it is overlapped by the Gastrocnemius, Plantaris, and Soleus muscles, the popliteal vein, and the internal popliteal nerve. The popliteal vein, which is intimately attached to the artery, lies superficial and external to it, until near its termination, when it crosses it and lies to its inner side. The popliteal nerve is still more superficial and external, crossing, however, the artery below the joint and lying on its inner side. *Laterally,* the artery is bounded by the muscles which are situated on either side of the popliteal space.

Peculiarities in Point of Division.—Occasionally the popliteal artery divides prematurely into its terminal branches; this division occurs most frequently opposite the knee-joint.

Unusual Branches.—The artery sometimes divides into the anterior tibial and peroneal, the posterior tibial being wanting or very small. In a single case the popliteal was found to divide into three branches, the anterior and posterior tibial and peroneal.

Surgical Anatomy.—Ligature of the popliteal artery is required in cases of wound of that vessel, but for aneurism of the posterior tibial it is preferable to tie the superficial femoral. The popliteal may be tied in the upper or lower part of its course; but in the middle of the ham the operation is attended with considerable difficulty, from the great depth of the artery and from the extreme degree of tension of the lateral boundaries of the space.

In order to expose the vessel in the upper part of its course, the patient should be placed in the prone position with the limb extended. An incision about three inches in length should then be made through the integument along the posterior margin of the Semimembranosus, and, the fascia lata having been divided, this muscle must be drawn inward. The internal popliteal nerve will be first exposed, lying very superficial and external to the artery; beneath this will be seen the popliteal vein, and still deeper and to its inner side the artery. The vein and nerve must be cautiously separated from the artery and the aneurism-needle passed around the vessel from without inward.

To expose the vessel in the lower part of its course, where the artery lies between the two heads of the Gastrocnemius, the patient should be placed in the same position as in the preceding operation. An incision should then be made through the integument in the middle line, commencing opposite the bend of the knee-joint, care being taken to avoid the external saphenous vein and nerve. After dividing the deep fascia and separating some dense cellular membrane, the artery, vein, and nerve will be exposed, descending between the two heads of the Gastrocnemius. Some muscular branches of the popliteal should be avoided if possible, or, if divided, tied immediately. The leg being now flexed, in order the more effectually to separate the two heads of the Gastrocnemius the nerve should be drawn inward and the vein outward, and the aneurism-needle passed between the artery and vein from without inward.

Plan of Relations of Popliteal Artery.

In Front.

Femur.
Ligamentum posticum.
Popliteus.

Inner Side.

Semimembranosus.
Internal condyle.
Gastrocnemius (inner head).

Popliteal Artery.

Outer Side.

Biceps.
Outer condyle.
Gastrocnemius (outer head).
Plantaris.

Behind.

Semimembranosus.
Fascia.
Popliteal vein.
Internal popliteal nerve.
Gastrocnemius.
Plantaris.
Soleus.

The branches of the popliteal artery are the

Muscular { Superior.
Inferior or Sural.
Cutaneous.
Superior External Articular.
Superior Internal Articular.
Azygos Articular.
Inferior External Articular.
Inferior Internal Articular.

The **superior muscular branches**, two or three in number, arise from the upper part of the popliteal artery, and are distributed to the Vastus externus and flexor muscles of the thigh, anastomosing with the inferior perforating and terminal branches of the profunda.

The **inferior muscular (sural)** are two large branches which are distributed to the two heads of the Gastrocnemius and to the Plantaris muscle. They arise from the popliteal artery opposite the knee-joint.

Cutaneous branches descend on each side and in the middle of the limb between the Gastrocnemius and integument; they arise separately from the popliteal artery or from some of its branches, and supply the integument of the calf.

The **superior articular arteries**, two in number, arise one on either side of the popliteal, and wind round the femur immediately above its condyles to the front of the knee-joint. The *internal branch* passes beneath the tendon of the Adductor magnus, and divides into two, one of which supplies the Vastus internus, inosculating with the anastomotica magna and inferior internal articular; the other ramifies close to the surface of the femur, supplying it and the knee-joint, and anastomosing with the superior external articular artery. The *external branch* passes above the outer condyle, beneath the tendon of the Biceps, and divides into a superficial and deep branch: the superficial branch supplies the Vastus externus, and anastomoses with the descending branch of the external circumflex artery; the deep branch supplies the lower part of the femur and knee-joint, and forms an anastomotic arch across the bone with the anastomotica magna artery.

The **azygos articular** is a small branch arising from the popliteal artery opposite the bend of the knee-joint. It pierces the posterior ligament, and supplies the ligaments and synovial membrane in the interior of the articulation.

The **inferior articular arteries**, two in number, arise from the popliteal beneath the Gastrocnemius, and wind round the head of the tibia below the joint. The *internal* one passes below the inner tuberosity, beneath the internal lateral ligament, at the anterior border of which it ascends to the front and inner side of the joint to supply the head of the tibia and the articulation of the knee. The *external* one passes outward above the head of the fibula to the front of the knee-joint, lying in its course beneath the outer head of the Gastrocnemius, the external lateral ligament, and the tendon of the Biceps muscle, and divides into branches which anastomose with the inferior internal articular artery, the superior articular arteries, and the recurrent branch of the anterior tibial.

ANTERIOR TIBIAL ARTERY (Fig. 406).

The **Anterior Tibial Artery** commences at the bifurcation of the popliteal at the lower border of the Popliteus muscle, passes forward between the two heads of the Tibialis posticus, and through the aperture left between the bones at the upper part of the interosseous membrane, to the deep part of the front of the leg; it then descends on the anterior surface of the interosseous membrane and of the tibia to the bend of the ankle-joint, where it lies more superficially and becomes the *dorsalis pedis.* A line drawn from the inner side of the head of the fibula to midway between the two malleoli will mark the course of the artery, the point where the artery comes in front of the interosseous membrane being in this line one and a quarter inches below the level of the head of the fibula.

RELATIONS.—In the upper two-thirds of its extent it rests upon the interosseous membrane, to which it is connected by delicate fibrous arches thrown across it; in the lower third, upon the front of the tibia and the anterior ligament of the ankle-joint. In the upper third of its course it lies between the Tibialis anticus and Extensor longus digitorum; in the middle third, between the Tibialis anticus and Extensor proprius pollicis. At the bend of the ankle it is crossed by the tendon of the Extensor proprius pollicis, and lies between it and the innermost tendon of the Extensor longus digitorum. It is covered in the upper two-thirds of its course by the muscles which lie on either side of it and by the deep fascia; in the lower third, by the integument, annular ligament, and fascia.

The anterior tibial artery is accompanied by two veins (venæ comites) which lie one on either side of the artery; the anterior tibial nerve lies at first to its outer side, and about the middle of the leg is placed superficial to it; at the lower part of the artery the nerve is generally again on the outer side. [See Rule, p. 562.]

PLAN OF THE RELATIONS OF THE ANTERIOR TIBIAL ARTERY.

In Front.

Integument, superficial and deep fasciæ.
Anterior tibial nerve.
Tibialis anticus (overlaps it in upper part of leg).
Extensor longus digitorum } (overlap it slightly).
Extensor proprius pollicis }

Inner Side.

Tibialis anticus.
Extensor proprius pollicis
(crosses it at its lower part).

Anterior Tibial.

Outer Side.

Anterior tibial nerve.
Extensor longus digitorum.
Extensor proprius pollicis.

Behind.

Interosseous membrane.
Tibia.
Anterior ligament of ankle-joint.

Peculiarities in Size.—This vessel may be diminished in size, may be deficient to a greater or less extent, or may be entirely wanting, its place being supplied by perforating branches from the posterior tibial or by the anterior division of the peroneal artery.

Course.—The artery occasionally deviates in its course toward the fibular side of the leg, regaining its usual position beneath the annular ligament at the front of the ankle. In two instances the vessel has been found to approach the surface in the middle of the leg, being covered merely by the integument and fascia below that point.

Surgical Anatomy.—The anterior tibial artery may be tied in the upper or lower part of

Digitized

FIG. 405.

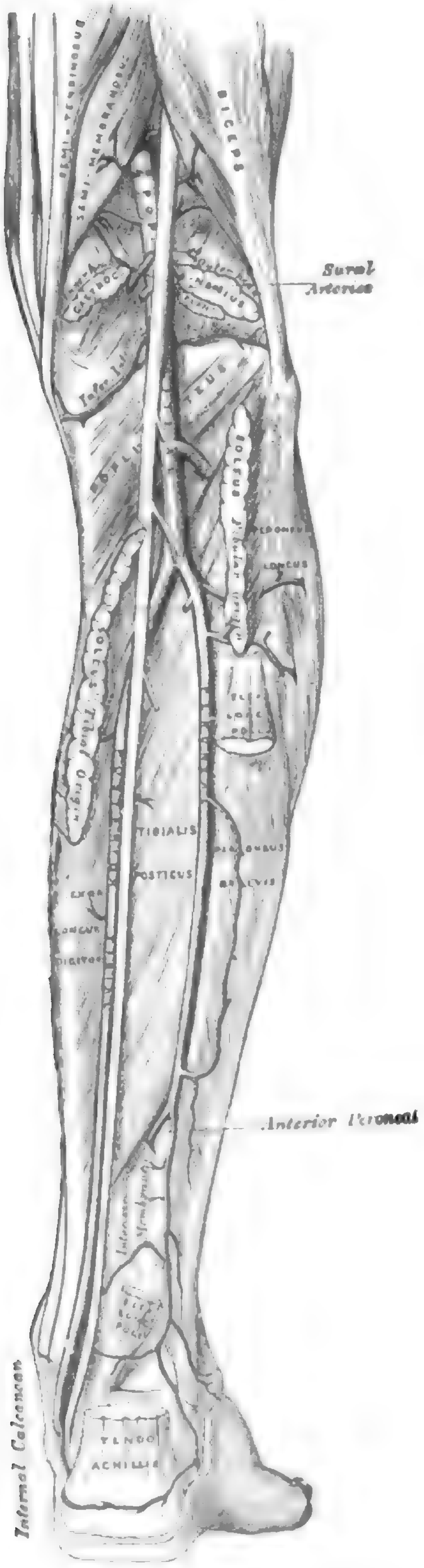
SEMI-TENDINOSUS
SEMI-MEMBRANOSUS
BICEPS
Sural Arteries
GASTROC.
Anterior Peroneal
SOLEUS Tibial Origin
SOLEUS Fibular Origin
PERONEUS
LONGUS
TIBIALIS
POSTICUS
PERONEUS
BREVIS
FLEX.
LONGUS
DIGITOR.
TENDO
ACHILLIS
Internal Calcanean

The Popliteal, Posterior Tibial, and Peroneal Arteries.

FIG. 406.

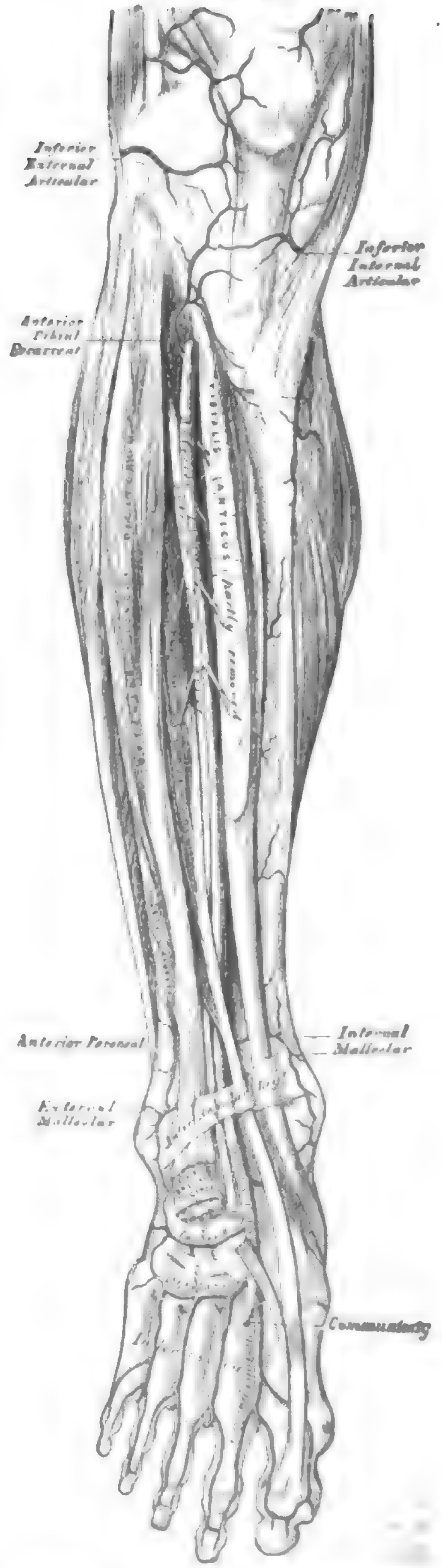
Inferior External Articular
Inferior Internal Articular
Anterior Tibial Recurrent
TIBIALIS ANTICUS
Anterior Peroneal
Internal Malleolar
External Malleolar
Communicating

Surgical Anatomy of the Anterior Tibial and Dorsalis Pedis Arteries.

the leg. In the upper part the operation is attended with great difficulty, on account of the depth of the vessel from the surface. An incision about four inches in length should be made through the integument, midway between the spine of the tibia and the outer margin of the fibula, the fascia and intermuscular septum between the Tibialis anticus and Extensor longus digitorum being divided to the same extent. The foot must be flexed to relax these muscles, and they must be separated from each other by the finger. The artery is then exposed deeply seated, lying upon the interosseous membrane, the nerve lying externally and one of the venæ comites on either side; these must be separated from the artery before the aneurism-needle is passed around it. [Once that the interspace between the Tibialis anticus and the Extensor longus digitorum is reached, it is of the utmost importance to remember that the Extensor proprius pollicis is interposed between these muscles, and does not reach the surface of the leg in the upper two-thirds. Hence in going downward the interspace between the Tibialis anticus and Extensor longus digitorum bifurcates like an inverted λ, the two legs of the λ having between them the Extensor proprius pollicis; and one may easily get to the wrong side of this muscle. The artery lies in the space between the Tibialis anticus and the Extensor proprius pollicis. To find the *anterior tibial artery* stick to the *anterior tibial muscle.*]

To tie the vessel in the lower third of the leg above the ankle-joint, an incision about three inches in length should be made through the integument between the tendons of the Tibialis anticus and Extensor proprius pollicis muscles, the deep fascia being divided to the same extent; the tendon on either side should be held aside, when the vessel will be seen lying upon the tibia, with the nerve superficial to it, and one of the venæ comites on either side.

In order to secure the artery over the instep an incision should be made on the fibular side of the tendon of the Extensor proprius pollicis, between it and the innermost tendon of the long Extensor; the deep fascia having been divided, the artery will be exposed, the nerve lying either superficial to it or to its outer side.

The branches of the anterior tibial artery are the

Recurrent Tibial.	Internal Malleolar.
Muscular.	External Malleolar.

The **recurrent branch** arises from the anterior tibial as soon as that vessel has passed through the interosseous space; it ascends in the Tibialis anticus muscle, and ramifies on the front and sides of the knee-joint, anastomosing with the articular branches of the popliteal and with the anastomotica magna.

The **muscular branches** are numerous; they are distributed to the muscles which lie on either side of the vessel, some piercing the deep fascia to supply the integument, others passing through the interosseous membrane and anastomosing with the branches of the posterior tibial and peroneal arteries.

The **malleolar arteries** supply the ankle-joint. The *internal* arises about two inches above the articulation, and passes beneath the tendons of the Extensor proprius pollicis and Tibialis anticus to the inner ankle, upon which it ramifies, anastomosing with branches of the posterior tibial and internal plantar arteries and with the internal calcanean from the posterior tibial. The *external* passes beneath the tendons of the Extensor longus digitorum and Peroneus tertius, and supplies the outer ankle, anastomosing with the anterior peroneal artery and with ascending branches from the tarsal branch of the dorsalis pedis.

DORSALIS PEDIS ARTERY (Fig. 406, p. 604).

The **Dorsalis Pedis**, the continuation of the anterior tibial, passes forward from the bend of the ankle along the tibial side of the foot to the back part of the first interosseous space, where it divides into two branches, the *dorsalis hallucis* and *communicating*.

RELATIONS.—This vessel in its course forward rests upon the astragalus, scaphoid, and internal cuneiform bones and the ligaments connecting them, being covered by the integument and fascia, and crossed near its termination by the innermost tendon of the Extensor brevis digitorum. On its *tibial side* is the tendon of the Extensor proprius pollicis; on its *fibular side* are the innermost tendon of the Extensor longus digitorum and the termination of the anterior tibial nerve. It is accompanied by two veins.

Plan of the Relations of the Dorsalis Pedis Artery.

In Front.
Integument and fascia.
Innermost tendon of Extensor brevis digitorum.

Tibial Side.
Extensor proprius pollicis.

Dorsalis Pedis.

Fibular Side.
Extensor longus digitorum.
Anterior tibial nerve.

Behind.
Astragalus.
Scaphoid.
Internal cuneiform and their ligaments.

Peculiarities in Size.—The dorsal artery of the foot may be larger than usual to compensate for a deficient plantar artery; or it may be deficient in its terminal branches to the toes, which are then derived from the internal plantar; or its place may be supplied altogether by a large anterior peroneal artery.

Position.—The artery frequently curves outward, lying external to the line between the middle of the ankle and the back part of the first interosseous space.

Surgical Anatomy.—This artery may be tied by making an incision through the integument, between two and three inches in length, on the fibular side of the tendon of the Extensor proprius pollicis, in the interval between it and the inner border of the short Extensor muscle. The incision should not extend farther forward than the back part of the first interosseous space, as the artery divides in that situation. The deep fascia being divided to the same extent, the artery will be exposed, the nerve lying upon its outer side.

Branches.—The branches of the dorsalis pedis are the

Tarsal.
Metatarsal.
Dorsalis pollicis or hallucis.
Communicating.
Interosseous.

The **tarsal artery** arises from the dorsalis pedis as that vessel crosses the scaphoid bone; it passes in an arched direction outward, lying upon the tarsal bones and covered by the Extensor brevis digitorum; it supplies that muscle and the articulations of the tarsus, and anastomoses with branches from the metatarsal, external malleolar, peroneal, and external plantar arteries.

The **metatarsal** arises a little anterior to the preceding; it passes outward to the outer part of the foot, over the bases of the metatarsal bones, beneath the tendons of the short Extensor, its direction being influenced by its point of origin, and it anastomoses with the tarsal and external plantar arteries. This vessel gives off three branches: the *interosseous*, which pass forward upon the three outer Dorsal interossei muscles, and in the clefts between the toes divide into two dorsal collateral branches for the adjoining toes. At the back part of each interosseous space these vessels receive the posterior perforating branches from the plantar arch, and at the fore part of each interosseous space they are joined by the anterior perforating branches from the digital artery. The outermost interosseous artery gives off a branch which supplies the outer side of the little toe.

The **dorsalis hallucis** runs forward along the outer border of the first metatarsal bone, and at the cleft between the first and second toes divides into two branches, one of which passes inward beneath the tendon of the Extensor proprius pollicis, and is distributed to the inner border of the great toe; the other branch bifurcates to supply the adjoining sides of the great and second toes.

The **communicating artery** dips down into the sole of the foot between the two heads of the first Dorsal interosseous muscle, and inosculates with the termination of the external plantar artery to complete the plantar arch. It here gives off two digital branches: one runs along the inner side of the great toe on its plantar surface; the other passes forward along the first metatarsal space, and bifurcates for the supply of the adjacent sides of the great and second toes.

POSTERIOR TIBIAL ARTERY [Fig. 405, p. 604].

The **Posterior Tibial Artery** is of large size, and extends obliquely downward from the lower border of the Popliteus muscle, along the tibial side of the leg, to the fossa between the inner ankle and the heel, where it divides beneath the origin of the Abductor pollicis into the *internal* and *external plantar* arteries. [As Wyeth has shown, it is important to note that this bifurcation takes place at a point corresponding to a line drawn from the point of the malleolus to the middle of the heel.] At its origin it lies opposite the interval between the tibia and fibula; as it descends it approaches the inner side of the leg, lying behind the tibia, and in the lower part of its course is situated midway between the inner malleolus and the tuberosity of the os calcis.

RELATIONS.—It lies successively upon the Tibialis posticus, the Flexor longus digitorum, the tibia, and the back part of the ankle-joint. It is *covered* by the deep transverse fascia, which separates it above from the Gastrocnemius and Soleus muscles. In the lower third, where it is more superficial, it is covered only by the integument and fascia, and runs parallel with the inner border of the tendo Achillis. It is accompanied by two veins and by the posterior tibial nerve, which lies at first to the inner side of the artery, but soon crosses it, and is, in the greater part of its course, on its outer side. [See Rule, p. 562.]

PLAN OF THE RELATIONS OF THE POSTERIOR TIBIAL ARTERY.

In Front.

Tibialis posticus.
Flexor longus digitorum.
Tibia.
Ankle-joint.

Inner Side.

Posterior tibial nerve,
upper fourth.

Posterior
Tibial.

Outer Side.

Posterior tibial nerve,
lower three-fourths.

Behind.

Integument and fascia.
Gastrocnemius.
Soleus.
Deep transverse fascia.
Posterior tibial nerve.

Behind the inner ankle the tendons and blood-vessels are arranged in the following order, from within outward [*i. e.* from the inner malleolus toward the heel]: First, the tendons of the Tibialis posticus and Flexor longus digitorum, lying in the same groove, behind the inner malleolus, the former being the most internal; external to these is the posterior tibial artery, having a vein on either side; and still more externally the posterior tibial nerve. About half an inch nearer the heel is the tendon of the Flexor longus pollicis. [The artery is therefore the *middle* one of these five structures.]

Peculiarities in Size.—The posterior tibial is not unfrequently smaller than usual, or absent, its place being supplied by a large peroneal artery, which passes inward at the lower end of the tibia, and either joins the small tibial artery or continues alone to the sole of the foot.

Surgical Anatomy.—The *application of a ligature* to the posterior tibial may be required in cases of wound of the sole of the foot attended with great hemorrhage, when the vessel should be tied at the inner ankle. In cases of wound of the posterior tibial, it will be necessary to enlarge the opening so as to expose the vessel at the wounded point, excepting where the vessel is injured by a punctured wound from the front of the leg. In cases of aneurism from wound of the artery low down, the vessel should be tied in the middle of the leg. But in aneurism of the posterior tibial high up, it would be better to tie the femoral artery.

To tie the posterior tibial artery at the ankle a semilunar incision should be made through the integument, about two inches and a half in length, midway between the heel and inner ankle, or a little nearer the latter. The subcutaneous cellular tissue having been divided, a strong and dense fascia, the internal annular ligament, is exposed. This ligament is continuous above with the deep fascia of the leg, covers the vessels and nerves, and is intimately adherent to the sheaths of the tendons. This having been cautiously divided upon a director, the sheath of the vessels is exposed, and, being opened, the artery is seen with one of the venæ comites on each side. The aneurism-needle should be passed round the vessel from the heel toward the ankle, in order to avoid the posterior tibial nerve, care being at the same time taken not to include the venæ comites.

The vessel may also be tied in the lower third of the leg by making an incision about three inches in length, parallel with the inner margin of the tendo Achillis. The internal saphenous vein being carefully avoided, the two layers of fascia must be divided upon a director, when the artery is exposed along the outer margin of the Flexor longus digitorum, with one of its venæ comites on either side, and the nerve lying external to it.

To tie the posterior tibial in the middle of the leg is a very difficult operation, on account of the great depth of the vessel from the surface and its being covered by the Gastrocnemius and Soleus muscles. The patient being placed in the recumbent position, the injured limb should rest on its outer side, the knee being partially bent, and the foot extended, so as to relax the muscles of the calf. An incision about four inches in length should then be made through the integument, a finger's breadth behind the inner margin of the tibia, taking care to avoid the internal saphenous vein. The deep fascia having been divided, the margin of the Gastrocnemius is exposed, and must be drawn aside, and the tibial attachment of the Soleus divided, a director being previously passed beneath it. The artery may now be felt pulsating beneath the deep fascia [*i. e.* the intermuscular fascia which separates the calf muscles from the deeper muscles of the leg] about an inch from the margin of the tibia. The fascia having been divided, and the limb placed in such a position as to relax the muscles of the calf as much as possible, the veins should be separated from the artery, and the aneurism-needle passed round the vessel from without inward, so as to avoid wounding the posterior tibial nerve.

The branches of the posterior tibial artery are the

Peroneal.
Anterior Peroneal.
Muscular.
Nutrient.
Communicating.
Internal Calcanean.

[Fig. 407.

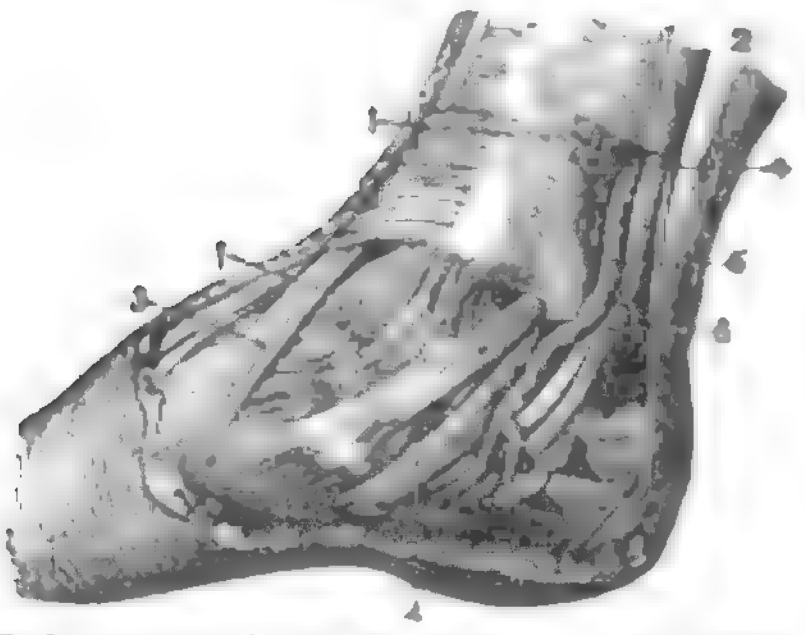

Relations of Parts behind the Inner Malleolus (from Hirschfeldt and Leveillé): 1, 1, Tibialis posticus; 2, Tendo Achillis; 3, Tibialis anticus, 5, 4, Flexor longus digitorum; 6, posterior tibial artery; 8, posterior tibial nerve.—The tendon of the Flexor longus pollicis is too deeply placed to be shown in this view.]

The **Peroneal Artery** lies deeply seated along the back part of the fibular side of the leg. It arises from the posterior tibial about an inch below the lower border of the Popliteus muscle, passes obliquely outward to the fibula, and then descends along the inner border of that bone, under cover or through the fibres of the Flexor longus pollicis, to the lower third of the leg, where it gives off the *anterior peroneal.* It then passes across the articulation between the tibia and fibula to the outer side of the os calcis, supplying the neighboring muscles and back of the ankle, and anastomosing with the external malleolar, tarsal, and external plantar arteries.

Relations.—This vessel rests at first upon the Tibialis posticus, and then for the greater part of its course on the interosseous membrane close to the bone, covered or surrounded by the fibres of the Flexor longus pollicis. It is *covered* in the upper part of its course by the Soleus and deep transverse fascia; *below*, by the Flexor longus pollicis.

Plan of the Relations of the Peroneal Artery.

In Front.
Tibialis posticus.
Interosseous membrane.

Outer Side.
Fibula.
Flexor longus pollicis.

Peroneal Artery.

Inner Side.
Flexor longus pollicis.

Behind.
Soleus.
Deep transverse fascia.
Flexor longus pollicis.

Peculiarities in Origin.—The peroneal artery may arise three inches below the Popliteus, or from the posterior tibial high up, or even from the popliteal.

Its size is more frequently increased than diminished; and then it either reinforces the posterior tibial by its junction with it, or altogether takes the place of the posterior tibial in the lower part of the leg and foot, the latter vessel only existing as a short muscular branch. In those rare cases where the peroneal artery is smaller than usual a branch from the posterior tibial supplies its place; and a branch from the anterior tibial compensates for the diminished anterior peroneal artery. In one case the peroneal artery has been found entirely wanting.

The anterior peroneal is sometimes enlarged, and takes the place of the dorsal artery of the foot.

The peroneal artery in its course gives off branches to the Soleus, Tibialis posticus, Flexor longus pollicis, and Peronei muscles, and a nutrient branch to the fibula.

The **anterior peroneal,** the only named branch of the peroneal artery, pierces the interosseous membrane about two inches above the outer malleolus to reach the fore part of the leg, and, passing down beneath the Peroneus tertius to the outer ankle, ramifies on the front and outer side of the tarsus, anastomosing with the external malleolar and tarsal arteries.

The **nutrient artery** of the tibia arises from the posterior tibial near its origin, and, after supplying a few muscular branches, enters the nutrient canal of that bone, which it traverses obliquely from above downward. This is the largest nutrient artery of bone in the body.

The **muscular branches** of the posterior tibial are distributed to the Soleus and deep muscles along the back of the leg.

The **communicating branch** to the peroneal runs transversely across the back of the tibia about two inches above its lower end, passing beneath the Flexor longus pollicis.

FIG. 408.

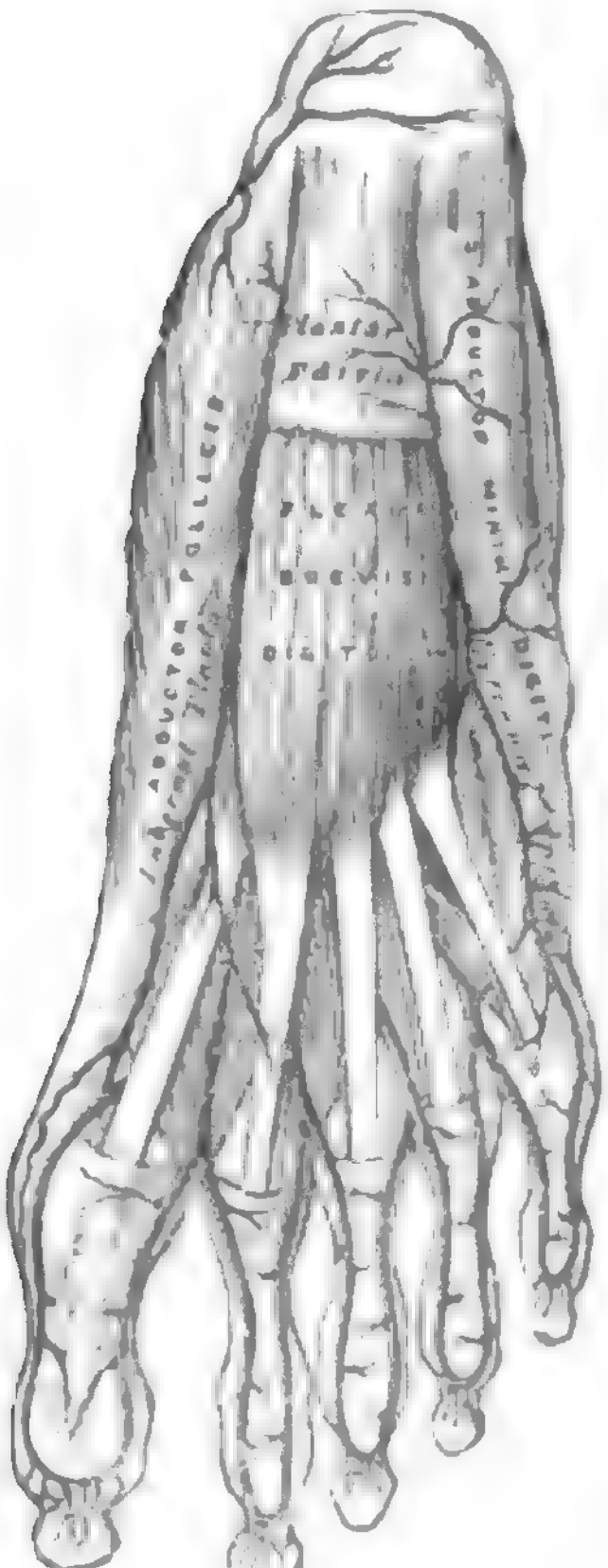

The Plantar Arteries, superficial view.

FIG. 409.

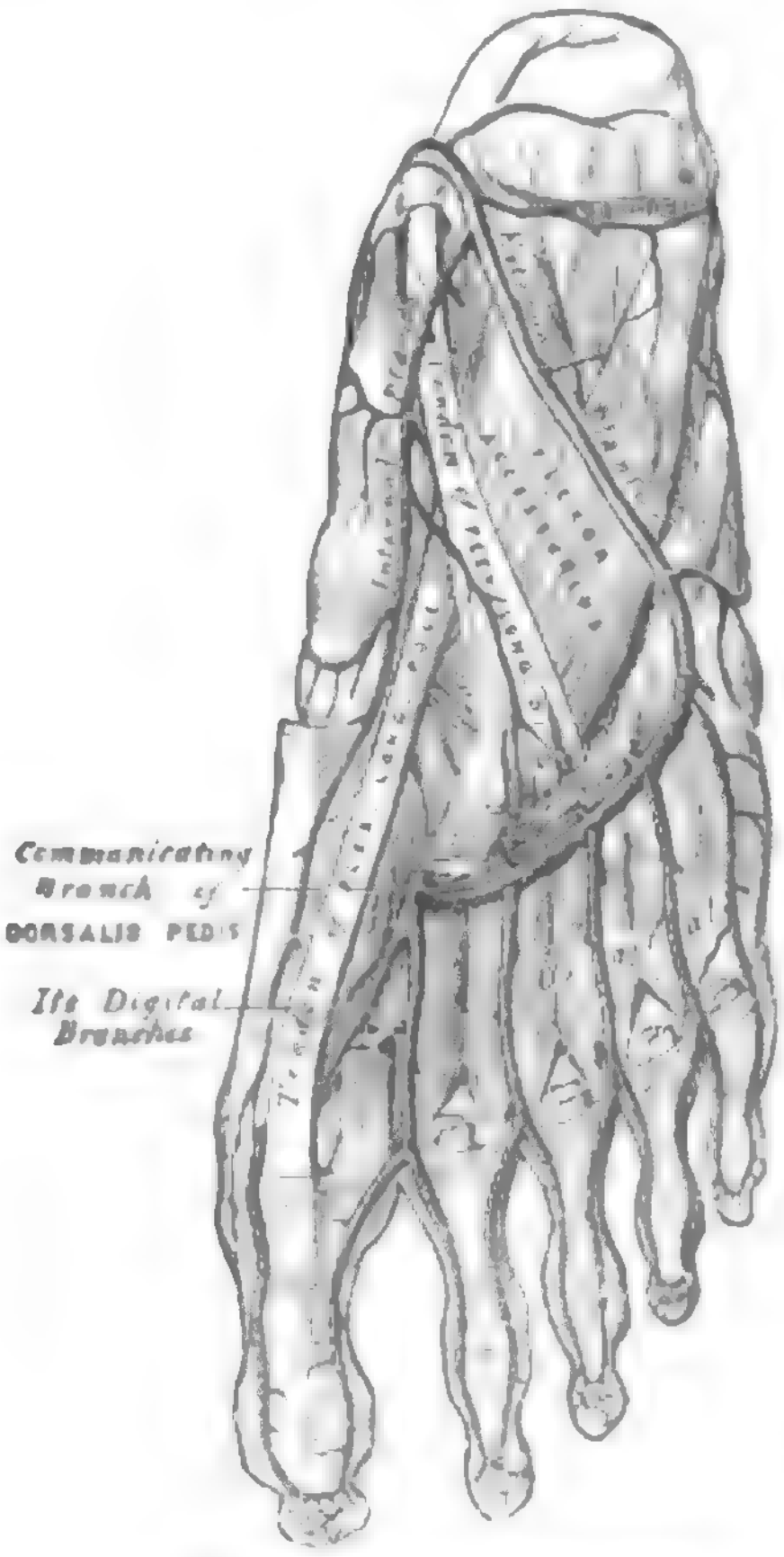

The Plantar Arteries, deep view.

The **internal calcanean** are several large arteries which arise from the posterior tibial just before its division; they are distributed to the fat and integument behind the tendo Achillis and about the heel, and to the muscles on the inner side of the sole, anastomosing with the peroneal and internal malleolar arteries.

The **Internal Plantar Artery** (Figs. 408, 409, p. 609), much smaller than the external, passes forward along the inner side of the foot. It is at first situated above[1] the Abductor pollicis, and then between it and the Flexor brevis digitorum, both of which it supplies. At the base of the first metatarsal bone, where it has become much diminished in size, it passes along the inner border of the great toe, inosculating with its digital branch.

The **External Plantar Artery**, much larger than the internal, passes obliquely outward and forward to the base of the fifth metatarsal bone. It then turns obliquely inward to the interval between the bases of the first and second metatarsal bones, where it anastomoses with the communicating branch from the dorsalis pedis artery, thus completing the *plantar arch.* As this artery passes outward, it is first placed between the os calcis and Abductor pollicis, and then between the Flexor brevis digitorum and Flexor accessorius; and as it passes forward to the base of the little toe, it lies more superficially between the Flexor brevis digitorum and Abductor minimi digiti, covered by the deep fascia and integument. The remaining portion of the vessel is deeply situated; it extends from the base of the metatarsal bone of the little toe to the back part of the first interosseous space, and forms the plantar arch; it is convex forward, lies upon the Interossei muscles opposite the tarsal ends of the metatarsal bones, and is covered by the Adductor pollicis, the Flexor tendons of the toes, and the Lumbricales.

Branches.—The plantar arch, besides distributing numerous branches to the muscles, integument, and fasciæ in the sole, gives off the following branches:

Posterior Perforating.	Digital—Anterior Perforating.

The **posterior perforating** are three small branches which ascend through the back part of the three outer interosseous spaces, between the heads of the Dorsal interossei muscles, and anastomose with the interosseous branches from the metatarsal artery.

The **digital branches** are four in number, and supply the three outer toes and half the second toe. The *first* passes outward from the outer side of the plantar arch, and is distributed to the outer side of the little toe, passing in its course beneath the Abductor and short Flexor muscles. The *second*, *third*, and *fourth* run forward along the interosseous spaces, and on arriving at the clefts between the toes divide into collateral branches which supply the adjacent sides of the three outer toes and the outer side of the second. At the bifurcation of the toes each digital artery sends upward, through the fore part of the corresponding metatarsal space, a small branch which inosculates with the interosseous branches of the metatarsal artery. These are the anterior perforating branches.

From the arrangement already described of the distribution of the vessels to the toes, it will be seen that both sides of the three outer toes and the outer side of the second toe are supplied by branches from the plantar arch, both sides of the great toe and the inner side of the second being supplied by the communicating branch of the dorsalis pedis.

---

[1] This refers to the erect position of the body. In the ordinary [position for] dissection the artery is deeper than the muscle.

Of the Veins.

THE **Veins** are the vessels which serve to return the blood from the capillaries of the different parts of the body to the heart. They consist of two distinct sets of vessels, the *pulmonary* and *systemic*.

Pulmonary Veins, unlike other vessels of this kind, contain arterial blood, which they return from the lungs to the left auricle of the heart.

The **Systemic Veins** return the venous blood from the body generally to the right auricle of the heart.

The **Portal Vein**, an appendage to the systemic venous system, is confined to the abdominal cavity, returning the venous blood from the viscera of digestion, and carrying it to the liver by a single trunk of large size, the *vena portæ*. This vessel ramifies in the substance of the liver and breaks up into a minute network of capillaries. These capillaries then reunite to form the hepatic veins, by which the blood is conveyed to the inferior vena cava.

The veins, like the arteries, are found in nearly every tissue of the body. They commence by minute plexuses which receive the blood from the capillaries. The branches which have their commencement in these plexuses unite together into trunks, and these in their passage toward the heart constantly increase in size as they receive tributaries and join other veins similar in size to themselves. The veins are larger and altogether more numerous than the arteries; hence the entire capacity of the venous system is much greater than that of the arterial, the pulmonary veins excepted, which do not exceed in capacity the pulmonary arteries. From the combined area of the smaller venous branches being greater than the main trunks, it results that the venous system represents a cone, the summit of which corresponds to the heart, its base to the circumference of the body. In form, the veins are not perfectly cylindrical like the arteries, their walls being collapsed when empty, and the uniformity of their surface being interrupted at intervals by slight contractions, which indicate the existence of valves in their interior. They usually retain, however, the same calibre as long as they receive no branches.

The veins communicate very freely with one another, especially in certain regions of the body; and this communication exists between the larger trunks as well as between the smaller branches. Thus in the cavity of the cranium and between the veins of the neck, where obstruction would be attended with imminent danger to the cerebral venous system, we find that the sinuses and larger veins have large and very frequent anastomoses. The same free communication exists between the veins throughout the whole extent of the spinal canal, and between the veins composing the various venous plexuses in the abdomen and pelvis, as the spermatic, uterine, vesical, prostatic, etc.

The [systemic] veins are subdivided into three sets—superficial veins, deep veins, and sinuses.

The **Superficial** or **Subcutaneous Veins** are found between the layers of the superficial fascia, immediately beneath the integument; they return the blood from these structures and communicate with the deep veins by perforating the deep fascia.

The **Deep Veins** accompany the arteries, and are usually enclosed in the same sheath with those vessels. In the smaller arteries, as the radial, ulnar, brachial, tibial, peroneal, they exist generally in pairs, one lying on each side of the vessel, and are called *venæ comites* [*i. e.* companion veins]. The larger arteries, as the axillary, subclavian, popliteal, and femoral, have usually only one accompanying

The **Choroid Vein** runs along the whole length of the outer border of the choroid plexus, receiving veins from the hippocampus major, the fornix, and corpus callosum, and unites at the anterior extremity of the choroid plexus with the vein of the corpus striatum.

The **Cerebellar Veins** occupy the surface of the cerebellum, and are disposed in three sets—superior, inferior, and lateral. The *superior* pass forward and inward across the superior vermiform process, and terminate in the straight sinus; some open into the venæ Galeni. The *inferior* cerebellar veins, of large size, run transversely outward, and terminate by two or three trunks in the lateral sinuses. The *lateral anterior* cerebellar veins terminate in the superior petrosal sinuses.

SINUSES OF THE DURA MATER [Figs. 412, 414].

The sinuses of the dura mater are venous channels analogous to the veins, their outer coat being formed by the dura mater; their inner, by a continuation of the lining membrane of the veins. They are fifteen in number, and are divided into two sets: 1, those situated at the upper and back part of the skull; 2, those at the base of the skull. The former are the

FIG. 412.

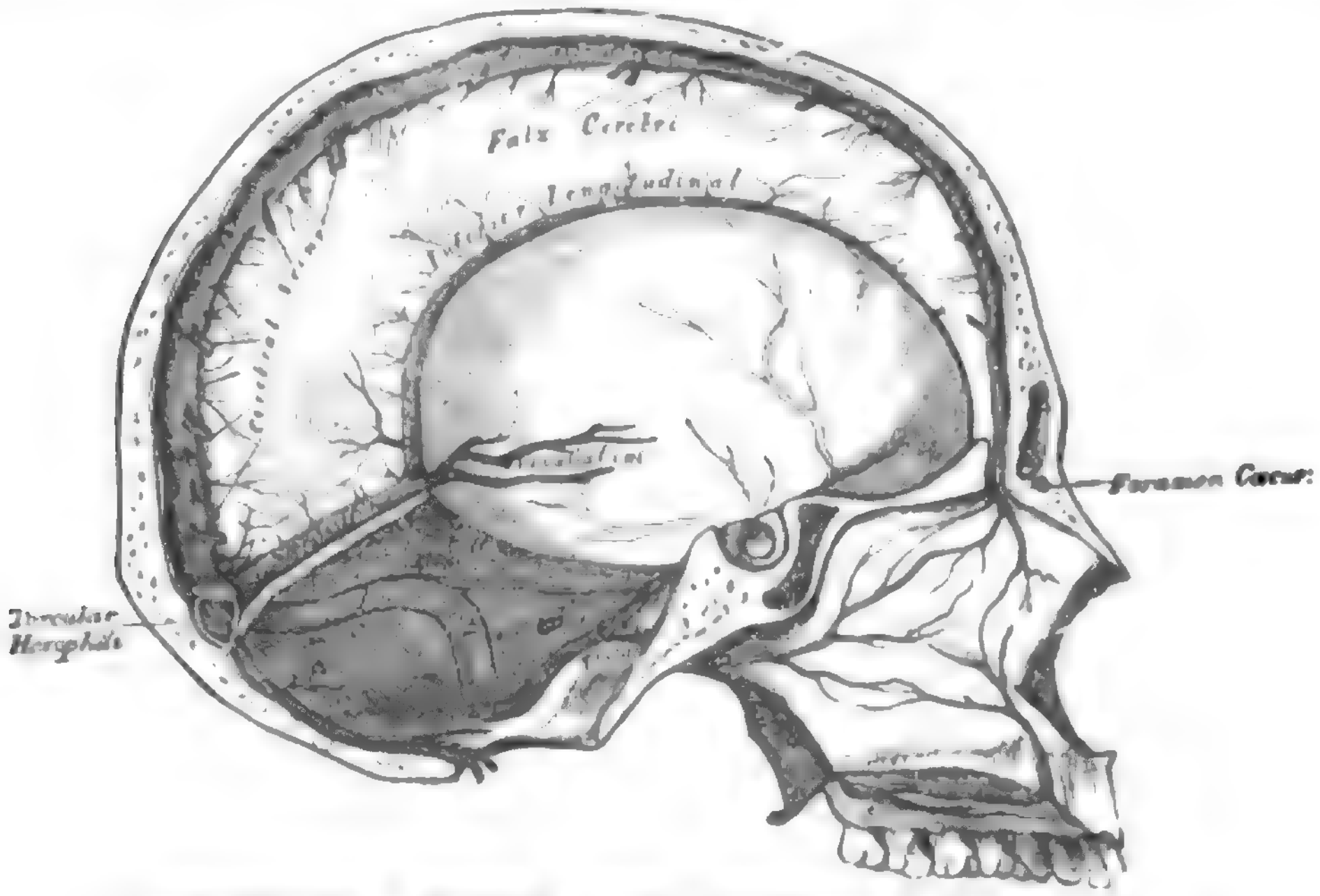

Vertical Section of the Skull, showing the Sinuses of the Dura Mater.

Superior Longitudinal.
Inferior Longitudinal.
Straight Sinus.
Lateral Sinuses.
Occipital Sinus.

The **Superior Longitudinal Sinus** occupies the attached margin of the falx cerebri. Commencing at the foramen cæcum, through which it constantly communicates by a small branch with the veins of the nasal fossæ, it runs from before backward, grooving the inner surface of the frontal, the adjacent margins of the two parietal, and the superior division of the crucial ridge of the occipital bone, and terminates by opening into the torcular Herophili. The sinus is triangular in form, narrow in front, and gradually increasing in size as it passes backward. On examining its inner surface it presents the internal openings of the cerebral veins, which run, for the most part, from behind forward, and open chiefly at the back part of the sinus, their orifices being concealed by fibrous folds; numerous fibrous bands (*chordæ Willisii*) are also seen, which extend transversely across the inferior angle of the sinus; and lastly, some small, white, projecting bodies, the *glandulæ Pacchioni.* This sinus receives the superior cerebral veins, numerous veins from the diploë and dura mater, and at the posterior extremity of the sagittal suture veins from the pericranium, which pass through the parietal foramen.

The *torcular Herophili* is the dilated extremity of the superior longitudinal sinus. It is of irregular form, and is lodged on one side (generally the right) of the internal occipital protuberance. From it the lateral sinus of the side to which it is deflected is derived. It receives also the blood from the occipital sinus.

The **Inferior Longitudinal Sinus**, more correctly described as the *inferior longitudinal vein*, is contained in the posterior part of the free margin of the falx cerebri. It is of a cylindrical form, increases in size as it passes backward, and terminates in the straight sinus. It receives several veins from the falx cerebri, and occasionally a few from the mesial surface of the hemispheres.

The **Straight Sinus [Sinus rectus]** is situated at the line of junction of the falx cerebri with the tentorium. It is triangular in form, increases in size as it proceeds backward, and runs obliquely downward and backward from the termination of the inferior longitudinal sinus to the lateral sinus of the opposite side to that into which the superior longitudinal sinus is prolonged. It communicates by a considerable opening with the torcular Herophili. Besides the inferior longitudinal sinus it receives the venæ Galeni and the superior cerebellar. A few transverse bands cross its interior.

The **Lateral Sinuses** are of large size, and are situated in the attached margin of the tentorium cerebelli. They commence at the internal occipital protuberance, the one, generally the right, being the direct continuation of the superior longitudinal sinus, the other of the straight sinus. They pass horizontally outward to the base of the petrous portion of the temporal bone; then curve downward and inward on each side to reach the jugular foramen, where they terminate in the internal jugular vein. Each sinus rests in its course upon the inner surface of the occipital, the posterior inferior angle of the parietal, the mastoid portion of the temporal, and on the occipital again just before its termination. These sinuses are frequently of unequal size, that formed by the superior longitudinal sinus being the larger, and they increase in size as they proceed from behind forward. The horizontal portion is of a triangular form, the curved portion semi-cylindrical; their inner surface is smooth, and not crossed by the fibrous bands found in the other sinuses. These sinuses receive the blood from the superior petrosal sinuses at the base of the petrous portion of the temporal bone, and they unite with the inferior petrosal sinus, just external to the jugular foramen, to form the internal jugular vein (Fig. 415). They communicate with the veins of the pericranium by means of the mastoid and posterior condyloid veins, and they receive some of the inferior cerebral and inferior cerebellar veins, and some veins from the diploë.

The **Occipital** is the smallest of the cranial sinuses. It is generally single, but occasionally there are two. It is situated in the attached margin of the falx cerebelli. It commences by several small veins around the margin of the foramen magnum, one of which joins the termination of the lateral sinus; it communicates with the posterior spinal veins, and terminates in the torcular Herophili.[1]

The sinuses at the base of the skull are the

Cavernous.	Inferior Petrosal.
Circular.	Superior Petrosal.
Transverse.	

---

[1] I am indebted to Mr. Ross, demonstrator of anatomy at St. George's Hospital, for the following note on the torcular Herophili and the sinuses converging to it. He examined them in ten subjects, and reports as follows:

1. In all there was a free communication between the opposite lateral sinuses.
2. The superior longitudinal sinus terminated in seven cases in the right lateral sinus; in two in the left lateral sinus; and in one case it divided, the right portion being much the larger.
3. The straight sinus terminated in four cases in the middle line—*i. e.* over the internal occipital protuberance: in three cases it divided, part going to the right and part to the left lateral sinus; in two cases it terminated in the left lateral sinus, and in one case in the right lateral sinus.
4. The occipital sinus terminated in nine cases in the middle line; in these cases it was most frequently single.
5. That lateral sinus in which the superior longitudinal sinus terminated was usually the larger of the two—in one or two cases twice the size of the other.

The **Cavernous Sinuses** are named from their presenting a reticulated structure. They are two in number, of large size, and placed one on each side of the sella Turcica, extending from the sphenoidal fissure to the apex of the petrous portion of the temporal bone; they receive anteriorly the ophthalmic vein through the sphenoidal fissure, and communicate behind with the petrosal sinuses and with each other by the circular and transverse sinuses. On the inner wall of each sinus is found the internal carotid artery, accompanied by filaments of the carotid plexus and by the sixth nerve; and on its outer wall, the third, fourth, and ophthalmic nerves. These parts are separated from the blood flowing along the sinus by the lining membrane, which is continuous with the inner coat of the veins. The cavity of the sinus, which is larger behind than in front, is intersected by filaments of fibrous tissue and small vessels. The cavernous sinuses receive some of the cerebral veins; they communicate with the lateral sinuses by means of the superior and inferior petrosal, and with the facial vein through the ophthalmic. They also communicate with each other by means of the circular sinus.

Fig. 413.

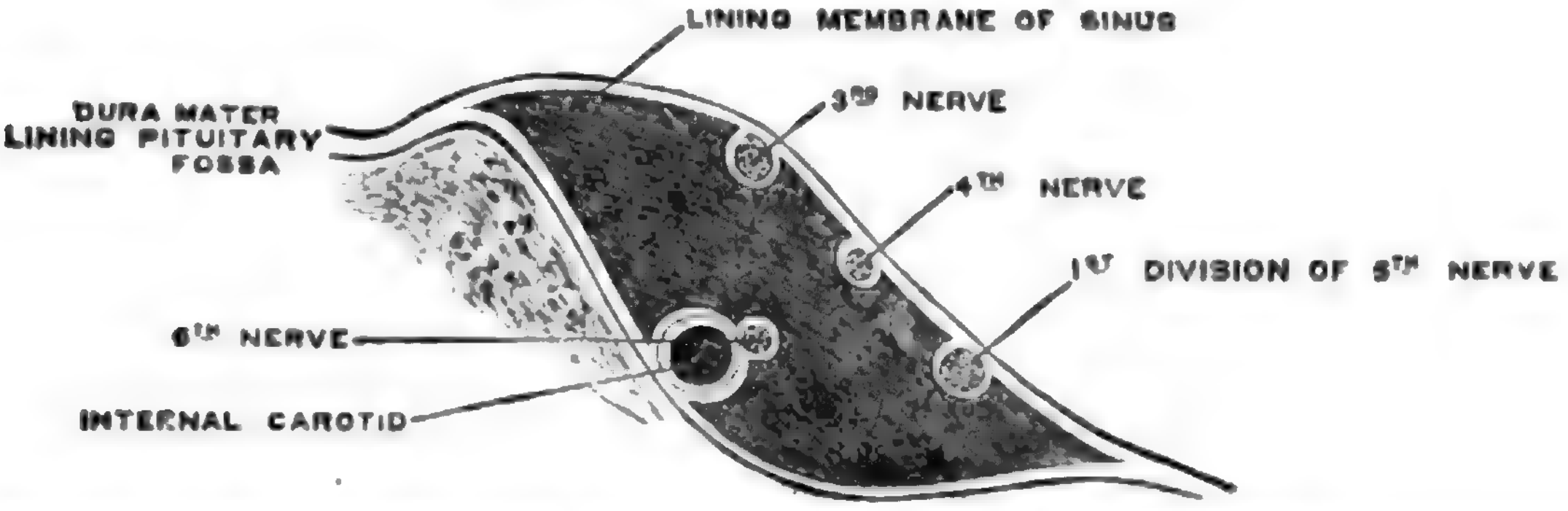
LINING MEMBRANE OF SINUS
DURA MATER LINING PITUITARY FOSSA
3RD NERVE
4TH NERVE
1ST DIVISION OF 5TH NERVE
6TH NERVE
INTERNAL CAROTID

Plan showing the Relative Position of the Structures in the Right Cavernous Sinus, viewed from behind.

The **Ophthalmic** is a large vein which connects the angular vein at the inner angle of the orbit with the cavernous sinus; it pursues the same course as the ophthalmic artery, and receives tributaries corresponding to the branches derived from that vessel. Forming a short single trunk, it passes through the inner extremity of the sphenoidal fissure and terminates in the cavernous sinus. Sometimes the veins from the floor of the orbit collect into a separate trunk, the *inferior ophthalmic vein*, which either passes out of the orbit through the spheno-maxillary fissure to join the pterygoid plexus, or else, passing backward through the sphenoidal fissure, it enters the cavernous sinus, either by a separate opening or in common with the ophthalmic vein.

Fig. 414.

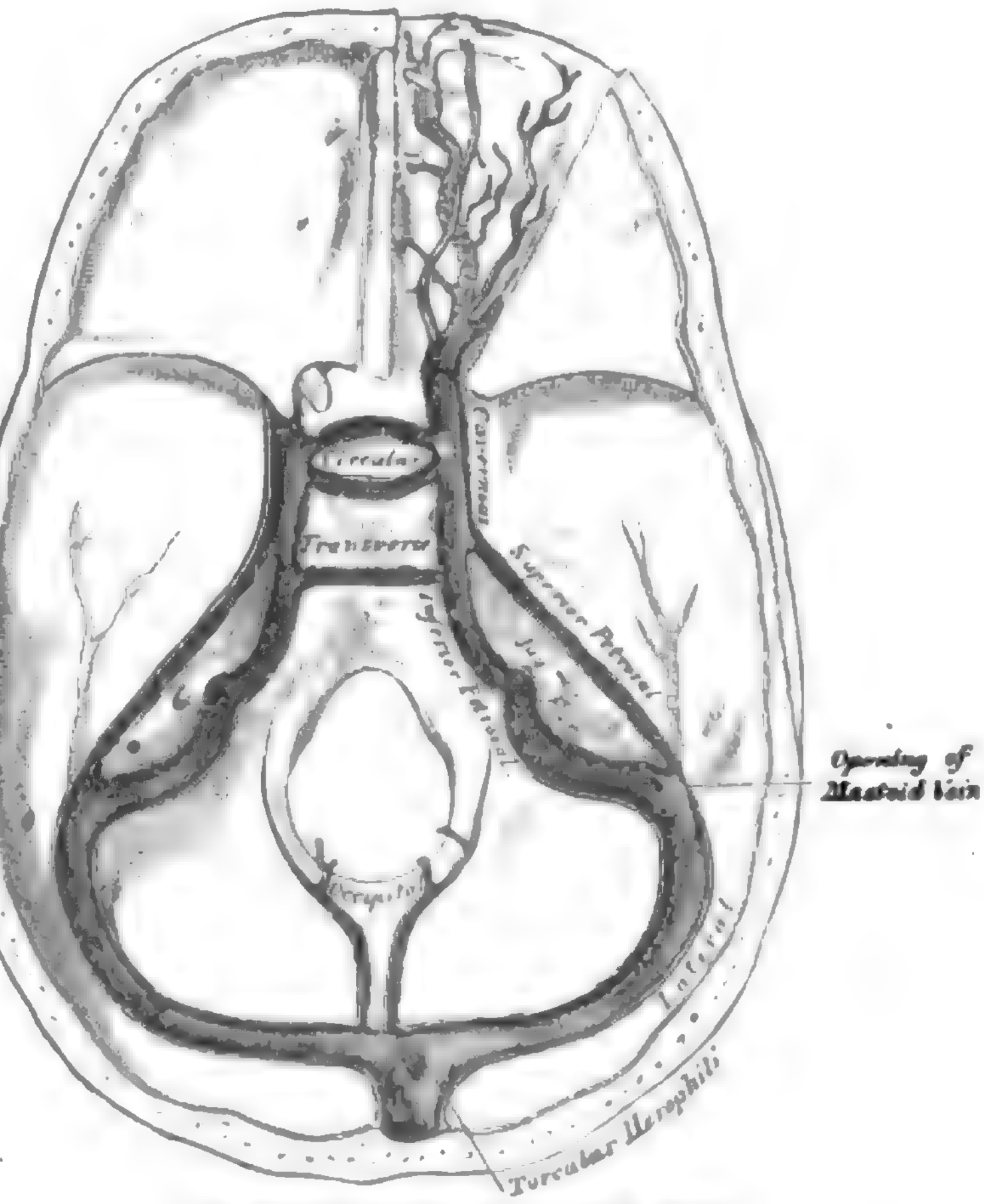
Circular
Transverse
Cavernous
Superior Petrosal
Inferior Petrosal
Jug. F.
Opening of Mastoid Vein
Occipital
Lateral
Torcular Herophili

The Sinuses at the Base of the Skull.

The **Circular Sinus** is formed by two transverse vessels which connect together the two cavernous sinuses, the one passing in front and the other behind the pituitary body, and thus forming with the cavernous sinuses a venous circle around the body. The anterior one is usually the larger of the two, and one or other is occasionally found to be absent.

The **Inferior Petrosal Sinus** is situated in the groove formed by the junction of the posterior border of the petrous portion of the temporal with the basilar process of the occipital. It commences in front at the termination of the cavernous sinus, and behind joins the lateral sinus external to the jugular foramen, forming the internal jugular vein.

The junction of the two sinuses takes place at the lower border of, or just external to, the jugular foramen. The exact relation of the parts to one another in the foramen is as follows: The inferior petrosal sinus is in front, and is directed obliquely downward and backward; the lateral sinus is situated at the back part of the foramen, and between the two are the glosso-pharyngeal, pneumogastric, and spinal accessory nerves. The junction of the sinuses takes place superficial to the nerves, so that these latter lie a little internal to the venous channels in the foramen. (See Fig. 415.) These sinuses are semi-cylindrical in form.

FIG. 415.

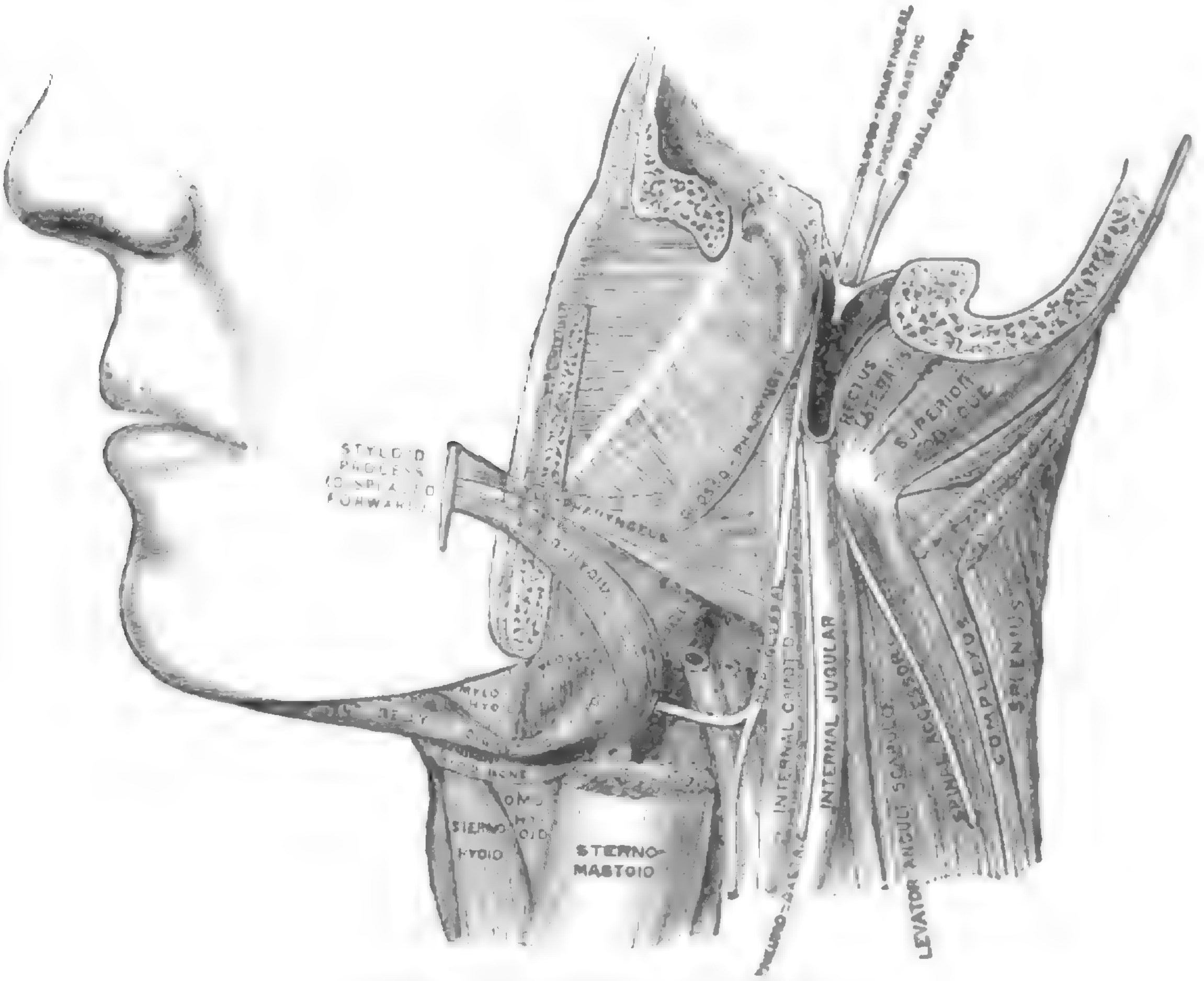
GLOSSO-PHARYNGEAL
PNEUMO-GASTRIC
SPINAL ACCESSORY
RECTUS LATERALIS
SUPERIOR OBLIQUE
STYLOID PROCESS (DISPLACED FORWARD)
STYLO-PHARYNGEUS
GLOSSO-PHARYNGEAL
STYLO-HYOID
HYPOGLOSSAL
INTERNAL CAROTID
INTERNAL JUGULAR
PNEUMO-GASTRIC
LEVATOR ANGULI SCAPULÆ
SPINAL ACCESSORY
COMPLEXUS
SPLENIUS
STYLO-HYOID
STERNO-HYOID
OMO-HYOID
STERNO-MASTOID

Relation of Structures in Jugular Foramen.

The **Transverse Sinus** or **Basilar Sinus** consists of several interlacing veins between the layers of the dura mater over the basilar process of the occipital bone, which serve to connect the two inferior petrosal and cavernous sinuses. With them the anterior spinal veins communicate.

The **Superior Petrosal Sinus** is situated along the superior border of the petrous portion of the temporal bone in the front part of the attached margin of the tentorium. It is small and narrow, and connects together the cavernous and lateral sinuses at each side. It receives a cerebellar vein (*anterior lateral cerebellar*) from the anterior border of the cerebellum, a vein from the internal ear, and sometimes a cerebral vein (great anastomotic vein of Trolard) from the under part of the middle lobe.

VEINS OF THE UPPER EXTREMITY.

The veins of the upper extremity are divided into two sets, *superficial* and *deep*.

The **Superficial Veins** are placed immediately beneath the integument between the two layers of superficial fascia; they commence in the hand chiefly on its dorsal aspect, where they form a more or less complete arch.

The **Deep Veins** accompany the arteries, and constitute the venæ comites of those vessels.

Both sets of vessels are provided with valves, which are more numerous in the deep than in the superficial.

The superficial veins of the upper extremity are the

Anterior Ulnar.
Posterior Ulnar.
Common Ulnar.
Radial.
Median.
Median Basilic.
Median Cephalic.
Basilic.
Cephalic.

The **Anterior Ulnar Vein** commences on the anterior surface of the ulnar side of the hand and wrist, and ascends along the inner side of the forearm to the bend of the elbow, where it joins with the posterior ulnar vein to form the common ulnar. Occasionally it opens separately into the median basilic vein. It communicates with branches of the median vein in front and with the posterior ulnar behind.

The **Posterior Ulnar Vein** commences on the posterior surface of the ulnar side of the hand and from the vein of the little finger (*vena salvatella*) situated over the fourth metacarpal space. It runs on the posterior surface of the ulnar side of the forearm, and just below the elbow unites with the anterior ulnar vein to form the common ulnar, or else joins the median basilic to form the basilic. It communicates with the deep veins of the palm by a branch which emerges from beneath the Abductor minimi digiti muscle.

The **Common Ulnar** is a short trunk which is not constant. When it exists it is formed by the junction of the two preceding veins, and, passing upward and outward, joins the median basilic to form the basilic vein. When it does not exist the anterior and posterior ulnar veins open separately into the median basilic vein.

The **Radial Vein** commences from the dorsal surface of the thumb, index finger, and radial side of the hand by tributaries communicating with the vena salvatella, and with the deep veins of the palm by a branch

FIG. 416.

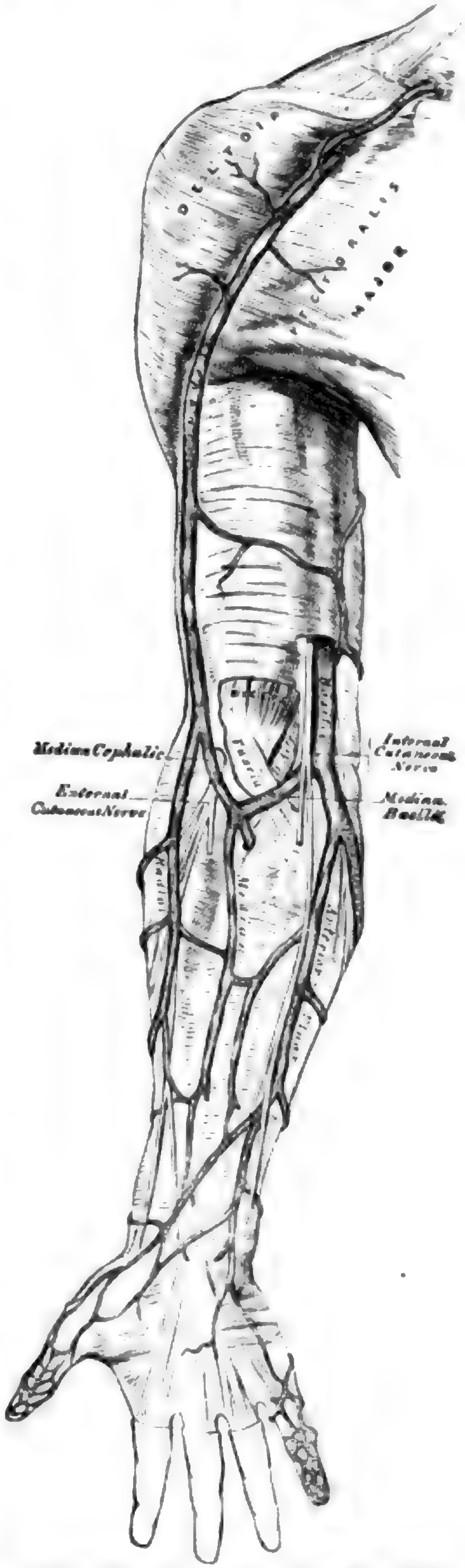

The Superficial Veins of the Upper Extremity.

which passes through the first interosseous space. It forms by the union of these tributaries a large vessel which ascends along the radial side of the forearm and receives numerous veins from both its surfaces. At the bend of the elbow it unites with the median cephalic to form the cephalic vein.

The **Median Vein** collects the blood from the superficial structures on the palmar surface of the hand and middle line of the forearm, communicating with the anterior ulnar and radial veins. At the bend of the elbow it receives a branch of communication from the deep veins accompanying the brachial artery, and divides into two branches, the median cephalic and median basilic, which diverge from each other as they ascend.

The **Median Cephalic,** usually the smaller of the two, passes outward in the groove between the Supinator longus and Biceps muscles, and joins with the radial to form the cephalic vein. The branches of the external cutaneous nerve pass beneath this vessel.

The **Median Basilic Vein** passes obliquely inward, in the groove between the Biceps and Pronator radii teres, and joins the common ulnar to form the basilic. This vein passes in front of the brachial artery, from which it is separated by a fibrous expansion (*the bicipital fascia*) which is given off from the tendon of the Biceps to the fascia covering the Flexor muscles of the forearm. Filaments of the internal cutaneous nerve pass in front as well as behind this vessel.[1]

The **Basilic** is a vein of considerable size formed by the coalescence of the common ulnar vein with the median basilic. It passes upward along the inner side of the Biceps muscle, pierces the deep fascia a little below the middle of the arm, and ascends in the course of the brachial artery, terminating by joining the venæ comites of that vessel to form the axillary vein.

The **Cephalic Vein** courses along the outer border of the Biceps muscle to the upper third of the arm; it then passes in the interval between the Pectoralis major and Deltoid muscles, accompanied by the descending branch of the acromial thoracic artery and the upper external cutaneous branch of the musculo-spiral nerve, pierces the costo-coracoid membrane, and terminates in the axillary vein just below the clavicle. This vein is occasionally connected with the external jugular or subclavian by a branch which passes from it upward in front of the clavicle. [In the living model the subcutaneous thoracic veins emptying into the cephalic in the interspace between the Deltoid and the Pectoralis major make it look as if the cephalic terminated over the Pectoral muscle. Its main trunk, however, is lost on the surface when it becomes deeper, and hence the deceptive appearance.]

The **Deep Veins of the Upper Extremity** follow the course of the arteries, forming their venæ comites. They are generally two in number, one lying on each side of the corresponding artery, and they are connected at intervals by short transverse branches.

There are two digital veins accompanying each artery along the sides of the fingers: these, uniting at their base, pass along the interosseous spaces in the palm, and terminate in the two venæ comites, which accompany the superficial palmar arch. Branches from these vessels on the radial side of the hand accompany the superficialis volæ, and on the ulnar side terminate in the deep ulnar veins. The deep ulnar veins, as they pass in front of the wrist, communicate with the interosseous and superficial veins, and at the elbow unite with the deep radial veins to form the venæ comites of the brachial artery.

The **Interosseous Veins** accompany the anterior and posterior interosseous arteries. The anterior interosseous veins commence in front of the wrist, where they communicate with the deep radial and ulnar veins; at the upper part of the forearm they receive the posterior interosseous veins, and terminate in the venæ comites of the ulnar artery.

---

[1] Cruveilhier says: "Numerous varieties are observed in the disposition of the veins of the elbow: sometimes the common median vein is wanting, but in those cases its two branches of bifurcation are furnished by the radial vein, and the cephalic is almost always in a rudimentary condition. In other cases only two veins are found at the bend of the elbow, the radial and ulnar, which are continuous, without any demarcation, with the cephalic and basilic."

The **Deep Palmar Veins** accompany the deep palmar arch, being formed by tributaries which accompany the ramifications of that vessel. They communicate with the deep ulnar veins at the inner side of the hand, and on the outer side terminate in the venæ comites of the radial artery. At the wrist they receive a dorsal and a palmar tributary from the thumb, and unite with the deep radial veins. Accompanying the radial artery these vessels terminate in the venæ comites of the brachial artery.

The **Brachial Veins** are placed one on each side of the brachial artery, receiving tributaries corresponding with the branches given off from that vessel; at the lower margin of the axilla they unite with the basilic to form the axillary vein.

The deep veins have numerous anastomoses, not only with each other, but also with the superficial veins.

The **Axillary Vein** is of large size, and formed by the junction of the venæ comites of the brachial artery with the basilic vein. It commences at the lower part of the axillary space, increases in size as it ascends by receiving tributaries corresponding with the branches of the axillary artery, and terminates immediately beneath the clavicle at the outer margin of the first rib, where it becomes the subclavian vein. This vessel is covered in front by the Pectoral muscles and costo-coracoid membrane, and lies on the thoracic side of the axillary artery. Near its termination it receives the cephalic vein. This vein is provided with a pair of valves opposite the lower border of the Subscapularis muscle; valves are also found at the termination of the cephalic and subscapular veins.

The **Subclavian Vein,** the continuation of the axillary, extends from the outer margin of the first rib to the inner end of the sterno-clavicular articulation, where it unites with the internal jugular to form the innominate vein. It is in relation in front with the clavicle and Subclavius muscle; behind, with the subclavian artery, from which it is separated internally by the Scalenus anticus and phrenic nerve; below, it rests in a depression on the first rib and upon the pleura; above, it is covered by the cervical fascia and integument.

The subclavian vein occasionally rises in the neck to a level with the third part of the subclavian artery, and in two instances has been seen passing with this vessel behind the Scalenus anticus. This vessel is usually provided with valves about an inch from its termination in the innominate, just external to the entrance of the external jugular vein.

TRIBUTARIES.—It receives the external and anterior jugular veins and a small branch from the cephalic outside the Scalenus, and on the inner side of that muscle the internal jugular vein.

The **Innominate** or **Brachio-cephalic Veins** (Fig. 417) are two large trunks placed one on each side of the root of the neck, and formed by the union of the internal jugular and subclavian veins of the corresponding side. [It will be noticed that there are *two* innominate *veins*, but only *one* innominate *artery*.]

The **Right Innominate Vein** is a short vessel, an inch and a half in length, which commences at the inner end of the clavicle, and, passing almost vertically downward, joins with the left vena innominata just below the cartilage of the first rib, close to the right border of the sternum, to form the *superior vena cava.* It lies superficial and external to the arteria innominata; on its right side the pleura is interposed between it and the apex of the lung. This vein at the angle of junction of the internal jugular with the subclavian receives the right vertebral vein and right *lymphatic duct,* and lower down the right internal mammary, right inferior thyroid, and sometimes the right superior intercostal veins.

The **Left Innominate Vein,** about three inches in length and larger than the right, passes from left to right across the upper and front part of the chest, at the same time inclining downward to unite with its fellow of the opposite side, forming the *superior vena cava.* It is in relation in front with the first piece of the sternum, from which it is separated by the Sterno-thyroid muscles, the thymus gland or its remains, and some loose areolar tissue. Behind, it lies across the roots of the three large arteries arising from the arch of the aorta. This vessel is joined by the left vertebral, left inferior thyroid, left internal mammary, and the left superior intercostal veins, and occasionally some thymic and pericardiac veins. [The *thoracic duct* empties into the left innominate vein at the angle of junction of the internal jugular and subclavian veins.] There are no valves in the venæ innominatæ.

Peculiarities.—Sometimes the innominate veins open separately into the right auricle: in such cases the right vein takes the ordinary course of the superior vena cava, but the left vein, after communicating by a small branch with the right one, passes in front of the root of the left lung, and, turning to the back of the heart, receives the cardiac veins, and terminates in the back of the right auricle. This occasional condition of the veins in the adult is a regular one in the fœtus at an early period, and the two vessels are persistent in birds and some Mammalia. The subsequent changes which take place in these vessels are the following: The communicating branch between the two trunks enlarges and forms the future left innominate vein; the remaining part of the left trunk is obliterated as far as the heart, where it remains pervious and forms the coronary sinus: a remnant of the obliterated vessel is seen in adult life as a fibrous band passing along the back of the left auricle and in front of the root of the left lung, called by Mr. Marshall the *vestigial fold of the pericardium.*

The **Internal Mammary Veins,** two in number to each artery, follow the course of that vessel, and receive branches corresponding with those derived from it. The two veins on each side unite into a single trunk, which terminates in the innominate vein.

The **Inferior Thyroid Veins,** two (frequently three or four) in number, arise in the venous plexus on the thyroid body, communicating with the middle and superior thyroid veins. The left one descends in front of the trachea.

FIG. 417.

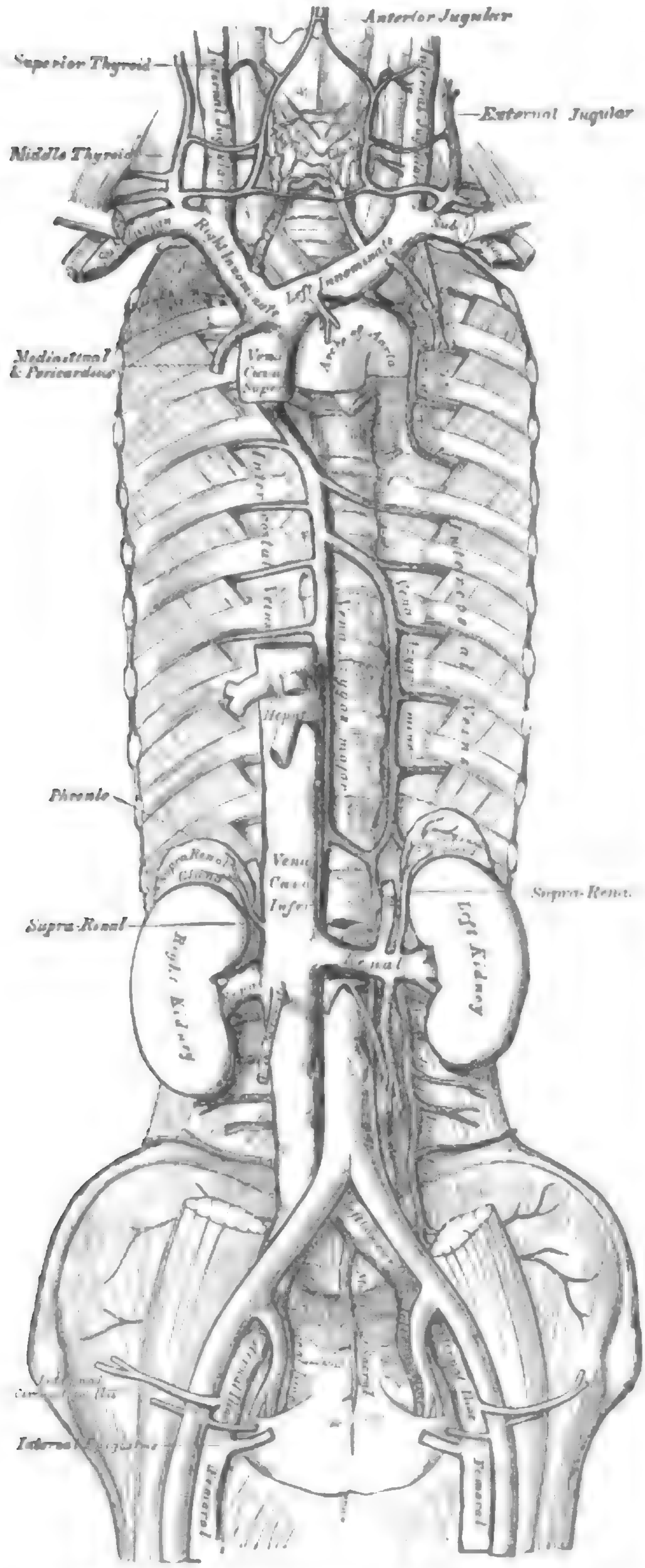
Anterior Jugular
Superior Thyroid
External Jugular
Middle Thyroid
Internal Jugular
Internal Jugular
Sub.
Right Innominate
Left Innominate
Arch of Aorta
Mediastinal & Pericardiac
Vena Cava Super
Intercostal Veins
Vena Azygos Major
Intercostal Veins
Hepat
Phrenic
Supra Renal Gland
Vena Cava Infer
Supra-Renal
Supra-Renal
Renal
Right Kidney
Left Kidney
Femoral
Femoral

The Venæ Cavæ and Azygos Veins, with their formative branches.

behind the Sterno-thyroid muscle, communicating with its fellow by tranverse branches, and terminates in the left vena innominata. The right one, which is placed a little to the right of the median line, opens into the right vena innominata just at its junction with the superior cava. These veins receive œsophageal, tracheal, and inferior laryngeal branches, and are provided with valves at their termination in the innominate veins.

The **Superior Intercostal Veins** return the blood from the upper intercostal spaces.

The *right superior intercostal*, much smaller than the left, closely corresponds with the superior intercostal artery, receiving the blood from the first or first and second intercostal spaces, and, passing downward, terminates in the vena azygos major. Occasionally it opens into the right innominate vein.

The *left superior intercostal* is always larger than the right, but varies in size in different subjects, being small when the left upper azygos vein is large, and *vice versâ*. It is usually formed by branches from the two or three upper intercostal spaces, and, passing across the arch of the aorta, terminates in the left vena innominata. The left bronchial vein and the left superior phrenic open into it.

The **Superior Vena Cava** receives the blood which is conveyed to the heart from the whole of the upper half of the body [and also the contents of the right lymphatic and the thoracic ducts]. It is a short trunk, varying from two inches and a half to three inches in length, formed by the junction of the two venæ innominatæ. It communicates immediately below the cartilage of the first rib close to the sternum on the right side, and, descending vertically, enters the pericardium about an inch and a half above the heart, and terminates in the upper part of the right auricle opposite the upper border of the third costal cartilage. At the angle of junction of the two innominate veins the right superior phrenic opens into the superior vena cava. In its course it describes a slight curve, the convexity of which is turned to the right side.

Relations.—*In front* with the pericardium and process of cervical fascia, which is continuous with it; this separates it from the thymus gland and from the sternum; *behind* with the root of the right lung; on its *right side* with the phrenic nerve and right pleura; on its *left side* with the commencement of the innominate artery and the ascending part of the aorta. The portion contained within the pericardium is covered by the serous layer of that membrane in its anterior three-fourths. It receives the vena azygos major just before it enters the pericardium, and several small veins from the pericardium and parts in the mediastinum. The superior vena cava has no valves.

The **Azygos Veins** connect together the superior and inferior venæ cavæ, supplying the place of those vessels in the part of the chest which is occupied by the heart.

The larger, or *right azygos vein* [*azygos major*], commences opposite the first or second lumbar vertebra by a branch from the right lumbar veins (*the ascending lumbar*), sometimes by a branch from the right renal vein or from the inferior vena cava. It enters the thorax through the aortic opening into the Diaphragm, and passes along the right side of the vertebral column to the fourth dorsal vertebra, where it arches forward over the root of the right lung, and terminates in the superior vena cava just before that vessel enters the pericardium. Whilst passing through the aortic opening of the Diaphragm it lies with the thoracic duct on the right side of the aorta; and in the thorax it lies upon the intercostal arteries, on the right side of the aorta and thoracic duct, in the posterior mediastinum.

Tributaries.—It receives nine or ten lower intercostal veins of the right side, the vena azygos minor, several œsophageal, mediastinal, and pericardial veins; near its termination the right bronchial vein; and is occasionally connected with the right superior intercostal vein. A few imperfect valves are found in this vein, but its tributaries are provided with complete valves.

The intercostal veins on the left side, below the two or three upper intercostal spaces, usually form two trunks, named the left lower and the left upper azygos veins.

The *left lower*, or *smaller azygos vein* [*azygos minor*], commences in the lumbar region by a branch from one of the lumbar veins (*ascending lumbar*) or from the left renal. It passes into the thorax through the left crus of the Diaphragm, and, ascending on the left side of the spine as high as the seventh or eighth dorsal vertebra, passes across the column, behind the aorta and thoracic duct, to terminate in the right azygos vein. It receives the four or five lower intercostal veins of the left side, and some œsophageal and mediastinal veins.

The *left upper azygos vein* varies according to the size of the left superior intercostal. It receives veins from the intercostal spaces between the left superior intercostal vein and highest tributary of the left lower azygos. They are usually two or three in number, and join to form a trunk which ends in the right azygos vein or in the left lower azygos. It sometimes receives the left bronchial vein. When this vein is small or altogether wanting, the left superior intercostal vein will extend as low as the fifth or sixth intercostal space.[1]

The *bronchial veins* return the blood from the substance of the lungs: that of the right side opens into the vena azygos major near its termination; that of the left side, into the left superior intercostal vein or left upper azygos vein.

THE SPINAL VEINS.

The numerous venous plexuses placed upon and within the spine may be arranged into four sets:

1. Those placed on the exterior of the spinal column (the *dorsi-spinal* veins).
2. Those situated in the interior of the spinal canal, between the vertebræ and the theca vertebralis (*meningo-rachidian* veins).
3. The veins of the bodies of the vertebræ (*venæ basis vertebrarum*).
4. The veins of the spinal cord (*medulli-spinal*).

1. **The Dorsi-spinal Veins** commence by small branches which receive their blood from the integument of the back of the spine and from the muscles in the vertebral grooves. They form a complicated network, which surrounds the spinous processes, the laminæ, and the transverse and articular processes of all the vertebræ. At the bases of the transverse processes they communicate, by means of ascending and descending branches, with the veins surrounding the contiguous vertebræ, and they join with the veins in the spinal canal by branches which perforate the ligamenta subflava. Other branches pass obliquely forward between the transverse processes, and communicate with the intraspinal veins through the intervertebral foramina. They terminate by joining the vertebral veins in the neck, the intercostal veins in the thorax, and the lumbar and sacral veins in the loins and pelvis.

FIG. 418.

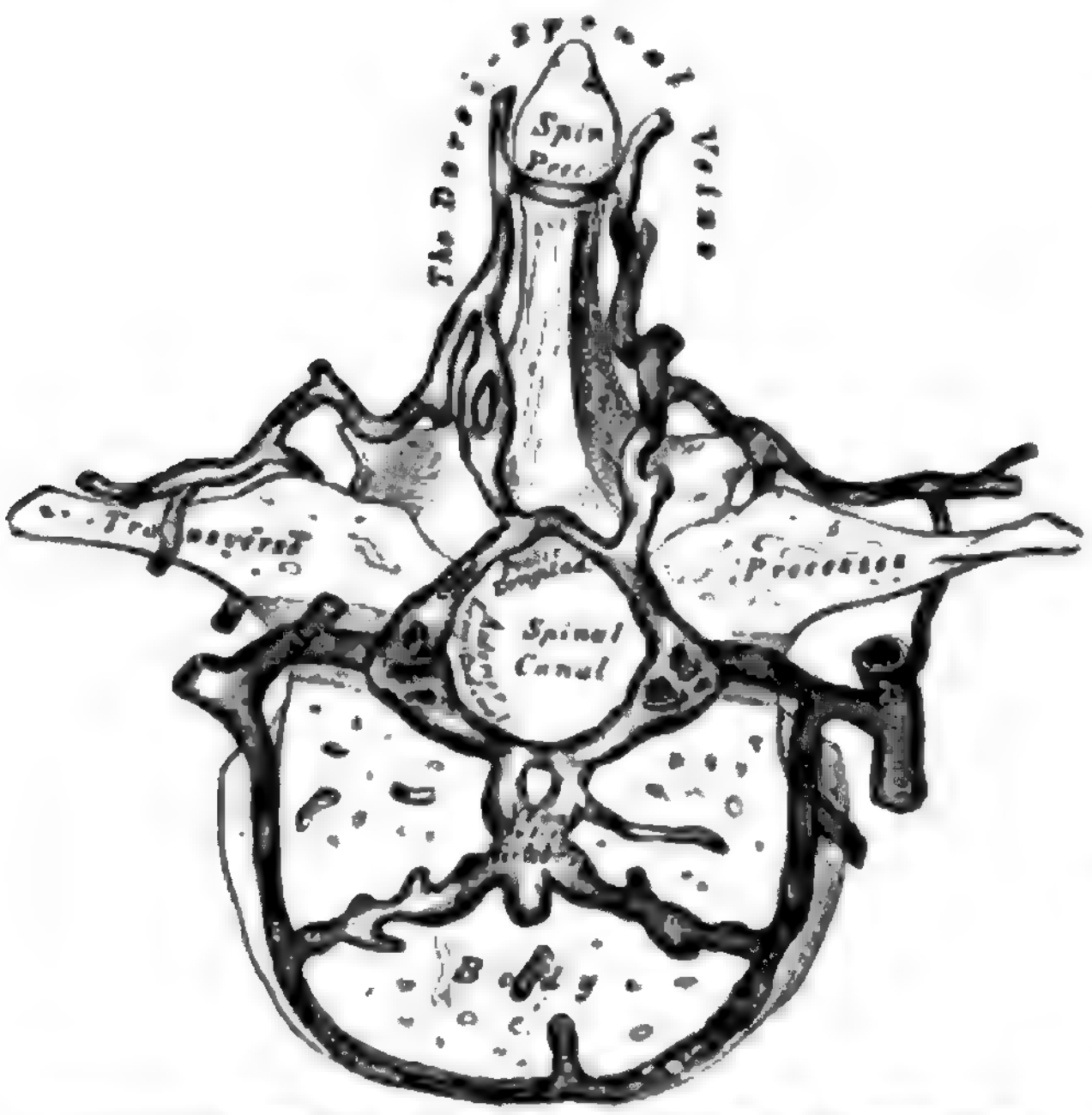

Transverse Section of a Dorsal Vertebra, showing the Spinal Veins.

2. **The Meningo-rachidian Veins.**—The principal veins contained in the spinal

---

[1] For an account of the arrangement of the azygos and superior intercostal veins in a number of consecutive cases from the same dissecting-room, see a paper by Mr. B. G. Morison, *Journ. of Anat. and Phys.*, vol. xiii. p. 346. The most important difference between his description and that in the text is that he always found two superior intercostal veins on both sides, the vein from the first space being separate and joining the corresponding innominate vein. The lower (and larger) superior intercostal vein he describes as opening into the azygos on the right and innominate on the left side.

canal are situated between the theca vertebralis and the vertebræ. They consist of two longitudinal plexuses, one of which runs along the posterior surface of the bodies of the vertebræ throughout the entire length of the spinal canal (*anterior longitudinal spinal veins*), receiving the veins belonging to the bodies of the vertebræ (*venæ basis vertebrarum*). The other plexus (*posterior longitudinal spinal veins*) is placed on the inner or anterior surface of the laminæ of the vertebræ, and extends also along the entire length of the spinal canal.

Fig. 419.

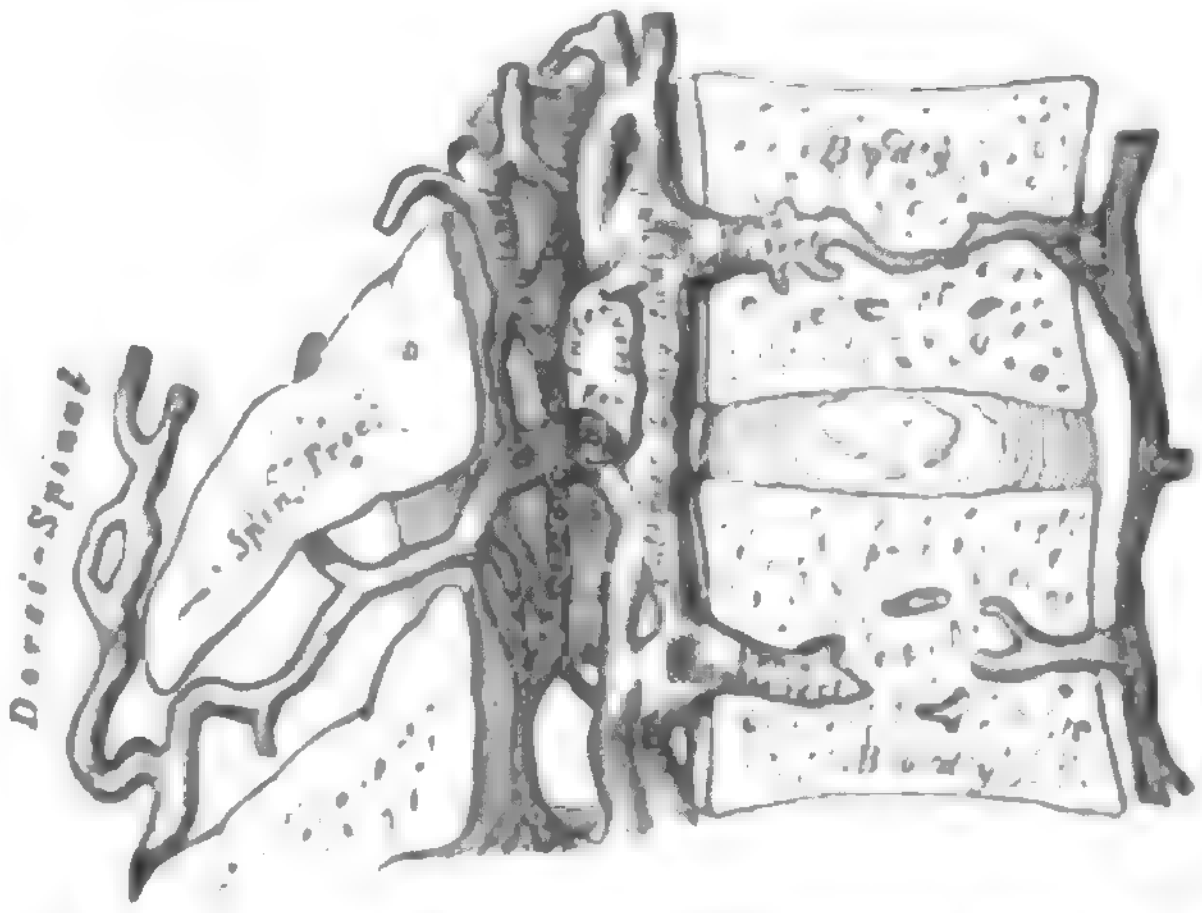

Vertical Section of Two Dorsal Vertebræ, showing the Spinal Veins.

The ***Anterior Longitudinal Spinal Veins*** consist of two large, tortuous, venous canals which extend along the whole length of the vertebral column from the foramen magnum, where they communicate by a venous ring around that opening, to the base of the coccyx, being placed one on each side of the posterior surface of the bodies of the vertebræ, along the margin of the posterior common ligament. These veins communicate together opposite each vertebra by transverse trunks which pass beneath the ligament and receive the large venæ basis vertebrarum from the interior of the body of each vertebra. The anterior longitudinal spinal veins are least developed in the cervical and sacral regions. They are not of uniform size throughout, being alternately enlarged and constricted. At the intervertebral foramina they communicate with the dorsi-spinal veins and with the vertebral veins in the neck, with the intercostal veins in the dorsal region, and with the lumbar and sacral veins in the corresponding regions.

The ***Posterior Longitudinal Spinal Veins***, smaller than the anterior, are situated one on either side, between the inner surface of the laminæ and the theca vertebralis. They communicate (like the anterior) opposite each vertebra by transverse trunks, and with the anterior longitudinal veins by lateral transverse branches which pass from behind forward. These veins, by branches which perforate the ligamenta subflava, join with the dorsi-spinal veins. From them branches are given off which pass through the intervertebral foramina and join the vertebral, intercostal, lumbar, and sacral veins.

3. The **Veins of the Bodies of the Vertebræ** (*venæ basis vertebrarum*) emerge from the foramina on their posterior surface, and join the transverse trunk connecting the anterior longitudinal spinal veins. They are contained in large tortuous channels in the substance of the bones, similar in every respect to those found in the diploë of the cranial bones. These canals lie parallel to the upper and lower surface of the bones. They commence by small openings on the front and sides of the bodies of the vertebræ, through which communicating branches from the veins external to the bone pass into its substance, and converge to the principal canal, which is sometimes double toward its posterior part, and open into the corresponding transverse branch uniting the anterior longitudinal veins. They become greatly developed in advanced age.

4. The **Veins of the Spinal Cord** (*medulli-spinal*) consist of a minute tortuous, venous plexus which covers the entire surface of the cord, being situated between the pia mater and arachnoid. These vessels emerge chiefly from the median furrows, and are largest in the lumbar region. Near the base of the skull they unite and form two or three small trunks which communicate with the vertebral veins, and then terminate in the inferior cerebellar veins or in the *inferior* petrosal sinuses. Each of the spinal nerves is accompanied by a branch as far as the intervertebral foramina, where they join the other veins from the spinal canal.

There are no valves in the spinal veins.

VEINS OF THE LOWER EXTREMITY.

The veins of the lower extremity are subdivided, like those of the upper, into two sets, superficial and deep, the superficial veins being placed beneath the integument between the two layers of superficial fascia, the deep veins accompanying the arteries and forming the venæ comites of those vessels. Both sets of veins are provided with valves, which are more numerous in the deep than in the superficial set. These valves are also more numerous in the lower than in the upper limb.

FIG. 420.

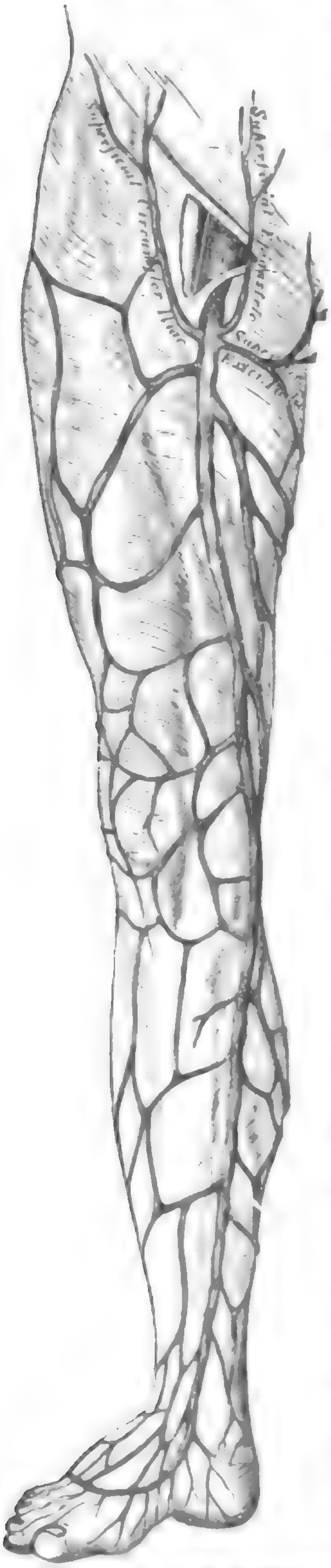

The Internal or Long Saphenous Vein and its Branches.

The **Superficial Veins** of the lower extremity are the *internal* or *long saphenous* and the *external* or *short saphenous*.

On the dorsum of the foot is a venous arch situated in the superficial structures over the anterior extremities of the metatarsal bones. It has its convexity directed forward, and receives digital tributaries from the upper surface of the toes; at its concavity it is joined by numerous small veins which form a plexus on the dorsum of the foot. The arch terminates internally in the long saphenous, externally in a short saphenous vein.

FIG. 421.

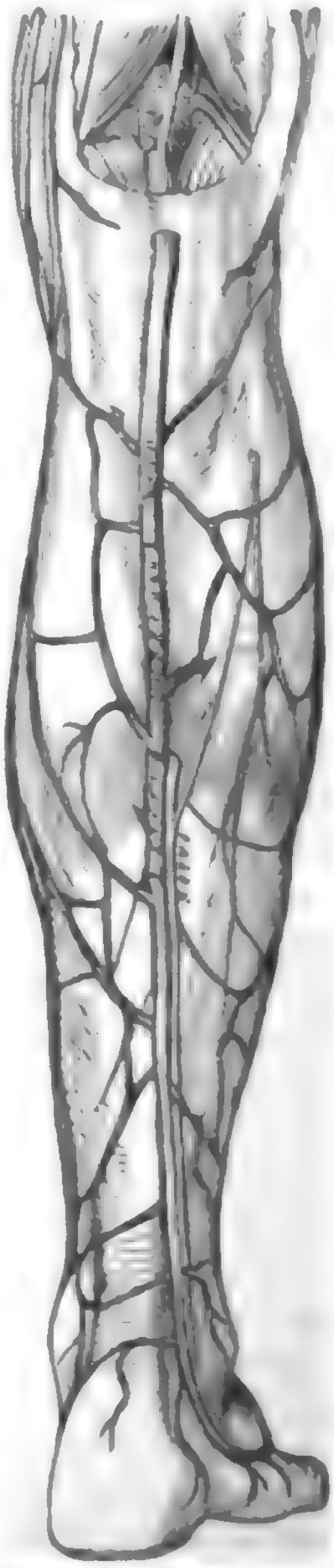

External or Short Saphenous Vein [right leg].

The **Internal or Long Saphenous Vein** [σαφής, manifest, easily seen] (Fig. 420) commences at the inner side of the arch on the dorsum of the foot; it ascends in front of the inner malleolus and along the inner side of the leg, behind the inner margin of the tibia, accompanied by the internal saphenous nerve. At the knee it passes backward behind the inner condyle of the femur, then ascends along the inside of the thigh, and, passing through the saphenous opening in the fascia lata, terminates in the femoral vein about an inch and a half below Poupart's ligament. This vein receives in its course cutaneous tributaries from the leg and thigh, and at the saphenous opening the superficial epigastric, superficial circumflex iliac, and external pudic veins. The veins from the inner and back part of the thigh frequently unite to form a large vessel which enters the main trunk near the saphenous opening; and sometimes those on the outer side of the thigh join to form another large vessel; so that occasionally three large veins are seen converging from different parts of the thigh toward the saphenous opening. The internal saphenous vein communicates in the foot with the internal plantar vein;

in the leg, with the posterior tibial veins by branches which perforate the tibial origin of the Soleus muscle and also with the anterior tibial veins; at the knee, with the articular veins; in the thigh, with the femoral vein by one or more branches. The valves in this vein vary from two to six in number; they are more numerous in the thigh than in the leg.

The **External** or **Short Saphenous Vein** (Fig. 421) commences at the outer side of the arch on the dorsum of the foot; it ascends behind the outer malleolus and along the outer border of the tendo Achillis, across which it passes at an acute angle to reach the middle line of the posterior aspect of the leg. Passing directly upward, it perforates the deep fascia in the lower part of the popliteal space, and terminates in the popliteal vein, between the heads of the Gastrocnemius muscle.[1] It is accompanied by the external saphenous nerve. It receives numerous large tributaries from the back part of the leg, and communicates with the deep veins on the dorsum of the foot and behind the outer malleolus. Before it perforates the deep fascia it gives off a communicating branch which passes upward and inward to join the internal saphenous vein. This vein has a variable number of valves, from three to nine (Gay), one of which is always found near its termination in the popliteal vein.

The **Deep Veins** of the lower extremity accompany the arteries and their branches, and are called the *venæ comites* of those vessels.

The **External** and **Internal Plantar** veins unite to form the **posterior tibial.** They accompany the posterior tibial artery and are joined by the *peroneal* veins.

The **Anterior Tibial Veins** are formed by a continuation upward of the venæ comites of the dorsalis pedis artery. They pass between the tibia and fibula, above the upper border of the interosseous membrane, and form, by their junction with the posterior tibial, the popliteal vein.

The valves in the deep veins are very numerous.

The **Popliteal Vein** is formed by the junction of the venæ comites of the anterior and posterior tibial vessels; it ascends through the popliteal space to the tendinous aperture in the Adductor magnus, where it becomes the femoral vein. In the lower part of its course it is placed internal to the artery; between the heads of the Gastrocnemius it is superficial to that vessel, but above the knee-joint it is close to its outer side. It receives the sural veins from the Gastrocnemius muscle, the articular veins, and the external saphenous. The valves in this vein are usually four in number.

The **Femoral Vein** accompanies the femoral artery through the upper two-thirds of the thigh. In the lower part of its course it lies external to the artery; higher up it is behind it, and beneath Poupart's ligament it lies to its inner side and on the same plane. It receives numerous muscular tributaries: the profunda femoris joins it near its termination, and about an inch and a half below Poupart's ligament the internal saphenous vein. The valves in this vein are four or five in number.

The **External Iliac Vein** commences at the termination of the femoral beneath the crural arch, and, passing upward along the brim of the pelvis, terminates opposite the sacro-iliac symphysis by uniting with the internal iliac to form the common iliac vein. On the right side it lies at first along the inner side of the external iliac artery, but as it passes upward gradually inclines behind it. On the left side it lies altogether on the inner side of the artery. It receives immediately above Poupart's ligament the epigastric and circumflex iliac veins and a small pubic vein corresponding to the pubic branch of the obturator artery. According to Friedreich, it frequently contains one and sometimes two valves.

The **Internal Iliac Vein** is formed by the venæ comites of the branches of the internal iliac artery, the umbilical arteries excepted. It receives the blood from the exterior of the pelvis by the gluteal, sciatic, internal pudic, and obturator veins, and from the organs in the cavity of the pelvis by the hemorrhoidal and vesico-prostatic plexuses in the male and the uterine and vaginal plexuses in the female. The vessels forming these plexuses are remarkable for their large size, their frequent anastomoses, and the number of valves which they contain. The internal iliac vein lies at first on the inner side, and then behind the internal iliac artery, and terminates opposite the sacro-iliac articulation by uniting with the external iliac to form the common iliac vein. This vessel has no valves.

---

[1] Mr. Gay calls attention to the fact that the external saphenous vein often (he says invariably) penetrates the fascia at or about the point where the tendon of the Gastrocnemius commences, and runs below the fascia in the rest of its course, or sometimes among the muscular fibres, to join the popliteal vein. (See Gay on *Varicose Disease of the Lower Extremities*, p. 24, where there is also a careful and elaborate description of the branches of the saphenous veins.)

The **Hemorrhoidal Plexus** surrounds the lower end of the rectum, being formed by the superior hemorrhoidal veins (tributaries of the inferior mesenteric) and the middle and inferior hemorrhoidal, which terminate in the internal iliac. The portal and general venous systems have a free communication by means of the branches composing this plexus.

The **Vesico-prostatic Plexus** surrounds the neck and base of the bladder and prostate gland. It communicates with the hemorrhoidal plexus behind, and receives the dorsal vein of the penis, which enters the pelvis beneath the subpubic ligament. This plexus is supported upon the sides of the bladder by a reflection of the pelvic fascia. The veins composing it are very liable to become varicose, and often contain hard earthy concretions called *phleboliths* [*i. e.* "vein-stones." These are not uncommon in varicose veins of the leg also, especially in the pouches behind the valves].

The **Dorsal Vein of the Penis** is a vessel of large size which returns the blood from the body of that organ. At first it consists of two branches, which are contained in the groove on the dorsum of the penis, and it receives veins from the glans, the corpus spongiosum, and numerous superficial veins; these unite near the root of the penis into a single trunk, which passes through the suspensory ligament of the penis, pierces the triangular ligament beneath the pubic arch, and divides into two branches which enter the prostatic plexus.

The **Vaginal Plexus** surrounds the mucous membrane, being especially developed at the orifice of the vagina; it communicates with the vesical plexus in front and with the hemorrhoidal plexus behind.

The **Uterine Plexus** is situated along the sides and superior angles of the uterus between the layers of the broad ligament, receiving large venous canals (the *uterine sinuses*) from the substance of the uterus. The veins composing this plexus anastomose frequently with each other and with the ovarian veins. They are not tortuous like the arteries.

The **Common Iliac Veins** are formed by the union of the external and internal iliac veins in front of the sacro-iliac articulation; passing obliquely upward toward the right side, they terminate upon the intervertebral substance between the fourth and fifth lumbar vertebræ, where the veins of the two sides unite at an acute angle to form the *inferior vena cava.* The *right common iliac* is shorter than the left, nearly vertical in its direction, and ascends behind, and then to the outer side of its corresponding artery. The *left common iliac*, longer and more oblique in its course, is at first situated on the inner side of the corresponding artery, and then behind the right common iliac. Each common iliac receives the ilio-lumbar and sometimes the lateral sacral veins. The left receives in addition the middle sacral vein. No valves are found in these veins.

The **Middle Sacral Veins** accompany the corresponding artery along the front of the sacrum, and terminate in the left common iliac vein; occasionally in the angle of junction of the two iliac veins.

Peculiarities.—The left common iliac vein, instead of joining with the right in its usual position, occasionally ascends on the left side of the aorta as high as the kidney, where, after receiving the left renal vein, it crosses over the aorta, and then joins with the right vein to form the vena cava. In these cases the two common iliacs are connected by a small communicating branch at the spot where they are usually united.[1]

---

[1] See two cases which have been described by Mr. Walsham in the *St. Bartholomew's Hospital Reports*, vols. xvi. and xvii.

The **Inferior Vena Cava** returns to the heart the blood from all the parts below the Diaphragm. It is formed by the junction of the two common iliac veins on the right side of the intervertebral substance between the fourth and fifth lumbar vertebræ. It passes upward along the front of the spine on the right side of the aorta, and, having reached the under surface of the liver, is contained in a groove in its posterior border. It then perforates the central tendon of the Diaphragm, enters the pericardium, where it is covered by its serous layer, and terminates in the lower and back part of the right auricle. At its termination in the auricle it is provided with a valve, the *Eustachian*, which is of large size during fœtal life.

RELATIONS.—*In front*, from below upward, with the mesentery, right spermatic artery, transverse portion of the duodenum, the pancreas, portal vein, and the posterior border of the liver, which partly and occasionally completely surrounds it; *behind*, with the vertebral column, the right crus of the Diaphragm, the right renal and lumbar arteries, right semilunar ganglion; on the *left side*, with the aorta. It receives in its course the following branches:

Lumbar.
Right Spermatic.
Renal.
Suprarenal.
Phrenic.
Hepatic.

Peculiarities in Position.—This vessel is sometimes placed on the left side of the aorta as high as the left renal vein, after receiving which it crosses over to its usual position on the right side; or it may be placed altogether on the left side of the aorta, as far upward as its termination in the heart: in such cases the abdominal and thoracic viscera, together with the great vessels, are all transposed.

Point of Termination.—Occasionally the inferior vena cava joins the right azygos vein, which is then of large size. In such cases the superior cava receives the whole of the blood from the body before transmitting it to the right auricle, except the blood from the hepatic veins, which passes directly into the right auricle.

The **Lumbar Veins**, three or four in number on each side, collect the blood by dorsal tributaries from the muscles and integument of the loins, and by abdominal tributaries from the walls of the abdomen, where they communicate with the epigastric veins. At the spine they receive veins from the spinal plexuses, and then pass forward, round the sides of the bodies of the vertebræ beneath the Psoas magnus, and terminate at the back part of the inferior cava. The left lumbar veins are longer than the right, and pass behind the aorta. The lumbar veins communicate with each other by branches which pass in front of the transverse processes. These veins are connected together by a longitudinal vessel which passes in front of the transverse processes of the lumbar vertebræ, and, communicating with each lumbar vein, is called the *ascending lumbar*. It forms the most frequent origin of the corresponding vena azygos, and serves to connect the common iliac, ilio-lumbar, lumbar, and azygos veins of the corresponding side of the body.

The **Spermatic Veins** emerge from the back of the testis and receive tributaries from the epididymis; they form a branched and convoluted plexus called the *spermatic plexus* (*plexus pampiniformis*) below the abdominal ring: the vessels composing this plexus are very numerous, and ascend along the cord in front of the vas deferens; having entered the abdomen through the inguinal canal, they coalesce to form two branches, which ascend on the Psoas muscle behind the peritoneum, lying one on each side of the spermatic artery, and unite to form a single vessel which opens on the right side into the inferior vena cava at an acute angle—on the left side into the left renal vein at a right angle. The spermatic veins are provided with valves.[1] The left spermatic vein passes behind the sigmoid flexure of the colon, a part of the intestine in which fecal accumulation is common: this circumstance, as well as the indirect communication of the vessel with the inferior vena cava, may serve to explain the more frequent occurrence of varicocele on the left side.

---

[1] Rivington has pointed out that a valve is usually found at the orifices of both the right and left spermatic veins. When no valves exist at the opening of the left spermatic vein into the left renal vein, valves are generally present in the renal vein within a quarter of an inch from the orifice of the spermatic vein (*Journal of Anatomy and Physiology*, vol. vii. p. 163).

The **Ovarian Veins** are analogous to the spermatic in the male; they form a plexus near the ovary and in the broad ligament and Fallopian tube, communicating with the uterine plexus. They terminate as in the male. Valves are occasionally found in these veins. These vessels, like the uterine veins, become much enlarged during pregnancy.

The **Renal Veins** are of large size and placed in front of the renal arteries.[1] The left is longer than the right, and passes in front of the aorta just below the origin of the superior mesenteric artery. It receives the left spermatic, the left inferior phrenic, and generally the left suprarenal veins. It opens into the vena cava a little higher than the right.

The **Suprarenal Veins** terminate on the right side in the vena cava; on the left side, in the left renal or phrenic vein.

The **Phrenic Veins** follow the course of the phrenic arteries. The *two superior*, of small size, accompany the phrenic nerve and comes nervi phrenici artery, the right terminating opposite the junction of the two venæ innominatæ, the left in the left superior intercostal or left internal mammary. The *two inferior phrenic veins* follow the course of the phrenic arteries, and terminate, the right in the inferior vena cava, the left in the left renal vein.

The **Hepatic Veins** commence in the substance of the liver, in the capillary terminations of the portal vein and hepatic artery: these tributaries, gradually uniting, usually form three large veins, which converge toward the posterior border of the liver and open into the inferior vena cava, whilst that vessel is situated in the groove at the back part of this organ. Of these three veins, one from the right and another from the left lobe open obliquely into the vena cava, that from the middle of the organ and lobulus Spigelii having a straight course. The hepatic veins run singly and are in direct contact with the hepatic tissue. They are destitute of valves.

PORTAL SYSTEM OF VEINS.

The portal venous system is composed of four large veins which collect the venous blood from the viscera of digestion. The trunk formed by their union (*vena portæ*) enters the liver and ramifies throughout its substance, and its branches, again emerging from that organ as the hepatic veins, terminate in the inferior vena cava. The branches of this vein are in all cases single and destitute of valves.

The veins forming the portal system are the

Inferior Mesenteric.
Superior Mesenteric.
Splenic.
Gastric.

The **Inferior Mesenteric Vein** returns the blood from the rectum, sigmoid flexure, and descending colon, corresponding with the ramifications of the branches of the inferior mesenteric artery. Ascending beneath the peritoneum in the lumbar region, it passes behind the transverse portion of the duodenum and pancreas and terminates in the splenic vein. Its hemorrhoidal branches inosculate with those of the internal iliac, and thus establish a communication between the portal and the general venous system.[2]

The **Superior Mesenteric Vein** returns the blood from the small intestines and from the cæcum and ascending and transverse portions of the colon, corresponding with the distribution of the branches of the superior mesenteric artery. The large trunk formed by the union of these branches ascends along the right side and in front of the corresponding artery, passes in front of the transverse portion of the duodenum, and unites behind the upper border of the pancreas with the splenic vein to form the vena portæ. It receives the right gastro-epiploic vein.

---

[1] The student may observe that all veins above the Diaphragm which do not lie on the same plane as the arteries which they accompany lie in front of them; and that all veins below the Diaphragm which do not lie on the same plane as the arteries which they accompany lie behind them, except the renal and profunda femoris vein.

[2] Besides this anastomosis between the portal vein and the branches of the vena cava, other anastomoses between the portal and systemic veins are formed by the communication between the gastric veins and the œsophageal veins, which empty themselves into the vena azygos minor, between the left renal vein and the veins of the intestines, especially of the colon and duodenum, and between superficial branches of the portal veins of the liver and the phrenic veins, as pointed out by Mr. Kiernan. (See *Physiological Anatomy*, by Todd and Bowman, 1859, vol. ii. p. 348.)

The **Splenic Vein** commences by five or six large branches, which return the blood from the substance of the spleen. These uniting form a single vessel, which passes from left to right behind the upper border of the pancreas below the artery, and terminates at its greater end by uniting at a right angle with the superior mesenteric to form the vena portæ. The splenic vein is of large size, and not tortuous like the artery. It receives the vasa brevia from the left extremity of the stomach, the left gastro-epiploic vein, pancreatic branches from the pancreas, the pancreatico-duodenal vein, and the inferior mesenteric vein.

FIG. 422.

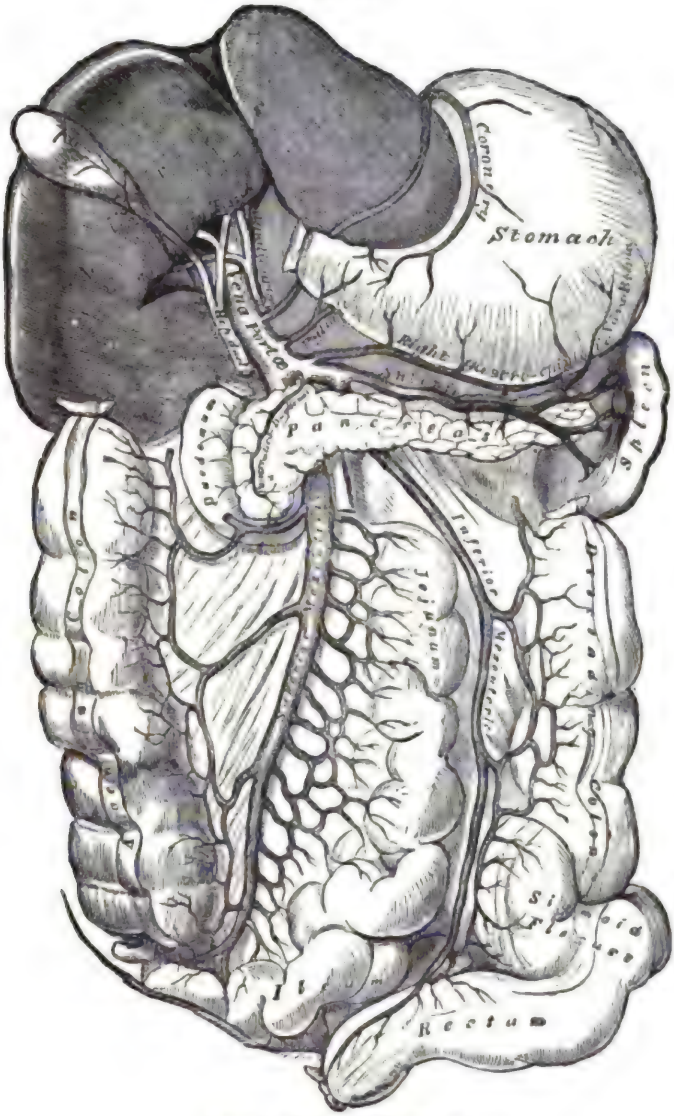

Portal Vein and its Branches.[1]

The **Gastric Veins** are two in number: one, a small vein, corresponds to the pyloric branch of the hepatic artery; the other, considerably larger, corresponds to the gastric artery. The former (*pyloric*, Walsham) runs along the lesser curvature of the stomach toward the pyloric end, receives branches from the pylorus and duodenum, and ends in the vena portæ. The latter (*coronary*, Walsham) begins near the pylorus, runs along the lesser curvature of the stomach toward the œsophageal opening, and then curves downward and backward between the folds of the lesser omentum to end in the vena portæ.[1]

---

[1] In this diagram the right gastro-epiploic vein opens into the splenic vein; generally it empties into the superior mesenteric, close to its termination.

The **Portal Vein** is formed by the junction of the superior mesenteric and splenic veins, their union taking place in front of the vena cava and behind the upper border of the great end of the pancreas. Passing upward through the right border of the lesser omentum to the under surface of the liver, it enters the transverse fissure, where it is somewhat enlarged, forming the *sinus* of the portal vein, and divides into two branches, which accompany the ramifications of the hepatic artery and hepatic duct throughout the substance of the liver. Of these two branches, the right is the larger but the shorter of the two. The portal vein is about three or four inches in length, and, whilst contained in the lesser omentum, lies behind and between the hepatic duct and artery, the former being to the right, the latter to the left. These structures are accompanied by filaments of the hepatic plexus of nerves and numerous lymphatics, surrounded by a quantity of loose areolar tissue (*capsule of Glisson*), and placed between the layers of the lesser omentum. The vena portæ receives the gastric and cystic veins; the latter vein sometimes terminates in the right branch of the vena portæ. Within the liver the portal vein receives the blood from the branches of the hepatic artery.

CARDIAC VEINS.

The veins which return the blood from the substance of the heart are the

Great Cardiac Vein.	Anterior Cardiac Veins.
Middle Cardiac Vein.	Right or Small Cardiac Vein.
Posterior Cardiac Veins.	Venæ Thebesii.

The **Great Cardiac Vein** (*coronary*) is a vessel of considerable size which commences at the apex of the heart and ascends along the anterior interventricular groove to the base of the ventricles. It then curves to the left side, around the auriculo-ventricular groove, between the left auricle and ventricle, to the back part of the heart, and opens into the coronary sinus, its aperture being guarded by two valves. It receives in its course tributaries from both ventricles, but especially the left, and also from the left auricle; one of these, ascending along the thick margin of the left ventricle, is of considerable size. The vessels joining it are provided with valves.

The **Middle Cardiac Vein** commences by small tributaries at the apex of the heart, communicating with those of the preceding. It ascends along the posterior interventricular groove to the base of the heart, and terminates in the coronary sinus, its orifice being guarded by a valve. It receives the veins from the posterior surface of both ventricles.

The **Posterior Cardiac Veins** are three or four small vessels which collect the blood from the posterior surface of the left ventricle and open into the lower border of the coronary sinus.

The **Anterior Cardiac Veins** are three or four small vessels which collect the blood from the anterior surface of the right ventricle. One of these (*the vein of Galen*), larger than the rest, runs along the right border of the heart. They open separately into the lower part of the right auricle.

The **Right** or **Small Coronary Vein** runs along the groove between the right auricle and ventricle, to open into the right extremity of the coronary sinus. It receives blood from the back part of the right auricle and ventricle.

---

[1] The above description of the gastric vein is the one given by Mr. Walsham, and differs from that usually found in the text-books. Since the publication of Mr. Walsham's paper I have verified the truth of his description. (See *Journal of Anatomy and Physiology*, vol. xiv. p. 399.)

The **Venæ Thebesii** are numerous minute veins which return the blood directly from the muscular substance, without entering the venous current. They open by minute orifices (*foramina Thebesii*) on the inner surface of the right auricle.

The **Coronary Sinus** is that portion of the great cardiac vein which is situated in the posterior part of the left auriculo-ventricular groove. It is about an inch in length, presents a considerable dilatation, and is covered by the muscular fibres of the left auricle. It receives the veins enumerated above, and an *oblique vein* from the back part of the left auricle, the remnant of the obliterated left innominate trunk of the fœtus, described by Mr. Marshall. The coronary sinus terminates in the right auricle, between the inferior vena cava and the auriculo-ventricular aperture, its orifice being guarded by a semilunar fold of the lining membrane of the heart, the *coronary valve*. All the branches joining this vessel, excepting the oblique vein above mentioned, are provided with valves.

Of the Lymphatics.

THE **Lymphatics** have derived their name from the appearance of the fluid contained in their interior (*lympha*, water). They are also called *absorbents*, from the property they possess of absorbing certain materials from the tissues and conveying them into the circulation.

The lymphatic system includes not only the lymphatic vessels and the glands through which they pass, but also the *lacteal* or *chyliferous* vessels. The lacteals are the lymphatic vessels of the small intestine, and differ in no respect from the lymphatics generally, excepting that they contain a milk-white fluid, the *chyle*, during the process of digestion, and convey it into the blood through the thoracic duct.

The lymphatics are exceedingly delicate vessels, the coats of which are so transparent that the fluid they contain is readily seen through them. They retain a nearly uniform size, being interrupted at intervals by constrictions which give them a knotted or beaded appearance. These constrictions are due to the presence of valves in their interior. Lymphatics have been found in nearly every texture and organ of the body which contains blood-vessels. Such non-vascular structures as cartilage, the nails, cuticle, and hair have none, but with these exceptions it is probable that eventually all parts will be found to be permeated by these vessels.

The lymphatics are arranged into a superficial and deep set. The superficial lymphatics, on the surface of the body, are placed immediately beneath the integument accompanying the superficial veins; they join the deep lymphatics in certain situations by perforating the deep fascia. In the interior of the body they lie in the submucous areolar tissue throughout the whole length of the gastro-pulmonary and genito-urinary tracts, and in the subserous areolar tissue in the cranial, thoracic, and abdominal cavities. The method of their origin has been described along with the other details of their minute anatomy (p. 85). Here it will be sufficient to say that a plexiform network of minute lymphatics may be found interspersed among the proper elements and blood-vessels of the several tissues, the vessels composing which, as well as the meshes between them, are much larger than those of the capillary plexus. From these networks small vessels emerge, which pass either to a neighboring gland or to join some larger lymphatic trunk. The deep lymphatics, fewer in number and larger than the superficial, accompany the deep blood-vessels. Their mode of origin is probably similar to that of the superficial vessels. The lymphatics of any part or organ exceed the veins in number, but in size they are much smaller. Their anastomoses also, especially those of the large trunks, are more frequent, and are effected by vessels equal in diameter to those which they connect, the continuous trunks retaining the same diameter.

The **lymphatic** or **absorbent glands**, named also *conglobate glands*, are small solid glandular bodies situated in the course of the lymphatic and lacteal vessels. They are found in the neck and on the external parts of the head; in the upper extremity, in the axilla and in front of the elbow; in the lower extremity, in the groin and popliteal space, and in some other situations. In the abdomen they are found in large numbers in the mesentery and along the side of the aorta, vena cava, and iliac vessels; and in the thorax, in the anterior and posterior mediastina. They are somewhat flattened and of a round or oval form. In size they vary from a hempseed to an almond, and their color, on section, is of a pinkish-gray tint, excepting the bronchial glands, which in the adult are mottled with black. [It is important that the student, by examination of these glands in his own groin, should familiarize himself with their normal size. In the axilla they are not usually perceptible at all, unless enlarged by disease.] Each gland has a layer or capsule of cellular tissue investing it, from which prolongations dip into its substance, forming partitions. The lymphatic and lacteal vessels pass through these bodies in their passage to the thoracic and lymphatic ducts. A lymphatic or lacteal vessel previous to entering a gland divides into several small branches, which are named *afferent vessels*. As they enter, their external coat becomes continuous with the capsule of the gland, and the vessels, much thinned and consisting only of their internal or endothelial coat, pass into the gland and branch out upon and in the tissue of the capsule, these branches opening into the lymph-sinuses of the gland. From these sinuses fine branches proceed to form a plexus, the vessels of which unite to form a single *efferent* vessel, which on emerging from the gland is again invested with an external coat. (Further details on the minute anatomy of the lymphatic vessels and glands will be found in the chapter on General Anatomy.)

THORACIC DUCT.

The **Thoracic Duct** (Fig. 423) conveys the great mass of the lymph and chyle into the blood. It is the common trunk of all the lymphatic vessels of the body, excepting those of the right side of the head, neck, and thorax, and right upper extremity, the right lung, right side of the heart, and the convex surface of the liver. It varies in length from fifteen to eighteen inches in the adult, and extends from the second lumbar vertebra to the root of the neck. It commences in the abdomen by a triangular dilatation, the *receptaculum chyli* (*reservoir* or *cistern of Pecquet*), which is situated upon the front of the body of the second lumbar vertebra, to the right side and behind the aorta, by the side of the right crus of the diaphragm. It ascends into the thorax through the aortic opening in the diaphragm, lying to the right of the aorta and is placed in the posterior mediastinum in front of the vertebral column, lying between the aorta and vena azygos major. Opposite the fourth dorsal vertebra it inclines toward the left side and ascends behind the arch of the aorta, on the left side of the œsophagus and behind the first portion of the left subclavian artery, to the upper orifice of the thorax. Opposite the upper border of the seventh cervical vertebra it curves downward above the subclavian artery and in front of the Scalenus anticus muscle so as to form an arch, and terminates near the angle of junction of the left internal jugular and subclavian veins. The thoracic duct at its commencement is about equal in size to the diameter of a goose-quill, diminishes considerably in its calibre in the middle of the thorax, and is again dilated just before its termination. It is generally flexuous in its course, and constricted at intervals so as to present a varicose appearance. The thoracic duct not unfrequently divides in the middle of its course into two branches of unequal size which soon reunite, or into several branches which form a plexiform interlacement. It occasionally bifurcates at its upper part into two branches, of which the one on the left side terminates in the usual manner, while that on the right opens into the right subclavian vein in connection with the right lymphatic duct. The thoracic duct has numerous valves throughout its whole course, but they are more numerous in the upper than in the lower part: at its termination it is provided with a pair of valves, the free borders of which are turned toward the vein, so as to prevent the passage of venous blood into the duct.

TRIBUTARIES.—The thoracic duct at its commencement receives four or five large trunks from the abdominal lymphatic glands, and also the trunk of the lacteal vessels. Within the thorax it is joined by the lymphatic vessels from the left half of the wall of the thoracic cavity, the lymphatics from the sternal and intercostal glands, those of the left lung, left side of the heart, trachea, and œsophagus; and just before its termination its receives the lymphatics of the left side of the head and neck and left upper extremity.

Structure (Fig. 65, p. 85).—The thoracic duct is composed of three coats, which differ in some respects from those of the lymphatic vessels. The *internal coat* consists of a layer of endothelium, consisting of a single layer of flattened lanceolate cells with serrated borders; of a subendothelial layer similar to that found in the arteries; and an elastic fibrous coat, the fibres of which run in a longitudinal direction. The *middle coat* consists of a longitudinal layer of white connective tissue with elastic fibres, external to which are several laminæ of muscular tissue, the fibres of which are for the most part disposed transversely, but some are oblique or longitudinal and intermixed with elastic fibres. The *external coat* is composed of areolar tissue, with elastic fibres and isolated fasciculi of muscular fibres.

Fig. 423.

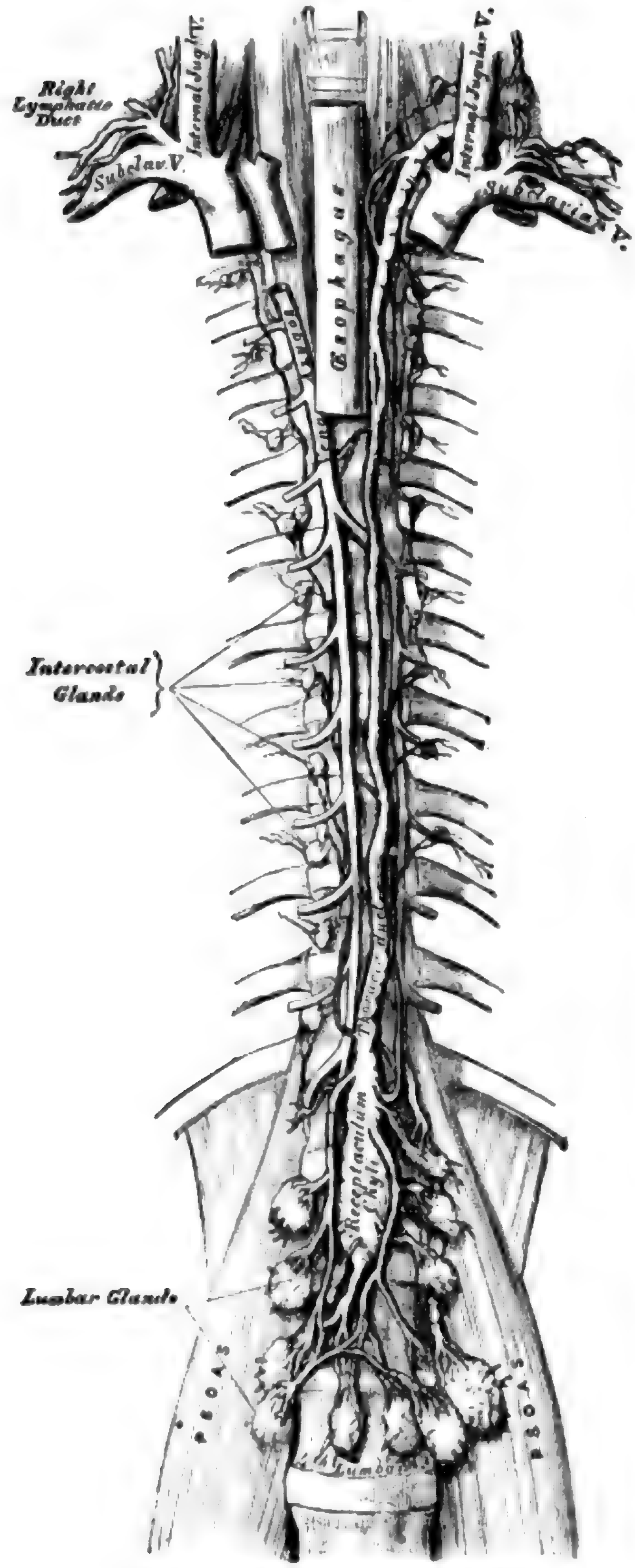

The Thoracic and Right Lymphatic Duct.

The **Right Lymphatic Duct** is a short trunk, about an inch in length and a line or a line and a half in diameter, which receives the lymph from the right side of the head and neck, the right upper extremity, the right side of the thorax, the right lung, and right side of the heart, and from part of the convex surface of the liver, and terminates at the angle of union of the right subclavian and right internal jugular veins. Its orifice is guarded by two semilunar valves which prevent the entrance of blood from the veins.

LYMPHATICS OF THE HEAD, FACE, AND NECK.

The **Superficial Lymphatic Glands of the Head** (Fig. 424) are of small size, few in number, and confined to its posterior region. They are the *occipital*, placed at the back of the head along the attachment of the Occipito-frontalis; and the *posterior auricular*, near the upper end of the Sterno-mastoid. These glands are affected in cutaneous eruptions and other diseases of the scalp. In the face the superficial lymphatic glands are more numerous: they are the *parotid*, some of which are superficial and others deeply placed in the substance of the parotid gland; the *zygomatic*, situated under the zygoma; the *buccal*, on the surface of the Buccinator muscle; and the *submaxillary*, the largest, beneath the body of the lower jaw.

The **Superficial Lymphatics of the Head** are divided into an anterior and a posterior set, which follow the course of the temporal and occipital vessels. The temporal set accompany the temporal artery in front of the ear to the parotid lymphatic glands, from which they proceed to the lymphatic glands of the neck. The occipital set follow the course of the occipital artery, descend to the occipital and posterior auricular lymphatic glands, and from thence join the cervical glands.

The **Superficial Lymphatics of the Face** are more numerous than those of the head, and commence over its entire surface. Those from the frontal region accompany the frontal vessels: they then pass obliquely across the face, running with the facial vein, pass through the buccal glands on the surface of the Buccinator muscle, and join the submaxillary lymphatic glands. The latter receive the lymphatic vessels from the lips, and are often found enlarged in cases of malignant disease of those parts.

The **Deep Lymphatics of the Face** are derived from the pituitary membrane of the nose, the mucous membrane of the mouth and pharynx, and the contents of the temporal and orbital fossæ: they accompany the branches of the internal maxillary artery, and terminate in the deep parotid and cervical lymphatic glands.

Fig. 424.

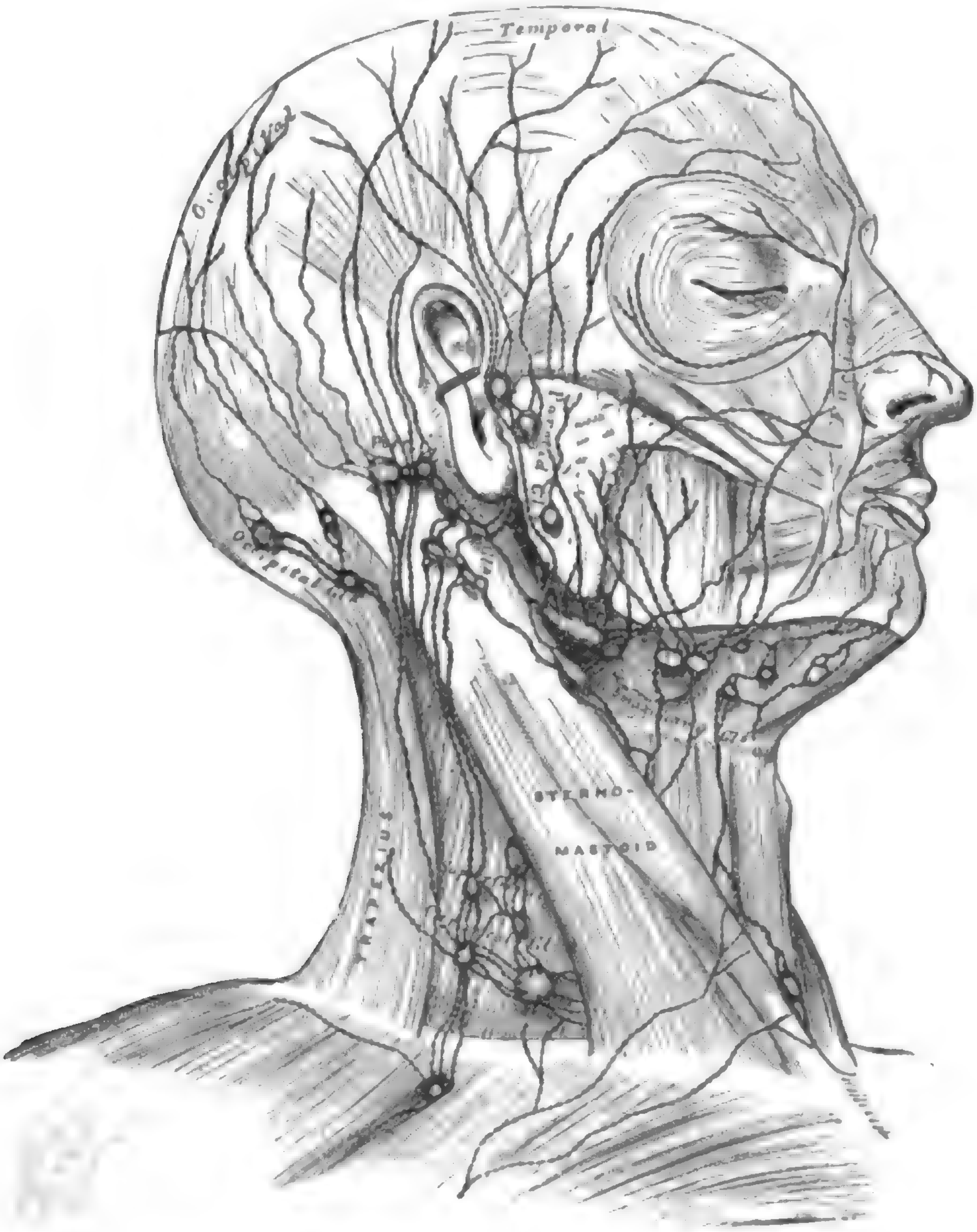

The Superficial Lymphatics and Glands of the Head, Face, and Neck.

The Deep Lymphatics of the Cranium consist of two sets, the meningeal and cerebral. The *meningeal* lymphatics accompany the meningeal vessels, escape through foramina at the base of the skull, and join the deep cervical lymphatic glands. The *cerebral* lymphatics are described by Eshmann as being situated between the arachnoid and pia mater, as well as in the choroid plexuses of the lateral ventricles: they accompany the trunks of the carotid and vertebral arteries, and probably pass through foramina at the base of the skull, to terminate in the deep cervical glands. They have not at present been demonstrated in the dura mater or in the substance of the brain.

The **Lymphatic Glands of the Neck** are divided into two sets, superficial and deep.

The **superficial cervical glands** (Fig. 424) are placed in the course of the external jugular vein between the Platysma and deep fascia. They are most numerous at the root of the neck, in the triangular interval between the clavicle, the Sterno-mastoid, and the Trapezius, where they are continuous with the axillary glands. A few small glands are also found on the front and sides of the larynx.

The **deep cervical glands** (Fig. 425) are numerous and of large size; they form an uninterrupted chain along the sheath of the carotid artery and internal jugular vein, lying by the side of the pharynx, œsophagus, and trachea, and extending from the base of the skull to the thorax, where they communicate with the lymphatic glands in that cavity.

Fig. 425.

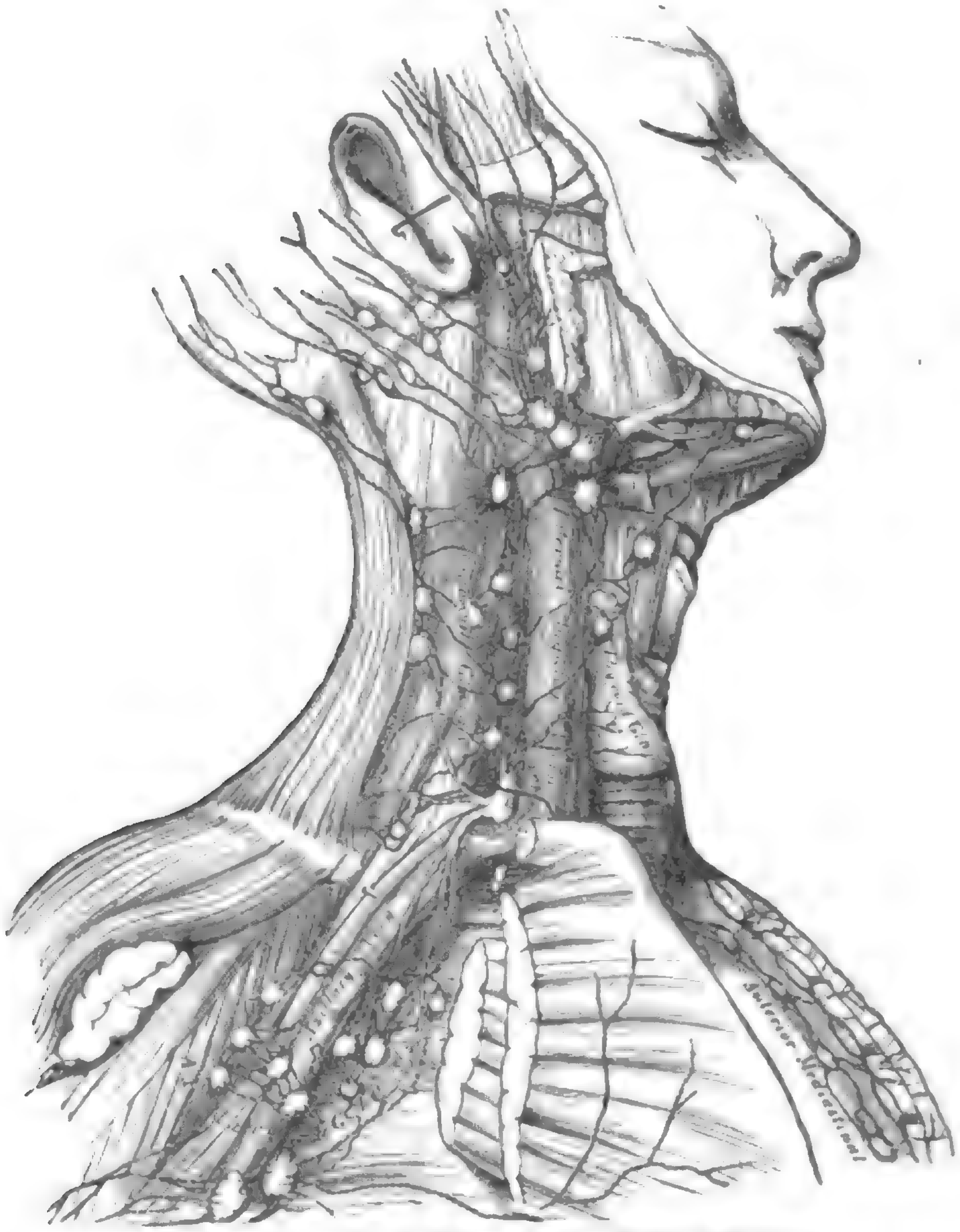

The Deep Lymphatics and Glands of the Neck and Thorax.

The **superficial and deep cervical lymphatics** are a continuation of those already described on the cranium and face. After traversing the glands in those regions they pass through the chain of glands which lie along the sheath of the carotid vessels, being joined by the lymphatics from the pharynx, œsophagus, larynx, trachea, and thyroid gland. At the lower part of the neck, after receiving some lymphatics from the thorax, they unite into a single trunk, which terminates on the left side in the thoracic duct; on the right side, in the right lymphatic duct.

LYMPHATICS OF THE UPPER EXTREMITY.

The Lymphatic Glands of the Upper Extremity (Fig. 426) may be subdivided into two sets, superficial and deep.

The **superficial lymphatic glands** are few and of small size. There are occasionally two or three in front of the elbow, and one or two above the internal condyle of the humerus, near the basilic vein. [These are sometimes enlarged in syphilis.]

FIG. 426.

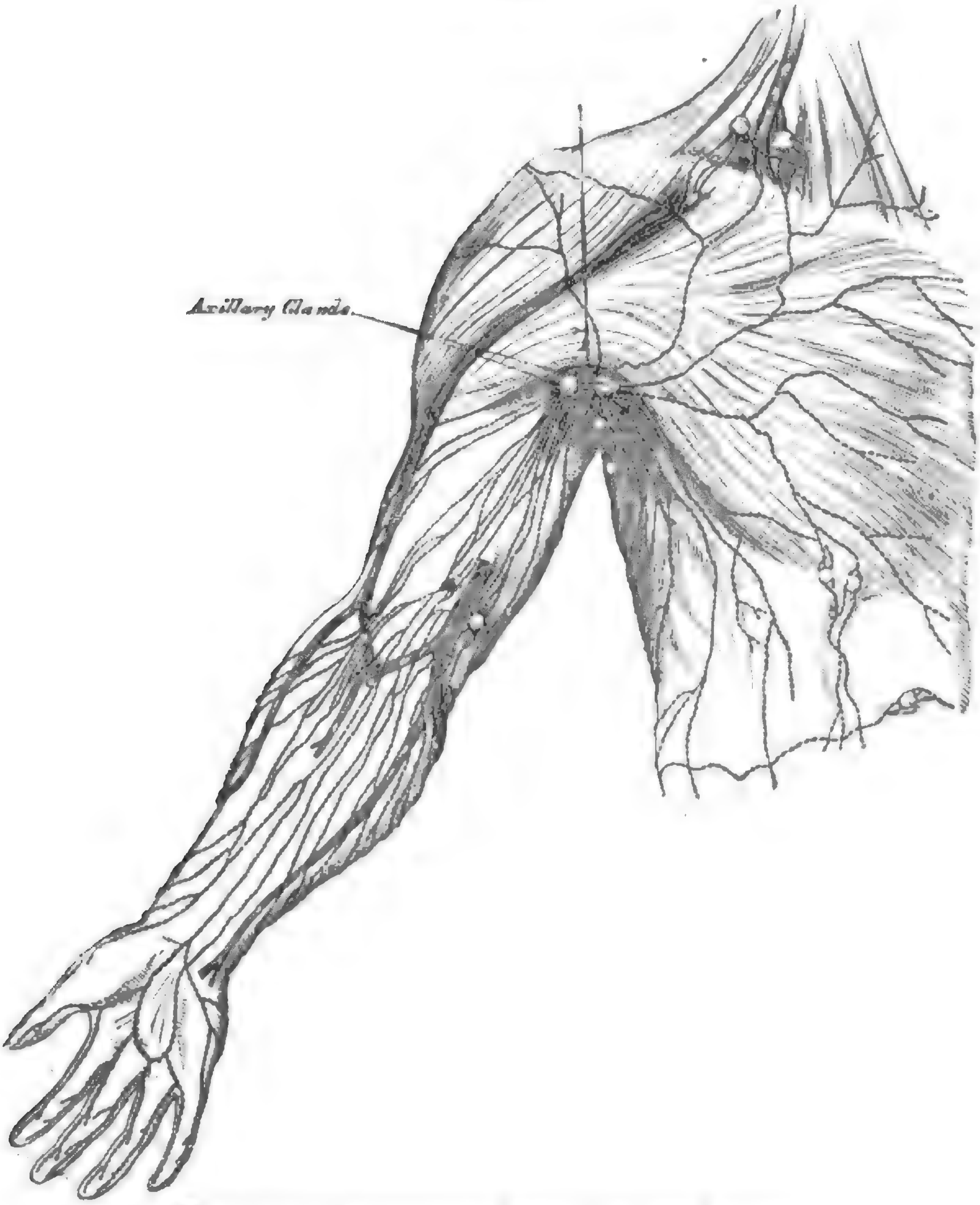

The Superficial Lymphatics and Glands of the Upper Extremity.

The **deep lymphatic glands** are also few in number. In the forearm a few small ones are occasionally found in the course of the radial and ulnar vessels; and in the arm there is a chain of small glands along the inner side of the brachial artery.

The **axillary glands** are of large size and usually ten or twelve in number. A chain of these glands surrounds the axillary vessels imbedded in a quantity of loose areolar tissue: they receive the lymphatic vessels from the arm; others are dispersed in the areolar tissue of the axilla; the remainder are arranged in two series, a small chain running along the lower border of the Pectoralis major as far as the mammary gland, receiving the lymphatics from the front of the chest and mamma; and others are placed along the lower margin of the posterior wall of the axilla, which receive the lymphatics from the integument of the back. Two or three subclavian lymphatic glands are placed immediately beneath the clavicle; it is through these that the axillary and deep cervical glands communicate with each other. In malignant diseases, tumors, or other affections implicating the upper part of the back and shoulder, the front of the chest and mamma, the upper part of the front and side of the abdomen, or the hand, forearm, and arm, the axillary glands are liable to be found enlarged. [These glands have assumed greater importance with the recent practice of cleaning out the entire axilla in cancer of the breast, etc., and should therefore be carefully examined.]

The **superficial lymphatics** of the upper extremity commence on the fingers, two vessels running along each side of each finger, one on the palmar and the other on the dorsal surface. Those on the palmar surface form an arch in the palm of the hand from which are derived two sets of vessels, which pass up the forearm, taking the course of the subcutaneous veins. The lymphatics from the dorsal surface of the fingers form a plexus on the back of the hand, and, winding around the inner and outer borders of the forearm, unite with those in front. Those from the inner border of the hand accompany the ulnar veins along the inner side of the forearm to the bend of the elbow, where they join with some lymphatics from the outer side of the forearm; they then follow the course of the basilic vein, communicate with the glands immediately above the elbow, and terminate in the axillary glands, joining with the deep lymphatics. The superficial lymphatics from the outer and back part of the hand accompany the radial veins to the bend of the elbow. They are less numerous than the preceding. At the bend of the elbow the greater number join the basilic group; the rest ascend with the cephalic vein on the outer side of the arm, some crossing the upper part of the Biceps obliquely, to terminate in the axillary glands, while one or two accompany the cephalic vein in the cellular interval between the Pectoralis major and Deltoid and enter the subclavian lymphatic glands.

The **deep lymphatics** of the upper extremity accompany the deep blood-vessels. In the forearm they consist of four sets, corresponding with the radial, ulnar, and interosseous arteries; they pass through the glands occasionally found in the course of those vessels, and communicate at intervals with the superficial lymphatics. In their course upward some of them pass through the glands which lie upon the brachial artery; they then enter the axillary and subclavian glands, and at the root of the neck terminate on the left side in the thoracic duct, and on the right side in the right lymphatic duct.

LYMPHATICS OF THE LOWER EXTREMITY.

The **Lymphatic Glands of the Lower Extremity** may be subdivided into two sets, superficial and deep; the former are confined to the inguinal region.

The **superficial inguinal glands**, placed immediately beneath the integument, are of large size and vary from eight to ten in number. They are divisible into two groups: a *superior*, disposed irregularly along Poupart's ligament, which receive the lymphatic vessels from the integument of the scrotum, penis [labia majora and minora and clitoris], parietes of the abdomen, perineal and gluteal regions, and the mucous membrane of the urethra; and an *inferior* group, which surround the saphenous opening in the fascia lata, a few being sometimes continued along the saphenous vein to a variable extent. The latter receive the superficial lymphatic vessels from the lower extremity. These glands frequently become enlarged in diseases implicating the parts from which their lymphatics originate. [It is very important to distinguish the two sets accurately, as enlargement of one set or of the other points to wholly different sources and regions of disease.] Thus in malignant or syphilitic affections of the prepuce and penis or of the labia majora in the female, in cancer scroti, in abscess in the perineum, or in any other disease affecting the integument and superficial structures in those parts or the subumbilical part of the abdominal wall or gluteal region, the upper chain of glands is almost invariably enlarged, the lower chain being implicated in diseases affecting the lower limb.

The **deep lymphatic glands** are the anterior, tibial, popliteal, deep inguinal, gluteal, and ischiatic.

The **anterior tibial gland** is not constant in its existence. It is generally found by the side of the anterior tibial artery upon the interosseous membrane at the upper part of the leg. Occasionally, two glands are found in this situation.

The **deep popliteal glands,** four or five in number, are of small size; they surround the popliteal vessels, imbedded in the cellular tissue and fat of the popliteal space.

The **deep inguinal glands** are placed beneath the deep fascia around the femoral artery and vein. They are of small size, and communicate with the superficial inguinal glands through the saphenous opening.

The **gluteal** and **ischiatic glands** are placed, the former above, the latter below, the Pyriformis muscle, resting on their corresponding vessels as they pass through the great sacro-sciatic foramen.

The **Lymphatics of the Lower Extremity,** like the veins, may be divided into two sets, superficial and deep.

The **superficial lymphatics** are placed beneath the integument in the superficial fascia, and are divisible into two groups: an internal group, which follow the course of the internal saphenous vein; and an external group, which accompany the external saphenous. The *internal group*, the larger, commence on the inner side and dorsum of the foot; they pass, some in front and some behind the inner ankle, run up the leg with the internal saphenous vein, pass with it behind the inner condyle of the femur, and accompany it to the groin, where they terminate in the group of inguinal glands which surround the saphenous opening. Some of the efferent vessels from these glands pierce the cribriform fascia and sheath of the femoral vessels, and terminate in a lymphatic gland

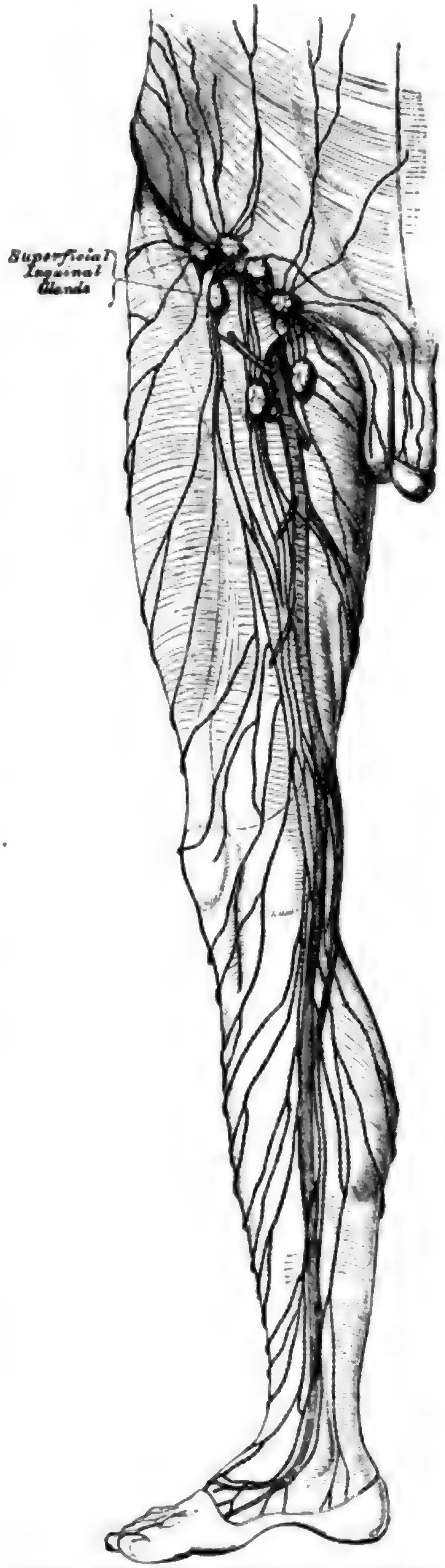

FIG. 427. The Superficial Lymphatics and Glands of the Lower Extremity.

contained in the femoral canal, thus establishing a communication between the lymphatics of the lower extremity and those of the trunk; others pierce the fascia lata and join the deep inguinal glands. The *external group* arise from the outer side of the foot, ascend in front of the leg, and, just below the knee, cross the tibia from without inward, to join the lymphatics on the inner side of the thigh. Others commence on the outer side of the foot, pass behind the outer malleolus, and accompany the external saphenous vein along the back of the leg, where they enter the popliteal glands.

The **deep lymphatics** of the lower extremity are few in number and accompany the deep blood-vessels. In the leg they consist of three sets, the anterior tibial, peroneal, and posterior tibial, which accompany the corresponding blood-vessels, two or three to each artery; they ascend with the blood-vessels and enter the lymphatic glands in the popliteal space; the efferent vessels from these glands accompany the femoral vein and join the deep inguinal glands; from these the vessels pass beneath Poupart's ligament and communicate with the chain of glands surrounding the external iliac vessels.

The deep lymphatics of the gluteal and ischiatic regions follow the course of the blood-vessels, and join the gluteal and ischiatic glands at the great sacrosciatic foramen.

LYMPHATICS OF THE PELVIS AND ABDOMEN.

The **Deep Lymphatic Glands in the Pelvis** are the external iliac, the internal iliac, and the sacral. Those of the abdomen are the lumbar glands.

The **external iliac glands** form an uninterrupted chain round the external iliac vessels, three being placed round the commencement of the vessels just behind the crural arch. They communicate below with the femoral lymphatics and above with the lumbar glands.

The **internal iliac glands** surround the internal iliac vessels; they receive the lymphatics corresponding to the branches of the internal iliac artery and communicate with the lumbar glands.

The **sacral glands** occupy the sides of the anterior surface of the sacrum, some being situated in the meso-rectal fold. These and the internal iliac glands are affected in malignant disease of the bladder, rectum, or uterus.

The **lumbar glands** are very numerous; they are situated on the front of the lumbar vertebræ, surrounding the common iliac vessels, the aorta, and vena cava; they receive the lymphatic vessels from the lower extremities and pelvis, as well as from the testes and some of the abdominal viscera; the efferent vessels from these glands unite into a few large trunks, which, with the lacteals, form the commencement of the thoracic duct. In addition to these there are a few small *lateral* lumbar glands which lie between the transverse processes of the vertebræ, behind the Psoas muscle, and receive lymphatics from the back. In some cases of malignant disease these glands become enormously enlarged, completely surrounding the aorta and vena cava, and occasionally greatly contracting the calibre of those vessels. In all cases of malignant disease of the testis and in malignant disease of the lower limb, before any operation is attempted, careful examination of the abdomen should be made in order to ascertain if any enlargement exists; and if any should be detected all operative measures should be avoided as fruitless.

The **Lymphatics of the Pelvis and Abdomen** may be divided into two sets, superficial and deep.

The **superficial lymphatics of the walls of the abdomen and pelvis** follow the course of the superficial blood-vessels. Those derived from the integument of the lower part of the abdomen below the umbilicus follow the course of the superficial epigastric vessels, and converge to the superior group of the superficial inguinal glands; the deep set accompany the deep epigastric vessels and communicate with the external iliac glands. The superficial lymphatics from the sides of the lumbar part of the abdominal wall wind round the crest of the ilium, accompanying the superficial circumflex iliac vessels, to join the superior group of the superficial inguinal glands; the greater number, however, run backward along with the ilio-lumbar and lumbar vessels, to join the lateral lumbar glands.

The **superficial lymphatics of the gluteal region** turn horizontally round the outer side of the nates and join the superficial inguinal glands.

FIG. 428.

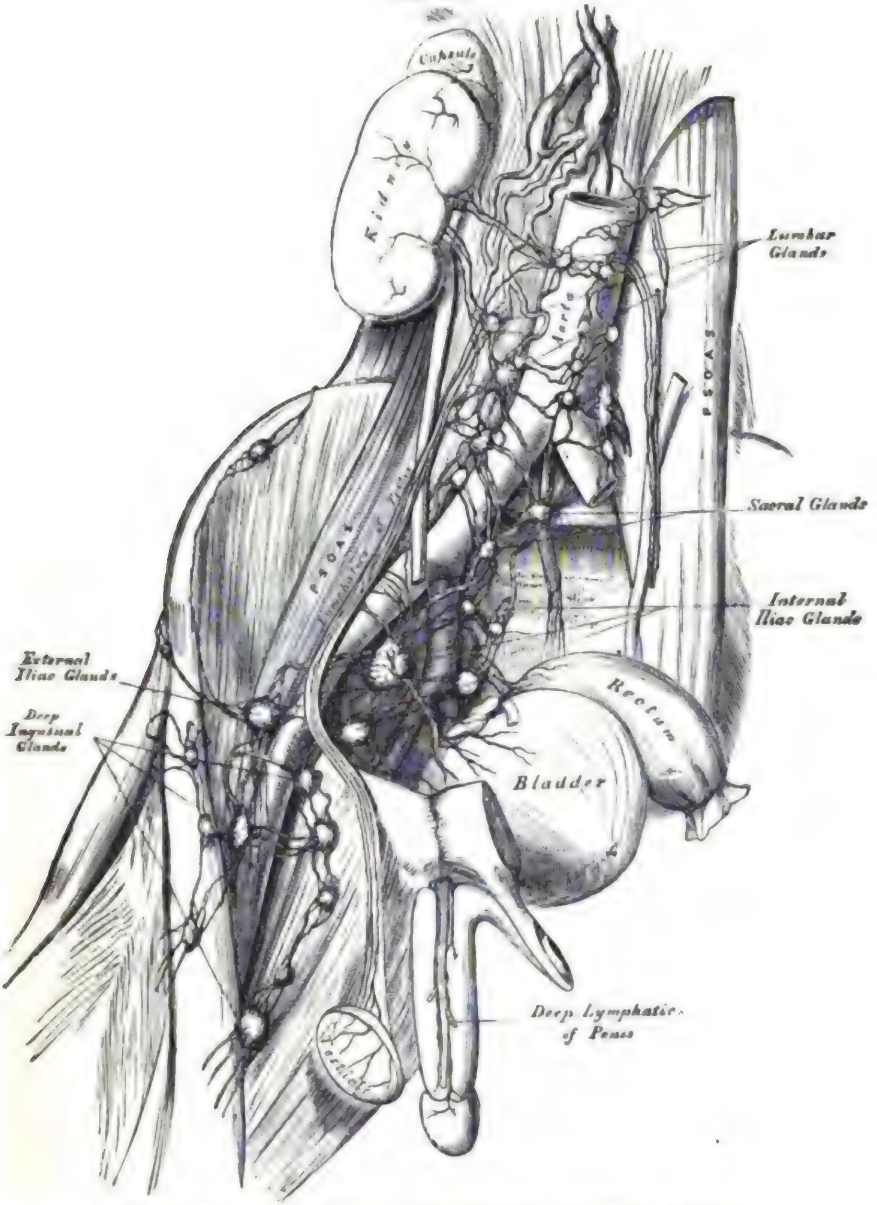
Capsule
Kidney
Lumbar Glands
Aorta
PSOAS
Sacral Glands
Internal Iliac Glands
PSOAS
Rectum
External Iliac Glands
Deep Inguinal Glands
Bladder
Deep Lymphatics of Penis
Testicle

The Deep Lymphatic Vessels and Glands of the Abdomen and Pelvis.

The **superficial lymphatics of the scrotum and perineum** follow the course of the external pudic vessels and terminate in the superficial inguinal glands.

The **superficial lymphatics of the penis** occupy the sides and dorsum of the organ, the latter receiving the lymphatics from the skin covering the glans penis; they all converge to the upper chain of the superficial inguinal glands. The deep lymphatic vessels of the penis follow the course of the internal pudic vessels and join the internal iliac glands.

In the **female** the lymphatic vessels of the mucous membrane of the labia, nymphæ, and clitoris terminate in the upper chain of the inguinal glands.

The **deep lymphatics of the pelvis and abdomen** take the course of the principal blood-vessels. Those of the parietes of the pelvis, which accompany the gluteal, ischiatic, and obturator vessels, follow the course of the internal iliac artery, and ultimately join the lumbar lymphatics.

The efferent vessels from the inguinal glands enter the pelvis beneath Poupart's ligament, where they lie in close relation with the femoral vein; they then pass through the chain of glands surrounding the external iliac vessels, and finally terminate in the lumbar glands. They receive the deep epigastric and circumflex iliac lymphatics.

The **lymphatics of the bladder** arise from the entire surface of the organ;[1] the greater number run beneath the peritoneum on its posterior surface, and, after passing through the lymphatic glands in that situation, join with the lymphatics from the prostate and vesiculæ seminales and enter the internal iliac glands.

The **lymphatics of the rectum** are of large size; after passing through some small glands that lie upon its outer wall and in the mesorectum they pass to the sacral glands.

The **lymphatics of the uterus** consist of two sets, superficial and deep, the former being placed beneath the peritoneum, the latter in the substance of the organ. The lymphatics of the cervix uteri, together with those from the vagina, enter the internal iliac and sacral glands; those from the body and fundus of the uterus pass outward in the broad ligaments, and, being joined by the lymphatics from the ovaries, broad ligaments, and Fallopian tubes, ascend with the ovarian vessels to open into the lumbar glands. In the unimpregnated uterus they are small, but during gestation they become very greatly enlarged.

The **lymphatics of the testicle** consist of two sets, superficial and deep: the former commence on the surface of the tunica vaginalis, the latter in the epididymis and body of the testis. They form several large trunks, which ascend with the spermatic cord, and, accompanying the spermatic vessels into the abdomen, open into the lumbar glands, hence the enlargement of these glands in malignant disease of the testis.

The **lymphatics of the kidney** arise on the surface and also in the interior of the organ; they join at the hilum, and, after receiving the lymphatic vessels from the ureter and suprarenal capsules, open into the lumbar glands.

The **lymphatics of the liver** are divisible into two sets, superficial and deep. The former arise in the subperitoneal areolar tissue over the entire surface of the organ. Those on the convex surface may be divided into four groups: 1, those which pass from behind forward, consisting of three or four branches, which ascend in the longitudinal ligament and unite to form a single trunk, which passes up between the fibres of the diaphragm, behind the ensiform cartilage, to enter the anterior mediastinal glands, and finally ascends to the root of the neck, to terminate in the right lymphatic duct; 2, another group, which also incline from behind forward, are reflected over the anterior margin of the liver to its under surface, and from thence pass along the longitudinal fissure to the glands in the gastro-hepatic omentum; 3, a third group incline outward to the right lateral ligament, and, uniting into one or two large trunks, pierce the diaphragm, and run along its upper surface to enter the anterior mediastinal glands; or, instead of entering the thorax, turn inward across the crus of the diaphragm and open into the commencement of the thoracic duct; 4, the fourth group incline outward from the surface of the left lobe of the liver to the left lateral ligament, pierce the diaphragm, and, passing forward, terminate in the glands in the anterior mediastinum.

The *superficial lymphatics on the under surface of the liver* are divided into three sets: 1, those on the right side of the gall-bladder enter the lumbar glands; 2, those surrounding the gall-bladder form a remarkable plexus: they accompany the hepatic vessels and open into the glands in the gastro-hepatic omentum; 3, those on the left of the gall-bladder pass to the œsophageal glands and to the glands which are situated along the lesser curvature of the stomach.

---

[1] Curnow states that they are confined to the base of the organ.

The *deep lymphatics* accompany the branches of the portal vein and the hepatic artery and duct through the substance of the liver; passing out at the transverse fissure, they enter the lymphatic glands along the lesser curvature of the stomach and behind the pancreas, or join with one of the lacteal vessels previous to its termination in the thoracic duct.

The **lymphatic glands of the stomach** are of small size; they are placed along the lesser and greater curvatures, some within the gastro-splenic omentum, whilst others surround the cardiac and pyloric orifices.

The **lymphatics of the stomach** consist of two sets, superficial and deep, the former originating in the subserous, and the latter in the submucous-coat. They follow the course of the blood-vessels, and may consequently be arranged into three groups. The *first group* accompany the gastric vessels along the lesser curvature, receiving branches from both surfaces of the organ, and pass to the glands around the pylorus. The *second group* pass from the great end of the stomach, accompanying the vasa brevia, and enter the splenic lymphatic glands. The *third group* run along the greater curvature with the right gastro-epiploic vessels, and terminate at the root of the mesentery in one of the principal lacteal vessels.

The **lymphatic glands of the spleen** occupy the hilum. Its *lymphatic vessels* consist of two sets, superficial and deep; the former are placed beneath its peritoneal covering, the latter in the substance of the organ: they accompany the blood-vessels, passing through a series of small glands, and after receiving the lymphatics from the pancreas ultimately pass into the thoracic duct.

THE LYMPHATIC SYSTEM OF THE INTESTINES.

The **lymphatic glands of the small intestine** are placed between the layers of the mesentery, occupying the meshes formed by the superior mesenteric vessels, and hence called **mesenteric glands**. They vary in number from a hundred to a hundred and fifty, and in size from that of a pea to that of a small almond. These glands are most numerous and largest above near the duodenum, and below opposite the termination of the ileum in the colon. This latter group becomes enlarged and infiltrated with deposit in cases of fever accompanied with ulceration of the intestines.

The **lymphatic glands of the large intestine** are much less numerous than the mesenteric glands; they are situated along the vascular arches formed by the arteries previous to their distribution, and even sometimes upon the intestine itself. They are fewest in number along the transverse colon, where they form an uninterrupted chain with the mesenteric glands.

The **lymphatics of the small intestine** are called **lacteals**, from the milk-white fluid they usually contain. They consist of two sets, superficial and deep: the former lie between the layers of the muscular coat and between the muscular and peritoneal coats, taking a longitudinal course along the outer side of the intestine; the latter occupy the submucous tissue, and course transversely around the intestine, accompanied by the branches of the mesenteric vessels: they pass between the layers of the mesentery, enter the mesenteric glands, and finally unite to form two or three large trunks which terminate in the thoracic duct.

The **lymphatics of the large intestine** consist of two sets: those of the cæcum, ascending and transverse colon, which, after passing through their proper glands, enter the mesenteric glands; and those of the descending colon and rectum, which pass to the lumbar glands.

THE LYMPHATICS OF THE THORAX.

The **deep lymphatic glands of the thorax** are the intercostal, internal mammary, anterior mediastinal, and posterior mediastinal.

The **intercostal glands** are small, irregular in number, and situated on each side of the spine near the costo-vertebral articulations, some being placed between the two planes of Intercostal muscles.

The **internal mammary glands** are placed at the anterior extremity of each intercostal space by the side of the internal mammary vessels.

The **anterior mediastinal glands** are placed in the loose areolar tissue of the anterior mediastinum, some lying upon the Diaphragm in front of the pericardium, and others around the great vessels at the base of the heart.

The **posterior mediastinal glands** are situated in the areolar tissue in the posterior mediastinum, forming a continuous chain by the side of the aorta and œsophagus; they communicate on each side with the intercostal, below with the lumbar, and above with the deep cervical glands.

The **superficial lymphatics of the front of the thorax** run across the great Pectoral muscle, and those on the back part of this cavity lie upon the Trapezius and Latissimus dorsi; they all converge to the axillary glands. The lymphatics from the greater part of the mammary gland pass outward to the lower border of the Pectoralis major muscle, where they enter a chain of small glands situated in the axillary space along the lower border of its anterior boundary. Some few lymphatics from the inner side of the mammary gland pass through the intercostal spaces to reach the anterior mediastinal glands.

The **deep lymphatics of the thorax** are the intercostal, internal mammary, and diaphragmatic.

The **intercostal lymphatics** follow the course of the intercostal vessels, receiving lymphatics from the intercostal muscles and pleura; they pass backward to the spine, and unite with lymphatics from the back part of the thorax and spinal canal. After traversing the intercostal glands they incline down the spine and terminate in the thoracic duct.

The **internal mammary lymphatics** follow the course of the internal mammary vessels; they commence in the muscles of the abdomen above the umbilicus, communicating with the epigastric lymphatics, ascend between the fibres of the Diaphragm at its attachment to the ensiform appendix, and in their course behind the costal cartilages are joined by the intercostal lymphatics; they terminate on the right side in the right lymphatic duct, on the left side in the thoracic duct.

The **lymphatics of the Diaphragm** follow the course of their corresponding vessels, and terminate, some in front in the anterior mediastinal and internal mammary glands, some behind in the intercostal and posterior mediastinal lymphatics.

The **bronchial glands** are situated around the bifurcation of the trachea and roots of the lungs. They are ten or twelve in number, the largest being placed opposite the bifurcation of the trachea, the smallest round the bronchi, and their primary divisions for some little distance within the substance of the lungs. In infancy they present the same appearance as lymphatic glands in other situations; in the adult they assume a brownish tinge, and in old age a deep-black color. Occasionally they become sufficiently enlarged to compress and narrow the canal of the bronchi, and they are often the seat of tubercle or cretaceous deposits.

The **lymphatics of the lung** consist of two sets, superficial and deep: the former are placed beneath the pleura, forming a minute plexus which covers the outer surface of the lung; the latter accompany the blood-vessels and run along the bronchi: they both terminate at the root of the lungs in the bronchial glands. The efferent vessels from these glands, two or three in number, ascend upon the trachea to the root of the neck, traverse the tracheal and œsophageal glands, and terminate on the left side in the thoracic duct and on the right side in the right lymphatic duct.

The **cardiac lymphatics** consist of two sets, superficial and deep: the former arise in the subserous areolar tissue of the surface, and the latter in the deeper tissues of the heart. They follow the course of the coronary vessels: those of the right side unite into a trunk at the root of the aorta, which, ascending across the arch of that vessel, passes backward to the trachea, upon which it ascends, to terminate at the root of the neck in the right lymphatic duct. Those of the left side unite into a single vessel at the base of the heart, which, passing along the pulmonary artery and traversing some glands at the root of the aorta, ascends on the trachea to terminate in the thoracic duct.

The **thymic lymphatics** arise from the spinal surface of the thymus gland and terminate on each side in the internal jugular veins.

The **thyroid lymphatics** arise from either lateral lobe of this organ; they converge to form a short trunk, which terminates on the right side in the right lymphatic duct, on the left side in the thoracic duct.

The **lymphatics of the œsophagus** form a plexus around that tube, traverse the glands in the posterior mediastinum, and, after communicating with the pulmonary lymphatic vessels near the roots of the lungs, terminate in the thoracic duct.

The Nervous System.

THE **Nervous System** is composed—1, of a series of large centres of nerve-matter, called, collectively, the *cerebro-spinal centre* or *axis;* 2, of smaller centres, termed *ganglia;* 3, of *nerves*, connected either with the cerebro-spinal axis or the ganglia; and 4, of certain modifications of the peripheral terminations of the nerves forming the organs of the external senses.

The **Cerebro-spinal Centre** consists of two parts, the spinal cord and the encephalon: the latter may be subdivided into the cerebrum, the cerebellum, the pons Varolii, and the medulla oblongata.

THE SPINAL CORD AND ITS MEMBRANES.

Dissection.—To dissect the cord and its membranes it will be necessary to lay open the whole length of the spinal canal. For this purpose the muscles must be separated from the vertebral grooves, so as to expose the spinous processes and laminæ of the vertebræ, and the latter must be sawn through on each side, close to the roots of the transverse processes, from the third or fourth cervical vertebra above to the sacrum below. The vertebral arches having been displaced by means of a chisel and the separate fragments removed, the dura mater will be exposed, covered by a plexus of veins and a quantity of loose areolar tissue, often infiltrated with serous fluid. The arches of the upper vertebræ are best divided by means of a strong pair of cutting bone-forceps.

MEMBRANES OF THE CORD.

The membranes which envelop the spinal cord are three in number. The most external is the *dura mater*, a strong fibrous membrane which forms a loose sheath around the cord. The most internal is the *pia mater*, a cellulo-vascular membrane which closely invests the entire surface of the cord. Between the two is the *arachnoid* membrane, an intermediate structure which envelops the cord and is connected to the pia mater by slender filaments of connective tissue.

The **Dura Mater** of the cord, continuous with that which invests the brain, is a loose sheath which surrounds the cord, and is separated from the bony walls of the spinal canal by a quantity of loose areolar adipose tissue and a plexus of veins. It is attached to the circumference of the foramen magnum and to the posterior common ligament throughout the whole length of the spinal canal by fibrous slips, and extends below as far as the top of the sacrum; but beyond this point it is impervious, being continued in the form of a slender cord to the back of the coccyx, where it blends with the periosteum. This sheath is much larger than is necessary for its contents, and its size is greater in the cervical and lumbar regions than in the dorsal. Its inner surface is smooth, covered by a layer of polygonal cells; and on each side may be seen the double openings which transmit the two roots of the corresponding spinal nerve, the fibrous layer of the dura mater being continued in the form of a tubular prolongation on them as they issue from these apertures. These prolongations of the dura mater are short in the upper part of the spine, but become gradually longer below, forming a number of tubes of fibrous membrane which enclose the sacral nerves and are contained in the spinal canal.

The chief peculiarities of the dura mater of the cord, as compared with that investing the brain, are the following:

The dura mater of the cord is not adherent to the bones of the spinal canal, which have an independent periosteum.

It does not send partitions into the fissures of the cord, as in the brain.

Its fibrous laminæ do not separate to form venous sinuses, as in the brain.

Structure.—The dura mater consists of white fibrous and elastic tissue arranged in bands or lamellæ which, for the most part, are parallel with one another. It is sparingly supplied with vessels, and some few nerves have been traced into it.

The **Arachnoid** is exposed by slitting up the dura mater and reflecting that membrane to either side (Fig. 429). It is a thin, delicate, tubular membrane which invests the surface of the cord and is connected to the pia mater by slender filaments of connective tissue. Above it is continuous with the cerebral arachnoid; on either side it is continued on the various nerves so as to form a sheath for them as they pass outward to the intervertebral foramina. The outer surface of the arachnoid is in contact with the inner surface of the dura mater, and the two are here and there connected together by isolated connective-tissue trabeculæ, especially on the posterior surface of the cord. For the most part, however, the membranes are not connected together, and the interval between them is named the *subdural space.* The inner surface of the arachnoid is separated from the pia mater by a considerable interval, which is called the *subarachnoidean space.*[1] This space is largest at the lower part of the spinal canal, and encloses the mass of nerves which form the cauda equina. It contains an abundant serous secretion, the *cerebro-spinal* [or *cephalo-rachidian*] *fluid*, and usually communicates with the general ventricular cavity of the brain by means of an opening in the pia mater at the inferior boundary of the fourth ventricle (*foramen of Majendie*). This secretion is sufficient in amount to expand the arachnoid membranes so as to completely fill up the whole of the space included in the dura mater. The subarachnoidean space is crossed at the back part of the cord by numerous fibrous bands which stretch from the arachnoid to the pia mater, especially in the cervical region, and is partially subdivided by a longitudinal membranous partition which serves to connect the arachnoid with the pia mater opposite the posterior median fissure. This partition is incomplete and cribriform in structure, consisting of bundles of white fibrous tissue interlacing with each other.[2] [These spaces around the cord are really lymph-spaces.]

FIG. 429.

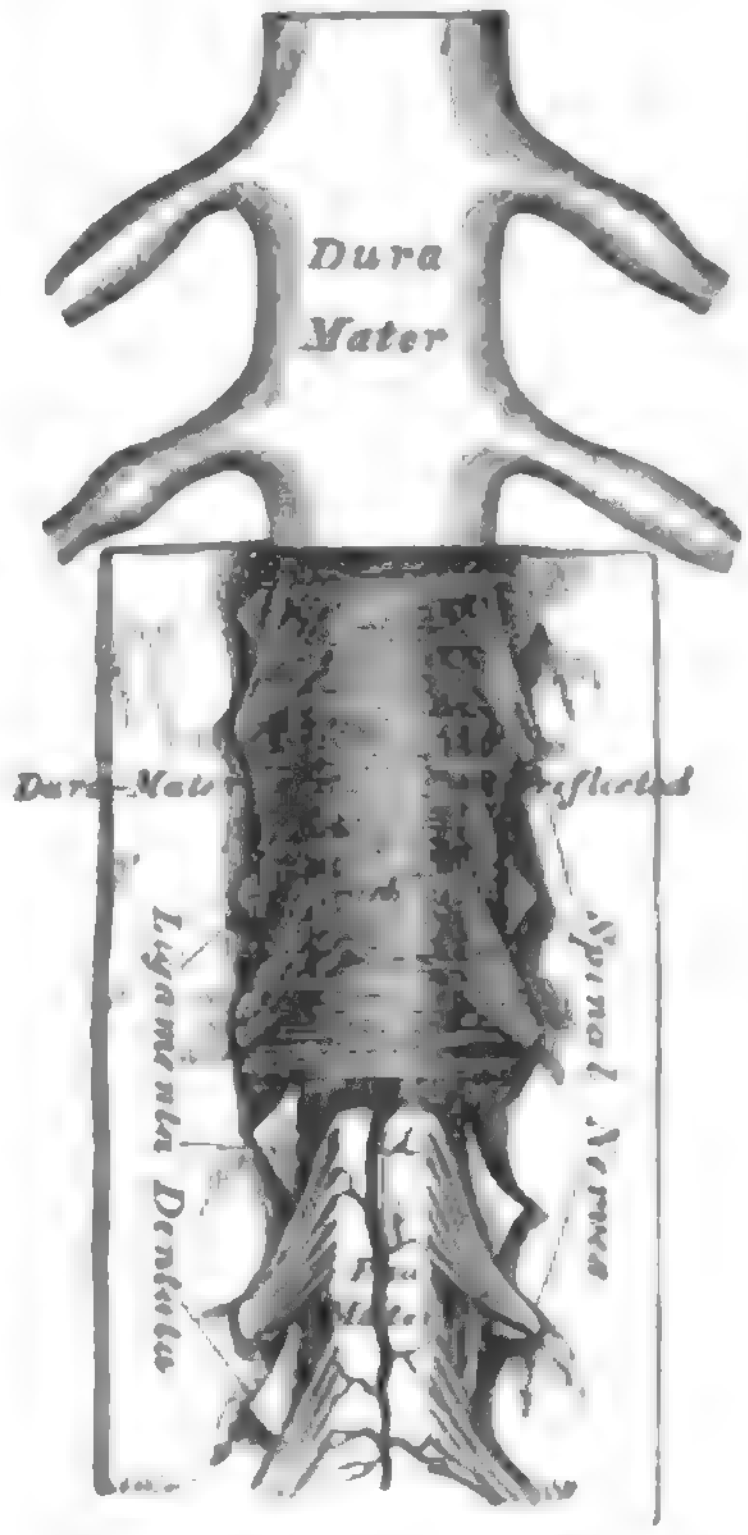

The Spinal Cord and its Membranes.

FIG. 430.



Transverse Section of the Spinal Cord and its Membranes.

Structure.—The arachnoid is a delicate membrane made up of closely-arranged parallel bundles of connective tissue, covered on the outer or dural surface by one or two layers of endothelial cells. The inner surface is also covered with an endothelium, and gives off a spongy network of trabeculæ of fibrous tissue, the surfaces of which are covered with endothelium and which stretch across between the arachnoid and pia mater. This spongy tissue is named *subarachnoid tissue* (Retzius and Key).

---

[1] [This mixture of Latin and Greek is an unfortunate barbarism of language, like "subdermal" for "hypodermic," but is probably too firmly intrenched to be dislodged. The proper term is "hypo-arachnoidean."]

[2] It will be noticed that this description of the arachnoid varies from that in former editions, which described this membrane as a closed sac, one layer of which, the *visceral layer*, ensheathed the cord, and the other, the *parietal layer*, was reflected over the inner surface of the dura mater. The space between the two layers was termed the "cavity of the arachnoid," and corresponded to the "subdural" space in the above description. Kölliker was the first to deny that the inner surface of the dura mater was covered by an outer layer of the arachnoid; he states that nothing is found here except epithelium, no trace of a special membrane existing. This view is now very generally adopted by anatomists, and appears to have derived additional confirmation from the investigations of Retzius and Axel Key, who state that the connection which was formerly described as taking place between the two layers of the arachnoid as they were prolonged in the form of a tubular sheath over the nerves does not exist. The same remark applies to the arachnoid membrane of the brain, which is no longer regarded as a closed sac. (See p. 663.)

The **Pia Mater** of the cord is exposed on the removal of the arachnoid (Fig. 429). It covers the entire surface of the cord, to which it is very intimately adherent, forming its neurilemma, and sends a process downward into its anterior fissure, and another, extremely delicate, into the posterior fissure. It also forms a sheath for each of the filaments of the spinal nerves, and invests the nerves themselves. A longitudinal fibrous band extends along the middle line on its anterior surface, called by Haller the *linea splendens;* and a somewhat similar band, the *ligamentum denticulatum*, is situated on each side. At the point where the cord terminates the pia mater becomes contracted, and is continued down as a long, slender filament (*filum terminale*), which descends through the centre of the mass of nerves forming the cauda equina, and is blended with the impervious sheath of dura mater on a level with the top of the sacral canal. It assists in maintaining the cord in its position during the movements of the trunk, and is from this circumstance called the central ligament of the spinal cord. It contains a little gray nervous substance which may be traced for some distance into its upper part, and is accompanied by a small artery and vein.

Structure.—The pia mater of the cord is less vascular in structure, but thicker and denser than the pia mater of the brain, with which it is continuous. It is composed of bundles of connective-tissue fibres arranged for the most part longitudinally. It is usually described as consisting of two layers, between which are a number of lymphatic spaces, which communicate with the subarachnoid space and in which the vessels ramify. It is also supplied with nerves, which are derived from the sympathetic and from the posterior roots of the spinal nerves. At the upper part of the cord the pia mater presents a grayish, mottled tint, which is owing to yellow or brown pigment-cells scattered among the elastic fibres.

The *Ligamentum Denticulatum* (Fig. 429) is a narrow fibrous band situated on each side of the spinal cord throughout its entire length, and separating the anterior from the posterior roots of the spinal nerves, having received its name from the serrated appearance which it presents. Its inner border is continuous with the pia mater at the side of the cord. Its outer border presents a series of triangular, dentated serrations, the points of which are fixed at intervals to the dura mater. These serrations are about twenty in number on each side, the first being attached to the dura mater, opposite the margin of the foramen magnum, between the vertebral artery and the hypoglossal nerve, and the last near the lower end of the cord. Its use is to support the cord in the fluid by which it is surrounded.

THE SPINAL CORD.

The **Spinal Cord** (*medulla spinalis*) is the cylindrical elongated part of the cerebro-spinal axis which is contained in the vertebral canal. Its length is usually about seventeen or eighteen inches, and its weight, when divested of its membranes and nerves, about one ounce and a half, its proportion to the encephalon being about 1 to 33. It does not nearly fill the canal in which it is contained, its investing membranes being separated from the surrounding walls by areolar tissue and a plexus of veins. It occupies, in the adult, the upper two-thirds of the vertebral canal, extending from the upper border of the atlas to the lower border of the body of the first lumbar vertebra, where it terminates in a slender filament of gray substance, which is continued for some distance into the *filum terminale*. In the fœtus, before the third month, it extends to the bottom of the sacral canal, but after this period it gradually recedes from below, as the growth of the bones composing the canal is more rapid in proportion than that of the cord, so that in the child at birth the cord extends as far as the third lumbar vertebra. Its position varies also according to the degree of curvature of the spinal column, being raised somewhat in flexion of the spine. On examining its surface it presents a difference in its diameter in different parts, being marked by two enlargements, an upper or cervical and a lower or lumbar. The cervical enlargement, which is the larger, extends from about the third cervical to the first or second dorsal vertebra: its greatest diameter is in the transverse direction, and it corresponds with the origin of the nerves which supply the upper extremities. The lower or lumbar enlargement is situated opposite the last two or three dorsal vertebræ, its greatest diameter being from before backward. It corresponds with the origin of the nerves which supply the lower extremities. In form the spinal cord is a flattened cylinder. It presents on its anterior surface, along the middle line, a longitudinal fissure, the *anterior median fissure;* and on its posterior surface another fissure, which also extends along the entire length of the cord, the *posterior median fissure.* These fissures serve to divide the cord into two symmetrical halves, which are united in the middle line, throughout their entire length, by a transverse band of nervous substance, the *commissure.*

The **Anterior Median Fissure** is wider but of less depth than the posterior, extending into the cord for about one-third of its thickness, and is deepest at the lower part of the cord. It contains a prolongation from the pia mater, and its floor is formed by the *anterior white commissure,* which is perforated by numerous blood-vessels passing to the centre of the cord.

FIG. 431.

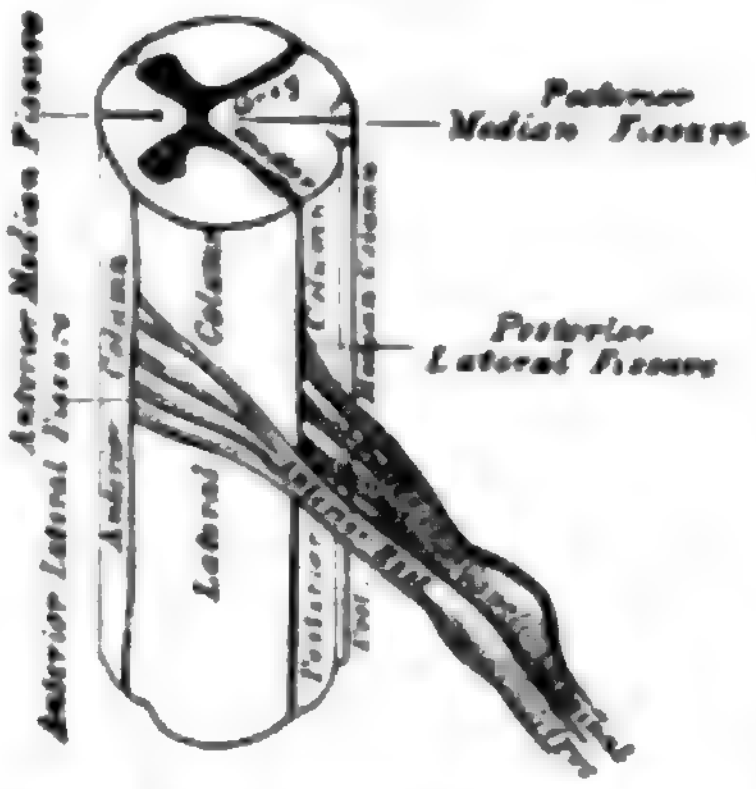

Spinal Cord, side view—plan of the Fissures and Columns.

The **Posterior Median Fissure** is not an actual fissure, as the space between the lateral halves of the posterior part of the cord is filled up by connective tissue and numerous blood-vessels, so that no actual hiatus exists, and there is consequently no prolongation of the pia mater into it. It extends into the cord to about one half its depth, and its floor is formed by the *posterior gray commissure.*

Lateral Fissures.—On either side of the anterior median fissure a linear series of foramina may be observed, indicating the points where the anterior roots of the spinal nerves emerge from the cord. This is called by some anatomists the *antero-lateral fissure* of the cord, although no actual fissure exists in this situation. And on either side of the posterior median fissure, along the line of attachment of the posterior roots of the nerves, a delicate fissure may be seen leading down to the gray matter, which approaches the surface in this situation; this is called the *postero-lateral fissure* of the spinal cord. On the posterior surface of the spinal cord, on either side of the posterior median fissure, is a slight longitudinal furrow marking off two slender tracts, the *posterior median columns.* These are most distinct in the cervical region, but are stated by Foville to exist throughout the whole length of the cord.

Columns of the Cord.—The fissures divide each half of the spinal cord into four columns: an anterior column, a lateral column, a posterior column, and a posterior median column.

The *anterior column* includes all the portion of the cord between the anterior median fissure and the antero-lateral fissure from which the anterior roots of the nerves arise. It is continuous with the anterior pyramid of the medulla oblongata.

The *lateral column,* the largest segment of the cord, includes all the portion between the antero- and postero-lateral fissures. It is continuous with the lateral column of the medulla. By some anatomists the anterior and lateral columns are included together under the name of the antero-lateral column, which forms rather more than two-thirds of the entire circumference of the cord.

The *posterior column* is situated between the posterior median and postero-lateral fissures. It is continuous with the restiform body of the medulla.

The *posterior median column* is that narrow segment of the cord which is seen on each side of the posterior median fissure, usually included with the preceding as the posterior column.

Structure of the Cord.—If a transverse section of the spinal cord be made, it will be seen to consist of white and gray nervous substance. The white matter is situated externally, and constitutes the greater part. The gray substance occupies the centre, and is so arranged as to present on the surface of the section two crescentic masses placed one in each lateral half of the cord, united together by a transverse band of gray matter, the *gray commissure.* Each crescentic mass has an anterior and posterior horn. The posterior horn is long and narrow, and approaches the surface of the postero-lateral fissure, near which it presents a slight enlargement, the *caput cornu:* from this it tapers to form the *apex cornu,* which at the surface of the cord becomes continuous with the fibres of the posterior roots of the spinal nerves. The anterior horn is short and thick, and does not quite reach the surface, but extends toward the point of attachment of the anterior roots of the nerves. Its margin presents a dentate or stellate appearance. Owing to the projections toward the surface of the anterior and posterior horns of the gray matter, each half of the cord is divided, more or less completely, into three columns, anterior, middle, and posterior, the anterior and middle being joined to form the antero-lateral column, as the anterior horn does not quite reach the surface.

Fig. 432.



Opposite Middle of Cervical Region.



Opposite Middle of Dorsal Region.

Opposite Lumbar Region.

Transverse Sections of the Cord.

The *gray commissure,* which connects the two crescentic masses of gray matter, is separated from the bottom of the anterior median fissure by the anterior white commissure. It consists of transverse fibres, with a considerable quantity of neuroglia between them. The fibres when they reach the lateral crescents diverge: some pass backward to the posterior roots, others spread out, at various angles, into the cervix cornu. The *anterior* [white] *commissure* is formed of fibres which pass horizontally between the gray matter of the anterior horn of one side and the anterior white column of the opposite side.

Running through the gray commissure of the whole length of the cord is a minute canal which is barely visible to the naked eye in the human cord, but is proportionately larger in some of the lower Vertebrata. It is called the *central canal* (Fig. 433) and opens above into the fourth ventricle, and terminates below in a somewhat dilated extremity. [This "central canal" is the spinal analogue of the cerebral ventricles, and might well be called the "sixth ventricle" or the "ventricle of the cord."]

The mode of arrangement of the gray matter, and its amount in proportion to the white, vary in different parts of the cord. Thus, the posterior horns are long and narrow in the cervical region, short and narrower in the dorsal, short but wider in the lumbar region. In the cervical region the crescentic portions are small, and the white matter more abundant than in any other region of the cord. In the dorsal region the gray matter is least developed, the white matter being also small in quantity. In the lumbar region the gray matter is more abundant than in any other region of the cord. Toward the lower end of the cord the white matter gradually ceases. The crescentic portions of the gray matter soon blend into a single mass which forms the only constituent of the extreme point of the cord.

Minute Anatomy of the Cord.—The cord consists of an outer part, composed of medullated nerve-fibres, which is the *white substance,* and of a central part, the *gray matter,* both supported in a peculiar kind of connective tissue called *neuroglia.*

The **neuroglia** consists of a homogeneous transparent matrix of a network of very delicate fibrillæ, and of small stellate or branched cells, the neuroglia-cells.

In addition to forming a ground substance, in which the nerve-fibres, nerve-cells, and blood-vessels are imbedded, a considerable accumulation takes place in three situations: 1, on the surface of the cord, beneath the pia mater; 2, around the central canal; and 3, in the posterior part of the posterior horn, forming the substantia cinerea gelatinosa.

The **white substance** of the cord consists of medullated nerve-fibres, with blood-vessels and neuroglia. On transverse section of the white substance of the cord a very striking object is presented. It is seen to be studded all over with minute dots, surrounded by a white area, and this again by a dark circle (Fig. 438). This is due to the longitudinal medullated fibres seen on section. The dot is the axis-cylinder, the white area the substance of Schwann, and the dark circle the tubular membrane of the fibres, which seems to consist of several laminæ. Externally, the neuroglia is seen to form a delicate connective sheath around the outer surface of the cord immediately beneath the pia mater, from which numerous septa pass in to separate the respective bundles of fibres and extend between the individual nerve-fibres, acting as a supporting medium in which they are imbedded. Thus it will be seen that the greater bulk of the white matter of the cord is made up of longitudinal medullated fibres, which are arranged in groups forming the anterior, lateral, and posterior columns.

FIG. 433.

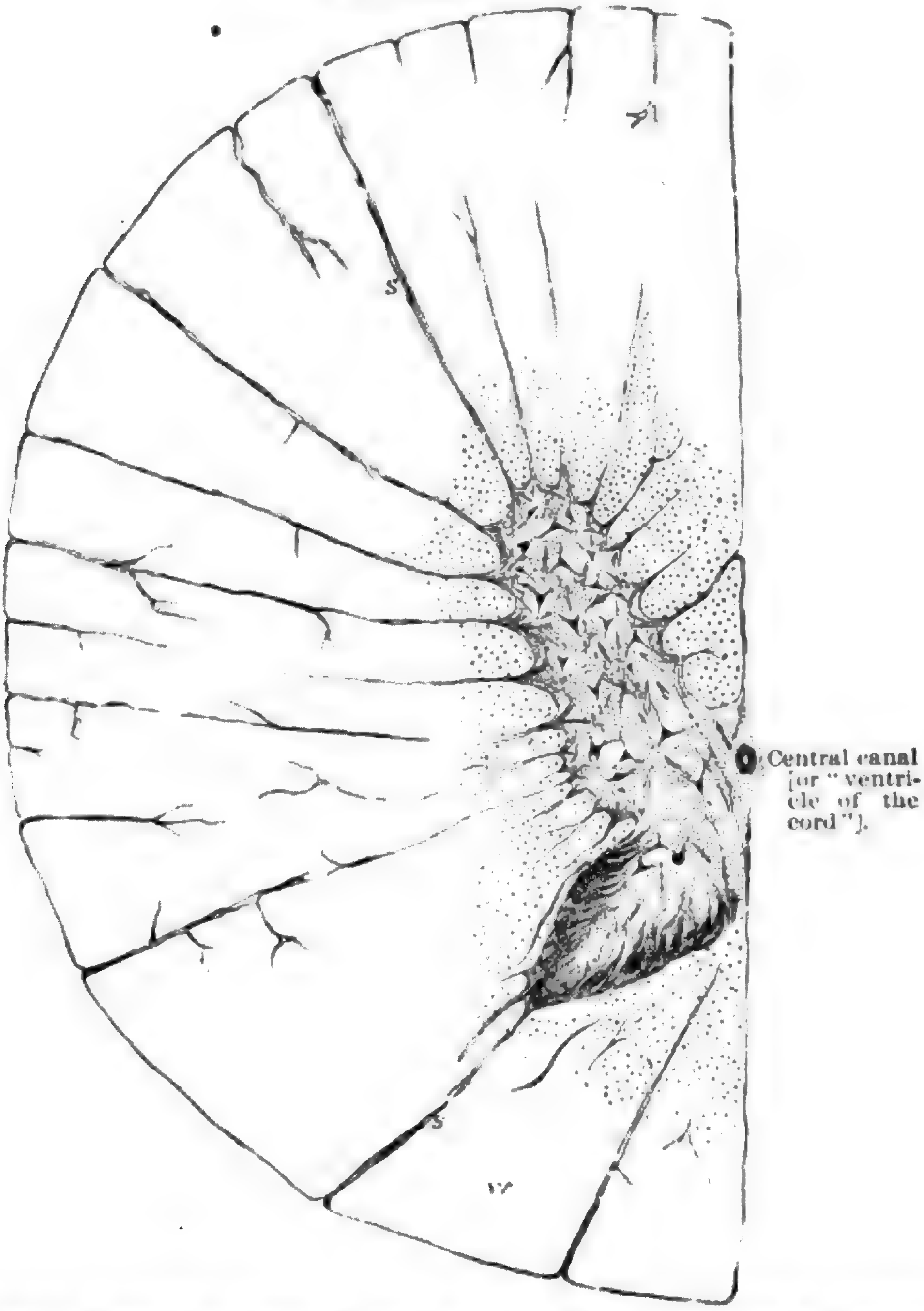

Transverse Section through the Cervical Portion of the Spinal Cord of a Calf (magnified 40 diameters—Klein and Noble Smith): *w*, the white matter of the cord, subdivided by septa of connective tissue, *s*, extending from the pia mater to the gray matter, which is seen in the interior with its ganglion-cells. The dots around this show divided nerve-fibres, which exist, but are not shown, in the other parts of the white substance. The central canal is seen in the gray matter.

There are, however, also oblique and transverse fibres in the white substance. These are principally found (1) at the bottom of the anterior median fissure, forming the anterior commissure, the fibres passing from the gray matter of the anterior horn on one side to the white matter of the anterior column of the opposite side: (2) horizontal or oblique fibres passing from the roots of the nerves into the gray matter; and (3) fibres leaving the gray matter and pursuing a longer or shorter horizontal course between the bundles of longitudinal fibres with which many of them are continuous.

The primary *septa* sent into the substance of the cord from the neuroglia on the surface are accompanied by prolongations of the pia mater, and pass in a radiating manner into the white substance and divide it up into a number of smaller portions or *columns*, which can be traced upward and are continuous with different columns of the medulla oblongata. Thus, on either side of the anterior median fissure a portion of the anterior column is divided off as the *direct pyramidal fasciculus*, which can be traced upward in continuity with the non-decussating fibres of the pyramidal column of the medulla. The remainder of the anterior column of the cord forms the *fundamental fasciculus*, which is continued into the deeper part of the medulla. The lateral column of the cord is divided into four tracts, the anterior division of which is called the *anterior radicular zone*, the peripheral portion of the posterior part the *cerebellar column*, and the internal part, next the gray substance, is termed the *mixed lateral column*, whilst an intermediate portion, between these last two, is the *fasciculus of Türck*, or the crossed portion of the pyramidal fasciculus, its fibres when traced upward forming the decussating portion of the anterior pyramidal tract of the medulla oblongata. The other three portions of the lateral column can be traced into the *lateral tract* of the medulla, the peripheral fibres, or those forming the cerebellar column, passing through it to the cerebellum.

FIG. 434.

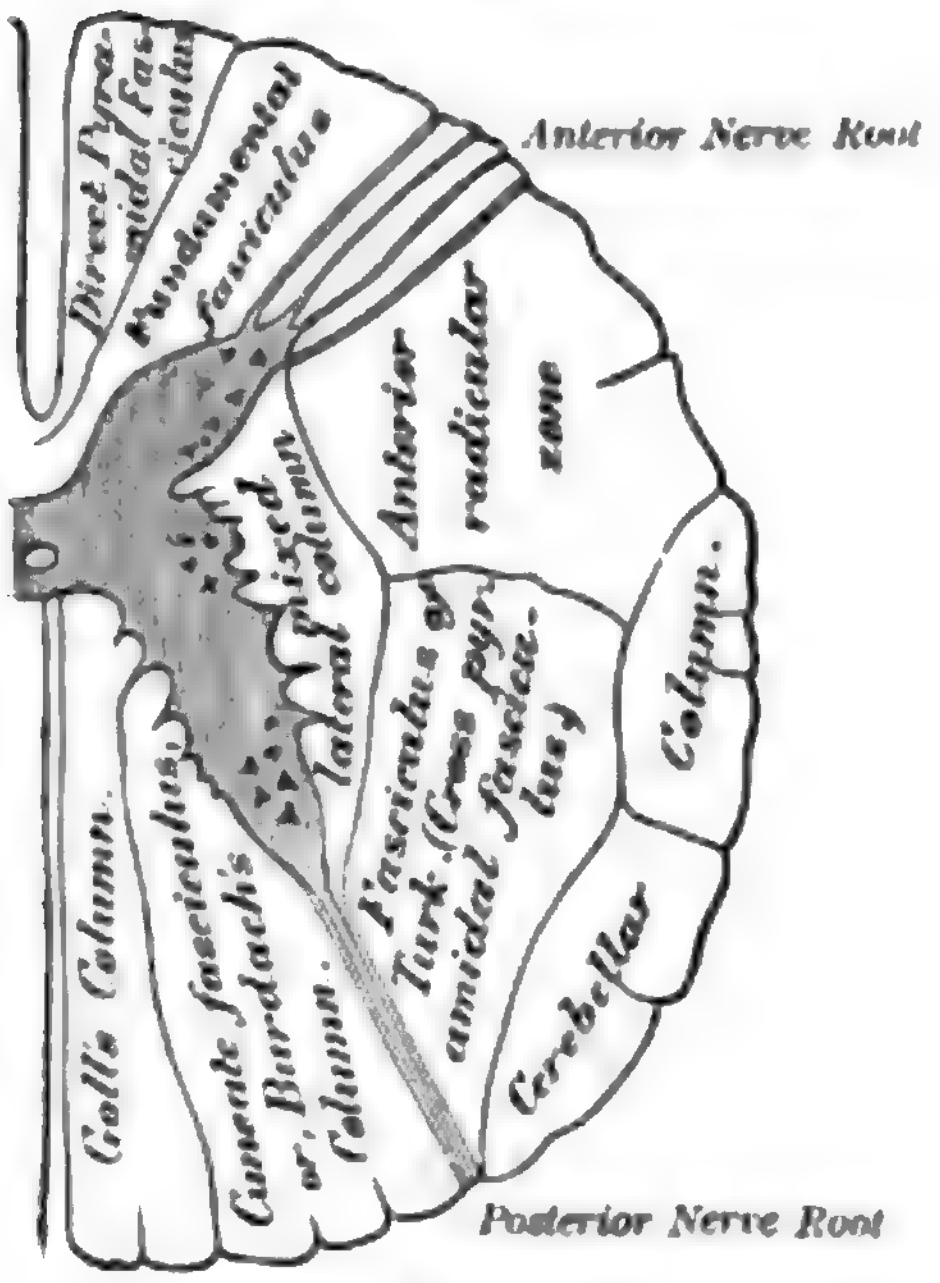
Direct Pyramidal Fasciculus
Fundamental fasciculus
Anterior Nerve Root
Anterior radicular zone
Mixed lateral column
Fasciculus of Türk (Crossed pyramidal fasciculus)
Column.
Cerebellar
Goll's Column.
Cuneate fasciculus, or, Burdach's Column.
Posterior Nerve Root

Columns of the Cord.

FIG. 435.

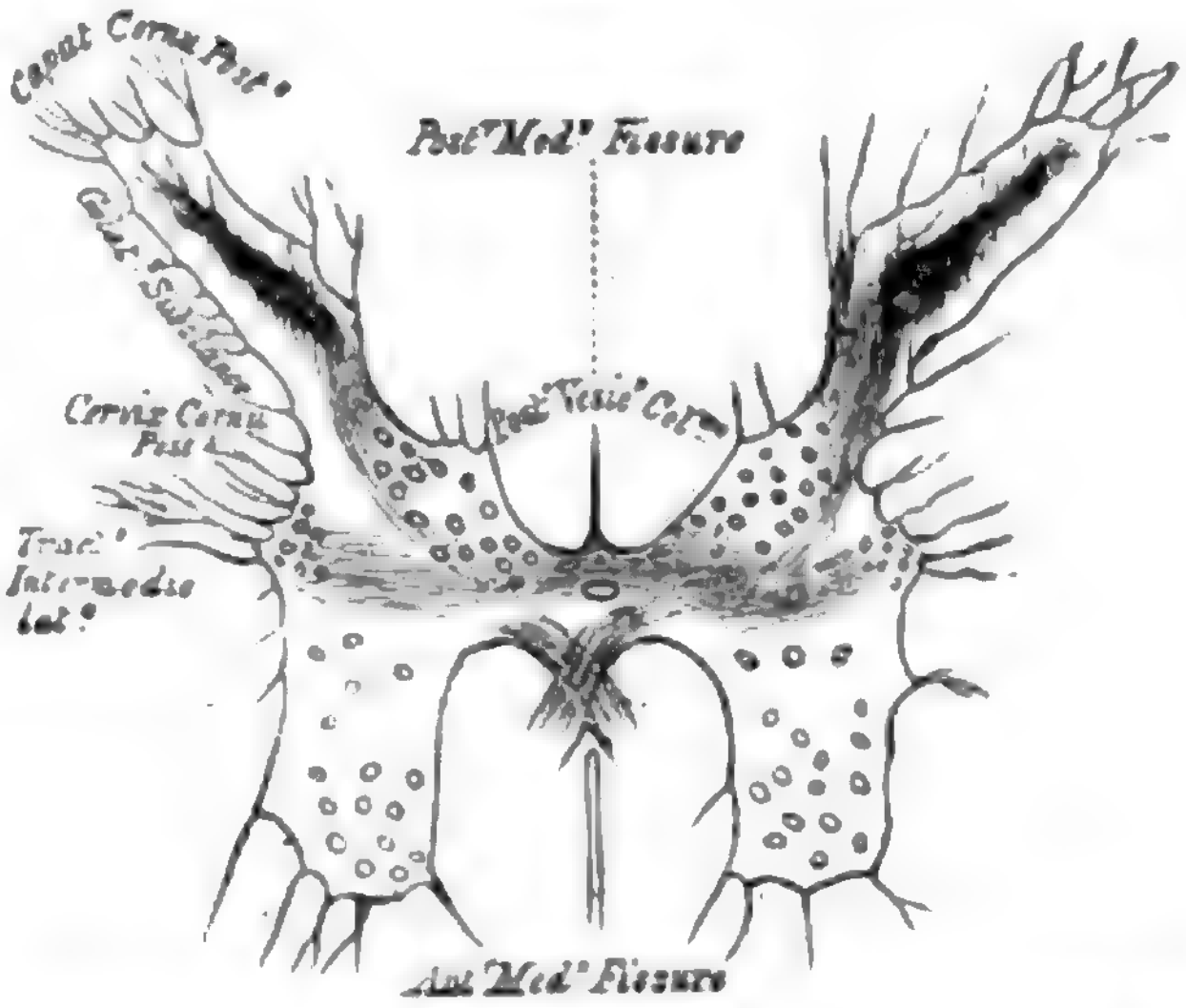
Caput Cornu Post.
Post. Med. Fissure
Gelat. Substance
Post. Vesic. Col.
Cervix Cornu Post.
Tract. Intermedio lat.
Ant. Med. Fissure

Transverse Section of the Gray Substance of the Spinal Cord, near the middle of the dorsal region (magnified 13 diameters—J. L. Clarke *del.*).

The posterior column of the cord is divided into two: the portion which lies next the posterior median fissure is called the *column of Goll*, and if traced upward is found to be continuous with the fasciculus gracilis of the medulla. The remainder of the posterior column is called the *cuneate fasciculus* or *Burdach's column*, and is prolonged into the medulla under the same name.

The gray substance of the cord occupies its central part in the shape of two crescentic horns joined together by a commissure. Each of these crescents has an anterior and a posterior cornu.

The *posterior horn* consists of two parts—the *caput cornu*, or expanded extremity of the horn (Fig. 436), round which is a lighter space or lamina of gelatinous substance; and the *cervix cornu*, or narrower portion, which connects it with the rest of the gray substance.

The gelatinous substance is a peculiar accumulation of neuroglia (Klein), and has been named by Rolando the *substantia cinerea gelatinosa*.

The *anterior horn* of the gray substance in the cervical and lumbar swellings, where it gives origin to the nerves of the extremities, is much larger than in any other region, and contains several distinct groups of large and variously shaped cells.

The gray commissure is situated behind the white commissure, which separates it from the bottom of the anterior median fissure. In it is a central canal lined by epithelium, around which is a layer of neuroglia of considerable thickness, the *central gray nucleus* of Kölliker. The gray substance of the cord consists of—1. nerve-fibres of variable but smaller average diameter than those of the columns; 2. nerve-cells of various shapes and sizes, with from two to eight processes; 3. blood-vessels and connective tissue.

FIG. 436.

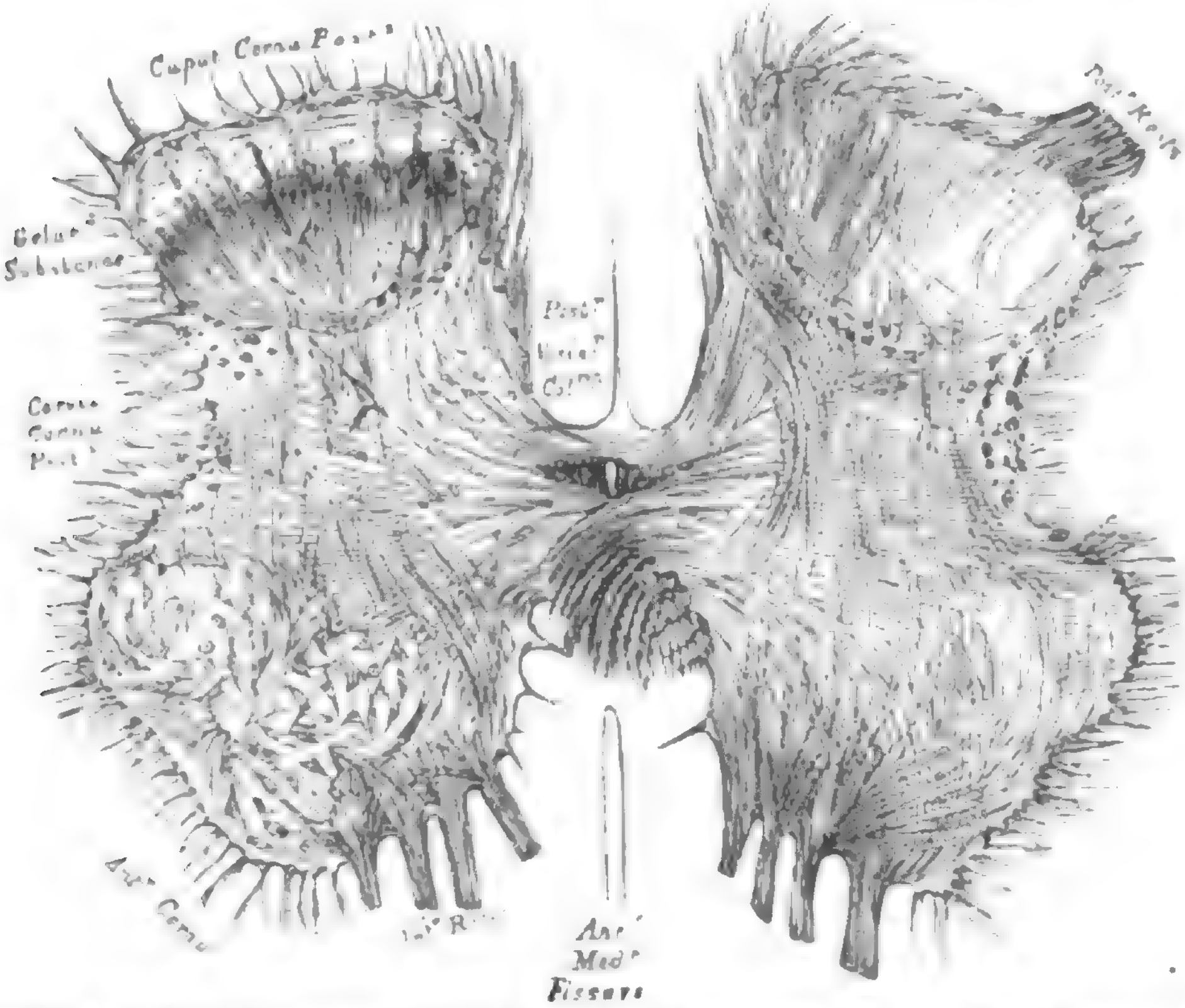

Transverse Section of the Gray Substance of the Spinal Cord, through the middle of the lumbar enlargement. On the left side of the figure groups of large cells are seen; on the right side the course of the fibres is shown without the cells (magnified 13 diameters—J. L. Clarke *del.*).

The *nerve-fibres* of the gray matter are for the most part composed of a minute and dense network of minute fibrils, which is termed "Gerlach's nerve-network," intermingled with nerves of a larger size. This network is continuous with the medullated fibres of the posterior nerve-roots on the one hand (Deiters), and with the branched processes of the ganglion-cells on the other (Gerlach), so that the cells are connected with the fibres only indirectly through the nerve-network. The arrangement of the fibres in the anterior horn of the gray matter appears to be somewhat different: here the nerve-fibres of the anterior root are directly continuous with some of the processes of the ganglion-cells, others of the processes communicating with Gerlach's nerve-network.

The *nerve-cells* of the gray matter are of two kinds—large branched nerve-vesicles which are collected into groups, and small round cells which resemble free nuclei and are found scattered throughout the whole of the gray matter.

In the anterior horn there are two or three groups of nerve-vesicles—one at the outer part of the cornu, and one, sometimes two, in the anterior portion (Fig. 436).

FIG. 437.



Longitudinal Section of the White and Gray Substance of the Spinal Cord, through the middle of the lumbar enlargement (mag. 14 diam.—J. L. Clarke *del.*).

FIG. 438.



Transverse Section through the White Matter of the Spinal Cord of a Calf (magnified about 300 diameters—Klein and Noble Smith). In the upper part are shown two isolated flattened nucleated cells of the neuroglia under a somewhat higher power than the rest. In the bulk of the figure the nerve-fibres are seen in transverse section. They are of different sizes, and possess a laminated medullary sheath surrounding the axis-cylinder; which [last] was deeply stained in the preparation, and is here represented by a black dot. The nerve-fibres are imbedded in the neuroglia. This contains, in a matrix which appears sometimes granular, sometimes homogeneous, numerous elastic fibrils, seen here in transverse section as minute dots, on account of their having a course parallel to the long axis of the cord. Amongst the neuroglia are also seen two branched connective-tissue cells—neuroglia-cells.

In the posterior horn, occupying the whole inner half of the cervix, is a group of nerve-cells, called the *posterior vesicular column* of Clarke [Fig. 385, p. 547].

FIG. 439.

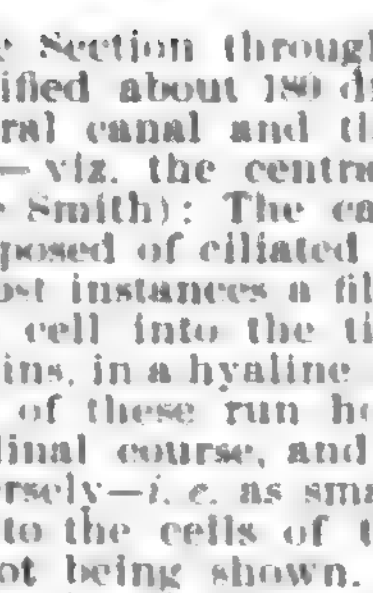

From a Transverse Section through the Spinal Cord of a Calf (magnified about 180 diameters, showing part of the central canal and the tissue immediately around it—viz. the central gray nucleus—Klein and Noble Smith): The canal is lined with epithelium, composed of ciliated more or less conical cells; in most instances a filamentous process passes from the cell into the tissue underneath. This tissue contains, in a hyaline matrix, a network of fibrils; most of these run horizontally, others have a longitudinal course, and appear therefore here cut transversely—*i. e.* as small dots. The nuclei correspond to the cells of the neuroglia, the cell-substance not being shown. Both the nuclei of the neuroglia-cells and those of the epithelium contain three or more large disk-shaped particles.

At the junction of the anterior and posterior cornu, in the outer portion of the gray matter, is a third group of cells, the *tractus intermedio-lateralis.* In the cervical region of the cord these cells extend in amongst the fibres of the white matter of the lateral column. [See Fig. 385, p. 547, for the location of the groups of cells in the cord, as well as the arterial supply of the cord.]

Origin of the Spinal Nerves in the Cord.—The *posterior roots* are larger than the anterior, but their component filaments are finer and more delicate. They are attached to the cord at the junction of the lateral and posterior columns, and at once enter the posterior horn of gray matter, either directly through the substantia gelatinosa, or indirectly by passing through the posterior column and entering the gray substance in front of the caput cornu. The former pass upward and downward and become continuous with Gerlach's nerve-network, some of the fibres extending across the commissure to the opposite side of the cord, others reaching the anterior column on the same side. The latter fibres enter the posterior vesicular column, and some, passing through it, run longitudinally in the posterior column (Figs. 436, 437).

The *anterior roots* are attached exclusively to the anterior column, or rather to the anterior part of the antero-lateral columns, for there is no antero-lateral *fissure* dividing the anterior from the lateral column. Within the gray substance the fibrils cross each other, and diverge in all directions like the expanded hairs of a brush (Figs. 436, 437), some of them running more or less longitudinally upward and downward, and others decussating with those of the opposite side through the anterior commissure in front of the central canal.

All the fibres of both roots of the nerves proceed through the white columns into the gray substance, with perhaps the exception of some which appear to run longitudinally in the posterior columns; but whether these latter fibres of the posterior roots ultimately enter the gray substance of the cord after a very oblique course, or whether they proceed upward to the brain, is uncertain.

The central canal of the spinal cord (Fig. 439) is lined by a layer of columnar ciliated epithelium: external to this is a considerable accumulation of neuroglia, forming a cylindrical mass which is called the *central gray nucleus* of Kölliker.

THE [ENCEPHALON OR] BRAIN AND ITS MEMBRANES.

Dissection.—To examine the brain with its membranes the skull-cap must be removed. In order to effect this, saw through the external table, the section commencing in front about an inch above the margin of the orbit, and extending behind to a level with the occipital protuberance. Then break the internal table with the chisel and hammer, to avoid injuring the investing membranes or brain; loosen and forcibly detach the skull-cap, when the dura mater will be exposed. The adhesion between the bone and the dura mater is very intimate, and much more so in the young subject than in the adult.

The membranes of the brain are—the dura mater, arachnoid membrane, and pia mater.

DURA MATER.

The **Dura Mater** is a thick and dense inelastic fibrous membrane which lines the interior of the skull. Its outer surface is rough and fibrillated, and adheres closely to the inner surface of the bones, forming their internal periosteum, this adhesion being more intimate opposite the sutures and at the base of the skull; at the margin of the foramen magnum it becomes continuous with the dura mater lining the spinal canal. Its inner surface is smooth and lined by a layer of endothelial cells. It sends numerous processes inward, into the cavity of the skull, for the support and protection of the different parts of the brain, and is prolonged to the outer surface of the skull through the various foramina which exist at the base, and thus become continuous with the pericranium; its fibrous layer forms sheaths for the nerves which pass through these apertures. At the base of the skull it sends a fibrous prolongation into the foramen cæcum; it lines the olfactory groove, and sends a series of tubular prolongations round the filaments of the olfactory nerves as they pass through the cribriform plate and also through the nasal slit; a prolongation is also continued through the sphenoidal fissure into the orbit, and another is continued into the same cavity through the optic foramen, forming a sheath for the optic nerve, which is continued as far as the eyeball. In the posterior fossa it sends a process down the internal auditory meatus, ensheathing the facial and auditory nerve; another through the jugular foramen, forming a sheath for the structures which pass through this opening; and a third through the anterior condyloid foramen. Around the foramen magnum it is closely adherent to the bone, and is continuous with the dura mater lining the spinal canal. In certain situations in the skull already mentioned (p. 619) the fibrous layers of this membrane separate to form sinuses for the passage of venous blood. Upon the upper surface of the dura mater, in the situation of the longitudinal sinus, may be seen numerous small whitish bodies, *the glandulæ Pacchioni.*

Structure.—The dura mater consists of white fibrous and elastic tissues arranged in flattened laminæ which are divisible into two layers, the fibres of the two layers intersecting each other obliquely. A layer of nucleated endothelial plates similar to those found on serous membranes lines its inner surface; these were formerly regarded as belonging to the arachnoid membrane.

Its *arteries* are very numerous, but are chiefly distributed to the bones. Those found in the anterior fossa are the anterior meningeal branches of the anterior and posterior ethmoidal and internal carotid. In the middle fossa are the middle and small meningeal branches of the internal maxillary, and a branch from the ascending pharyngeal which enters the skull through the foramen lacerum medium basis cranii. In the posterior fossa are the meningeal branch of the occipital, which enters the skull through the jugular foramen; the posterior meningeal, from the vertebral; and occasionally meningeal branches from the ascending pharyngeal, which enter the skull, one at the jugular foramen, the other at the anterior condyloid foramen.

The *veins* which return the blood from the dura mater and partly from the bones anastomose with the diploic veins. These vessels terminate in the various sinuses, with the exception of two which accompany the middle meningeal artery and pass out of the skull at the foramen spinosum to join the internal maxillary vein.

The *nerves* of the dura mater are—the recurrent branch of the fourth and filaments from the Gasserian ganglion, from the ophthalmic and hypoglossal nerves, and from the sympathetic.

The so-called glandulæ Pacchioni are numerous small whitish granulations, usually collected into clusters of variable size, which are found in the following situations: 1, upon the outer surface of the dura mater, in the vicinity of the superior longitudinal sinus, being received into little depressions on the inner surface of the calvarium; 2, on the inner surface of the dura mater; 3, in the superior longitudinal sinus; 4, on the pia mater near the margin of the hemispheres.

These bodies are not glandular in structure, but simply enlarged normal villi of the arachnoid. In their growth they perforate the dura mater, and are thus found on its outer surface, and when of large size they cause absorption of the bone and come to be lodged in pits or depressions on the inner table of the skull. The manner in which they perforate the dura mater is as follows: At an early period of their growth they project through minute holes in the inner layer of the dura mater, which open into large venous spaces, situated in the tissues of the membrane, on either side of the longitudinal sinus and communicating with it. In their onward growth the villi push the outer layer of the dura mater before them, and this forms over them a delicate membranous sheath. In structure they consist of trabeculæ of connective tissue covered over by a layer of epithelium. The spongy tissue of which they are composed is continuous with the trabecular tissue of the subarachnoid space.

These bodies are not found in infancy, and very rarely until the third year. They are usually found after the seventh year, and from this period they increase in number as age advances. Occasionally they are wanting.

Processes of the Dura Mater.—The processes of the dura mater sent inward into the cavity of the skull are three in number—the falx cerebri, the tentorium cerebelli, and the falx cerebelli.

The *falx cerebri*, so named from its sickle-like form, is a strong arched process of the dura mater which descends vertically in the longitudinal fissure between the two hemispheres of the brain. It is narrow in front, where it is attached to the crista galli of the ethmoid bone, and broad behind, where it is connected with the upper surface of the tentorium. Its upper margin is convex, and attached to the inner surface of the skull as far back as the internal occipital protuberance. In this situation it is broad, and contains the superior longitudinal sinus. Its lower margin is free, concave, and presents a sharp curved edge, which contains the inferior longitudinal sinus.

The *tentorium cerebelli* is an arched lamina of dura mater elevated in the middle and inclining downward toward the circumference. It covers the upper surface of the cerebellum, and supports the posterior lobes of the brain and prevents them pressing upon the cerebellum. It is attached behind, by its convex border, to the transverse ridges upon the inner surface of the occipital bone, and there encloses the lateral sinuses; in front to the superior margin of the petrous portion of the temporal bone, enclosing the superior petrosal sinuses; and at the apex of this bone the free or internal border and the attached or external border meet, and, forming two processes, cross one another and are continued forward to be attached to the anterior and posterior clinoid processes respectively. Along the middle line of its upper surface the posterior border of the falx cerebri is attached, the straight sinus being placed at their point of junction. Its anterior border is free and concave, and presents a large oval opening for the transmission of the crura cerebri.

The *falx cerebelli* is a small triangular process of dura mater received into the indentation between the two lateral lobes of the cerebellum behind. Its base is attached above to the under and back part of the tentorium; its posterior margin, to the lower division of the vertical crest on the inner surface of the occipital bone. As it descends it sometimes divides into two smaller folds, which are lost on the sides of the foramen magnum.

ARACHNOID MEMBRANE.

The **Arachnoid** (ἀράχνη, εἶδος, like a spider's web), so named from its extreme thinness, is a delicate membrane which envelops the brain, lying between the pia mater internally and the dura mater externally; from this latter membrane it is separated by a space, the *subdural space*.[1]

It invests the brain loosely, being separated from direct contact with the cerebral substance by the pia mater and a quantity of loose areolar tissue, the *subarachnoidean*. On the upper surface of the cerebrum the arachnoid is thin and transparent, and may be easily demonstrated by injecting a stream of air beneath it by means of a blowpipe; it passes over the convolutions without dipping down into the sulci between them. At the base of the brain the arachnoid is thicker, and slightly opaque toward the central part; it covers the anterior lobes, and is extended across between the two middle lobes so as to leave a considerable interval between it and the brain, the *anterior subarachnoidean space:* it is in contact with the pons and under surface of the cerebellum; but between the hemispheres of the cerebellum and the medulla oblongata another considerable interval is left between it and the brain, called the *posterior subarachnoidean space*. These two spaces communicate together across the crura cerebelli. The arachnoid membrane surrounds the nerves which arise from the brain, and encloses them in loose sheaths as far as their point of exit from the skull.

The *subarachnoid space* is the interval between the arachnoid and pia mater: this space is narrow on the surface of the hemispheres, but at the base of the brain a wide interval is left between the two middle lobes, and behind between the hemispheres of the cerebellum and the medulla oblongata. This space is the seat of an abundant serous secretion, the *cerebro-spinal fluid*, which fills up the interval between the arachnoid and pia mater. The subarachnoid space usually communicates with the general ventricular cavity of the brain by means of an opening in the inferior boundary of the fourth ventricle.

The subdural space also contains fluid; this is, however, small in quantity compared with the cerebro-spinal fluid.

Structure.—The arachnoid consists of bundles of white fibrous and elastic tissue intimately blended together. Its outer surface is covered with a layer of endothelium. From its inner surface are given off a number of bundles of fine connective tissue, which form a sponge-like trabecular network in the subarachnoid space, in the interstices of which the cerebro-spinal fluid is contained. Vessels of considerable size, but few in number, and, according to Bochdalek, a rich plexus of nerves derived from the motor division of the inferior maxillary, the facial, and the spinal accessory nerves, are found in the arachnoid.

---

[1] See foot-note, p. 653.

The *cerebro-spinal* [or *cephalo-rachidian*] *fluid* fills up the subarachnoid space. It is a clear, limpid fluid, having a saltish taste and a slightly alkaline reaction. According to Lassaigne, it consists of 98.5 parts of water, the remaining 1.5 per cent. being solid matters, animal and saline. It varies in quantity, being most abundant in old persons, and is quickly reproduced. Its chief use is probably to afford mechanical protection to the nervous centres and to prevent the effects of concussions communicated from without.

PIA MATER.

The **Pia Mater** is a vascular membrane, and derives its blood from the internal carotid and vertebral arteries. It consists of a minute plexus of blood-vessels held together by an extremely fine areolar tissue. It invests the entire surface of the brain, dipping down between the convolutions and laminæ, and is prolonged into the interior, forming the velum interpositum and choroid plexuses of the fourth ventricle. Upon the surfaces of the hemispheres, where it covers the gray matter of the convolutions, it is very vascular, and gives off from its inner surface a multitude of minute vessels which extend perpendicularly for some distance into the cerebral substance. At the base of the brain, in the situation of the anterior and posterior perforated spaces, a number of long straight vessels are given off, which pass through the white matter to reach the gray substance in the interior. On the cerebellum the membrane is more delicate and the vessels from its inner surface are shorter. Upon the crura cerebri and pons Varolii its characters are altogether changed; it here presents a dense fibrous structure marked only by slight traces of vascularity.

According to Fohmann and Arnold, this membrane contains numerous lymphatic vessels. Its nerves are derived from the sympathetic, and also from the third, fifth, sixth, facial, glosso-pharyngeal, pneumogastric, and spinal accessory. They accompany the branches of the arteries.

THE BRAIN.

The **Brain** (*encephalon*) is that portion of the cerebro-spinal axis which is contained in the cranial cavity. It is divided into four principal parts—viz. the cerebrum, the cerebellum, the pons Varolii, and the medulla oblongata.

The **Cerebrum** forms the largest portion of the encephalon, and occupies a considerable part of the cavity of the cranium, resting in the anterior and middle fossæ of the base of the skull, and separated posteriorly from the cerebellum by the tentorium cerebelli. About the middle of its under surface is a narrow constricted portion, part of which, the *crura cerebri*, is continued onward into the pons Varolii below, and through it to the medulla oblongata and spinal cord, whilst another portion, the *crura cerebelli*, passes down into the cerebellum.

The **Cerebellum** (little brain or after-brain) is situated in the inferior occipital fossæ, being separated from the under surface of the posterior lobes of the cerebrum by the tentorium cerebelli. It is connected to the rest of the encephalon by means of connecting bands called *crura:* of these, two ascend to the cerebrum, two descend to the medulla oblongata, and two blend together in front, forming the pons Varolii.

The **Pons Varolii** is that portion of the encephalon which rests upon the upper part of the basilar process and body of the sphenoid bone. It constitutes the bond of union of the various segments above named, receiving above the crura from the cerebrum; at the sides, the crura from the cerebellum; and below, the medulla oblongata.

The **Medulla Oblongata** extends from the lower border of the pons Varolii to the upper part of the spinal cord. It lies beneath the cerebellum, resting on the lower part of the basilar groove of the occipital bone.

Weight of the Encephalon.—The average weight of the brain in the adult male is 49½ oz., or a little more than 3 lb. avoirdupois; that of the female, 44 oz.; the average difference between the two being from 5 to 6 oz. The prevailing weight of the brain in the male ranges between 46 oz. and 53 oz.; and in the female, between 41 oz. and 47 oz. In the male the maximum weight out of 278 cases was 65 oz., and the minimum weight 34 oz. The maximum weight of the adult female brain, out of 191 cases, was 56 oz., and the minimum weight 31 oz. According to Luschka, the average weight of a man's brain is 1424 grammes (about 45 ounces), of a woman's, 1273 grammes (about 41 ounces); and according to Krause, 1570 grammes (about 48½ oz.) for the male and 1350 (about 43 oz.) for the female. It appears that the weight of the brain increases rapidly up to the seventh year, more slowly to between sixteen and twenty, and still more slowly to between thirty and forty, when it reaches its maximum. Beyond this period, as age advances and the mental faculties decline, the brain diminishes slowly in weight, about an ounce for each subsequent decennial period. These results apply alike to both sexes.

The size of the brain was formerly said to bear a general relation to the intellectual capacity of the individual. Cuvier's brain weighed rather more than 64 oz., that of the late Dr. Abercrombie 63 oz., and that of Dupuytren 62½ oz. On the other hand, the brain of an idiot seldom weighs more than 23 oz. But these facts are by no means conclusive, and it is well known that these weights have been equalled by the brains of persons who never displayed any remarkable intellect. Dr. Haldennan of Cincinnati has recorded the case of a mulatto, aged forty-five, whose brain weighed 68⅜ oz.; he had been a slave, and was never regarded as particularly intelligent; he was illiterate, but is said to have been reserved, meditative, and economical. Dr. Ensor, district medical officer at Port Elizabeth, reports that the brain of Cary, the Irish informer, weighed 61 oz. M. Nikiforoff has published an article on the subject of the weight of brains in the *Novosti*. According to him, the weight of the brain has no influence whatever on the mental faculties. It ought to be remembered that the significance of the weight of the brain should depend upon the proportion it bears to the dimensions of the whole body and to the age of the individual. It is equally important to know what was the cause of death, for long disease or old age exhausts the brain. To define the real degree of development of the brain it is therefore necessary to have a knowledge of the condition of the whole body, and, as this is usually lacking, the mere record of weight possesses little significance.

The human brain is heavier than that of all the lower animals, excepting the elephant and whale. The brain of the former weighs from 8 lb. to 10 lb., and that of a whale, in a specimen seventy-five feet long, weighed rather more than 5 lb.

MEDULLA OBLONGATA.

The **Medulla Oblongata** is the upper enlarged part of the spinal cord, and extends from the upper border of the atlas to the lower border of the pons Varolii. It is directed [from above] obliquely downward and backward; its anterior surface rests on the basilar groove of the occipital bone; its posterior surface is received into the fossa between the hemispheres of the cerebellum, forming the floor of the fourth ventricle. It is pyramidal in form, its broad extremity directed upward, its lower end being narrow at its point of connection with the cord. It measures an inch and a quarter in length, three-quarters of an inch in breadth at its widest part, and half an inch in thickness. Its surface is marked, in the median line in front and behind, by an *anterior* and *posterior median fissure*, which are continuous with those of the spinal cord. The anterior fissure contains a fold of pia mater, and terminates just below the pons in a cul-de-sac, the *foramen cæcum*. The posterior is

Digitized by Gc

a deep but narrow fissure continued upward to about the middle of the medulla, where it expands into the fourth ventricle. These two fissures divide the medulla into two symmetrical halves, each lateral half being subdivided by minor grooves into four columns, which, from before backward, are named the *anterior pyramid*, *lateral tract* and *olivary body*, the *restiform body*, the *posterior pyramid*.

FIG. 440.

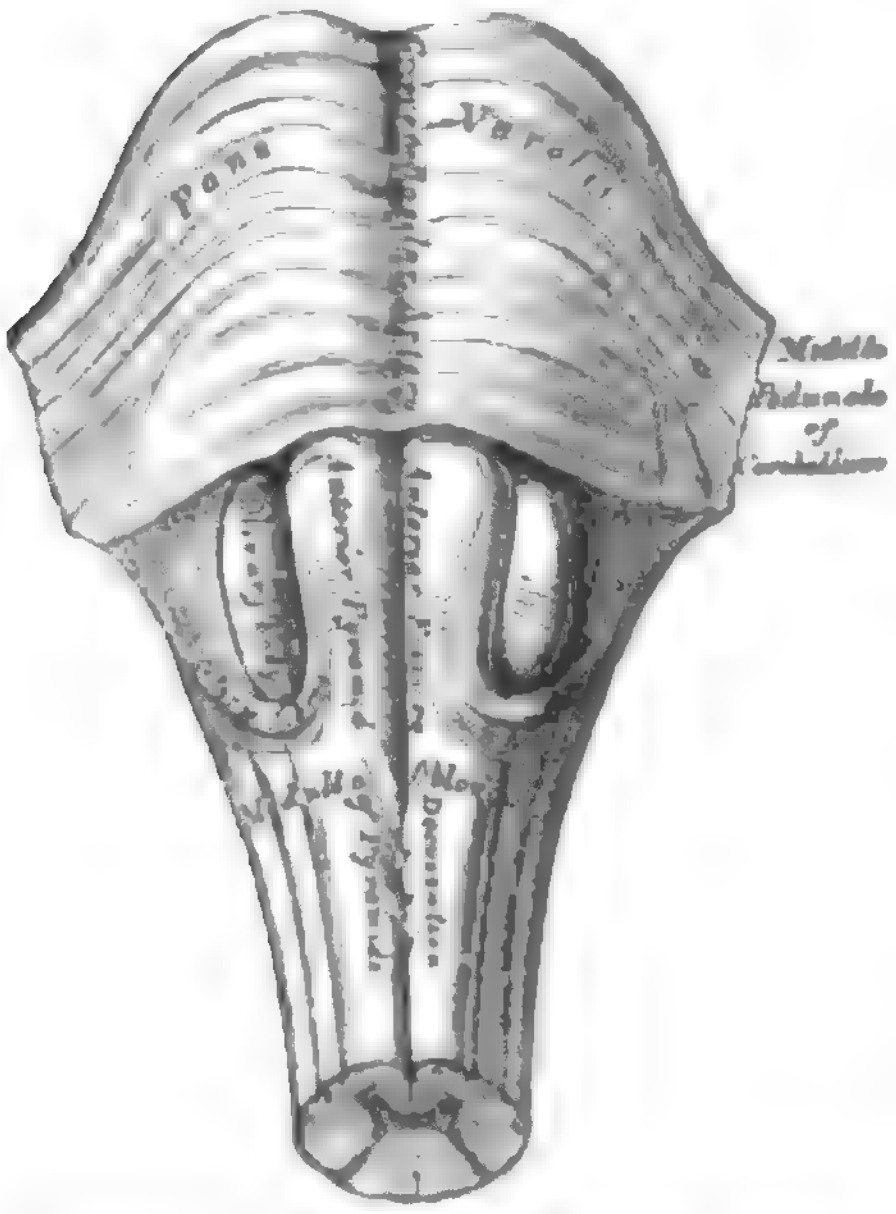

Medulla Oblongata and Pons Varolii, anterior surface.

The **anterior pyramids,** or **corpora pyramidalia,** are two pyramidal bundles of white matter placed one on either side of the anterior median fissure, and separated from the olivary body, which is external to them, by a slight depression. At the lower border of the pons they are somewhat constricted; they then become enlarged and taper slightly as they descend, being continuous below with the anterior columns of the cord. On separating the pyramids below it will be observed that their innermost fibres form from four to five bundles on each side, which decussate with one another across the anterior median fissure; this decussation, however, is not formed of fibres from the anterior column of the cord, but from the deep portion of the lateral columns, which pass forward to the surface between the diverging anterior columns. The outermost fibres do not decussate; they are derived from the anterior columns of the cord, and are continued directly upward through the pons Varolii.

Lateral Tract and Olivary Body.—The lateral tract is continuous with part of the lateral column of the cord. Below it is broad, and includes that part of the medulla between the anterior pyramids and restiform body; but above it is pushed a little backward and narrowed by the projection forward of the olivary body.

FIG. 441.

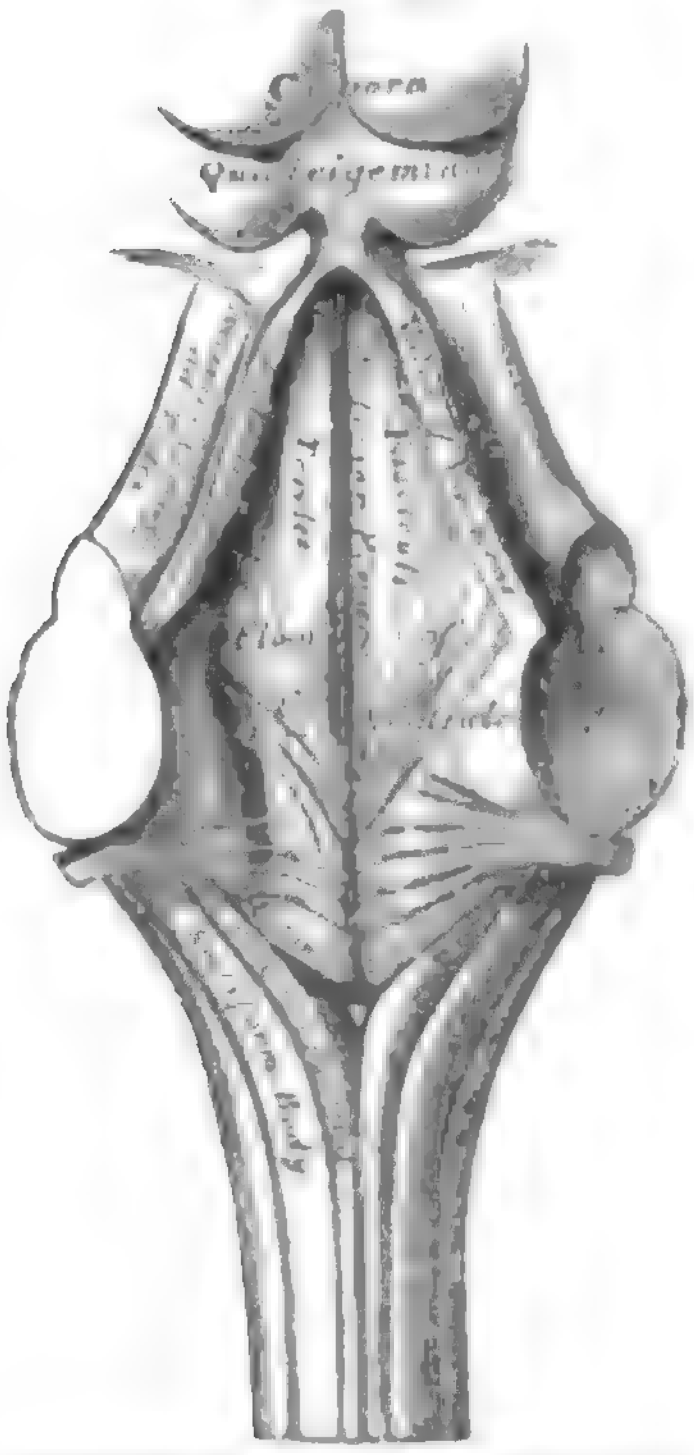

Posterior Surface of the Medulla Oblongata.

The **olivary bodies** are two prominent oval masses situated behind the anterior pyramids, from which they are separated by slight grooves. They equal in breadth the anterior pyramids, are a little broader above than below, and are about half an inch in length, being separated above from the pons Varolii by a slight depression. Numerous white fibres (*fibræ arciformes*) are seen winding round the lower end of each body, sometimes crossing their surface, and it is separated above from the lower border of the pons by a band of arched fibres.

The *restiform bodies* (Fig. 441) are the largest columns of the medulla, and continuous below with the posterior columns of the cord. They are two rounded, cord-like eminences placed between the lateral tracts in front and the posterior pyramids behind, from both of which they are separated by slight grooves. As they ascend they diverge from each other, assist in forming the lateral boundaries of the fourth ventricle, and then enter the corresponding hemisphere of the cerebellum, forming its inferior peduncle, while other fibres are continued from the restiform bodies into the cerebrum.

The **posterior pyramids** (*funiculi graciles*) are two narrow white cords placed one on each side of the posterior median fissure, and separated from the restiform bodies by a narrow groove. They consist entirely of white fibres, and are continuous with the posterior median columns of the spinal cord. These bodies lie at first in close contact. Opposite the apex of the fourth ventricle they form an enlargement (*processus clavatus*), and then diverging form the lateral boundaries of the lower part of the fourth ventricle, and, gradually tapering off, become lost in the corresponding restiform body.

The *posterior surface of the medulla oblongata* forms part of the floor of the fourth ventricle. It is of a triangular form, bounded on each side by the diverging posterior pyramids, and is that part of the ventricle which from the resemblance to the point of a pen is called the *calamus scriptorius*. The divergence of the posterior pyramids and restiform bodies opens to view the gray matter of the medulla, which is continuous below with the gray commissure of the cord. In the middle line is seen a longitudinal furrow continuous with the posterior median fissure of the cord, terminating below, at the point of the ventricle, in a cul-de-sac, the *ventricle of Arantius*, which descends into the medulla to a slight extent. It is the remains of a canal which in the fœtus extends throughout the entire length of the cord. [This statement is erroneous. The canal persists throughout life, and is the "central canal" of the cord (Fig. 433, p. 657). The ventricle of Arantius is therefore only apparently a cul-de-sac. The central canal, or "ventricle of the cord," is continuous with the fourth ventricle, and is the lowest one of the continuous series of cavities in the interior of the central nervous system, due to its mode of development.]

Structure.—The medulla oblongata, like the spinal cord, consists of both gray and white matter. But the outer surface of the medulla does not consist so exclusively of white matter as in the cord, for the gray matter is exposed on its posterior surface, forming the floor of the fourth ventricle by the divergence of the restiform bodies and posterior pyramids. The white matter is arranged, as has been described, into four columns, and through these the fibres of the cord can be traced upward into the rest of the encephalon.

The *anterior pyramid* is composed of fibres derived from the direct pyramidal fasciculus of the anterior column of the cord of its own side, and from the crossed pyramidal fasciculus (fasciculus of Türck) of the lateral column of the opposite half of the cord, and is continued upward into the cerebrum and cerebellum. The fibres may be divided into three sets, internal, middle, and external. The *internal*, the chief mass of fibres from the pyramid, enter the pons, and, coursing through the superficial layer of the crus, pass upward to the cerebrum. The *middle* fasciculus encloses the olivary body, and, receiving fibres from it, enters the pons as the *olivary fasciculus* or *fillet*. The *external* fibres pass beneath the olivary body to the restiform body, and spread out into the structure of the cerebellum. The anterior pyramids contain no gray matter.

The *lateral tract* is continuous below with the lateral column of the cord. Its fibres pass in three different directions. The most external join the restiform body and pass to the cerebellum. The internal, more numerous, pass forward, pushing aside the fibres of the anterior column, and form part of the opposite anterior pyramid under the name of "crossed pyramidal fasciculus." The middle fibres ascend beneath the olivary body to the cerebrum, passing along the back of the pons, and form, together with fibres from the restiform body and posterior pyramids, the *fasciculi teretes* in the floor of the fourth ventricle.

Olivary Body.—If a transverse section is made through either olivary body, it will be found to consist of a small ganglionic mass deeply imbedded in the medulla, partly appearing on the surface as a smooth, olive-shaped eminence (Fig. 442). It consists externally of a white substance, and internally of a gray nucleus, the *corpus dentatum*. The gray matter is arranged in the form of a hollow capsule, open at its upper and inner part, and presenting a zigzag or dentated outline. White fibres pass into or from the interior of this body by the aperture in the upper part of the capsule. They join with those fibres of the anterior column which ascend on

FIG. 442.

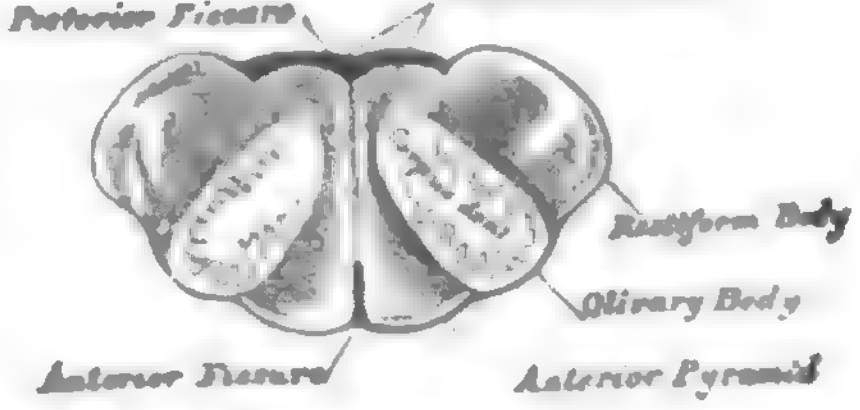

Transverse Section of Medulla Oblongata.

the outer side and beneath the olivary body to form the olivary fasciculus, which ascends to the cerebrum.

The *restiform body* is formed chiefly of fibres from the fasciculus cuneatus of the posterior column of the cord, which is continued up into the lower part of the medulla under the same name. In the medulla between the fasciculus cuneatus and the posterior pyramid there exists another tract, called the funiculus of Rolando, which is produced by the enlargement and approach to the surface of the caput cornu of the gray matter. These two fasciculi, the fasciculus cuneatus and the funiculus of Rolando, are joined by some transverse bundles of fibres, the arciform fibres of Rolando, which pass from the anterior median fissure across the olivary body, and the three form the restiform body. On entering the pons it divides into two fasciculi above the point of the fourth ventricle. The external fasciculus enters the cerebellum; the inner fasciculus joins the posterior pyramid, is continued up along the fourth ventricle, and can be traced up to the cerebrum with the fasciculi teretes.

FIG. 443.

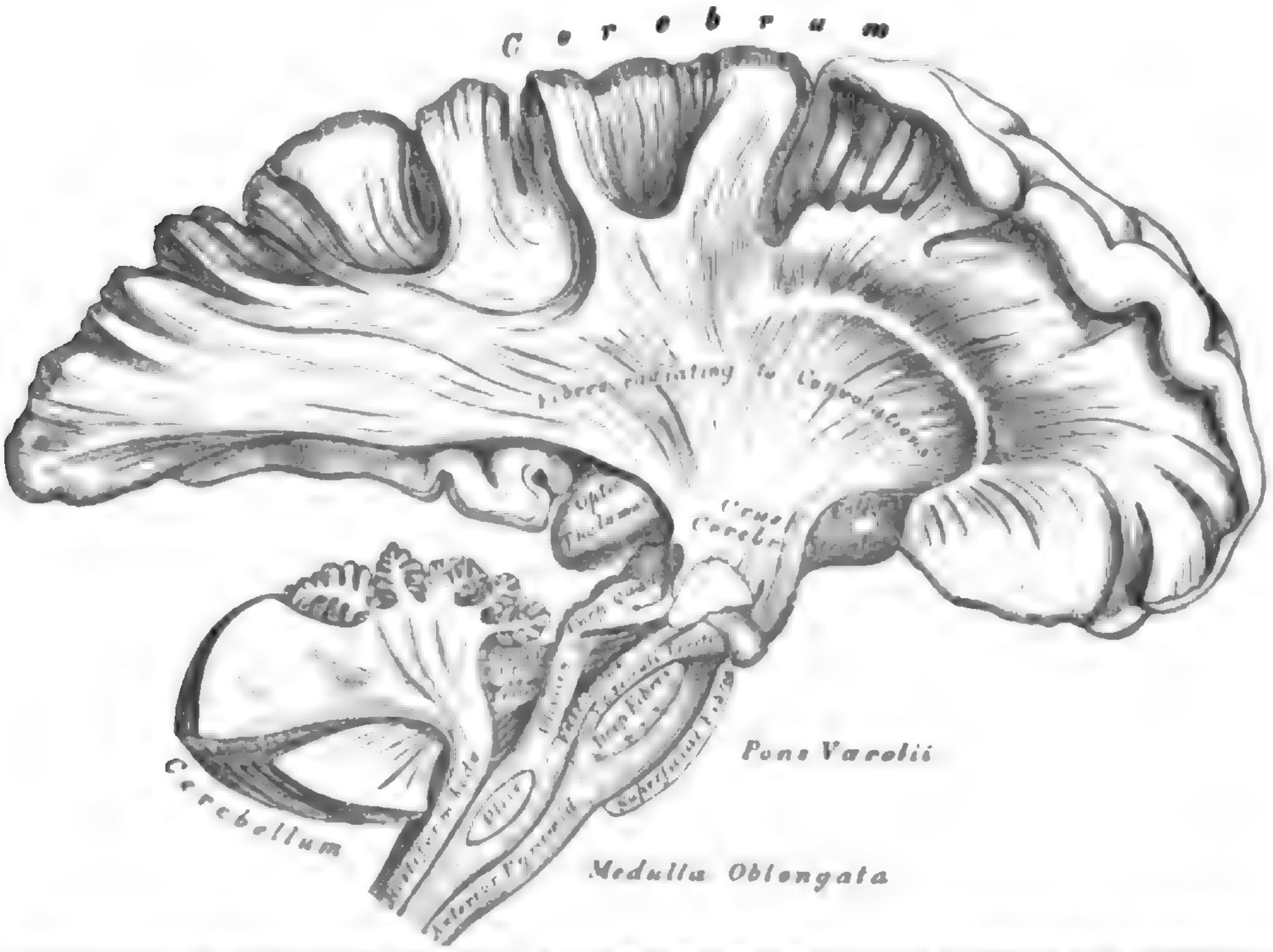

The Columns of the Medulla Oblongata, and their connection with the cerebrum and cerebellum.

The *posterior pyramid* is formed by the fasciculus of Goll of the posterior column of the cord; it joins the fasciculus teres and is continued with it to the cerebrum.

The course of the fibres of the medulla will be better understood by reference to the accompanying plan (Fig. 445, p. 671), copied, by permission of Mr. H. E. Clark, from Wilson's *Anatomist's Vade-Mecum;* [and Fig. 444, from Flechsig].

Septum of the Medulla Oblongata.—Above the decussation of the anterior pyramids numerous white fibres extend from behind forward in the median line, forming a septum which subdivides the medulla into two lateral halves. Some of these fibres emerge at the anterior median fissure, and form a band which curves round the lower border of the olivary body or passes transversely across it, and round the side of the medulla, forming the *arciform fibres* of Rolando. Others appear in the floor of the fourth ventricle issuing from the posterior median fissure, and form the white striæ in that situation.

Gray Matter of the Medulla Oblongata.—[For the vascular supply of the medulla, as well as the location of some of its nuclei, see Fig. 386, p. 548.] The *gray matter* of the medulla oblongata, which contains many multipolar ganglion-cells, is partly continuous with the gray matter of the cord and partly arranged in independent masses. In the lower part of the medulla the gray matter, which is continuous with the cord, is arranged in the shape of two crescentic horns, with their convexities toward each other and connected by a central commissure; but in the upper part it loses its crescentic arrangement, becomes more abundant, and is disposed with less regularity. The posterior horns become enlarged and gradually shifted outward, so that they form rounded masses close under the surface of the lateral columns, and have received the names of the *tubercles* of Rolando. The rest of the posterior horn surrounds the posterior part of the central canal, but as this expands into the fourth ventricle the gray matter is pushed outward into the posterior pyramid and the fasciculus cuneatus, which is passing upward to form the restiform body; in each of these funiculi it forms a distinct accumulation of gray matter, constituting the *nucleus gracilis* and the *nucleus cuneatus*. The anterior horn of gray matter is broken up by the passage through it of the crossed pyramidal fibres from the lateral column of the cord. By this means the anterior portion of the horn is completely isolated from the remainder and constitutes the *lateral nucleus of gray matter*, which is situated near the surface of the lateral column. The rest of the anterior horn, being permeated by the decussating fibres, presents a sort of coarse network arrangement called the *formatio reticularis*. The part corresponding to the transverse gray commissure of the cord is exposed to view by the divergence of the posterior white fibres on the surface of the medulla, and forms a continuous mass, constituting the floor of the fourth ventricle. The ganglion-cells are here collected into groups, forming the so-called *nuclei* from which many of the cranial nerves arise. The lowest of these groups, situated just at the point where the medulla commences, and on either side of the central canal, is the nucleus of origin of the spinal accessory and hypoglossal nerves; somewhat in front and external to this several collections of ganglion-cells are situated, which together constitute the nucleus of origin of the pneumogastric nerve, the separate filaments of which the nerve consists at its origin arising from the different groups. Higher than this, and nearer the anterior part of the medulla, is a third group of cells, which constitutes the nucleus of the glosso-pharyngeal. And highest of all, and at some distance from the middle line, is the nucleus of the auditory nerve.

Another independent mass of gray matter is found in the corpus dentatum within the olivary body, which is continuous with the posterior part of the formatio reticularis of the anterior horn. And nearer the septum of the medulla, but continuous with the corpus dentatum, is a thin layer or stratum of gray matter called the accessory corpus dentatum.

PONS VAROLII.

The **Pons Varolii** (*mésocéphale*, Chaussier) is the bond of union of the various segments of the encephalon, connecting the cerebrum above, the medulla oblongata below, and the cerebellum behind. It is situated above the medulla oblongata, below the crura cerebri, and between the hemispheres of the cerebellum.

Its *under surface* presents a broad transverse band of white fibres which arches like a bridge across the upper part of the medulla, extending between the two hemispheres of the cerebellum. This surface projects considerably beyond the level of these parts, is of quadrangular form, rests upon the sphenoid and basilar groove of the occipital bone, and is limited before and behind by very prominent margins. It presents along the middle line a longitudinal groove, wider in front than behind, which lodges the basilar artery; numerous transverse striæ are also observed on each side, which indicate the course of its superficial fibres.

Its *upper surface* forms part of the floor of the fourth ventricle, and in part is in contact with the corpora quadrigemina.

At each side its fibres become contracted into a thick rounded cord, the *crus cerebelli*, which enters the substance of the cerebellum, constituting its middle peduncle.

Structure.—The pons Varolii consists of alternate layers of transverse and longitudinal fibres intermixed with gray matter (Fig. 443).

The *transverse fibres* connect together the two lateral hemispheres of the cerebellum, and constitute its great transverse commissure. They consist of a superficial and a deep layer. The superficial layer passes uninterruptedly across the surface of the pons, forming a uniform layer, which consists of fibres derived from the crus cerebelli on each side, meeting in the median line. The deep layer of transverse fibres decussates [at a right angle] with the longitudinal fibres continued up from the medulla, and contains much gray matter between its fibres.

[Fig. 444.

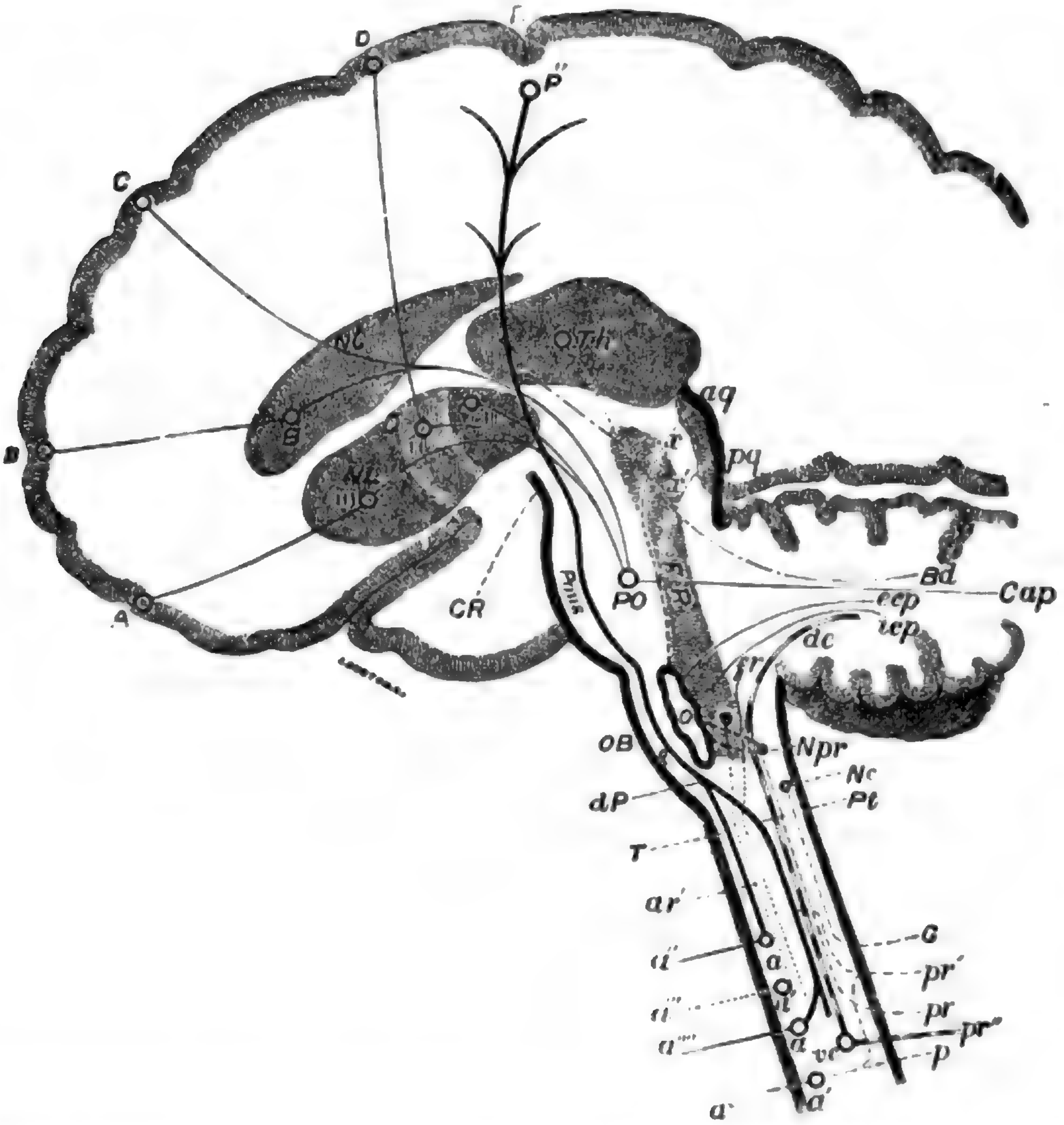

Diagram of the Gray Masses of the Spinal Cord and Brain, showing the course of the conducting paths.

R, Fissure of Rolando.

P'', *P*, *T*, and *Pt*, Course of the fibres of the pyramidal tract from their origin in the central convolutions to their termination in the anterior gray horns (*a*, *a'*).

I, *II*, *III*, First, second, and third portions of the lenticular nucleus (*NL*); *NC*, Caudate nucleus; *Th*, Optic thalamus.

D, *C*, *B*, *A*, Points from which fibres issue connecting the cortex of the brain and basal ganglion, and also the gray substance of the pons (*PO*); *Bd*, Fibres connecting the cerebellum and optic thalamus; and *Cap*, those connecting the cerebellum and the gray substance of the pons.

aq and *pq*, Anterior and posterior pair of corpora quadrigemina respectively.

r, Upper, and *r'*, lower fibres connecting the olivary body and the corpora quadrigemina.

FR, Formatio reticularis of the medulla oblongata, formed by fibres from the optic thalamus (*Th*), the internal division of the inferior peduncle of the cerebellum (*icp*), from the spinal cord (*fr*, *ar*, and *ar'*), and probably also from the clavate nucleus (*Nc*).

O, Olivary body; *ecp*, fibres of the restiform bodies connecting the olivary bodies and cerebellum; other fibres connect it with the triangular (*Npr*) and clavate (*Nc*) nuclei.

dp, Decussation of the pyramids.

pr', Fibres of the posterior roots which pass upward and downward into the gray substance, and pursue only a short course.

a, *a'*, *a''*, *a'''*, anterior roots.

p, *pr*, *pr''*, *G*, Fibres of the posterior roots (Flechsig).]

Fig. 446.

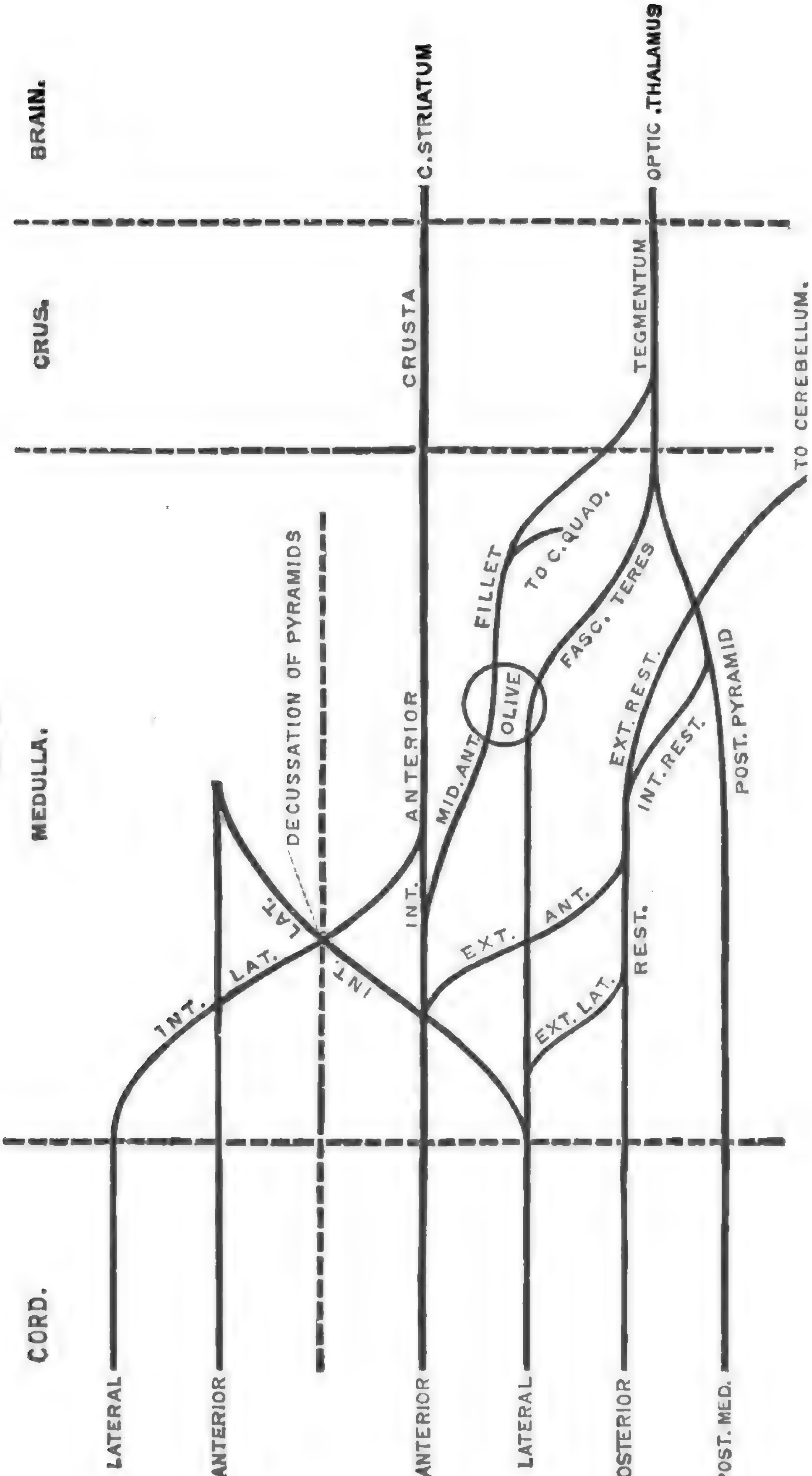
CORD.
MEDULLA.
CRUS.
BRAIN.
LATERAL
ANTERIOR
DECUSSATION OF PYRAMIDS
ANTERIOR
LATERAL
POSTERIOR
POST. MED.
INT. LAT.
LAT.
INT.
INT.
ANTERIOR
MID. ANT.
EXT. ANT.
EXT. LAT.
OLIVE
FILLET
TO C. QUAD.
FASC. TERES
REST.
EXT. REST.
INT. REST.
POST. PYRAMID
TO CEREBELLUM.
CRUSTA
TEGMENTUM
C. STRIATUM
OPTIC THALAMUS

DIAGRAM OF THE COURSE OF THE FIBRES THROUGH THE MEDULLA TO THE BRAIN.

The *longitudinal fibres* are continued up through the pons: 1, from the anterior pyramid; 2, from the olivary body; 3, from the lateral and posterior columns of the cord, receiving special fibres from the gray matter of the pons itself.

1. The *fibres from the anterior pyramid* ascend through the pons, imbedded between two layers of transverse fibres, being subdivided in their course into smaller bundles; at the upper border of the pons they enter the crus cerebri, forming its fasciculated portion or crusta.

2. The *olivary fasciculus* divides in the pons into two bundles, one of which ascends to the corpora quadrigemina; the other is continued to the cerebrum with the fibres of the lateral column.

3. The *fibres from the lateral and posterior columns* of the cord, with a bundle from the olivary fasciculus and restiform body, are intermixed with much gray matter, and appear in the floor of the fourth ventricle as the fasciculi teretes: they ascend to the deep or cerebral part of the crus cerebri.

The *gray matter* of the pons is irregularly scattered through its substance. No gray matter, however, is found on its anterior or superficial surface, which is occupied exclusively by the superficial transverse white fibres; but the posterior or dorsal surface is chiefly constituted of gray matter, traversed by longitudinal white fibres, forming a well-defined formatio reticularis. It is directly continuous with the gray matter of the medulla. In this formation are three collections or groups of ganglion-cells, forming the nuclei of origin of the facial and trifacial nerves and the superior olivary nucleus.

The *superior olivary nucleus* is situated in the lower part of the pons, close to the medulla, behind the longitudinal fibres from the anterior pyramid, and is enclosed by some transverse fibres called the *trapezium*.

Septum.—The pons is subdivided into two lateral halves by a median septum, which extends through its posterior half and is continuous with that of the medulla, and like it formed by antero-posterior fibres which decussate in the middle line.

CEREBRUM, UPPER SURFACE (Figs. 446, 447).

The **Cerebrum**[1] in man constitutes the largest portion of the encephalon. Its upper surface is of an ovoidal form, broader behind than in front, convex in its general outline, and divided into two lateral halves or hemispheres, right and left, by the *great longitudinal fissure*, which extends throughout the entire length of the cerebrum in the middle line, reaching down to the base of the brane in front and behind, but interrupted in the middle by a broad transverse commissure of white matter, the *corpus callosum*, which connects the two hemispheres together. This fissure lodges the falx cerebri, and indicates the original development of the brain by two lateral halves.

Each hemisphere presents an outer surface, which is convex to correspond with the vault of the cranium; an inner surface, flattened and in contact with the opposite hemisphere (the two inner surfaces forming the sides of the longitudinal fissure); and an under surface or base, of more irregular form, which rests in front on the anterior and middle fossæ of the base of the skull and behind upon the tentorium.

Convolutions.—If the arachnoid is removed with the forceps, the entire surface of each hemisphere will be seen to present a number of convoluted eminences, *the convolutions* or *gyri*, separated from each other by depressions (*fissures* and *sulci*) of various depths. The outer surface of each convolution, as well as the sides and bottom of the sulci between them, are composed of gray matter, which is called the *cortical substance*. The interior of each convolution is composed of white matter, and white fibres also blend with the gray matter at the sides and bottom of the sulci. By this arrangement the convolutions are adapted to increase the amount of gray matter without occupying much additional space, while they also afford a greater extent of surface for the termination of the white fibres in the gray matter. On closer examination, however, the cortical substance is found subdivided into four layers, two of which are composed of gray and two of white matter. The most external is an outer white stratum, not equally thick over all parts of the brain, being most marked on the convolutions in the longitudinal fissure and on the under part of the brain, especially on the middle lobe, near the descending horn of the lateral ventricle. Beneath this is a thick reddish-gray lamina, and then another thin white stratum; lastly, a thin stratum of gray matter, which lies in close contact with the white fibres of the hemispheres: consequently, white and gray laminæ alternate with one another in the convolutions.[2] In certain convolutions, however, the cortical substance consists of no less than six layers, three gray and three white, an additional white stratum dividing the most superficial gray one into two: this is especially marked in those convolutions which are situated near the corpus callosum.

---

[1] [In studying the brain no one should overlook the splendid *Topographical Anatomy of the Brain*, by Prof. J. C. Dalton, Philadelphia, 1885. In the *Brooklyn Annals of Anatomy and Surgery* for 1880 also is an excellent and clear account of much of the anatomy of the cerebrum, by the same author.]

Fig. 446.

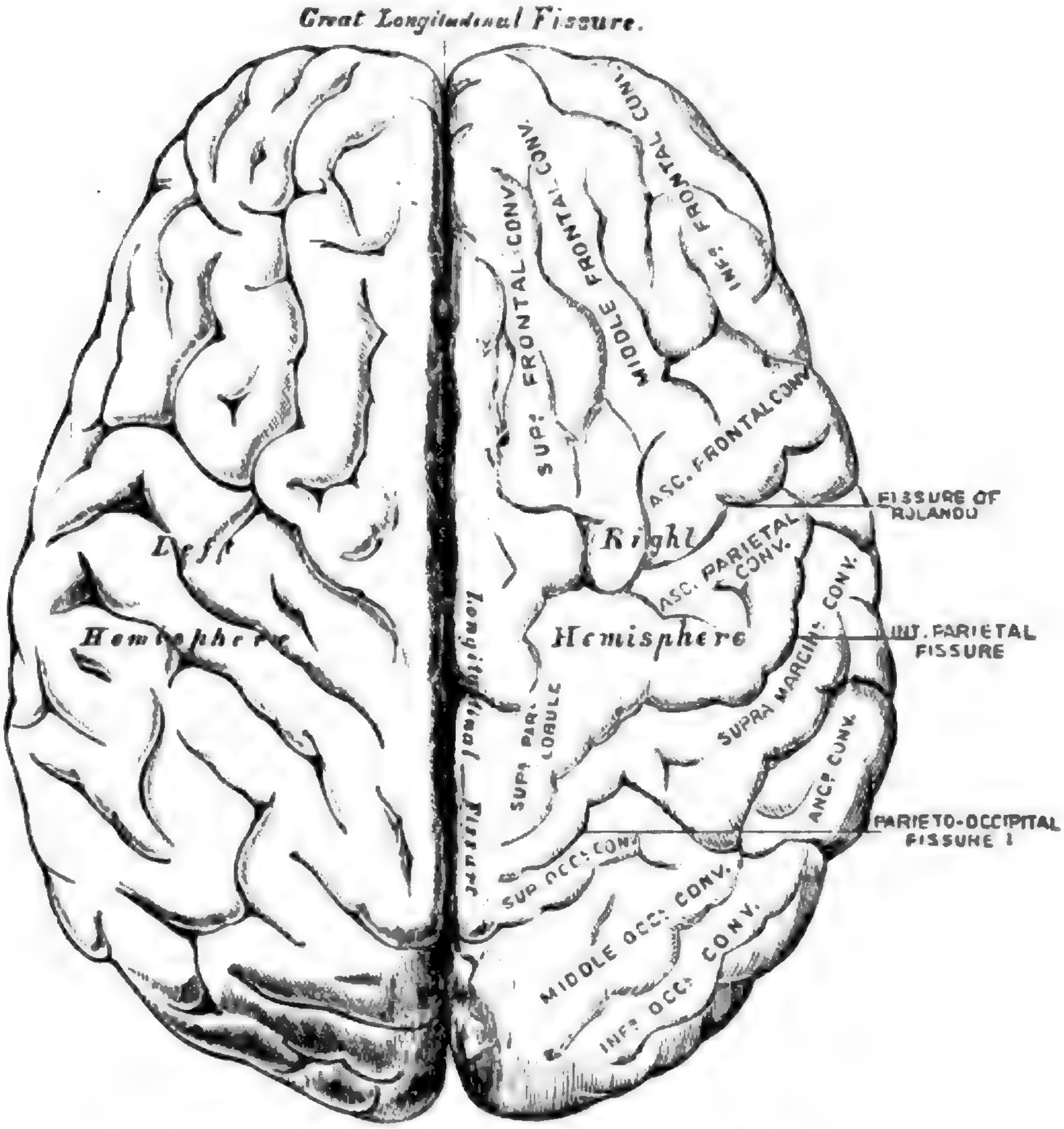
Great Longitudinal Fissure.
Left
Hemisphere
Right
Hemisphere
Longitudinal Fissure
SUP. FRONTAL CONV.
MIDDLE FRONTAL CONV.
INF. FRONTAL CONV.
ASC. FRONTAL CONV.
FISSURE OF ROLANDO
ASC. PARIETAL CONV.
INT. PARIETAL FISSURE
SUPRA MARGINAL CONV.
SUP. PAR. LOBULE
ANG. CONV.
PARIETO-OCCIPITAL FISSURE 1
SUP. OCC. CONV.
MIDDLE OCC. CONV.
INF. OCC. CONV.

Upper Surface of the Brain, the Arachnoid having been removed.

The **sulci** are generally an inch in depth; they vary in different brains and in different parts of the same brain; they are usually deepest on the outer convex surface of the hemispheres; the deepest is situated on the inner surface of the hem-

---

[1] In the specimen from which this figure was drawn the parieto-occipital fissure has been bridged over or obliterated by one of the annectant convolutions of the occipital lobe, but its continuation can be traced on the internal aspect of the hemisphere. (See Fig. 392, 3.)

[2] The student should bear in mind that it is extremely doubtful whether these laminæ, visible to the naked eye, correspond to the layers of which the cortical gray matter is said to be histologically composed, and which will presently be described.

isphere, on a level with the corpus callosum, and corresponds to the projection in the posterior horn of the lateral ventricle, *hippocampus minor*.

The number and extent of the convolutions, as well as their depth, appear to bear close relation to the intellectual power of the individual, as is shown in their increasing complexity of arrangement as we ascend from the lowest Mammalia up to man. Thus they are absent in some of the lower orders of Mammalia, and they increase in number and extent through the higher orders. In man they present the most complex arrangement. Again, in the child at birth, before the intellectual faculties are exercised, the convolutions have a very simple arrangement, presenting few undulations, and the sulci between them are less deep than in the adult. In old age, when the mental faculties have diminished in activity, the convolutions become much less prominently marked.

[FIG. 447.

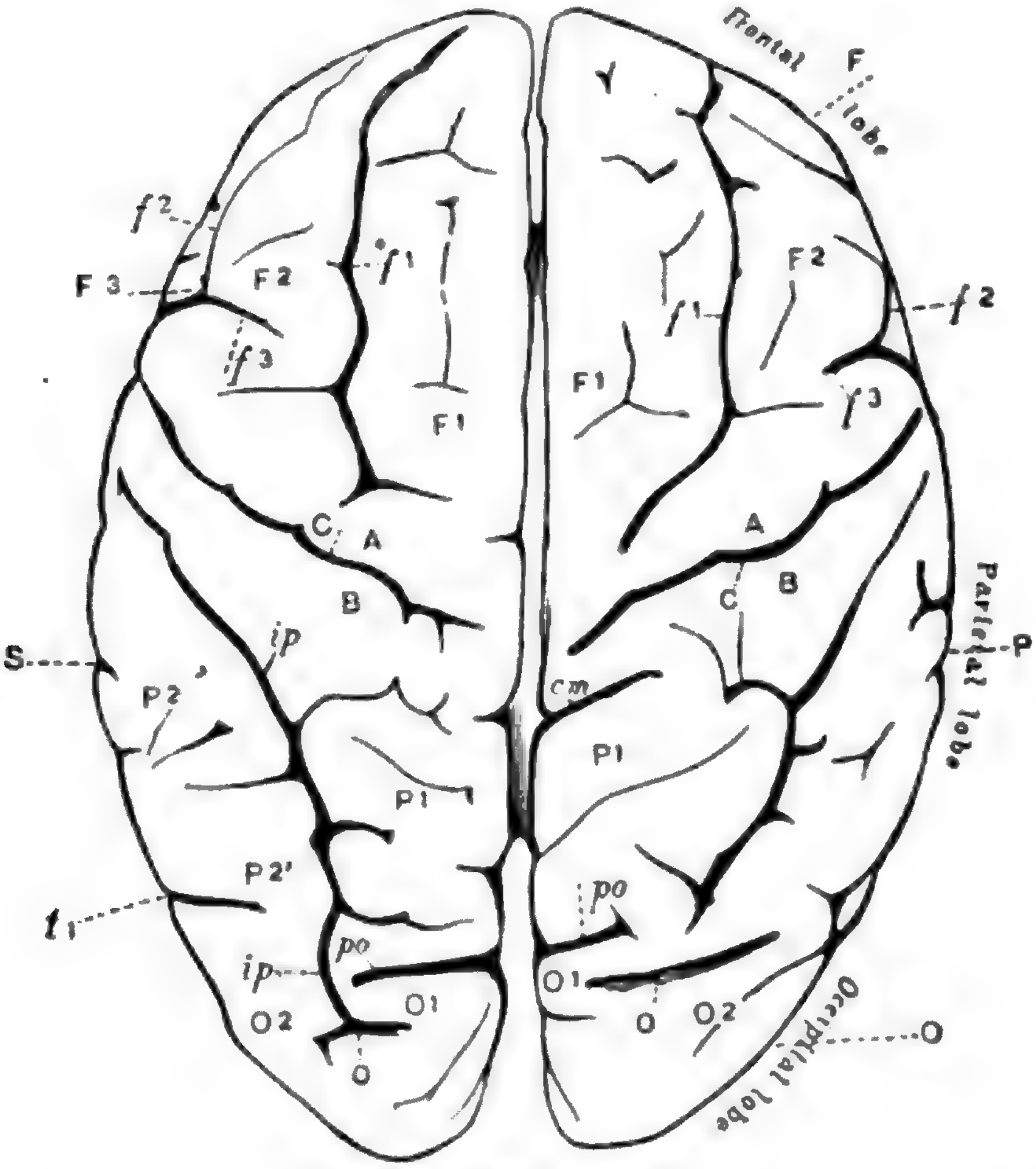

View of the Brain from Above.

F, frontal lobe; *P*, parietal lobe; *O*, occipital lobe; S_1, end of the horizontal branch of the fissura Sylvii; *c*, central fissure or fissure of Rolando; *A*, anterior central or ascending frontal convolution; *B*, posterior central or ascending parietal convolution; F_1, upper, F_2, middle, F_3, lower frontal convolution; f_1, superior frontal sulcus; f_2, inferior frontal sulcus; f_3, vertical fissure (sulcus præcentralis); P_1, upper or postero-parietal lobule; P_2, lower parietal lobule, constituted by P_2, gyrus supramarginalis, P_2', gyrus angularis; *ip*, interparietal sulcus; *cm*, calloso-marginal sulcus; *po*, parieto-occipital fissure; t_1, upper temporal fissure; O_1, first occipital convolution; O_2, second occipital convolution; *o*, sulcus occipitalis transversus.]

The **convolutions** on the outer convex surface of the hemisphere, the general direction of which is more or less oblique, are the largest and most complicated convolutions of the brain, frequently becoming branched like the letter Y in their course upward and backward toward the longitudinal fissure: these convolutions attain their greatest development in man, and are especially characteristic of the human brain. They are seldom [exactly] symmetrical on the two sides.

Fissures.—There are five principal fissures in the brain. Many of the larger sulci are, however, called fissures also, but these five are the chief landmarks: 1, The *great longitudinal fissure*, separating the two hemispheres; 2, the *great trans-*

verse fissure of Bichat, between the cerebrum and cerebellum, which admits the pia mater into the interior of the brain under the hinder end of the corpus callosum as the velum interpositum (see p. 696 and Fig. 475, 20, p. 701); 3, the *fissure of Sylvius;* 4, the *fissure of Rolando* (*c*, Figs. 447 and 448); 5, the *parieto-occipital fissure* (*po*). Of these fissures, the first two separate the great divisions of the brain, and the last three separate the lobes of the brain from each other. All other fissures are intralobular.[1] (For the topographical relations of the cerebral surface see p. 681.)

The **fissure of Sylvius** [*S*, *S′*, *S″*] begins at the base of the brain at the anterior perforated space, and, passing outward to the external surface of the hemisphere, divides into two branches: one, passing upward toward the longitudinal fissure, may be termed the *ascending* limb; the other, the longer one, running nearly horizontally backward, may be called the *horizontal* limb.[[2]]

[Fig. 448.

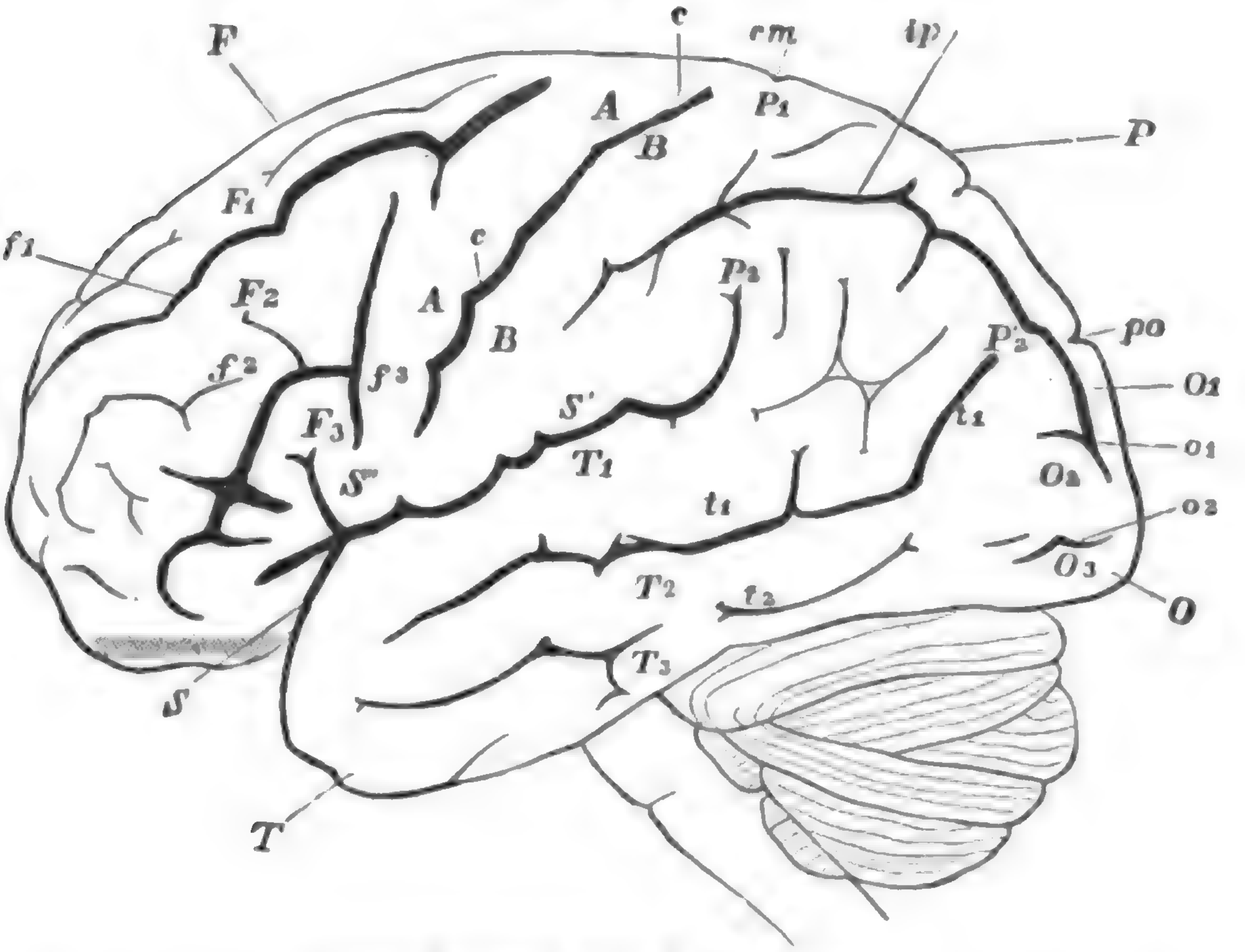

Outer Surface of the Left Hemisphere.

F, Frontal lobe; P, parietal lobe; O, occipital lobe; T, temporo-sphenoidal lobe; S, fissure of Sylvius, S′, horizontal, S″, ascending ramus of the same; *c*, sulcus centralis or fissure of Rolando; A, anterior central or ascending frontal convolution; B, posterior central or ascending parietal convolution; F_1, superior, F_2, middle, and F_3, inferior frontal convolutions; f_1, superior, and f_2, inferior frontal sulcus; f_3, sulcus præcentralis; P_1, superior parietal or postero-parietal lobule; P_2, inferior parietal lobule, viz.: P_2, gyrus supra-marginalis; P_2', gyrus angularis; *ip*, sulcus intra-parietalis; *cm*, termination of the calloso-marginal fissure; O_1, first, O_2, second, O_3, third occipital convolutions; *po*, parieto-occipital fissure; o_1, sulcus occipitalis transversus; o_2, sulcus occipitalis longitudinalis inferior; T_1, first, T_2, second, T_3, third temporo-sphenoidal convolutions; t_1, first, t_2, second temporo-sphenoidal fissures (Ecker).]

The **Fissure of Rolando** [*c*] is situated about the middle of the outer surface of the hemisphere. It commences at or near the great longitudinal fissure, half an inch behind the mid-point between the glabella and the external occipital protuberance, and runs downward and forward to terminate a little above the horizontal limb of the fissure of Sylvius. The upper two-thirds of its course lies at an angle of 67° with the great longitudinal fissure. It then becomes more vertical, forming a knee-like angle. In front and behind it are two very important convolutions, the ascending frontal and ascending parietal convolutions, united above in the *paracentral lobule*, and below in the *operculum*, which overhangs the island of Reil.

---

[1] [The nomenclature of the fissures and convolutions is by no means yet fixed in detail. The student must remember, therefore, that other names may be found in other text-books, and he must be careful not to become confused by them.]

[2] [Turner makes the anterior limb of this important fissure continuous with the precentral sulcus, and the English editor of Gray has followed this. As nearly all anatomists believe them to be separate, I have changed the text accordingly. In the figures in the English edition not only is the above represented, but the posterior limb of the Sylvian fissure and the intraparietal and the parieto-occipital fissures are all there represented as one continuous fissure, and both the frontal sulci join the precentral sulcus. I have substituted the more accurate plates of Ecker. In the text on the brain, while adhering as nearly as possible to the English edition, I have been compelled to make many changes that could not well be indicated by brackets. I have therefore omitted them entirely, except in references and to the section on Cerebral Localization and Topography, of which I have added the whole.]

The **Parieto-occipital Fissure** [*po*] is only seen to a slight extent on the outer surface of the hemisphere, and is not so distinctly marked as the others. The portion on the outer surface of the hemisphere is sometimes called the *external* parieto-occipital fissure, to distinguish it from the continuation of the sulcus on the internal surface of the hemisphere, which would then be termed the *internal* parieto-occipital fissure. It commences about midway between the posterior extremity of the brain and the fissure of Rolando, and runs downward and forward for a variable distance, becoming indistinct below.

Lobes.—These three fissures divide the external surface of the hemisphere into five lobes—the *frontal*, the *parietal*, the *occipital*, the *temporo-sphenoidal*, and the *central* or *island of Reil* [Figs. 447 to 450].

The **Frontal Lobe** is that portion of the brain which is situated in front of the fissure of Rolando and above the fissure of Sylvius. Its under surface rests on the orbital plate of the frontal bone, and is termed the *orbital* lobe.

The *precentral* or *vertical fissure* [f_3] runs upward through this lobe, dividing off a convolution which lies between it and the fissure of Rolando, and which is called the *ascending frontal convolution* [A]. The front portion of this lobe, on the outer surface, is divided into three principal convolutions by two antero-posterior sulci called the superior and inferior frontal sulci (f_1, f_2). The inferior sulcus (f_2) generally is united at a right angle with the precentral sulcus (f_3). The three convolutions are named respectively the *superior*, *middle*, *and inferior*, or first, second, and third frontal convolutions [F_1, F_2, F_3]. The third is often called Broca's convolution.

The under surface of the frontal lobe, which rests on the orbital plate of the frontal bone, is named the *orbital* lobe (Fig. 449.) It presents a well-marked groove or sulcus for the olfactory nerve which often covers most of the sulcus. The convolution internal to this sulcus [F_1] is the inferior part of the first frontal convolution. External to the sulcus this surface of the frontal lobe shows the lower ends of the second and third frontal convolutions [F_2, F_3], sometimes called here respectively the internal and external orbital convolutions. The second, owing to the short olfactory sulcus, is usually partly blended with the first.

The **Parietal Lobe** is bounded in front by the fissure of Rolando, behind by the parieto-occipital fissure, and below by the horizontal limb of the fissure of Sylvius, which separates it from the temporo-sphenoidal lobe. It presents four well-marked convolutions, more or less separated from each other by secondary fissures. Of these fissures, one, the *intraparietal* [*ip*] commences above the horizontal limb of the fissure of Sylvius, opposite the knee-like bend in the fissure of Rolando, and runs at first upward, parallel to and behind the fissure of Rolando, separating a convolution, the *ascending parietal* [B], which thus lies between the fissure of Rolando and the intraparietal fissure, and is parallel with the ascending frontal convolution. The intraparietal fissure then turns backward, runs parallel with the great longitudinal fissure, and separates a convolution, the *superior parietal* [P_1] (posterior parietal lobule), which lies along the margin of the longitudinal fissure. This is continuous in front with the ascending parietal convolution, and behind is limited by the parieto-occipital fissure. The remaining part of the parietal lobe—namely, that part between the intraparietal fissure above and in front and the horizontal limb of the fissure of Sylvius and the hinder part of the first temporal fissure below—is divided into two convolutions by a short vertical fissure: the anterior of these is the *supramarginal* [P_2] convolution, and the posterior the *angular* convolution [P_2'];

this latter convolution is joined with the temporo-sphenoidal and occipital lobes by small connecting convolutions. The upper ends of the ascending frontal and ascending parietal convolutions are known as the *paracentral lobule* (Fig. 450, Pc).

The **Occipital Lobe** is situated at the posterior extremity of the brain, and is separated above from the parietal lobe by the parieto-occipital fissure [*po*]; below and in front it is united with the temporo-sphenoidal and parietal lobes by small connecting convolutions. It is imperfectly divided by two small transverse fissures [o_1 o_2] into three convolutions, named respectively the *first, second,* and *third occipital* convolutions [O_1, O_2, O_3].

The **Temporo-sphenoidal Lobe** [T] is that portion of the hemisphere which is lodged in the middle fossa of the base of the skull. In front and above it is limited by the fissure of Sylvius; behind it is connected with the parietal and occipital lobes. It is divided into three convolutions by two antero-posterior fissures, the first and second *temporo-sphenoidal fissures* (t_1, t_2): of these, the upper one runs parallel to the horizontal limb of the fissure of Sylvius, and is hence sometimes named the *parallel* fissure. The three convolutions formed by these two fissures are named respectively the *first, second,* and *third temporo-sphenoidal* convolutions in their numerical order from above downward [T_1, T_2, T_3].

FIG. 449.

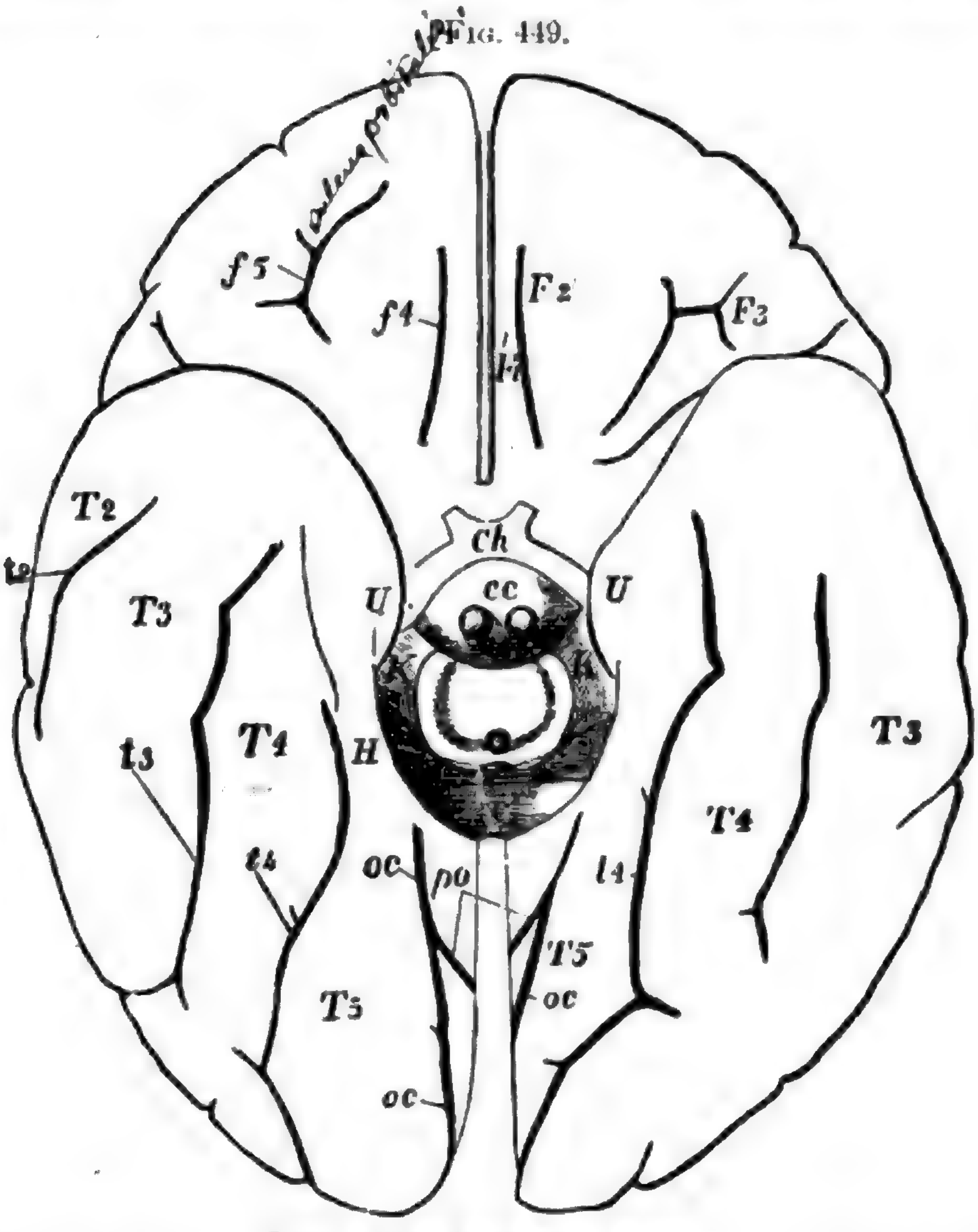

View of the Brain from below.

F_1, First frontal convolution or gyrus rectus; F_2, middle or second frontal; F_3, inferior or third frontal convolution; f_4, sulcus olfactorius; f_5, sulcus orbitalis; T_2, second or middle temporo-sphenoidal convolution; T_3, third or inferior temporo-sphenoidal convolution; T_4, gyrus occipito-temporalis lateralis lobulus fusiformis); T_5, gyrus occipito-temporalis medialis (lobulus lingualis); t_4, sulcus occipito-temporalis inferior; t_3, sulcus temporo-sphenoidalis inferior, or third temporal fissure; t_2, sulcus temporo-sphenoidalis medialis, or second temporal fissure; *po*, parieto-occipital fissure; *oc*, calcarine fissure; *H*, gyrus hippocampi; *U*, gyrus uncinarus; *Ch*, optic chiasma; *cc*, corpora albicantia; *KK*, crura cerebri; *C*, corpus callosum (Ecker).]

The **Central Lobe** or **Island of Reil** [or **Insula**] is best seen in section in Fig. 469, p. 693, and Fig. 470, p. 694. It is situated in the fissure of Sylvius at the base of the brain, and is hidden under the overhanging and fused lower ends of the ascending frontal and ascending parietal convolutions known as the operculum, being connected in front with the posterior extremity of the orbital lobe, and separated externally by a deep sulcus from the inferior frontal convolution and from the lower ends of the ascending frontal and parietal convolutions. It is a triangular-shaped prominent cluster of about six convolutions, the *gyri operti*, so called from being covered in by the sides of the fissure. By the removal of these convolutions the extraventricular part of the corpus striatum would be reached.

On the *inner* or *median* surface of the hemispheres the arrangement of the convolutions is less complex; they are generally well defined, and, some of them being of great length, there is not the same subdivision into smaller lobes as on the external surface (Fig. 450). The fissures on the internal surface are five in number, and are named the *calloso-marginal*, the *parieto-occipital*, the *calcarine*, the *collateral*, and the *dentate*.

[FIG. 450.

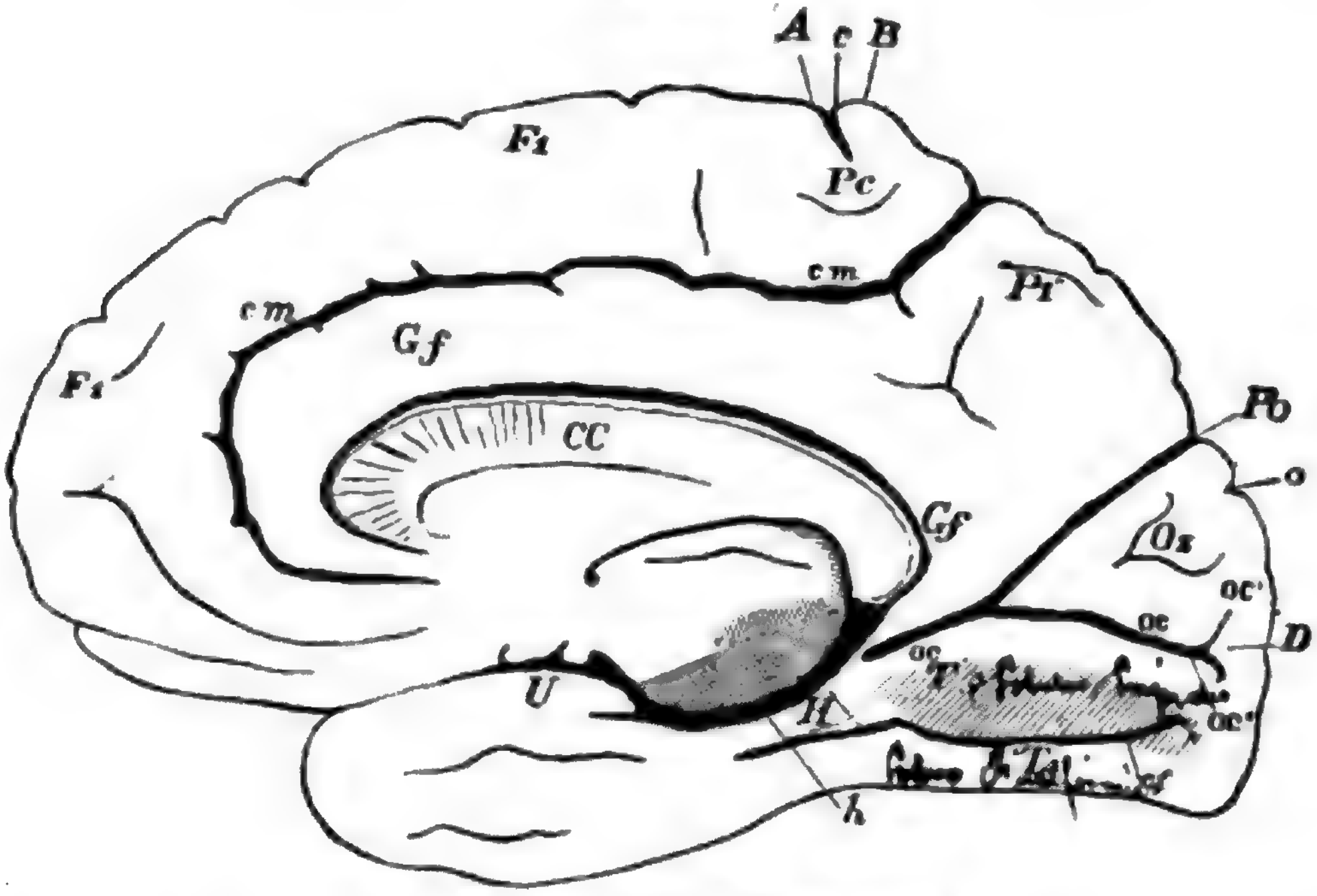

Inner Surface of Right Hemisphere.

CC, corpus callosum, longitudinally divided; *Gf*, gyrus fornicatus; H, gyrus hippocampi; *h*, sulcus hippocampi, or dentate fissure; U, uncinate gyrus; *cm*, sulcus calloso-marginalis; F_1, median aspect of the first frontal convolution; c, terminal portion of the sulcus centralis, or fissure of Rolando; A, ascending frontal; B, ascending parietal convolution; P_1'', precuneus; *oz*, cuneus; *po*, parieto-occipital fissure; *o*, sulcus occipitalis transversus; *oc*, calcarine fissure; *oc'*, superior, *oc''*, inferior ramus of the same; D, gyrus descendens; T_4, gyrus occipito-temporalis lateralis (lobulis fusiformis); T_5, gyrus occipito-temporalis medialis (lobulus lingualis); *ct*, collateral or occipito-temporal fissure (Ecker).]

The **calloso-marginal fissure** [*cm*] is seen in front, commencing below the anterior extremity of the corpus callosum; it at first runs forward and upward parallel with the rostrum of the corpus callosum, and, winding round the genu of that body, it continues from before backward between the upper margin of the hemisphere and the corpus callosum to about midway between the anterior and posterior extremities of the brain, where it turns upward to reach the upper margin of the inner surface of the hemisphere and joins the superior extremity of the fissure of Rolando or terminates in its immediate vicinity, generally behind it. It separates the marginal or first frontal convolution [F] from the gyrus fornicatus [G*f*].

The **parieto-occipital fissure** [*po*] (internal parieto-occipital) is the continuation of the short fissure of the same name seen on the outer surface of the hemisphere. It extends in a curved direction downward and forward to join the calcarine fissure. It separates the precuneus or quadrate lobe from the cuneate lobe [cuneus, *oz*].

The **calcarine fissure** [*oc*] commences usually by two branches [*oc'*, *oc''*] at the back of the hemisphere, runs nearly horizontally forward, and is joined by the parieto-occipital fissure, and continues as far as the posterior inferior extremity of the gyrus fornicatus. It separates the cuneate lobe [*oz*] from the lobulus lingualis [T_5].

The **collateral** or **occipito-temporal fissure** [c *f*] is situated below the preceding, being separated from it by the lingual lobule. It runs forward from the posterior extremity of the brain nearly as far as the commencement of the fissure of Sylvius. It lies below the posterior and middle horn of the lateral ventricle, and causes the prominence in the interior of the lateral ventricle known as the eminentia collateralis.

The **dentate fissure** or **sulcus hippocampi** (*h*) commences immediately below the posterior extremity of the corpus callosum, and runs forward to terminate at the recurved part or hook of the uncinate gyrus [U]. It corresponds with the prominence of the hippocampus major in the descending horn of the lateral ventricle.

The lobes or convolutions seen on the internal surface of the hemisphere are six in number, and are named *gyrus fornicatus, marginal, quadrate, cuneate, uncinate,* and *temporo-sphenoidal.*

The **gyrus fornicatus** [G *f*, G *f*], or convolution of the corpus callosum, begins just in front of the anterior perforated space at the base of the brain; it ascends in front of the genu of the corpus callosum and runs backward along the upper surface of this body to its posterior extremity, where it passes downward and forward under the name of the *gyrus hippocampi* (H) to terminate as the *uncinate gyrus* (U) nearly opposite where it began. It is bounded above by the calloso-marginal fissure [*cm*], which separates it from the marginal or first frontal convolution [F_1].

The **marginal** or **first frontal convolution** [F_1] is situated above the preceding, and has received its name from its position along the edge of the longitudinal fissure.

[FIG. 451.

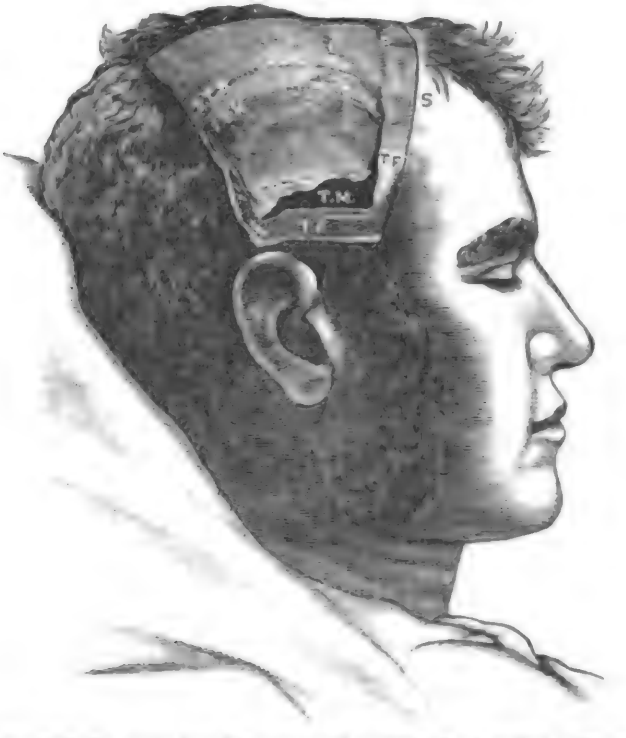

Head of a Cadaver from which the scalp has been removed opposite the so-called motor-region of the brain: S, edge of cut scalp; P, pericranium; C, coronal suture; S. T. R., ridge of temporal fascia, or superior temporal ridge (superior stephanion); I. T. R., ridge of temporal muscle, or inferior temporal ridge (inferior stephanion); S. Q., squamo-parietal suture; T. M., temporal muscle; T. F., temporal fascia (Horsley).]

It is the inner aspect of the first frontal convolution. It commences in front at the anterior perforated space, runs along the margin of the longitudinal fissure on the under surface of the orbital lobe, being bounded externally by the sulcus for the olfactory nerve: it then turns upward to the upper surface of the hemisphere, and runs backward, forming the marginal convolution on the inner surface to the point where the calloso-marginal fissure turns upward to reach the superior border of the hemisphere. Its posterior portion, in front of the precuneus or quadrate lobe, partially cut off by a fairly constant furrow at right angles to the corpus callosum, is known as the **paracentral lobule** (Pc). It is the fused upper ends of the ascending frontal (A) and ascending parietal (B) convolutions.

The **quadrate** lobule or **precuneus** ($\mathrm{P}_{1'}$) lies between the calloso-marginal fissure [*cm*] in front and the parieto-occipital [*po*] behind. Below it joins the gyrus fornicatus.

The **cuneus** or **occipital lobule** [*cuneus*, a wedge (oz)] is triangular in shape, being situated between the parieto-occipital [*po*] and calcarine fissure [*oc*], which, as above mentioned, meet behind the posterior extremity of the gyrus fornicatus.

[Fig. 452.

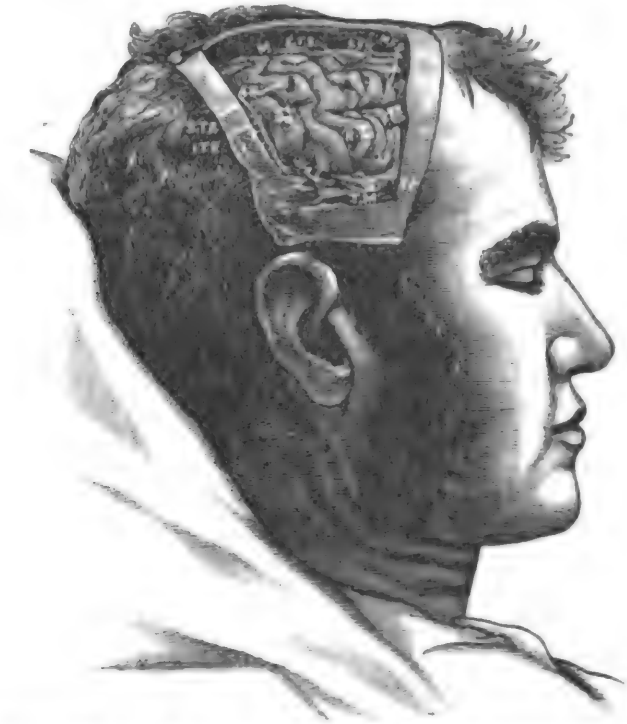

View of the same Head as Fig. 451, the base being removed by a vertical saw-cut through the inferior stephanion, by another along the squamo-parietal suture, by one parallel to the fissure of Rolando and just in front of the parietal eminence, and by one along the outer border of the sagittal suture: M, margin of the hemisphere; S. F. S., superior frontal sulcus; S. F. G., superior frontal gyrus; M. F. G., middle frontal gyrus; P. C. S., precentral or vertical sulcus; A. F., ascending frontal gyrus; A. P., ascending parietal gyrus; I. P., intraparietal sulcus; R, fissure of Rolando; S, fissure of Sylvius; T. M., temporal muscle; T. F., temporal fascia; S. T. R., superior temporal ridge (superior stephanion); I. T. R., inferior temporal ridge (inferior stephanion); U, subordinate sulcus in ascending frontal gyrus which unites the phonatory centre (Horsley).]

The **uncinate gyrus** [U] is the anterior inferior termination of the gyrus fornicatus (G*f*) through the gyrus hippocampi (H), and extends to the fissure of Sylvius, being bounded above by the dentate fissure [*h*], and separated below from the temporo-sphenoidal lobe by the collateral fissure [C *f*]. From the anterior extremity a narrow portion is recurved or bent backward in the form of a hook, which is sometimes called the *crochet* or *uncus*.

The Temporo-sphenoidal Lobe.—The temporo-sphenoidal lobe has on its outer surface the three convolutions already described. On its under and inner surface are two more, divided from each other by the collateral or occipito-temporal sulcus (C *f*). They are the lateral occipito-temporal convolution or fusiform lobule (T_4) and the median occipito-temporal convolution or lingual lobule (T_5).

Besides the great primary convolutions above named and described, and which can be recognized in almost any well-developed brain, there are a great number of secondary convolutions which pass from one to another of the primary, and often render the arrangement of the latter somewhat obscure; of these, the connections of the occipital lobe above mentioned, and which are named *annectant* convolutions, may be taken as examples.

[**Cerebral Localization and Topography.**—Within the last few years, as a result chiefly of experiment on the lower animals, the localization of various functions, especially those of motion, in different parts of the brain, has made great progress and become fairly definite. While the localities in which they are situated are not separated by hard and fast lines, they do occupy absolutely constant focal positions. In Figs. 453 and 454, from Ferrier, these localities, so far as ascertained at present, are indicated. Compare them with Figs. 455 to 463, from Horsley.

Approximately, as based on experiments on monkeys, and to some extent on observations on man, until further clinical and pathological demonstrations in man remove the probably slight errors, they must serve as working diagrams.

(1), on the postero-parietal lobule (precuneus)—the centres for movements of the opposite leg and foot in locomotion.

(2), (3), (4), at the upper end of the fissure of Rolando and hinder part of the first frontal convolution—the centres for various complex movements of the arms and legs, as in climbing, swimming, etc. In this area Horsley states that the arm and leg of the same side are involved together.

(5), at the posterior part of the superior frontal convolution—extension forward of the arm and hand, as in putting forth the hand to touch something in front.

(6), on the ascending frontal convolution just behind the upper and hinder end of the middle frontal convolution—movements of the hand and forearm, in which the Biceps is particularly engaged—viz. supination of the hand and flexion of the forearm.

(7) and (8), respectively for the elevators and depressors of the angle of the mouth.

(9) and (10), as one, mark the centre for movements of the lips and tongue, as in speech. This especially occupies the posterior portion of the inferior frontal (generally known as Broca's) convolution. Disease of this region on the left side produces aphasia.

(11), the centre for the Platysma, retraction of the angle of the mouth.

(12), a centre for lateral movements of the head and eyes, with elevation of the eyelids and dilatation of the pupils.

(13) and (13′), on the supramarginal lobule and angular gyrus, including also the occipital lobe, indicate the centre for vision.

(14), on the superior temporo-sphenoidal convolution, indicate the centre for hearing.

(*a*), (*b*), (*c*), (*d*), on the ascending parietal convolution, indicate the centres for movements of the fingers and wrist.

The centre for smell is situated in the hook of the hippocampal region (Fig. 450, U).

In close proximity, but not exactly defined as to limits, is the centre for taste.

The centre for touch is situated in the hippocampal region (Fig. 450, H) and gyrus fornicatus (G *f*).

Figs. 455 to 463, from Horsley, indicate similarly the localization of functions in the brain, and the student is referred to his paper[1] for a fuller description of the areas.

The relation that these localities of definite function in the brain bear to the exterior of the skull itself is of the greatest importance, for if accurately ascertained we can by means of it determine from the outside just where the fissures, sulci, and convolutions lie, and therefore where the above areas for certain functions are situated. Cerebral topography and localization have been utilized

---

[1] *Amer. Journ. Med. Sci.*, April, 1887.

[Fig. 453.

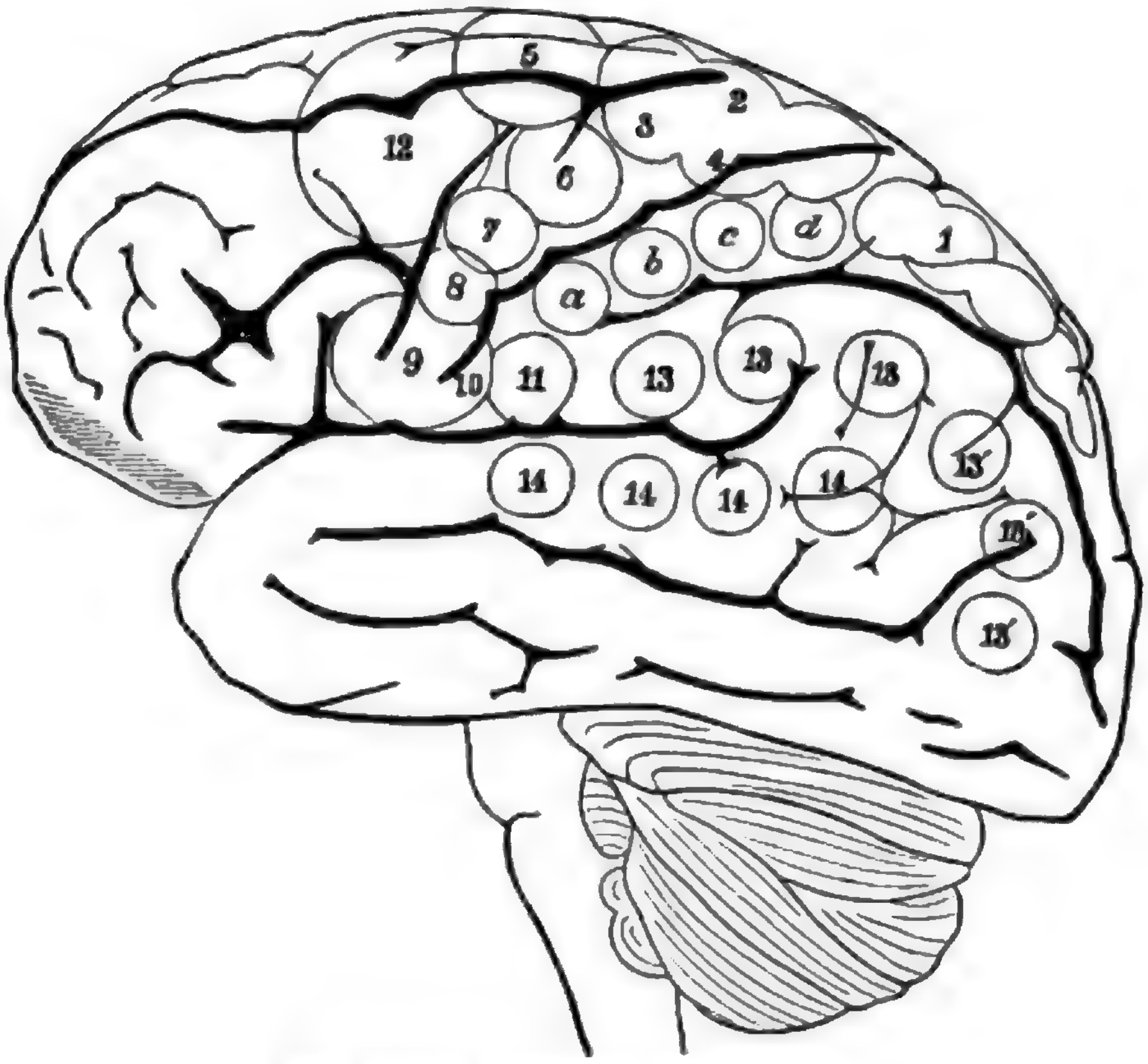
5
2
12
3
6
4
7
c
d
1
b
8
a
9
10
11
13
13
13
13'
14
14
14
14
13'
13'

Side View of the Brain of Man (Ferrier).]

[Fig. 454.

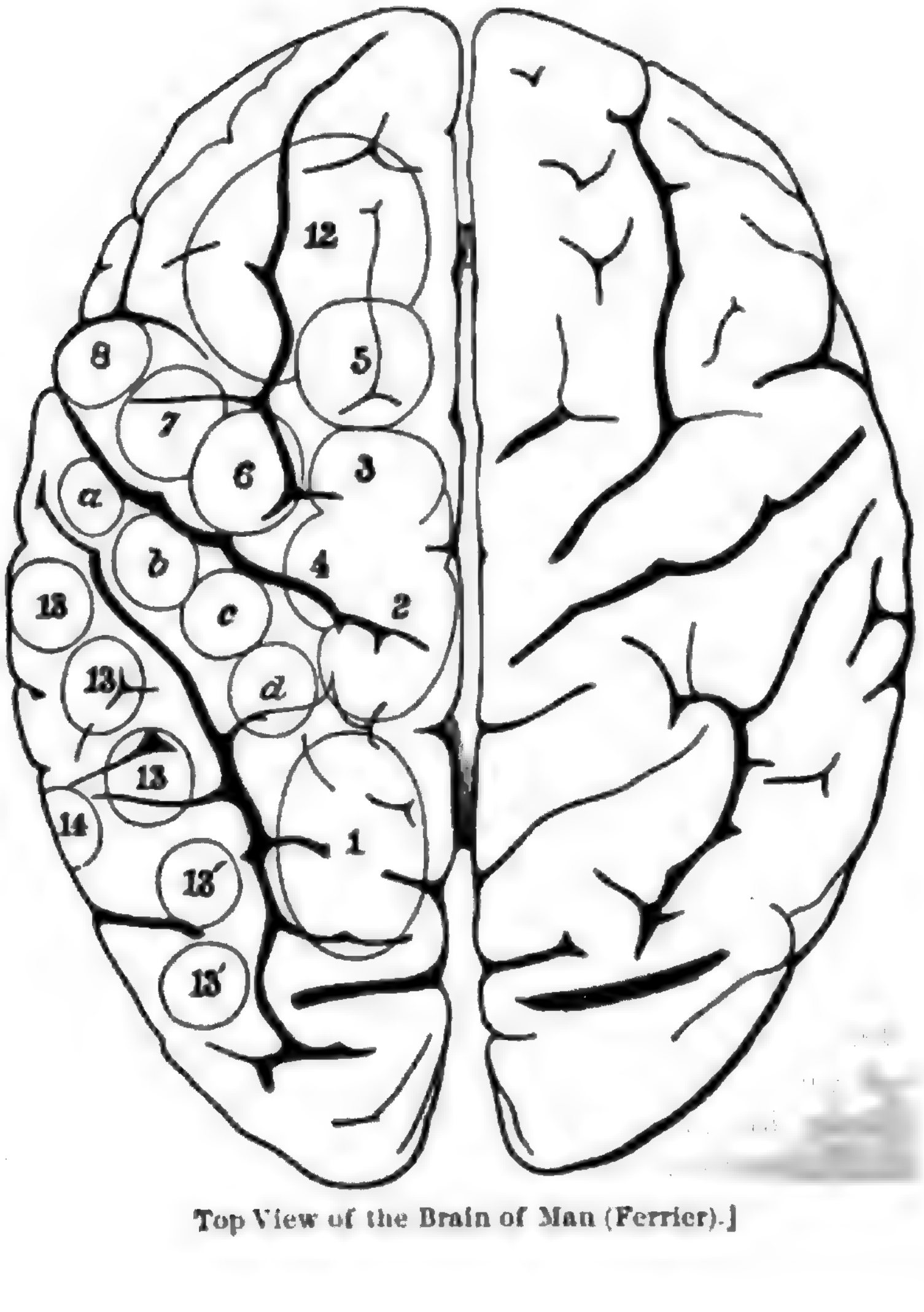
12
8
5
7
6
3
a
4
b
2
13
c
13
d
13
14
1
13'
13'

Top View of the Brain of Man (Ferrier).]

[FIG. 455.

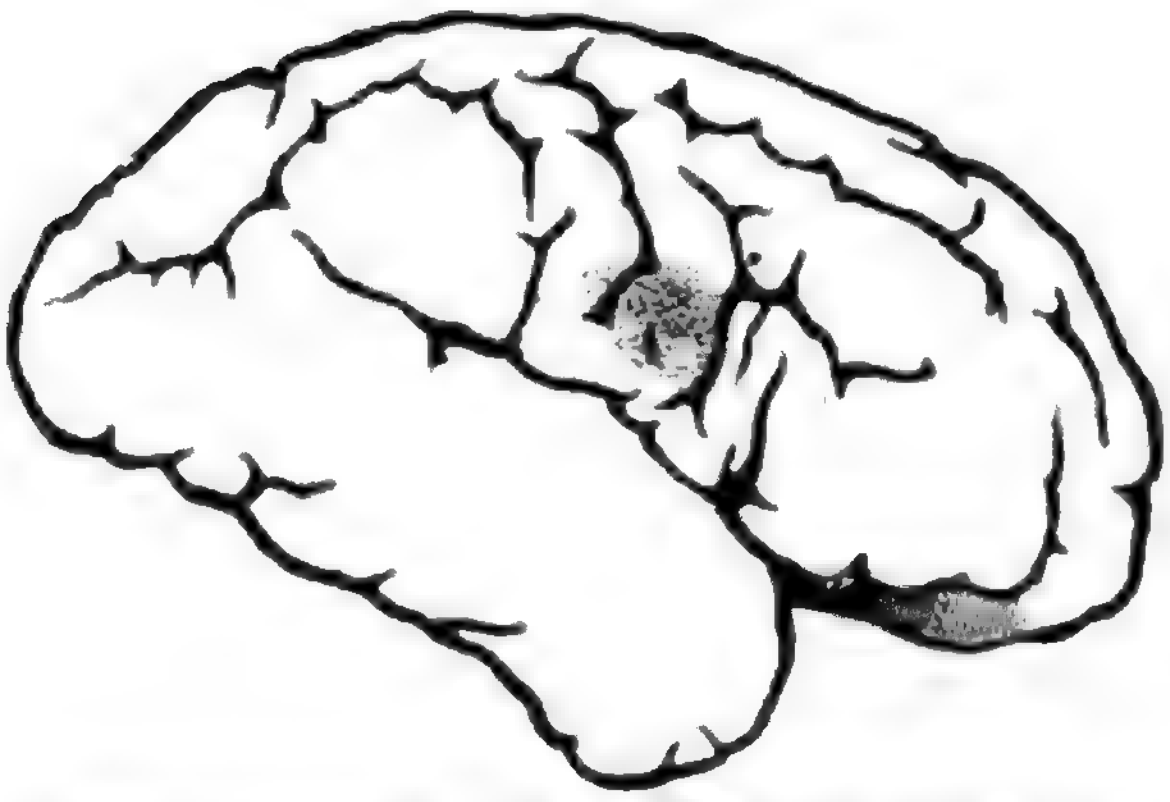

Representation of the Upper Face and Angle of the Mouth (Horsley).]

[FIG. 456.

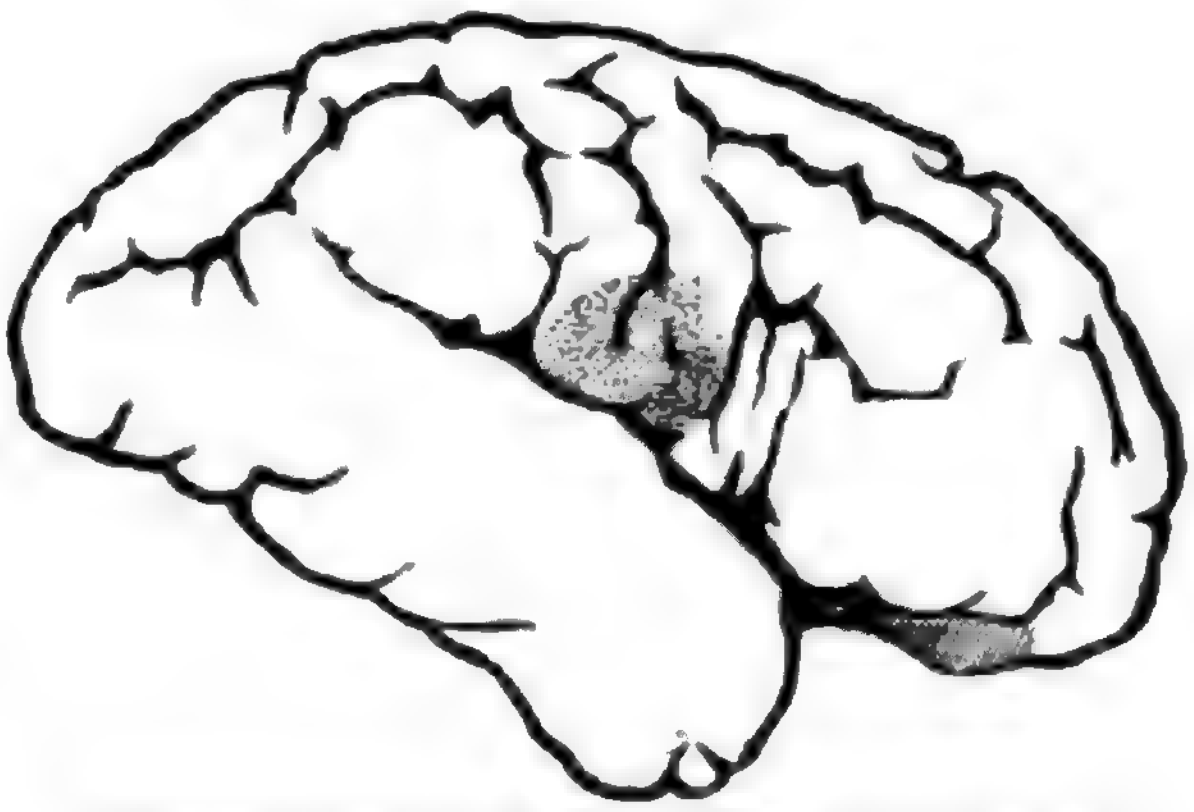

Representation of the Vocal Chords (adduction) (Horsley).]

[FIG. 457.

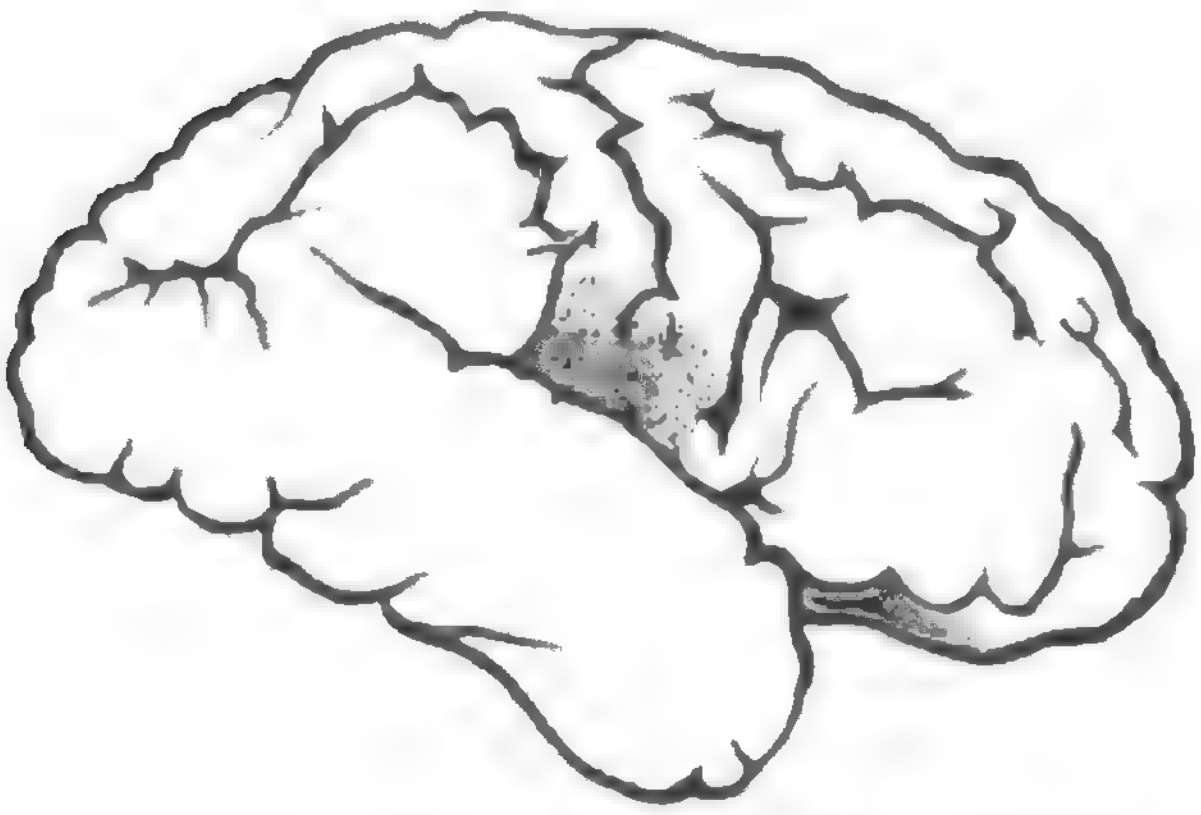

Representation of the Lower Face and Floor of the Mouth (Horsley).]

[FIG. 458.

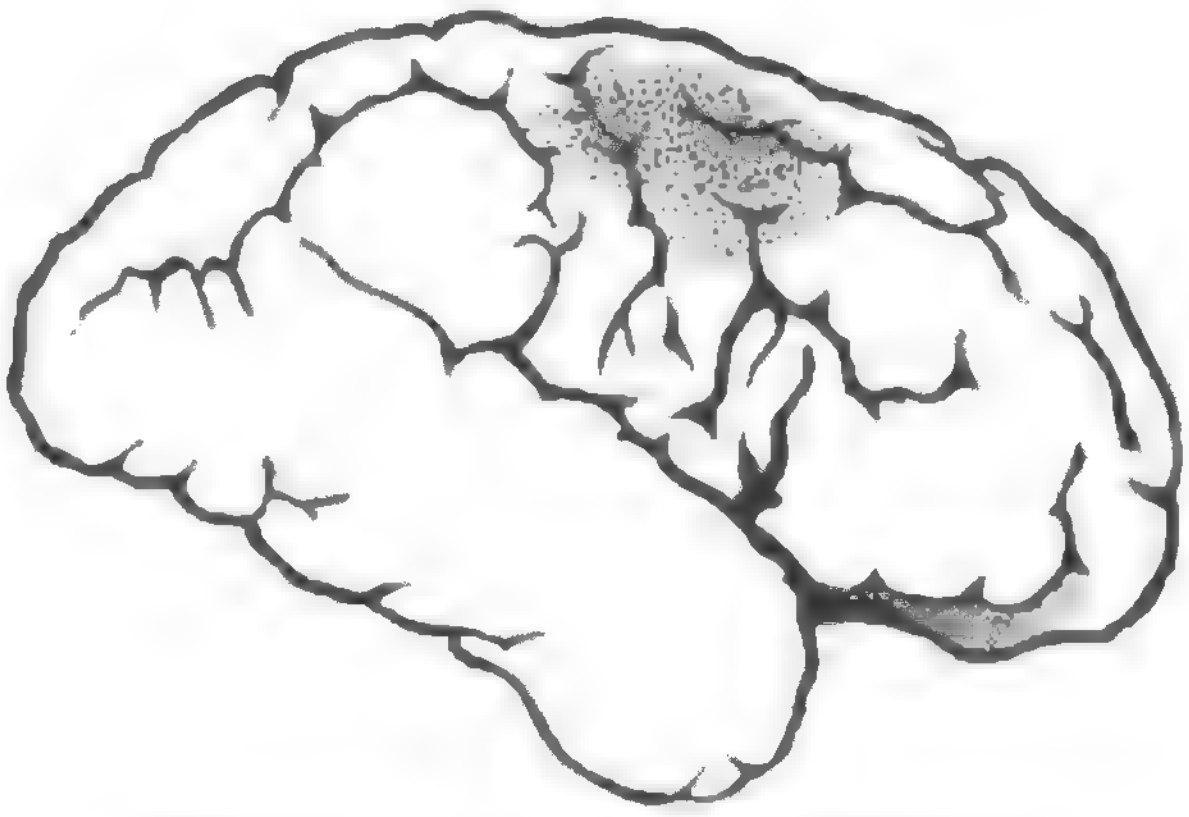

Representation of the Shoulder (Horsley).]

[FIG. 459.

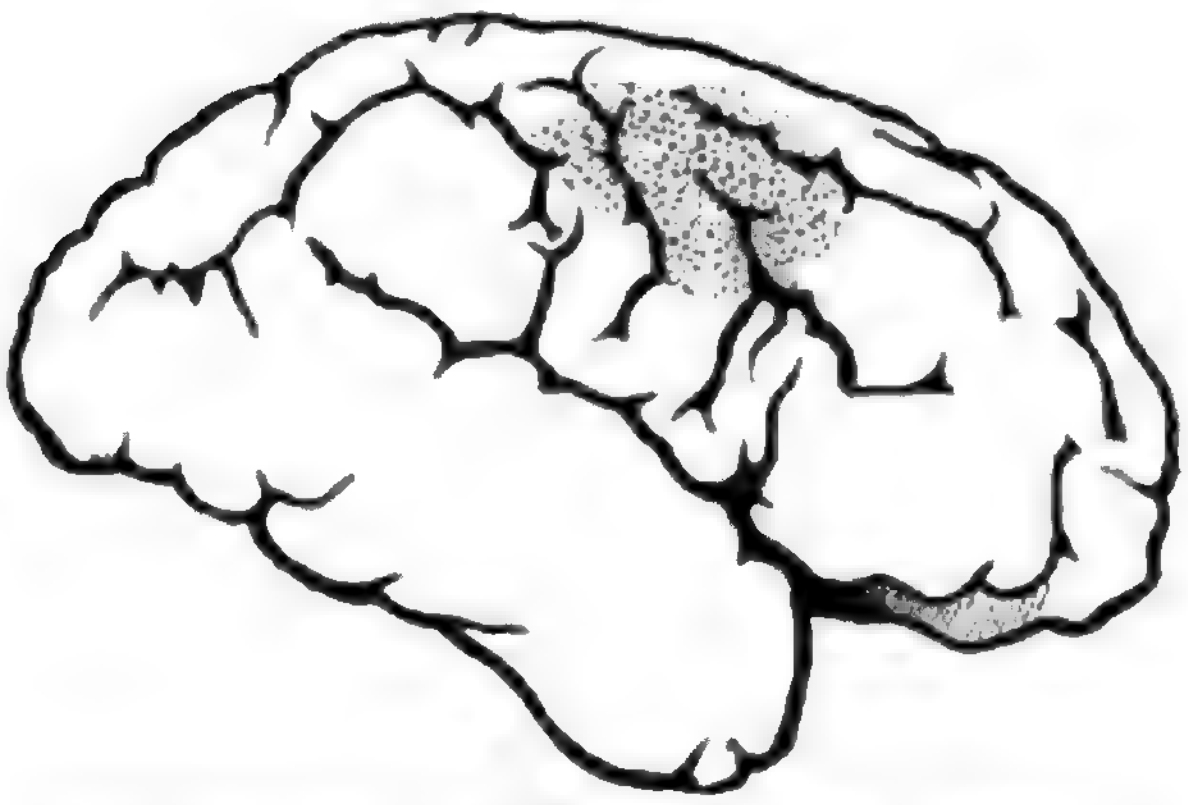

Representation of the Elbow and Wrist (Horsley).]

[FIG. 460.

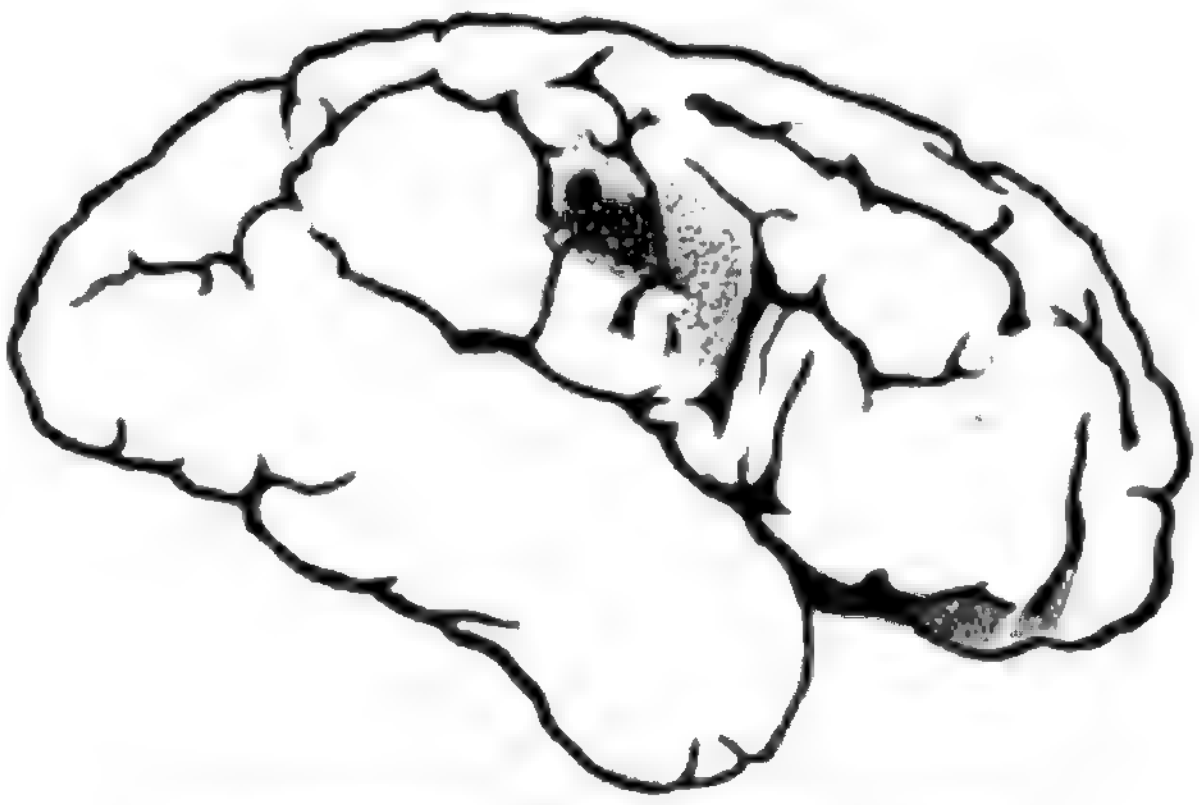

Representation of the Thumb (Horsley).]

[FIG. 461.

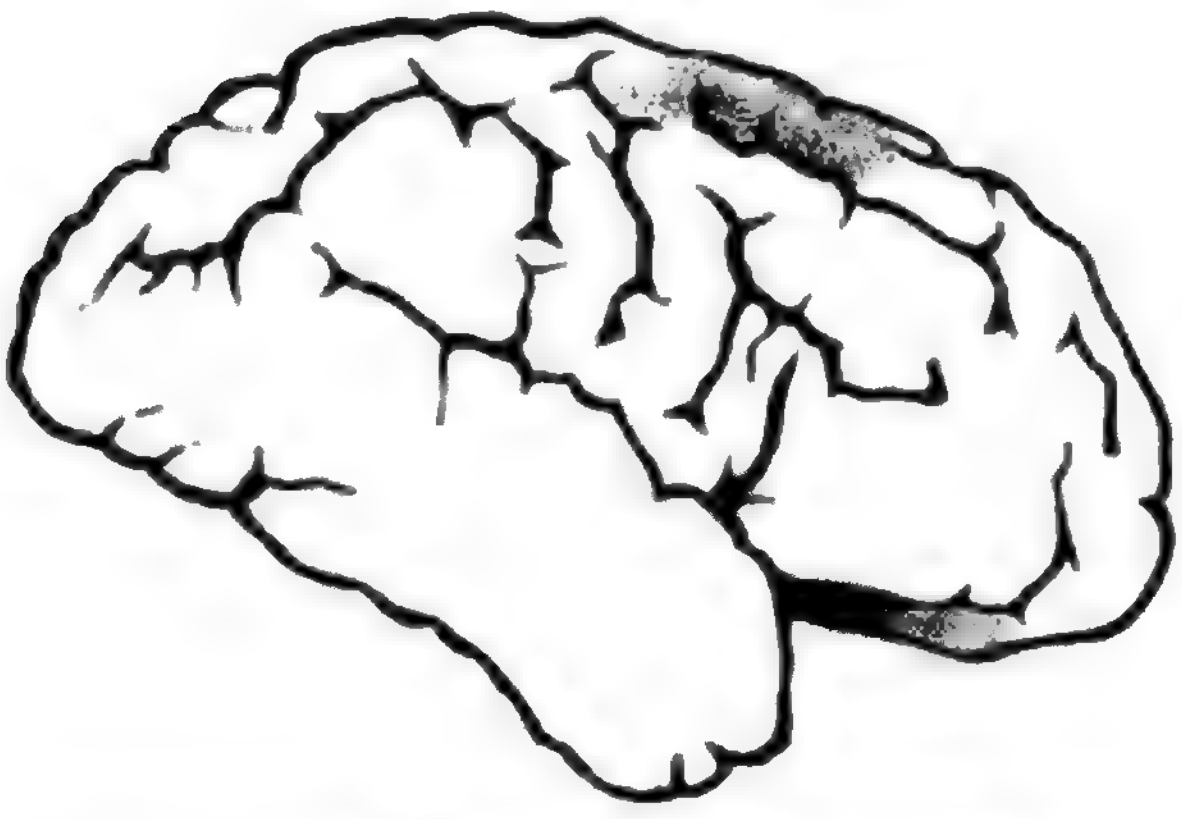

Reproduction of the Combined synchronous Action of both Limbs (Horsley).]

[FIG. 462.

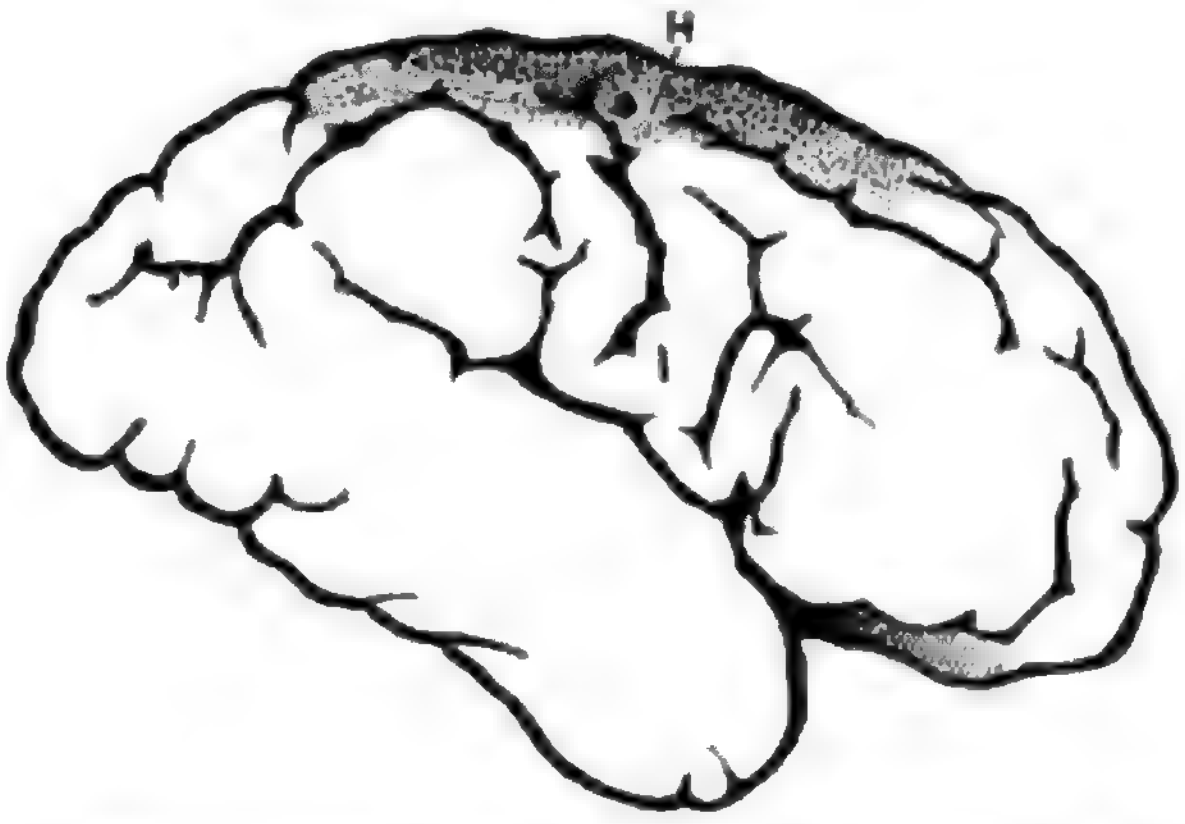

Representation of the Lower Limb: H, focus of Representation of the Hallux (Beevor and Horsley).]

Digitized

[Fig. 463.

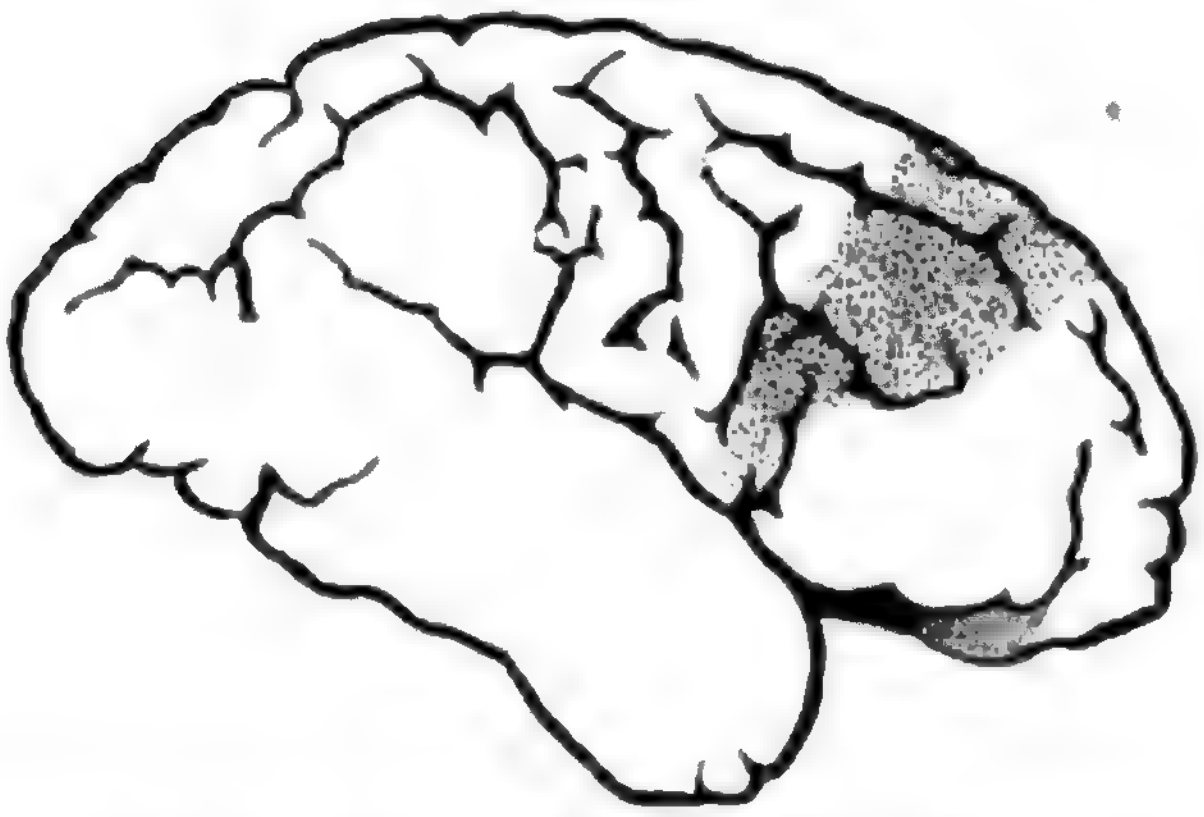

Representation of the Head and Neck, together with Conjugate Deviation of the Eyes (Horsley).]

recently in the most brilliant operations for the removal of tumors from the cerebrum by Godlee,[1] Horsley,[2] and Weir,[3] and others, and from the cerebellum by Horsley and May,[4] and for the relief of abscess of the brain, etc. The new field thus opened gives promise in the near future of the most extraordinary results.

The following brief account of the topographical relations of the brain (especially of the motor region) to the exterior of the skull is appended as the most serviceable statement that can at present be made.[5]

In determining the functional areas it is more important to be accurate vertically than horizontally, as the variation of function from above downward is greater than from before backward. In these areas "minimal stimulation"—that is, just sufficient electrical stimulation to produce any movement—is followed by movement of a certain segment of the body rather than of single muscles; and if the degree of stimulation be increased, neighboring centres, and therefore other segments of the body, are involved (*i. e.* primary and secondary movements).

Landmarks on the Skull.—The points to be determined on the skull are as follows: The frontal and parietal eminences can be easily defined by the eye and touch. The nasion, N (Broca), is the root of the nose. The ophryon (O) is the point where the middle line is crossed by a horizontal line at the level of the upper border of the eyebrows. It corresponds in general to the glabella or the elevation between the eyebrows. The inion (I) is the base of the external occipital protuberance. The stephanion (S) is the point where the upper temporal ridge—that is, the one for the temporal fascia—crosses the coronal sutures. This may be better called the upper stephanion, the lower stephanion (S′) being the intersection of the coronal suture and the ridge for the temporal muscle. The pterion (P) is the (usually) H-shaped junction of the parietal, great wing of the sphenoid, frontal, and temporal bones. The horizontal bar of the H, the spheno-parietal suture, slopes and lies halfway between the stephanion and the upper border of the zygoma, an inch and a half behind the external angular process.

The temporal ridges are two in number—the upper for the temporal fascia and the lower for the temporal muscle. The upper is the better marked, and can be easily followed by the finger from the external angular process backward. The lower one is best made out by closing and relaxing the jaw, when the upper edge of the bellying temporal muscle can be felt by the finger.[6] It also begins at the external angular process, but runs at a lower level than the fascial ridge, and at the middle is about two-fifths of an inch below it.

The sutures next must be fixed. The lambda (L) or the point of union of the sagittal and lambdoidal sutures, the posterior fontanelle, can be easily felt. From this the lambdoidal suture runs outward and downward on both sides, and can be determined with fair accuracy by pushing the scalp backward and forward, when its irregularities can be felt. From the lambda the sagittal suture runs in the median line forward till it meets the coronal suture at the bregma (B). This point can best be fixed by drawing a vertical line from ear to ear over the top of the head. Measurement of 185 skulls has given me, as a mean result, that the bregma lies 0.375 of an inch in front of the bi-auricular line. The greatest distance was 1.2 inches. In 16 of these skulls the bregma corresponded to the line exactly; in only 7 did it lie behind it, the maximum being 0.9 inch.

---

[1] *Lancet*, Dec. 20, 1884.

[2] *Brit. Med. Journ.*, Oct. 10, 1881, and April 23, 1887.

[3] *Medical News*, April 16, 1887.

[4] Horsley, *l. c.*; May, *Lancet*, April 16, 1887.

[[5] In this description I owe much to Mr. Horsley's article in the *Amer. Journ. Med. Sci.* for April, 1887. The student desirous of fuller information is referred to this paper; to Ferrier's *Functions of the Brain*; Reil, *Lancet*, 1884; Turner, *Journ. Anat. and Phys.*, 1873 and 1874, and other works.]

[[6] Horsley, as I think, incorrectly states that the lower (muscular) ridge only has been heretofore described. A reference to the text of earlier editions of Gray alone will show that the upper (fascial) ridge has been the one described. Broca and others also distinctly note both ridges.]

[Fig. 464.

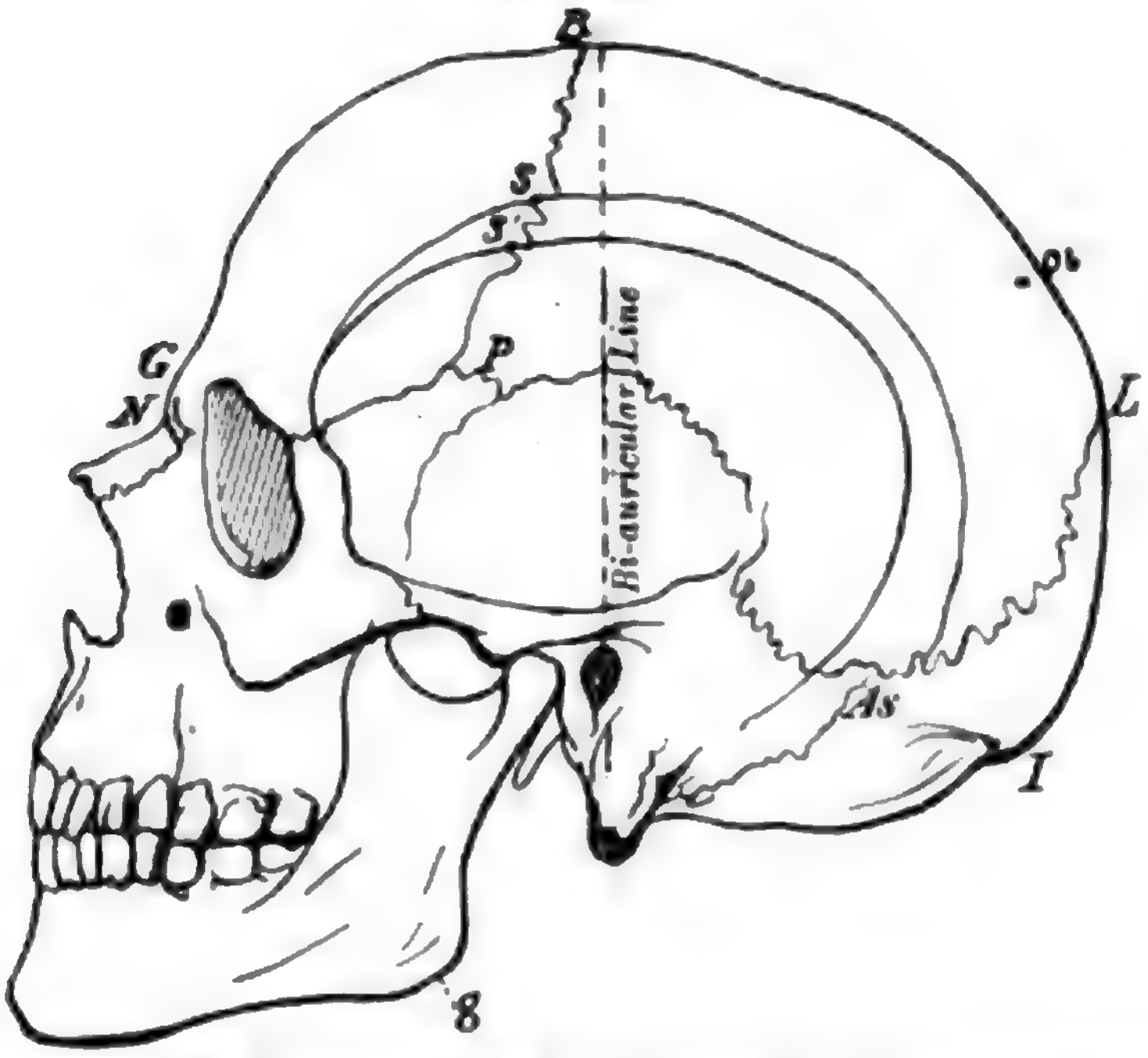

Skull showing the Points named by Broca.

N, Nasion (junction of the nasal and frontal).
G, Ophryon (on a level with the superior border of the eyebrows, and corresponding nearly to the glabella, the smooth swelling between the eyebrows).
B, Bregma (junction of the sagittal and coronal sutures).
Ob, Obelion (the sagittal suture between the parietal foramina).
L, Lambda (junction of sagittal and lambdoidal sutures).
I, Inion (external occipital protuberance).
Basion, middle of anterior wall of foramen magnum.
As, Asterion (junction of the occipital, parietal, and temporal bones).
g, Gonion (angle of the lower jaw)
S, Stephanion (or, better, the superior stephanion, intersection of ridge for temporal fascia and coronal suture).
S', Inferior stephanion (intersection of ridge for temporal muscle and coronal suture).
P, Pterion (point of junction of great wing of sphenoid and the frontal, parietal, and squamous bones. This may be H-shaped or K-shaped, or "returné," in which the frontal or temporal just touch.]

Starting from the bregma, by shoving the scalp backward and forward the fingers can perceive (with some difficulty, however, in certain cases, especially in the aged) the irregularities of the coronal suture, but toward the stephanion they become more marked, and can be pretty well appreciated. In case of difficulty it will assist in finding the suture if the generally well-marked groove on the parietal bone behind it, and slighter groove in the frontal bone in front of it, be recognized. The suture lies in the ridge between the two grooves. This suture and the two temporal ridges being determined, the upper and lower stephanions are fixed.

The arching squamo-parietal suture begins at the pterion. Its highest point is at the junction of the upper and middle thirds of a vertical line drawn from the upper border of the zygoma to the ridge of the temporal muscle, in front of the temporo-maxillary articulation.

Relation of the Fissures and Convolutions to the Landmarks on the Skull.—*Fissures and Sulci.*—The most important of the fissures to be fixed is the fissure of Rolando. Its upper end is (1) about 1⅛ to 2 inches behind the bregma (Broca, Turner, and others); or (2), measuring from the glabella backward, 55.7 per cent. of the distance between the anterior and posterior limits of the cerebrum—

i. e. from glabella to the inion (Hare); or (3) half an inch behind the mid-point of the line drawn from the glabella to the inion (Thane). This point being fixed, if a line be drawn downward and forward at an angle of 67°, it will give quite accurately the upper two-thirds of the fissure of Rolando. The lower third becomes somewhat more vertical, forming a knee-like bend. To fix this important fissure, Horsley fastens to the middle of a 10-inch strip of metal or of stout paper a second at an angle of 67°. Mark a scale of, say, quarter inches both forward and backward on each arm of the long median strip, the zero-point of which between the anterior and posterior scales, as suggested by Dr. Morris J. Lewis of Philada., shall be half an inch in front of the second arm. Placing this long strip in the middle line of the head, so that the reading of the scale at the glabella and inion shall be identical, the lateral strip will mark the upper two-thirds of the fissure of Rolando. The head should be shaved.

The fissure of Sylvius begins at the pterion (1⅛ inches behind the external angular process—Hare). The short anterior branch runs upward and forward, continuing the line of the squamo-sphenoidal suture, but one or two millimeters in front of it. The long posterior limb passes upward and backward half a millimeter above the squamo-parietal suture, as far as its highest point, and from there curves slightly upward toward the centre of the parietal eminence, which it nearly reaches. The anterior limb of this fissure runs just in front of the lower end of the coronal suture, and limits the motor area of the brain anteriorly, while its posterior limb limits the same area postero-inferiorly.

[FIG. 465.

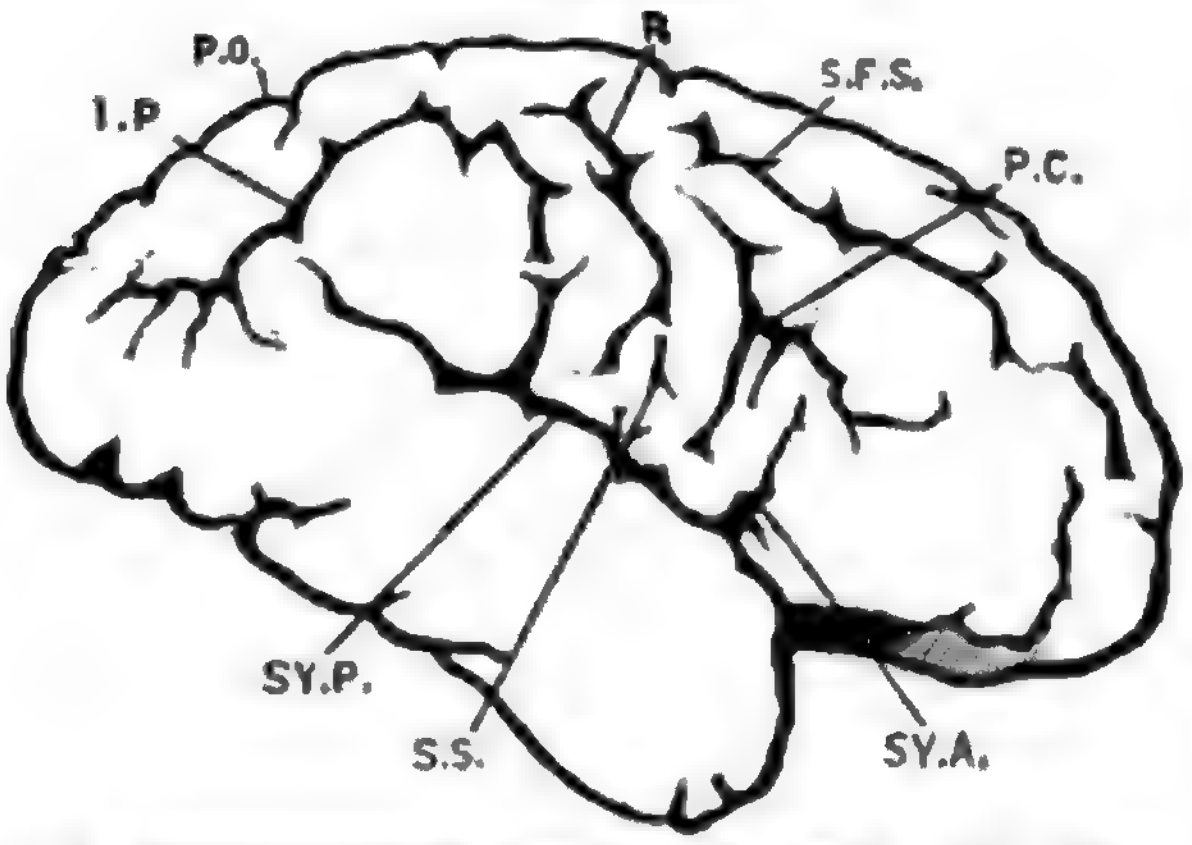

P.O., parieto-occipital fissure (external); I. P., intraparietal sulcus; R., fissure of Rolando; S. F. S., superior frontal sulcus; P. C., precentral sulcus (vertical) and inferior frontal sulcus (horizontal); Sy. A., anterior limb of the Sylvian fissure; Sy. P., posterior limb of the Sylvian fissure; S. S., subordinate sulcus separating area of absolute adduction of vocal chords. (Horsley.)]

The precentral sulcus is of great importance also, as it divides two convolutions of very different functions, and on each side of it has convolutions of great motor importance. It runs parallel to and just behind the coronal suture, and is almost vertical to a tangent at the bregma; hence its other name, the vertical sulcus. Its upper end reaches to the level of the middle of the fissure of Rolando. From it, about on the level of the superior temporal ridge (superior stephanion), the inferior frontal sulcus runs forward. Above the origin of this sulcus the precentral sulcus continues halfway across the root of the middle frontal convolution. Its lower end is separated from the fissure of Sylvius by a horseshoe-shaped convolution of great importance (the operculum), and nearly always one centimeter wide.

The superior frontal sulcus starts from the ascending frontal convolution midway between the fissure of Rolando and the line of the precentral sulcus. Its posterior end, therefore, lies behind the precentral sulcus. The superior and inferior frontal sulci run forward and slightly downward, practically parallel with the great longitudinal fissure.

The intraparietal sulcus lies behind the fissure of Rolando and bounds the motor area posteriorly. Its begins opposite the knee-like bend at the junction of the middle and lower thirds of the fissure of Rolando. As it goes upward it lies about midway between the Rolandic fissure and the parietal eminence. It then separates farther from the fissure of Rolando, and so widens the ascending parietal convolution that its upper end is known as a lobule—the superior parietal lobule. In the middle of its course it runs about parallel to the great longitudinal fissure and midway between it and the parietal eminence. Farther on it passes by the external end of the parieto-occipital fissure, and goes downward and backward into the occipital lobe.

The parieto-occipital fissure on the upper surface of the cerebrum is a short fissure about an inch long, at a right angle to the great longitudinal fissure, and two to three millimeters in front of the lambda.

The *convolutions* are mapped out so soon as we have fixed the sulci as above described, and it is not needful to enter into further details. The localization of function has been already stated (p. 681).

In estimating the motor value of the convolutions it must be remembered that the so-called motor cells are not found in the gray matter of the sulci deeper than the thickness of the cortical layer proper, and that faradism of the walls and floor of a sulcus evokes no movement. This function seems limited to the surface layer entirely.]

CEREBRUM, UNDER SURFACE OR BASE (Fig. 466).

The under surface of each hemisphere presents a subdivision, as already mentioned, into three lobes, named, from their position, anterior, middle, and posterior.

The *anterior* or *frontal lobe*, of a triangular form, with its apex backward, is somewhat concave, and rests upon the convex surface of the roof of the orbit, being separated from the middle lobe by the fissure of Sylvius. The *middle lobe*, which is more prominent, is received into the middle fossa of the base of the skull, and comprises the parietal and temporo-sphenoidal lobes. The *posterior* or *occipital lobe* rests upon the tentorium, its extent forward being limited by the anterior margin of the cerebellum.

The various objects exposed to view on the under surface of the cerebrum in and near the middle line are here arranged in the order in which they are met with from before backward:

Longitudinal fissure.
Corpus callosum and its peduncles.
Lamina cinerea.
Olfactory nerve.
Fissure of Sylvius.
Anterior perforated space.
Optic commissure.
Tuber cinereum.
Infundibulum.
Pituitary body.
Corpora albicantia.
Posterior perforated space.
Crura cerebri.

The **longitudinal fissure** partially separates the two hemispheres from one another: it divides the two anterior lobes in front, and on raising the cerebellum and pons it will be seen completely separating the two posterior lobes, the intermediate portion of the fissure being filled up by the great transverse band of white matter, the *corpus callosum*. Of these two portions of the longitudinal fissure, that which separates the posterior lobes is the longer. In the fissure between the two anterior lobes the anterior cerebral arteries may be seen ascending on the corpus callosum, and at the back part of this portion of the fissure the anterior curved portion of the corpus callosum descends to the base of the brain.

The **corpus callosum** terminates at the base of the brain by a concave margin, which is connected with the tuber cinereum through the intervention of a thin layer of gray substance, the *lamina cinerea*. This may be exposed by gently raising and drawing back the optic commissure. A broad white band may be observed on each side passing from the under surface of the corpus callosum backward and outward to the commencement of the fissure of Sylvius; these bands are called the *peduncles of the corpus callosum*. They may be traced upward around the genu to become continuous with the *striæ longitudinales* or *nerves of Lancisi* on the upper surface of the corpus callosum (Fig. 467, p. 691). Laterally, the corpus callosum extends into the anterior lobe. [It is the great transverse commissure connecting the two hemispheres.]

The **lamina cinerea** is a thin layer of gray substance extending backward above the optic commissure from the termination of the corpus callosum to the tuber cinereum; it is continuous on either side with the gray matter of the anterior perforated space, and forms the anterior part of the inferior boundary of the third ventricle. It connects the *genu* or reflected portion of the corpus callosum with the optic commissure, and is on this account described by Sappey as the gray root of the optic nerves.

The **olfactory nerve,** with its bulb, is seen on either side of the longitudinal fissure upon the under surface of each anterior lobe.

The **fissure of Sylvius** separates the anterior and middle lobes and lodges the middle cerebral artery. At its commencement is seen a point of medullary substance, corresponding to a subjacent band of white fibres, connecting the frontal and temporo-sphenoidal lobes, and called the *fasciculus unciformis;* on following this fissure outward it divides into two branches, which enclose the triangular-shaped prominent cluster of isolated convolutions called the *island of Reil* (*gyri operti*).

FIG. 466.

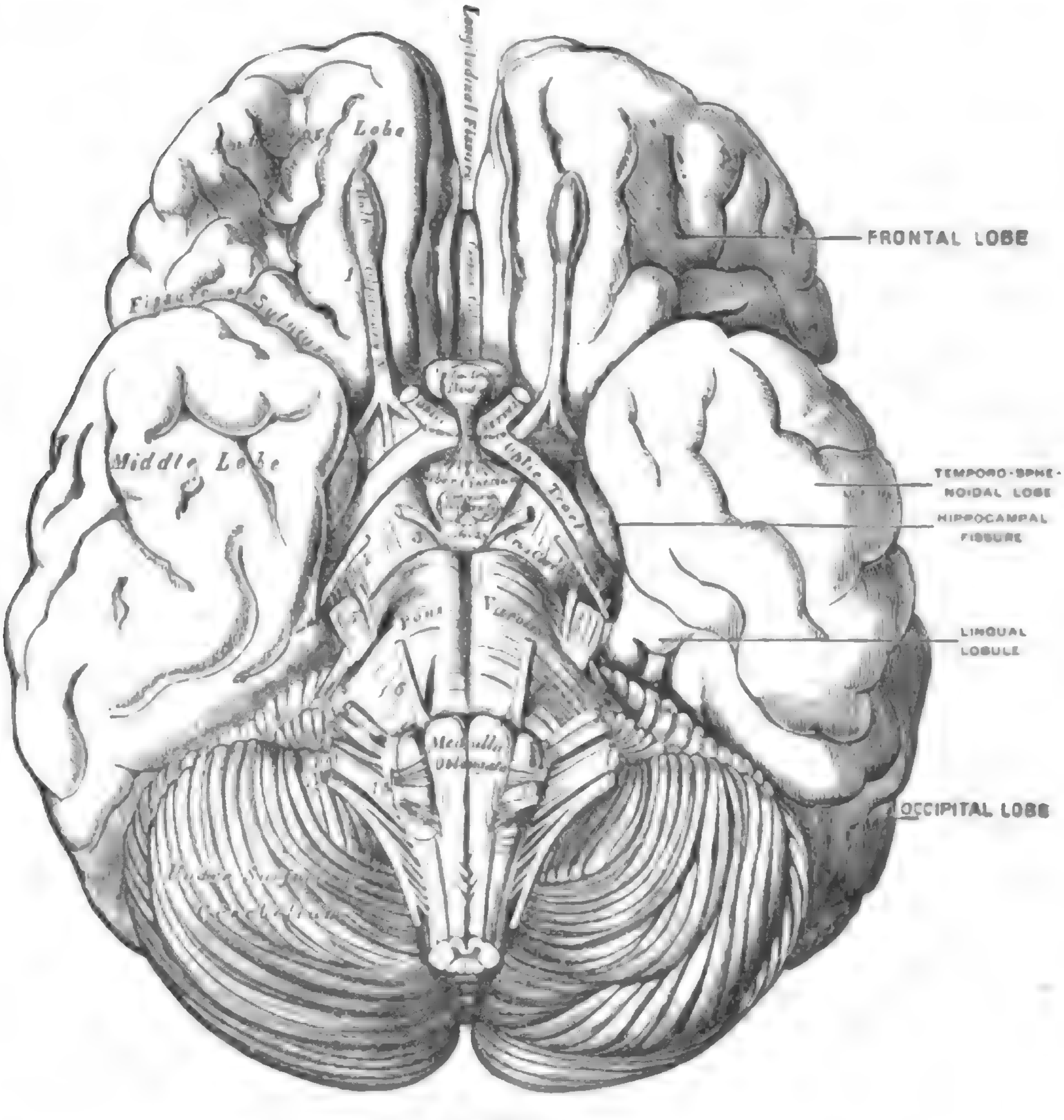
Longitudinal Fissure
Lobe
Fissure of Sylvius
Middle Lobe
Optic Tract
3
Pons
Varolii
6
Medulla Oblongata
FRONTAL LOBE
TEMPORO-SPHE-NOIDAL LOBE
HIPPOCAMPAL FISSURE
LINGUAL LOBULE
OCCIPITAL LOBE

Base of the Brain.

The **anterior perforated space (substantia perforata)** is situated at the inner side of the fissure of Sylvius. It is of a triangular shape, bounded in front by the convolutions of the anterior lobe and the roots of the olfactory nerve; behind by the optic tract; externally by the middle lobe and commencement of the fissure of Sylvius; internally, it is continuous with the lamina cinerea and crossed by the peduncle of the corpus callosum. It is of a grayish color, and corresponds to the under surface of the corpus striatum, a large mass of gray matter situated in the interior of the brain; it has received its name from being perforated by numerous minute apertures for the transmission of small straight vessels into the substance of the corpus striatum.

The **optic commissure** is situated in the middle line immediately in front of the tuber cinereum and below the lamina cinerea.[1] It is the point of junction between the two optic nerves.

Immediately behind the diverging optic tracts, and between them and the peduncles of the cerebrum (*crura cerebri*), is a lozenge-shaped interval, the *interpeduncular space*, in which are found the following parts: the tuber cinereum, infundibulum, pituitary body, corpora albicantia, and the posterior perforated space.

The **tuber cinereum** is an eminence of gray matter situated between the optic tracts and the corpora albicantia; it is connected with the surrounding parts of the cerebrum, forms part of the floor of the third ventricle, and is continuous with the gray substance in that cavity. From the middle of its under surface a conical tubular process of gray matter, about two lines in length, is continued downward and forward, to be attached to the posterior lobe of the pituitary body; this is the *infundibulum*. Its canal, which is funnel-shaped, communicates with the third ventricle.

The **pituitary body** (*hypophysis cerebri*) is a small reddish-gray vascular mass, weighing from five to ten grains and of an oval form, situated in the sella Turcica, in connection with which it is retained by a process of dura mater derived from the inner wall of the cavernous sinus. This process covers in the pituitary fossa, enclosing the pituitary body and having a small hole in its centre through which the infundibulum passes. It is very vascular and consists of two lobes, separated from one another by a fibrous lamina. Of these, the anterior is the larger, of an oblong form and somewhat concave behind, where it receives the posterior lobe, which is round. The two lobes differ both in development and structure. The *anterior* lobe, of a dark, yellowish-gray color, is developed from the ectoderm of the buccal cavity, and resembles to a considerable extent, in microscopic structure, the thyroid body. It consists of a number of isolated vesicles and slightly convoluted alveoli lined by epithelium and united together by connective tissue. The epithelium is columnar and occasionally ciliated. The alveoli sometimes contain a colloid material similar to that found in the thyroid body, and their walls are surrounded by a close network of lymphatics and capillary blood-vessels. The *posterior* lobe is developed by an outgrowth from the embryonic brain, and during fœtal life contains a cavity which communicates through the infundibulum with the cavity of the third ventricle. In the adult it becomes firmer and more solid, and consists of a sponge-like connective tissue arranged in the form of reticulating bundles, between which are branched cells, some of them containing pigment. In the lower animals the two lobes are quite distinct, and it is only in the Mammalia that they become connected together.

The **corpora albicantia or mamillaria** are two small round white masses, each about the size of a pea, placed side by side immediately behind the tuber cinereum. They are formed by the anterior crura of the fornix, hence called the *bulbs of the fornix*, which, after descending to the base of the brain, are folded upon themselves before passing upward to the thalami optici [Fig. 466, and Fig. 475, p. 701]. They are composed externally of white substance and internally of gray matter, the gray matter of the two being connected by a transverse commissure of the same material. At an early period of fœtal life they are blended together into one large mass, but become separated about the seventh month.

The **posterior perforated space** (*pons Tarini*) corresponds to a whitish-gray substance placed between the corpora albicantia in front, the pons Varolii behind, and the crura cerebri on either side. It forms the back part of the floor of the third ventricle, and is perforated by numerous small orifices for the passage of blood-vessels to the optic thalami.

The **crura cerebri** (*peduncles of the cerebrum*) are two thick cylindrical bundles of white matter which emerge from the anterior border of the pons and diverge as they pass forward and outward to enter the under part of either hemisphere. Each crus is about three-quarters of an inch in length and somewhat broader in front than behind. They are marked upon their surface with longitudinal striæ, and each is crossed, just before entering the hemisphere, by a flattened white band, the *optic tract*, which is adherent by its upper border to the peduncle. In the interior of the crura is contained a mass of dark gray matter called *locus niger*. The third nerve may be seen emerging from the inner side of either crus, and the fourth nerve winding round its outer side from above.

---

[1] That is to say, the commissure is superficial to the lamina in the order of dissection when the base is uppermost.

Each crus consists of a superficial and a deep layer of longitudinal white fibres continued upward from the pons: these layers are separated from each other by the locus niger.

The *superficial longitudinal fibres* are named the *crusta*. They consist of coarse fasciculi of nerve-fibres, which are collected on the under or free surface of the crus, and pass from the margin of the pons Varolii to the internal capsule and the cerebral hemisphere.

The *deep longitudinal fibres* or *tegmentum* form the posterior or deeper part of the crus cerebri. They consist of small masses of gray substance separated by longitudinal fibres, forming a well-marked *formatio reticularis* similar to that found in the pons and medulla, and with which it is connected. The longitudinal fibres are continuous with those of the pons derived from the olivary body and from the lateral and posterior columns of the medulla, and include fibres derived from the superior peduncle of the cerebellum. They enter the optic thalamus, in which some terminate, and others are continued through it into the cortex of the hemispheres.

The *locus niger* is a mass of gray matter situated between the superficial and deep layers of fibres above described. It is placed nearer the inner than the outer side of the crus. It contains small multipolar ganglion-cells, in which are lodged numerous dark pigment-granules.

The posterior lobes of the cerebrum are concealed from view by the upper surface of the cerebellum and pons Varolii. When these parts are removed the two hemispheres are seen to be separated by the great longitudinal fissure, this fissure being interrupted by the posterior rounded border of the corpus callosum.

GENERAL ARRANGEMENT OF THE PARTS COMPOSING THE CEREBRUM.

As the peduncles or crura of the cerebrum enter the hemispheres they diverge from one another so as to leave an interval between them, the *interpeduncular space*. As they ascend, the component fibres of each pass through two large masses of gray matter, the ganglia of the brain, called the *thalamus opticus* and *corpus striatum*, which project as rounded eminences from the upper and inner side of each peduncle. The hemispheres are connected together, above these masses, by the great transverse commissure, the *corpus callosum*, and the interval left between its under surface, the upper surface of the ganglia, and the parts closing the interpeduncular space forms the general ventricular cavity. The upper part of this cavity is subdivided into two by a vertical septum, the *septum lucidum*, and thus the two lateral ventricles are formed. The lower part of the cavity forms the third ventricle, which communicates with the lateral ventricles above and with the fourth ventricle behind. The fifth ventricle is the interval left between the two layers composing the septum lucidum.

INTERIOR OF THE CEREBRUM.

If the upper part of either hemisphere is removed with a scalpel, about half an inch above the level of the corpus callosum its internal white matter will be exposed. It is an oval-shaped centre of white substance surrounded on all sides by a narrow convoluted margin of gray matter which presents an equal thickness in nearly every part. This white central mass has been called the *centrum ovale minus*. Its surface is studded with numerous minute red dots (*puncta vasculosa*), produced by the escape of blood from divided blood-vessels. In inflammation or great congestion of the brain these are very numerous and of a dark color. If the remaining portion of one hemisphere is slightly separated from the other, a broad band of white substance will be observed connecting them at the bottom of the longitudinal fissure; this is the *corpus callosum*. The margins of the hemispheres, which overlap this portion of the brain, are called the *labia cerebri*. Each labium is part of the convolution of the corpus callosum (*gyrus fornicatus*), already described, and the space between it and the upper surface of the corpus callosum has been termed the *ventricle of the corpus callosum* (Fig. 471, 2).

The hemispheres should now be sliced off to a level with the corpus callosum, when the white substance of that structure will be seen connecting the two hemispheres. The large expanse of medullary matter now exposed, surrounded by the convoluted margin of gray substance, is called the *centrum ovale majus* of Vieussens.

FIG. 467.

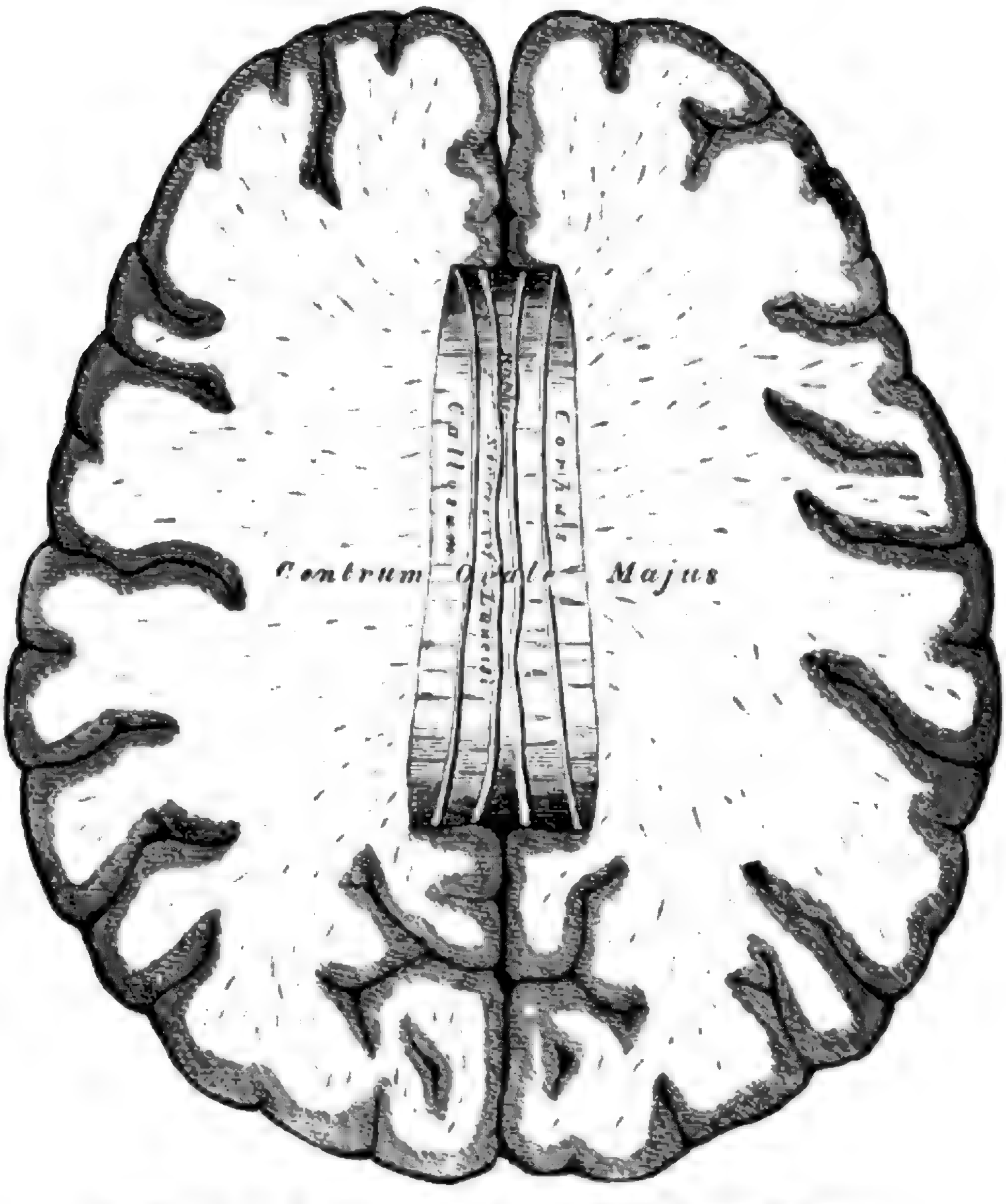

Section of the Brain, made on a level with the Corpus Callosum.

The Corpus Callosum is a thick stratum of transverse fibres exposed at the bottom of the longitudinal fissure. It connects the two hemispheres of the brain, forming their great transverse commissure, and forms the roof of a space in the interior of each hemisphere, the *lateral ventricle*. It is about four inches in length, extending to within an inch and a half of the anterior and to within two inches and a half of the posterior part of the brain. It is somewhat broader behind than in front, and is thicker at either end than in its central part, being thickest behind. It presents a somewhat arched form (Fig. 475, 5, p. 701) from before backward, terminating anteriorly in a rounded border which curves downward and backward between the anterior lobes to the base of the brain. In its course it forms a distinct bend, named the *genu*, and is then continued downward and backward to the base of the brain, where it is connected, through the lamina cinerea, with the tuber cinereum.

The reflected portion of the corpus callosum is called the *beak* or *rostrum*; it becomes gradually narrower as it descends, and is attached by its lateral margins to the frontal lobes. At its termination the corpus callosum gives off two bundles of white substance, which, diverging from one another, pass backward, across the anterior perforated space, to the entrance of the fissure of Sylvius. They are called the *peduncles* of the corpus callosum. Posteriorly, the corpus callosum forms a thick rounded fold called the *splenium* or *pad*, which is free for a little distance as it curves forward, and is then continuous with the fornix. On its upper surface the fibrous structure of the corpus callosum is very apparent, being collected into coarse transverse bundles. Along the middle line is a linear depression, the *raphé*, bounded laterally by two or more slightly elevated longitudinal bands, called the *striæ longitudinales* or *nerves of Lancisi*; and still more externally other longitudinal striæ are seen beneath the convolutions which rest on the corpus callosum. These are the *striæ longitudinales laterales*. The under surface of the corpus callosum is continuous behind with the fornix, being separated from it in front by the septum lucidum, which forms a vertical partition between the two ventricles. On either side the fibres of the corpus callosum penetrate into the substance of the hemispheres, and connect together the anterior, middle, and part of the posterior lobes. It is the large number of fibres derived from the anterior and posterior lobes which explains the great thickness of the two extremities of this commissure.

An incision should now be made through the corpus callosum, on either side of the raphé, when two large irregular-shaped cavities will be exposed which extend through a great part of the length of each hemisphere. These are the lateral ventricles.

The **lateral ventricles** are serous cavities formed by the upper part of the general ventricular space in the interior of the brain. They are lined by a thin, diaphanous lining membrane covered by nucleated epithelium (*the ependyma*), with cilia scattered here and there in patches. It is moistened by a serous fluid, which is sometimes, even in health, secreted in considerable quantity. These cavities are two in number, one in each hemisphere, and they are separated from each other by a vertical septum, the *septum lucidum*.

[Fig. 468.

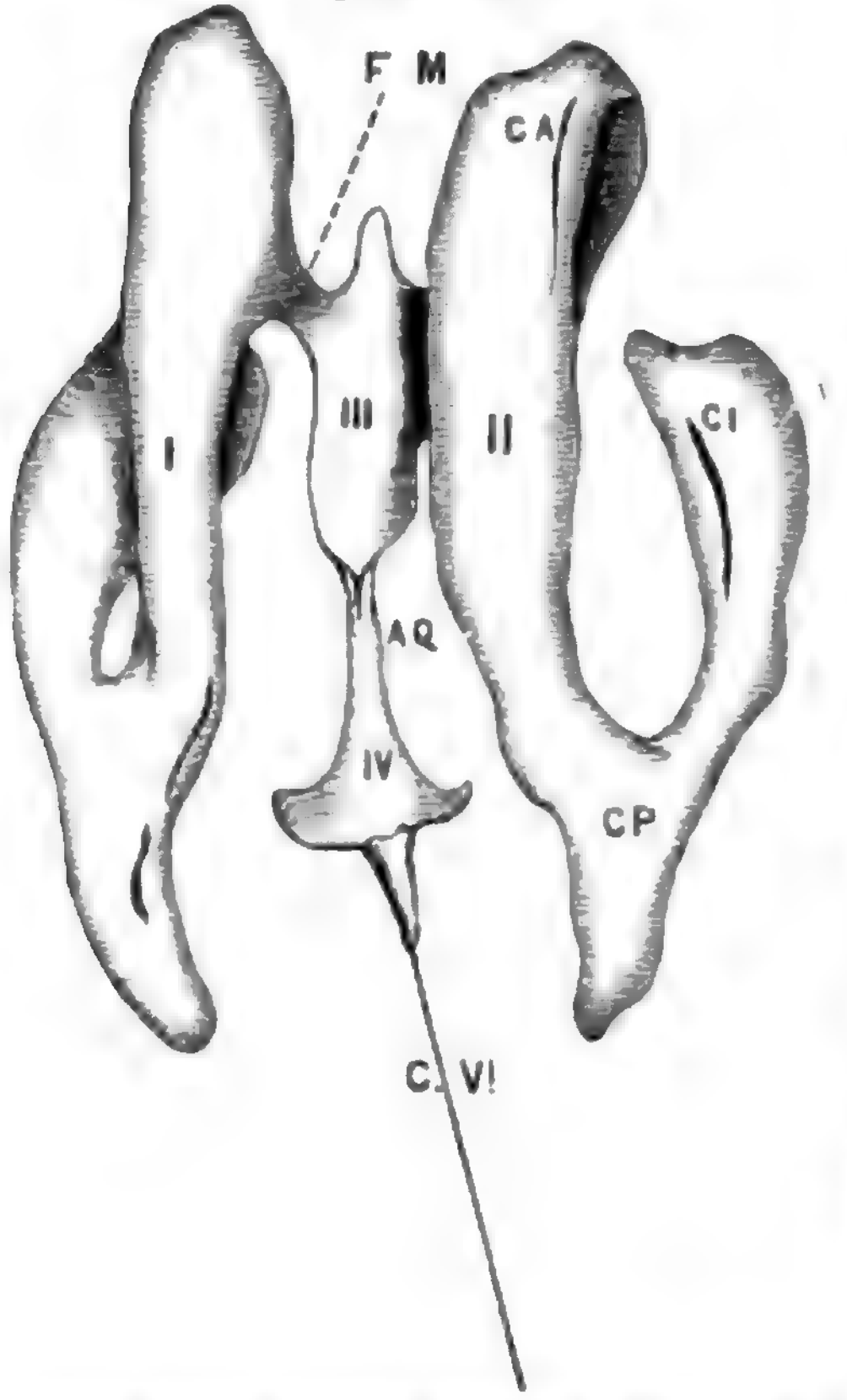

Cast showing Form of the Cavities (ventricles) in the Brain: I, II, Two lateral ventricles: CA, cornu anterior; CP, cornu posterior; CI, cornu inferior. III, Third ventricle: FM, foramen of Monro; AQ, aqueduct of Sylvius, or iter e tertio ad quartum ventriculum. IV, Fourth ventricle; C.VI, This line indicates the prolongation of the fourth ventricle into the ventricle of the cord (or sixth ventricle), or central canal (altered from Féré).]

Each lateral ventricle consists of a central cavity or *body*, and three smaller cavities or *cornua* which extend from it in different directions. The anterior cornu curves forward and outward into the substance of the anterior lobe. The posterior cornu, called the *digital cavity*, curves backward into the posterior lobe. The middle cornu descends into the middle lobe.

The *central cavity*, or body of the lateral ventricle, is triangular in form. It is bounded above by the under surface of the corpus callosum, which forms the roof of the cavity. Internally is a vertical partition, the *septum lucidum*, which separates it from the opposite ventricle and connects the under surface of the corpus callosum with the fornix. Its floor is formed by the following parts enumerated in their order of position from before backward: the *corpus striatum*, *tænia semicircularis*, *optic thalamus*, *choroid plexus*, *corpus fimbriatum*, and *fornix*.

The *anterior cornu* is triangular in form, passing outward into the anterior lobe and curving round the anterior extremity of the corpus striatum. It is bounded above by the corpus callosum; below and externally by the corpus striatum; and in front by the reflected portion of the corpus callosum.

The *posterior cornu*, or *digital cavity*, curves backward into the substance of the posterior lobe, its direction being backward and outward, and then inward. On its floor is seen a longitudinal eminence which is produced by the extension inward of the calcarine sulcus; this is called the *hippocampus minor*. Between the middle and posterior horns a smooth eminence is observed which varies considerably in size in different subjects. It is called the *eminentia collateralis*.

The **corpus striatum** [Figs. 469, 470, 471, and 475] has received its name from the striped appearance which its section presents, in consequence of diverging white fibres being mixed with the gray matter which forms the greater part of its substance. The greater portion of this body is imbedded in the white substance of the hemisphere, and is therefore external to the ventricle. It is termed the *extraventricular* portion, or the *nucleus lenticularis*, and consists of three segments; a part, however, is visible in the ventricle and its anterior cornu; this is the *intraventricular* portion or the *nucleus caudatus*. The intraventricular portion [caudate nucleus] is a pear-shaped mass, of a gray color externally; its broad extremity is directed forward into the fore part of the body and anterior cornu of the lateral ventricle: its narrow end [the tail or *surcingle*] is directed outward and backward [and continues in a curvilinear course into the roof of the descending horn of the ventricle, running forward to reach the amygdala. This last is an almost isolated mass of gray matter beneath the lenticular nucleus, and continuous with the deep-seated convolution of the temporal lobe]. It is covered by the serous lining of the cavity, and crossed by some veins of considerable size. It is separated from the extraventricular portion by a lamina of white matter [the continuation of the white fibres of the cord and crura cerebri on their way to the surface of the cerebrum], which is called the *internal capsule*, which also separates the intraventricular portion of the corpus striatum from the optic thalamus. It is called internal capsule, in contradistinction to a lamina of white matter which covers the outer surface of the extraventricular portion of the

[Fig. 469.

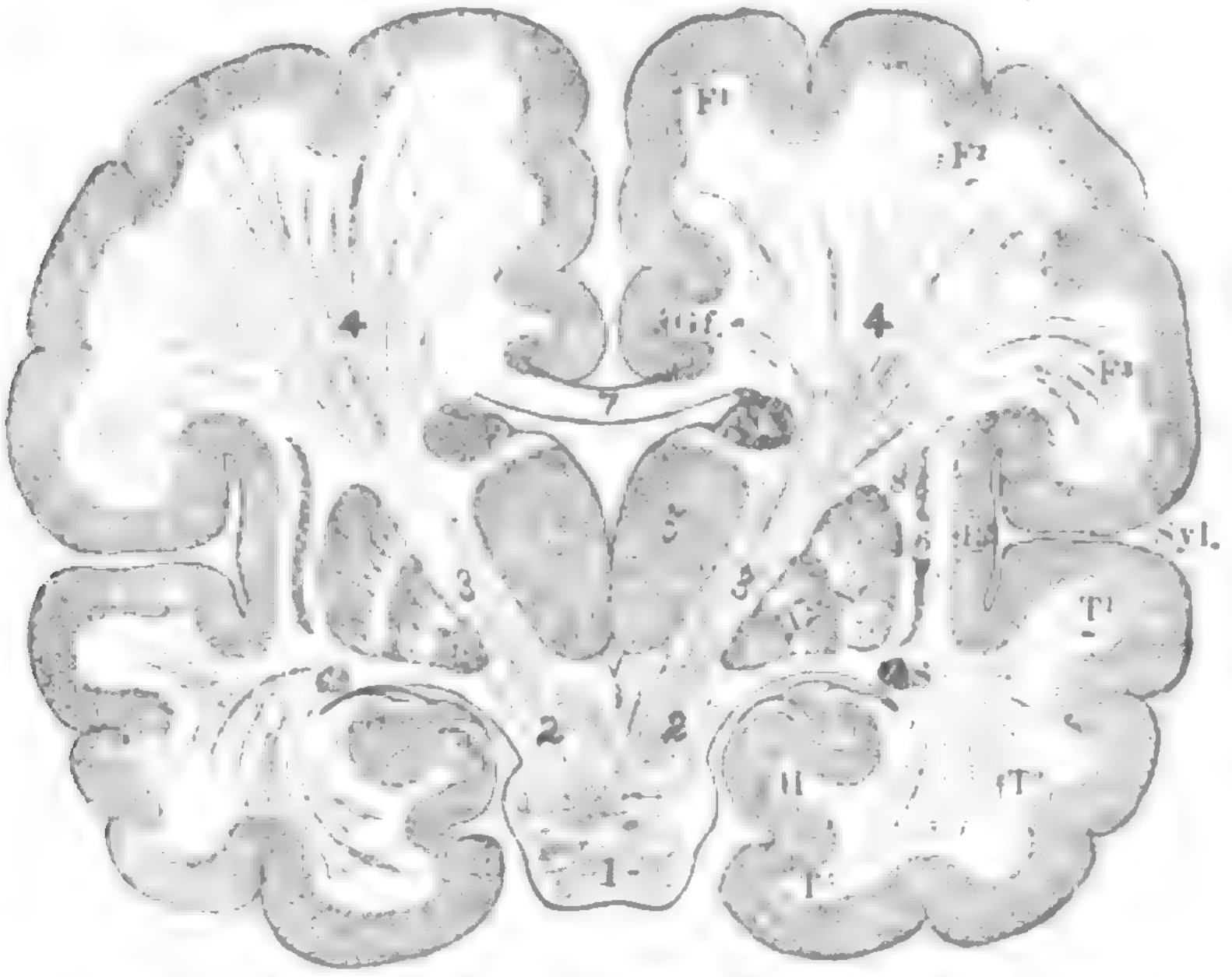

Diagram of Human Brain in Transverse Vertical Section.

1, pons Varolii; 2, 2, crura cerebri; 3, 3, internal capsule; 4, 4, corona radiata; 5, optic thalamus; 6, claustrum; 7, corpus callosum; 8, external capsule; C, corpus striatum (caudate nucleus); S, surcingle; L N, lenticular nucleus; Syl, fissure of Sylvius; Gf, gyrus fornicatus; F^1, first frontal convolution; F^2, second frontal convolution; F^3, third frontal convolution; T^1, first temporal convolution; T^2, second temporal convolution; T^3, third temporal convolution; H, gyrus hippocampi; R, island of Reil (Dalton).]

corpus striatum, and which is known as the *external capsule*. This in its turn is covered by a thin layer of gray matter termed the *claustrum*, which presents ridges or furrows on its outer surface corresponding to the convolutions and sulci of the island of Reil, with which it is in relation.

The **tænia semicircularis** is a narrow, whitish, semi-transparent band of medullary substance situated in the depression between the nucleus caudatus and optic thalamus. Anteriorly, it descends in connection with the anterior pillar of the fornix; behind, it is continued into the descending horn of the ventricle, where it enters a mass of gray matter, the *nucleus amygdalæ*, at the bottom of the cornu. Its surface, especially at its fore part, is transparent and dense in structure, and this was called by Tarinus the *horny band*. It consists of longitudinal white fibres, the deepest of which run between the corpus striatum and optic thalamus. Beneath it is a large vein (*vena corporis striati*) which receives numerous small veins from the surface of the corpus striatum and optic thalamus and joins the venæ Galeni.

[Fig. 470.

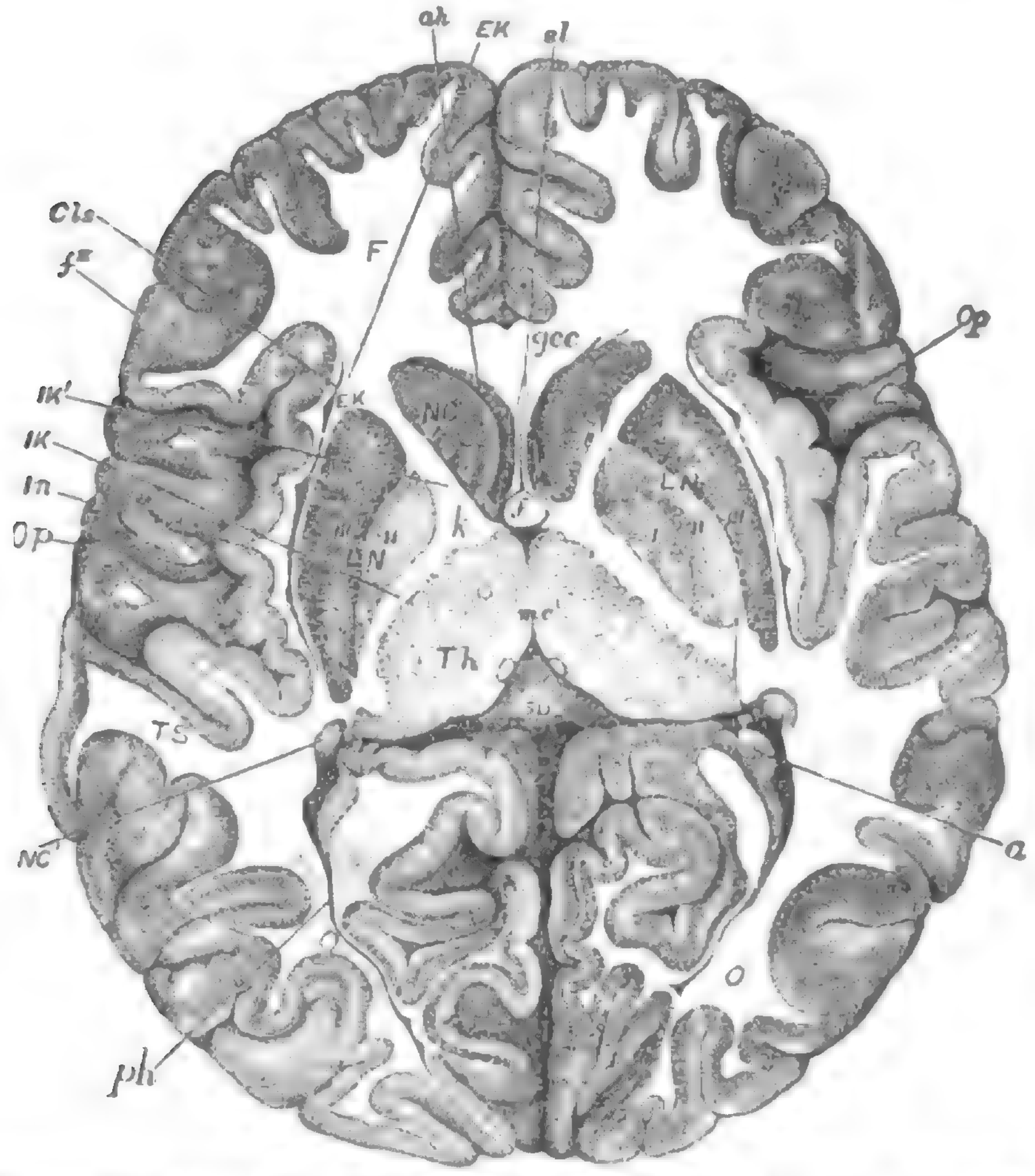

Horizontal Section of the Brain of a Child Nine Months of Age, the right side being at a somewhat lower level than the left half.

F, frontal, *TS*, temporo-sphenoidal, and *O*, occipital lobes; *Op*, operculum; *In*, island of Reil; *Cls*, claustrum; *f'''*, third frontal convolution; *Th*, optic thalamus; *NC*, caudate nucleus; *NC'*, tail of caudate nucleus (surcingle); *LN*, lenticular nucleus; *I*, *II*, *III*, first, second, and third divisions of the lenticular nucleus; *EK*, external capsule; *IK*, posterior division, *IK'*, anterior division, and *K*, knee of the internal capsule; *ah*, *ph*, anterior and posterior horns respectively of the lateral ventricles; *gcc*, knee of the corpus callosum; *sp*. splenium; *mc*, middle commissure; *f*, fornix; *sl*, septum lucidum; *a*, cornu ammonis (Flechsig).]

The **choroid plexus** is a highly vascular, fringe-like membrane occupying the margin of the fold of pia mater (*velum interpositum*) in the interior of the brain. It extends in a curved direction across the floor of the lateral ventricle. In front, where it is small and tapering, it communicates with the choroid plexus of the opposite side through a large oval aperture, the *foramen of Monro*. Posteriorly, it descends into the middle horn of the lateral ventricle, where it joins with the pia mater through the transverse fissure. In structure it consists of minute and highly vascular villous processes composed of large round corpuscles, containing, besides a central nucleus, several yellowish granules and fat-molecules and covered by a single layer of flattened epithelium. The arteries of the choroid plexus enter the ventricle at the descending cornu, and, after ramifying through its substance, send branches into the substance of the brain. The veins of the choroid plexus terminate in the venæ Galeni.

The **corpus fimbriatum** (*tænia hippocampi*) is a narrow, white, tape-like band situated immediately behind the choroid plexus. It is the lateral edge of the posterior pillar of the fornix, and is attached along the inner border of the hippocampus major as it descends into the middle horn of the lateral ventricle. It may be traced as far as the crochet or hook of the uncinate convolution.

FIG. 471.

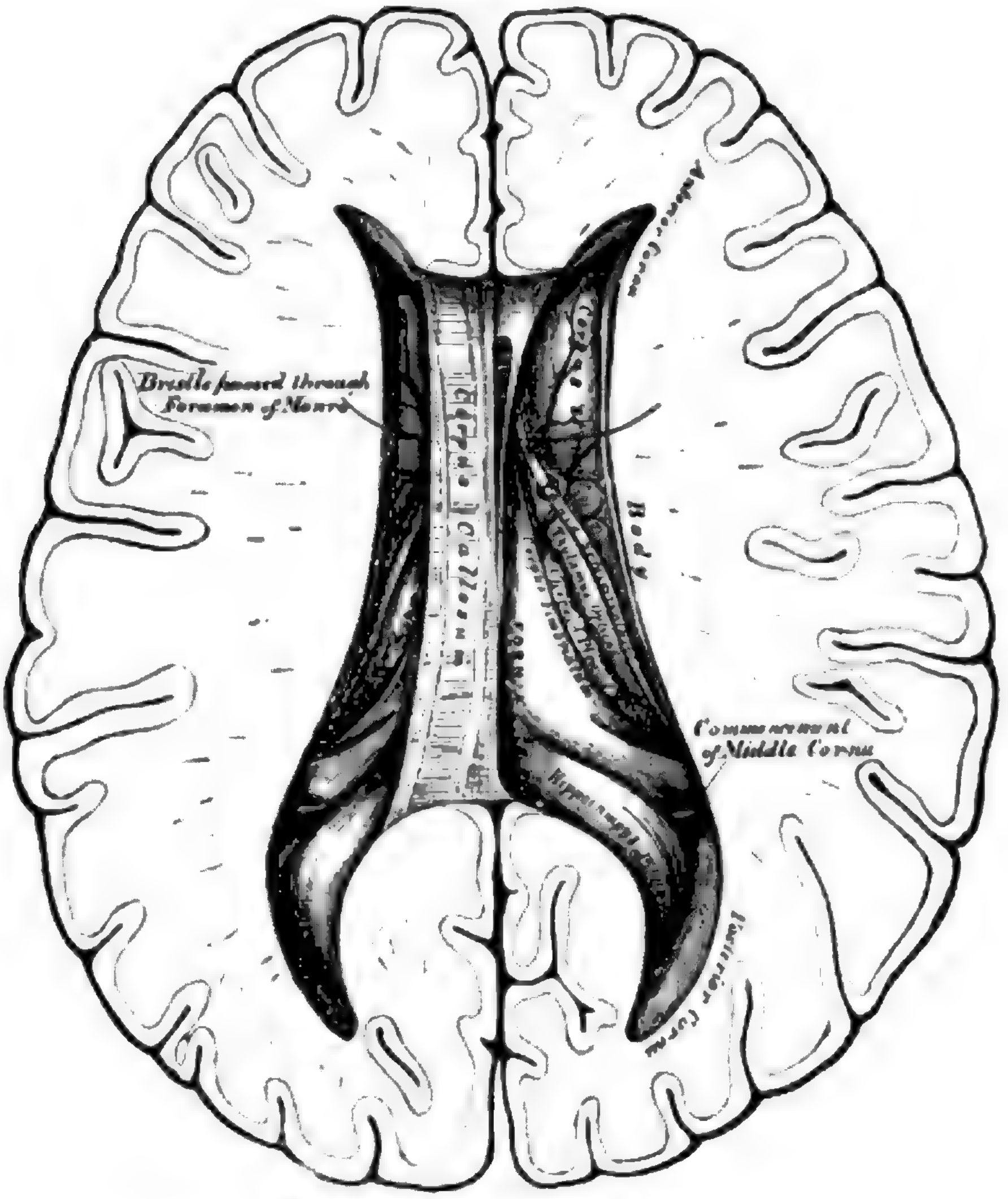
Anterior Cornu
Bristle passed through Foramen of Monro
Corpus Callosum
Body
Commencement of Middle Cornu
Posterior Cornu

The Lateral Ventricles of the Brain.

The *optic thalamus* and *fornix* will be described when more completely exposed in a later stage of the dissection of the brain.

The middle cornu should now be exposed, throughout its entire extent, by introducing the little finger gently into it and cutting outward along the finger through the substance of the hemisphere, which should be removed to an extent sufficient to expose the entire cavity.

The *middle* or *descending cornu*, the largest of the three, traverses the middle lobe of the brain, forming in its course a remarkable curve round the back of the optic thalamus. It passes at first backward, outward, and downward, and then curves round the crus cerebri forward and inward, nearly to the point of the middle lobe, close to the fissure of Sylvius. Its upper boundary is formed by the medullary substance of the middle lobe and the under surface of the optic thalamus. Its lower boundary, or floor, presents for examination the following parts: the *hippocampus major, pes hippocampi, pes accessorius, corpus fimbriatum, choroid plexus, fascia dentata, transverse fissure.*

The **hippocampus major, or cornu Ammonis** (Fig. 473), so called from its resemblance to a ram's horn, is a white eminence, of a curved elongate form, extending throughout the entire length of the floor of the middle horn of the lateral ventricle. At its lower extremity it becomes enlarged, and presents a number of rounded elevations with intervening depressions, which, from presenting some resemblance to the paw of an animal, is called the *pes hippocampi.* If a transverse section is made through the hippocampus major (Fig. 472, 4), it will be seen that this eminence is produced by the extension inward of the dentate sulcus on the exterior of the brain. This sulcus is filled with gray substance, which projects along the free margin of the hippocampus major, forming a notched ridge, the *fascia dentata.* The hippocampus is covered on its ventricular surface by a thin lamina of gray matter which is continuous with the corpus fimbriatum of the fornix.

FIG. 472.

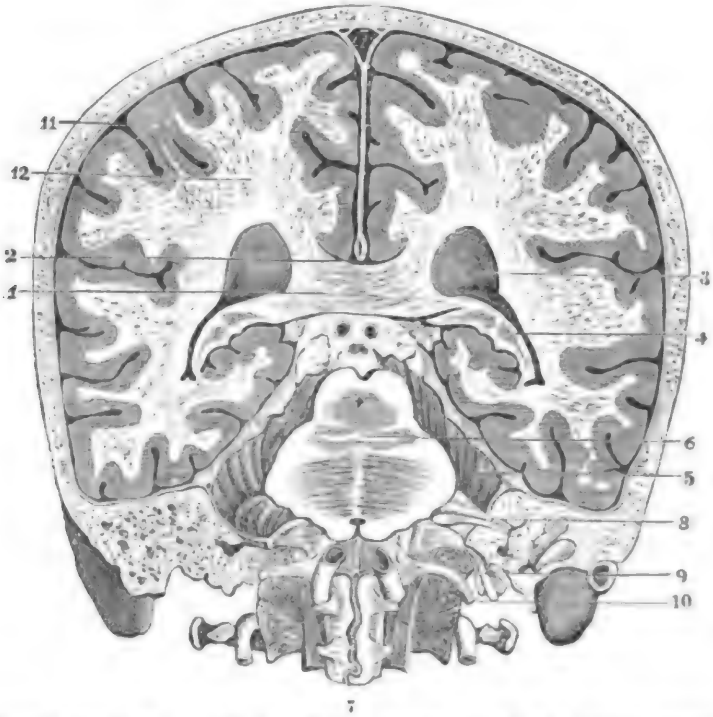

Transverse Vertical Section of the Brain, through the fore part of the foramen magnum, looked at from the front (after Hirschfeld and Leveillé).

1. Corpus callosum in relation with the falx and the cerebral hemispheres.
2. Ventricle of the corpus callosum.
3. Lateral ventricles.
4. Hippocampus major, white externally and gray internally.
5. Cerebellum, separated from the cerebrum by the tentorium.
6. Section through the corpora quadrigemina, aqueduct of Sylvius, and pons Varolii.
7. Medulla oblongata, with the vertebral arteries and the anterior spinal branch in relation with it.
8. Auditory nerve, passing into the meatus auditorius internus.
9. Pneumogastric nerve, passing through the posterior lacerated foramen.
10. Hypoglossal nerve, passing through the anterior condyloid foramen.

11, 12. Gray and white substance of the convolutions. The fibres of the corpus callosum are shown radiating through the white to the gray substance.

The **pes accessorius, or eminentia collateralis,** has already been mentioned as a white eminence, varying in size, placed between the hippocampus major and hippocampus minor, at the junction of the posterior with the descending cornu. It is formed by the protrusion inward of the collateral fissure.

The **corpus fimbriatum** is the thin lateral margin of the posterior pillar of the fornix, prolonged, as already mentioned, from the central cavity of the lateral ventricle.

Fascia Dentata [Fig. 473].—On separating the inner border of the corpus fimbriatum from the choroid plexus, and raising the edge of the former, a serrated band of gray substance, the edge of the gray substance of the dentate convolution, will be seen beneath it: this is the *fascia dentata*. Correctly speaking, it is placed external to the cavity of the descending cornu.

The [continuation forward of the] **transverse fissure** [or fissure of Bichat, between the cerebrum and cerebellum] is seen on separating the corpus fimbriatum from the optic thalamus. It is situated beneath the fornix, extending from the middle line behind, downward on either side to the end of the descending cornu. It is of a horseshoe shape. Its horizontal portion is bounded above by the splenium or rounded posterior extremity of the corpus callosum, and below by the corpora quadrigemina. Its lateral portions curve downward and forward, and are bounded below and in front by the crura cerebri and optic thalami; above and behind by the hippocampus major and the corpus fimbriatum of the fornix. Through this fissure the pia mater passes from the exterior of the brain into the ventricles to form the [velum interpositum and] the choroid plexuses. Where the pia mater projects into the lateral ventricle beneath the edge of the fornix it is connected with the lining membrane of these cavities, so as to exclude all communication with the exterior of the brain.

FIG. 473.

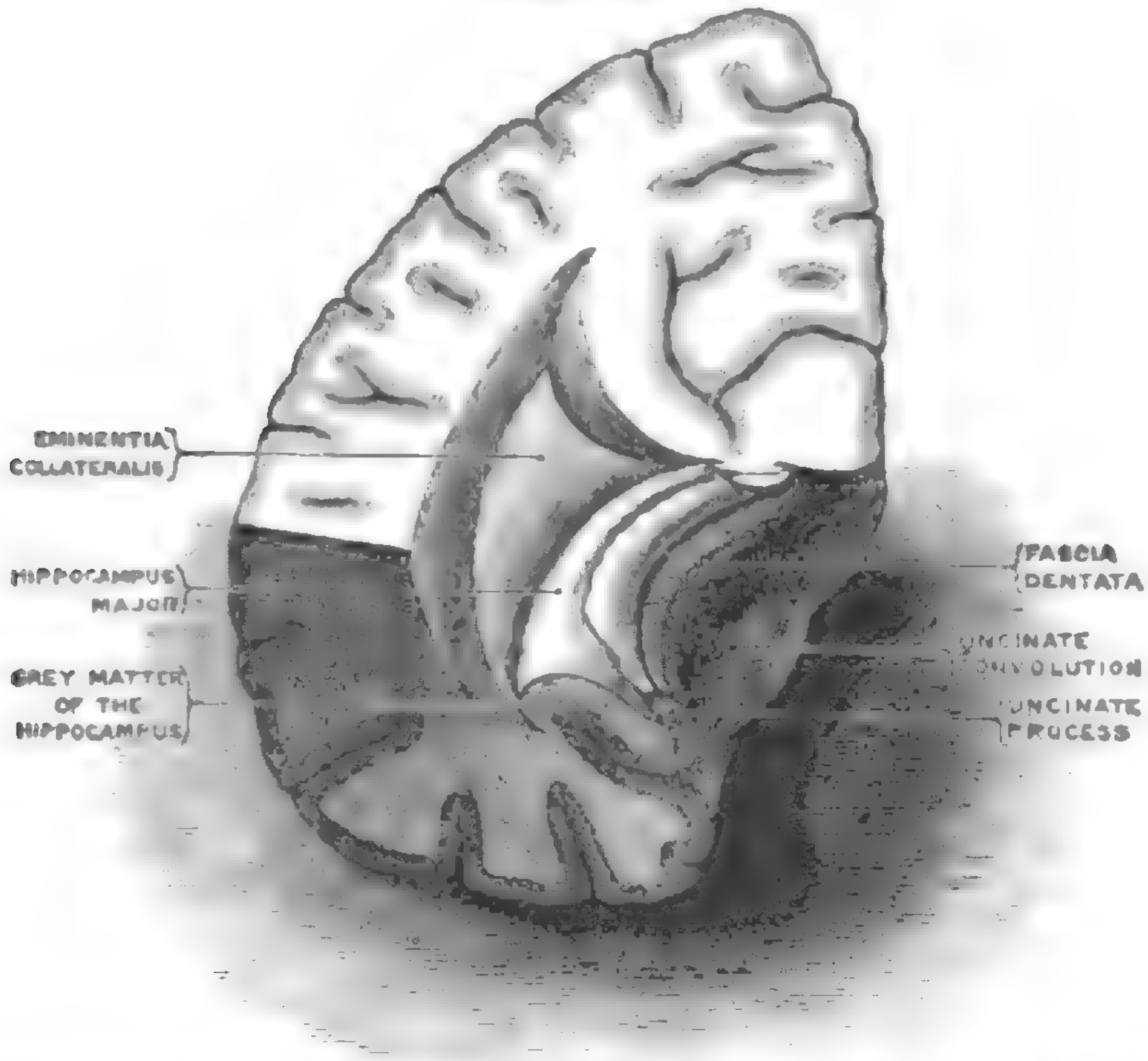

Transverse Section of the Middle Horn of the Lateral Ventricle (from a drawing by Mr. F. A. Barton).

The **septum lucidum** (Fig. 476, 6) forms the internal boundary of the lateral ventricles. It is a thin, semi-transparent septum, attached above to the under surface of the corpus callosum; below to the anterior part of the fornix; and in front of this to the prolonged portion of the corpus callosum. It is triangular in form, broad in front and narrow behind, its surfaces looking toward the cavities of the ventricles. The septum consists of two laminæ separated by a narrow interval, the *fifth ventricle.*

Fifth Ventricle.—The fifth ventricle was originally a part of the great longitudinal fissure which has become shut off by the union of the hemispheres in the formation of the corpus callosum above and the fornix below. Its walls are therefore formed by the median wall of the hemispheres, and consist of an internal layer of gray matter derived from the gray matter of the cortex, and an external layer of white substance continuous with the white matter of the cerebral hemispheres. This is lined on its external surface by the ependyma of the lateral ventricle. The fifth ventricle is not lined by epithelium. In the fœtus and in some animals this space communicates below with the third ventricle, but in the adult it forms a separate cavity. In cases of serous effusion in the ventricles the septum is often found softened and partially broken down.

The fifth ventricle may be exposed by cutting through the septum and attached portion of the corpus callosum with scissors; after examining which, the corpus callosum should be cut across toward its anterior part, and the two portions carefully dissected, the one forward, the other backward, when the fornix will be exposed.

FIG. 474.

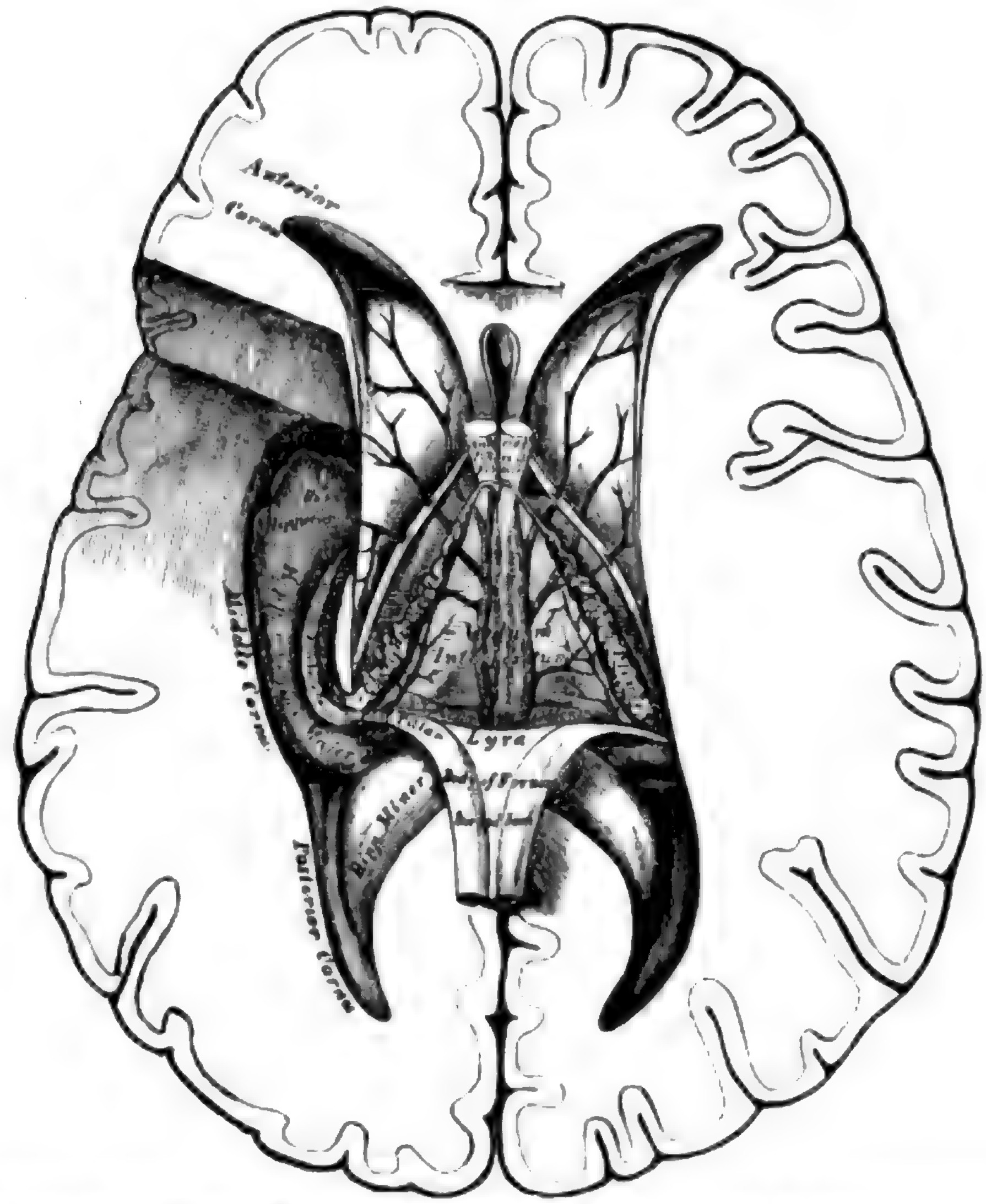

The Fornix, Velum Interpositum, and Middle or Descending Cornu of the Lateral Ventricle.

The **fornix** (Figs. 471, 476) is a longitudinal lamella of white fibrous matter situated beneath the corpus callosum, with which it is continuous behind, but separated from it in front by the septum lucidum. It may be described as consisting of two symmetrical halves, one for either hemisphere. These two portions are joined together in the middle line, where they form the *body*, but are separated from one another in front and behind, forming the *anterior and posterior crura*.

The *body* of the fornix is triangular, narrow in front, broad behind. Its upper surface is connected in the median line to the septum lucidum in front and the corpus callosum behind. Its under surface rests upon the velum interpositum, which separates it from the third ventricle and the inner portion of the optic thalami. Its lateral edges form, on each side, part of the floor of the lateral ventricles, and are in contact with the choroid plexuses.

The *anterior crura* arch downward toward the base of the brain, separated from each other by a narrow interval. They are composed of white fibres, which descend through a quantity of gray matter in the lateral walls of the third ventricle and are placed immediately behind the anterior commissure. At the base of the brain the white fibres of each crus form a sudden curve upon themselves, spread out and form the outer part of the corresponding *corpus albicans*, from which point they may be traced upward into the substance of the corresponding optic thalamus (Fig. 476). The anterior crura of the fornix are connected in their course with the peduncle of the pineal gland and the superficial fibres of the tænia semicircularis, and receive fibres from the septum lucidum.

The *posterior crura* at their commencement are intimately connected by their upper surfaces with the corpus callosum; diverging from one another, they pass downward into the descending horn of the lateral ventricle, being continuous with the concave border of the hippocampus major. The lateral thin edges of the posterior crura have received the name of *corpus fimbriatum*, already described. Upon examining the under surface of the fornix between its diverging posterior crura, a triangular portion of the under surface of the corpus callosum may be seen. On it are a number of lines, some transverse, others longitudinal or oblique. This appearance has been termed the *lyra*, from the fancied resemblance it bears to the strings of a harp.

Between the anterior pillars of the fornix and the anterior extremities of the optic thalami an oval aperture is seen on each side, the *foramen of Monro* (Fig. 475). The two openings descend toward the middle line, and, joining together, lead into the upper part of the third ventricle. These openings communicate with the lateral ventricles on each side and below with the third ventricle.

Divide the fornix across anteriorly, and reflect the two portions, the one forward, the other backward, when the velum interpositum will be exposed.

The **velum interpositum** (Fig. 474, and Fig. 476, 10, p. 701) is a vascular membrane, a prolongation from the pia mater into the interior of the brain through the transverse fissure, passing beneath the posterior rounded border of the corpus callosum and fornix, and above the corpora quadrigemina, pineal gland, and optic thalami. It is of a triangular form, and separates the under surface of the body of the fornix from the cavity of the third ventricle. Its posterior border forms an almost complete investment for the pineal gland. Its anterior extremity or apex is bifid, each bifurcation being continued into the corresponding lateral ventricle through the *foramen of Monro*, forming the anterior extremity of the choroid plexus. On its under surface are two vascular fringes, which diverge from each other behind and project into the cavity of the third ventricle. These are the *choroid plexuses of the third ventricle*. To its lateral margins are connected the choroid plexuses of the lateral ventricles. Of the arteries of the velum interpositum, some branches from the superior cerebellar and posterior cerebral enter from behind, beneath the corpus callosum; another constant branch, the anterior choroid, enters the velum interpositum at the extremity of the middle horn of the lateral ventricle, and supplies this structure and the choroid plexus. Its veins, the *venæ Galeni*, two in number, run between its layers; they are formed by the venæ corporis striati and the veins of the choroid plexuses; the venæ Galeni unite posteriorly into a single trunk, which terminates in the straight sinus (Fig. 412, p. 619).

The velum interpositum should now be removed. This must be effected carefully, especially at its posterior part, where it invests the pineal gland; the optic thalami will then be exposed, with the cavity of the third ventricle between them (Fig. 475).

The **optic thalami** are two large oblong masses placed between the diverging portions of the corpora striata; they are of a white color superficially; internally they are composed chiefly of gray matter. Each thalamus rests upon its corresponding crus cerebri, which it embraces. *Externally*, it is separated from the corpus striatum by the internal capsule, through which it is continuous with the hemisphere. *Internally*, it forms the lateral boundary of the third ventricle, and running along its upper border is seen the peduncle of the pineal gland. Its *upper surface* is free, being partly seen in the lateral ventricle; it is partially covered by the fornix, and marked in front by an eminence, the *anterior tubercle*. Its *under surface* forms the roof of the descending cornu of the lateral ventricle; into it the crus cerebri passes. Its *posterior and inferior part*, which projects into the descending horn of the lateral ventricle, presents two small rounded eminences, the *internal* and *external geniculate bodies*. Its *anterior extremity*, which is narrow, forms the posterior boundary of the foramen of Monro.

The **third ventricle** is the narrow oblong fissure placed between the optic thalami and extending to the base of the brain. It is bounded above by the under surface of the velum interpositum, from which are suspended the choroid plexuses of the third ventricle, and laterally by two white tracts, one on either side, the *peduncles of the pineal gland*. Its floor, somewhat oblique in its direction, is formed, from before backward, by the parts which close the interpeduncular space—viz. the lamina cinerea, the tuber cinereum and infundibulum, the corpora albicantia, and the locus perforatus posticus; its sides, by the optic thalami; it is bounded in front by the anterior crura of the fornix and part of the anterior commissure; behind, by the posterior commissure and the iter a tertio ad quartum ventriculum.

FIG. 475.

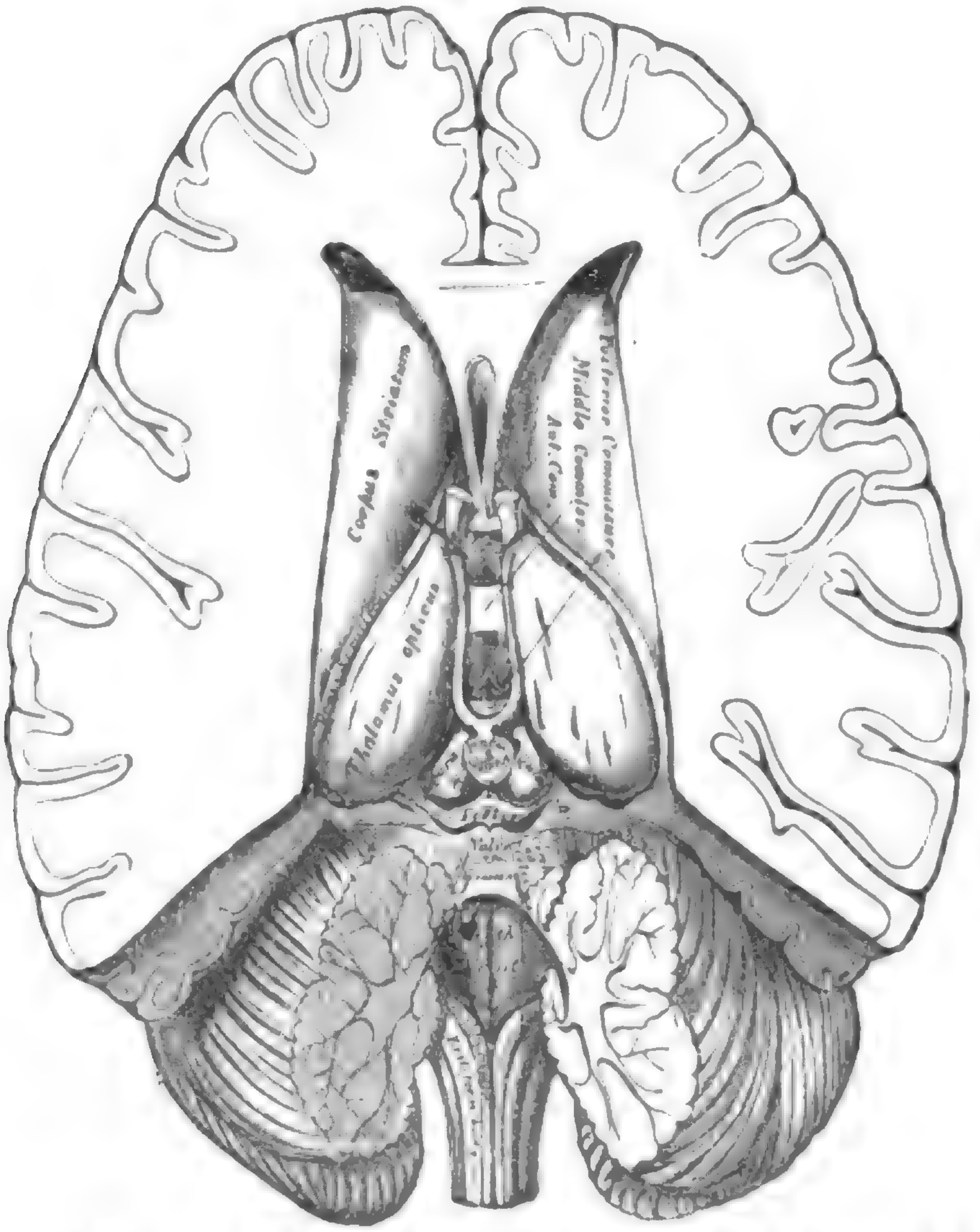

The Third and Fourth Ventricles. An arrow [anteriorly] has been placed in the position of the foramen of Monro, [and another posteriorly passes through the iter a tertio ad quartum ventriculum].

The cavity of the third ventricle is crossed by three commissures, named, from their position, *anterior*, *middle*, and *posterior*.

The *anterior commissure* is a rounded cord of white fibres placed in front of the anterior crura of the fornix. It perforates the corpus striatum on either side, and spreads out into the substance of the hemispheres over the roof of the descending horn of each lateral ventricle.

The *middle* or *soft commissure* consists almost entirely of gray matter. It connects together the optic thalami, and is continuous with the gray matter lining the anterior part of the third ventricle. It is frequently broken in examining the brain, and might then be supposed to have been wanting.

FIG. 476.

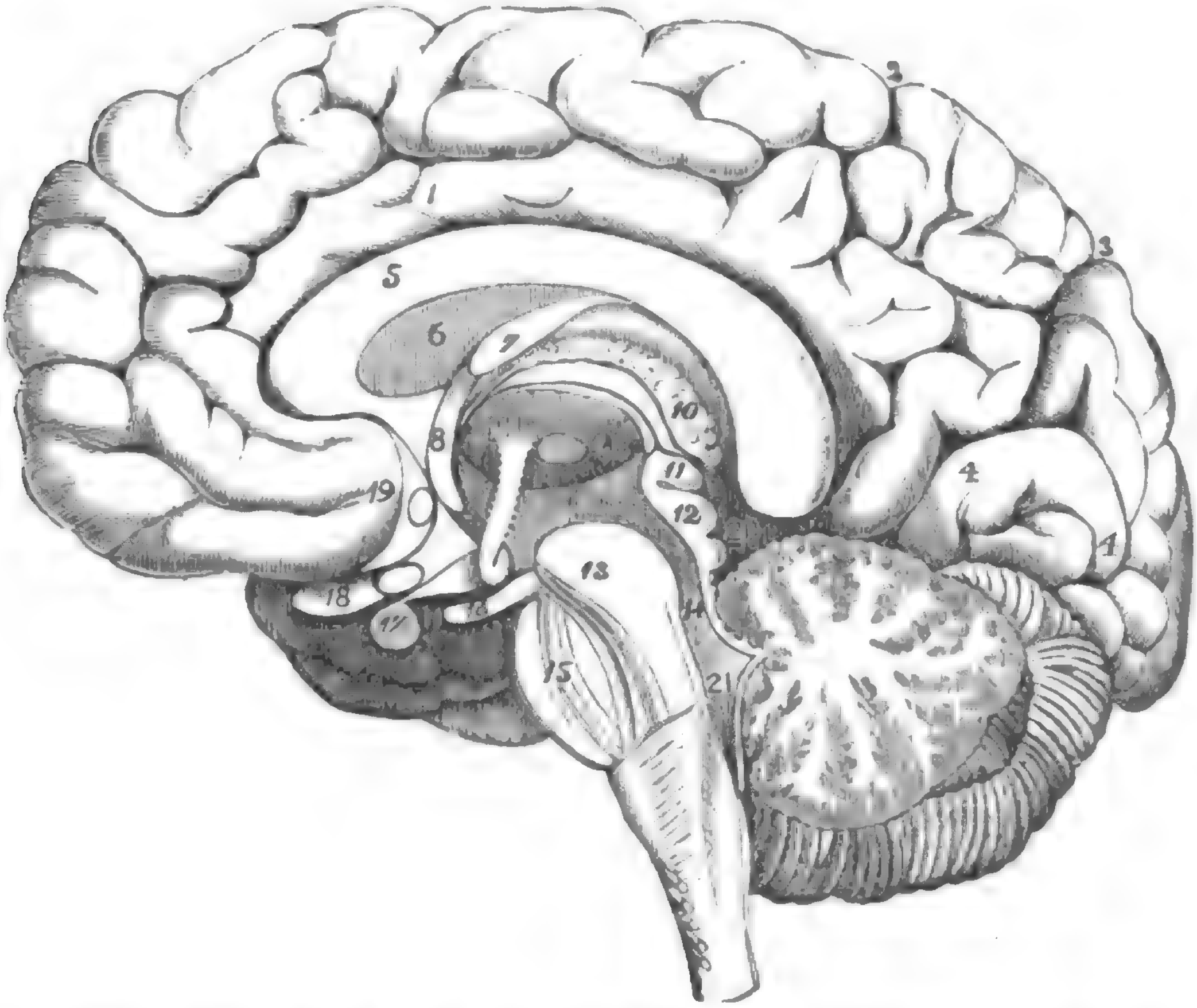

Vertical Median Section of the Encephalon, showing the parts in the middle line.

1. Convolution of corpus callosum. Above it is the calloso-marginal fissure, running out to join at
2. The fissure of Rolando.
3. The parieto-occipital fissure.
4, 4, point to the calcarine fissure, which is just above the numbers. Between 2 and 3 are the convolutions of the quadrate lobe. Between 3 and 4 is the cuneate lobe.
5. The corpus callosum.
6. The septum lucidum.
7. The fornix.
8. Anterior pillar of the fornix, descending to the base of the brain, and turning on itself to form the corpus albicans. Its course to the optic thalamus is indicated by a dotted line.
9. The optic thalamus. Behind the anterior crus of the fornix (8) a shaded part indicates the foramen of Monro; in front of the number 9 an oval mark shows the position of the gray matter continuous with the middle commissure.
10. The velum interpositum.
11. The pineal gland.
12. The corpora quadrigemina.
13. The crus cerebri.
14. [The iter e tertio ad quartum ventriculum. Between 14 and the cerebellum is the valve of Vieussens, seen in profile, stretching between the two processus e cerebello ad testes. The processus e cerebello ad medullam is seen between 21 and the cerebellum.]
15. The pons Varolii.
16. The third nerve.
17. The pituitary body.
18. The optic nerve.
19 points to the anterior commissure, indicated by an oval mark behind the number.
[20. The transverse fissure of Bichat.
21. The fourth ventricle.]

The *posterior commissure*, smaller than the anterior, is a flattened white band of fibres connecting together the two optic thalami posteriorly. It bounds the third ventricle posteriorly, and is placed in front of and beneath the pineal gland, above the opening leading to the fourth ventricle.

The third ventricle has four openings connected with it (Figs. 468, 471, and 476). In front are the two oval apertures of the foramina of Monro, one on either side, through which the third communicates with the lateral ventricles. Behind is a third opening leading into the fourth ventricle by a canal, the *aqueduct of Sylvius*, or *iter a tertio* *ad quartum ventriculum.* The fourth, situated in the anterior part of the floor of the ventricle, is a deep pit which leads downward to the funnel-shaped cavity of the infundibulum (*iter ad infundibulum*).

The lining membrane of the lateral ventricles is continued through the foramen of Monro into the third ventricle, and extends along the iter a tertio into the fourth ventricle; at the bottom of the iter ad infundibulum it ends in a cul-de-sac.

The **foramen of Monro** is the means by which the two lateral ventricles communicate with the third ventricle. It may be regarded as a Y-shaped passage, the two upper diverging limbs communicating with the lateral ventricles respectively, and joining below to open into the third ventricle. Its roof is formed by the anterior extremity of the body of the fornix, which, dividing into its two crura, arches downward in front of the anterior extremity of the optic thalami. The crus is not, however, in contact with the thalamus, but an interval is left between the two, which is the foramen of Monro. Its boundaries are, therefore, in front, the anterior pillars of the fornix; behind, the anterior extremity of the optic thalamus; above, the body of the fornix; and below, the groove where the corpus striatum and optic thalamus meet.

Behind the third ventricle and in front of the cerebellum are the corpora quadrigemina, and, resting upon these, the pineal gland.

The **pineal gland** (*epiphysis cerebri*), so named from its peculiar shape (*pinus*, a fir-cone), is a small reddish-gray body, conical in form (hence its synonym, *conarium*), placed immediately behind the posterior commissure and between the nates, upon which it rests. It is retained in its position by a duplicature of pia mater derived from the under surface of the velum interpositum, which almost completely invests it. The pineal gland is about four lines in length and from two to three in width at its base, and is said to be larger in the child than in the adult, and in the female than in the male. Its base is connected to the cerebrum by two peduncles (*the peduncles of the pineal gland*), which pass forward upon the upper and inner margin of the optic thalami to the anterior crura of the fornix, with which they become blended: these two peduncles join together at their posterior extremity in front of the pineal gland, forming a sort of festoon, and the base of the gland is connected to their posterior margin at the point of junction. In front the band of union is joined to the back of the posterior commissure. The pineal gland consists of a number of follicles lined by epithelium and connected together by ingrowths of connective tissue. The follicles contain a transparent viscid fluid and a quantity of sabulous matter, named *acervulus cerebri*, composed of phosphate and carbonate of lime, phosphate of magnesia, and ammonia, with a little animal matter. These concretions are almost constant in their existence and are found at all periods of life. When this body is solid the sabulous matter is found upon its surface and occasionally upon its peduncles.

On the removal of the pineal gland and adjacent portion of pia mater the corpora quadrigemina are exposed.

The **corpora or tubercula quadrigemina** (*optic lobes*) are four rounded eminences placed in pairs, two in front and two behind, and separated from one another by a crucial depression. They are situated immediately behind the third ventricle and posterior commissure, beneath the posterior border of the corpus callosum, and above the iter a tertio ad quartum ventriculum. The anterior pair, *the nates*, are the larger, oblong from before backward, and of a gray color. The posterior pair, *the testes*, are hemispherical in form and lighter in color than the preceding. They are connected on each side with the optic thalamus and commencement of the optic tracts by means of two white prominent bands termed *brachia*. Those connecting the nates with the thalamus (*brachia anteriora*) are the larger and pass obliquely outward. Those connecting the testes with the thalamus are called the *brachia posteriora*. Both pairs, in the adult, are quite solid, being composed of white matter externally and gray matter within. These bodies are larger in the lower animals than in man. In fishes, reptiles, and birds they are only two in number, are called the *optic lobes* from their connection with the optic nerves, and are hollow in their interior; but in Mammalia they are four in number, as in man, and quite solid. In the human fœtus they are developed at a very early period, and form a large proportion of the cerebral mass; at first they are only two in number, as in the lower Vertebrata, and hollow in their interior.

These bodies receive, from below, white fibres from the olivary fasciculus or fillet; they are also connected with the cerebellum by means of a large white cord on each side, the *processus e cerebello ad testes*, or superior peduncles of the cerebellum, which is continued onward to the thalami through the tubercula quadrigemina.

The **valve of Vieussens,** or **anterior medullary velum,** is a thin translucent lamina of white matter, marked superficially by a few transverse streaks of gray substance, stretched between the two processus e cerebello ad testes; it covers in the canal leading from the third to the fourth ventricle, forming part of the roof of the latter cavity. It is narrow in front, where it is connected with the testes, and broader behind, at its connection with the vermiform process of the cerebellum. A slight elevated ridge, the *frænulum*, descends upon the upper part of the valve from the corpora quadrigemina, and on either side of it may be seen the fourth nerve, which is connected with its fellow of the opposite side by a transverse band of fibres forming a partial decussation. Its lower half is covered by a thin transversely-grooved lobule of gray matter prolonged from the anterior border of the cerebellum: this is called by the Italian anatomists the *linguetta laminosa*.

The *corpora geniculata* are two small, flattened, oblong masses placed on the outer side of the corpora quadrigemina and on the under and back part of each optic thalamus, and named, from their position, *corpus geniculatum externum* and *internum*. The two bodies are separated from one another by one of the roots of the optic tract.

Internal Structure of the Cerebrum.—The **cerebrum,** like the other parts of the great nerve-centre, is composed of gray and white matter. In order to give some general idea of its construction, at all events in part, it may be compared, for the sake of illustration, to a tree, the trunk of which divides into two main branches, and these break up into smaller branches, which finally end in twigs, to which are attached the leaves, forming an investment to the branches and covering the whole tree. The trunk is represented by the medulla oblongata as it passes through the foramen magnum; the two main branches, by the crura cerebri, which break up into smaller branches, which diverge from each other, dividing and subdividing, until they reach the surface of the hemispheres, where they terminate in single nerve-fibres, to which are attached the basal axial cylinder processes of the nerve-cells, represented by the leaves. These cells are arranged on the surface, resembling a cap covering the hemispheres, and constitute the cerebral cortex. But here the analogy ends, for in the cerebrum we have, in addition to this cortex, other masses of gray matter situated in the middle of the brain, and other white fibres besides these diverging ones which have been mentioned, and which serve either to connect together the two hemispheres of which the cerebrum consists, or else serve to connect different structures in the same hemisphere.

The *gray matter* of the cerebrum is disposed in three great groups: 1, the gray matter of the cerebral cortex; 2, the gray matter of the basal ganglia—that is, the great ganglia of the base of the cerebrum; 3, the gray matter which lines the internal surface of the upper part of the cerebro-spinal tube—that is, the remains of the cavity in the original vesicles from which the brain was formed, and which constitutes the central cavities of the organ.

1. The **gray matter of the cortex** (Fig. 477) invests the surface of the hemispheres and gives them external form. When vertical sections are made through it and examined microscopically, it is found to consist of five separate layers, but to this there are some exceptions. According to Meynert, these are to be found in the posterior portion of the occipital lobe, in the gray cortex of the hippocampus major, in the wall of the fissure of Sylvius, and in the olfactory bulb. The five

layers in the common type are as follows: (1) The first layer is principally composed of a matrix or neuroglia, through which a few small ganglion-cells are irregularly distributed, and a nerve-fibre network. (2) The second layer consists of numerous small pyramidal cells, which have their long axes vertical to the surface of the convolutions, and are closely aggregated together, so as to completely fill the layer with a number of closely-compressed cells. (3) The third layer is named by Meynert the *formation of the cornu ammonis*, as it is made up of cells, which are the only morphological element found in this part. It consists of the same sort of pyramidal cells, arranged vertically to the surface, as was found in the preceding layer, but they are of very much larger size, and increase progressively toward the deeper parts of the layer, and they are much more widely separated from each other. This layer is the principal and broadest one of the series, and is at least twice as deep as the preceding layer. (4) The fourth layer is termed the *granular formation* by Meynert, and consists of numerous small, irregular, rarely triangular or elongated cells, which resemble the nerve-corpuscles found in the internal granule-layer of the retina, and which are closely aggregated together. (5) The fifth layer is termed the *claustral formation*, and consists of a very large proportion of spindle-shaped cells, which are the peculiar elements of this layer. They are especially numerous in the inner half, and are arranged horizontally, extending parallel to the surface. They have received their name from the fact that the claustrum is made up almost entirely of an accumulation of these cells. It will be seen, therefore, that the differences in these layers depends upon the varying form and size of these cells and the closeness of their arrangement, and that the typical form of cell, and the only one which is admitted by some observers, is the pyramidal cell or nerve-corpuscle. These nerve-corpuscles are destitute of a cell-wall; they present a nucleus, sometimes round or oval, sometimes angular, and give off many processes. One of these, which, in the cells arranged vertically to the surface, projects outward and is named the *process of the apex*, is strong and branched, and according to Cleland is continuous with the nerve-fibre network in the first or superficial layer of the cortex. Another process projects inward toward the white matter of the hemisphere and from the opposite extremity of the cell. It is termed the *process of the centre of the base*. It is more slender than the preceding and remains unbranched. It is an axis-cylinder process, and, becoming invested with a medullary sheath, constitutes a nerve-fibre extending into the central white matter. In addition to these, lateral processes are given off, forming the *processes of the basal angle*, which can be traced for a longer or shorter distance and break up into a network of extremely minute nerve-fibres.

FIG. 477.

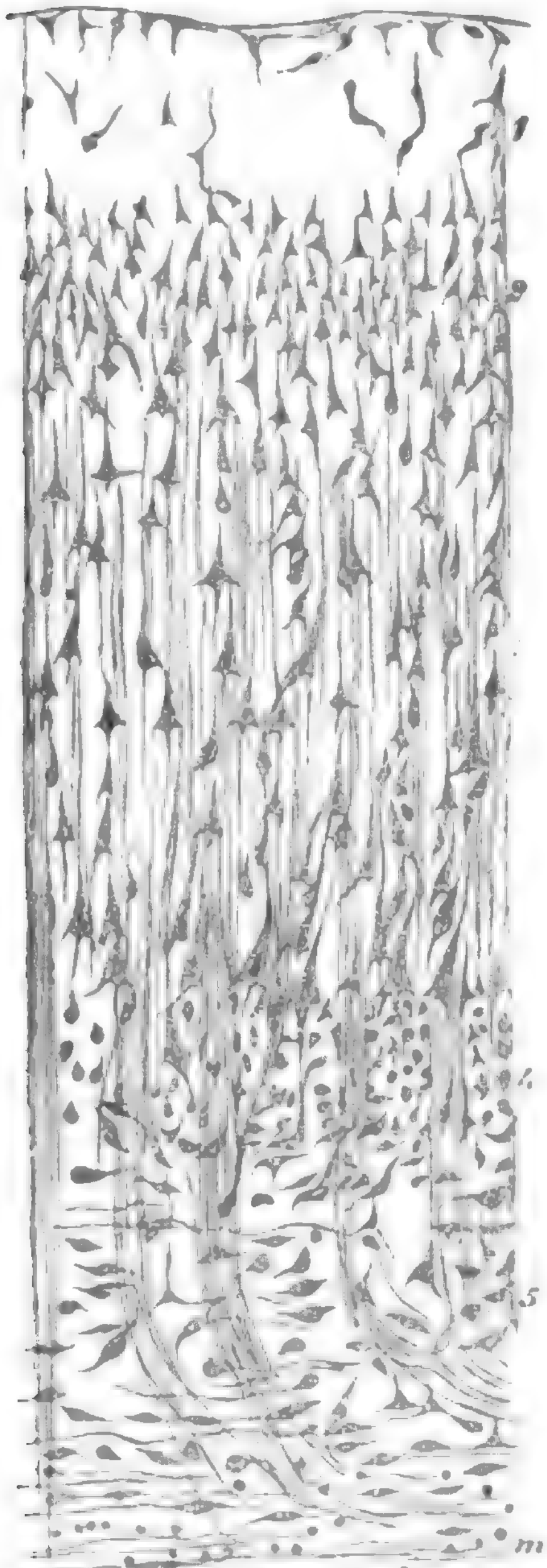

Gray Matter of the Cerebral Cortex (Meynert).

Special Types of the Gray Matter of the Cortex.—According to Meynert, the gray matter on the summit of the occipital lobe consists of eight layers. This is produced by the intercalation of intermediate granule-layers similar to those forming the fourth layer of the typical cortex. In the gray matter of the cortex of the hippocampus major or cornu ammonis pyramidal cells are alone formed, such as have been described in the third layer of the typical cortex. This constitutes the greater part of the structure in this situation, the fourth and fifth layers being absent and the second layer containing no cells. In the wall of the Sylvian fissure the gray matter is termed the *claustrum*, and part of it separates the island of Reil from the external capsule of the corpus striatum. This presents peculiarities of structure, consisting mainly of fusiform cells, such as constitute the fourth layer. The olfactory bulb, which may be regarded as a portion of the cerebral hemispheres, forming "a cap superimposed upon a conical process of the cerebrum," presents another variety of structure, differing from the type of the cortex of the hemispheres. The bulb consists of both gray and white matter, and sometimes retains a central cavity lined by epithelium. The lower part is gray matter, and consists of the following layers from below upward: (1) The olfactory nerve-layer, consisting of a layer of non-medullated nerve-fibres derived from the nerves which supply the olfactory region. (2) The stratum glomerulosum, consisting of nodulated masses, containing small nuclear cells and a convoluted olfactory nerve-fibre amongst the cells. (3) The stratum gelatinosum, consisting of fusiform or pyramidal nerve-cells and a fine network of nerve-fibre. (4) The granular layer, consisting of small irregular nerve-cells resembling the fourth layer of the cerebellum or the granular layer of the retina.

2. **The Gray Matter of the Basal Ganglia.**—The great ganglia of the base of the brain are the optic thalamus, the corpus striatum, the corpora quadrigemina, the corpora geniculata, and the locus niger. Only a part, however, of the gray matter of the corpora quadrigemina, that found on the periphery of the body, belongs to this group; the remainder, that contained in its centre around the Sylvian aqueduct, belongs properly to the third group, which will be discussed immediately.

The *optic thalamus* is chiefly formed of gray matter, covered over by a superficial layer of white, which on the outer side separates it from the internal capsule. The gray matter is arranged in two masses, the outer and inner nuclei, partially divided by a vertical white septum. It is traversed by numerous nerve-fibres, which for the most part have no definite direction; some, however, converge and form a bundle which passes downward to form the anterior root of the fornix. It contains comparatively large nerve-cells, both multipolar and fusiform. The inner nucleus is connected across the middle line with the inner nucleus of the opposite side by the middle commissure of the third ventricle, which, however, belongs to the third group of gray matter.

The *corpus striatum* presents two distinct and separate masses—the *nucleus caudatus*, which is the intraventricular portion of the corpus striatum; and the *nucleus lenticularis*, which is the extraventricular portion. The two are separated from each other by a distinct lamina of white matter, the *internal capsule*, which also separates the nucleus lenticularis from the outer part of the optic thalamus. The gray matter of the corpus striatum is permeated by tracts of medullated nerve-fibres, some of which probably originate in it, though the actual connection of the nerve-fibres with the cells has not been demonstrated. The nerve-cells are multipolar, both large and small, the larger being principally found in the lenticular nucleus.

The *corpora quadrigemina* consists of two distinct and separate collections of gray matter, one at or near the surface, which belongs to the basal ganglia, and one in the centre lining the aqueduct of Sylvius. The former only will be considered at present. The *peripheral* gray matter of the corpora quadrigemina differs somewhat in the anterior and posterior lobes. The posterior lobes or testes are composed almost entirely of gray matter, covered over by a thin stratum of white matter, and separated from the *central* gray matter by tracts of transverse white fibres derived from and forming part of the fillet. The anterior lobes or nates are covered superficially by a thin stratum of white matter; beneath this is a layer of gray matter termed the *stratum cinerum*, and consisting, as well as the gray matter of the posterior lobes, of small multipolar cells imbedded in a fine network of nerves. Beneath this again is a characteristic mass of gray matter, termed the *stratum opticum*, which is made up of fine nerve-fibres coursing in a longitudinal direction, and containing between them small masses of gray substance consisting of small multipolar nerve-cells imbedded in gray matter. Lastly, between this body and the central gray matter around the Sylvian aqueduct is a thin lamina of white matter, derived from the fillet.

The *geniculate bodies* are continuous with the gray substance of the optic thalamus, and the external one (corp. geniculatum externum) is peculiar on account of its dark color, due to its cells containing pigment. It presents a laminated arrangement, and consists of alternate thick layers of gray matter and thin layers of white matter. Its cells are multipolar. The internal body (corp. geniculatum internum) is of lighter color, does not present a laminated arrangement, and its cells are smaller in size and fusiform in shape.

The *locus niger*, or gray matter of the crus cerebri, like the external geniculate body, is peculiar from the large amount of dark pigment-granules which are contained in its ganglion-cells, and which give to it its dark color, from which it has derived its name. Its cells are small and multipolar.

3. The **central gray matter of the cerebrum** lines the upper part of the cerebro-spinal tube, which is the remains of the cavity in the original vesicles from which the brain was formed, and is continuous with the gray matter of the floor of the fourth ventricle, and through it with the gray matter of the cord [which surrounds the "ventricle of the cord" or central canal]. This central gray matter is found lining the aqueduct of Sylvius, by which the third communicates with the fourth ventricle; it covers the inner wall of each optic thalamus, forming the middle or gray commissure of the third ventricle; it also lines the floor of the third ventricle; it covers behind the upper surface of the tegmentum of the crus, and in front it approaches the surface of the brain, forming the posterior perforated space and the lamina cinerea. It forms also the tuber cinereum and the infundibulum, and in the lower Vertebrata, especially fishes, the posterior lobe of the pituitary body. In the higher vertebrates this lobe does not present any nervous structure, being encroached upon and obliterated by an ingrowth of connective tissue and vessels. The gray matter surrounding the Sylvian aqueduct, which has been before mentioned as the central gray matter of the corpora quadrigemina, presents some features requiring especial mention. It forms a tolerably thick layer surrounding the canal, but is thicker on the lower wall—that is, below the canal—than above. The cells, which are multipolar, are here collected into groups, and form nuclei for the origin of the third, fourth, and fifth cranial nerves. The nucleus for the third and fourth consists of a column of cells of large size on either side of, and close to, the median line. The upper nucleus of the fifth is situated external to this at the extreme lateral margin of the lower part of the gray matter. In addition to these cells there are found at the periphery of the zone of gray matter surrounding the aqueduct some other and larger cells, sometimes single, sometimes grouped in twos or threes, or even more. They are globular and lie in the midst of well-marked nerve-fibres, with which their processes appear to be continuous.

The **white matter of the cerebrum** consists of medullated fibres varying in size and arranged in bundles, separated by neuroglia. They may be divided into three distinct systems, according to the course which they take: (1) diverging or peduncular fibres, which connect the hemispheres with the medulla oblongata and cord; (2) transverse commissural fibres, which connect together the two hemispheres; (3) commissural fibres, which connect different structures in the same hemisphere.

1. The **diverging** or **peduncular fibres** consist of a main body which originates in the cord and medulla oblongata, form the longitudinal fibres of the pons, and, dividing into two main branches diverging from each other, constitute the *crura cerebri* or *cerebral peduncles*, and ascend into the optic thalami and corpora striata, and, emerging from these bodies, form the *corona radiata* and radiate into the convolutions of the hemispheres. As they pass through the optic thalami and corpora striata many of the fibres terminate in the gray matter of these ganglia.

and other fibres arise from them in greater number than those which terminate in them, so that more fibres pass out of the ganglia than pass into them. But, in addition to these, others of the peduncular fibres pass uninterruptedly through the ganglia from the cerebral peduncles to the corona radiata. In the crura cerebri, as has been before described, the diverging fibres derived from the longitudinal fibres of the pons Varolii are arranged in two strata, which are separated by the locus niger, the anterior or superficial stratum forming the *crusta* of these bodies, and the posterior or deeper stratum the *tegmentum.* The fibres derived from these two sources take a different course, and will have to be separately considered.

The fibres of the *crusta* are derived from the anterior pyramid of the medulla (see Figs. 444 and 445, pp. 670 and 671), which fibres are continued upward through the pons to form the crusta; they are reinforced in their passage through the crus by accessory fibres derived from the central gray matter around the Sylvian aqueduct and from the locus niger. When they emerge from the crus some of the fibres pass to the internal capsule, between the caudate and lenticular nuclei, where they give off branches to these ganglia and receive others from them, and then, issuing from the capsule, they diverge to form a part of the corona radiata, passing to the cerebral cortex. Others of the fibres pass directly upward as radiating fibres to the gray matter of the cerebral hemispheres.

The fibres of the *tegmentum* are continuous with those longitudinal fibres of the pons which are derived from the formatio reticularis of the medulla, which is formed by fibres from the olivary body, lateral and posterior columns of the cord, and the superior peduncle of the cerebellum. They are reinforced by fibres from the corpora quadrigemina and corpora geniculata, and enter the optic thalamus, in which many terminate and from which others arise; others pass through the body, and, with those fibres arising in it, spread out to form the corona radiata, especially joining the ganglion-cells of the cortex of the temporo-sphenoidal and occipital lobes.

2. The **transverse commissural fibres** connect together the two hemispheres. They include (*a*) the transverse fibres of the corpus callosum; (*b*) the anterior commissure; (*c*) the posterior commissure.

The *corpus callosum*, which has already been described, connects together the two hemispheres of the brain, penetrating into the substance of the convolutions, and intersecting the fibres of the corona radiata in the anterior, middle, and part of the posterior lobes.

The *anterior commissure* is a round bundle of white fibres which appears to connect the two corpora striata in the third ventricle. The fibres can, however, be traced through this body, and are then seen to curve backward and outward and spread out in the medullary substance of the temporo-sphenoidal lobe.

The *posterior commissure* passes into the optic thalamus on either side. It consists of decussating fibres which come from the tegmentum of the crus on one side, and pass through the optic thalamus, across the third ventricle, to the white substance of the temporo-sphenoidal lobe of the other. Some of the fibres may also serve as commissural fibres between the two optic thalami.

3. **Commissural Fibres connecting Different Structures in the Same Hemisphere.**—These fibres are of two kinds: (1) those which connect adjacent convolutions, and which are termed *arcuate* or *association fibres;* (2) those which connect more distant parts in the same hemisphere—the *longitudinal* or *collateral* fibres.

The *arcuate* or *association fibres* are situated immediately beneath the gray substance of the cortex of the hemispheres, and connect together adjacent convolutions.

The *longitudinal* or *collateral fibres* include the following: (*a*) the fornix; (*b*) the longitudinal fibres of the corpus callosum; (*c*) the tænia semicircularis; (*d*) the uncinate fasciculus; (*e*) the fillet of the gyrus fornicatus; (*f*) the inferior longitudinal fasciculus.

(*a*) The *fornix* connects the optic thalamus with the hippocampus major and uncinate convolution. It has already been described as arising from the gray matter of the optic thalamus: it then emerges from the under surface of this body, forms the corpus albicans, where the fibres are arranged in loops, between which nerve-cells are to be found; it then passes upward into the third ventricle, and joins with the fibres of the other side, forming the body of the fornix; from this the posterior pillars diverge, and, entering the middle cornu of the lateral ventricle, part of its fibres are distributed to the hippocampus major, and the remainder end as the tænia hippocampi or fimbria, which is continued as a distinct piece to the *crochet* or *uncus* of the uncinate convolution.

(*b*) The *longitudinal fibres of the corpus callosum*, or *nerves of Lancisi*, connect the anterior and posterior extremities of the gyrus fornicatus or convolution of the corpus callosum.

(*c*) The *tænia semicircularis*, situated between the corpus striatum and optic thalamus in the lateral ventricle, is connected in front with the anterior pillar of the fornix, and behind with a nucleus of gray matter (*nucleus amygdalæ*) situated at the apex of the temporo-sphenoidal lobe and projecting into the termination of the middle horn of the lateral ventricle.

(*d*) The *uncinate fasciculus* connects the convolutions of the frontal and temporo-sphenoidal lobes. It passes across the bottom of the Sylvian fissure and traverses the claustrum.

(*e*) The *fillet of the gyrus fornicatus* is a band of white matter which encircles the hemisphere in an antero-posterior direction, lying in the substance of the convolution of the corpus callosum. Commencing in front at the anterior perforated space, it passes forward and upward parallel with the rostrum, winds round the genu, runs in the convolution from before backward immediately above the corpus callosum, turns round its posterior extremity, and is continued downward and forward in the temporo-sphenoidal lobe to again reach the perforated space. In its course it is connected with the secondary convolutions of the gyrus fornicatus by short arcuate fibres.

(*f*) The *inferior longitudinal fasciculus* is a collection of fibres which connects the temporo-sphenoidal and occipital lobes, running along the outer wall of the middle and posterior cornu.

[For the **Blood-vessels of the Brain,** see p. 534.]

THE CEREBELLUM.

The **Cerebellum,** or *little brain,* is that portion of the encephalon which is contained in the inferior occipital fossæ. It is situated beneath the posterior lobes of the cerebrum, from which it is separated by the tentorium. Its average weight in the male is 5 oz. 4 dr. It attains its maximum weight between the twenty-fifth and fortieth years, its increase in weight after the fourteenth year being relatively greater in the female than in the male. The proportion between the cerebellum and cerebrum is, in the male, as 1 to 8⅐, and in the female as 1 to 8¼. In the infant the cerebellum is proportionately much smaller than in the adult, the relation between it and the cerebrum being, according to Chaussier, between 1 to 13 and 1 to 26; by Cruveilhier the proportion was found to be 1 to 20. In form the cerebellum is oblong and flattened from above downward, its great diameter being from side to side. It measures from three and a half to four inches transversely and from two to two and a half inches from before backward, being about two inches thick in the centre and about six lines at the circumference, which is the thinnest part. It consists of gray and white matter: the former, darker than that of the cerebrum, occupies the surface; the latter, the interior. The surface of the cerebellum is not convoluted like the cerebrum, but traversed by numerous curved furrows or sulci, which vary in depth at different parts and separate the laminæ of which its exterior is composed.

Its *upper surface* (Fig. 478) is somewhat elevated in the median line and depressed toward its circumference; it consists of two lateral hemispheres connected together by an elevated median portion or lobe, the *superior vermiform pro-*

cess. The median lobe is the fundamental part, and in some animals, as fishes and reptiles, the only part which exists, the hemispheres being additions and attaining their maximum size in man. The hemispheres are separated in front by a deep notch, the *incisura cerebelli anterior*, which encircles the corpora quadrigemina behind; they are also separated by a similar notch behind, the *incisura cerebelli posterior*, in which is received the upper part of the falx cerebelli. The superior vermiform process (upper part of the median lobe of the cerebellum) extends from the notch on the anterior to that on the posterior border. It is divided into three lobes: the *lobulus centralis*, a small lobe, situated in the incisura anterior; the *monticulus cerebelli*, the central projecting part of the process; and the *commissura simplex*, a small lobe near the incisura posterior.

Fig. 478.

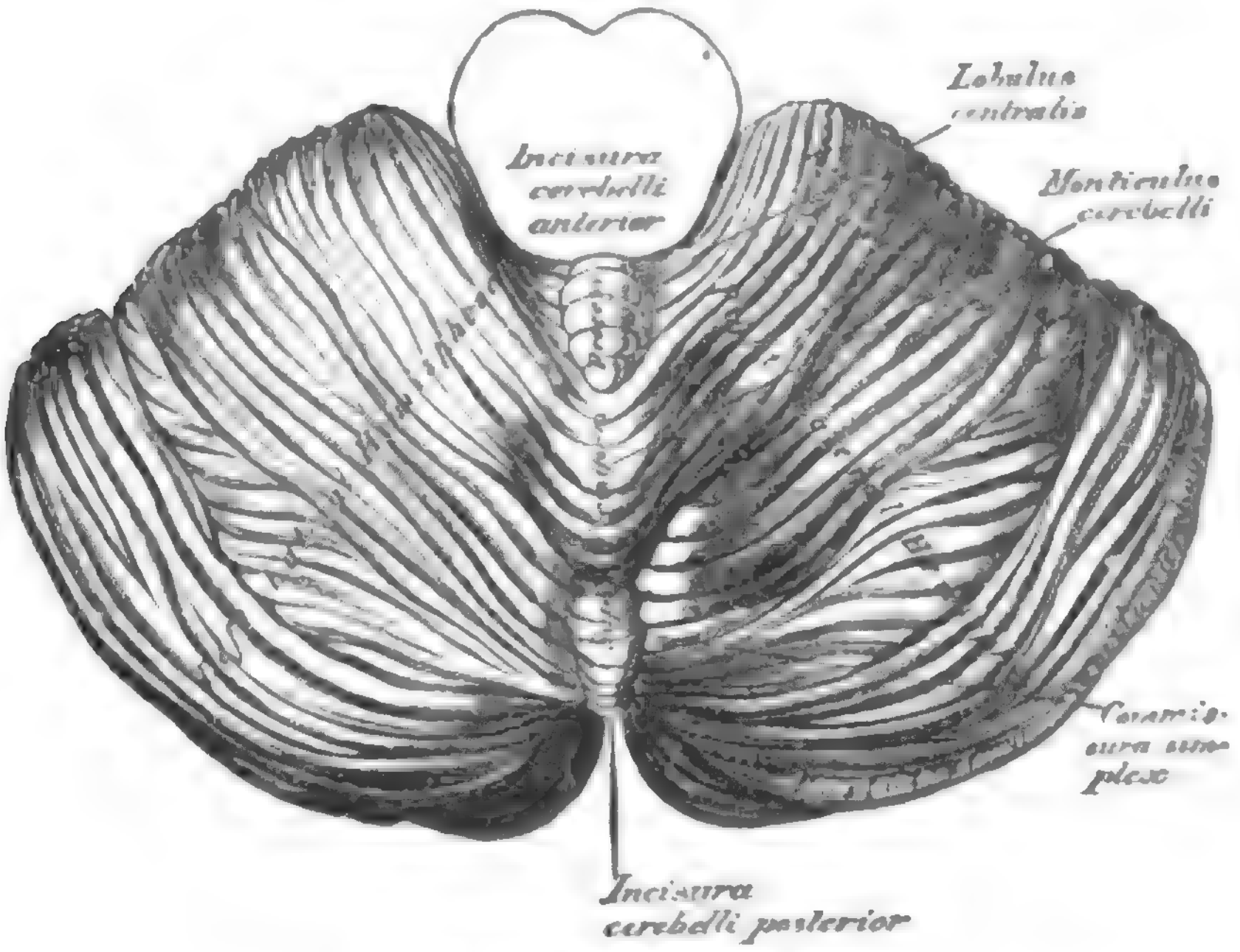
Lobulus centralis
Monticulus cerebelli
Incisura cerebelli anterior
Commissura simplex
Incisura cerebelli posterior

Upper Surface of the Cerebellum.

Fig. 479.

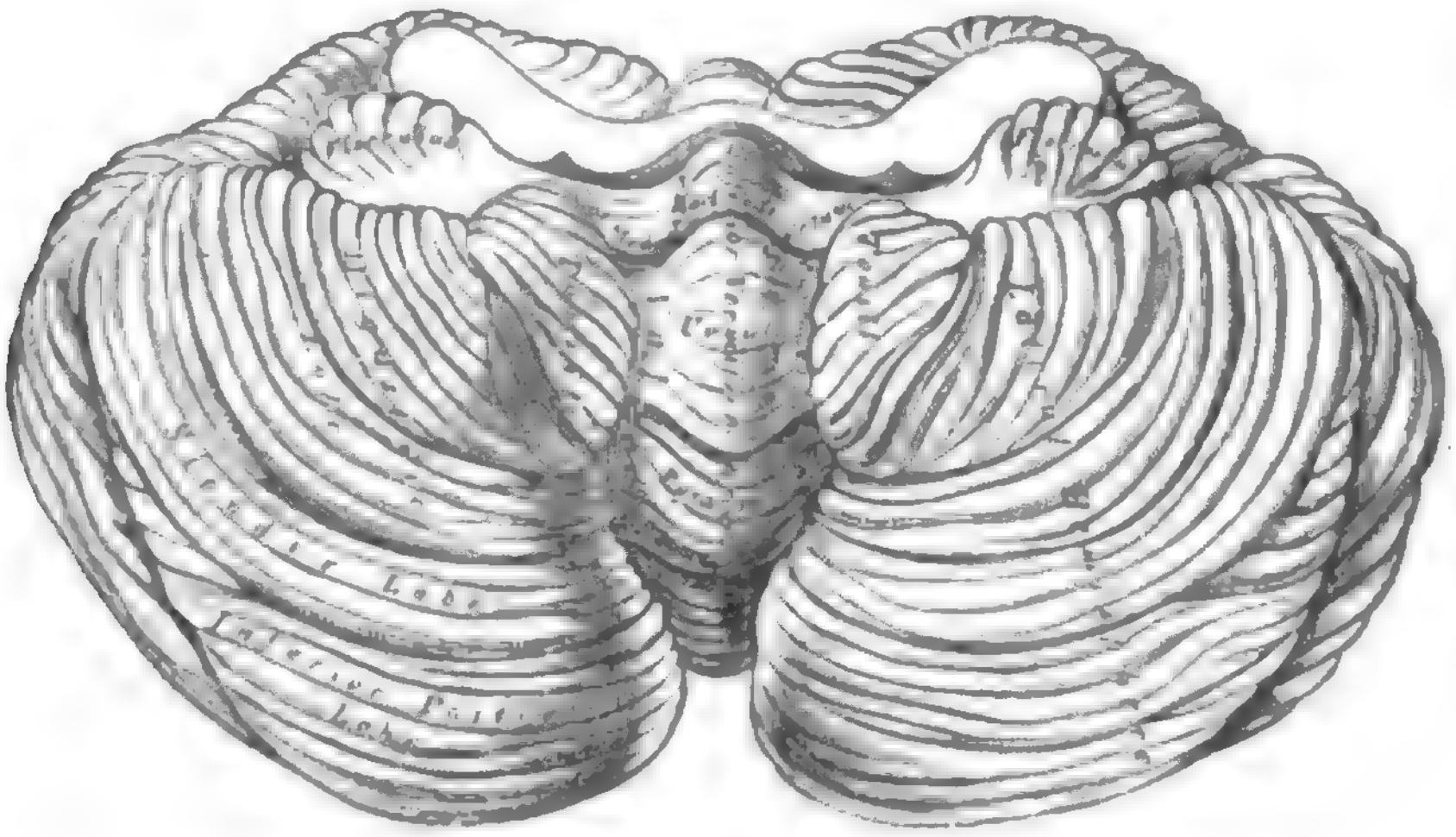
Slender Lobe
Inferior Post. Lobe

Under Surface of the Cerebellum.

The *under surface* of the cerebellum (Fig. 479) is subdivided into two lateral hemispheres by a depression, the *valley*, which extends from before backward in the middle line. The lateral hemispheres are lodged in the inferior occipital fossæ; the median depression or valley receives the back part of the medulla oblongata, is broader in the centre than at either extremity, and has projecting from its floor part of the median lobe of the cerebellum, called the *inferior vermiform process.* The parts entering into the composition of this body are, from behind forward, the *commissura brevis*, situated in the incisura posterior; in front of this, a laminated conical projection, the *pyramid;* more anteriorly, a larger eminence, the *uvula*, which is placed between the two rounded lobes, the *amygdalæ* or *tonsils*, which occupy the sides of the valley. The uvula is connected with the amygdalæ by a commissure of gray matter indented on the surface, called the *furrowed band.* In front of the uvula is the *nodule;* it is the anterior pointed termination of the inferior vermiform process, and projects into the cavity of the fourth ventricle; it has been named by Malacarne the *laminated tubercle.* On each side of the nodule is a thin layer of white substance attached externally to the flocculus and internally to the nodule; these form together the *posterior medullary velum* or commissure of the flocculus. It is usually covered in and concealed by the amygdalæ, and cannot be seen until they are drawn aside. This band is of a semilunar form on each side, its anterior margin being free and concave, its posterior attached just in front of the furrowed band. Between it and the nodule and the uvula behind is a deep fossa called the *swallow's nest* (*nidus hirundinis*).

Lobes of the Cerebellum.—Each hemisphere is divided into an upper and a lower portion by the great horizontal fissure, which commences in front at the pons and passes horizontally round the free margin of either hemisphere backward to the middle line. From this primary fissure numerous secondary fissures proceed which separate the cerebellum into lobes.

Upon the upper surface of either hemisphere there are two lobes, separated from each other by a fissure. These are the *anterior or square lobe*, which extends as far back as the posterior edge of the vermiform process, and the *posterior or semilunar lobe*, which passes from the termination of the preceding to the great horizontal fissure.

Upon the under surface of either hemisphere there are five lobes, separated by sulci; these are, from before backward—1, the *flocculus* or *subpeduncular lobe*, a prominent tuft situated behind and below the middle peduncle of the cerebellum: its surface is composed of gray matter subdivided into a few small laminæ: it is sometimes called the *pneumogastric lobule*, from being situated behind the pneumogastric nerve; 2, the *amygdala* or *tonsil*, situated on either side of the great median fissure or valley and projecting into the fourth ventricle; 3, the *digastric lobe*, situated on the outside of the tonsil and connected in part with the pyramid; 4, the *slender lobe*, behind the digastric, and connected with the back part of the pyramid and the commissura brevis; and, more posteriorly, 5, the *inferior posterior lobe*, which also joins the commissura brevis in the valley.

FIG. 480.

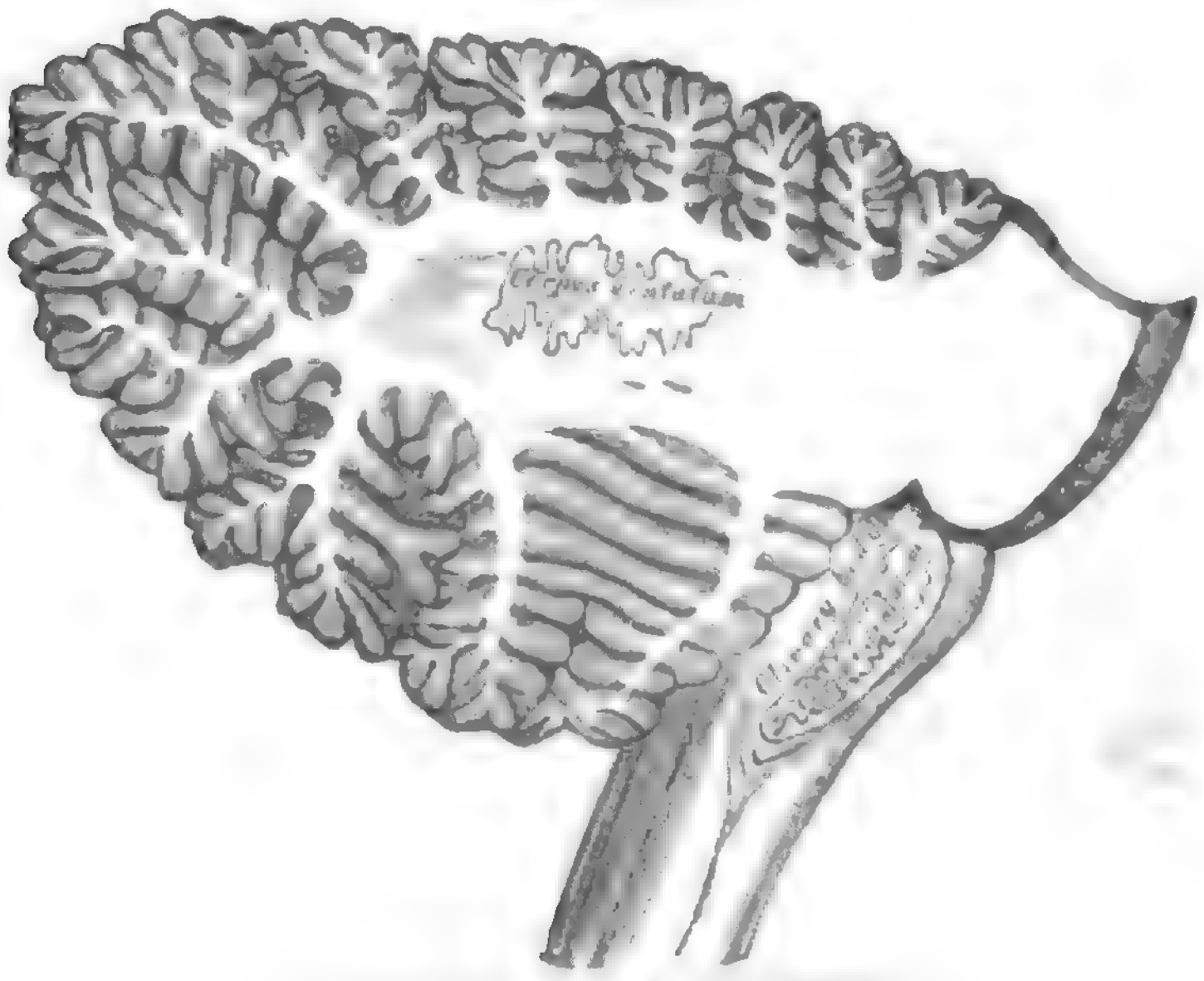

Vertical Section of the Cerebellum.

Internal Structure of the Cerebellum. — The cerebellum consists of both white and gray matter.

If a vertical section (Fig. 480) is made through either hemisphere of the cerebellum midway between its centre and the superior vermiform process, the interior will be found to consist of a central stem of white matter which contains in its interior a gray mass, the *corpus dentatum.* From the surface of this central stem a series of plates of medullary matter are detached, which, covered with gray matter, form the laminæ, and from the anterior part of each hemisphere arise three large processes or peduncles—superior, middle, and inferior—by which the cerebellum is connected with the rest of the encephalon.

The **white matter** includes two varieties of nerve-matter: (1) the *peduncular* fibres which are directly continuous with the fibres of the peduncles of the cerebellum; (2) the fibres (*fibræ propriæ*) proper to the cerebellum itself.

The *peduncles* of the cerebellum—superior, middle, and posterior—serve to connect it with the rest of the encephalon.

The *superior peduncles* (processus e cerebello ad testes) arise from the middle of the white matter of the cerebral hemispheres; they run beneath the testes of the corpora quadrigemina, and, emerging at its posterior border, pass outward and backward to the cerebellum. Each peduncle forms the upper part of the lateral boundary of the fourth ventricle, and is connected with its fellow of the opposite side by the valve of Vieussens. Beneath the corpora quadrigemina the innermost fibres of each peduncle decussate with each other, so that some fibres from the one half of the cerebrum are continued into the other half of the cerebellum. Upon entering the cerebellum the fibres of this peduncle pass to a great extent into the interior of the corpus dentatum, though some wind round it and reach the gray cortical matter, especially on its inferior surface.

The *middle peduncles* (*processus ad pontem*), the largest of the three, connect together the two hemispheres of the cerebellum, forming their great transverse commissure. They consist of a mass of curved fibres which arise in the gray matter of the foliated cortex of the hemispheres of the cerebellum and pass across the pons Varolii, forming its tranverse fibres, to the same point on the opposite side.

The *inferior peduncles* (*processus ad medullam*) connect the cerebellum with the medulla oblongata. As the restiform bodies they pass upward and outward, forming part of the lateral wall of the fourth ventricle; entering the cerebellum, they end in the gray cortex of the upper surface of this organ.

The *fibræ propriæ* of the cerebellum are of two kinds: (1) *commissural fibres*, which cross the middle line to connect the opposite halves of the hemispheres, some at the anterior part and others at the posterior part of the vermiform process; (2) *arcuate or association fibres*, which connect one lamina with another, arching across the fissures between the laminæ.

The **gray matter** of the cerebellum is found in two situations: (1) on the surface, forming the cortex; (2) as independent masses in the interior.

The gray matter of the cortex presents a characteristic foliated appearance, from its arrangement in a series of laminæ, due to the division of the central white substance into a series of plates which divide and subdivide and are capped with gray matter. This arrangement gives to the cut surface of the organ a foliated appearance, to which the name *arbor vitæ* has been applied (Fig. 480). This cortex presents a remarkable structure consisting of two distinct layers—viz. an external gray or cellular layer, and an internal rust-colored granular layer. Between the two, or rather situated in the deepest part of the gray or cellular layer, is an incomplete stratum of the characteristic cells of the cerebellum, the *corpuscles of Purkinje*. Externally, the cortex is covered by pia mater, and internally is the medullary centre, consisting mainly of nerve-fibres.

The *external gray* or *cellular layer* (Fig. 481, *a*) consists of a transparent tissue, like neuroglia, containing fibres and cells. The fibres are delicate fibrillæ running at right angles to the surface, and many of them connected with the processes of the large nerve-cells immediately below; others are delicate supporting connective-tissue-like fibres, which spread out into a broad base against the inner surface of the pia mater.

The cells are granule-like bodies, some very small and probably belonging to the neuroglia; others, according to Lockhart Clarke, connected with the processes of the corpuscles of Purkinje, which lie immediately beneath.

The *corpuscles of Purkinje* (Fig. 481, *b*) are flask-shaped cells resting in the external layer against the rust-colored internal layer. From their under surface a single slender process arises, which passes through the inner layer and becomes continuous with the axial cylinder of a medullated nerve-fibre in the medullary substance beneath. From the other extremity two peripheral processes are given off, which branch in an antler-like manner in the external layer, some of the finer processes becoming connected with the cells in this layer.

FIG. 481.

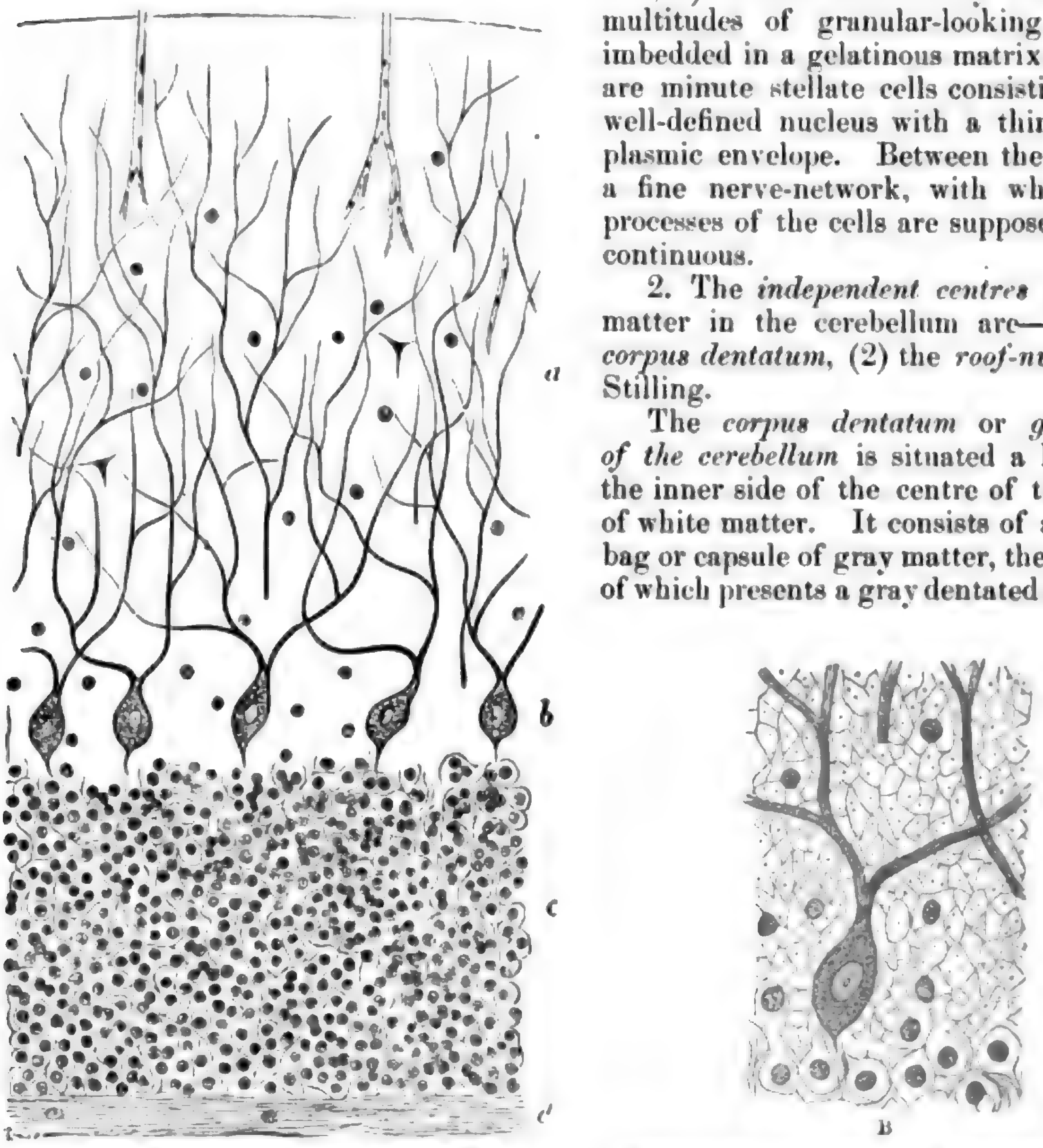

Vertical Section through the Gray Matter of the Human Cerebellum (magnified about 100 diameters—Klein and Noble Smith): *a*, the external gray or cellular layer; *b*, corpuscles of Purkinje; *c*, internal rust-colored granular layer; *d*, white substance. Two branched capillaries are seen at the upper part passing into the gray matter from the pia mater. The nerve-network has been omitted in the larger figure for the sake of clearness. It is seen in B, which shows one of the ganglion-cells of Purkinje with its dichotomously branched processes, and a portion of the adjoining granular and cellular layers. Nearer the surface the meshes of the nerve-network become more elongated, as if they were stretched out in a direction vertical to the surface. At the surface, however, they are like those here represented, but smaller.

The *inner* or *rust-colored layer* (Fig. 481, *c*) is characterized by containing multitudes of granular-looking bodies imbedded in a gelatinous matrix. They are minute stellate cells consisting of a well-defined nucleus with a thin protoplasmic envelope. Between the cells is a fine nerve-network, with which the processes of the cells are supposed to be continuous.

2. The *independent centres* of gray matter in the cerebellum are—(1) the *corpus dentatum*, (2) the *roof-nuclei* of Stilling.

The *corpus dentatum* or *ganglion of the cerebellum* is situated a little to the inner side of the centre of the stem of white matter. It consists of an open bag or capsule of gray matter, the section of which presents a gray dentated outline, open at its anterior part. It is surrounded by white fibres; white fibres are also contained in its interior, which issue from it to join the superior peduncles. The *roof-nuclei* of Stilling are two small gray masses situated at the anterior end of the superior vermiform process and projecting into the valve of Vieussens, so as to assist in the formation of the roof of the fourth ventricle.

FOURTH VENTRICLE (Fig. 441, p. 666, and Figs. 475 and 476, pp. 700 and 701).

The **fourth ventricle, or ventricle of the cerebellum,** is the space between the posterior surface of the medulla oblongata and pons in front and the cerebellum behind. It is lozenge- or diamond-shaped; that is to say, it is composed of two triangles, with their bases opposed to each other. The lower triangle appears to be formed by the divergence of the posterior pyramids or funiculi graciles and the restiform bodies of the medulla oblongata on either side. These columns pass upward and outward at an acute angle to the lateral hemispheres of the cerebellum, leaving by their divergence a triangular space which forms the lower half of the fourth ventricle. In like manner, the upper triangle appears to be formed by the divergence of the superior peduncles (processus e cerebello ad testes) of the cerebellum. These crura as they emerge from the corpora quadrigemina are in contact by their lateral margins, but they gradually diverge, passing downward, backward, and outward, to reach the cerebellum, thus enclosing a triangular space which forms the upper half of the fourth ventricle. This cavity is therefore bounded laterally by the processus e cerebello ad testes above, and by the diverging restiform bodies and posterior pyramids below.

It presents four angles. The upper angle reaches as high as the upper border of the pons; it presents the lower opening of the aqueduct of Sylvius, by which this ventricle communicates with the third ventricle. The lower angle is on a level with the lower border of the olivary body, and presents a minute opening, the aperture of the central canal of the spinal cord. At its lateral angles the fourth ventricle is extended for a short distance between the side of the medulla and the cerebellum, where these two structures come in contact.

The *roof* is arched and is formed in the upper triangle by the valve of Vieussens —a lamina of white matter streaked with gray which bridges across from one superior peduncle to the other. The roof of the lower half is formed by a reflection of pia mater passing from the under surface of the inferior vermiform process of the cerebellum to the spinal cord. Above this is the inferior vermiform process itself. This pia-matral covering is lined on its under or ventricular surface by a layer of epithelium which is continuous with that lining the sides and base of the cavity, and is perforated by a hole, the *foramen of Majendie*, by which the cavity of the ventricle communicates with the subarachnoidean space.

The *floor* is formed by the posterior surface of the medulla oblongata and pons. In the median line is seen a fissure which gradually becomes obliterated above and terminates below at the lower angle of the ventricle. From the resemblance that there is in the diverging lower boundaries of the space and the central fissure to the nib of a writing-pen, the lower triangle has been named the *calamus scriptorius.* On each side of the median fissure are two spindle-shaped longitudinal eminences, the *fasciculi teretes;* they extend the entire length of the floor, being indistinct below and of a grayish color, but well marked and whiter above. Each eminence consists of fibres derived from the lateral tract, restiform body, and posterior pyramid, which ascend to the cerebrum. External to this eminence there is a slight groove which terminates below in a little fossa, called the *fovea posterior*, and in the same groove, opposite the widest part of the ventricle, there is a second depression or fossa, called the *fovea anterior*. Above the anterior fossa and external to the fasciculi teretes is a small eminence of dark gray substance which presents a bluish tint through the thin stratum covering it; this is called the *locus cæruleus;* and a thin streak of the same color, continued up from this on either side of the fasciculi teretes as far as the top of the ventricle, is called the *tænia violacea.* The lower part of the floor of the ventricle is crossed by several white transverse lines, *lineæ transversæ;* they emerge from the posterior median fissure; some enter the crus cerebelli, others enter the roots of origin of the auditory nerve, whilst some pass upward and outward on the floor of the ventricle.

In addition to the objects above mentioned there are to be seen on the floor of the fourth ventricle several little elevations or eminences which correspond to the nuclei of origin of some of the cranial nerves, which, as before mentioned, arise from special collections of ganglion-cells in the gray matter of the floor of this cavity. One of these eminences is to be seen on either side of the middle line, close to the inferior angle of the space; this marks the nucleus of origin of the hypoglossal and spinal accessory nerve. In front and external to this, and just behind the fovea posterior, is a second eminence, which marks the nuclei of the pneumogastric and glosso-pharyngeal nerves, the lower part of the elevation corresponding to the roots of origin of the pneumogastric; the upper part to that of the glosso-pharyngeal. In front of the fovea posterior and in a line with the preceding elevation is a third, which marks the position of the nucleus of the auditory nerve. Finally, in the upper part of the space close behind the fovea anterior is a rounded elevation which denotes the common nucleus of the abducent and facial nerves.

The *lining membrane* of the fourth ventricle is continuous with that of the third through the aqueduct of Sylvius, and its cavity communicates below with the subarachnoid space of the brain and cord through an aperture in the layer of pia mater extending between the cerebellum and medulla oblongata. Laterally, this membrane is reflected outward a short distance between the cerebellum and medulla.

The *choroid plexuses* of the fourth ventricle are two in number: they are delicate vascular fringes which project into the ventricle on each side, passing from the point of the inferior vermiform process to the outer margin of the restiform bodies.

The *gray matter* in the floor of the ventricle consists of a tolerably thick stratum continuous below with the gray commissure of the cord, and extending up as high as the aqueduct of Sylvius, and, in addition, of some special deposits connected with the roots of origin of certain nerves which have already been referred to.

Cranial Nerves.

THE **Cranial Nerves** arise from some part of the cerebro-spinal centre, and are transmitted through foramina in the base of the cranium. They have been named by Willis numerically, according to the order in which they pass out of the base of the brain. Other names are also given to them, derived from the parts to which they are distributed or from their functions. Taken in their order, from before backward, they are as follows:

1st,	Olfactory.	7th,	Facial (Portio dura).
2d,	Optic.		Auditory (Portio mollis).
3d,	Motor oculi.	8th,	Glosso-pharyngeal.
4th,	Pathetic.		Pneumogastric (Par vagum).
5th,	Trifacial (Trigeminus).		Spinal Accessory.
6th,	Abducens.	9th,	Hypoglossal.

It will be seen, however, that this arrangement is somewhat defective; that, in fact, two entirely separate and distinct nerves, the facial and auditory, are classed together as the seventh pair; and that three nerves, the glosso-pharyngeal, pneumogastric, and spinal accessory, are included in the eighth pair. This has induced Sömmerring to alter the numerical arrangement somewhat. He considers the seventh pair as consisting of two nerves, which he enumerates as seventh and eighth respectively, and the eighth pair as consisting of three distinct nerves, which he names the ninth, tenth, and eleventh, while the last, or ninth nerve of Willis, he calls the twelfth cranial nerve.

The following table will show the respective arrangements:

	Sömmerring.		Willis.	
Olfactory,	First	pair.	First	pair.
Optic,	Second	"	Second	"
Motor oculi,	Third	"	Third	"
Pathetic,	Fourth	"	Fourth	"
Trifacial,	Fifth	"	Fifth	"
Abducens,	Sixth	"	Sixth	"
Facial (Portio dura),	Seventh	"	Seventh	"
Auditory (Portio mollis),	Eighth	"		
Glosso-pharyngeal,	Ninth	"	Eighth	"
Pneumogastric,	Tenth	"		
Spinal Accessory,	Eleventh	"		
Hypoglossal,	Twelfth	"	Ninth	"

There can be no doubt that the arrangement of Sömmerring is the better of the two, and it is gradually being adopted by anatomical writers of the present day. It has been thought better, therefore, to alter the plan that has hitherto been adopted in this work, and to adopt the nomenclature of Sömmerring. [The little branch of the hypoglossal nerve descending on the sheath of the carotid artery, however, still retains its old name, the *ramus descendens noni* (descending branch of the ninth), though really a branch of the twelfth nerve.

The cranial nerves may be subdivided into four groups, according to the peculiar function possessed by each—viz. nerves of special sense, nerves of common sensation, nerves of motion, and mixed nerves. These groups may be thus arranged:

Nerves of Special Sense.

- Olfactory.
- Optic.
- Auditory.
- Part of glosso-pharyngeal.
- Lingual or gustatory branch of fifth.

Nerves of Common Sensation.

- Fifth (greater portion).
- Part of glosso-pharyngeal.

Nerves of Motion.

- Motor oculi.
- Pathetic.
- Part of third division of fifth.
- Abducens.
- Facial.
- Hypoglossal.

Mixed Nerves.

- Pneumogastric.
- Spinal accessory.

All the cranial nerves are connected to some part of the surface of the brain. This is termed their *superficial* or *apparent origin*. But their fibres may, in all cases, be traced deeply into the substance of the organ. This part is called their *deep* or *real origin*.[1]

First Nerve (Fig. 466, p. 688).

The **first** or **Olfactory Nerve**, the special nerve of the sense of smell, is in reality a slender process of brain-substance extending forward on the under surface of the frontal lobe and terminating in a bulbous extremity, from which the olfactory nerves are given off. The process arises by three roots.

The *external*, or *long*, *root* is a narrow, white, medullary band which passes outward across the fissure of Sylvius into the substance of the island of Reil. Its deep origin has been traced to the nucleus of gray matter in the temporo-sphenoidal lobe in front of the pes hippocampi.

The *middle*, or *gray*, *root* arises from a papilla of gray matter (*caruncula mammillaris*) imbedded in the anterior lobe. It contains white fibres in its interior which are connected with the corpus striatum.

The *internal*, or *short*, *root* is composed of white fibres which arise from the inner and back part of the anterior lobe, being connected, according to Foville, with the longitudinal fibres of the gyrus fornicatus.

These three roots unite and form a flat band, narrower in the middle than at either extremity, and of a somewhat prismoid form on section. It is soft in texture, and contains a considerable amount of gray matter in its substance. As it passes forward it is contained in a deep sulcus between two convolutions lying on the under surface of the anterior lobe, on either side of the longitudinal fissure, and is retained in position by the arachnoid membrane which covers it. On reaching the cribriform plate of the ethmoid bone it expands into an oblong mass of gray brain-substance, the *olfactory bulb*. From the under part of this bulb are given off numerous filaments, about twenty in number, which pass through the cribriform foramina and are distributed to the mucous membrane of the nose. Each filament is surrounded by a tubular prolongation from the dura mater and pia mater, the former being lost on the periosteum lining the nose; the latter, in the neurilemma of the nerve. The filaments, as they enter the nares, are divisible into three groups: an inner group, larger than those on the outer wall, spread out over the upper third of the septum; a middle set, confined to the roof of the nose; and an outer set, which are distributed over the superior and middle turbinated bones and the surface of the ethmoid in front of them. As the filaments descend they unite in a plexiform network, and are believed by most observers to terminate in the *cells of Schultze.*

---

[1] The deep origin, or point of connection, of the cranial nerves with the brain is still, in some instances, a matter of uncertainty. It seems probable that each of them arises from some special centre of gray matter, termed a *nucleus:* at all events, many of them can be traced to such special nuclei, through which, no doubt, they are connected with other portions of the cerebral mass. It has been thought advisable in the text to give only the most modern views as to the deep origin of these nerves, without burdening the student's mind with all the different opinions of anatomists which have at various times been set forth in regard to the place from which these nerves take their origin. For these recent views the Editor, as stated in a former edition, is indebted to the late Dr. Lockhart Clarke.

The olfactory differs in structure from other nerves in containing gray matter in its interior and being soft and pulpy in consistence. Its filaments are deficient in the white substance of Schwann, and consist of axis-cylinders with a distinct nucleated sheath, in which there are, however, fewer nuclei than in ordinary non-medullated fibres.

SECOND NERVE.

The **second** or **Optic Nerve,** the special nerve of the sense of sight, is distributed exclusively to the eyeball. The nerves of opposite sides are connected together at the commissure, and from the back of the commissure they may be traced to the brain under the name of the optic tracts.

The *optic tract* at its connection with the brain is divided into two bands. One of these arises from the *stratum opticum* of the corpora quadrigemina, emerges from this body as the anterior brachium, and passes between the inner and outer geniculate bodies; the other arises from the optic thalamus and passes through the inner geniculate body, from which it derives fibres, and joins with the other band to form the tract. From this origin the tract winds obliquely across the under surface of the crus cerebri in the form of a flattened band destitute of neurilemma, and is attached to the crus by its anterior margin. It then assumes a cylindrical form, and as it passes forward is connected with the tuber cinereum and lamina cinerea, from both of which it receives fibres. It finally joins with the tract of the opposite side to form the *optic commissure.*

FIG. 482.

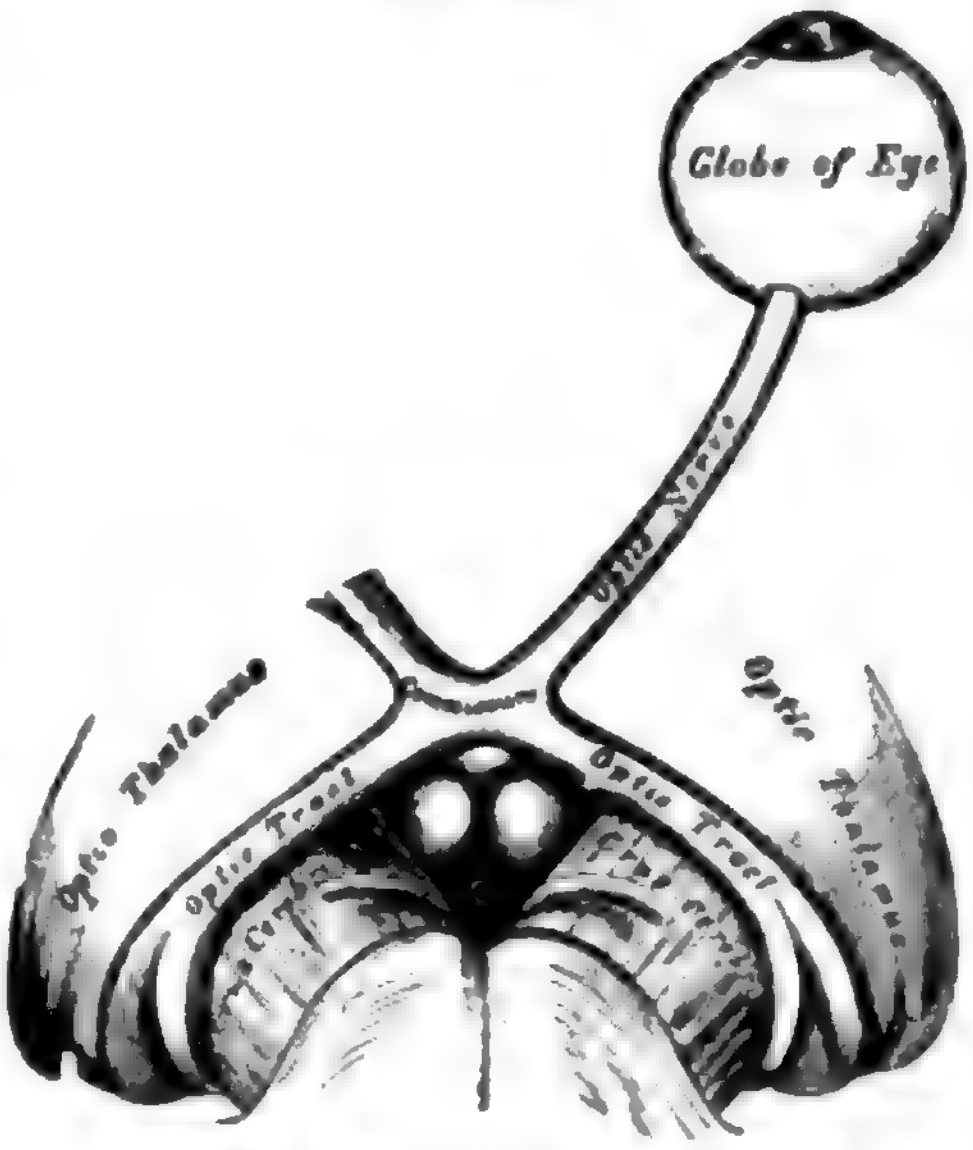

The Optic Nerves and Optic Tracts.

The *commissure* or *chiasma,* somewhat quadrilateral in form, rests upon the optic groove of the sphenoid bone, being bounded above by the lamina cinerea, behind by the tuber cinereum, on either side by the anterior perforated space. Within the commissure the optic nerves of the two sides undergo a partial decussation. The fibres which form the inner margin of each tract are continued across from one to the other side of the brain, and have no connection with the optic nerves. These may be regarded as commissural fibres (*intercerebral*) between the thalami of opposite sides. Some fibres are continued across the anterior border of the chiasma, and connect the optic nerves of the two sides, having no relation with the optic tracts.[1] They may be regarded as commissural fibres between the two retinæ (*interretinal fibres*). The outer fibres of each tract are continued into the optic nerve of the same side. The central fibres of each tract are continued into the optic nerve of the opposite side, decussating in the commissure with similar fibres of the opposite tract.[2]

FIG. 483.

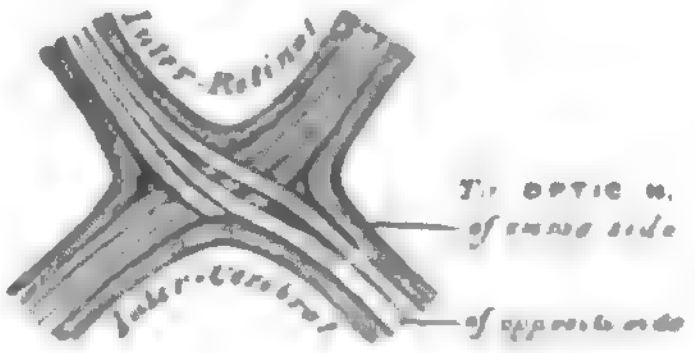

Course of the Fibres in the Optic Commissure.

The *optic nerves* arise from the fore part of the commissure, and, diverging from one another, become rounded in form and firm in texture, and are enclosed in a sheath derived from the arachnoid. As each nerve passes through the corresponding optic foramen it receives a sheath from the dura mater, and as it enters the orbit this sheath subdivides into two layers, one of which becomes continuous with the periosteum of the orbit; the other forms a sheath for the nerve and surrounds it as far as the sclerotic. The nerve passes through the cavity of the orbit, pierces the sclerotic and choroid coats at the back part of the eyeball a little to the nasal side of its centre, and expands into the retina. Arnold describes a communication between the optic nerve in the orbit and the ascending branches of Meckel's ganglion. A small artery, the *arteria centralis retinæ*, perforates the optic nerve a little behind the globe, and runs along its interior in a tubular canal of fibrous tissue. It supplies the inner surface of the retina and is accompanied by corresponding veins. [For the exact connection between the optic nerve and the retina see the description of the Eye.]

---

[1] The presence of these fibres has been doubted by some observers, but they have been recently asserted to exist by Stilling.

[2] A specimen of congenital absence of the optic commissure is to be found in the museum of the Westminster Hospital.

THIRD NERVE (Figs. 484, 485).

FIG. 484.

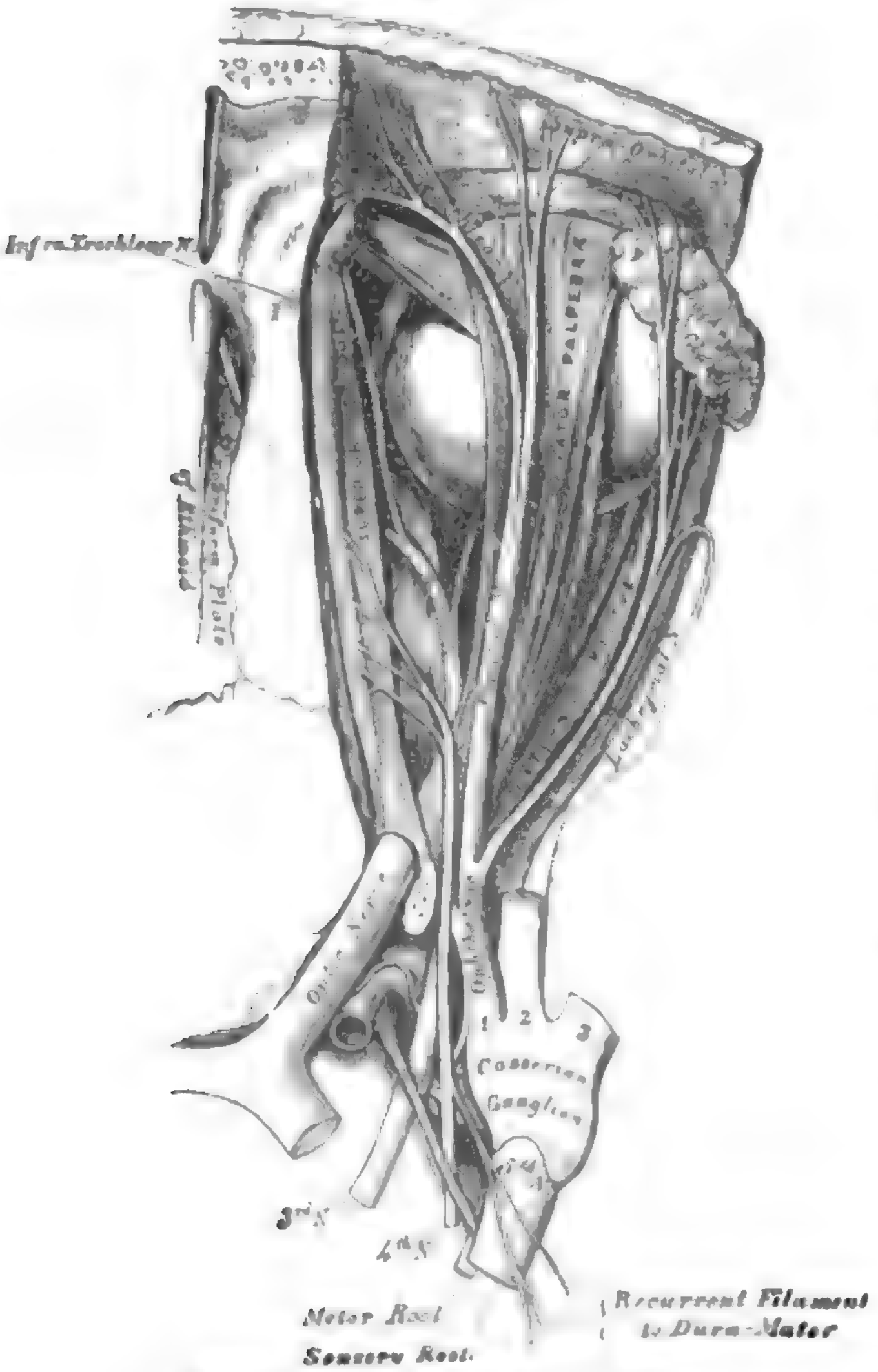

Nerves of the Orbit, seen from above.

The third or **Motor oculi Nerve** supplies all the muscles of the orbit except the Superior oblique and External rectus; it also sends motor filaments to the iris and the ciliary muscle. It is a rather large nerve, of rounded form and firm texture, having its apparent origin from the inner surface of the crus cerebri immediately in front of the pons Varolii.

The *deep origin* may be traced through the locus niger and tegmentum of the crus to a nucleus situated on either side of the median line in the floor of the aqueduct of Sylvius, beneath the corpora quadrigemina. On emerging from the brain the nerve is invested with a sheath of pia mater and enclosed in a prolongation from the arachnoid. It then pierces the dura mater below and external to the posterior clinoid process, passing between the two processes from the free and attached borders of the tentorium, which are prolonged forward to be connected with the anterior and posterior clinoid processes of the sphenoid bone. It passes along the outer wall of the cavernous sinus, above the other orbital nerves, receiving in its course one or two filaments from the cavernous plexus of the sympathetic. It then divides into two branches, which enter the orbit through the sphenoidal fissure between the two heads of the External rectus muscle. On passing through the fissure the nerve is placed below the fourth and the frontal and lachrymal branches of the ophthalmic nerve, and has, passing between its two divisions, the nasal nerve.

The *superior division*, the smaller, passes inward over the optic nerve, and supplies the Superior rectus and Levator palpebræ. It occasionally communicates with the ganglionic branch of the nasal nerve.

The *inferior division*, the larger, divides into three branches. One passes beneath the optic nerve to the Internal rectus, another to the Inferior rectus, and the third, the largest of the three, passes forward between the Inferior and External recti to the Inferior oblique. From the latter a short thick branch is given off to the lower part of the lenticular ganglion, which forms its inferior root and gives one or two filaments to the Inferior rectus. All these branches enter the muscles on their ocular surface.

FOURTH NERVE (Fig. 484).

The **fourth** or **Pathetic Nerve** (*trochlear*), the smallest of the cranial nerves, supplies the Superior oblique muscle. Its *apparent* origin, at the base of the brain, is on the outer side of the crus cerebri, just in front of the pons Varolii, but the fibres can be traced backward behind the corpora quadrigemina to the valve of Vieussens, on the upper surface of which the two nerves are connected by a transverse band of fibres, forming a partial decussation. Its *deep* origin may be traced to a nucleus in the floor of the aqueduct of Sylvius immediately below that of the third nerve. The nerve winds round the outer side of the crus cerebri immediately above the pons Varolii, pierces the dura mater in the free border of the tentorium cerebelli near the posterior clinoid process, above the oval opening for the fifth nerve, and passes forward through the outer wall of the cavernous sinus between the third and the ophthalmic division of the fifth. It crosses the third nerve and enters the orbit through the sphenoidal fissure. It now becomes the highest of all the nerves, lying at the inner extremity of the fissure internal to the frontal nerve. In the orbit it passes inward above the origin of the Levator palpebræ, and finally enters the orbital surface of the Superior oblique muscle.

In the outer wall of the cavernous sinus this nerve receives some filaments from the cavernous plexus of the sympathetic. It is not unfrequently blended with the ophthalmic division of the fifth, and occasionally gives off a branch to assist in the formation of the lachrymal nerve. It also gives off a recurrent branch, which passes backward between the layers of the tentorium, dividing into two or three filaments which may be traced as far back as the wall of the lateral sinus.

FIFTH NERVE.

The **fifth** or **Trifacial Nerve** (*trigeminus*) is the largest cranial nerve, and resembles a spinal nerve in several particulars: it arises by two roots; of these the anterior is the smaller and is the motor root, the posterior the larger and sensory. Moreover, like the spinal nerves, the posterior or sensory root has a ganglion developed upon it. The functions of this nerve are various. It is a nerve of common sensation and of motion, and perhaps to a certain extent of special sense. It is the great sensitive nerve of the head and face, the motor nerve of the muscles of mastication, and its lingual branch is possibly one of the nerves of the special sense of taste. It arises by two roots—a posterior larger or sensory, and an anterior smaller or motor root. Its *superficial origin* is from the side of the pons Varolii, a little nearer to the upper than the lower border. The smaller root consists of three or four bundles; in the larger the bundles are more numerous, varying in number from seventy to a hundred; the two roots are separated from one another by a few of the transverse fibres of the pons. The large root of the fifth or trigeminal arises chiefly from the gray tubercle of Rolando or the upper expanded extremity of the posterior gray horn of the medulla; the small or motor root arises from two masses of larger multipolar cells situated on the inner side and close to the gray tubercle, and intimately connected with it. The two roots of the nerve pass forward through an oval opening in the dura mater on the superior border of the petrous portion of the temporal bone, above the internal auditory meatus: they then run between the bone and the dura mater to the apex of the petrous portion of the temporal bone, where the fibres of the sensory root form a large semilunar ganglion (*Gasserian*), while the motor root passes beneath the ganglion without having any connection with it, and outside the cranium joins with one of the trunks derived from it.

The **Gasserian** or **semilunar ganglion**[1] is lodged in a depression near the apex of the petrous portion of the temporal bone. It is of somewhat crescentic form, with its convexity turned forward. Its upper surface is intimately adherent to the dura mater. Besides the small or motor root the large superficial petrosal nerve lies underneath the ganglion.

Branches.—This ganglion receives on its *inner side* filaments from the carotid plexus of the sympathetic, and from it some minute branches are given off to the tentorium cerebelli and the dura mater in the middle fossa of the cranium. From its *anterior border*, which is directed forward and outward, three large branches proceed—the *ophthalmic*, *superior maxillary*, and *inferior maxillary*. The ophthalmic and superior maxillary consist exclusively of fibres derived from the larger root and ganglion, and are solely nerves of common sensation. The third division, or inferior maxillary, is composed of fibres from both roots. This, therefore, strictly speaking, is the only portion of the fifth nerve which can be said to resemble a spinal nerve.

FIG. 485.

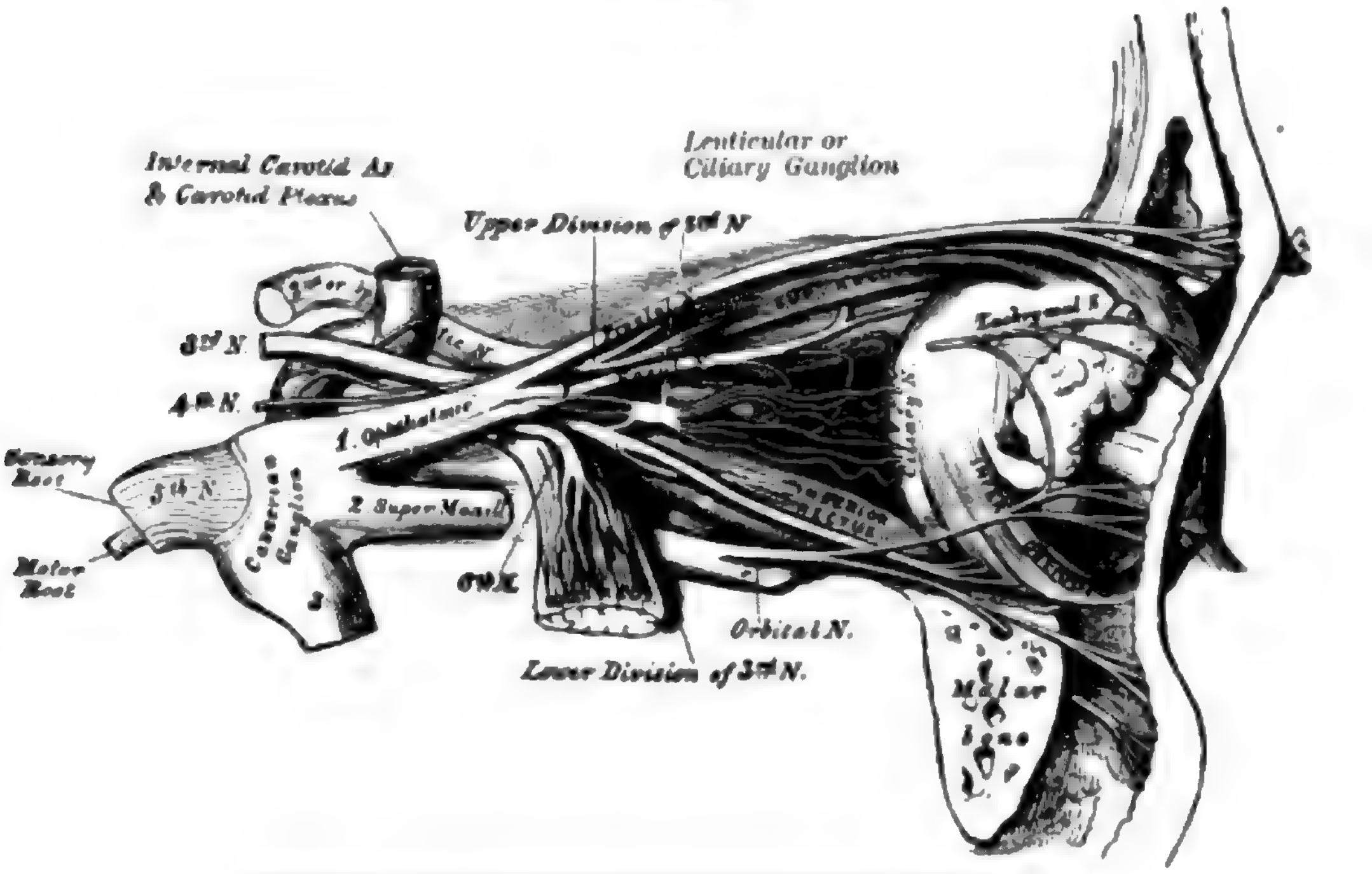
Internal Carotid Ay & Carotid Plexus
Lenticular or Ciliary Ganglion
Upper Division of 3rd N
3rd N.
4th N.
1. Ophthalmic
Sensory Root
5th N.
Gasserian Ganglion
2. Super Maxill.
Motor Root
3
6th N.
Orbital N.
Lower Division of 3rd N.
Malar bone
Inferior Rectus

Nerves of the Orbit and Ophthalmic Ganglion (side view).

OPHTHALMIC NERVE (Figs. 484, 485).

The **Ophthalmic**, or first division of the fifth, is a sensory nerve. It supplies the eyeball, the lachrymal gland, the mucous lining of the eye and nasal fossæ, and the integument and muscles of the eyebrow, forehead, and nose. It is the smallest of the three divisions of the fifth, arising from the upper part of the Gasserian ganglion. It is a short, flattened band about an inch in length, which passes forward along the outer wall of the cavernous sinus below the other nerves, and just before entering the orbit through the sphenoidal fissure divides into three branches, *lachrymal*, *frontal*, and *nasal*. The ophthalmic nerve is joined by filaments from the cavernous plexus of the sympathetic, communicates with the third and sixth nerve, and is not unfrequently joined with the fourth, and gives off recurrent filaments which pass between the layers of the tentorium along with a branch from the fourth nerve.

---

[1] I am indebted to my friend Mr. J. McCarthy for the following note: "A Viennese anatomist, Raimund Balthasar Hirsch (1765), was the first who recognized the ganglionic nature of the swelling on the sensory root of the fifth nerve, and called it, in honor of his otherwise unknown teacher, Jon. Laur. Gasser, the 'ganglion Gasseri.' Julius Casserius, whose name is given to the musculo-cutaneous nerve of the arm, was professor at Padua, 1545–1605." (See Hyrth, *Lehrbuch der Anatomie*, p. 895 and p. 55.)

Its branches are the

Lachrymal. Frontal. Nasal.

The **Lachrymal** is the smallest of the three branches of the ophthalmic. Not unfrequently it arises by two filaments, one from the ophthalmic, the other from the fourth; and this Swan considers to be its usual condition. It passes forward in a separate tube of dura mater, and enters the orbit through the narrowest part of the sphenoidal fissure. In the orbit it runs along the upper border of the External rectus muscle with the lachrymal artery, and sends off a recurrent branch which joins the orbital branch of the superior maxillary nerve and occasionally takes the place of the temporal branch of this nerve, which is then absent. Within the lachrymal gland it gives off several filaments, which supply the gland and the conjunctiva. Finally, it pierces the palpebral ligaments, and terminates in the integument of the upper eyelid, joining with filaments of the facial nerve.

The **Frontal** is the largest division of the ophthalmic, and may be regarded, both from its size and direction, as the continuation of the nerve. It enters the orbit above the muscles, through the highest and broadest part of the sphenoidal fissure, and runs forward along the middle line between the Levator palpebræ and the periosteum. Midway between the apex and the base of the orbit it divides into two branches, supratrochlear and supraorbital.

The *supratrochlear branch*, the smaller of the two, passes inward above the pulley of the Superior oblique muscle, and gives off a descending filament which joins with the infratrochlear branch of the nasal nerve. It then escapes from the orbit between the pulley of the Superior oblique and the supraorbital foramen, curves up on to the forehead close to the bone, and ascends beneath the Corrugator supercilii and Occipito-frontalis muscles, to both of which it is distributed;[1] finally, it is lost in the integument of the forehead.

The *supraorbital branch* passes forward through the supraorbital foramen, and gives off in this situation palpebral filaments to the upper eyelid. It then ascends upon the forehead, and terminates in muscular, cutaneous, and pericranial branches. The *muscular branches* supply the Corrugator supercilii, Occipito-frontalis, and Orbicularis palpebrarum, furnishing these muscles with common sensation and joining in the substance of the latter muscle with the facial nerve. The *cutaneous branches*, two in number, an inner and an outer, supply the integument of the cranium as far back as the occiput. They are at first situated beneath the Occipito-frontalis, the inner branch perforating the frontal portion of the muscle, the outer branch its tendinous aponeurosis. The *pericranial branches* are distributed to the pericranium over the frontal and parietal bones. They are derived from the cutaneous branches whilst beneath the muscle.

The **Nasal Nerve** is intermediate in size between the frontal and lachrymal, and more deeply placed than the other branches of the ophthalmic. It enters the orbit between the two heads of the External rectus, and passes obliquely inward across the optic nerve, beneath the Levator palpebræ and Superior rectus muscles, to the inner wall of the orbit, where it enters the anterior ethmoidal foramen, immediately below the Superior oblique. It then enters the cavity of the cranium, traverses a shallow groove on the front of the cribriform plate of the ethmoid bone, and passes down, through the slit by the side of the crista galli, into the nose, where it divides into two branches, an internal and an external. The *internal branch* supplies the mucous membrane near the fore part of the septum of the nose. The *external branch* descends in a groove on the inner surface of the nasal bone, and supplies a few filaments to the mucous membrane covering the fore part of the outer wall of the nares as far as the inferior spongy bone; it then leaves the cavity of the nose between the lower border of the nasal bone and the upper lateral cartilage of the nose, and, passing down beneath the Compressor nasi, supplies the integument of the ala and the tip of the nose, joining with the facial nerve.

---

[1] The student should remember that the first two divisions of the fifth nerve are purely sensory, and that in the text, when branches are described from these two divisions as supplying muscles, it is only with sensation, and that these nerves are not their true motor supply.

The branches of the nasal nerve are the *ganglionic*, *ciliary*, and *infratrochlear*.

[Fig. 486.

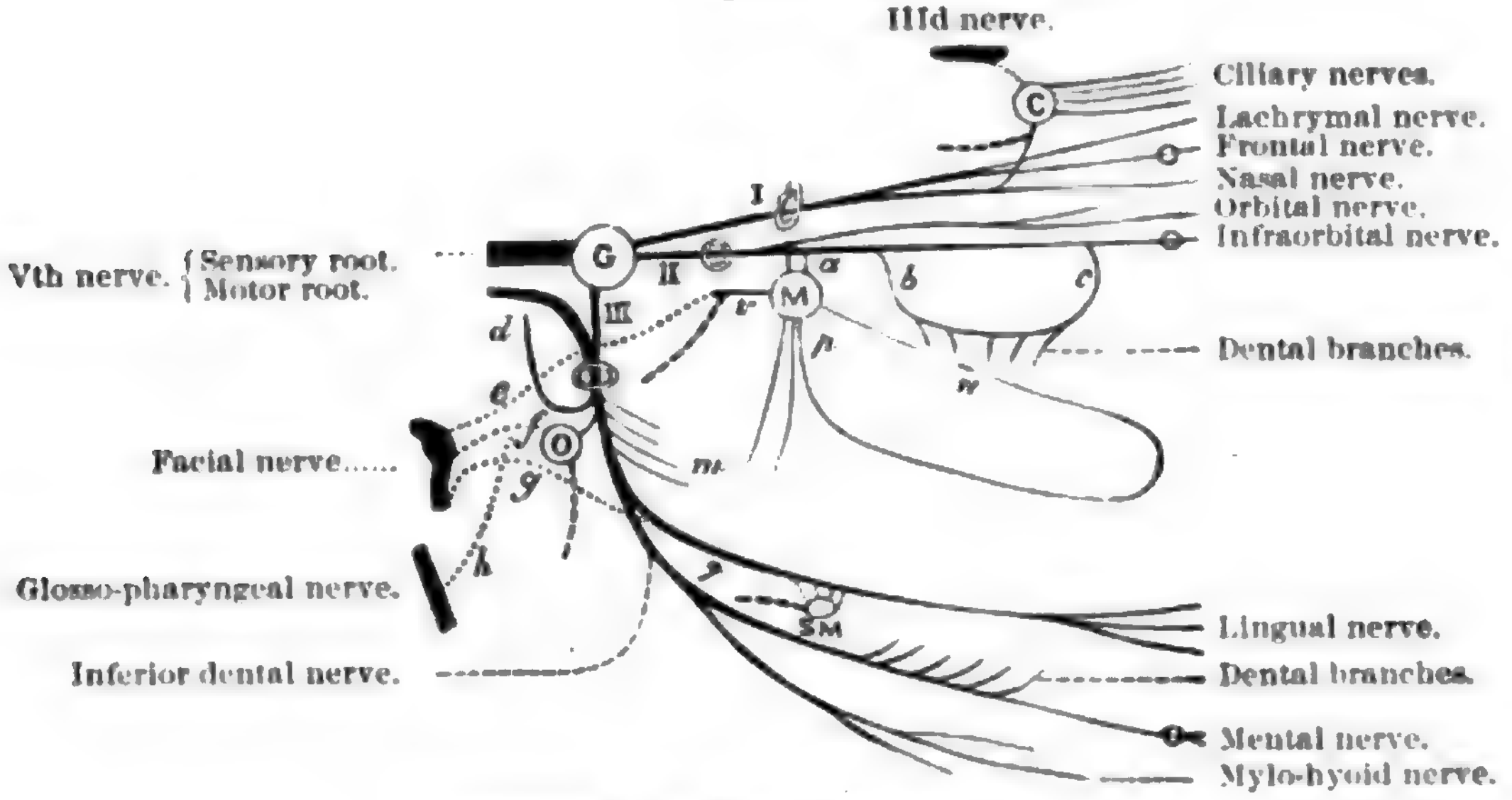

Diagram of the Fifth Nerve and its Ganglia.

G, Ganglion of Gasser.
C. Ciliary ganglion.
M, Meckel's ganglion.
O, Otic ganglion.
S M. Submaxillary ganglion.
I, First or ophthalmic division of fifth passing through the sphenoidal fissure.
II, Second or superior maxillary division of fifth passing through the foramen rotundum.
III, Third or inferior maxillary division of fifth (containing all the motor root) passing through the foramen ovale.
.... Motor roots of the ganglia.
——— Sensory roots of the ganglia.
------ Sympathetic roots of the ganglia.
a, Spheno-palatine nerves.
b, Posterior dental nerve.
c, Anterior dental nerve.
d, Auriculo-temporal nerve.
e, Greater (or large) superficial petrosal nerve, which, after it is joined by the sympathetic branch from the carotid plexus, becomes the Vidian (*r*) and goes to the ganglion of Meckel (M).
f, Lesser (or small) superficial petrosal going to the otic ganglion (O).
g, *g*, Chorda tympani nerve going to join the inferior dental, and thence to the submaxillary ganglion (S M).
h, Branch of Jacobson's nerve (glosso-pharyngeal), which joins the lesser superficial petrosal nerve.
m, Muscular branches to muscles of mastication.
n, Naso-palatine nerve.
p, Palatine nerves, the anterior anastomosing with the naso-palatine.
r, Vidian nerve.

The three foramina of exit of the fifth nerve on the face are indicated by small circles on the frontal, infraorbital, and mental nerves.—W. W. K.]

The *ganglionic* is a slender branch, about half an inch in length, which usually arises from the nasal between the two heads of the External rectus. It passes forward on the outer side of the optic nerve, and enters the superior and posterior angle of the ciliary ganglion, forming its superior or long root. It is sometimes joined by a filament from the cavernous plexus of the sympathetic or from the superior division of the third nerve.

The *long ciliary nerves*, two or three in number, are given off from the nasal as it crosses the optic nerve. They join the short ciliary nerves from the ciliary ganglion, pierce the posterior part of the sclerotic, and, running forward between it and the choroid, are distributed to the ciliary muscle and iris.

The *infratrochlear branch* is given off just as the nasal nerve passes through the anterior ethmoidal foramen. It runs forward along the upper border of the Internal rectus, and is joined beneath the pulley of the Superior oblique by a filament from the supratrochlear nerve. It then passes to the inner angle of the eye, and supplies the integument of the eyelids and side of the nose, the conjunctiva, lachrymal sac, and caruncula lachrymalis.

OPHTHALMIC, LENTICULAR, OR CILIARY GANGLION (Fig. 485).

Connected with the three divisions of the fifth nerve are four small ganglia. With the first division is connected the *ophthalmic ganglion;* with the second division, the *spheno-palatine* or *Meckel's ganglion;* and with the third, the *otic* and *submaxillary* ganglia. All the four receive sensitive filaments from the fifth, and motor and sympathetic filaments from various sources; these filaments are called the *roots of the ganglia.* The ganglia are also connected with the cervical portion of the sympathetic.

The **Ophthalmic, Lenticular,** or **Ciliary Ganglion** is a small, quadrangular, flattened ganglion, of a reddish-gray color and about the size of a pin's head, situated at the back part of the orbit between the optic nerve and the External rectus muscle, lying generally on the outer side of the ophthalmic artery. It is enclosed in a quantity of loose fat, which makes its dissection somewhat difficult.

Its *branches of communication* or *roots* are three, all of which enter its posterior border. One, the long root [sensory], is derived from the nasal branch of the ophthalmic, and joins its superior angle. The second, the short root [motor], is a short thick nerve, occasionally divided into two parts, which is derived from the branch of the third nerve for the Inferior oblique muscle, and is connected with the inferior angle of the ganglion. The third, the sympathetic root, is a slender filament from the cavernous plexus of the sympathetic. This is frequently blended with the long root, but sometimes passes to the ganglion separately. According to Tiedemann, this ganglion receives a filament of communication from the spheno-palatine ganglion.

Its *branches of distribution* are the short ciliary nerves. These are delicate filaments, from six to ten in number, which arise from the fore part of the ganglion in two bundles, connected with its superior and inferior angles; the lower bundle is the larger. They run forward with the ciliary arteries in a wavy course, one set above and the other below the optic nerve, and are joined by the long ciliary from the nasal. They pierce the sclerotic at the back part of the globe, pass forward in delicate grooves on its inner surface, and are distributed to the ciliary muscle and iris. A small filament is described by Tiedemann, penetrating the optic nerve with the arteria centralis retinæ.

Superior Maxillary Nerve (Fig. 487).

The **Superior Maxillary,** or second division of the fifth, is a sensory nerve. It is intermediate, both in position and size, between the ophthalmic and inferior maxillary. It commences at the middle of the Gasserian ganglion as a flattened plexiform band, and passes forward through the foramen rotundum, where it becomes more cylindrical in form and firmer in texture. It then crosses the spheno-maxillary fossa, enters the orbit through the spheno-maxillary fissure, traverses the infraorbital canal in the floor of the orbit, and appears upon the face at the infraorbital foramen.[1] At its termination the nerve lies beneath the Levator labii superioris muscle, and divides into a leash of branches, which spread out upon the side of the nose, the lower eyelid, the upper lip, joining with filaments of the facial nerve.

The branches of this nerve may be divided into three groups: 1, those given off in the spheno-maxillary fossa; 2, those in the infraorbital canal; 3, those on the face.

Spheno-maxillary fossa	Orbital or Temporo-malar.
	Spheno-palatine.
	Posterior Dental.
Infraorbital canal .	Anterior Dental.
On the face . . .	Palpebral.
	Nasal.
	Labial.

In addition to these named branches the superior maxillary nerve frequently gives off a minute recurrent branch directly after its origin from the Gasserian ganglion, which supplies the dura mater.

The **orbital** or **temporo-malar branch** arises in the spheno-maxillary fossa, enters the orbit by the spheno-maxillary fissure, and divides at the back of that cavity into two branches, temporal and malar.

---

[1] After it enters the infraorbital canal the nerve is frequently called the *infraorbital.*

The *temporal branch* runs in a groove along the outer wall of the orbit (in the malar bone), receives a branch of communication from the lachrymal, and, passing through a foramen in the malar bone, enters the temporal fossa. It ascends between the bone and substance of the Temporal muscle, pierces this muscle and the temporal fascia about an inch above the zygoma, and is distributed to the integument covering the temple and side of the forehead, communicating with the facial and auriculo-temporal branch of the inferior maxillary nerve. As it pierces the temporal fascia it gives off a slender twig which runs between the two layers of the fascia to the outer angle of the orbit.

FIG. 487.

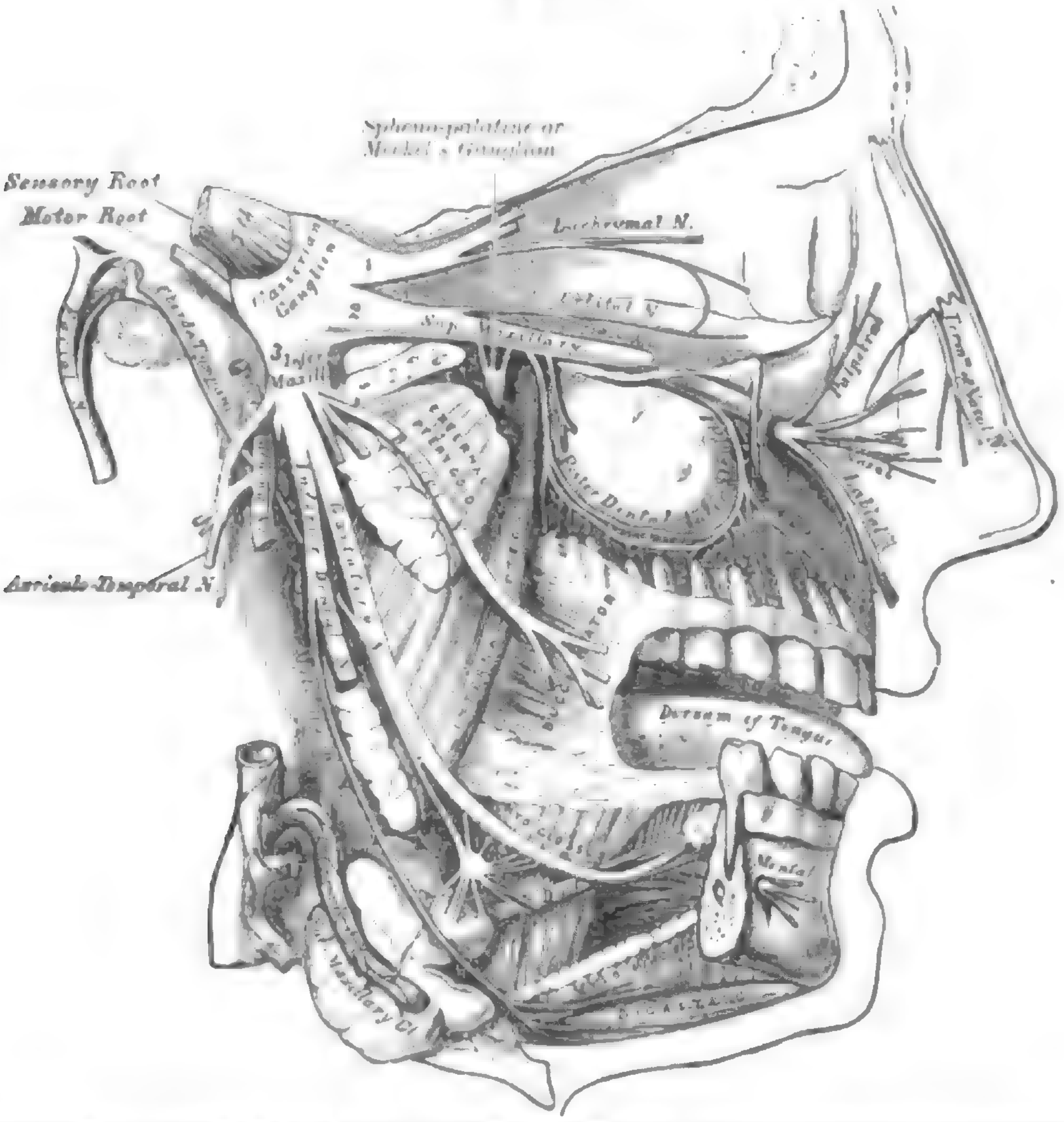
Spheno-palatine or
Meckel's Ganglion
Sensory Root
Motor Root
Lachrymal N.
Casserian Ganglion
1
2
3 Infer. Maxill.
Orbital N.
Sup. Maxillary
Chorda Tympani
Outer Dental
Palpebral
Infra-Nasal N.
Labial
Auriculo-Temporal N.
Dorsum of Tongue
Mental
Maxillary Gl.

Distribution of the Second and Third Divisions of the Fifth Nerve and Submaxillary Ganglion.

The *malar branch* passes along the external inferior angle of the orbit, emerges upon the face through a foramen in the malar bone, and, perforating the Orbicularis palpebrarum muscle, supplies the skin on the prominence of the cheek, and is named *subcutaneous malæ*. It joins with the facial and the palpebral branches of the superior maxillary.

The **spheno-palatine branches**, two in number, descend to the spheno-palatine ganglion.

The **posterior dental branches** arise from the trunk of the nerve just as it is about to enter the infraorbital canal; they are generally two in number, but sometimes arise by a single trunk, and immediately divide and pass downward on the tuberosity of the superior maxillary bone. One of them enters a canal in the substance of the superior maxillary bone, passes from behind forward, and joins opposite the canine fossa with the anterior dental. Numerous filaments are given off from the lower border of this nerve, which form a minute plexus in the outer wall of the superior maxillary bone immediately above the alveoli. From this plexus filaments are distributed to the pulp of the molar teeth, the lining membrane of the antrum, and corresponding portion of the gums. The other branch is distributed to the gums and mucous membrane of the cheek.

The **anterior dental,** of large size, is given off from the superior maxillary nerve just before its exit from the infraorbital foramen; it enters a special canal in the anterior wall of the antrum and communicates with the posterior dental. In its course through its special canal it gives off a branch which is sometimes called the *middle dental*, which supplies the bicuspid teeth. Occasionally this branch is given off directly from the superior maxillary nerve in the back part of the infraorbital canal, and runs in a special canal to the bicuspid teeth. Other filaments of the anterior dental nerve are distributed to the canine and incisor teeth, and others are lost upon the lining membrane covering the fore part of the inferior meatus. In this situation it forms a communication with a nasal branch from Meckel's ganglion [marked by a swelling], called the *ganglion of Bochdalek.*

The **palpebral branches** pass upward beneath the Orbicularis palpebrarum. They supply this muscle, the integument, and conjunctiva of the lower eyelid with sensation, joining at the outer angle of the orbit with the facial nerve and malar branch of the orbital.

The **nasal branches** pass inward; they supply the integument of the side of the nose, and join with the nasal branch of the ophthalmic.

The **labial branches,** the largest and most numerous, descend beneath the Levator labii superioris, and are distributed to the integument and muscles of the upper lip, the mucous membrane of the mouth, and labial glands.

All these branches are joined, immediately beneath the orbit, by filaments from the facial nerve, forming an intricate plexus, the *infraorbital.*

SPHENO-PALATINE OR MECKEL'S GANGLION (Figs. 487, 488).

The **Spheno-palatine Ganglion** (*Meckel's*), the largest of the cranial ganglia, is deeply placed in the spheno-maxillary fossa, close to the spheno-palatine foramen. It is triangular or heart-shaped, of a reddish-gray color, and is situated just below the superior maxillary nerve as it crosses the fossa. The two spheno-palatine branches of this nerve descend to the ganglion; the fibres derived from them for the most part pass in front of the ganglion as they proceed to their destination in the palate and nasal fossa, and are not incorporated in the ganglionic mass; some few of the fibres, however, enter the ganglion, constituting its sensory root. Like the other ganglia of the fifth nerve, it possesses a motor, a sensory, and a sympathetic root. Its motor root is derived from the facial through the Vidian, its sensory root from the fifth, and its sympathetic root from the carotid plexus through the Vidian. Its branches are divisible into four groups: *ascending*, which pass to the orbit; *descending*, to the palate; *internal*, to the nose; and *posterior* branches, to the pharynx.

The *ascending branches* are two or three delicate filaments which enter the orbit by the spheno-maxillary fissure and supply the periosteum. Arnold describes and delineates these branches as ascending to the optic nerve. Böck describes a branch as going to the cavernous sinus to communicate with the sixth nerve, and Tiedemann a communicating branch to the ophthalmic ganglion.

The *descending* or *palatine branches* are distributed to the roof of the mouth, the soft palate, tonsil, and lining membrane of the nose. They are almost a direct continuation of the spheno-palatine branches of the superior maxillary nerve, and are three in number—anterior, middle, and posterior.

The *anterior* or *large palatine nerve* descends through the posterior palatine canal, emerges upon the hard palate at the posterior palatine foramen, and passes forward through a groove in the hard palate nearly as far as the incisor teeth. It supplies the gums, the mucous membrane and glands of the hard palate, and communicates in front with the termination of the naso-palatine nerve. While in the posterior palatine canal it gives off inferior nasal branches, which enter the nose through openings in the palate bone, and ramify over the middle meatus and the middle and inferior spongy bones; and at its exit from the canal a palatine branch is distributed to both surfaces of the soft palate.

The *middle* or *external palatine nerve* descends, in the same canal as the preceding, to the posterior palatine foramen, distributing branches to the uvula, tonsil, and soft palate. It is occasionally wanting.

The *posterior* or *small palatine nerve* descends with a small artery through the small posterior palatine canal, emerging by a separate opening behind the posterior palatine foramen. It supplies the Levator palati and Azygos uvulæ muscles, the soft palate, tonsil, and uvula. The middle and posterior palatine join with the tonsillar branches of the glosso-pharyngeal to form the plexus around the tonsil (circulus tonsillaris). One of these palatine nerves usually supplies the Palato-glossus and Palato-pharyngeus muscles.

FIG. 488.

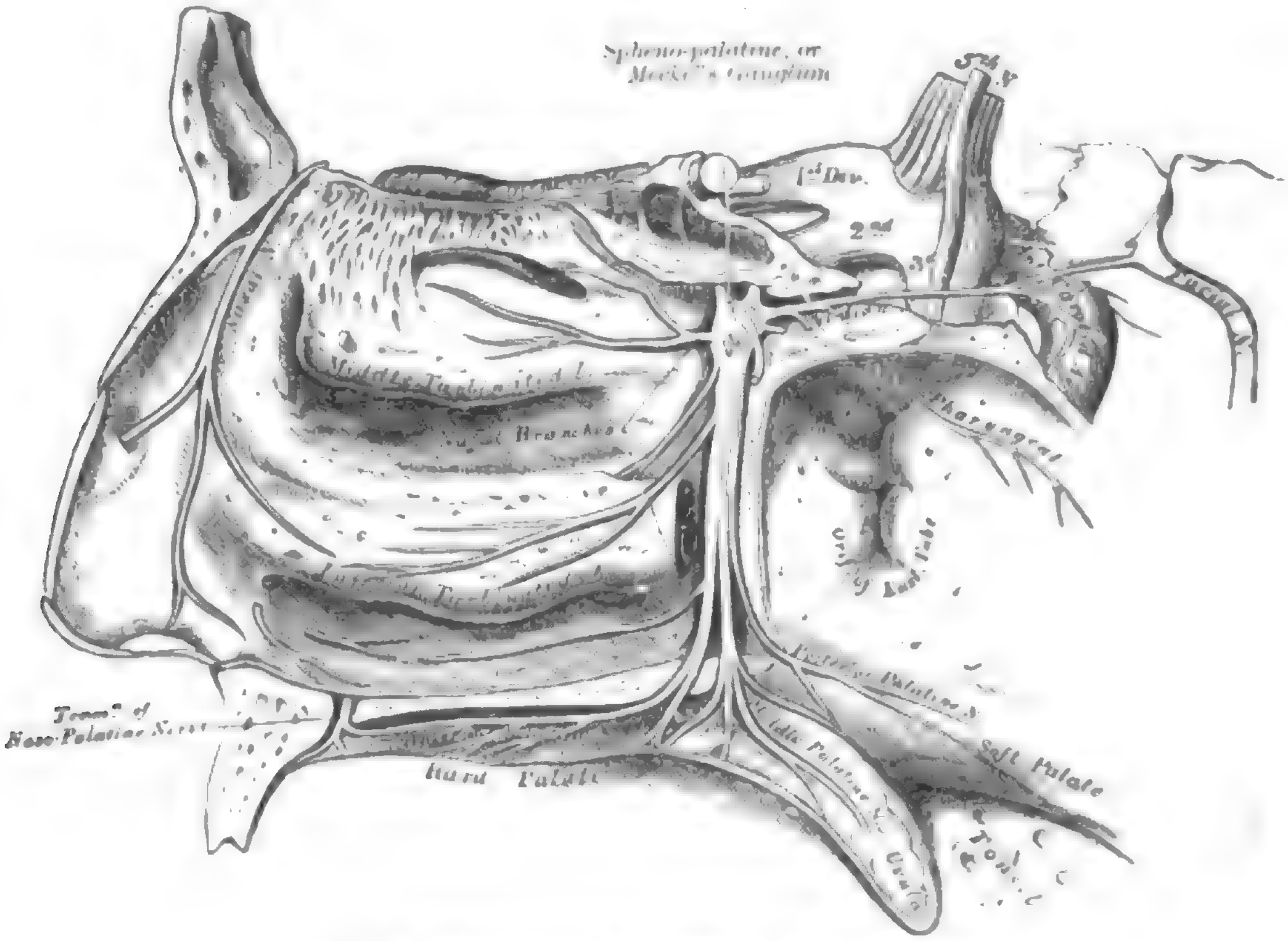
Spheno-palatine, or
Meckel's Ganglion
5th N.
1st Div.
2nd
3rd
Vidian
Carotid
Facial
Nasal
Middle Turbinated
Nasal Branches
Inferior Turbinated
Pharyngeal
Orifice of Eust. Tube
Posterior Palatine N.
Termn. of
Naso-Palatine Nerve
Hard Palate
Middle Palatine N.
Soft Palate
Uvula
Tonsil

The Spheno-palatine Ganglion and its Branches.

The *internal branches* are distributed to the septum and outer wall of the nasal fossæ. They are the superior nasal (anterior) and the naso-palatine.

The *superior nasal branches (anterior)*, four or five in number, enter the back part of the nasal fossa by the spheno-palatine foramen. They supply the mucous membrane covering the superior and middle spongy bones and that lining the posterior ethmoidal cells, a few being prolonged to the upper and back part of the septum. One of these branches (the posterior) is continued on to the wall of the antrum, and there forms a communication with the anterior dental nerve. At the point of communication a swelling exists, denominated "the ganglion of Bochdalek," the nature of which seems, however, uncertain.

The *naso-palatine nerve* (*Cotunnius*) enters the nasal fossa with the other nasal nerves, and passes inward across the roof of the nose, below the orifice of the sphenoidal sinus, to reach the septum; it then runs obliquely downward and forward along the lower part of the septum to the anterior palatine foramen, lying between the periosteum and mucous membrane. It descends to the roof of the mouth through the anterior palatine canal. The two nerves are here contained in separate and distinct canals situated in the intermaxillary suture and termed the foramina of Scarpa, the left nerve being usually anterior to the right one. In the mouth they become united, supply the mucous membrane behind the incisor teeth, and join with the anterior palatine nerve. The naso-palatine nerve occasionally furnishes a few small filaments to the mucous membrane of the septum.

The *posterior branches* are the Vidian and the pharyngeal (pterygo-palatine).

The *Vidian nerve*, if traced *from* Meckel's ganglion, may be said to arise from the back part of the ganglion, and then to pass through the Vidian canal, entering the cartilage filling in the foramen lacerum [medium] basis cranii and dividing into two branches, the large superficial petrosal and the deep petrosal. In its course along the Vidian canal it distributes a few filaments to the lining membrane at the back part of the roof of the nose and septum and that covering the end of the Eustachian tube. These are upper posterior nasal branches.

The *large superficial petrosal branch* (*nervus petrosus superficialis major*) enters the cranium through the foramen lacerum [medium] basis cranii, having pierced the cartilaginous substance which fills in this aperture. It runs beneath the Gasserian ganglion and dura mater, contained in a groove on the anterior surface of the petrous portion of the temporal bone, enters the hiatus Fallopii, where it receives a communicating branch from Jacobson's nerve, and, being continued through it into the aquæductus Fallopii, joins the gangliform enlargement on the facial nerve. Properly speaking, this nerve passes from the facial to the spheno-palatine ganglion, forming its motor root.

The *deep petrosal branch* (*nervus petrosus profundus*) is shorter but larger than the other, of a reddish-gray color, and soft in texture. It crosses the foramen lacerum surrounded by the cartilaginous substance which fills in that aperture, and enters the carotid canal on the outer side of the carotid artery to join the carotid plexus.

This description of the Vidian nerve as a branch from the ganglion is the more convenient anatomically inasmuch as the nerve is generally dissected *from* the ganglion as a single trunk *dividing* into two branches. But it is more correct, physiologically, to describe the Vidian as being formed by the *union* of the two branches (great petrosal and deep petrosal) from the facial and the sympathetic, and as running *into* the ganglion. The filaments which are described above as given off from the Vidian nerve would then be regarded as branches from the ganglion which are merely enclosed in the same sheath as the Vidian.

The *pharyngeal nerve* (*pterygo-palatine*) is a small branch arising from the back part of the ganglion, occasionally together with the Vidian nerve. It passes through the pterygo-palatine canal with the pterygo-palatine artery, and is distributed to the mucous membrane of the upper part of the pharynx behind the Eustachian tube.

INFERIOR MAXILLARY NERVE (Fig. 487, p. 724).

The **Inferior Maxillary Nerve** distributes branches to the teeth and gums of the lower jaw, the integument of the temple and external ear, the lower part of the face and lower lip, and the muscles of mastication: it also supplies the tongue with a large branch which may possibly serve as a nerve of the special sense of taste. It is the largest of the three divisions of the fifth, and consists of two portions—the large or sensory root proceeding from the inferior angle of the Gasserian ganglion, and the small or motor root, which passes beneath the ganglion and unites with the sensory division just after its exit through the foramen ovale. Immediately beneath the base of the skull this nerve divides into two trunks, anterior and posterior.

The *anterior* and smaller division, which receives nearly the whole of the motor root, divides into branches which supply the muscles of mastication. They are the masseteric, deep temporal, buccal, and two pterygoid.

The **masseteric branch** passes outward, above the External pterygoid muscle, in front of the temporo-maxillary articulation, and crosses the sigmoid notch with the masseteric artery to the Masseter muscle, in which it ramifies nearly as far as its anterior border. It occasionally gives a branch to the Temporal muscle and a filament to the articulation of the jaw.

The **deep temporal branches,** two in number, anterior and posterior, supply the deep surface of the Temporal muscle. The *posterior branch,* of small size, is placed at the back of the temporal fossa. It is sometimes joined with the masseteric branch. The *anterior branch* is reflected upward, at the pterygoid ridge of the sphenoid, to the front of the temporal fossa. It is generally given off from the buccal nerve. Sometimes there are three deep temporal branches.

The **buccal branch** pierces the External pterygoid, and passes downward beneath the inner surface of the coronoid process of the lower jaw or through the fibres of the Temporal muscle to reach the surface of the Buccinator, upon which it divides into a superior and an inferior branch. It gives a branch to the External pterygoid during its passage through the muscle, and a few ascending filaments to the Temporal muscle, one of which occasionally joins with the anterior branch of the deep temporal nerve. The *upper branch* supplies the integument and upper part of the Buccinator muscle, joining with the facial nerve round the facial vein. The *lower branch* passes forward to the angle of the mouth; it supplies the integument and Buccinator muscle, as well as the mucous membrane lining the inner surface of that muscle, and joins the facial nerve.[1]

The **pterygoid branches** are two in number, one for each pterygoid muscle. The *branch to the Internal pterygoid* is long and slender, and passes inward to enter the deep surface of the muscle. This nerve is intimately connected at its origin with the otic ganglion. The *branch to the External pterygoid* is most frequently derived from the buccal, but it may be given off separately from the anterior trunk of the nerve.

The *posterior* and larger division of the inferior maxillary nerve is for the most part sensory, but receives a few filaments from the motor root. It divides into three branches—auriculo-temporal, gustatory, and inferior dental.

The **Auriculo-temporal Nerve** generally arises by two roots, between which the middle meningeal artery passes. It runs backward beneath the External pterygoid muscle to the inner side of the neck of the lower jaw. It then turns upward with the temporal artery, between the external ear and condyle of the jaw, under cover of the parotid gland, and, escaping from beneath this structure, ascends over the zygoma and divides into two temporal branches. The *posterior temporal,* the smaller of the two, is distributed to the upper part of the pinna and the neighboring tissues. The *anterior temporal* accompanies the temporal artery to the vertex of the skull, and supplies the integument of the temporal region, communicating with the facial nerve and orbital branch of the superior maxillary.

The auriculo-temporal nerve has *branches of communication* with the facial and otic ganglion. Those joining the facial nerve, usually two in number, pass forward from behind the neck of the condyle of the jaw to join this nerve at the posterior border of the Masseter muscle. They form one of the principal branches of communication between the facial and the fifth nerve. The filaments of communication with the otic ganglion are derived from the commencement of the auriculo-temporal nerve.

It gives off *auricular branches,* two in number, inferior and superior. The *inferior auricular* arises behind the articulation of the jaw, and is distributed to the ear below the external meatus; other filaments twine round the internal maxillary artery and communicate with the sympathetic. The *superior auricular* arises in front of the external ear and supplies the integument covering the tragus and pinna.

Branches to the meatus auditorius, two in number, arise from the point of communication between the auriculo-temporal and facial nerves, and are distributed to the meatus.

---

[1] There seems to be no reason to doubt that the branch supplying the Buccinator muscle is entirely a nerve of ordinary sensation, and that the true motor supply of this muscle is from the facial.

A *branch to the temporo-maxillary articulation* is usually derived from the auriculo-temporal nerve.

Parotid branches, which supply the parotid gland, are also given off from this nerve.

The **Lingual** or **Gustatory**[1] **Nerve** supplies the papillæ and mucous membrane of the tongue. It is deeply placed throughout the whole of its course. It lies at first beneath the External pterygoid muscle, together with the inferior dental nerve, being placed to the inner side of the latter nerve, and is occasionally joined to it by a branch which crosses the internal maxillary artery. The chorda tympani also joins it at an acute angle in this situation. The nerve then passes between the Internal pterygoid muscle and the inner side of the ramus of the jaw, and crosses obliquely to the side of the tongue over the Superior constrictor muscle of the pharynx, and between the Stylo-glossus muscle and deep part of the submaxillary gland; the nerve lastly runs across Wharton's duct and along the side of the tongue to its apex, lying immediately beneath the mucous membrane. [As it passes to the side of the base of the tongue it is accessible for operation.]

Its *branches of communication* are with the facial through the chorda tympani, the inferior dental and hypoglossal nerves, and the submaxillary ganglion. The branches to the submaxillary ganglion are two or three in number; those connected with the hypoglossal nerve form a plexus at the anterior margin of the Hyo-glossus muscle.

Its *branches of distribution* are few in number. They supply the mucous membrane of the mouth, the gums, the sublingual gland, the filiform and fungiform papillæ, and mucous membrane of the tongue, the terminal filaments anastomosing at the tip of the tongue with the hypoglossal nerve.

The **inferior dental** is the largest of the three branches of the inferior maxillary nerve. It passes downward with the inferior dental artery, at first beneath the External pterygoid muscle, and then between the internal lateral ligament and the ramus of the jaw to the dental foramen. It then passes forward in the dental canal of the inferior maxillary bone, lying beneath the teeth, as far as the mental foramen, where it divides into two terminal branches, incisor and mental. [In this canal the nerve can be reached for operation by removal of the external layer of the lower jaw-bone.] The *incisor branch* is continued onward within the bone to the middle line, and supplies the canine and incisor teeth. The *mental branch* emerges from the bone at the mental foramen, and divides beneath the Depressor anguli oris into two or three branches: one descends to supply the skin of the chin, and another (sometimes two) ascends to supply the skin and mucous membrane of the lower lip. These branches communicate freely with the facial nerve.

The branches of the inferior dental are the mylo-hyoid and dental.

The *mylo-hyoid* is derived from the inferior dental just as that nerve is about to enter the dental foramen. It descends in a groove on the inner surface of the ramus of the jaw, in which it is retained by a process of fibrous membrane. It supplies the cutaneous surface of the Mylo-hyoid muscle and the anterior belly of the Digastric, occasionally sending one or two filaments to the submaxillary gland.

The *dental branches* supply the molar and bicuspid teeth. They correspond in number to the fangs of those teeth, each nerve entering the orifice at the point of the fang and supplying the pulp of the tooth.

Two small ganglia are connected with the inferior maxillary nerve—the otic with the trunk of the nerve, and the submaxillary with its lingual branch, the gustatory.

OTIC GANGLION (Fig. 489).

The **Otic Ganglion** (Arnold's) is a small, oval-shaped, flattened ganglion of a reddish-gray color situated immediately below the foramen ovale, on the inner sur-

---

[[1] It is much better to call this the Lingual Nerve. It is certainly distributed to the tongue, but its function as to taste is dubious.]

face of the inferior maxillary nerve and round the origin of the internal pterygoid nerve. It is in relation *externally* with the trunk of the inferior maxillary nerve at the point where the motor root joins the sensory portion; *internally* with the cartilaginous part of the Eustachian tube and the origin of the Tensor palati muscle; *behind* it is the middle meningeal artery.

Fig. 489.

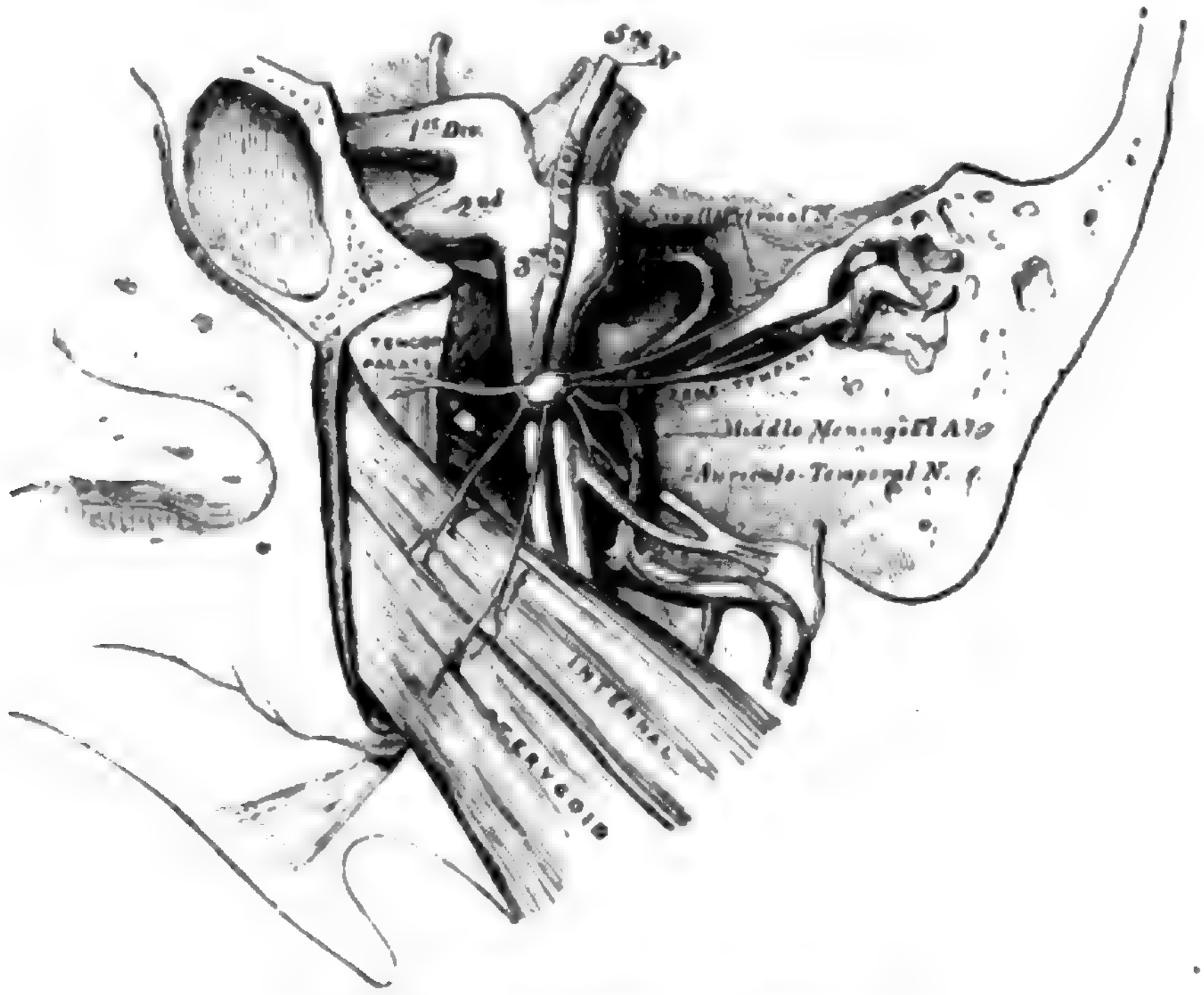

The Otic Ganglion and its Branches.

Branches of Communication.—This ganglion is connected with the inferior maxillary nerve and its internal pterygoid branch by two or three short, delicate filaments, and also with the auriculo-temporal nerve. From the former it obtains its motor, from the latter its sensory root,[1] its communication with the sympathetic being effected by a filament from the plexus surrounding the middle meningeal artery. This ganglion also communicates with the glosso-pharyngeal and facial nerves through the small petrosal nerve continued from the tympanic plexus (p. 738).

Its branches of distribution are a filament to the Tensor tympani, and one to the Tensor palati. The former passes backward, on the outer side of the Eustachian tube; the latter arises from the ganglion, near the origin of the internal pterygoid nerve, and passes forward. It also gives off a small communicating branch to the chorda tympani.

SUBMAXILLARY GANGLION (Fig. 487, p. 724).

The **Submaxillary Ganglion** is of small size, fusiform in shape, and situated above the deep portion of the submaxillary gland near the posterior border of the Mylo-hyoid muscle, being connected by filaments with the lower border of the gustatory nerve.

Branches of Communication.—This ganglion is connected with the gustatory nerve by a few filaments which join it separately at its fore and back part. It also receives a branch from the chorda tympani, by which it communicates with the facial, and communicates with the sympathetic by filaments from the sympathetic plexus around the facial artery.

---

[1] Experiments on animals seem to prove that this is not the sensory root of the ganglion, but rather a branch of distribution passing from the otic ganglion to the auriculo-temporal nerve, and through it to the parotid gland. It probably receives its sensory root from the glosso-pharyngeal nerve. (See p. 738.)

Branches of Distribution.—These are five or six in number; they arise from the lower part of the ganglion and supply the mucous membrane of the mouth and Wharton's duct, some being lost in the submaxillary gland. According to Meckel, a branch from this ganglion occasionally descends in front of the Hyo-glossus muscle, and, after joining with one from the Hypoglossal, passes to the Genio-hyo-glossus muscle.

[Fig. 490 shows the distribution of the sensory branches of the fifth nerve to the skin of the head and neck.

[Fig. 490.

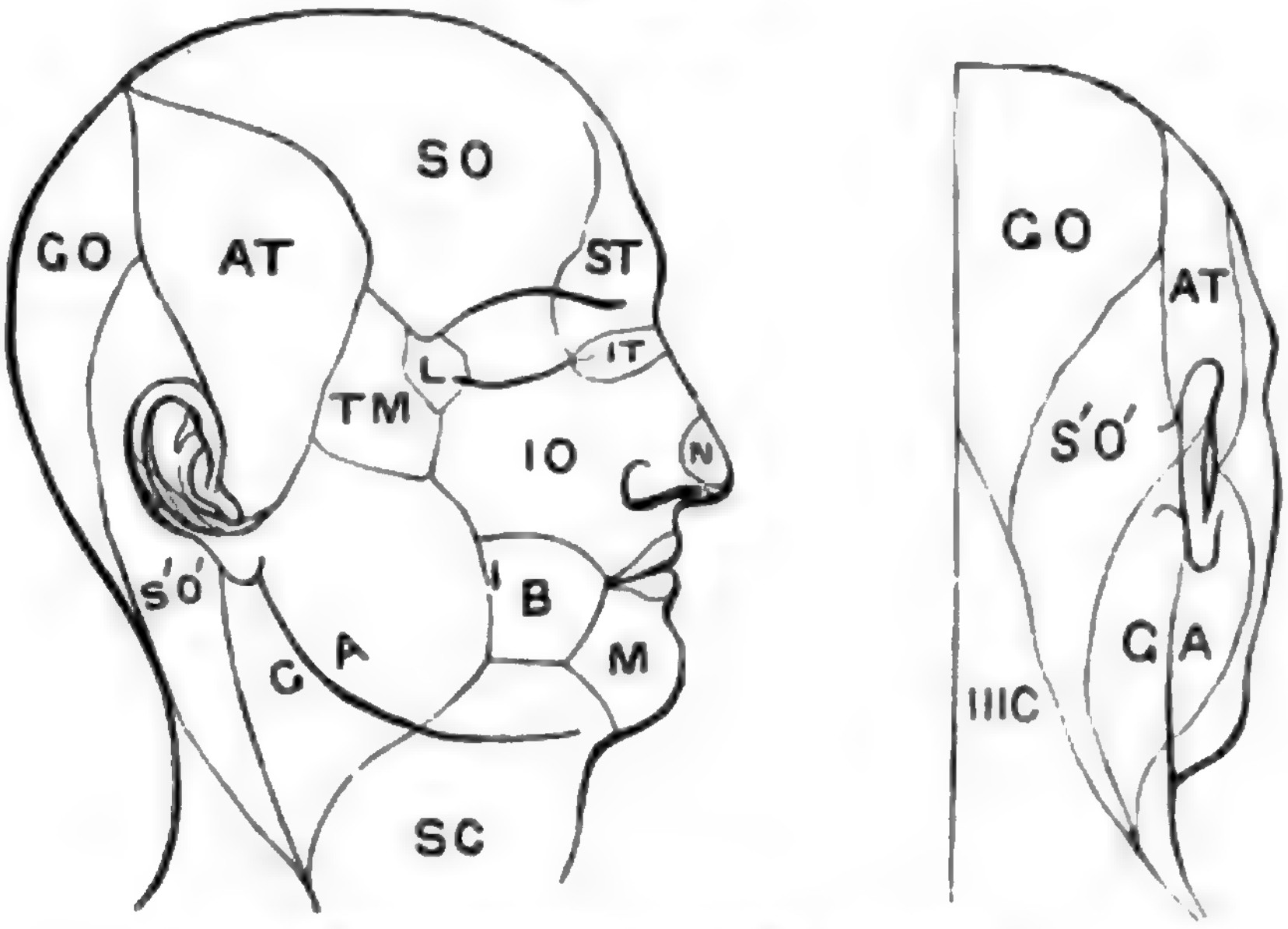

Sensory Nerves of the Head and Face.

First division of the fifth:
SO, Supraorbital.
ST, Supratrochlear.
IT, Infratrochlear.
L, Lachrymal.
N, Nasal.
Second division of the fifth:
IO, Infraorbital.
TM, Temporo-malar.

Third division of the fifth:
B, Buccal.
M, Mental.
AT, Auriculo-temporal.
Branches of the cervical plexus:
GO, Great occipital.
S'O', Small occipital.
GA, Great auricular.
SC, Superficial cervical.
IIIC, Third cervical (Flower).]

Sixth Nerve (Fig. 485, p. 720).

The **sixth or Abducens Nerve** supplies the External rectus muscle. Its *apparent origin* is by several filaments from the constricted part of the corpus pyramidale close to the pons, or from the lower border of the pons itself in the groove between this body and the medulla. The *deep origin* of this nerve is from the gray substance of the fasciculus teres, on the floor of the fourth ventricle, from a nucleus common to it and a part of the facial nerve.

The nerve pierces the dura mater on the basilar surface of the sphenoid bone, runs through a notch immediately below the posterior clinoid process, and enters the cavernous sinus. It passes forward through the sinus, lying on the outer side of the internal carotid artery, where it is joined by several filaments from the carotid and cavernous plexus, by one from Meckel's ganglion (Böck), and another from the ophthalmic nerve. It enters the orbit through the sphenoidal fissure, and lies above the ophthalmic vein, from which it is separated by a lamina of dura mater. It then passes between the two heads of the External rectus, and is distributed to that muscle on its ocular surface.

The above-mentioned nerve, as well as the third, fourth, and the ophthalmic division of the fifth, as they pass to the orbit bear a certain relation to each other in the cavernous sinus, at the sphenoidal fissure, and in the cavity of the orbit, which will be now described.

In the *cavernous sinus* (Fig. 413, p. 621) the third, fourth, and ophthalmic division of the fifth are placed in the dura mater of the outer wall of the sinus in their numerical order, both from above downward and from within outward. The sixth nerve lies at the outer side of the internal carotid artery. As these nerves pass forward to the sphenoidal fissure the third and fifth nerves become divided into branches, and the sixth approaches the rest, so that their relative position becomes considerably changed.

In the *sphenoidal fissure* (Fig. 491) the fourth and the frontal and lachrymal divisions of the ophthalmic lie upon the same plane, the former being most internal, the latter external, and they enter the cavity of the orbit above the muscles. The remaining nerves enter the orbit between the two heads of the External rectus. The superior division of the third is the highest of these; beneath this lies the nasal branch of the fifth; then the inferior division of the third; and the sixth lowest of all.

Fig. 491.

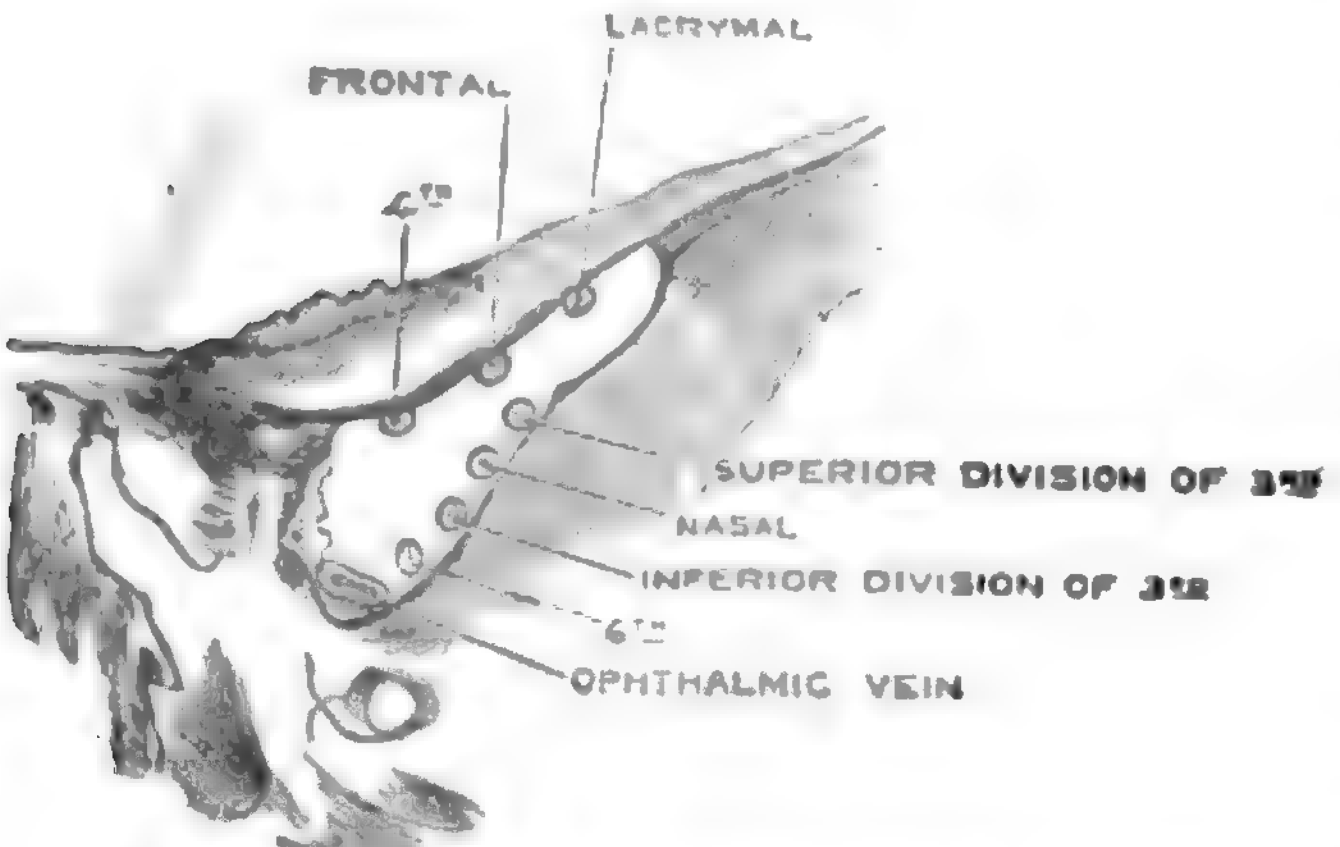

Relations of Structures passing through the Sphenoidal Fissure.

In the *orbit* the fourth and the frontal and lachrymal divisions of the ophthalmic lie on the same plane immediately beneath the periosteum, the fourth nerve being internal and resting on the Superior oblique, the frontal resting on the Levator palpebræ, and the lachrymal on the External rectus. Next in order comes the superior division of the third nerve, lying immediately beneath the Superior rectus, and then the nasal division of the fifth, crossing the optic nerve from the outer to the inner side of the orbit. Beneath these is found the optic nerve, surrounded in front by the ciliary nerves and having the lenticular ganglion on its outer side between it and the External rectus. Below the optic is the inferior division of the third and the sixth, which lies on the outer side of the orbit.

Seventh Nerve (Figs. 492, 493).

The **seventh** or **Facial Nerve** (*portio dura* of the seventh pair of Willis) [so called from its greater hardness as compared with the auditory nerve, which is the *portio mollis*, or "soft portion"] is the motor nerve of all the muscles of expression in the face and of the Platysma and Buccinator. It also supplies two of the muscles of the external ear, the posterior belly of the Digastric and the Stylo-hyoid. Through the chorda tympani it supplies the Lingualis; by its tympanic branch, the Stapedius; through the otic ganglion, the Tensor tympani; and through the connection of its trunk with the Vidian nerve by the petrosal nerve it probably supplies the Levator palati and Azygos uvulæ. It arises from the lateral tract of the medulla oblongata in the groove between the olivary and restiform bodies. Its *deep origin* is twofold: 1, from the gray substance of the fasciculus teres on the floor of the fourth ventricle, in common with the sixth nerve; 2, from the nucleus of the motor root of the trigeminus. Between these two origins it forms a loop along the floor of the ventricle. This nerve is situated a little nearer

Fig. 492.

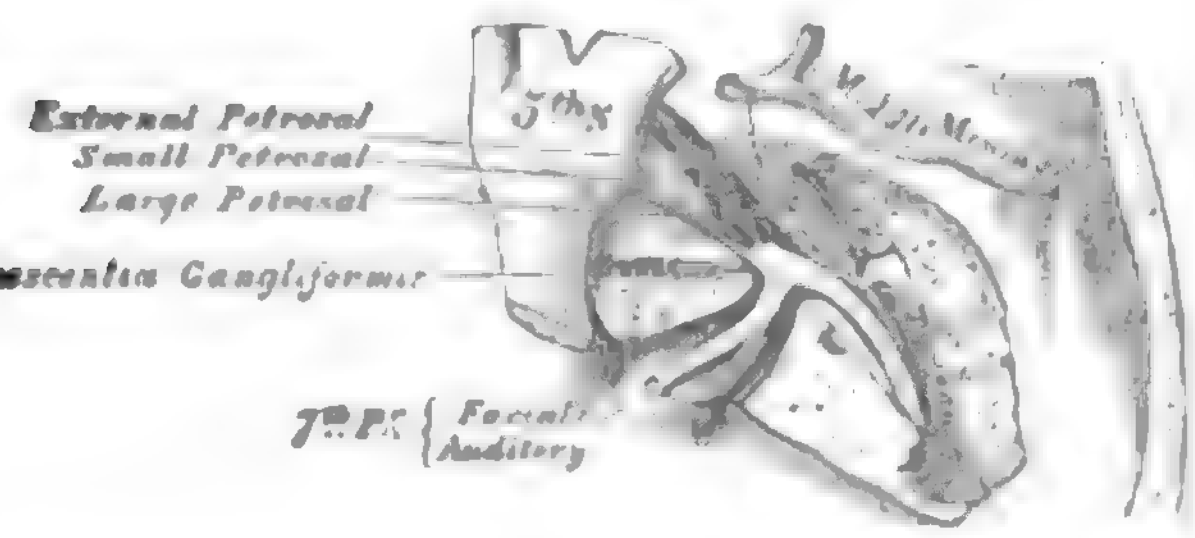

The Course and Connections of the Facial Nerve in the Temporal Bone.

to the middle line than the portio mollis, close to the lower border of the pons Varolii, from which some of its fibres are derived.

Connected with this nerve, and lying between it and the portio mollis, is a small fasciculus (*portio inter duram et mollem* of Wrisberg, or *pars intermedia*). This accessory portion arises from the lateral column of the cord.

The nerve passes forward and outward upon the crus cerebelli, and enters the internal auditory meatus with the auditory nerve. Within the meatus the facial nerve lies first to the inner side of the auditory, and then in a groove upon that nerve, and is connected to it by one or two filaments.

At the bottom of the meatus it enters the aquæductus Fallopii, and follows the serpentine course of that canal through the petrous portion of the temporal bone, from its commencement at the internal meatus to its termination at the stylo-mastoid foramen. [Its passage through this rigid, unyielding bony canal may explain its frequent paralysis from neuritis.] It is at first directed outward toward the hiatus Fallopii, where it forms a reddish gangliform swelling (*intumescentia gangliformis* or *geniculate ganglion*), and is joined by several nerves; then, bending suddenly backward, it runs in the internal wall of the tympanum above the fenestra ovalis, and at the back of that cavity passes vertically downward to the stylo-mastoid foramen.

On emerging from this aperture it runs forward in the substance of the parotid gland, crosses the external carotid artery, and divides behind the ramus of the lower jaw into two primary branches, *temporo-facial* and *cervico-facial*, from which numerous offsets are distributed over the side of the head, face, and upper part of the neck, supplying the superficial muscles in these regions. As the primary branches and their offsets diverge from each other, they present somewhat the appearance of a bird's claw; hence the name of *pes anserinus* is given to the division of the facial nerve in and near the parotid gland. [Just after its emergence from the stylo-mastoid foramen it is accessible for operation.[1]]

The communications of the facial nerve may be thus arranged:

In the internal auditory meatus .	With the auditory nerve.
In the aquæductus Fallopii . .	With Meckel's ganglion by the large petrosal nerve. With the otic ganglion by the small petrosal nerve. With the sympathetic on the middle meningeal by the external petrosal nerve.
At its exit from the stylo-mastoid foramen	With the glosso-pharyngeal. " pneumogastric. " carotid plexus. " auricularis magnus. " auriculo-temporal.
On the face	With the three divisions of the fifth.

In the internal auditory meatus some minute filaments pass between the facial and auditory nerves.

Opposite the hiatus Fallopii the gangliform enlargement on the facial nerve communicates, by means of the large petrosal nerve, with Meckel's ganglion, forming its motor root; by a filament from the small petrosal with the otic ganglion; and by the external petrosal with the sympathetic filaments accompanying the middle meningeal artery (Bidder). From the gangliform enlargement, according to Arnold, a twig is sent back to the auditory nerve.

At its exit from the stylo-mastoid foramen it sends a twig to the glosso-pharyngeal, another to the pneumogastric nerve, and communicates with the carotid plexus of the sympathetic, with the great auricular branch of the cervical plexus, with the auriculo-temporal branch of the inferior maxillary nerve in the parotid gland, and on the face with the terminal branches of the three divisions of the fifth.

[[1] See a paper by the American Editor in the *Trans. Amer. Surg. Assoc.*, 1886.]

FIG. 493.

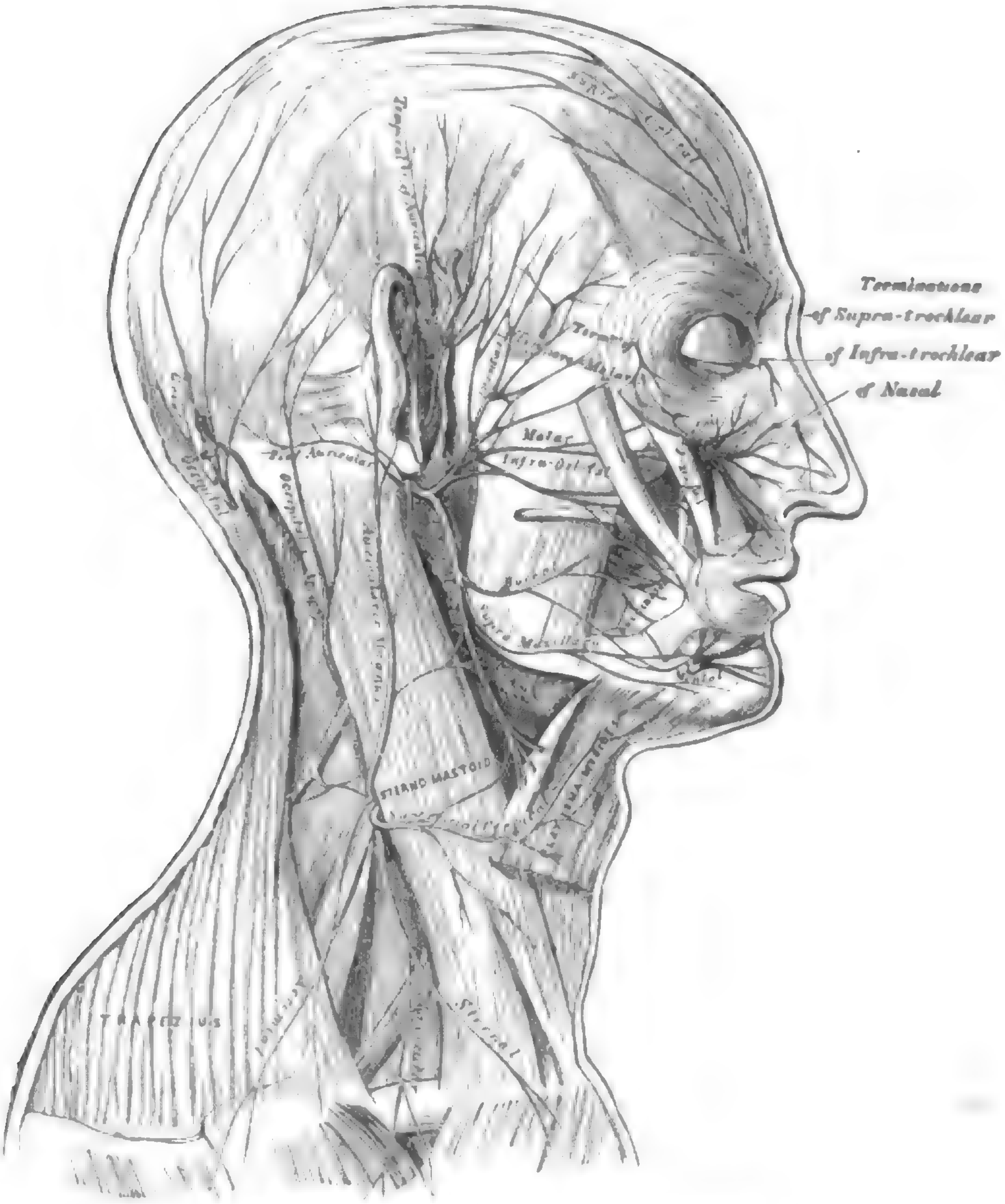
Terminations
of Supra-trochlear
of Infra-trochlear
of Nasal
Malar
Infra-Orbital
Post Auricular
Occipital
Supra Maxillary
Buccal
STERNO MASTOID
TRAPEZIUS
Sternal

The Nerves of the Scalp, Face, and Side of the Neck.

BRANCHES OF DISTRIBUTION.

Within the aquæductus Fallopii	Tympanic. Chorda tympani.	
At its exit from the stylo-mastoid foramen	Posterior auricular. Digastric. Stylo-hyoid.	
On the face	Temporo-facial.	Temporal. Malar. Infraorbital.
	Cervico-facial.	Buccal. Supramaxillary. Inframaxillary.

The **Tympanic branch** arises from the nerve opposite the pyramid; it is a small filament which supplies the Stapedius muscle.

The **Chorda tympani** is given off from the facial as it passes vertically downward at the back of the tympanum, about a quarter of an inch before its exit from the stylo-mastoid foramen. It passes from below upward in a distinct canal parallel with the aquæductus Fallopii, and enters the cavity of the tympanum through an aperture (*iter chordæ posterius*) on its posterior wall between the opening of the mastoid cells and the attachment of the membrana tympani, and becomes invested with mucous membrane. It passes forward through the cavity of the tympanum, between the handle of the malleus and vertical ramus of the incus, to its anterior inferior angle, and emerges from that cavity through a foramen at the inner end of the Glaserian fissure which is called the *iter chordæ anterius*, or *canal of Huguier*. It then descends between the two Pterygoid muscles, meets the gustatory nerve at an acute angle, and accompanies it to the submaxillary gland; part of it then joins the submaxillary ganglion; the rest is continued onward into the proper muscular fibres of the tongue—the Lingualis muscle. Before joining the gustatory nerve it receives a small communicating branch from the otic ganglion.[1]

The **Posterior Auricular Nerve** arises close to the stylo-mastoid foramen and passes upward in front of the mastoid process, where it is joined by a filament from the auricular branch of the pneumogastric, and communicates with the deep branch of the auricularis magnus and with the small occipital; as it ascends between the meatus and mastoid process it divides into two branches. The *auricular branch* supplies the Retrahens aurem. The *occipital branch*, the larger, passes backward along the superior curved line of the occipital bone and supplies the occipital portion of the Occipito-frontalis.

The **Stylo-hyoid** is a long slender branch which passes inward, entering the Stylo-hyoid muscle about its middle; it communicates with the sympathetic filaments on the external carotid artery.

The **Digastric branch** usually arises by a common trunk with the preceding; it divides into several filaments, which supply the posterior belly of the Digastric; one of these perforates that muscle to join the glosso-pharyngeal nerve.

The **Temporo-facial**, the larger of the two terminal branches, passes upward and forward through the parotid gland, crosses the neck of the condyle of the jaw, being connected in this situation with the auriculo-temporal branch of the inferior maxillary nerve, and divides into branches which are distributed over the temple and upper part of the face; these are divided into three sets, temporal, malar, and infraorbital.

The *temporal branches* cross the zygoma to the temporal region, supplying the Attrahens aurem muscle, and join with the temporal branch of the superior maxillary and with the auriculo-temporal branch of the inferior maxillary. The more anterior branches supply the frontal portion of the Occipito-frontalis and the Orbicularis palpebrarum muscle, joining with the supraorbital branch of the ophthalmic.

The *malar branches* pass across the malar bone to the outer angle of the orbit, where they supply the Orbicularis and Corrugator supercilii muscles, joining with filaments from the lachrymal and supraorbital nerves; others supply the lower eyelid, joining with filaments of the malar branches (*subcutaneous malæ*) of the superior maxillary nerve.

The *infraorbital*, of larger size than the rest, pass horizontally forward to be distributed between the lower margin of the orbit and the mouth. The *superficial branches* run beneath the skin and above the superficial muscles of the face which they supply: some supply the lower eyelid and Pyramidalis nasi, joining at the inner angle of the orbit with the infratrochlear and nasal branches of the ophthalmic. The *deep branches* pass beneath the Levator labii superioris, supplying it and the Levator anguli oris, and form a plexus (*infraorbital*) by joining with the infraorbital branch of the superior maxillary nerve and the buccal branches of the cervico-facial.

[[1] Sapolini believes that the chorda tympani is an independent thirteenth cranial nerve, originating from the intermediate nerve of Wrisberg. He has traced it from the fourth ventricle to the geniculate ganglion of the seventh nerve, and from the chorda tympani backward, to the same ganglion, and believes these two portions to be one and the same nerve, running with the seventh, but anatomically distinct from it. He believes it to be the special nerve of speech.]

The **Cervico-facial** division of the facial nerve passes obliquely downward and forward through the parotid gland, where it is joined by branches from the great auricular nerve; opposite the angle of the lower jaw it divides into branches which are distributed on the lower half of the face and upper part of the neck. These may be divided into three sets—buccal, supramaxillary, and inframaxillary.

The *buccal branches* cross the Masseter muscle. They supply the Buccinator and Orbicularis oris, and join with the infraorbital branches of the temporo-facial division of the nerve, and with filaments of the buccal branch of the inferior maxillar nerve.

The *supramaxillary branches* pass forward beneath the Platysma and Depressor anguli oris, supplying the muscles of the lip and chin and communicating with the mental branch of the inferior dental nerve.

The *inframaxillary branches* run forward beneath the Platysma, and form a series of arches across the side of the neck over the suprahyoid region. One of these branches descends vertically to join with the superficial cervical nerve from the cervical plexus; others supply the Platysma.

EIGHTH NERVE.

The **eighth** or **Auditory Nerve** (*portio mollis* of the seventh pair of *Willis*) is the special nerve of the sense of hearing, being distributed exclusively to the internal ear.

The auditory nerve appears at the base of the brain in the groove between the olivary and restiform bodies at the lower border of the pons. It lies external to the facial nerve. It has three origins: 1, from the superior vermiform process of the cerebellum; 2 and 3, from the inner and outer auditory nuclei formed chiefly by the gray substance of the posterior pyramid and restiform body. The nerve winds round the restiform body, from which it receives fibres, and passes forward across the posterior border of the crus cerebelli in company with the facial nerve, from which it is partially separated by a small artery. It then enters the meatus auditorius internus in company with the facial nerve, and at the bottom of the meatus divides into two branches, cochlear and vestibular, which are distributed, the former to the cochlea, the latter to the vestibule and semicircular canals. The auditory nerve is very soft in texture (hence the name *portio mollis*), destitute of neurilemma, and within the meatus receives one or two filaments from the facial. The distribution of the auditory nerve in the internal ear will be found described along with the anatomy of that organ in a subsequent page.

FIG. 494.

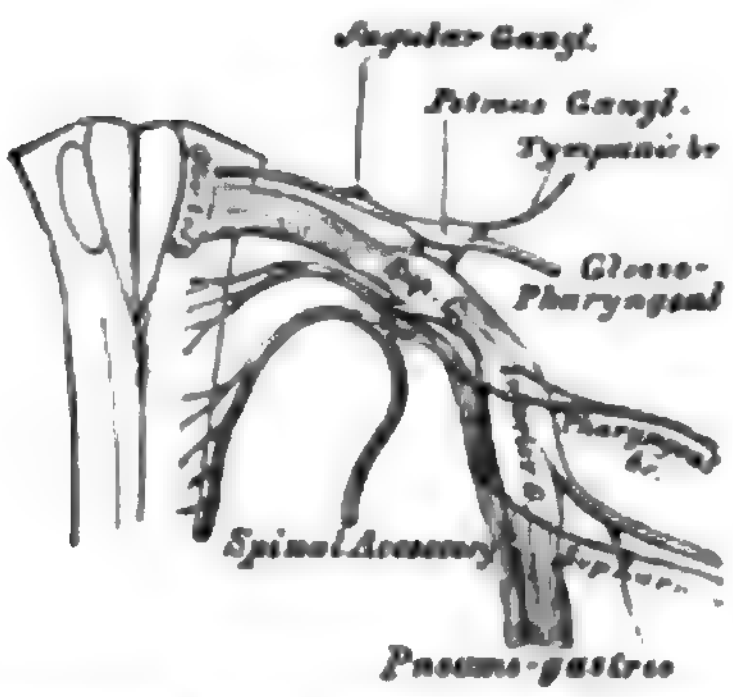

Nerves of the Eighth Pair, their origin, ganglia, and communications.

NINTH PAIR.

The **ninth** or **Glosso-pharyngeal Nerve** (Figs. 494, 495), is distributed, as its name implies, to the tongue and pharynx, being the nerve of sensation to the mucous membrane of the pharynx, fauces, and tonsil, and a special nerve of taste in all the parts of the tongue to which it is distributed. It is the smallest of the three divisions of the eighth pair of Willis, and arises by three or four filaments closely connected together from the upper part of the medulla oblongata in the groove between the restiform and the olivary body.

Its *deep origin* may be traced through the fasciculi of the lateral tract to a nucleus of gray matter at the lower part of the floor of the fourth ventricle, above the nucleus of the vagus and below that of the auditory nerve. From its superficial origin it passes outward across the flocculus, and leaves the skull at the central part of the jugular foramen, in a separate sheath of the dura mater and arachnoid, in front of the pneumogastric and spinal accessory nerves (Fig. 415, p. 622). In its passage through the jugular foramen it grooves the lower border of the petrous portion of the temporal bone, and at its exit from the skull passes forward between the jugular vein and internal carotid artery, and descends in front of the latter vessel and beneath the styloid process and the muscles connected with it to the lower border of the Stylo-pharyngeus. The nerve now curves inward, forming an arch on the side of the neck, and lying upon the Stylo-pharyngeus and Middle constrictor of the pharynx, above the superior laryngeal nerve. It then passes beneath the Hyo-glossus, and is finally distributed to the mucous membrane of the fauces and base of the tongue, the mucous glands of the mouth and tonsil.

FIG. 495.

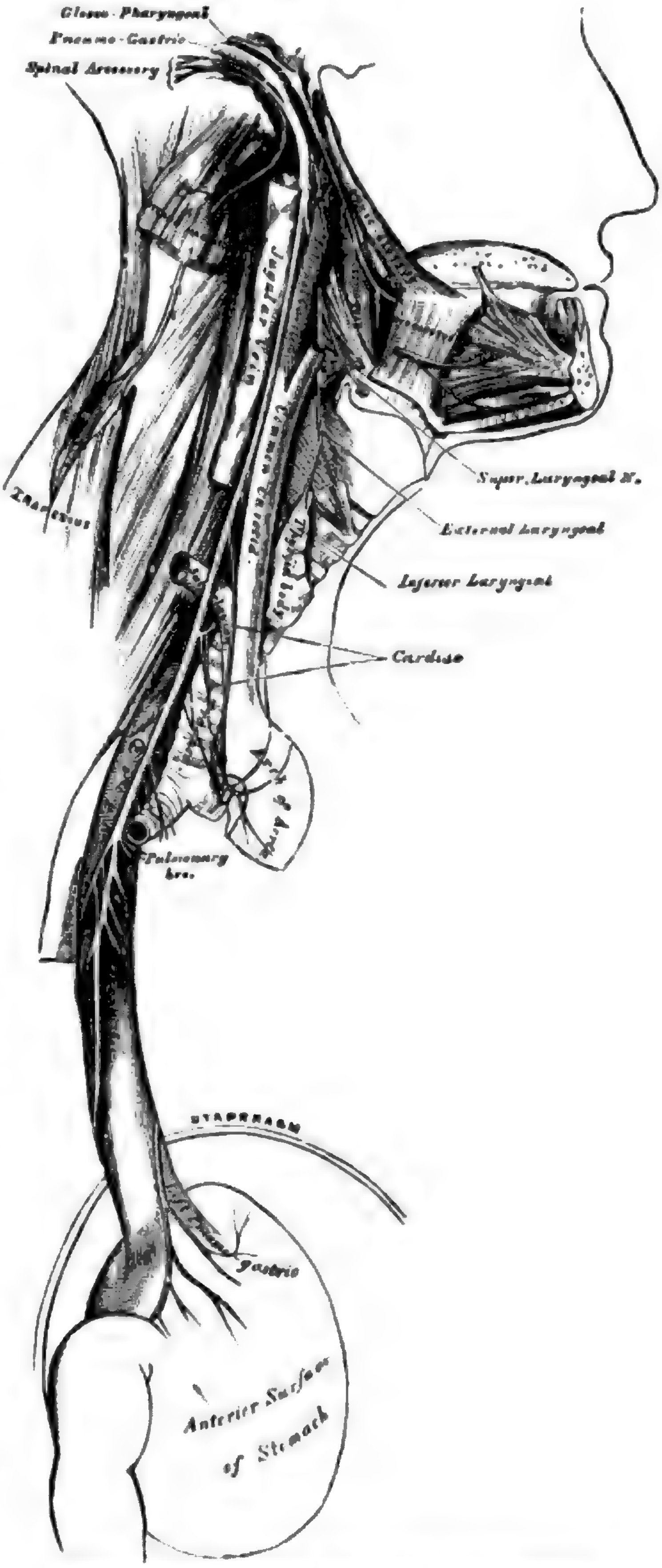
Glosso-Pharyngeal
Pneumo-Gastric
Spinal Accessory
Jugular Vein
Common Carotid
Thyroid body
Scalenus
Super. Laryngeal N.
External Laryngeal
Inferior Laryngeal
Cardiac
Arch of Aorta
Pulmonary brs.
Diaphragm
Gastric
Anterior Surface of Stomach

Course and Distribution of the Eighth Pair of Nerves.

In passing through the jugular foramen the nerve presents, in succession, two gangliform enlargements. The superior, the smaller, is called the *jugular ganglion;* the inferior and larger, the *petrous ganglion* or the *ganglion of Andersch.*

The **superior or jugular ganglion** is situated in the upper part of the groove in which the nerve is lodged during its passage through the jugular foramen. It is of very small size, and involves only the outer side of the trunk of the nerve, a small fasciculus passing beyond it which is not connected directly with it.

The **inferior or petrous ganglion** is situated in a depression in the lower border of the petrous portion of the temporal bone; it is larger than the former, and involves the whole of the fibres of the nerve. From this ganglion arise those filaments which connect the glosso-pharyngeal with other nerves at the base of the skull.

Its branches of communication are with the pneumogastric and sympathetic.

The branches to the pneumogastric are two filaments—one to its auricular branch, and one to the upper ganglion of the pneumogastric.

The branch to the sympathetic is connected with the superior cervical ganglion.

There is also a branch of communication with the facial which perforates the posterior belly of the Digastric. It arises from the trunk of the nerve below the petrous ganglion, and joins the facial just after its exit from the stylo-mastoid foramen.

The branches of the glosso-pharyngeal nerve are the tympanic, carotid, pharyngeal, muscular, tonsillar, and lingual.

The **tympanic branch** (*Jacobson's nerve*) arises from the petrous ganglion, and enters a small bony canal in the lower surface of the petrous portion of the temporal bone, the lower opening of which is situated on the bony ridge which separates the carotid canal from the jugular fossa. Jacobson's nerve ascends to the tympanum, enters that cavity by an aperture in its floor close to the inner wall, and divides into branches which are contained in grooves upon the surface of the promontory, forming the tympanic plexus.

Its branches of distribution are—one to the fenestra rotunda, one to the fenestra ovalis, and one to the lining membrane of the Eustachian tube and tympanum.

Its branches of communication are three, and occupy separate grooves on the surface of the promontory. One of these arches forward and downward to the carotid canal to join the carotid plexus. A second runs forward and upward to join the greater superficial petrosal nerve as it lies in the hiatus Fallopii. The third branch runs upward through the substance of the petrous portion of the temporal bone. In its course it passes by the ganglionic enlargement of the facial nerve, and, receiving a connecting filament from it, becomes the lesser superficial petrosal nerve. This nerve enters the skull through a small aperture situated external to the hiatus Fallopii on the anterior surface of the petrous bone, courses forward across the base of the skull, and emerges through a foramen in the middle fossa (sometimes the foramen ovale) and joins the otic ganglion.

The **carotid branches** descend along the trunk of the internal carotid artery as far as its point of bifurcation, communicating with the pharyngeal branch of the pneumogastric and with the branches of the sympathetic.

The **pharyngeal branches** are three or four filaments which unite opposite the Middle constrictor of the pharynx with the pharyngeal branches of the pneumogastric, the external laryngeal, and sympathetic nerves to form the pharyngeal plexus, branches from which perforate the muscular coat of the pharynx to supply the muscles and mucous membrane.

The **muscular branches** are distributed to the Stylo-pharyngeus.

The **tonsillar branches** supply the tonsil, forming a plexus (*circularis tonsillaris*) around this body, from which branches are distributed to the soft palate and fauces, where they communicate with the palatine nerves.

The *lingual branches* are two in number: one supplies the circumvallate papillæ and the mucous membrane covering the surface of the base of the tongue; the other perforates its substance and supplies the mucous membrane and papillæ of the side of the organ.

TENTH PAIR (Fig. 495, and Fig. 520, p. 787).

The **tenth** or **Pneumogastric Nerve** (*nervus vagus* or *par vagum*) has a more extensive distribution than any of the other cranial nerves, passing through the neck and thorax to the upper part of the abdomen. It is composed of both motor and sensory filaments. It supplies the organs of voice and respiration with motor and sensory fibres, and the pharynx, œsophagus, stomach, and heart with motor influence. Its *superficial origin* is by eight or ten filaments from the groove between the restiform and the olivary body below the glosso-pharyngeal; its *deep origin* may be traced deeply through the fasciculi of the medulla to terminate in a gray nucleus near the lower part of the floor of the fourth ventricle. The filaments become united and form a flat cord, which passes outward across the flocculus to the jugular foramen, through which it emerges from the cranium. In passing through this opening the pneumogastric accompanies the spinal accessory, being contained in the same sheath of dura mater with it, a membranous septum separating it from the glosso-pharyngeal, which lies in front (Fig. 415, p. 622). The nerve in this situation presents a well-marked ganglionic enlargement, which is called *ganglion jugulare*, or the *ganglion of the root of the pneumogastric:* to it the accessory part of the spinal accessory nerve is connected. After the exit of the nerve from the jugular foramen a second gangliform swelling is formed upon it, called the *ganglion inferius* or the *ganglion of the trunk of the nerve;* below which it is again joined by filaments from the accessory nerve. The nerve passes vertically down the neck within the sheath of the carotid vessels lying between the internal carotid artery and internal jugular vein as far as the thyroid cartilage, and then between the same vein and the common carotid to the root of the neck. Here the course of the nerve becomes different on the two sides of the body.

On the *right side* the nerve passes across the subclavian artery, between it and the subclavian vein, and descends by the side of the trachea to the back part of the root of the lung, where it spreads out in a plexiform network (*posterior pulmonary*), from the lower part of which two cords descend upon the œsophagus, on which they divide, forming, with branches from the opposite nerve, the œsophageal plexus (*plexus gulæ*); below, these branches are collected into a single cord, which runs along the back part of the œsophagus, enters the abdomen, and is distributed to the posterior surface of the stomach, joining the left side of the solar plexus, and sending filaments to the splenic plexus and a considerable branch to the cœliac plexus.

On the *left side* the pneumogastric nerve enters the chest between the left carotid and subclavian arteries, behind the left innominate vein. It crosses the arch of the aorta, and descends behind the root of the left lung and along the anterior surface of the œsophagus to the stomach, distributing branches over its anterior surface, some extending over the great cul-de-sac, and others along the lesser curvature. Filaments from these branches enter the gastro-hepatic omentum and join the left hepatic plexus.

The *Ganglion of the Root* is of a grayish color, circular in form, about two lines in diameter, and resembles the ganglion on the large root of the fifth nerve.

Connecting branches.—To this ganglion the accessory portion of the spinal accessory nerve is connected by several delicate filaments; it also has a communicating twig with the petrous ganglion of the glosso-pharyngeal, with the facial nerve by means of its auricular branch, and with the sympathetic by means of an ascending filament from the superior cervical ganglion.

The *Ganglion of the Trunk* (inferior) is a plexiform cord, cylindrical in form, of a reddish color, and about an inch in length; it involves the whole of the fibres of the nerve, and passing over it is the accessory portion of the spinal accessory nerve, which blends with the pneumogastric below the ganglion, and is then principally continued into its pharyngeal and superior laryngeal branches.

Connecting branches.—This ganglion is connected with the hypoglossal, the superior cervical ganglion of the sympathetic, and the loop between the first and second cervical nerves.

The *branches of the pneumogastric* are—

In the jugular fossa	Auricular.
In the neck	Pharyngeal. Superior laryngeal. Recurrent laryngeal. Cervical cardiac.
In the thorax	Thoracic cardiac. Anterior pulmonary. Posterior pulmonary. Œsophageal.
In the abdomen	Gastric.

The **auricular branch** (Arnold's) arises from the ganglion of the root, and is joined soon after its origin by a filament from the petrous ganglion of the glosso-pharyngeal; it passes outward behind the jugular vein and enters a small canal on the outer wall of the jugular fossa. Traversing the substance of the temporal bone, it crosses the aquæductus Fallopii about two lines above its termination at the stylo-mastoid foramen; here it gives off an ascending branch which joins the facial, and a descending branch which communicates with the posterior auricular branch of the same nerve: the continuation of the nerve reaches the surface by passing through the auricular fissure between the mastoid process and the external auditory meatus, supplies the integument at the back part of the pinna, and communicates with the branches of the auricularis magnus.

The **pharyngeal branch,** the principal motor nerve of the pharynx, arises from the upper part of the inferior ganglion of the pneumogastric, receiving a filament from the accessory portion of the spinal accessory; it passes across the internal carotid artery (in front or behind) to the upper border of the Middle constrictor, where it divides into numerous filaments, which communicate with those from the glosso-pharyngeal, superior laryngeal (its external branch), and sympathetic to form the pharyngeal plexus, from which branches are distributed to the muscles and mucous membrane of the pharynx. As this nerve crosses the internal carotid some filaments are distributed, together with those from the glosso-pharyngeal, upon the wall of this vessel.

The **superior laryngeal** is the nerve of sensation to the larynx. It is larger than the preceding, and arises from the middle of the inferior ganglion of the pneumogastric. In its course it receives a branch from the accessory portion of the spinal accessory nerve. It descends by the side of the pharynx behind the internal carotid, where it divides into two branches, the external and internal laryngeal.

The *external laryngeal* branch, the smaller, descends by the side of the larynx, beneath the Sterno-thyroid, to supply the Crico-thyroid muscle. It gives branches to the pharyngeal plexus and the Inferior constrictor, and communicates with the superior cardiac nerve behind the common carotid.

The *internal laryngeal* branch descends to the opening in the thyro-hyoid membrane, through which it passes with the superior laryngeal artery, and is distributed to the mucous membrane of the larynx. A small branch enters the Arytenoid muscle, and another communicates with the recurrent laryngeal nerve.

The branches to the mucous membrane are distributed, some in front to the epiglottis, the base of the tongue, and the epiglottidean glands; while others pass backward, in the aryteno-epiglottidean fold, to supply the mucous membrane surrounding the superior orifice of the larynx, as well as the membrane which lines the cavity of the larynx as low down as the vocal chord.

The filament to the Arytenoid muscle is distributed partly to it and partly to the mucous lining of the larynx.

The filament which joins with the recurrent laryngeal descends beneath the mucous membrane on the inner surface of the lateral part of the thyroid cartilage, where the two nerves become united.

The **inferior** or **recurrent laryngeal** [Fig. 364, p. 503], so called from its reflected course, is the motor nerve of the larynx. It arises on the right side in front of the subclavian artery, winds from before backward round that vessel, and ascends obliquely to the side of the trachea behind the common carotid and inferior thyroid arteries. On the left side it arises in front of the arch of the aorta, and winds from before backward round the aorta at the point where the obliterated remains of the ductus arteriosus are connected with it, and then ascends to the side of the trachea. The nerves on both sides ascend in the groove between the trachea and œsophagus, and, passing under the lower border of the Inferior constrictor muscle, enter the larynx behind the articulation of the inferior cornu of the thyroid cartilage with the cricoid, being distributed to all the muscles of the larynx excepting the Crico-thyroid, and joining with the superior laryngeal.

The recurrent laryngeal as it winds round the subclavian artery and aorta gives off several cardiac filaments, which unite with the cardiac branches from the pneumogastric and sympathetic. As it ascends in the neck it gives off œsophageal branches, more numerous on the left than on the right side, which supply the mucous membrane and muscular coat of the œsophagus; tracheal branches to the mucous membrane and muscular fibres of the trachea; and some pharyngeal filaments to the Inferior constrictor of the pharynx.

The **cervical cardiac branches**, two or three in number, arise from the pneumogastric at the upper and lower part of the neck.

The *superior* branches are small, and communicate with the cardiac branches of the sympathetic and with the great cardiac plexus.

The *inferior* branches, one on each side, arise at the lower part of the neck just above the first rib. On the right side this branch passes in front or by the side of the arteria innominata, and communicates with one of the cardiac nerves proceeding to the deep cardiac plexus. On the left side it passes in front of the arch of the aorta and joins the superficial cardiac plexus.

The **thoracic cardiac branches**, on the right side, arise from the trunk of the pneumogastric as it lies by the side of the trachea, and from its recurrent laryngeal branch, but on the left side from the recurrent nerve only; passing inward, they terminate in the deep cardiac plexus.

The **anterior pulmonary branches**, two or three in number and of small size, are distributed on the anterior aspect of the root of the lungs. They join with filaments from the sympathetic and form the anterior pulmonary plexus.

The **posterior pulmonary branches**, more numerous and larger than the anterior, are distributed on the posterior aspect of the root of the lung: they are joined by filaments from the third and fourth thoracic ganglia of the sympathetic, and form the posterior pulmonary plexus. Branches from both plexuses accompany the ramifications of the air-tubes through the substance of the lungs.

The **œsophageal branches** are given off from the pneumogastric both above and below the pulmonary branches. The lower are more numerous and larger than the upper. They form, together with branches from the opposite nerve, the *œsophageal plexus* or *plexus gulæ*.

The **gastric branches** are the terminal filaments of the pneumogastric nerve. The nerve on the right side is distributed to the posterior surface of the stomach, and joins the left side of the cœliac plexus and the splenic plexus. The nerve on the left side is distributed over the anterior surface of the stomach, some filaments passing across the great cul-de-sac, and others along the lesser curvature. They unite with branches of the right nerve and with the sympathetic, some filaments passing through the lesser omentum to the left hepatic plexus.

ELEVENTH PAIR (Fig. 495).

The **eleventh** or **Spinal Accessory Nerve** [*i. e.* **nervus spinalis ad pneumogastricum accessorius**], consists of two parts—one the accessory part to the vagus, and the other the spinal portion.

The **accessory part**, the smaller of the two, arises by four or five delicate filaments from the lateral tract of the cord below the roots of the vagus; these filaments may be traced to a nucleus of gray matter at the back of the medulla, below the origin of the vagus. It joins, in the jugular foramen, with the upper ganglion of the vagus by one or two filaments, and is continued into the vagus below the second ganglion. It is principally distributed to the pharyngeal and superior laryngeal branches of the vagus, but some branches from it are continued into the recurrent laryngeal nerve and probably into the cardiac nerves also.

The **spinal portion**, firm in texture, arises by several filaments from the lateral tract of the cord as low down as the sixth cervical nerve; the fibres pierce the tract, and are connected with the anterior horn of the gray matter of the cord. This portion of the nerve ascends between the ligamentum denticulatum and the posterior roots of the spinal nerves, enters the skull through the foramen magnum, and is then directed outward to the jugular foramen, through which it passes, lying in the same sheath as the pneumogastric, but separated from it by a fold of the arachnoid, and is here connected with the accessory portion. At its exit from the jugular foramen it passes backward, either in front of or behind the internal jugular vein, and descends obliquely behind the Digastric and Stylo-hyoid muscles to the upper part of the Sterno-mastoid. It pierces that muscle and passes obliquely across the occipital triangle, to terminate in the deep surface of the Trapezius. This nerve gives several branches to the Sterno-mastoid during its passage through it, and joins in its substance with branches from the second cervical which supply the muscle. Beneath the Trapezius it joins with the third and fourth cervical nerves to form a sort of plexus from which fibres are distributed to the muscle, and in the occipital triangle between the two muscles it joins with the second and third cervical nerves and assists in the formation of the cervical plexus. [It is accessible for operation by incision at either the anterior or posterior border of the Sterno-cleido-mastoid muscle at its upper portion.]

TWELFTH PAIR (Fig. 496).

The **twelfth** or **Hypoglossal Nerve** is the motor nerve of the tongue. It arises by several filaments, from ten to fifteen in number, from the groove between the pyramidal and olivary bodies, in a continuous line with the anterior roots of the spinal nerves. The *deep origin* of the nerve can be traced through the olivary body to a special nucleus at the lowest point of the fourth ventricle, close to the decussation of the pyramids. The filaments of this nerve are collected into two

FIG. 496.

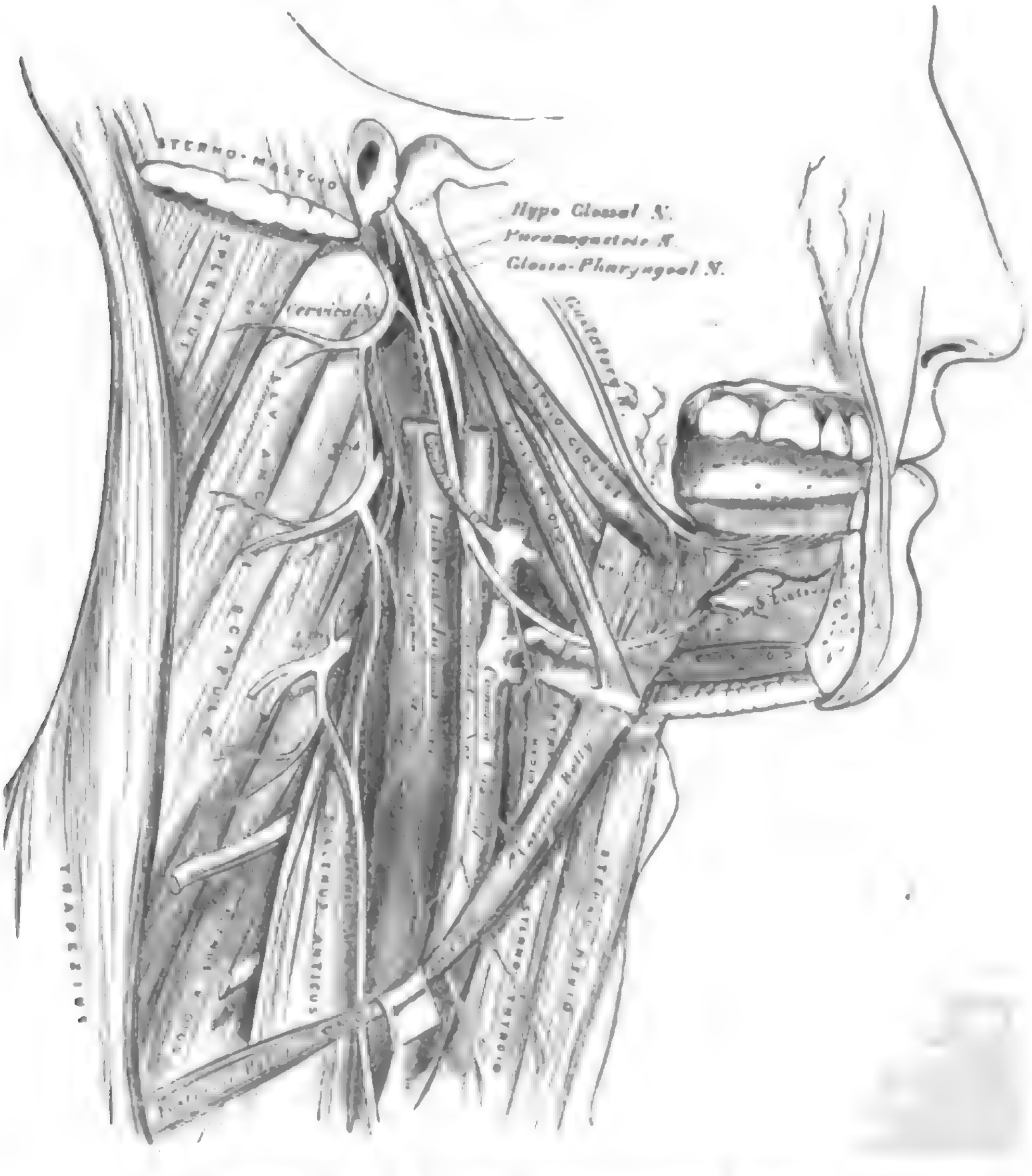
Sterno-Mastoid
Hypo Glossal N.
Pneumogastric N.
Glosso-Pharyngeal N.
Gustatory N.
2nd Cervical N.
Splenius
Lev. Ang. Scapulae
Trapezius
Scalenus Anticus
Anterior Belly
Sterno-Thyroid

Hypoglossal Nerve, Cervical Plexus, and their Branches.

bundles, which perforate the dura mater separately, opposite the anterior condyloid foramen, and unite together after their passage through it. In those cases in which the anterior condyloid foramen in the occipital bone is double, these two portions of the nerve are separated by the small piece of bone which divides the foramen. The nerve descends almost vertically to a point corresponding with the angle of the jaw. It is at first deeply seated beneath the internal carotid artery and internal jugular vein, and intimately connected with the pneumogastric nerve; it then passes forward between the vein and artery, and lower down in the neck becomes superficial below the Digastric muscle. The nerve then loops round the occipital artery, and crosses the external carotid below the tendon of the Digastric muscle. It passes beneath the Mylo-hyoid muscle, lying between it and the Hyo-glossus, and communicates at the anterior border of the latter muscle with the gustatory nerve; it is then continued forward in the fibres of the Genio-hyo-glossus muscle as far as the tip of the tongue, distributing branches to its substance.

Branches of this nerve communicate with the

Pneumogastric.
Sympathetic.
First and second cervical nerves.
Gustatory.

The communication with the pneumogastric takes place close to the exit of the nerve from the skull, numerous filaments passing between the hypoglossal and lower ganglion of the pneumogastric; sometimes the two nerves are united so as to form one mass.

The communication with the sympathetic takes place opposite the atlas by branches derived from the superior cervical ganglion, and in the same situation the nerve is joined by a filament derived from the loop connecting the first two cervical nerves.

The communication with the gustatory takes place near the anterior border of the Hyo-glossus muscle by numerous filaments which ascend upon it.

The branches of distribution are the

Descendens noni.
Muscular.
Thyro-hyoid.
Meningeal.

The **descendens noni** [*i. e. descending* branch of the *ninth* nerve—a relic of the older enumeration of Willis] is a long slender branch which quits the hypoglossal where it turns round the occipital artery. It descends obliquely across the sheath of the carotid vessels, and joins the communicating branches from the second and third cervical nerves just below the middle of the neck to form a loop. From the convexity of this loop branches pass forward to supply the Sterno-hyoid, Sterno-thyroid, and both bellies of the Omo-hyoid. According to Arnold, another filament descends in front of the vessels into the chest and joins the cardiac and phrenic nerves. The descendens noni is occasionally contained in the sheath of the carotid vessels, being sometimes placed over and sometimes beneath the internal jugular vein.

The **thyro-hyoid** is a small branch arising from the hypoglossal near the posterior border of the Hyo-glossus; it passes obliquely across the great cornu of the hyoid bone and supplies the Thyro-hyoid muscle.

The **muscular branches** are distributed to the Stylo-glossus, Hyo-glossus, Genio-hyoid, and Genio-hyo-glossus muscles. At the under surface of the tongue numerous slender branches pass upward into the substance of the organ.

Meningeal Branches.—As the hypoglossal nerve passes through the anterior condyloid foramen it gives off, according to Luschka, several filaments to the dura mater in the posterior fossa of the base of the skull.

The Spinal Nerves.

THE **Spinal Nerves**[1] are so called because they take their origin from the spinal cord and are transmitted through the intervertebral foramina on either side of the spinal column. There are thirty-one pairs of spinal nerves, which are arranged into the following groups, corresponding to the region of the spine through which they pass:

Cervical	8 pairs.
Dorsal	12 "
Lumbar	5 "
Sacral	5 "
Coccygeal	1 pair.

It will be observed that each group of nerves corresponds in number with the vertebræ in that region, except the cervical and coccygeal.

Each spinal nerve arises by two roots, an anterior or motor root, and a posterior or sensory root.

ROOTS OF THE SPINAL NERVES.

The **anterior roots** arise somewhat irregularly from a linear series of depressions on the antero-lateral column of the spinal cord, gradually approaching toward the anterior median fissure as they descend.

The fibres of the anterior roots, according to the researches of Dr. Lockhart Clarke, are attached to the anterior part of the antero-lateral column, and, after penetrating horizontally through the longitudinal fibres of this tract, enter the gray substance, where their fibrils cross each other and diverge in all directions like the expanded hairs of a brush, some of them running more or less longitudinally upward and downward, and others decussating with those of the opposite side through the anterior commissure in front of the central canal. Kölliker states that many fibres of the anterior root enter the lateral column of the same side, where, turning *upward*, they pursue their course as longitudinal fibres. In other respects the description of the origin of the anterior roots by these observers is very similar.

The **posterior roots** are all attached to the cord at the postero-lateral fissure. They enter the gray substance of the posterior cornu, either directly through the substantia gelatinosa, or indirectly by first passing through the white matter of the posterior column and winding round in front of the caput cornu. Those which enter the gray matter at once for the most part turn upward and downward, and become continuous with the fine nerve-plexus in the central portion of the gray matter; some few fibres pass transversely through the posterior commissure to the opposite side, and others into the anterior cornu of the same side. Those fibres which enter the gray matter in front of the caput cornu reach the posterior vesicular column and blend with it, a few fibres passing through it to become longitudinal in the posterior column of the cord.

The *posterior roots* of the nerves are larger, but the individual filaments are finer and more delicate, than those of the anterior. As their component fibrils pass outward toward the aperture in the dura mater they coalesce into two bundles,

---

[[1] Since the section on the Histology of the Nerves was printed I have received the second edition of the *Bradshawe Lecture* for 1883, by Mr. John Marshall. In the original lecture he predicted that besides the vaso-motor (sympathetic) nerves distributed to the blood-vessels of the nerves, there would be found sensory *nervi nervorum*. In the second edition this prediction is verified, and he gives several excellent drawings by Prof. Victor Horsley demonstrating their existence.]

receive a tubular sheath from that membrane, and enter the ganglion which is developed upon each root.

The posterior root of the first cervical nerve forms an exception to these characters. It is smaller than the anterior, has frequently no ganglion developed upon it, and when the ganglion exists it is often situated within the dura mater.

The *anterior roots* are the smaller of the two, devoid of any ganglionic enlargement, and their component fibrils are collected into two bundles near the intervertebral foramina.

GANGLIA OF THE SPINAL NERVES.

A ganglion is developed upon the posterior root of each of the spinal nerves. These ganglia are of an oval form and of a reddish color; they bear a proportion in size to the nerves upon which they are formed, and are placed in the intervertebral foramina external to the point where the nerves perforate the dura mater. Each ganglion is bifid internally where it is joined by the two bundles of the posterior root, the two portions being united into a single mass externally. The ganglion upon the first and second cervical nerves forms an exception to these characters, being placed on the arches of the vertebræ over which the nerves pass. The ganglia also of the sacral nerves are placed within the spinal canal, and that on the coccygeal nerve also in the canal about the middle of its posterior root.

[DIVISIONS OF THE SPINAL NERVES.]

Immediately beyond the ganglion the two roots coalesce, their fibres intermingle, and the trunk thus formed passes out of the intervertebral foramen, and divides into an *anterior division*[1] for the supply of the anterior part of the body, and a *posterior division* for the posterior part, each containing fibres from both roots.

ANTERIOR DIVISIONS OF THE SPINAL NERVES.

The anterior divisions of the spinal nerves supply the parts of the body in front of the spine, including the limbs. They are for the most part larger than the posterior divisions, this increase of size being proportioned to the larger extent of structures they are required to supply. Each division is connected by slender filaments with the sympathetic. In the dorsal region the anterior divisions of the spinal nerves are completely separate from each other and are uniform in their distribution, but in the cervical, lumbar, and sacral regions they form intricate plexuses previous to their distribution.

POSTERIOR DIVISIONS OF THE SPINAL NERVES.

The posterior divisions of the spinal nerves are generally smaller than the anterior; they arise from the trunk resulting from the union of the roots in the intervertebral foramina, and, passing backward, divide into external and internal branches, which are distributed to the muscles and integument behind the spine. The first cervical and lower sacral nerves are exceptions to these characters.

[POINTS OF ORIGIN AND EMERGENCE OF THE SPINAL NERVES.

The roots of the spinal nerves, as soon as they leave the spinal cord, run obliquely downward to the intervertebral foramina, through which they pass. The obliquity of their course increases from above downward, especially in the lower nerves. Hence their points of emergence from the spinal cord and their points of emergence from the spinal column are not at the same level. It is often important to know the relation of these points of origin from the spinal cord, and

---

[1] For the sake of clearness I have thought it better to call the primary branches into which the compound nerve divides, "divisions," instead of "branches," as in the former editions.

[FIG. 497.

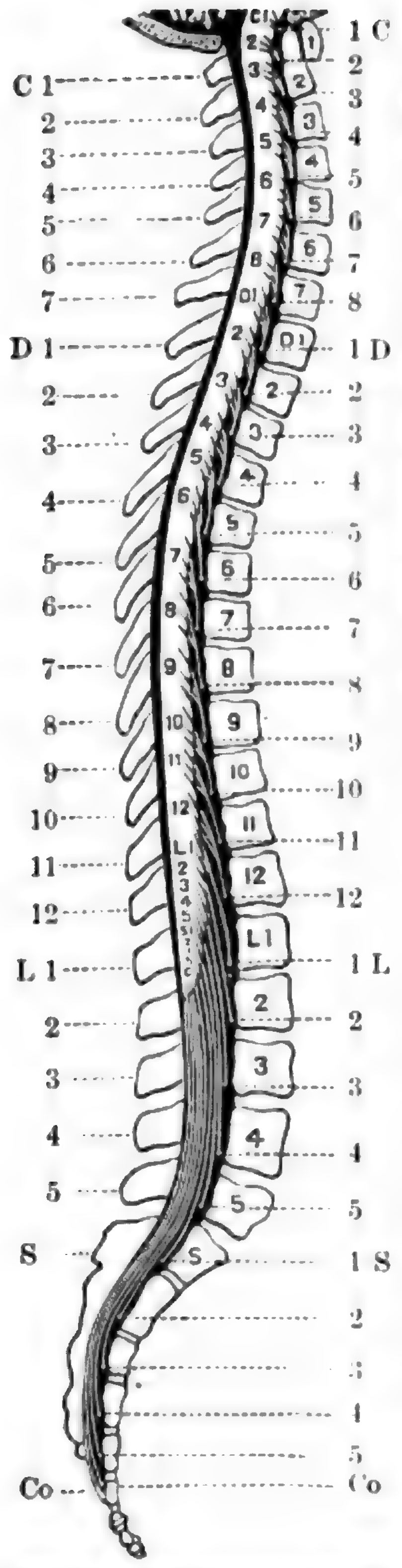

MOTOR.	SENSORY.	REFLEX.
St. Mastoid. Trapezius.	Neck and Scalp.	
Diaphragm.	Neck and Shoulder.	Scapular.
Serratus.		
Shoulder.	Shoulder.	
Arm. mus.	Arm.	
Hand. (ulnar lowest.)	Hand.	
Intercostal Muscles.	Front of Thorax.	Epigastric.
	Ensiform area.	
Abdominal Muscles.	Abdomen (Umbilicus 10th).	Abdominal.
	Buttock, upper part.	
Flexors, hip.	Groin and Scrotum (front).	Cremasteric.
	Thigh outer side.	
Extensors, knee.	Thigh front.	*Knee-jerk.*
Adductors.	Thigh inner side.	
Abductors. hip.	Leg inner side.	Gluteal.
	Buttock, lower part.	
Extensors (?)	Back of Thigh.	
Flexors, knee (?)		*Foot-clonus.*
Muscles of leg moving foot.	Leg and Foot except inner part.	Plantar.
Perineal and Anal Muscles.	Perineum and Anus.	
	Skin from Coccyx to Anus.	

Diagram and Table showing the Approximate Relation of the Spinal Nerves of the Various Motor, Sensory, and Reflex Functions of the Spinal Cord. (*From anatomical and pathological data. From Gowers.*)]

of emergence through the intervertebral foramina to the spinous processes of the vertebræ. Fig. 497 illustrates this, as well as the motor, sensory, and reflex functions of the various spinal nerves.]

CERVICAL NERVES.

The roots of the cervical nerves increase in size from the first to the fifth, and then remain the same size to the eighth. The posterior roots bear a proportion to the anterior as 3 to 1, which is much greater than in any other region, the individual filaments being also much larger than those of the anterior roots. In direction the roots of the cervical are less oblique than those of the other spinal nerves. The first cervical nerve is directed a little upward and outward; the second is horizontal; the others are directed obliquely downward and outward, the lowest being the most oblique, and consequently longer than the upper, the distance between their place of origin and their point of exit from the spinal canal never exceeding the depth of one vertebræ.

The *trunk of the first cervical nerve* (*suboccipital*) leaves the spinal canal between the occipital bone and the posterior arch of the atlas, the second, between the posterior arch of the atlas and the lamina of the axis; and the eighth (the last), between the last cervical and first dorsal vertebræ.

Each nerve at its exit from the intervertebral foramen divides into an anterior and a posterior division. The anterior divisions of the four upper cervical nerves form the cervical plexus. The anterior divisions of the four lower cervical nerves, together with the first dorsal, form the brachial plexus.

POSTERIOR DIVISIONS OF THE CERVICAL NERVES (Fig. 498).

The **posterior division of the first cervical** (*suboccipital*) nerve differs from the posterior divisions of the other cervical nerves in not dividing into an external and internal branch. It is larger than the anterior, and escapes from the spinal canal between the occipital bone and the posterior arch of the atlas lying behind the vertebral artery. It enters the suboccipital triangle formed by the Rectus capitis posticus major, the Obliquus superior, and Obliquus inferior, and supplies the Recti and Obliqui muscles and the Complexus. From the branch which supplies the Inferior oblique a filament is given off which joins the second cervical nerve. This nerve also occasionally gives off a cutaneous filament, which accompanies the occipital artery and communicates with the occipitalis major and minor nerves.

The **posterior division of the second cervical nerve** is three or four times greater than the anterior branch, and the largest of all the posterior cervical divisions. It emerges from the spinal canal between the posterior arch of the atlas and lamina of the axis, below the Inferior oblique. It supplies this muscle and receives a communicating filament from the first cervical. It then divides into an external and an internal branch.

The *internal* branch, called, from its size and distribution, the **occipitalis major** [Fig. 493, p. 734], ascends obliquely inward between the Obliquus inferior and Complexus, and pierces the latter muscle and the Trapezius near their attachments to the cranium. It is now joined by a filament from the third cervical nerve, and, ascending on the back part of the head with the occipital artery, divides into two branches, which supply the integument of the scalp as far forward as the vertex, communicating with the occipitalis minor. It gives off an auricular branch to the back part of the ear, and muscular branches to the Complexus. The *external* branch is often joined by the external branch of the posterior division of the third, and supplies the Complexus, Splenius, and Trachelo-mastoid.

The **posterior division of the third cervical** is smaller than the preceding, but larger than the fourth; it differs from the posterior divisions of the other cervical nerves in its supplying an additional filament to the integument of the occiput. This occipital branch arises from the internal or cutaneous branch beneath the Trapezius; it pierces that muscle, and supplies the skin on the lower and back part of the head. It lies to the inner side of the occipitalis major, with which it is connected. The posterior division of the third nerve, like the others, divides into an external and internal branch. The *internal* branch passes between the Semispinalis and Complexus, and, piercing the Splenius and Trapezius, supplies the skin over the latter muscle; the *external* branch joins with that of the posterior division of the second to supply the Splenius, Complexus, and Trachelo-mastoid.

The posterior division of the suboccipital nerve and the internal branches of the posterior divisions of the second and third cervical nerves are occasionally joined beneath the Complexus by communicating branches. This communication is described by Cruveilhier as the *posterior cervical plexus*.

The **posterior divisions of the fourth, fifth, sixth, seventh, and eighth cervical nerves** (Fig. 507, p. 765) pass backward and divide behind the posterior Intertransverse muscles into external and internal branches. The *external* branches supply the muscles at the side of the neck—viz. the Cervicalis ascendens, Transversalis colli, and Trachelo-mastoid. The *internal* branches, the larger, are distributed differently in the upper and lower part of the neck. Those derived from the fourth and fifth nerves pass between the Semispinalis and Complexus muscles, and, having reached the spinous processes, perforate the aponeurosis of the Splenius and Trapezius, and are continued outward to the integument over the Trapezius, whilst those derived from the three lowest cervical nerves are the smallest, and are placed beneath the Semispinalis, which they supply, and then pass into the Interspinalis, Multifidus

FIG. 498.

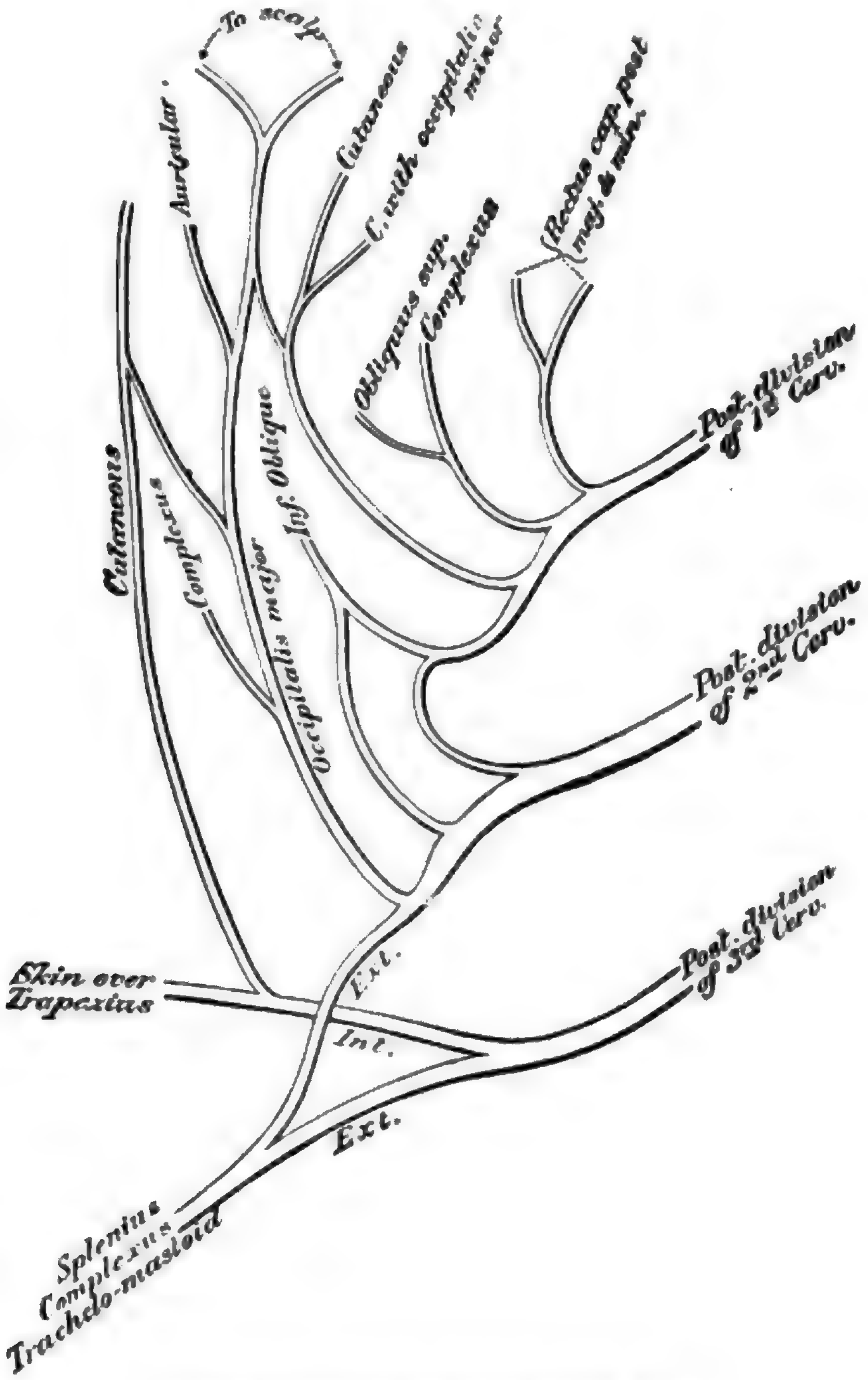
To scalp
Auricular
Cutaneous
C. with occipitalis minor
Rectus cap. post. maj. & min.
Obliquus sup.
Complexus
Post. division of 1st Cerv.
Cutaneous
Complexus
Occipitalis major
Inf. Oblique
Post. division of 2nd Cerv.
Skin over Trapezius
Ext.
Int.
Post. division of 3rd Cerv.
Ext.
Splenius
Complexus
Trachelo-mastoid

Posterior Divisions of the Upper Cervical Nerves.

spinæ, and Complexus, and send twigs through this latter muscle to supply the integument near the spinous processes (Hirschfeld).[1]

ANTERIOR DIVISIONS OF THE CERVICAL NERVES.

The **anterior division of the first** or **suboccipital nerve** is of small size. It escapes from the spinal canal through a groove upon the posterior arch of the atlas. In this groove it lies beneath the vertebral artery, to the inner side of the Rectus capitis lateralis. As it crosses the foramen in the transverse process of the atlas it receives a filament from the sympathetic. It then descends, in front of this process, to communicate with an ascending branch from the second cervical nerve.

Communicating filaments from this nerve join the pneumogastric, the hypoglossal, and the sympathetic, and some branches are distributed to the Rectus lateralis and the two Anterior recti. According to Valentin, the anterior division of the suboccipital also distributes filaments to the occipito-atloid articulation and mastoid process of the temporal bone.

The **anterior division of the second cervical nerve** escapes from the spinal canal between the posterior arch of the atlas and the lamina of the axis, and, passing forward on the outer side of the vertebral artery, divides in front of the Intertransverse muscle into an ascending branch, which joins the first cervical, and one or two descending branches, which join the third. It gives off the small occipital; a branch to assist in forming the great auricular; another to assist in forming the superficial cervical; one of the communicantes noni; and a filament to the Sterno-mastoid which communicates in the substance of the muscle with the spinal accessory.

The **anterior division of the third cervical nerve** is double the size of the preceding. At its exit from the intervertebral foramen it passes downward and outward beneath the Sterno-mastoid, and divides into two branches. The ascending branch joins the anterior division of the second cervical; the descending branch passes down in front of the Scalenus anticus and communicates with the fourth. It gives off the greater part of the great auricular and superficial cervical nerves; one of the communicantes noni; a branch to the supraclavicular nerves; a filament to assist in forming the phrenic and muscular branches to the Levator anguli scapulæ and Trapezius: this latter nerve communicates beneath the muscle with the spinal accessory. Sometimes the nerve to the Scalenus medius is derived from this source.

The **anterior division of the fourth cervical** is of the same size as the preceding. It receives a branch from the third, sends a communicating branch to the fifth cervical, and, passing downward and outward, divides into numerous filaments which cross the posterior triangle of the neck, forming the supraclavicular nerves. It gives a branch to the phrenic nerve, whilst it is contained in the intertransverse space, and sometimes a branch to the Scalenus medius muscle. It also gives a branch to the Levator anguli scapulæ and to the Trapezius which unites with the branch given off from the third nerve and communicates beneath the muscle with the spinal accessory.

The **anterior divisions of the fifth, sixth, seventh, and eighth cervical nerves** are remarkable for their large size. They are much larger than the preceding nerves, and are all of equal size. They assist in the formation of the brachial plexus.

CERVICAL PLEXUS.

The **Cervical Plexus** (Fig. 499, p. 751) is formed by the anterior divisions of the four upper cervical nerves. It is situated opposite the four upper vertebræ, resting upon the Levator anguli scapulæ and Scalenus medius muscles and covered in by the Sterno-mastoid.

---

[1] It will be seen that this statement, made on the authority of Hirschfeld, differs from that contained in the last edition of this work and in many of the textbooks on anatomy, where it is stated that the posterior divisions of the three lowest cervical nerves do not furnish any cutaneous filaments. The subject has been carefully investigated by my friend Mr. Ross, demonstrator of anatomy at St. George's Hospital, who informs me that he has been able to demonstrate the existence of cutaneous filaments from each of the three lowest cervical nerves.

Its branches may be divided into two groups, *superficial* and *deep*, which may be thus arranged:

- *Superficial*
  - Ascending
    - Superficialis colli.
    - Auricularis magnus.
    - Occipitalis minor.
  - Descending Supraclavicular
    - Sternal.
    - Clavicular.
    - Acromial.
- *Deep* . . .
  - Internal
    - Communicating.
    - Muscular.
    - Communicans noni.
    - Phrenic.
  - External
    - Communicating.
    - Muscular.

SUPERFICIAL BRANCHES OF THE CERVICAL PLEXUS (Fig. 499, p. 751; Fig. 490, p. 731; Fig. 493, p. 734; and Fig. 507, p. 765).

The **Superficialis colli** arises from the second and third cervical nerves, turns round the posterior border of the Sterno-mastoid about its middle, and, passing obliquely forward beneath the external jugular vein to the anterior border of that muscle, perforates the deep cervical fascia, and divides beneath the Platysma into two branches, which are distributed to the antero-lateral parts of the neck.

The *ascending branch* gives a filament which accompanies the external jugular vein; it then passes upward to the submaxillary region and divides into branches, some of which form a plexus with the cervical branches of the facial nerve beneath the Platysma; others pierce that muscle, supply it, and are distributed to the integument of the upper half of the neck, at its fore part, as high as the chin.

The *descending branch* (occasionally represented by two or more filaments) pierces the Platysma, and is distributed to the integument of the side and front of the neck as low as the sternum.

The **Auricularis magnus** is the largest of the ascending branches. It arises from the second and third cervical nerves, winds round the posterior border of the Sterno-mastoid, and after perforating the deep fascia ascends upon that muscle beneath the Platysma to the parotid gland, where it divides into numerous branches.

The *facial branches* pass across the parotid, and are distributed to the integument of the face; others penetrate the substance of the gland and communicate with the facial nerve.

The *posterior* or *auricular branches* ascend to supply the integument of the back part of the pinna, communicating with the auricular branches of the facial and pneumogastric nerves.

The *mastoid branch* joins the posterior auricular branch of the facial, and, crossing the mastoid process, is distributed to the integument behind the ear.

The **Occipitalis minor** arises from the second cervical nerve; it curves round the posterior border of the Sterno-mastoid above the preceding, and is directed almost vertically along the posterior border of that muscle to the back part of the side of the head. Near the cranium it perforates the deep fascia, and is continued upward along the side of the head behind the ear, supplying the integument and Occipito-frontalis muscle, and communicating with the occipitalis major, auricularis magnus, and posterior auricular branch of the facial.

This nerve gives off an *auricular branch* which supplies the Attolens aurem and the integument of the upper and back part of the auricle, communicating with the mastoid branch of the auricularis magnus. This branch is occasionally derived from the great occipital nerve. The occipitalis minor varies in size; it is occasionally double.

The **Descending** or **Supraclavicular branches** arise from the third and fourth cervical nerves: emerging beneath the posterior border of the Sterno-mastoid, they descend in the interval between that muscle and the Trapezius, and divide into branches which are arranged, according to their position, into three groups.

Fig. 499.

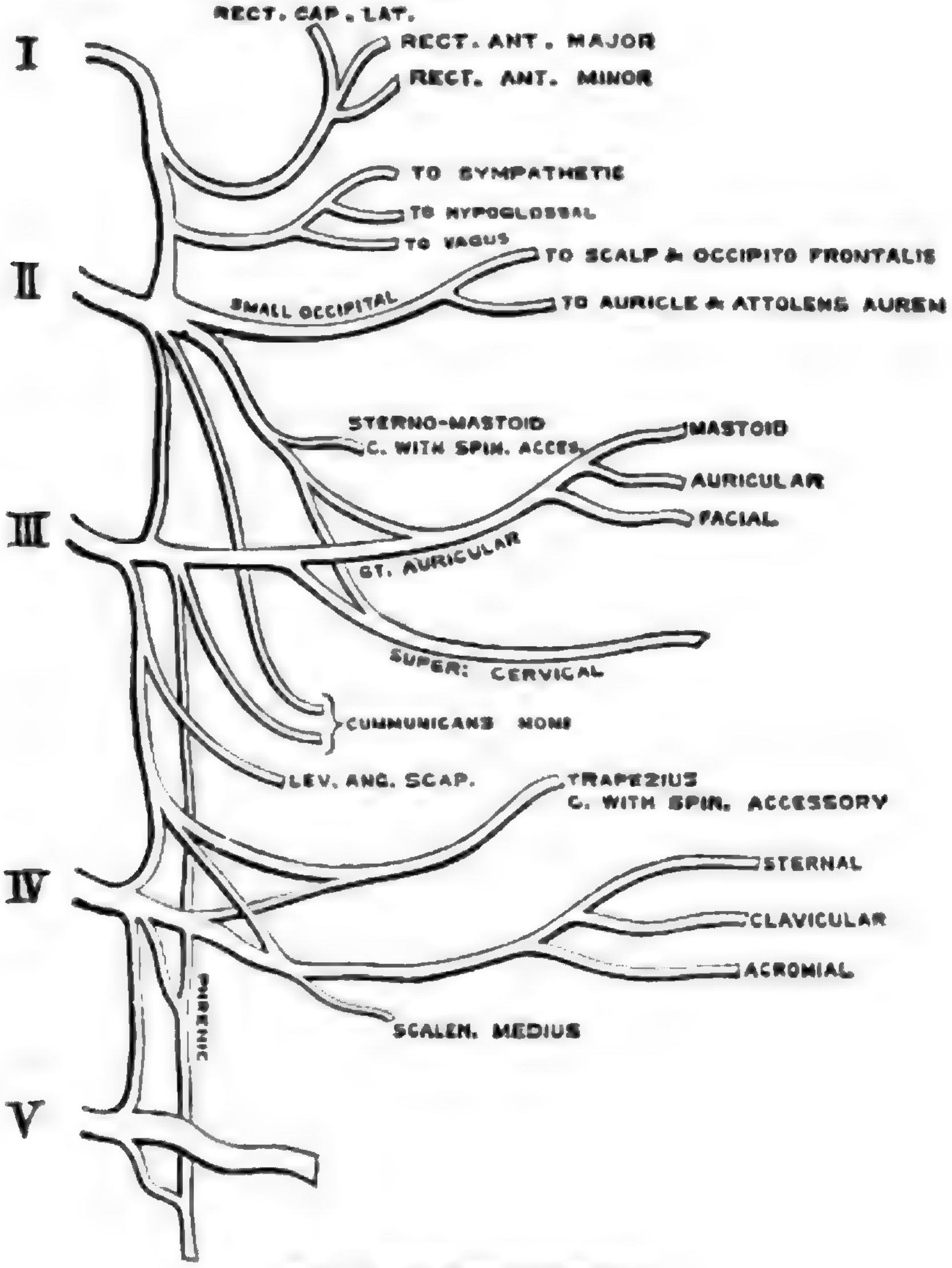
RECT. CAP. LAT.
I
RECT. ANT. MAJOR
RECT. ANT. MINOR
TO SYMPATHETIC
TO HYPOGLOSSAL
TO VAGUS
TO SCALP & OCCIPITO FRONTALIS
II
SMALL OCCIPITAL
TO AURICLE & ATTOLENS AUREM
STERNO-MASTOID
C. WITH SPIN. ACCES.
MASTOID
AURICULAR
FACIAL
III
GT. AURICULAR
SUPER: CERVICAL
CUMMUNICANS NONI
LEV. ANG. SCAP.
TRAPEZIUS
C. WITH SPIN. ACCESSORY
STERNAL
IV
CLAVICULAR
ACROMIAL
PHRENIC
SCALEN. MEDIUS
V

Plan of the Cervical Plexus.

The *inner* or *sternal branch* crosses obliquely over the clavicular and sternal attachments of the Sterno-mastoid, and supplies the integument as far as the median line.

The *middle* or *clavicular branch* crosses the clavicle, and supplies the integument over the Pectoral and Deltoid muscles, communicating with the cutaneous branches of the upper intercostal nerves. The clavicular branch has been known to pass through a foramen in the clavicle at the junction of the outer with the middle third of the bone.

The *external* or *acromial branch* passes obliquely across the outer surface of the Trapezius and the acromion, and supplies the integument of the upper and back part of the shoulder.

DEEP BRANCHES OF THE CERVICAL PLEXUS, INTERNAL SERIES.

The **communicating branches** consist of several filaments which pass from the loop between the first and second cervical nerves in front of the atlas to the pneumogastric, hypoglossal, and sympathetic, and a communicating branch between the fourth and fifth cervical.

Muscular branches supply the Anterior recti and Rectus lateralis muscles; they proceed from the first cervical nerve and from the loop formed between it and the second.

The **Communicans noni** (Fig. 496, p. 742) consists usually of two filaments, one being derived from the second, and the other from the third cervical. These filaments pass downward on the outer side of the internal jugular vein, cross in front of the vein a little below the middle of the neck, and form a loop with the descendens noni in front of the sheath of the carotid vessels. Occasionally the junction of these nerves takes place within the sheath.

The **Phrenic Nerve** (*internal respiratory of Bell*) [the motor nerve of the Diaphragm] arises from the third and fourth cervical nerves, and receives a communicating branch from the fifth, or sometimes from the fifth and sixth. It descends to the root of the neck, lying obliquely across the front of the Scalenus anticus, passes over the first part of the subclavian artery, between it and the subclavian vein, and, as it enters the chest, crosses the internal mammary artery near its origin. Within the chest it descends nearly vertically in front of the root of the lung and by the side of the pericardium, between it and the mediastinal portion of the pleura, to the Diaphragm, where it divides into branches which separately pierce that muscle and are distributed to its under surface.

The two phrenic nerves differ in their length, and also in their relations at the upper part of the thorax.

The *right nerve* is situated more deeply, and is shorter and more vertical in direction, than the left; it lies on the outer side of the right vena innominata and superior vena cava.

The *left nerve* is rather longer than the right, from the inclination of the heart to the left side and from the Diaphragm being lower on this than on the opposite side. At the upper part of the thorax it crosses in front of the arch of the aorta to the root of the lung.

Each nerve supplies filaments to the pericardium and pleura, and near the chest is joined by a filament from the sympathetic, and occasionally by one from the union of the descendens noni with the spinal nerves: this filament is found, according to Swan, only on the left side. It is also usually connected by a filament with the nerve to the Subclavius muscle. Branches have been described as passing to the peritoneum.

From the *right nerve* one or two filaments pass to join in a small ganglion with phrenic branches of the solar plexus, and branches from this ganglion are distributed to the hepatic plexus, the suprarenal capsule, and inferior vena cava. From the *left nerve* filaments pass to join the phrenic plexus of the sympathetic, but without any ganglionic enlargement.

DEEP BRANCHES OF THE CERVICAL PLEXUS, EXTERNAL SERIES.

Communicating Branches.—The cervical plexus communicates with the spinal accessory nerve in the substance of the Sterno-mastoid muscle, in the occipital triangle, and beneath the Trapezius.

Muscular branches are distributed to the Sterno-mastoid, Levator anguli scapulæ, Scalenus medius, and Trapezius.

The branch for the Sterno-mastoid is derived from the second cervical, the Levator anguli scapulæ receiving branches from the third and the Trapezius branches from the third and fourth. The Scalenus medius is supplied sometimes from the third, sometimes the fourth, and occasionally from both nerves.

THE BRACHIAL PLEXUS (Fig. 500).

The **Brachial Plexus** is formed by the union of the anterior branches of the four lower cervical and the greater part of the first dorsal nerves. It extends from the lower part of the side of the neck to the axilla. It is very broad and presents little of a plexiform arrangement at its commencement, is narrow opposite the clavicle, becomes broad, and forms a more dense interlacement in the axilla, and divides opposite the coracoid process into numerous branches for the supply of the upper limb. The nerves which form the plexus are all similar in size, and their mode of communication is subject to considerable variation, so that no one plan can be given as applying to every case. The following appears, however, to be the most constant arrangement: The fifth and sixth cervical unite together soon after their exit from the intervertebral foramina to form a common trunk. The eighth cervical and first dorsal also unite to form one trunk. So that the nerves forming the plexus, as they lie on the Scalenus medius external to the outer border of the Scalenus anticus, are blended into three trunks—an outer one, formed by the junction of the fifth and sixth cervical nerves; a middle one, consisting of the seventh cervical nerve; and an inner one, formed by the junction of the eighth cervical and first dorsal nerves. As they pass beneath the clavicle each of these three trunks divides into two branches, an *anterior* and a *posterior*. The anterior divisions of the outer and middle trunks then unite to form a common cord, which is situated on the outer side of the middle part of the axillary artery, and is called the *outer cord* of the brachial plexus. The anterior division of the inner trunk, formed by the union of the eighth cervical and first dorsal, courses down on the inner side of the axillary artery in the middle of the axilla, and forms the *inner cord* of the brachial plexus. The posterior cords of the outer trunk (formed by the junction of the fifth and sixth nerves) and of the middle trunk (the seventh nerve) unite together to form the *posterior cord*

Fig. 500.

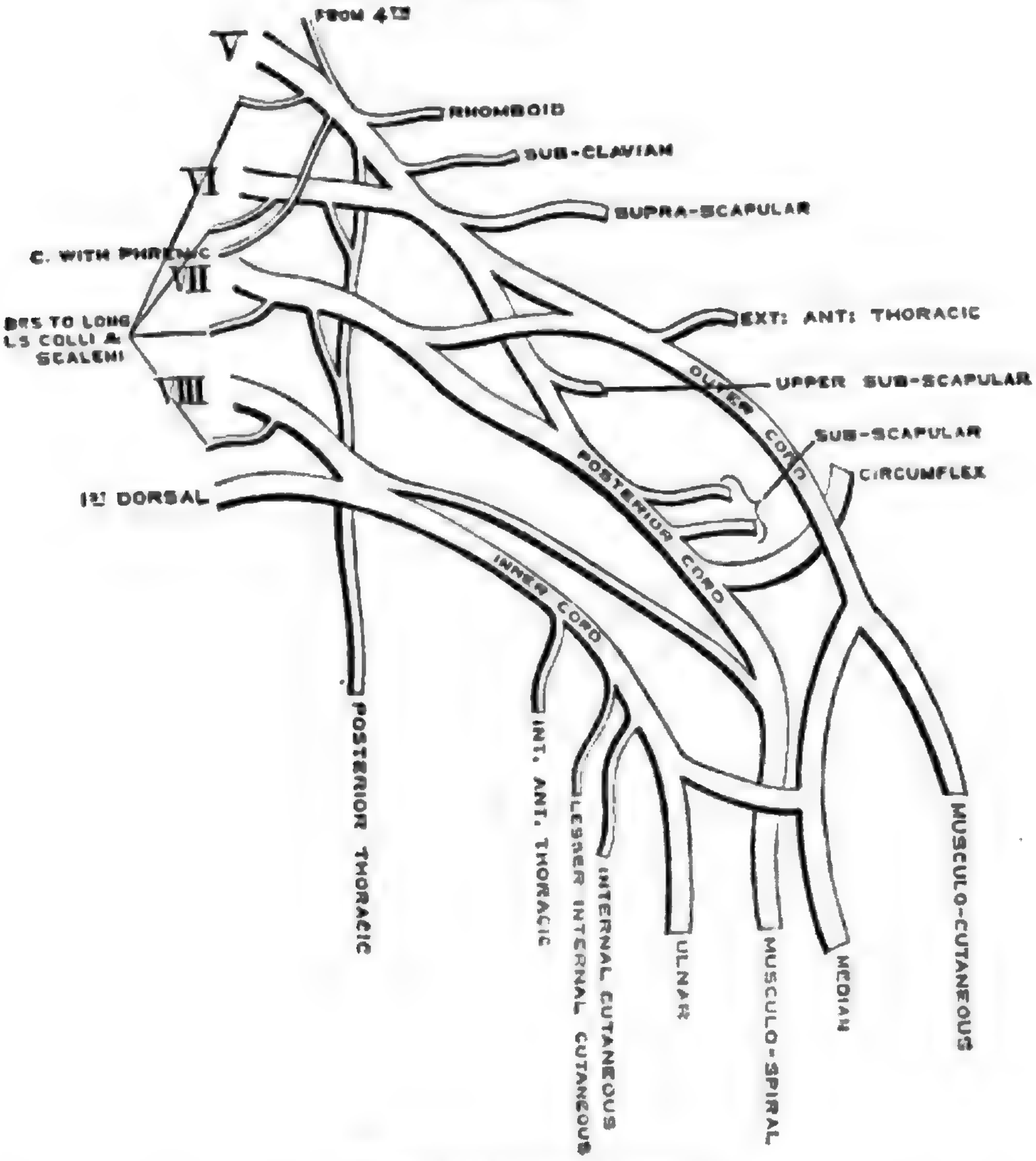
FROM 4TH
V
RHOMBOID
SUB-CLAVIAN
VI
SUPRA-SCAPULAR
C. WITH PHRENIC
VII
BRS TO LONG
LS COLLI &
SCALENI
EXT: ANT: THORACIC
VIII
OUTER CORD
UPPER SUB-SCAPULAR
SUB-SCAPULAR
CIRCUMFLEX
1ST DORSAL
POSTERIOR CORD
INNER CORD
POSTERIOR THORACIC
INT. ANT. THORACIC
LESSER INTERNAL CUTANEOUS
INTERNAL CUTANEOUS
ULNAR
MUSCULO-SPIRAL
MEDIAN
MUSCULO-CUTANEOUS

Plan of the Brachial Plexus.

of the brachial plexus, which is situated behind the second portion of the axillary artery. From this posterior trunk are given off the two lower subscapular nerves, the upper subscapular nerve being given off from the posterior division of the outer trunk prior to its junction with the posterior division of the middle trunk. The posterior trunk divides into the circumflex and musculo-spiral nerves; and the latter of these two nerves is subsequently joined by the posterior division of the inner trunk, formed by the union of the eighth cervical and first dorsal.[1]

The brachial plexus communicates with the cervical plexus by a branch from the fourth to the fifth nerve, and with the phrenic nerve by a branch from the fifth cervical, which joins that nerve on the Anterior scalenus muscle: the cervical and first dorsal nerves are also joined by filaments from the middle and inferior cervical ganglia of the sympathetic close to their exit from the intervertebral foramina.

RELATIONS.—*In the neck* the brachial plexus lies at first between the Anterior and Middle scaleni muscles, and then above and to the outer side of the subclavian artery. [At this point it is accessible for operations, such as stretching or resection.] It then passes behind the clavicle and Subclavius muscle, lying upon the first serration of the Serratus magnus and the Subscapularis muscles. *In the axilla* it is placed on the outer side of the first portion of the axillary artery; it surrounds the artery in the second part of its course, one cord lying upon the outer side of that vessel, one on the inner side, and one behind it; and at the lower part of the axillary space gives off its terminal branches to the upper extremity.

Branches.—The branches of the brachial plexus are arranged into two groups—viz. those given off above the clavicle, and those below that bone.

BRANCHES ABOVE THE CLAVICLE.

Communicating.
Muscular.
Posterior thoracic.
Suprascapular.

The **communicating branch** with the phrenic is derived from the fifth cervical nerve or from the loop between the fifth and sixth; it joins the phrenic on the Anterior scalenus muscle.

The **muscular branches** supply the Longus colli, Scaleni, Rhomboidei, and Subclavius muscles. Those for the Scaleni and Longus colli arise from the lower cervical nerves at their exit from the intervertebral foramina. The rhomboid branch arises from the fifth cervical, pierces the Scalenus medius, and passes beneath the Levator anguli scapulæ, which it occasionally supplies, to the Rhomboid muscles. The nerve to the Subclavius is a small filament which arises from the fifth cervical at its point of junction with the sixth nerve; it descends in front of the subclavian artery to the Subclavius muscle, and is usually connected by a filament with the phrenic nerve.

The **posterior thoracic nerve** (*long thoracic, external respiratory of Bell*) (Fig. 505, p. 760) supplies the Serratus magnus, and is remarkable for the length of its course. It sometimes arises by two roots from the fifth and sixth cervical nerves immediately after their exit from the intervertebral foramina, but generally by three roots from the fifth, sixth, and seventh nerves. These unite in the substance of the Middle scalenus muscle, and after emerging from it the nerve passes down behind the brachial plexus and the axillary vessels, resting on the outer surface of the Serratus magnus. It extends along the side of the chest to the lower border of that muscle, and supplies it with numerous filaments.

---

[1] It will be noticed that this description varies from that in previous editions, which was the formerly-accepted description of the plexus. The investigations of anatomists, and especially of Mr. Clement Lucas, have proved, however, that this description was not strictly correct, and the account given above substantially agrees with that of Mr. Lucas, as well as with that of Henle, the main point of difference being that the posterior division of the inner trunk—which, by the way, is an inconsiderable fasciculus in point of size—does not assist in forming the posterior cord of the plexus, but is entirely concerned in forming the musculo-spiral nerve. This I have found in my investigation to be the more constant arrangement of the two. The student must not expect, however, to find in every instance an exact counterpart of the above description, since the plexus is subject in its formation to the greatest diversities, and there is no doubt that an ingenious dissector, by splitting the nerves, may make almost any complicated arrangement which may suit his fancy. (See Mr. Lucas's paper in the *Guy's Hospital Reports*, 1875.) [See also a paper founded on an elaborate series of dissections by Dr. J. F. Walsh, *Amer. Journal Med. Sci.*, 1877.]

The **suprascapular nerve** (Fig. 506, p. 762) arises from the cord formed by the fifth and sixth cervical nerves; passing obliquely outward beneath the Trapezius, it enters the supraspinous fossa through the notch in the upper border of the scapula, and, passing beneath the Supraspinatus muscle, curves in front of the spine of the scapula to the infraspinous fossa. In the supraspinous fossa it gives off two branches to the Supraspinatus muscle and an articular filament to the shoulder-joint; and in the infraspinous fossa it gives off two branches to the Infraspinatus muscle, besides some filaments to the shoulder-joint and scapula.

BRANCHES BELOW THE CLAVICLE.

To the chest	Anterior thoracic.
To the shoulder	Subscapular. Circumflex.
To the arm, forearm, and hand . .	Musculo-cutaneous. Internal cutaneous. Lesser internal cutaneous. Median. Ulnar. Musculo-spiral.

The branches given off below the clavicle are derived from the three cords of the brachial plexus in the following manner:

From the outer cord arise the external of the two anterior thoracic nerves, the musculo-cutaneous nerve, and the outer head of the median.

From the inner cord arise the internal of the two anterior thoracic nerves, the internal cutaneous, the lesser internal cutaneous (nerve of Wrisberg), the ulnar, and inner head of the median.

From the posterior cord arise two of the three subscapular nerves, the third arising from the posterior division of the trunk formed by the fifth and sixth cervical nerves: the cord then divides into the musculo-spiral and circumflex nerves.

The **Anterior Thoracic Nerves** (Fig. 505, p. 760), two in number, supply the Pectoral muscles.

The *external* or superficial branch, the larger of the two, arises from the outer cord of the brachial plexus, through which its fibres may be traced to the fifth, sixth, and seventh cervical nerves. It passes inward across the axillary artery and vein, pierces the costo-coracoid membrane, and is distributed to the under surface of the Pectoralis major. It sends down a communicating filament to join the internal branch, which forms a loop round the inner side of the axillary artery.

The *internal* or deep branch arises from the inner cord, and through it from the eighth cervical and first dorsal. It passes upward between the axillary artery and vein (sometimes perforates the vein), and joins with the filament from the superficial branch. It then passes to the under surface of the Pectoralis minor muscle, where it divides into a number of branches which supply the muscle on its under surface. Some of the branches pass through the muscle; others wind round its upper border and pierce the costo-coracoid membrane to supply the Pectoralis major.

The **Subscapular Nerves**, three in number, supply the Subscapularis, Teres major, and Latissimus dorsi muscles. The fasciculi of which they are composed may be traced to the fifth, sixth, and seventh cervical nerve.

The *upper subscapular nerve*, the smallest, enters the upper part of the Subscapularis muscle.

The *lower subscapular nerve* enters the axillary border of the Subscapularis and terminates in the Teres major. The latter muscle is sometimes supplied by a separate branch.

The *middle* or *long subscapular*, the largest of the three, follows the course of the subscapular artery along the posterior wall of the axilla to the Latissimus dorsi, through which it may be traced as far as its lower border.

The **Circumflex Nerve** (Fig. 506, p. 762) supplies some of the muscles and the integument of the shoulder and the shoulder-joint. It arises from the posterior cord of the brachial plexus in common with the musculo-spiral nerve, and its fibres may be traced through the posterior cord to the fifth, sixth, and seventh cervical nerves. It is at first placed behind the axillary artery, between it and the Subscapularis muscle, and passes downward and outward to the lower border of that muscle. It then winds backward, in company with the posterior circumflex artery, through a quadrilateral space bounded above by the Teres minor, below by the Teres major, internally by the long head of the Triceps, and externally by the neck of the humerus, and divides into two branches.

The *upper branch* winds round the neck of the humerus, beneath the Deltoid, with the posterior circumflex vessels as far as the anterior border of that muscle, supplying it and giving off cutaneous branches which pierce the muscle and ramify in the integument covering its lower part.

The *lower branch* at its origin distributes filaments to the Teres minor and back part of the Deltoid muscles. Upon the filament to the former muscle a gangliform enlargement usually exists. The nerve then pierces the deep fascia, and supplies the integument over the lower two-thirds of the posterior surface of the Deltoid, as well as that covering the long head of the Triceps.

The circumflex nerve, before its division, gives off an articular filament which enters the shoulder-joint below the Subscapularis.

The **Musculo-cutaneous Nerve** (Fig. 505, p. 760) (*external cutaneous* or *perforans Casserii*) supplies some of the muscles of the arm and the integument of the forearm. It arises from the outer cord of the brachial plexus, receiving filaments from the fifth, sixth, and seventh cervical nerves opposite the lower border of the Pectoralis minor. It then perforates the Coraco-brachialis muscle, passes obliquely between the Biceps and Brachialis anticus to the outer side of the arm, and a little above the elbow winds round the outer border of the tendon of the Biceps, and, perforating the deep fascia, becomes cutaneous. This nerve in its course through the arm supplies the Coraco-brachialis, Biceps, and part of the Brachialis anticus muscles. It sends a small branch to the bone, which enters the nutrient foramen, with the accompanying artery and a filament, from the branch supplying the Brachialis anticus, to the elbow-joint.

The cutaneous portion of the nerve passes behind the median cephalic vein, and divides opposite the elbow-joint into an anterior and a posterior branch.

The *anterior branch* descends along the radial border of the forearm to the wrist, and supplies the integument over the outer half of the anterior surface. At the wrist-joint it is placed in front of the radial artery, and some filaments piercing the deep fascia accompany that vessel to the back of the wrist, supplying the carpus. The nerve then passes downward to the ball of the thumb, where it terminates in cutaneous filaments. It communicates with a branch from the radial nerve and the palmar cutaneous branch of the median.

The *posterior branch* passes downward along the back part of the radial side of the forearm to the wrist. It supplies the integument of the lower third of the forearm, communicating with the radial nerve and the external cutaneous branch of the musculo-spiral.

The **Internal Cutaneous Nerve** (Fig. 505) is one of the smallest branches of the brachial plexus. It arises from the inner cord in common with the ulnar and internal head of the median, and at its commencement is placed on the inner side of the brachial artery. It derives its fibres from the eighth cervical and first dorsal nerves. It passes down the inner side of the arm, pierces the deep fascia with the basilic vein about the middle of the limb, and, becoming cutaneous, divides into branches.

This nerve gives off near the axilla a cutaneous filament which pierces the fascia and supplies the integument covering the Biceps muscle, nearly as far as the elbow. This filament lies a little external to the common trunk, from which it arises.

The *anterior branch*, the larger of the two, passes usually in front of, but occasionally behind, the median basilic vein. It then descends on the anterior surface of the ulnar side of the forearm, distributing filaments to the integument as far as the wrist, and communicating with a cutaneous branch of the ulnar nerve.

[Fig. 501.

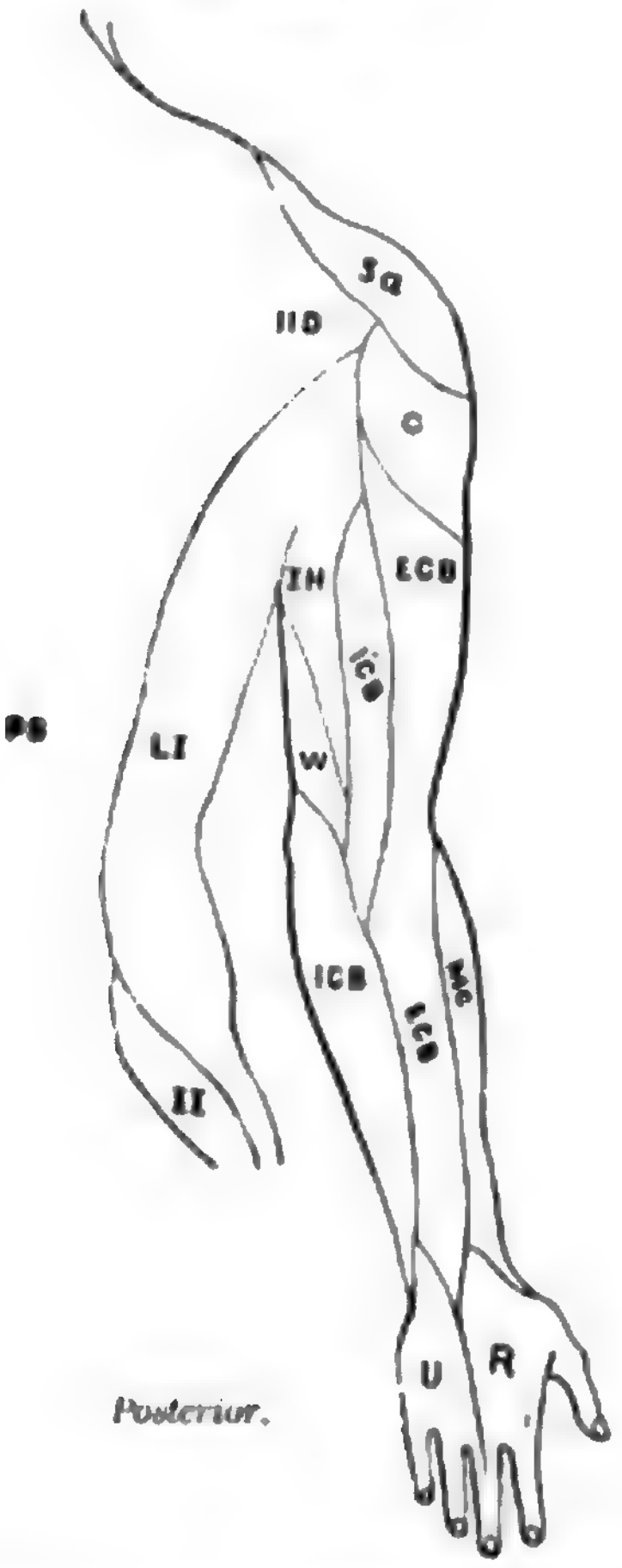

[Fig. 502.

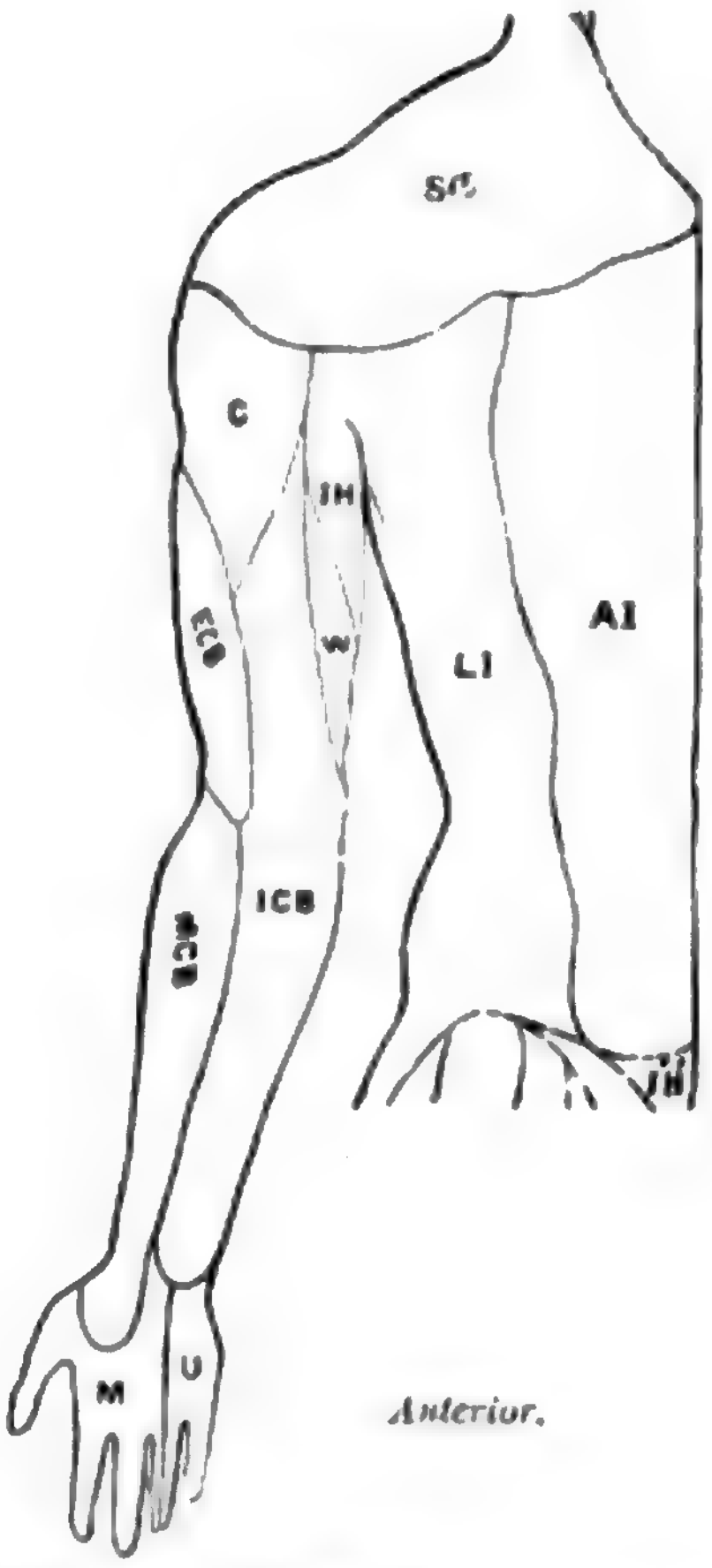

Cutaneous Nerves of the Trunk, right upper extremity.

Sa, Supraclavicular nerve.
IID, Second dorsal.
PS, Posterior branches of the spinal nerves.
LI, Lateral branches of the intercostal nerves.
AI, Anterior branches of the intercostal nerves.
II, Iliac branch of ilio-inguinal nerve.
I'H', Ilio-hypogastric nerve.
C, Circumflex nerve.
IH, Intercostal humeral.
W, Nerve of Wrisberg.
I'CB, Internal cutaneous branch of musculo-spiral nerve.
ECB, external cutaneous branch of musculo-spiral nerve.
ICB, Internal cutaneous nerve.
MC, Musculo-cutaneous nerve.
R, Radial nerve.
U, Ulnar nerve.
M, Median nerve (after Flower).]

The *posterior branch* passes obliquely downward on the inner side of the basilic vein, passes behind the internal condyle of the humerus to the back of the forearm, and descends on the posterior surface of its ulnar side as far as the wrist, distributing filaments to the integument. It communicates above the elbow with the lesser internal cutaneous, and above the wrist with the dorsal cutaneous branch of the ulnar nerve (Swan).

The **Lesser Internal Cutaneous Nerve** (*nerve of Wrisberg*) (Fig. 505) is distributed to the integument on the inner side of the arm. It is the smallest of the branches of the brachial plexus, and, arising from the inner cord with the internal cutaneous and ulnar nerves, receives its fibres from the eighth cervical and first dorsal nerves. It passes through the axillary space, at first lying behind, and then on the inner side of the axillary vein, and communicates with the intercosto-humeral nerve. It descends along the inner side of the brachial artery to the middle of the arm, where it pierces the deep fascia, and is distributed to the integument of the back part of the lower third of the arm, extending as far as the elbow, where some filaments are lost in the integument in front of the inner condyle, and others over the olecranon. It communicates with the posterior branch of the internal cutaneous nerve.

In some cases the nerve of Wrisberg and intercosto-humeral are connected by two or three filaments which form a plexus at the back part of the axilla. In other cases the intercosto-humeral is of large size, and takes the place of the nerve of Wrisberg, receiving merely a filament of communication from the brachial plexus which represents the latter nerve. In other cases this filament is wanting, the place of the nerve of Wrisberg being supplied entirely from the intercosto-humeral.

FIG. 503.

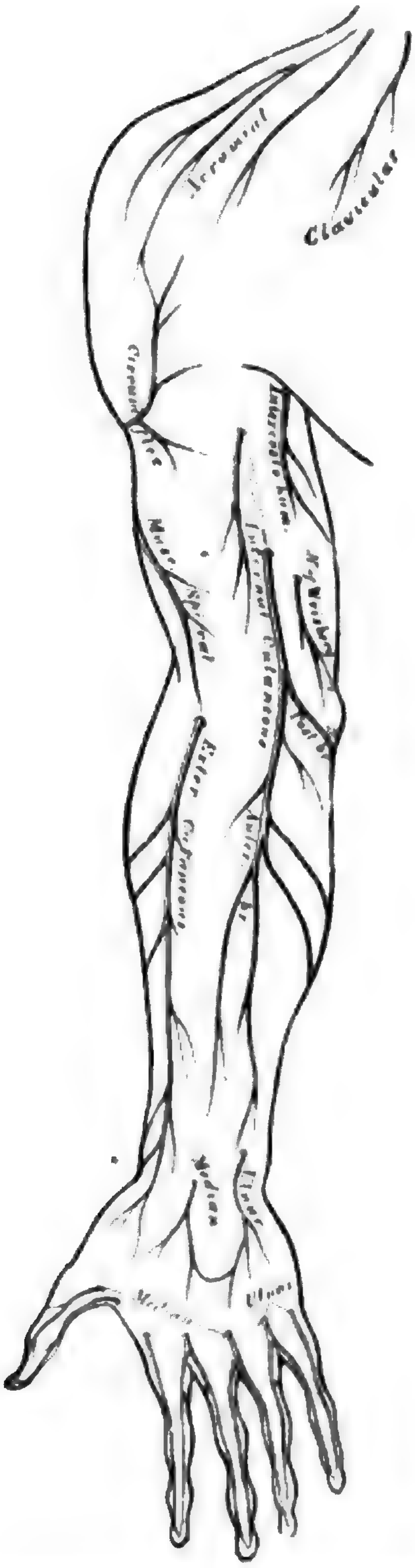
Acromial
Clavicular
Circumflex
Intercosto hum.
Musc. Spiral
Internal Cutaneous
N. of Wrisberg
Int. br.
Exter. Cutaneous
Anter. br.
Median
Ulnar
Median
Ulnar

Cutaneous Nerves of Right Upper Extremity, anterior view.

FIG. 504.

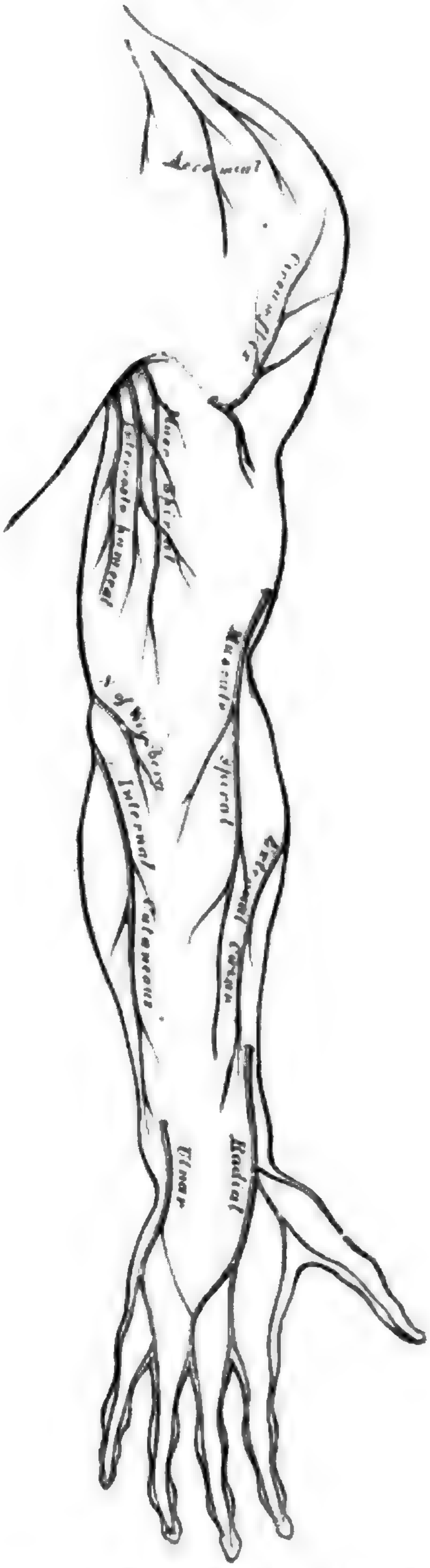
Acromial
Circumflex
Musc. Spiral
Intercosto humeral
N. of Wrisberg
Internal Cutaneous
Musculo Spiral
External Cutan.
Ulnar
Radial

Cutaneous Nerves of Right Upper Extremity, posterior view.

The Median Nerve (Fig. 505) has received its name from the course it takes along the middle of the arm and forearm to the hand, lying between the ulnar and the musculo-spiral and radial nerves. It arises by two roots—one from the outer and one from the inner cord of the brachial plexus; these embrace the lower part of the axillary artery, uniting either in front or on the outer side of that vessel. It receives filaments from all five cords of the brachial plexus. As it descends through the arm it lies at first on the outer side of the brachial artery, crosses that vessel in the middle of its course, usually in front, but occasionally behind it, and lies on its inner side to the bend of the elbow, where it is placed beneath the bicipital fascia, and is separated from the elbow-joint by the Brachialis anticus. *In the forearm* it passes between the two heads of the Pronator radii teres, and descends beneath the Flexor sublimis, lying on the Flexor profundus, to within two inches above the annular ligament, where it becomes more superficial, lying between the tendons of the Flexor sublimis and Flexor carpi radialis, beneath, or rather to the ulnar side of, the tendon of the Palmaris longus, covered by the integument and fascia. It then passes beneath the annular ligament into the hand. In its course through the forearm it is accompanied by a small artery. [The median nerve is accessible for operation at almost any part of its course.]

Branches.—No branches are given off from the median nerve in the arm. *In the forearm* its branches are muscular, anterior interosseous, and palmar cutaneous.

The *muscular branches* supply all the superficial muscles on the front of the forearm, except the Flexor carpi ulnaris. These branches are derived from the nerve near the elbow. The branch furnished to the Pronator radii teres often arises above the joint.

The *anterior interosseous* supplies the deep muscles on the front of the forearm, except the inner half of the Flexor profundus digitorum. It accompanies the anterior interosseous artery along the interosseous membrane, in the interval between the Flexor longus pollicis and Flexor profundus digitorum muscles, both of which it supplies, and terminates below in the Pronator quadratus.

The *palmar cutaneous branch* arises from the median nerve at the lower part of the forearm. It pierces the fascia above the annular ligament, and, descending over that ligament, divides into two branches, of which the *outer* supplies the skin over the ball of the thumb, and communicates with the anterior branch of the external cutaneous nerve, and the *inner* supplies the integument of the palm of the hand, communicating with the cutaneous branch of the ulnar.

In the palm of the hand the median nerve is covered by the integument and palmar fascia, and rests upon the tendons of the Flexor muscles. In this situation it becomes enlarged, somewhat flattened, of a reddish color, and divides into two branches. Of these, the *external* supplies a muscular branch to some of the muscles of the thumb and digital branches to the thumb and index finger, the *internal* supplying digital branches to the contiguous sides of the index and middle and of the middle and ring fingers.

The *branch to the muscles of the thumb* is a short nerve which subdivides to supply the Abductor, Opponens, and outer head of the Flexor brevis pollicis muscles, the remaining muscles of this group being supplied by the ulnar nerve.

The *digital branches* are five in number. The *first* and *second* pass along the borders of the thumb, the external branch communicating with branches of the radial nerve. The *third* passes along the radial side of the index finger, and supplies the first Lumbricalis muscle. The *fourth* subdivides to supply the adjacent sides of the index and middle fingers, and sends a branch to the second Lumbricalis muscle. The *fifth* supplies the adjacent sides of the middle and ring fingers, and communicates with a branch from the ulnar nerve.

Each digital nerve opposite the base of the first phalanx gives off a dorsal branch, which joins the dorsal digital nerve from the radial and runs along the side of the dorsum of the finger, to end in the integument over the last phalanx. At the end of the finger the digital nerve divides into a palmar and a dorsal branch, the former of which supplies the extremity of the finger, and the latter ramifies

Fig. 505.

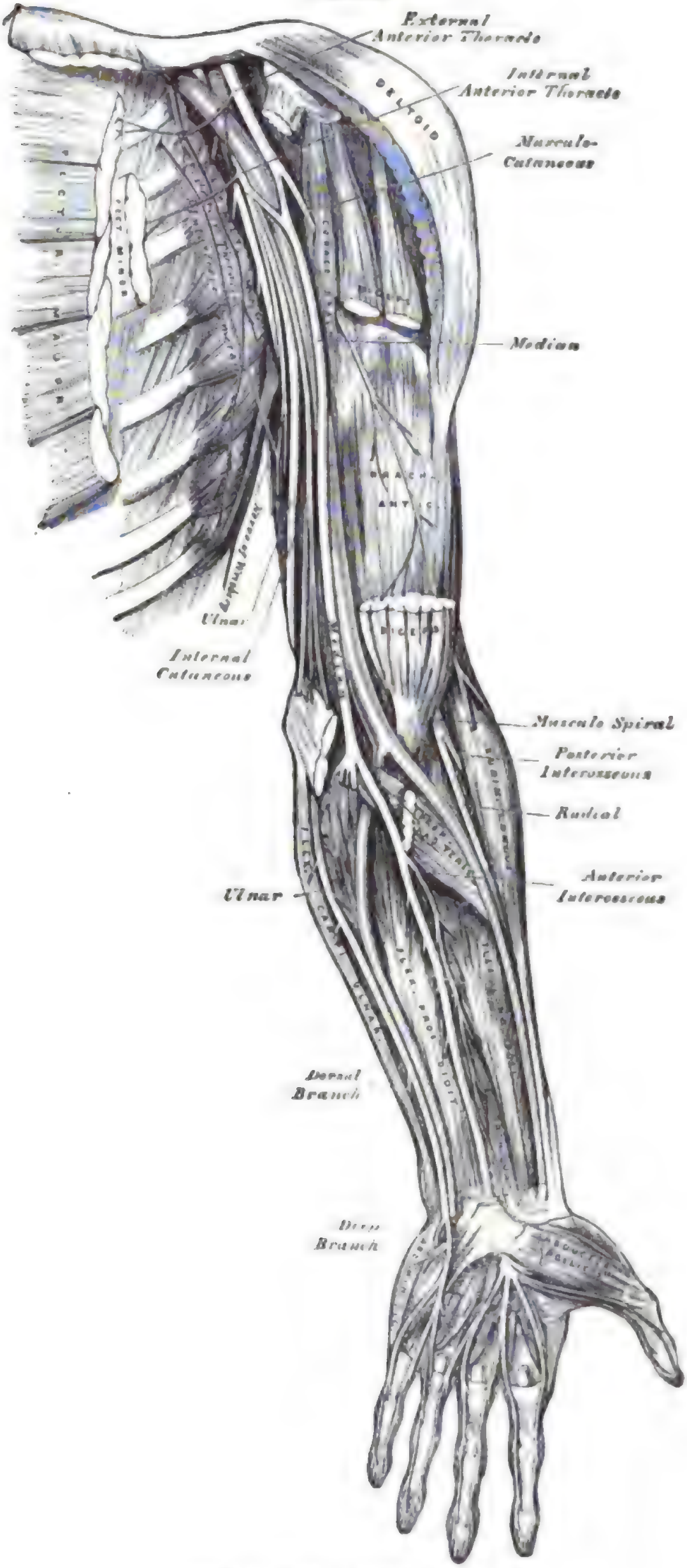
External
Anterior Thoracic
Internal
Anterior Thoracic
Musculo-
Cutaneous
DELTOID
PECT. MAJOR
PECT. MINOR
BRACH. ANT. C.
BICEPS
Median
Ulnar
Internal
Cutaneous
Musculo Spiral
Posterior
Interosseous
Radial
Anterior
Interosseous
Ulnar
FLEX. CARPI ULNAR
FLEX. PROF. DIGIT.
Dorsal
Branch
Deep
Branch

Nerves of the Left Upper Extremity

round and beneath the nail. The digital nerves, as they run along the fingers, are placed superficial to the digital arteries. [The careful observations of Weir Mitchell,[1] Létiévant, and others, after section of the nerves supplying the skin of the hand, have shown that the region supplied by the same nerve in different persons varies very much, and also that there must be peripheral anastomoses which can scarcely be dissected, but are well determined by such physiological experiments.]

The **Ulnar Nerve** (Fig. 505) is placed along the inner or ulnar side of the upper limb, and is distributed to the muscles and integument of the forearm and hand. It is smaller than the median, behind which it is placed, diverging from it in its course down the arm. It arises from the inner cord of the brachial plexus, in common with the inner head of the median and the internal cutaneous nerve, and derives its fibres from the eighth cervical and first dorsal nerves. At its commencement it lies at the inner side of the axillary artery, and holds the same relation with the brachial artery to the middle of the arm. From this point it runs obliquely across the internal head of the Triceps, pierces the internal intermuscular septum, and descends to the groove between the internal condyle and the olecranon, accompanied by the inferior profunda artery. [In resection of the elbow great care must be taken not to wound the nerve in this situation.] *At the elbow* it rests upon the back of the inner condyle, and passes into the forearm between the two heads of the Flexor carpi ulnaris. *In the forearm* it descends in a perfectly straight course along its ulnar side, lying upon the Flexor profundus digitorum, its upper half being covered by the Flexor carpi ulnaris, its lower half lying on the outer side of the muscle, covered by the integument and fascia. The ulnar artery, in the upper third of its course, is separated from the ulnar nerve by a considerable interval, but in the rest of its extent the nerve lies to its inner side. *At the wrist* the ulnar nerve crosses the annular ligament on the outer side of the pisiform bone a little behind the ulnar artery, and immediately beyond this bone divides into two branches, superficial and deep palmar. [The ulnar nerve is accessible for operation in nearly its whole length, except just above and below the elbow.]

The branches of the ulnar nerve are—

In the forearm
- Articular (elbow).
- Muscular.
- Cutaneous.
- Dorsal cutaneous.
- Articular (wrist).

In the hand
- Superficial palmar.
- Deep palmar.

The *articular branches* distributed to the elbow-joint consist of several small filaments. They arise from the nerve as it lies in the groove between the inner condyle and olecranon.

The *muscular branches* are two in number—one supplying the Flexor carpi ulnaris, the other the inner half of the Flexor profundus digitorum. They arise from the trunk of the nerve near the elbow.

The *cutaneous branch* arises from the ulnar nerve about the middle of the forearm, and divides into two branches.

The one branch (frequently absent) pierces the deep fascia near the wrist, and is distributed to the integument, communicating with a branch of the internal cutaneous nerve.

The second branch (*palmar cutaneous*) lies on the ulnar artery, which it accompanies to the hand, some filaments entwining round the vessel; it ends in the integument of the palm, communicating with branches of the median nerve.

The *dorsal cutaneous branch* arises about two inches above the wrist; it passes backward beneath the Flexor carpi ulnaris, perforates the deep fascia, and, running along the ulnar side of the back of the wrist and hand, supplies the inner side of the little finger and the adjoining sides of the little and ring fingers; it communi-

---

[[1] See especially the *Trans. Coll. Phys. Phila.*, 1876, and *Brain*, Oct., 1878.]

cates with the posterior branch of the internal cutaneous nerve, and sends a communicating filament to that branch of the radial nerve which supplies the adjoining sides of the middle and ring fingers.

The *articular filaments to the wrist* are also supplied by the ulnar nerve.

FIG. 506.

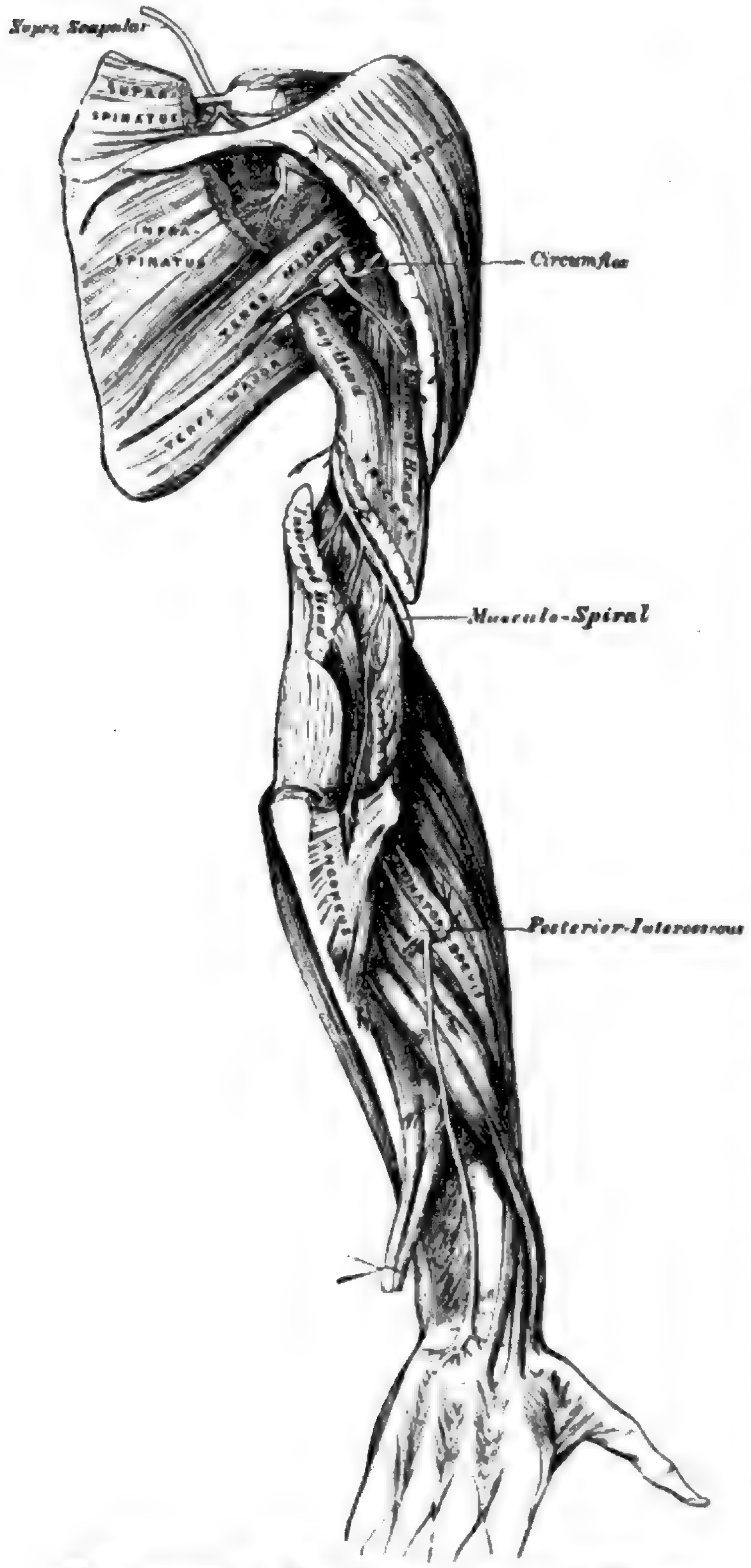

The Suprascapular, Circumflex, and Musculo-spiral Nerves.

The *superficial palmar branch* supplies the Palmaris brevis and the integument on the inner side of the hand, and terminates in two digital branches, which are distributed, one to the ulnar side of the little finger, the other to the adjoining sides of the little and ring fingers, the latter communicating with a branch from the median. The digital branches are distributed to the fingers in the same manner as the digital branches of the median already described.

The *deep palmar branch* passes between the Abductor and Flexor brevis minimi digiti muscles, and follows the course of the deep palmar arch beneath the flexor tendons. At its origin it supplies the muscles of the little finger. As it crosses the deep part of the hand it sends two branches to each interosseous space, one for the Dorsal and one for the Palmar interosseous muscle, the branches to the second and third Palmar interossei supplying filaments to the two inner Lumbricales muscles. At its termination between the thumb and index finger it supplies the Adductor pollicis and the inner head of the Flexor brevis pollicis.

The **Musculo-spiral Nerve** (Fig. 506), the largest branch of the brachial plexus, supplies the muscles of the back part of the arm and forearm and the integument of the same parts, as well as that of the back of the hand. It arises from the posterior cord of the brachial plexus by a common trunk with the circumflex nerve, and is afterward joined by the posterior division of the trunk, formed by the junction of the eighth cervical and first dorsal nerves. It receives filaments from all the five spinal nerves forming the brachial plexus. At its commencement it is placed behind the axillary and upper part of the brachial arteries, passing down in front of the tendons of the

Latissimus dorsi and Teres major. It winds round the humerus in the musculo-spiral groove with the superior profunda artery, passing from the inner side of the bone, between the internal and external heads of the Triceps muscle. It pierces the external intermuscular septum, and descends between the Brachialis anticus and Supinator longus to the front of the external condyle, where it divides into the radial and posterior interosseous nerves. [In its course between the Brachialis anticus and the Supinator longus it is accessible for operation.]

The branches of the musculo-spiral nerve are—

Muscular.
Radial.
Cutaneous.
Posterior interosseous.

The *muscular branches* are divided into internal, posterior, and external: they supply the Triceps, Anconeus, Supinator longus, Extensor carpi radialis longior, and Brachialis anticus. These branches are derived from the nerve at the inner side, back part, and outer side of the arm.

The internal muscular branches supply the inner and middle heads of the Triceps muscle. That to the inner head of the Triceps is a long, slender filament which lies close to the ulnar nerve, as far as the lower third of the arm, and is often intimately connected with it.

The posterior muscular branch, of large size, arises from the nerve in the groove between the Triceps and the humerus. It divides into branches which supply the outer head of the Triceps and Anconeus muscles. The branch for the latter muscle is a long, slender filament which descends in the substance of the Triceps to the Anconeus.

The external muscular branches supply the Supinator longus, Extensor carpi radialis longior, and usually the outer part of the Brachialis anticus.

The *cutaneous branches* are three in number, one internal and two external.

The internal cutaneous branch arises in the axillary space with the inner muscular branch. It is of small size, and passes through the axilla to the inner side of the arm, supplying the integument on its posterior aspect nearly as far as the olecranon. In its course it crosses beneath the intercosto-humeral, with which it communicates.

The two external cutaneous branches perforate the outer head of the Triceps at its attachment to the humerus. The upper and smaller one follows the course of the cephalic vein to the front of the elbow, supplying the integument of the lower half of the upper arm on its anterior aspect. The lower branch pierces the deep fascia below the insertion of the Deltoid, and passes down along the outer side of the arm and elbow, and along the back part of the radial side of the forearm to the wrist, supplying the integument in its course, and joining, near its termination, with the posterior branch of the external cutaneous nerve.

The **Radial Nerve** passes along the front of the radial side of the forearm to the commencement of its lower third. It lies at first a little to the outer side of the radial artery, concealed beneath the Supinator longus. In the middle third of the forearm it lies beneath the same muscle, in close relation with the outer side of the artery. It quits the artery about three inches above the wrist, passes beneath the tendon of the Supinator longus, and, piercing the deep fascia at the outer border of the forearm, divides into two branches.

The external branch, the smaller of the two, supplies the integument of the radial side and ball of the thumb, joining with the anterior branch of the external cutaneous nerve.

The internal branch communicates above the wrist with the posterior branch from the external cutaneous, and on the back of the hand forms an arch with the dorsal cutaneous branch of the ulnar nerve. It then divides into three digital nerves, which are distributed as follows: the first supplies the ulnar side of the thumb and the radial side of the index finger; the second, the adjoining sides of the index and middle fingers; and the third, the adjacent borders of the middle and ring fingers.[1] The latter nerve communicates with a filament from the dorsal branch of the ulnar nerve.

The **Posterior Interosseous Nerve** winds to the back of the forearm through the fibres of the Supinator brevis, and passes down between the superficial and deep layers of muscles to the middle of the forearm. Considerably diminished in size, it descends on the interosseous membrane, beneath the Extensor secundi internodii pollicis, to the back of the carpus, where it presents a gangliform enlargement from which filaments are distributed to the ligaments and articulations of the carpus. It supplies all the muscles of the radial and posterior brachial regions, excepting the Anconeus, Supinator longus, and Extensor carpi radialis longior.

DORSAL NERVES (Fig. 507).

The **Dorsal Nerves** are twelve in number on each side. The first appears between the first and second dorsal vertebræ, and the last between the last dorsal and first lumbar.

The *roots of origin* of the dorsal nerves are of small size and vary but slightly from the second to the last. Both roots are very slender, the posterior roots only slightly exceeding the anterior in thickness. They gradually increase in length from above downward, and pass down in contact with the spinal cord, for a distance equal to a height of at least two vertebræ in the lower part of the dorsal region, before they emerge from the spinal canal. They then join in the intervertebral foramen, and at their exit divide into two primary divisions—a posterior (dorsal) and an anterior (intercostal).

The first and last dorsal nerves are peculiar in some respects. (See pp. 766, 767.)

POSTERIOR DIVISIONS OF THE DORSAL NERVES.

The **posterior divisions of the dorsal nerves**, which are smaller than the anterior, pass backward between the transverse processes, and divide into external and internal branches.

The *external branches* increase in size from above downward. They pass through the Longissimus dorsi to the cellular interval between it and the Sacrolumbalis, and supply those muscles, as well as their continuations upward to the head and the Levatores costarum; the five or six lower nerves also give off cutaneous filaments.

The *internal branches* of the six upper nerves pass inward to the interval between the Multifidus spinæ and Semispinalis dorsi muscles, which they supply, and then, piercing the origin of the Rhomboidei and Trapezius, become cutaneous by the side of the spinous processes. The internal branches of the six lower nerves are distributed to the Multifidus spinæ without giving off any cutaneous filaments.

The *cutaneous branches* of the dorsal nerves are twelve in number, the six upper being derived from the internal branches, and the six lower from the external branches. The former pierce the Rhomboid and Trapezius muscles close to the spinous processes and ramify in the integument. They are frequently furnished with gangliform enlargements. The six lower cutaneous branches pierce the Serratus posticus inferior and Latissimus dorsi in a line with the angles of the ribs.

ANTERIOR DIVISIONS OF THE DORSAL NERVES.

The **anterior divisions of the dorsal nerves** (*intercostal nerves*) are twelve in number on each side. They are, for the most part, distributed to the parietes of the

---

[1] According to Hutchinson, the digital nerve to the thumb reaches only as high as the root of the nail; on the forefinger, as high as the middle of the second phalanx; on the middle and ring fingers, not higher than the first phalangeal joint (*London Hosp. Gaz.*, vol. iii. p. 319).

FIG. 507.

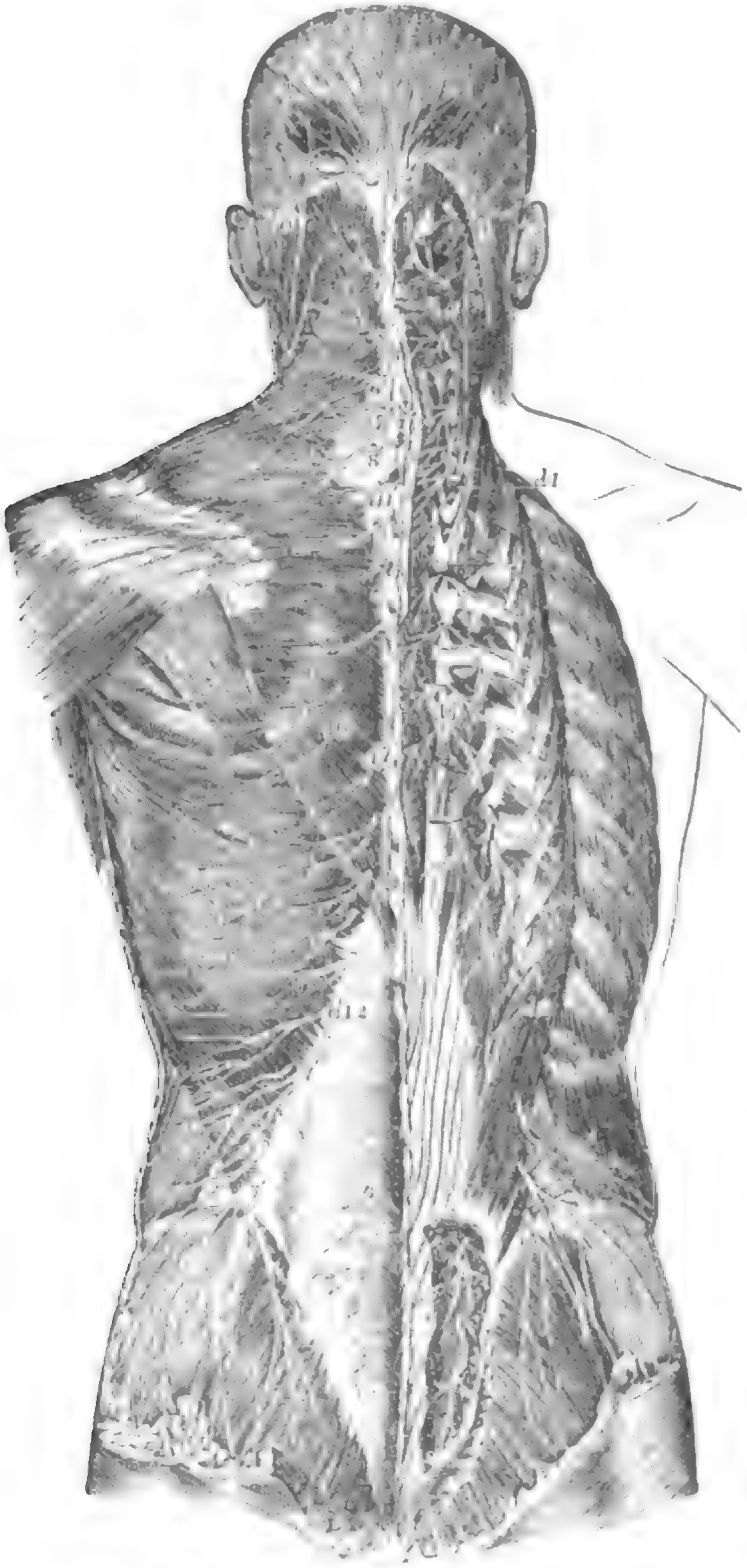

Superficial and Deep Distribution of the Posterior Branches of the Spinal Nerves (after Hirschfeld and Leveillé). On the left side the cutaneous branches are represented lying on the superficial layer of muscles. On the right side the superficial muscles have been removed, the Splenius capitis and Complexus divided in the neck, and the Erector spinæ divided and partly removed in the back, so as to expose the posterior divisions of the spinal nerves near their origin: *a. a*, lesser occipital nerve from the cervical plexus; 1, external muscular branches of the first cervical nerve, and union by a loop with the second; 2, placed on the Rectus capitis posticus major muscle, marks the great occipital nerve, passing round the short muscles and piercing the Complexus: the external branch is seen to the outside; 3, external branch from the posterior division of the third nerve; 3', its internal branch, sometimes called the third occipital; 4' to 8', the internal branches of the several corresponding nerves on the left side: the external branches of these nerves, proceeding to muscles, are displayed on the right side; *d* 1 to *d* 6, and thence to *d* 12, external muscular branches of the posterior divisions of the twelve dorsal nerves on the right side; *d* 1 to *d* 6', the internal cutaneous branches of the six upper dorsal nerves on the left side; *d* 7' to *d* 12', cutaneous twigs from the external branches of the six lower dorsal nerves; *l*, *l*, external branches from the posterior divisions of several lumbar nerves on the right side, piercing the muscles, the lower descending over the gluteal region; *l'*, *l'*, the same, more superficially, on the left side; *s*, *s*, the issue and union by loops of the posterior divisions of four sacral nerves on the right side; *s'*, *s'*, some of those distributed to the skin on the left side.

thorax and abdomen, separately from each other, without being joined in a plexus: in which respect they differ from the other spinal nerves. Each nerve is connected with the adjoining ganglia of the sympathetic by one or two filaments. The intercostal nerves may be divided into two sets, from the difference they present in their distribution. The six upper, with the exception of the first and the intercosto-humeral branch of the second, are limited in their distribution to the parietes of the chest. The six lower supply the parietes of the chest and abdomen, the last one sending a cutaneous filament to the hip.

The First Dorsal Nerve.—The anterior division of the first dorsal nerve divides into two branches: one, the larger, leaves the thorax in front of the neck of the first rib and enters into the formation of the brachial plexus; the other and smaller branch runs along the first intercostal space, forming the *first intercostal nerve*, and terminates on the front of the chest by forming the first anterior cutaneous nerve of the thorax. The first intercostal nerve gives off no lateral cutaneous branch.

The Upper Six Dorsal Nerves.—The anterior divisions of the second, third, fourth, fifth, and sixth dorsal nerves and the small branch from the first dorsal are confined to the parietes of the thorax, and are named *upper* or *pectoral intercostal nerves*. They pass forward in the intercostal spaces with the intercostal vessels, being situated below them. At the back of the chest they lie between the pleura and the External intercostal muscle, but are soon placed between the two planes of intercostal muscles as far as the middle of the rib. They then enter the substance of the Internal intercostal muscles, and running amidst their fibres as far as the costal cartilages, they gain the inner surface of the muscles and lie between them and the pleura. Near the sternum they cross the internal mammary artery and Triangularis sterni, pierce the Internal intercostal and Pectoralis major muscles, and supply the integument of the mamma and front of the chest, forming the anterior cutaneous nerves of the thorax, the branch from the second nerve becoming joined with the supraclavicular nerves of the cervical plexus.

Branches.—Numerous slender muscular filaments supply the Intercostal and Triangularis sterni muscles. Some of these branches at the front of the chest cross the costal cartilages from one to another intercostal space.

Lateral Cutaneous Nerves.—These are derived from the intercostal nerves, midway between the vertebræ and sternum; they pierce the External intercostal and Serratus magnus muscles and divide into two branches, anterior and posterior.

The *anterior branches* are reflected forward to the side and the fore part of the chest, supplying the integument of the chest and mamma and the upper digitations of the External oblique.

The *posterior branches* are reflected backward to supply the integument over the scapula and over the Latissimus dorsi.

The first intercostal nerve has no lateral cutaneous branch. The lateral cutaneous branch of the second intercostal nerve is of large size, and does not divide like the other nerves into an anterior and posterior branch. It is named, from its origin and distribution, the *intercosto-humeral nerve* (Fig. 505, p. 760). It pierces the External intercostal muscle, crosses the axilla to the inner side of the arm, and joins with a filament from the nerve of Wrisberg. It then pierces the fascia, and supplies the skin of the upper half of the inner and back part of the arm, communicating with the internal cutaneous branch of the musculo-spiral nerve. The size of this nerve is in inverse proportion to the size of the other cutaneous nerves, especially the nerve of Wrisberg. A second intercosto-humeral nerve is frequently given off from the third intercostal. It supplies filaments to the armpit and inner side of the arm.

The Lower Six Dorsal Nerves.—The anterior divisions of the seventh, eighth, ninth, tenth, and eleventh dorsal nerves are continued anteriorly from the intercostal spaces into the abdominal wall, and the twelfth dorsal is confined throughout its whole course in the abdominal wall, since it is placed below the last rib; hence these nerves are named *lower* or *abdominal* intercostal nerves. They have (with the exception of the last) the same arrangement as the upper ones as far as the anterior extremities of the intercostal spaces, where they pass behind the costal cartilages and between the Internal oblique and Transversalis muscles to the sheath of the Rectus, which they perforate. They supply the Rectus muscle, and terminate in branches which become subcutaneous near the linea alba. These branches, which are named the anterior cutaneous nerves of the abdomen, supply the integument of the front of the belly; they are directed outward as far as the lateral cutaneous nerves. The lower intercostal nerves supply the intercostal and abdominal muscles, and about the middle of their course give off lateral cutaneous branches, which pierce the External intercostal and External oblique muscles and are distributed to the integument of the abdomen, the anterior branches passing nearly as far forward as the margin of the Rectus, the posterior branches passing to supply the skin over the Latissimus dorsi, where they join the dorsal cutaneous nerves.

The **last dorsal** is larger than the other dorsal nerves. Its anterior division runs along the lower border of the last rib in front of the Quadratus lumborum, perforates the aponeurosis of the Transversalis, and passes forward between it and the Internal oblique, to be distributed in the same manner as the preceding nerves. It communicates with the ilio-hypogastric branch of the lumbar plexus, and is frequently connected with the first lumbar nerve by a slender branch, the *dorsi-lumbar nerve*, which descends in the substance of the Quadratus lumborum.

The *lateral cutaneous branch* of the last dorsal is remarkable for its large size; it perforates the Internal and External oblique muscles, passes downward over the crest of the ilium in front of the iliac branch of the ilio-hypogastric (Fig. 515, p. 779), and is distributed to the integument of the front of the hip, some of its filaments extending as low down as the trochanter major. It does not divide into an anterior and posterior branch like the others.

LUMBAR NERVES.

The **lumbar** nerves are five in number on each side: the first appears between the first and second lumbar vertebræ, and the last between the last lumbar and the base of the sacrum.

The **roots** of the lumbar nerves are the largest and their filaments the most numerous of all the spinal nerves, and they are closely aggregated together upon the lower end of the cord. The anterior roots are the smaller, but there is not the same disproportion between them and the posterior roots as in the cervical nerves. The roots of these nerves have a vertical direction and are of considerable length, more especially the lower ones, since the spinal cord does not extend beyond the first lumbar vertebra. The roots become joined in the intervertebral foramina, and the nerves, so formed, divide at their exit into two divisions, anterior and posterior.

POSTERIOR DIVISIONS OF THE LUMBAR NERVES.

The **posterior divisions** of the lumbar nerves (Fig. 507, p. 765) diminish in size from above downward; they pass backward between the transverse processes and divide into external and internal branches.

The external branches supply the Erector spinæ and Intertransverse muscles. From the three upper branches cutaneous nerves are derived which pierce the aponeurosis of the Latissimus dorsi muscle and descend over the back part of the crest of the ilium, to be distributed to the integument of the gluteal region, some of the filaments passing as far as the trochanter major.

The internal branches, the smaller, pass inward close to the articular processes of the vertebræ, and supply the Multifidus spinæ and Interspinales muscles.

ANTERIOR DIVISIONS OF THE LUMBAR NERVES.

The **anterior divisions** of the lumbar nerves increase in size from above downward. At their origin they communicate with the lumbar ganglia of the sympathetic by long slender filaments, which accompany the lumbar arteries round the sides of the bodies of the vertebræ beneath the Psoas muscle. The nerves pass obliquely outward behind the Psoas magnus or between its fasciculi, distributing filaments to it and the Quadratus lumborum. The anterior divisions of the four upper nerves are connected together in this situation by anastomotic loops, and form the *lumbar plexus.* The anterior division of the fifth lumbar, joined with a branch from the fourth, descends across the base of the sacrum to join the anterior division of the first sacral nerve and assist in the formation of the sacral plexus. The cord resulting from the union of the fifth lumbar and the branch from the fourth is called the *lumbo-sacral nerve.*

LUMBAR PLEXUS.

The **lumbar plexus** is formed by the loops of communication between the anterior divisions of the four upper lumbar nerves. The plexus is narrow above, and often connected with the last dorsal by a slender branch, the *dorsi-lumbar nerve;* it is broad below, where it is joined to the sacral plexus by the lumbo-sacral cord. It is situated in the substance of the Psoas muscle near its posterior part, in front of the transverse processes of the lumbar vertebræ.

The mode in which the plexus is formed is the following: The first lumbar nerve receives a branch from the last dorsal, and gives off the ilio-hypogastric and ilio-inguinal, and a communicating branch which passes down to the second lumbar and forms a part of the genito-crural nerve. The second gives off the remainder of the genito-crural and a descending branch to communicate with the third; from it the greater part of the external cutaneous is given off. The fibres of this communicating branch are prolonged partly into the anterior crural and partly into the obturator nerve.

Fig. 508.

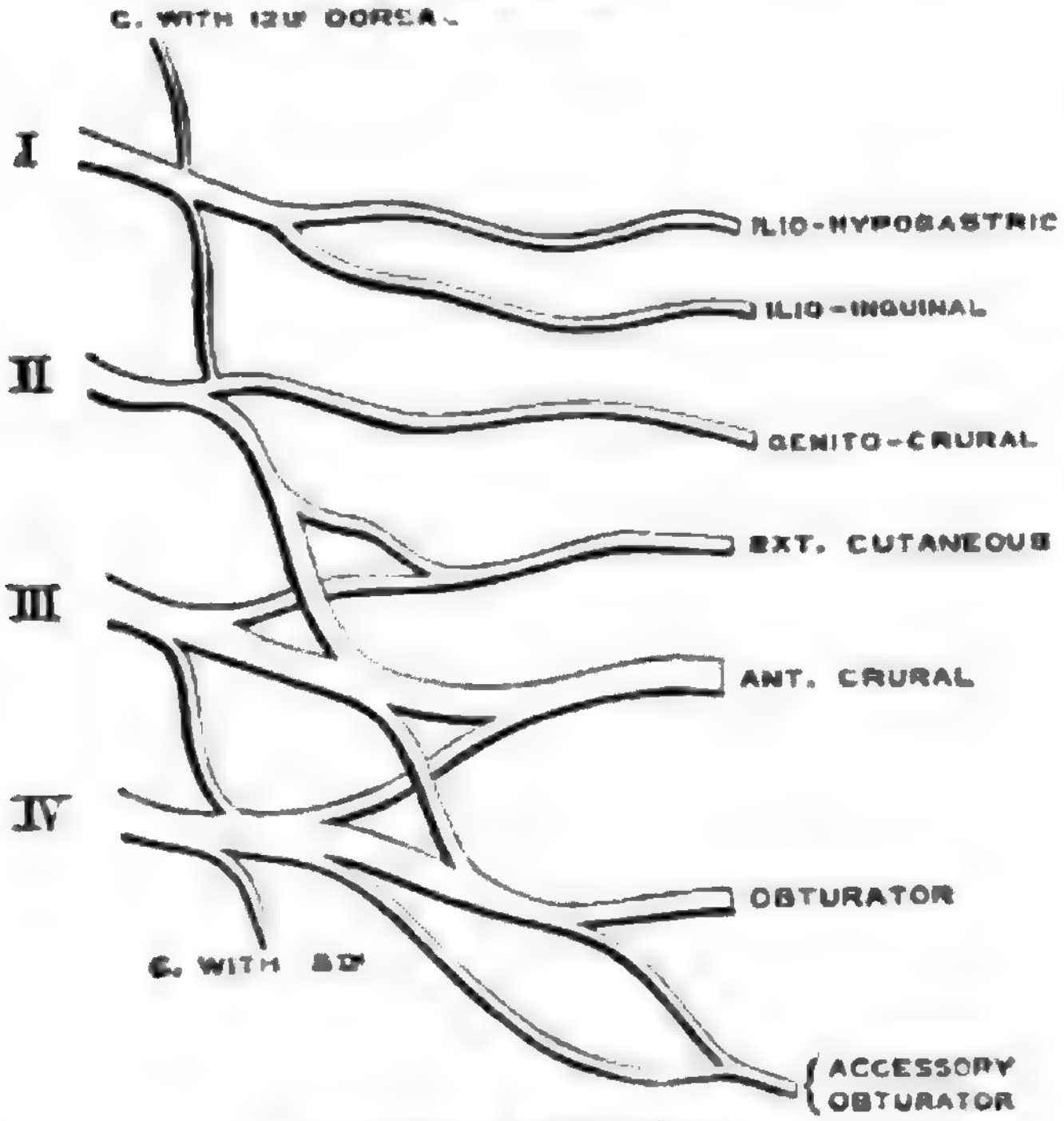

Plan of the Lumbar Plexus.

The third lumbar nerve gives off a small filament to the external cutaneous and divides into two large branches, which assist in forming the anterior crural and obturator nerves. When the accessory obturator exists some of its fibres are derived from this third nerve. It also gives off a communicating branch to the fourth. The fourth nerve gives a communicating filament to the fifth, and divides into two branches, which complete the anterior crural and obturator. Sometimes it also furnishes part of the accessory obturator.

From this arrangement it follows that the ilio-hypogastric and ilio-inguinal are derived entirely from the first lumbar nerve; the genito-crural partly from the first, but principally from the second nerve; the external cutaneous for the most part from the second, but receiving a small filament from the third; the anterior crural and obturator by fibres derived from the second, third, and fourth; and the accessory obturator, when it exists, from the third and fourth, probably receiving also some fibres from the second through its communicating branch.

The branches of the lumbar plexus are the

Ilio-hypogastric.
Ilio-inguinal.
Genito-crural.
External cutaneous.
Obturator.
Accessory obturator.
Anterior crural.

The **Ilio-hypogastric Nerve** (*superior musculo-cutaneous*) arises from the first lumbar nerve. It emerges from the outer border of the Psoas muscle at its upper part, and crosses obliquely in front of the Quadratus lumborum to the crest of the ilium. It then perforates the Transversalis muscle at its back part, and divides between it and the Internal oblique into two branches, iliac and hypogastric.

Fig. 509.

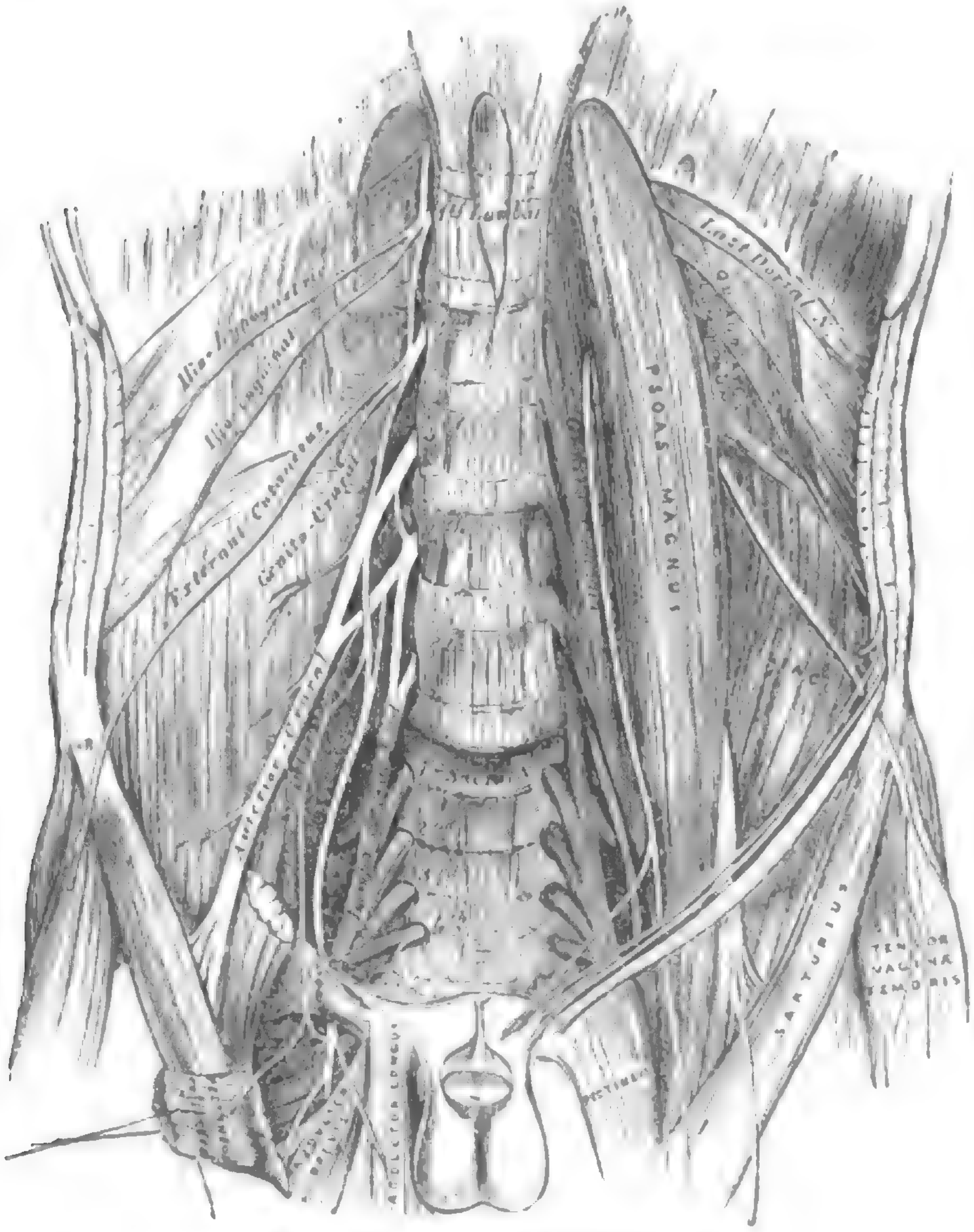
III Lumbar
Ilio-hypogastric
Ilio-inguinal
External Cutaneous
Genito-Crural
Anterior Crural
Last Dorsal N.
PSOAS MAGNUS
SARTORIUS
TENSOR VAGINAE FEMORIS
ADDUCTOR LONGUS

The Lumbar Plexus and its Branches.[1]

The *iliac branch* pierces the Internal and External oblique muscles immediately above the crest of the ilium, and is distributed to the integument of the gluteal region, behind the lateral cutaneous branch of the last dorsal nerve (Fig. 515, p. 779). The size of this nerve bears an inverse proportion to that of the cutaneous branch of the last dorsal nerve.

The *hypogastric branch* (Fig. 510) continues onward between the Internal oblique and Transversalis muscles. It then pierces the Internal oblique, and near the middle line perforates the aponeurosis of the External oblique above the external abdominal ring, and is distributed to the integument covering the hypogastric region.

---

[1] The arrangement of the lumbar plexus on the right side in this woodcut is not strictly correct. (See the plan on preceding page.)

The ilio-hypogastric nerve communicates with the last dorsal and ilio-inguinal nerves.

The **Ilio-inguinal Nerve** (*inferior musculo-cutaneous*), smaller than the preceding, arises with it from the first lumbar nerve. It emerges from the outer border of the Psoas just below the ilio-hypogastric, and, passing obliquely across the Quadratus lumborum and Iliacus muscles, perforates the Transversalis near the fore part of the crest of the ilium, and communicates with the ilio-hypogastric nerve between that muscle and the Internal oblique. The nerve then pierces the Internal oblique, distributing filaments to it, and, accompanying the spermatic cord through the inguinal canal, it escapes at the external abdominal ring, and is distributed to the integument of the upper and inner part of the thigh, and to the scrotum in the male and to the labium in the female. The size of this nerve is in inverse proportion to that of the ilio-hypogastric. Occasionally it is very small, and ends by joining the ilio-hypogastric; in such cases a branch from the ilio-hypogastric takes the place of the ilio-inguinal, or the latter nerve may be altogether absent.

The **Genito-crural Nerve** arises from the second lumbar, and by a few fibres from the cord of communication between it and the first. It passes obliquely through the substance of the Psoas, descends on its surface to near Poupart's ligament, and divides into a genital and crural branch.

The *genital branch* descends on the external iliac artery, sending a few filaments round that vessel; it then pierces the fascia transversalis or passes through the internal abdominal ring, descends along the back part of the spermatic cord to the scrotum, and supplies, in the male, the Cremaster muscle; in the female it accompanies the round ligament, and is lost upon it.

The *crural branch* passes along the inner margin of the Psoas muscle, beneath Poupart's ligament, into the thigh, entering the sheath of the femoral vessels and lying superficial and a little external to the femoral artery. It pierces the anterior layer of the sheath of the vessels, and, becoming superficial by passing through the fascia lata, it supplies the skin of the anterior aspect of the thigh as far as midway between the pelvis and knee. On the front of the thigh it communicates with the outer branch of the middle cutaneous nerve, derived from the anterior crural.

A few filaments from this nerve may be traced on to the femoral artery; they are derived from the nerve as it passes beneath Poupart's ligament.

The **External Cutaneous Nerve** arises from the second and third lumbar nerves. It emerges from the outer border of the Psoas muscle about its middle, and crosses the Iliacus muscle obliquely to the notch immediately beneath the anterior superior spine of the ilium, where it passes under Poupart's ligament into the thigh and divides into two branches of nearly equal size.

The *anterior branch* descends in an aponeurotic canal formed in the fascia lata, becomes superficial about four inches below Poupart's ligament, and divides into branches which are distributed to the integument along the anterior and outer part of the thigh as far down as the knee. This nerve occasionally communicates with the long saphenous nerve in front of the knee-joint.

The *posterior branch* pierces the fascia lata, and subdivides into branches which pass backward across the outer and posterior surface of the thigh, supplying the integument from the crest of the ilium as far as the middle of the thigh.

The **Obturator Nerve** supplies the Obturator externus and Adductor muscles of the thigh, the articulations of the hip and knee, and occasionally the integument of the thigh and leg. It arises by two branches: one from the third, the other from the fourth lumbar nerve, receiving also some fibres from the second. It descends through the inner fibres of the Psoas muscle, and emerges from its inner border near the brim of the pelvis; it then runs along the lateral wall of the pelvis, above the obturator vessels, to the upper part of the obturator foramen, where it enters the thigh, and divides into an anterior and a posterior branch separated by the Adductor brevis muscle.

The *anterior branch* (Fig. 511) passes down in front of the Adductor brevis, being covered by the Pectineus and Adductor longus, and at the lower border of

FIG. 510.

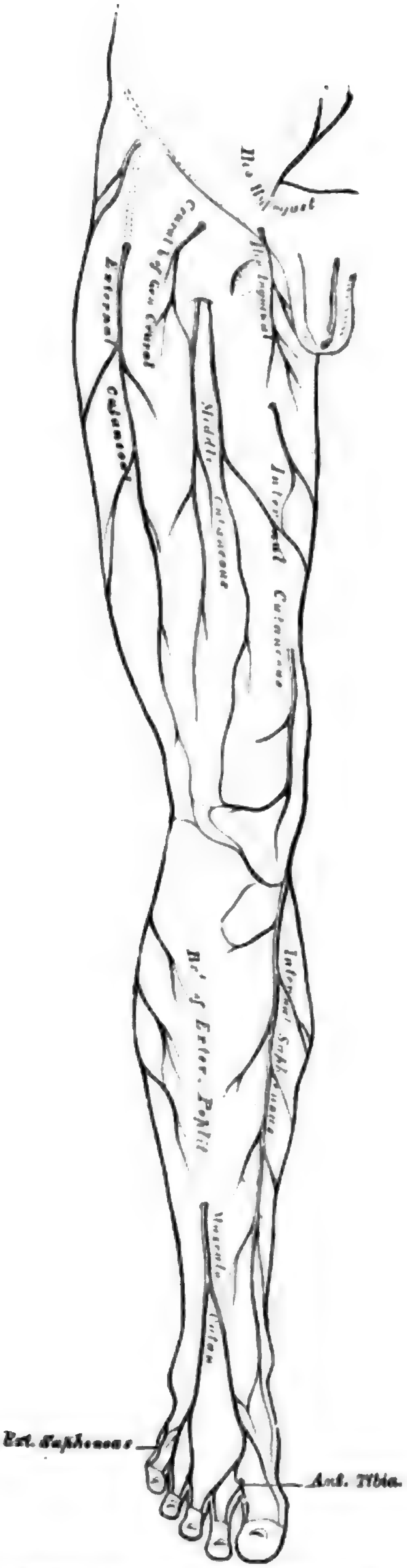
Ilio Hypogast
Crural b. of Gen. Crural
Ilio Inguinal
External Cutaneous
Middle Cutaneous
Internal Cutaneous
Br. of Exter. Poplit
Internal Saphenous
Musculo Cutan
Ext. Saphenous
Ant. Tibia.

Cutaneous Nerves of Lower Extremity, front view.

FIG. 511.

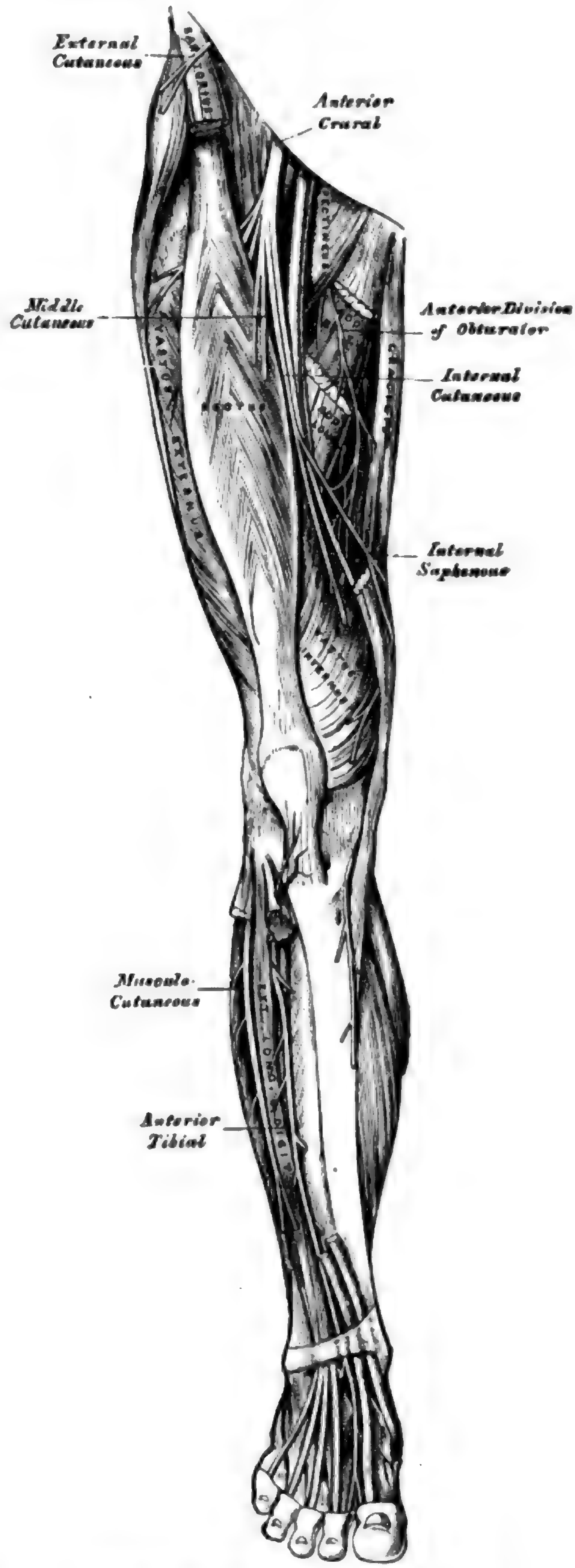
External Cutaneous
Anterior Crural
Middle Cutaneous
Anterior Division of Obturator
Internal Cutaneous
Internal Saphenous
Musculo-Cutaneous
Anterior Tibial

Nerves of the Lower Extremity, front view.

the latter muscle communicates with the internal cutaneous and internal saphenous nerves, forming a kind of plexus. It then descends upon the femoral artery, upon which it is finally distributed.

This nerve near the obturator foramen gives off an articular branch to the hip-joint. Behind the Pectineus it distributes muscular branches to the Adductor longus and Gracilis, and occasionally to the Adductor brevis and Pectineus, and receives a communicating branch from the accessory obturator nerve.

[Fig. 512.

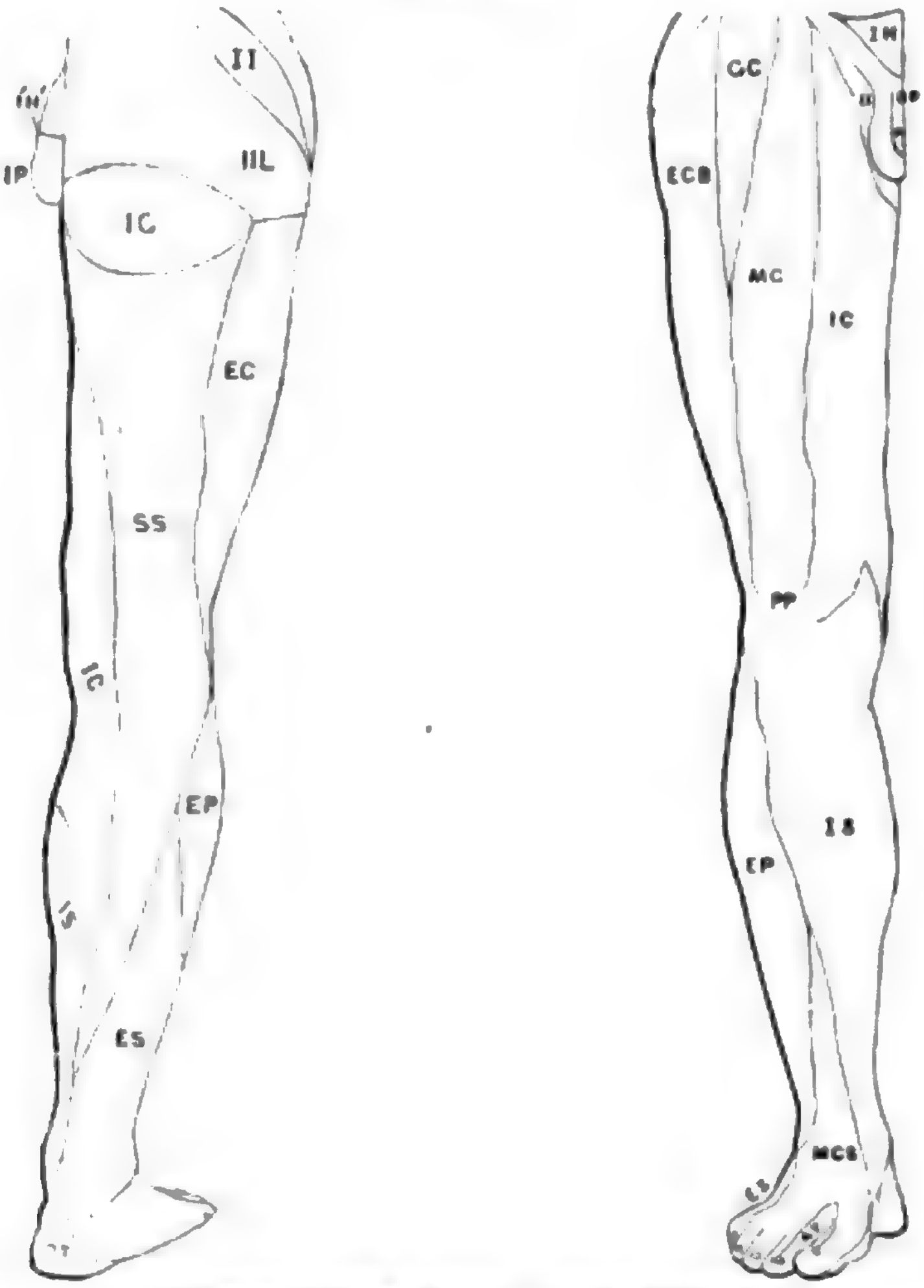

Cutaneous Nerves of the Lower Extremity.

Lumbar Plexus:
IH, Ilio-hypogastric nerve.
II, Ilio-inguinal.
IIL, Second lumbar nerve.
GC, Genito-crural.
EC, External cutaneous.
MC, Middle cutaneous.
IC, Internal cutaneous.
IS, Internal saphenous.
PP, Plexus patellæ.

Sacral Plexus:
DP, Dorsalis penis of pudic.
IP, Inferior hemorrhoidal of pudic.
P, Superficial perineal of pudic and inferior pudendal of small sciatic.
IG, Inferior gluteal of small sciatic.
SS, Small sciatic.
EP, Branches from external popliteal.
ES, External saphenous.
MCS, Musculo-cutaneous.
AT, Branches of anterior tibial.
PT, Branch of posterior tibial (after Flower).]

Occasionally this communicating branch is continued down, as a cutaneous branch, to the thigh and leg. This occasional cutaneous branch emerges from beneath the lower border of the Adductor longus, descends along the posterior margin of the Sartorius to the inner side of the knee, where it pierces the deep fascia, communicates with the long saphenous nerve, and is distributed to the integument of the inner side of the leg as low down as its middle. When the branch is small its place is supplied by the internal cutaneous nerve.

The *posterior branch* of the obturator nerve pierces the Obturator externus, sending branches to supply it, and passes behind the Adductor brevis on the front of the Adductor magnus, where it divides into numerous muscular branches, which supply the Adductor magnus and occasionally the Adductor brevis. One of the branches gives off a filament to the knee-joint.

The *articular branch* for the knee-joint perforates the lower part of the Adductor magnus and enters the popliteal space; it then descends upon the popliteal artery as far as the back part of the knee-joint, where it perforates the posterior ligament and is distributed to the synovial membrane. It gives filaments to the artery in its course.

The **Accessory Obturator Nerve** (Fig. 509, p. 769) is of a small size, and arises either from the obturator nerve near its origin or by separate filaments from the third and fourth lumbar nerves, probably receiving also some fibres from the second through its communicating branch. It descends along the inner border of the Psoas muscle, crosses the body of the pubes, and passes beneath the Pectineus muscle, where it divides into numerous branches. One of these supplies the Pectineus, penetrating its under surface, another is distributed to the hip-joint, while a third communicates with the anterior branch of the obturator nerve. This branch, when of large size, is prolonged (as already mentioned) as a cutaneous branch to the leg. The accessory obturator nerve is not constantly found; when absent, the hip-joint receives two branches from the obturator nerve. Occasionally it is very small and becomes lost in the capsule of the hip-joint.

The **Anterior Crural Nerve** (Figs. 509, 511) is the largest branch of the lumbar plexus. It supplies muscular branches to the Iliacus, Pectineus, and all the muscles on the front of the thigh, excepting the Tensor vaginæ femoris, cutaneous filaments to the front and inner side of the thigh and to the leg and foot, and articular branches to the knee. It arises from the third and fourth lumbar nerves, receiving also a fasciculus from the second. It descends through the fibres of the Psoas muscle, emerging from it at the lower part of its outer border, and passes down between it and the Iliacus, and beneath Poupart's ligament, into the thigh, where it becomes somewhat flattened and divides into an anterior or cutaneous and a posterior or muscular part. Beneath Poupart's ligament it is separated from the femoral artery by the Psoas muscle, and lies beneath the iliac fascia.

Within the pelvis the anterior crural nerve gives off from its outer side some small branches to the Iliacus, and a branch to the femoral artery, which is distributed upon the upper part of that vessel. The origin of this branch varies; it occasionally arises higher than usual, or it may arise lower down in the thigh.

External to the pelvis the following branches are given off:

From the Anterior Division.[1]	*From the Posterior Division.*
Middle cutaneous.	Muscular.
Internal cutaneous.	Articular.
Long saphenous.	

The *middle cutaneous nerve* (Fig. 510) pierces the fascia lata (occasionally the Sartorius also) about three inches below Poupart's ligament, and divides into two branches, which descend in immediate proximity along the fore part of the thigh, distributing numerous branches to the integument as low as the front of the knee, where it communicates with a branch of the internal saphenous nerve. Its outer branch communicates above with the crural branch of the genito-crural nerve, and the inner branch with the internal cutaneous nerve below. The Sartorius muscle is supplied by this or the following nerve.

The *internal cutaneous nerve* passes obliquely across the upper part of the sheath of the femoral artery, and divides in front or at the inner side of that vessel into two branches, anterior and internal.

The anterior branch perforates the fascia lata at the lower third of the thigh, and divides into two branches, one of which supplies the integument as low down as the inner side of the knee; the other crosses the patella to the outer side of the joint, communicating in its course with the long saphenous nerve. A cutaneous filament is occasionally given off from this nerve which accompanies the long saphenous vein, and it sometimes communicates with the internal branch of the nerve.

---

[1] One of the muscles of the thigh, the Sartorius, receives its nervous supply from this group.

The internal branch descends along the inner border of the Sartorius muscle to the knee, where it pierces the fascia lata, communicates with the long saphenous nerve, and gives off several cutaneous branches. The nerve then passes down the inner side of the leg, to the integument of which it is distributed. This nerve, beneath the fascia lata, joins in a plexiform network by uniting with branches of the long saphenous and obturator nerves (Fig. 511). When the communicating branch from the latter nerve is large and continued to the integument of the leg, the inner branch of the internal cutaneous is small and terminates at the plexus, occasionally giving off a few cutaneous filaments.

This nerve before subdividing gives off a few filaments which pierce the fascia lata, to supply the integument of the inner side of the thigh, accompanying the long saphenous vein. One of these filaments passes through the saphenous opening, a second becomes subcutaneous about the middle of the thigh, and a third pierces the fascia at its lower third.

The *long* or *internal saphenous nerve* is the largest of the cutaneous branches of the anterior crural. It approaches the femoral artery where this vessel passes beneath the Sartorius, and lies on its outer side, beneath the aponeurotic covering of Hunter's canal, as far as the opening in the lower part of the Adductor magnus. It then quits the artery and descends vertically along the inner side of the knee beneath the Sartorius, pierces the deep fascia between the tendons of the Sartorius and Gracilis, and becomes subcutaneous. The nerve then passes along the inner side of the leg, accompanied by the internal saphenous vein, descends behind the internal border of the tibia, and at the lower third of the leg divides into two branches: one continues its course along the margin of the tibia, terminating at the inner ankle; the other passes in front of the ankle, and is distributed to the integument along the inner side of the foot as far as the great toe, communicating with the internal branch of the musculo-cutaneous nerve.

Branches.—The long saphenous nerve *about the middle of the thigh* gives off a communicating branch which joins the plexus formed by the obdurator and internal cutaneous nerves.

At *the inner side of the knee* it gives off a large branch (*n. cutaneus patellæ*) which pierces the Sartorius and fascia lata, and is distributed to the integument in front of the patella. This nerve communicates *above* the knee with the anterior branch of the internal cutaneous; *below* the knee with other branches of the long saphenous; and on the *outer side* of the joint with branches of the middle and external cutaneous nerves, forming a plexiform network, the *plexus patellæ*. The cutaneous nerve of the patella is occasionally small, and terminates by joining the internal cutaneous, which supplies its place in front of the knee.

Below the knee the branches of the long saphenous nerve are distributed to the integument of the front and inner side of the leg, communicating with the cutaneous branches from the internal cutaneous or obturator nerve.

The **deep group** of branches of the anterior crural nerve are muscular and articular.

The *muscular branches* supply the Pectineus and all the muscles on the front of the thigh except the Tensor vaginæ femoris, which is supplied from the superior gluteal nerve, and the Sartorius, which is supplied by filaments from the middle or internal cutaneous nerves.

The branches to the *Pectineus*, usually two in number, pass inward behind the femoral vessels and enter the muscle on its anterior surface.

The branch of the *Rectus* muscle enters its under surface high up.

The branch of the *Vastus externus*, of large size, follows the course of the descending branch of the external circumflex artery to the lower part of the muscle. It gives off an articular filament to the knee-joint.

The branches to the *Vastus internus* and *Crureus* enter the middle of those muscles, the one to the Vastus internus supplying a filament to the knee-joint.

The *articular branches*, two in number, supply the knee-joint. One, a long slender filament, is derived from the nerve to the Vastus externus. It penetrates the capsular ligament of the joint on its anterior aspect. The other is derived from the nerve to the Vastus internus. It descends along the internal intermuscular septum, accompanying the deep branch of the anastomotica magna artery, pierces the capsular ligament of the joint on its inner side, and supplies the synovial membrane.

THE SACRAL AND COCCYGEAL NERVES.

The *sacral nerves* are five in number on each side. The four upper ones pass from the sacral canal through the sacral foramina; the fifth, through the foramen between the sacrum and coccyx.

The *roots of origin* of the upper sacral (and lumbar) nerves are the largest of all the spinal nerves, whilst those of the lowest sacral and coccygeal nerve are the smallest.

The **roots** of these nerves are of very considerable length, being longer than those of any of the other spinal nerves, on account of the spinal cord not extending beyond the first lumbar vertebra. From their great length and the appearance they present in connection with the spinal cord the roots of origin of these nerves are called collectively the *cauda equina*. Each sacral and coccygeal nerve divides into two divisions, anterior and posterior.

The **posterior sacral nerves** (Fig. 513) are small, diminish in size from above downward, and emerge, except the last, from the sacral canal by the posterior sacral foramina.

The *three upper ones* are covered at their exit from the sacral canal by the Multifidus spinæ, and divide into external and internal branches.

The *internal branches* are small and supply the Multifidus spinæ.

The *external branches* join with each other and with the last lumbar and fourth sacral nerves by means of communicating loops. These branches pass outward to the outer surface of the great sacro-sciatic ligament, where they form a second series of loops beneath the Gluteus maximus. Cutaneous branches from this second series of loops, usually three in number, pierce the Gluteus maximus—one near the posterior inferior spine of the ilium, another opposite the end of the sacrum, and the third midway between the other two. They supply the integument over the posterior part of the gluteal region.

The *two lower posterior sacral nerves* are situated below the Multifidus spinæ. They are of small size, and do not divide into internal and external branches, but join with each other and with the coccygeal nerve, so as to form loops on the back of the sacrum, filaments from which supply the integument over the coccyx.

The **coccygeal nerve** divides into its anterior and posterior divisions in the spinal canal. The *posterior* division is the smaller. It does not divide, but receives, as already mentioned, a communicating branch from the last sacral, and is lost in the fibrous structure on the back of the coccyx.

The **anterior sacral nerves** diminish in size from above downward. The four upper ones emerge from the anterior sacral foramina: the anterior division of the fifth, after emerging from the spinal canal through its terminal opening, curves forward between the sacrum and the coccyx. All the anterior sacral nerves communicate with the sacral ganglia of the sympathetic at their exit from the sacral foramina. The *first* nerve, of large size, unites with the lumbo-sacral cord formed by the fifth lumbar and a branch from the fourth. The *second*, equal in size to the preceding, and the *third*, about one-fourth the size of the second, unite with this trunk, and form, with a small fasciculus from the fourth, the *sacral plexus*, a visceral branch being given off from the third nerve to the bladder.

The **fourth anterior sacral nerve** sends a branch to join the sacral plexus. The remaining portion of the nerve divides into visceral and muscular branches, and a communicating filament descends to join the fifth sacral nerve. The *visceral* *branches* are distributed to the viscera of the pelvis, communicating with the sympathetic nerve. These branches ascend upon the rectum and bladder—in the female upon the vagina and bladder—communicating with branches of the sympathetic to form the hypogastric plexus. The *muscular branches* are distributed to the Levator ani, Coccygeus, and Sphincter ani. Cutaneous filaments arise from the latter branch, which supply the integument between the anus and coccyx. Another cutaneous branch is frequently given off from this nerve, though sometimes from the pudic (Schwalbe). It perforates the great sacro-sciatic ligament, and, winding round the lower border of the Gluteus maximus, supplies the skin over the lower and inner part of this muscle.

The **fifth anterior sacral nerve,** after passing from the lower end of the sacral canal, curves forward through the fifth sacral foramen, formed between the lower part of the sacrum and the transverse process of the first piece of the coccyx. It pierces the Coccygeus muscle, and descends upon its anterior surface to the tip of the coccyx, where it again perforates the muscle, to be distributed to the integument over the back part and side of the coccyx. This nerve communicates above with the fourth sacral and below with the coccygeal nerve, and supplies the Coccygeus muscle.

FIG. 513.

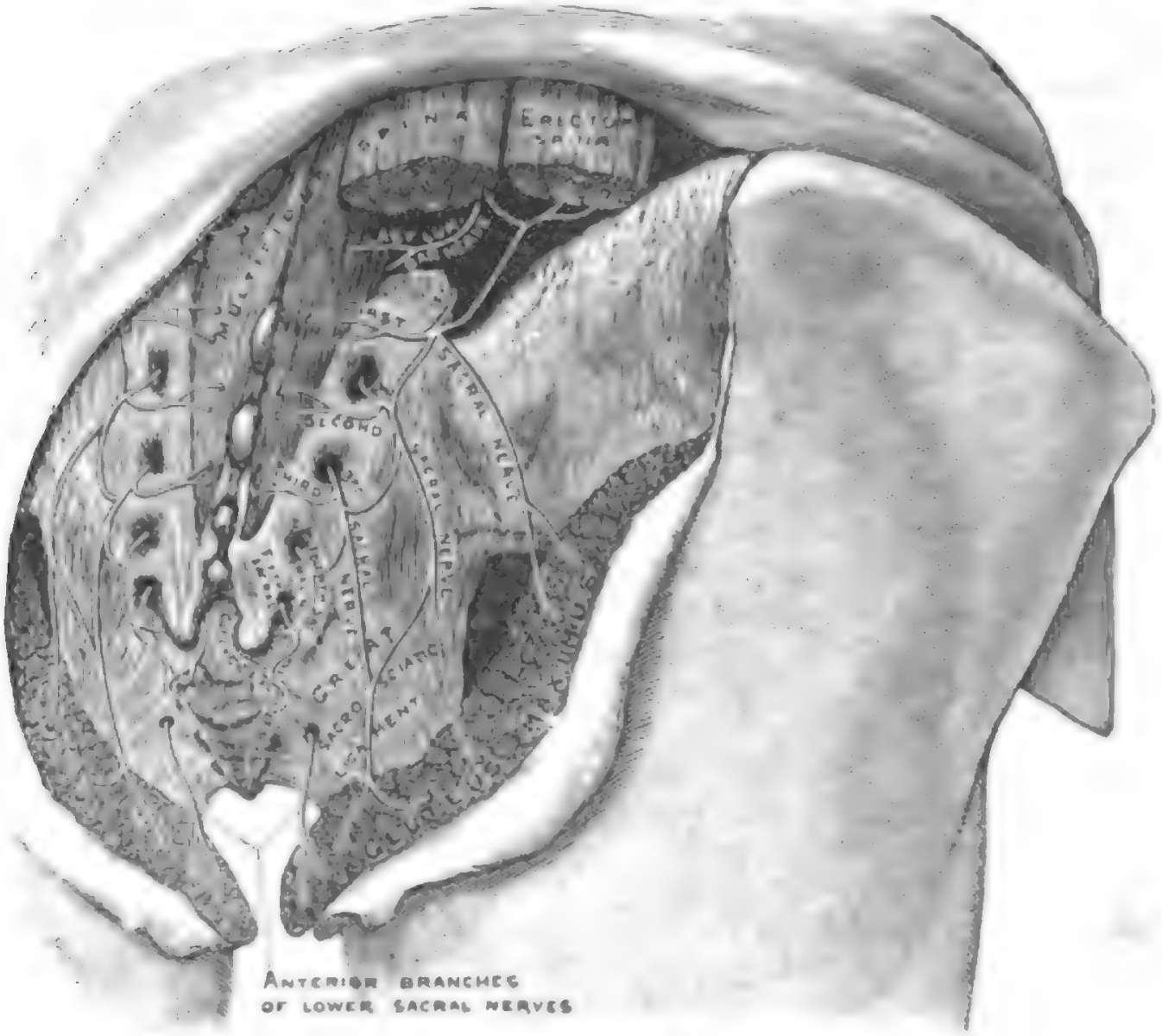

The Posterior Sacral Nerves.

The **anterior division of the coccygeal nerve** is a delicate filament which escapes at the termination of the sacral canal; it passes downward behind the rudimentary transverse process of the first piece of the coccyx, and curves forward, through the notch between the first and second pieces, piercing the Coccygeus muscle and descending on its anterior surface to near the tip of the coccyx, where it again pierces the muscle, to be distributed to the integument over the back part and side of the coccyx. It is joined by a branch from the fifth anterior sacral as it descends on the surface of the Coccygeus muscle.

SACRAL PLEXUS (Fig. 514).

The sacral plexus is formed by the lumbo-sacral cord, the anterior divisions of the three upper sacral nerves, and part of that of the fourth. These nerves proceed in different directions, the upper ones obliquely downward and outward, the lower one nearly horizontally, and they all unite into a single broad, flat cord. The sacral plexus is triangular in form, its base corresponding with the exit of the nerves from the sacrum, its apex with the lower part of the great sacro-sciatic foramen. It rests upon the anterior surface of the Pyriformis, and is covered in front by the pelvic fascia, which separates it from the sciatic and pudic branches of the internal iliac artery and from the viscera of the pelvis.

FIG. 514.

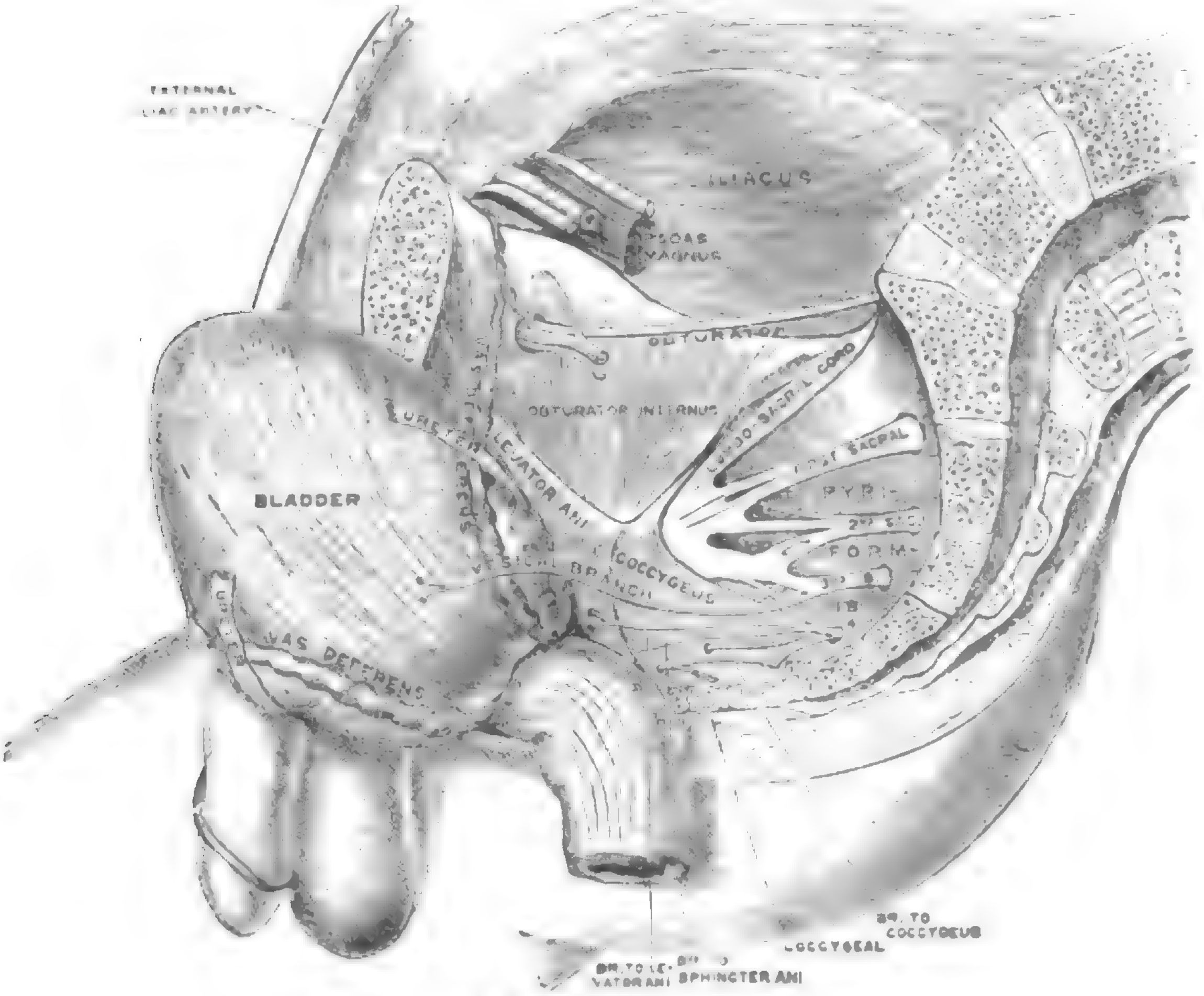
EXTERNAL ILIAC ARTERY
ILIACUS
PSOAS MAGNUS
OBTURATOR
OBTURATOR INTERNUS
LUMBO-SACRAL CORD
1ST SACRAL
PYRI-
2ND SAC.
FORM-
3RD
URETER
LEVATOR ANI
BLADDER
COCCYGEUS
VESICAL BRANCH
URETER
VAS DEFERENS
BR. TO COCCYGEUS
COCCYGEAL
BR. TO LEVATOR ANI
BR. TO SPHINCTER ANI

Side View of Pelvis, showing sacral plexus.

The branches of the sacral plexus are—

Muscular. Pudic.
Superior gluteal. Small sciatic.
Great sciatic.

The **muscular branches** supply the Pyriformis, Obturator internus, the two Gemelli, and the Quadratus femoris. The branch to the Pyriformis arises either from the plexus or from the upper sacral nerves before they enter the plexus: the branch to the Obturator internus arises at the junction of the lumbo-sacral and first sacral nerves; it passes out of the pelvis through the great sacro-sciatic foramen, crosses behind the spine of the ischium, and enters the pelvis again through the lesser sacro-sciatic foramen to the inner surface of the Obturator internus. The branch of the Gemellus superior arises from the lower part of the plexus, near the pudic nerve: the small branch to the Gemellus inferior and Quadratus femoris also arises from the lower part of the plexus: it passes through the great sacro-sciatic foramen, and courses down beneath the Gemelli and tendon of the Obturator internus, and supplies the muscles on their deep or anterior surface. It gives off an articular branch to the hip-joint. This branch is occasionally derived from the upper part of the great sciatic nerve.

The **Superior Gluteal Nerve** (Fig. 516) arises from the back part of the lumbosacral cord; it passes from the pelvis through the great sacro-sciatic foramen above the Pyriformis muscle, accompanied by the gluteal vessels, and divides into a superior and an inferior branch.

The *superior branch* follows the line of origin of the Gluteus minimus, and supplies it and the Gluteus medius.

The *inferior branch* crosses obliquely between the Gluteus minimus and medius, distributing filaments to both these muscles, and terminates in the Tensor vaginæ femoris, extending nearly to its lower end.

The **Pudic Nerve** arises from the lower part of the sacral plexus, and leaves the pelvis, through the great sacro-sciatic foramen, below the Pyriformis. It then crosses the spine of the ischium and re-enters the pelvis through the lesser sacro-sciatic foramen. It accompanies the pudic vessels upward and forward along the outer wall of the ischio-rectal fossa, being contained in a sheath of the obturator fascia, and divides into two terminal branches, the perineal nerve and the dorsal nerve of the penis. Near its origin it gives off the inferior hemorrhoidal nerve.

The *inferior hemorrhoidal nerve* is occasionally derived from the sacral plexus. It passes across the ischio-rectal fossa, with its accompanying vessels, toward the lower end of the rectum, and is distributed to the integument round the anus. Branches of this nerve communicate with the inferior pudendal and superficial perineal nerves at the fore part of the perineum.

The *perineal nerve*, the inferior and larger of the two terminal branches of the pudic, is situated below the pudic artery. It accompanies the superficial perineal artery in the perineum, dividing into cutaneous and muscular branches.

The cutaneous branches (superficial perineal) are two in number, posterior and anterior. The *posterior branch* passes to the fore part of the ischio-rectal fossa, distributing filaments to the Sphincter ani and integument in front of the anus, which communicate with the inferior hemorrhoidal nerve; it then passes forward, with the anterior branch, to the back of the scrotum, communicating with the anterior branch and with the inferior pudendal. The *anterior branch* passes to the fore part of the ischio-rectal fossa in front of the preceding, and accompanies it to the scrotum and under part of the penis. This branch gives one or two filaments to the Levator ani.

The muscular branches are distributed to the Transversus perinæi, Accelerator urinæ, Erector penis, and Compressor urethræ. The nerve of the bulb supplies the corpus spongiosum; some of its filaments run for some distance on the surface before penetrating to the interior.

The *dorsal nerve of the penis* is the superior division of the pudic nerve: it accompanies the pudic artery along the ramus of the ischium; piercing the posterior layer of the deep perineal fascia, it runs forward along the inner margin of the ramus of the pubes between the two layers of the deep fascia. It then pierces the anterior layer, and in company with the dorsal artery of the penis passes through the suspensory ligament, and, running forward, is distributed to the glans. On the penis this nerve gives off a cutaneous branch which runs along the side of the organ: it is joined with branches of the sympathetic, and supplies the integument of the upper surface and sides of the penis and prepuce, giving a large branch to the corpus cavernosum.

In the female the pudic nerve is distributed to the parts analogous to those in the male, its superior division terminating in the clitoris, its inferior in the external labia and perineum.

The **Small Sciatic Nerve** (Fig. 516) supplies the integument of the perineum and back part of the thigh and leg, and one muscle, the Gluteus maximus. It is usually formed by the union of two branches which arise from the lower part of the sacral plexus. It issues from the pelvis through the great sacro-sciatic foramen

Fig. 515.

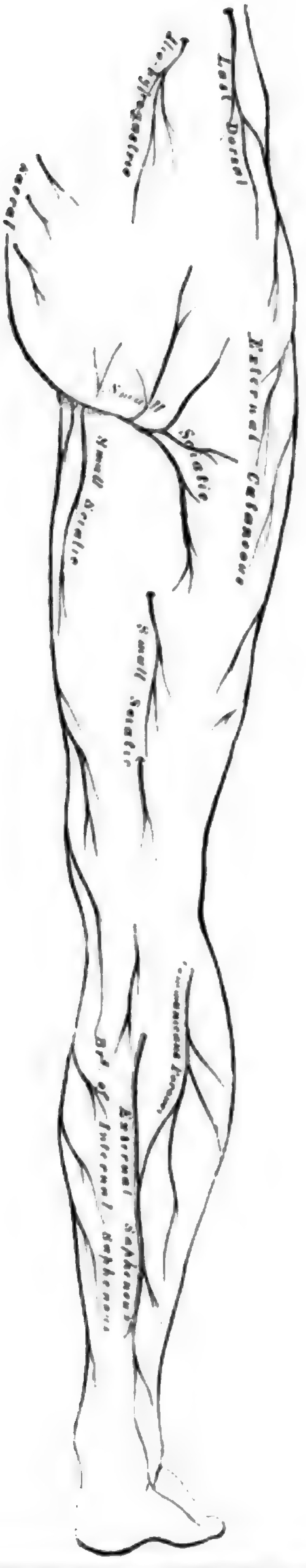
Ilio-hypogastric
Last Dorsal
Sacral
External Cutaneous
Small Sciatic
Small Sciatic
Small Sciatic
Communicans Peronei
Br. of Internal Saphenous
External Saphenous

Cutaneous Nerves of Lower Extremity, posterior view.

Fig. 516.

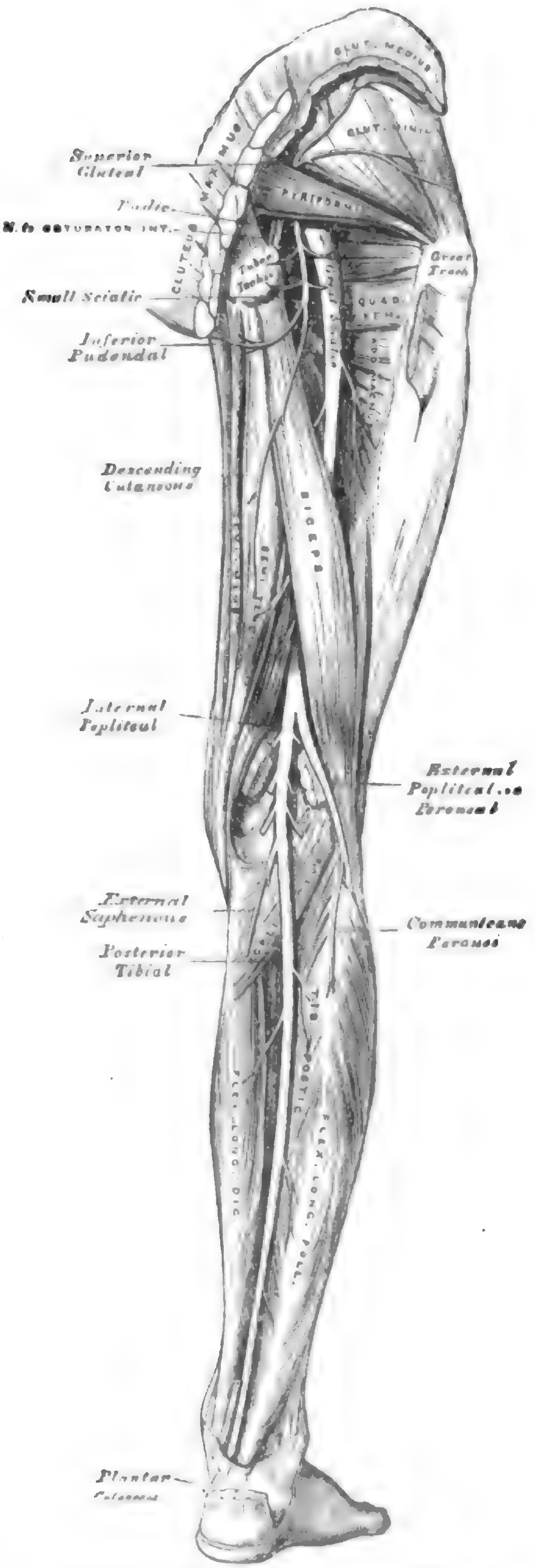
GLUT. MEDIUS
GLUT. MINIM.
Superior Gluteal
MAXIMUS
PYRIFORMIS
Pudic
N. to OBTURATOR INT.
GLUTEUS
Tuber Ischii
Great Troch.
Small Sciatic
QUAD. FEM.
Inferior Pudendal
ADD. MAG.
Descending Cutaneous
BICEPS
Internal Popliteal
External Popliteal or Peroneal
External Saphenous
Communicans Peronei
Posterior Tibial
TIB. POSTIC.
FLEX. LONG. DIG.
FLEX. LONG. POLL.
Plantar Cutaneous

Nerves of the Lower Extremity,[1] posterior view.

---

[1] In this diagram the External saphenous and Communicans peronei are not in their normal position. They have been displaced by the removal of the superficial muscles.

below the Pyriformis muscle, descends beneath the Gluteus maximus with the sciatic artery, and at the lower border of that muscle passes along the back part of the thigh, beneath the fascia lata, to the lower part of the popliteal region, where it pierces the fascia and becomes cutaneous. It then accompanies the external saphenous vein below the middle of the leg, its terminal filaments communicating with the external saphenous nerve.

The branches of the small sciatic nerve are muscular (inferior gluteal) and cutaneous.

The *inferior gluteal*[1] consist of several large branches given off to the under surface of the Gluteus maximus near its lower part.

The *cutaneous branches* consist of two groups, internal and ascending.

The *internal cutaneous branches* are distributed to the skin at the upper and inner side of the thigh on its posterior aspect. One branch, longer than the rest, the *inferior pudendal*, curves forward below the tuber ischii, pierces the fascia lata, and passes forward beneath the superficial fascia of the perineum to be distributed to the integument of the scrotum in the male and the labium in the female, communicating with the superficial perineal and inferior hemorrhoidal nerves.

The *ascending cutaneous branches* consist of two or three filaments which turn upward round the lower border of the Gluteus maximus, to supply the integument covering its surface. One or two filaments occasionally descend along the outer side of the thigh, supplying the integument as far as the middle of that region.

Two or three branches are given off from the lesser sciatic nerve as it descends beneath the fascia of the thigh; they supply the integument of the back part of the thigh, popliteal region, and upper part of the leg.

The **Great Sciatic Nerve** (Fig. 516) supplies nearly the whole of the integument of the leg, the muscles of the back of the thigh, and those of the leg and foot. It is the largest nervous cord in the body, measuring three-quarters of an inch in breadth, and is the continuation of the lower part of the sacral plexus. It passes out of the pelvis through the great sacro-sciatic foramen below the Pyriformis muscle. It descends between the trochanter major and tuberosity of the ischium, along the back part of the thigh to about its lower third, where it divides into two large branches, the *internal* and *external popliteal nerves*.

This division may take place at any point between the sacral plexus and the lower third of the thigh. When the division occurs at the plexus, the two nerves descend together side by side, or they may be separated at their commencement by the interposition of part or the whole of the Pyriformis muscle. As the nerve descends along the back of the thigh, it rests at first upon the External rotator muscles in company with the small sciatic nerve and artery, being covered by the Gluteus maximus; lower down, it lies upon the Adductor magnus and is covered by the long head of the Biceps. [The great sciatic nerve is accessible for operation in the middle line of the thigh, just below the gluteo-femoral crease.]

The *branches* of the nerve before its division are articular and muscular.

The *articular branches* arise from the upper part of the nerve; they supply the hip-joint, perforating its fibrous capsule posteriorly. These branches are sometimes derived from the sacral plexus.

The *muscular branches* are distributed to the flexors of the leg—viz. the Biceps, Semitendinosus, and Semimembranosus, and a branch to the Adductor magnus. These branches are given off beneath the Biceps muscle.

The **Internal Popliteal Nerve**, the larger of the two terminal branches of the great sciatic, descends along the back part of the thigh, through the middle of the popliteal space, to the lower part of the Popliteus muscle, where it passes with the artery beneath the arch of the Soleus and becomes the posterior tibial. It lies at first very superficial, and at the outer side of, and some distance from, the popliteal vessels; opposite the knee-joint it is in close relation with the vessels and crosses to the inner side of the artery.

---

[1] Some authors describe this nerve as a separate branch of the sacral plexus, derived from the lumbo-sacral cord and the first and second sacral nerves. If this is so, it is, as a rule, very intimately connected with the small sciatic at its origin.

The *branches* of this nerve are the articular, muscular, and a cutaneous branch, the *external* or *short saphenous nerve*.

The *articular branches*, usually three in number, supply the knee-joint; two of these branches accompany the superior and inferior internal articular arteries, and a third the azygos artery.

The *muscular branches*, four or five in number, arise from the nerve as it lies between the two heads of the Gastrocnemius muscle; they supply that muscle, the Plantaris, Soleus, and Popliteus. The nerves which supply the Popliteus turn round its lower border and are distributed to its deep surface.

The *external* or *short saphenous nerve* (communicans poplitei) descends between the two heads of the Gastrocnemius muscle, and about the middle of the back of the leg pierces the deep fascia, and receives a communicating branch (communicans peronei) from the external popliteal nerve (Fig. 515). The nerve then continues its course down the leg near the outer margin of the tendo Achillis, in company with the external saphenous vein, winds round the outer malleolus, and is distributed to the integument along the outer side of the foot and little toe, communicating on the dorsum of the foot with the musculo-cutaneous nerve. In the leg its branches communicate with those of the small sciatic.

The **Posterior Tibial Nerve** (Fig. 516) commences at the lower border of the Popliteus muscle, and passes along the back part of the leg with the posterior tibial vessels to the interval between the inner malleolus and the heel, where it divides into the *external* and *internal plantar nerves*. It lies upon the deep muscles of the leg, and is covered in the upper part by the muscles of the calf, lower down by the skin and fascia. In the upper part of its course it lies to the inner side of the posterior tibial artery, but it soon crosses that vessel and lies to its outer side as far as the ankle. In the lower third of the leg it is placed parallel with the inner margin of the tendo Achillis.

FIG. 517.

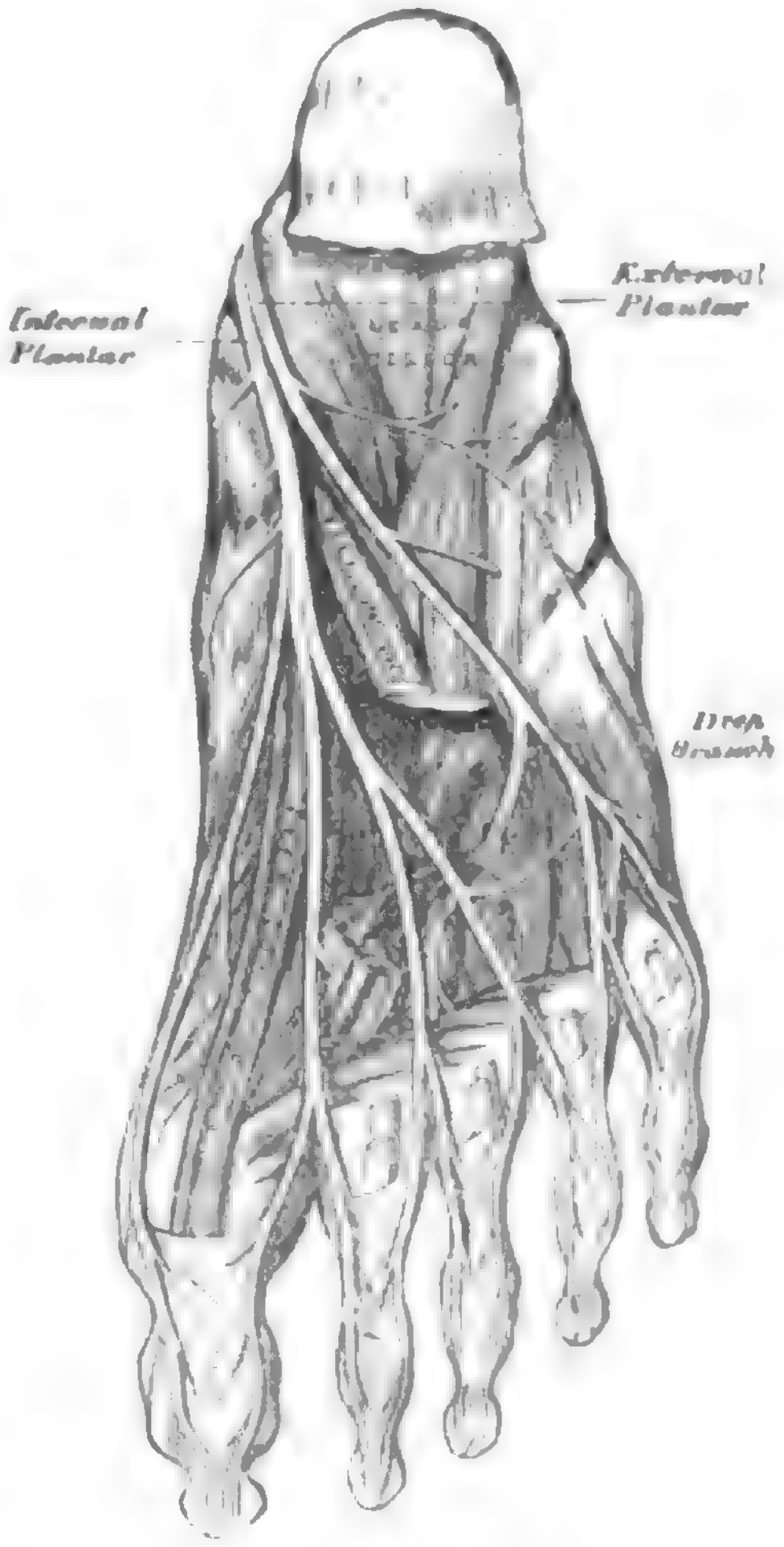

The Plantar Nerves.

The *branches* of the posterior tibal nerve are muscular, plantar-cutaneous, and articular.

The *muscular branches* arise either separately or by a common trunk from the upper part of the nerve. They supply the Tibialis posticus, Flexor longus digitorum, and Flexor longus pollicis muscles, the branch to the latter muscle accompanying the peroneal artery.

The *plantar-cutaneous branch* perforates the internal annular ligament and supplies the integument of the heel and inner side of the sole of the foot.

The *articular* branch is given off just above the bifurcation of the nerve and supplies the ankle-joint.

The **Internal Plantar Nerve** (Fig. 517), the larger of the two terminal branches of the posterior tibial, accompanies the internal plantar artery along the inner side of the foot. From its origin at the inner ankle it passes beneath the Abductor pollicis, and then forward between this muscle and the Flexor brevis digitorum, divides opposite the bases of the metatarsal bones into four digital branches, and communicates with the external plantar nerve.

Branches.—In its course the internal plantar nerve gives off *cutaneous branches* which pierce the plantar fascia and supply the integument of the sole of the foot; *muscular branches*, which supply the Abductor pollicis and Flexor brevis digitorum; *articu-*

lar branches to the articulations of the tarsus and metatarsus; and *four digital branches.* These pass between the divisions of the plantar fascia in the clefts between the toes, and are distributed in the following manner: The *first* supplies the inner border of the great toe, and sends a filament to the Flexor pollicis brevis muscle; the *second* bifurcates to supply the adjacent sides of the great and second toes, sending a filament to the first Lumbrical muscle; the *third* digital branch supplies the adjacent sides of the second and third toes and the second Lumbrical muscle; the *fourth* supplies the corresponding sides of the third and fourth toes and receives a communicating branch from the external plantar nerve. It will be observed that the distribution of these branches is precisely similar to that of the median nerve in the hand. Each digital nerve gives off cutaneous and articular filaments, and opposite the last phalanx sends a dorsal branch which supplies the structure round the nail, the continuation of the nerve being distributed to the ball of the toe.

The **External Plantar Nerve,** the smaller of the two, completes the nervous supply to the structures of the foot, being distributed to the little toe and one-half of the fourth, as well as to most of the deep muscles, its distribution being similar to that of the ulnar in the hand. It passes obliquely forward with the external plantar artery to the outer side of the foot, lying between the Flexor brevis digitorum and Flexor accessorius, and in the interval between the former muscle and Abductor minimi digiti divides into a superficial and a deep branch. Before its division it supplies the Flexor accessorius and Abductor minimi digiti.

The *superficial branch* separates into two digital nerves: one, the smaller of the two, supplies the outer side of the little toe, the Flexor brevis minimi digiti, and the two Interosseous muscles of the fourth metatarsal space; the other and larger digital branch supplies the adjoining sides of the fourth and fifth toes and communicates with the internal plantar nerve.

The *deep* or *muscular branch* accompanies the external plantar artery into the deep part of the sole of the foot, beneath the tendons of the Flexor muscles and Adductor pollicis, and supplies all the Interossei (except those in the fourth metatarsal space), the two outer Lumbricales, the Adductor pollicis, and the Transversus pedis.

The **External Popliteal or Peroneal Nerve** (Fig. 516), about one-half the size of the internal popliteal, descends obliquely along the outer sides of the popliteal space to the fibula, close to the inner margin of the Biceps muscle. It is easily felt beneath the skin behind the head of the fibula at the inner side of the tendon of the Biceps. [In tenotomy of the Biceps great care must be taken not to divide this nerve. The knife-blade is introduced flatwise between the tendon and the nerve and parallel to both of them. Its edge is then turned toward the tendon and its back toward the nerve.] About an inch below the head of the fibula it pierces the origin of the Peroneus longus, and divides beneath that muscle into the anterior tibial and musculo-cutaneous nerves.

The *branches* of the peroneal nerve previous to its division are articular and cutaneous.

The *articular branches,* two in number, accompany the superior and inferior external articular arteries to the outer side of the knee. The upper one occasionally arises from the great sciatic nerve before its bifurcation. A third (*recurrent*) articular nerve is given off at the point of division of the peroneal nerve; it ascends with the tibial recurrent artery through the Tibialis anticus muscle to the front of the knee, which it supplies.

The *cutaneous branches,* two or three in number, supply the integument along the back part and outer side of the leg as far as its middle or lower part; one of these, larger than the rest, the *communicans peronei,* arises near the head of the fibula, crosses the external head of the Gastrocnemius to the middle of the leg, and joins with the external saphenous. This nerve occasionally exists as a separate branch which is continued down as far as the heel.

The **Anterior Tibial Nerve** (Fig. 511, p. 771) commences at the bifurcation of the peroneal nerve, between the fibula and upper part of the Peroneus longus, passes obliquely forward beneath the Extensor longus digitorum to the fore part of the interosseous membrane, and reaches the outer side of the anterior tibial artery above the middle of the leg; it then descends with the artery to the front of the ankle-joint, where it divides into an external and an internal branch. This nerve lies at first on the outer side of the anterior tibial artery, then in front of it, and again at its outer side at the ankle-joint.

The *branches* of the anterior tibial nerve in its course through the leg are the muscular nerves to the Tibialis anticus, Extensor longus digitorum, Peroneus tertius, and Extensor proprius pollicis muscles, and an *articular* branch to the ankle-joint.

The *external* or *tarsal branch* of the anterior tibial passes outward across the tarsus, beneath the Extensor brevis digitorum, and, having become ganglionic like the posterior interosseous nerve at the wrist, supplies the Extensor brevis digitorum and the articulations of the tarsus and metatarsus.

The *internal branch*, the continuation of the nerve, accompanies the dorsalis pedis artery along the inner side of the dorsum of the foot, and at the first interosseous space divides into two branches, which supply the adjacent sides of the great and second toes, communicating with the internal division of the musculo-cutaneous nerve.

The **Musculo-cutaneous Nerve** (Fig. 513, p. 776) supplies the muscles on the fibular side of the leg and the integument of the dorsum of the foot. It passes forward between the Peronei muscles and the Extensor longus digitorum, pierces the deep fascia at the lower third of the leg on its front and outer side, and divides into two branches. This nerve in its course between the muscles gives off muscular branches to the Peroneus longus and brevis and cutaneous filaments to the integument of the lower part of the leg.

The *internal branch* of the musculo-cutaneous nerve passes in front of the ankle-joint and along the dorsum of the foot, supplying the inner side of the great toe and the adjoining sides of the second and third toes. It also supplies the integument of the inner ankle and inner side of the foot, communicating with the internal saphenous nerve, and joins with the anterior tibial nerve, between the great and second toes.

The *external branch*, the larger, passes along the outer side of the dorsum of the foot, to be distributed to the adjoining sides of the third, fourth, and fifth toes. It also supplies the integument of the outer ankle and outer side of the foot, communicating with the short saphenous nerve.

The distribution of these branches of the musculo-cutaneous nerve will be found to vary; together they supply all the toes excepting the outer side of the little toe and the adjoining sides of the great and second toes, the former being supplied by the external saphenous, and the latter by the internal branch of the anterior tibial.

[The popliteal nerves are easily accessible for operation in their respective positions in the ham. The anterior and posterior tibial nerves can be reached by the same operations as the corresponding arteries.]

The Sympathetic Nerve.

THE **Sympathetic Nervous System** consists of (1) a series of ganglia connected together by intervening cords, extending on each side of the vertebral column from the base of the skull to the coccyx; (2) of three great gangliated plexuses or aggregations of nerves and ganglia situated in front of the spine in the thoracic, abdominal, and pelvic cavities respectively; (3) of smaller ganglia situated in relation with the abdominal [and other] viscera; and (4) of numerous nerve-fibres. These latter are of two kinds: *communicating*, by which the ganglia communicate with each other and with the cerebro-spinal nerves; and *distributory*, supplying in general all the internal viscera and the coats of the blood-vessels. [By the blood-vessels the sympathetic reaches all parts of the body.]

Each **gangliated cord** may be traced upward from the base of the skull into its cavity by an ascending branch which passes through the carotid canal, forms a plexus on the internal carotid artery, and communicates with the ganglia on the first and second divisions of the fifth nerve. According to some anatomists, the two cords are joined at their cephalic extremities by these ascending branches, communicating in a small ganglion (the *ganglion of Ribes*) situated upon the anterior communicating artery. The ganglia of these cords are distinguished as cervical, dorsal, lumbar, and sacral, and except in the neck they correspond pretty nearly in number to the vertebræ against which they lie. They may be thus arranged:

Cervical portion	3	pairs of ganglia.
Dorsal "	12	" "
Lumbar "	4	" "
Sacral "	5	" "

In the neck they are situated in front of the transverse processes of the vertebræ; in the dorsal region, in front of the heads of the ribs; in the lumbar region, on the sides of the bodies of the vertebræ; and in the sacral region, in front of the sacrum. As the two cords pass into the pelvis they converge and unite together in a single ganglion (*ganglion impar*) placed in front of the coccyx. Each ganglion may be regarded as a distinct centre, and in addition to its branches of distribution possesses also branches of communication which communicate with other ganglia and with the cerebro-spinal nerves.

The branches of communication between the ganglia are composed of gray and white nerve-fibres, the latter being continuous with those fibres of the spinal nerves which pass to the ganglia.

The branches of communication between the ganglia and the cerebro-spinal nerves also consist of a white and gray portion; the former proceeding from the spinal nerve *to* the ganglion, the latter passing *from* the ganglion to the spinal nerve, so that a double interchange takes place between the two systems.

The **three great gangliated plexuses** are situated in front of the spine in the thoracic, abdominal, and pelvic regions, and are named, respectively, the *cardiac*, the *solar* or *epigastric*, and the *hypogastric* plexuses. They consist of collections of nerves and ganglia, the nerves being derived from the gangliated cords and from the cerebro-spinal nerves. They distribute branches to the viscera.

Smaller ganglia are also found lying amidst the nerves, some of them of microscopic size, in certain viscera; as, for instance, in the heart, the stomach, and the uterus. They serve as additional centres for the origin of nerve-fibres.

The **branches of distribution** derived from the gangliated cords, from the prævertebral plexuses, and also from the smaller ganglia are principally destined for the blood-vessels and thoracic and abdominal viscera, supplying the involuntary muscular fibre of the coats of the vessels and the hollow viscera and the secreting cells, as well as the muscular coats of the vessels in the glandular viscera.

[Fig. 518.—Diagram of the Sympathetic Nerve.

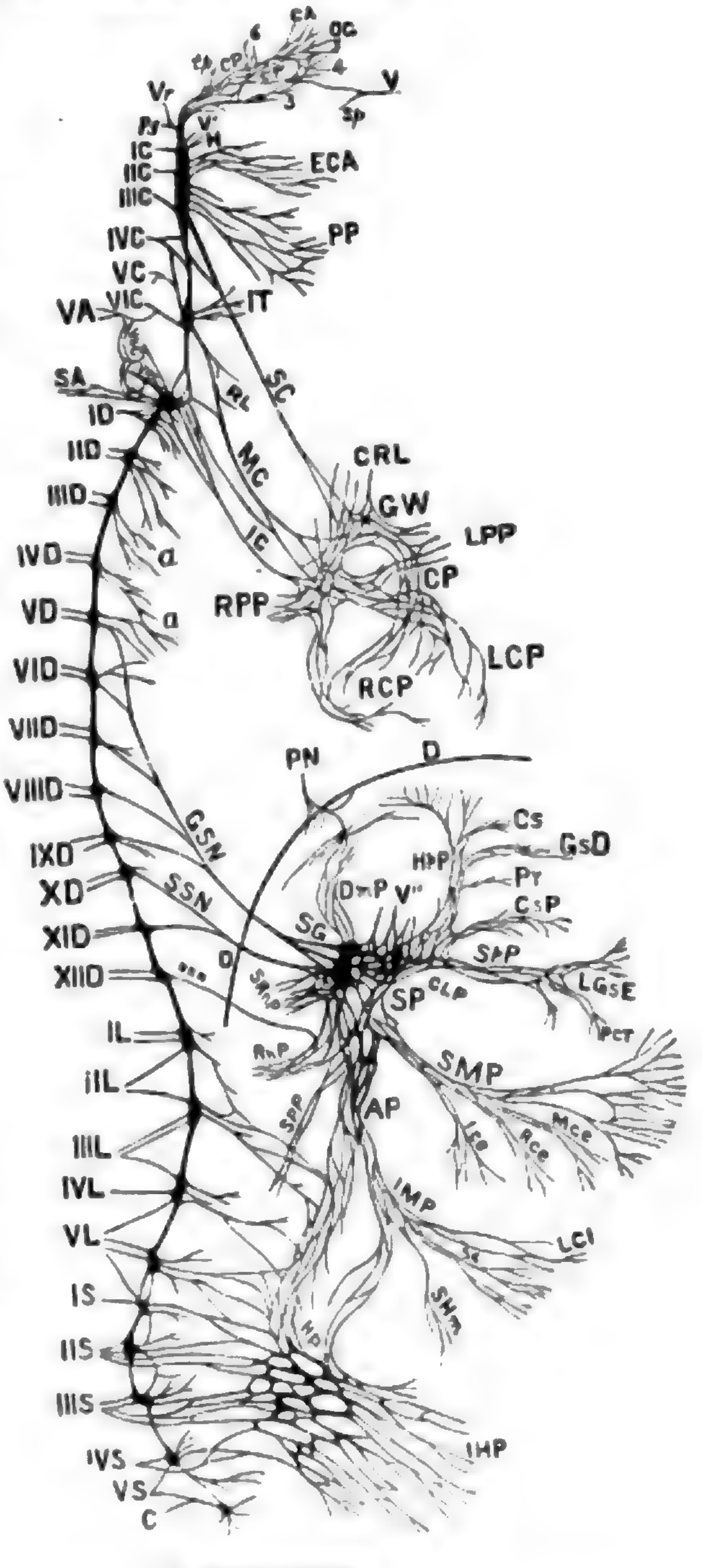

The Superior Cervical Ganglion.

IC to IVC, Branches of communication to four upper cervical nerves.
PS, Branches of communication to petrosal ganglion.
V r, Branches of communication to ganglion of root of pneumogastric.
V', Branches of communication to ganglion of trunk of pneumogastric.
H, Branches of communication to hypoglossal nerve.
CP, Carotid plexus.
C'P, Cavernous plexus.
CA, Branches accompanying internal carotid artery.
OG, Branches to ophthalmic ganglion.
th, To tympanic branch of glosso-pharyngeal.
3, to third nerve.
4, to fourth nerve.
5, to fifth nerve.
6, to sixth nerve.
V, Vidian nerve to spheno-palatine ganglion.
Sp, Large superficial petrosal from facial nerve.
EAC, Accompanying branches of external carotid artery.
PP, Pharyngeal plexus, formed by union with branches of vagus and glosso-pharyngeal nerves.
SG, Superior cardiac nerve.

The Middle Cervical, or Thyroid Ganglion.

IVC to VIC, Branches of communication with fourth, fifth, and sixth cervical nerves.
IT, Inferior thyroid branches.
MC, Middle cardiac nerve.
RL, To recurrent laryngeal.

The Inferior Cervical Ganglion.

VIIC to VIIIC, Branches of communication with seventh and eighth cervical nerves.
IC, Inferior cardiac nerve.
CP, Cardiac plexus.
GW, Ganglion of Wrisberg.
LCP, Posterior, or left coronary plexus.
RCP, Anterior, or right coronary plexus.
CRL, Cardiac branches from pneumogastric or recurrent laryngeal nerves.
APP, To right anterior pulmonary plexus.
LPP, To left anterior pulmonary plexus.

ID to IID, Branches of communication from the first to the twelfth dorsal nerves.
a, *a*, To aorta, vertebræ, œsophagus, and posterior pulmonary plexus.
GSN, Great splanchnic nerve.
SSN, Small splanchnic nerve.
SSN', Smallest splanchnic nerve.
D, Diaphragm.
PN, Phrenic nerve.
SP, Epigastric, or solar plexus.
CLP, Cœliac plexus.
Cs, Cystic plexus.
GSD, Gastro-duodenal plexus.
CsP, Gastric or coronary plexus.
Py, Pyloric plexus.
SpP, Splenic plexus.
LGsE, Left gastro-epiploic plexus.
Pcr, Pancreatic plexus.
HpP, Hepatic plexus.
V'', Branches from pneumogastric.
DmP, Diaphragmatic plexus.
SG, Semilunar ganglion.
SRnP, Suprarenal plexus.
RnP, Renal plexus.
SpP, Spermatic plexus.
SMP. Superior mesenteric plexus.
Mce, Middle colic.
Rce, Right colic.
Ice, Ileo-colic.

AP, Aortic plexus.
IMP, Inferior mesenteric plexus.
LCl, Left colic plexus.
Sz, Sigmoid plexus.
SHm, Superior hemorrhoidal plexus.
IL to VL, Branches of communication with the five lumbar nerves.
IS to VS, Branches of communication with the five sacral nerves.
C, Branches of communication with the coccygeal nerve.
HP, Hypogastric plexus.
IHP, Pelvic, or inferior hypogastric plexus, giving branches to all the pelvic viscera (Flower).]

In addition to these various divisions of the sympathetic, the ganglia connected with the three branches of the fifth cranial nerve are believed by some to constitute a part of the sympathetic system. These ganglia have already been described (p. 722 *et seqq.*).

FIG. 519.

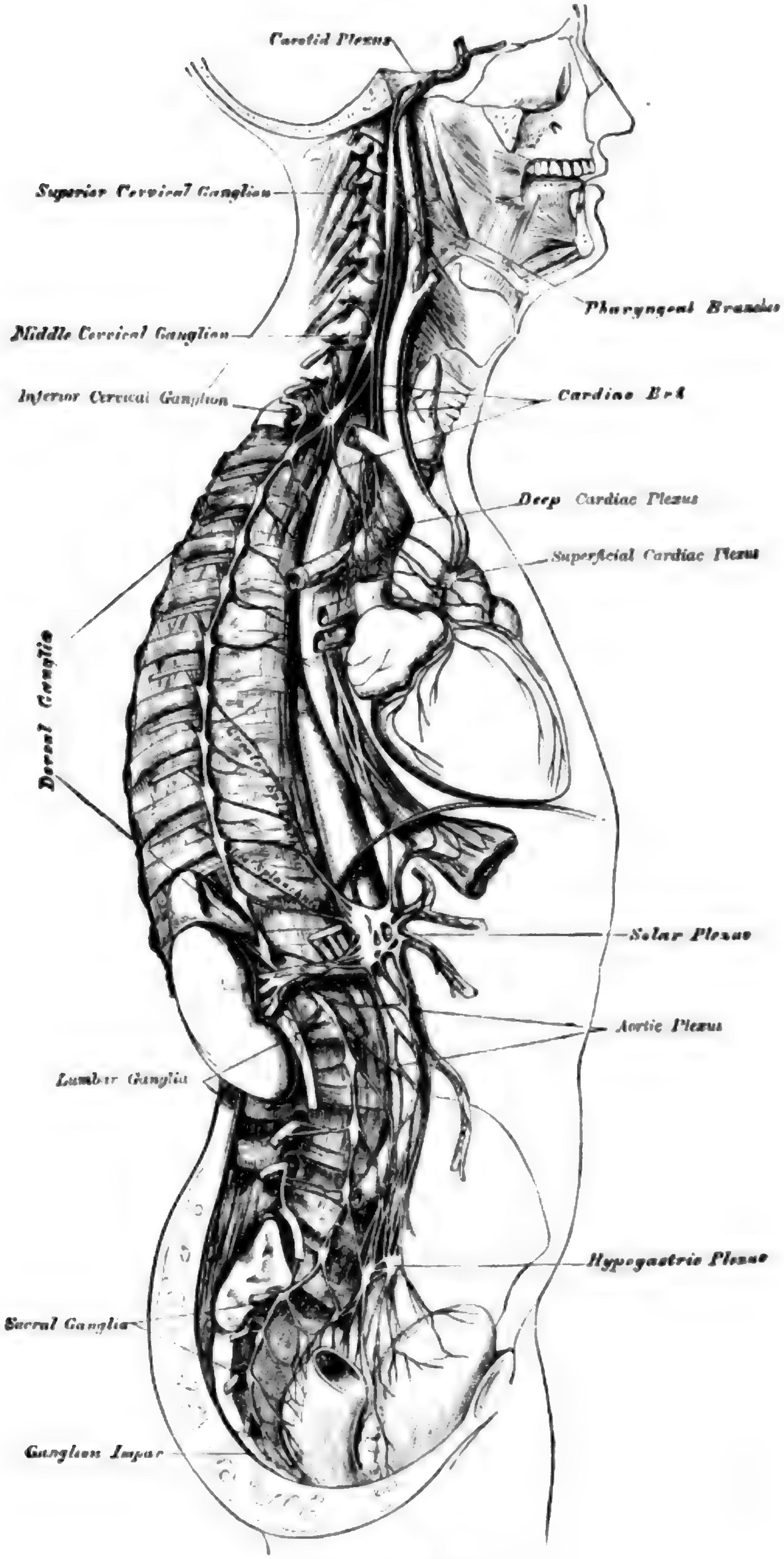
Carotid Plexus
Superior Cervical Ganglion
Pharyngeal Branches
Middle Cervical Ganglion
Inferior Cervical Ganglion
Cardiac Br.s
Deep Cardiac Plexus
Superficial Cardiac Plexus
Dorsal Ganglia
Solar Plexus
Aortic Plexus
Lumbar Ganglia
Hypogastric Plexus
Sacral Ganglia
Ganglion Impar

The Sympathetic Nerve.

CERVICAL PORTION OF THE GANGLIATED CORD.

The cervical portion of the gangliated cord consists of three ganglia on each side, which are distinguished, according to their position, as the superior, middle, and inferior cervical.

[FIG. 520.

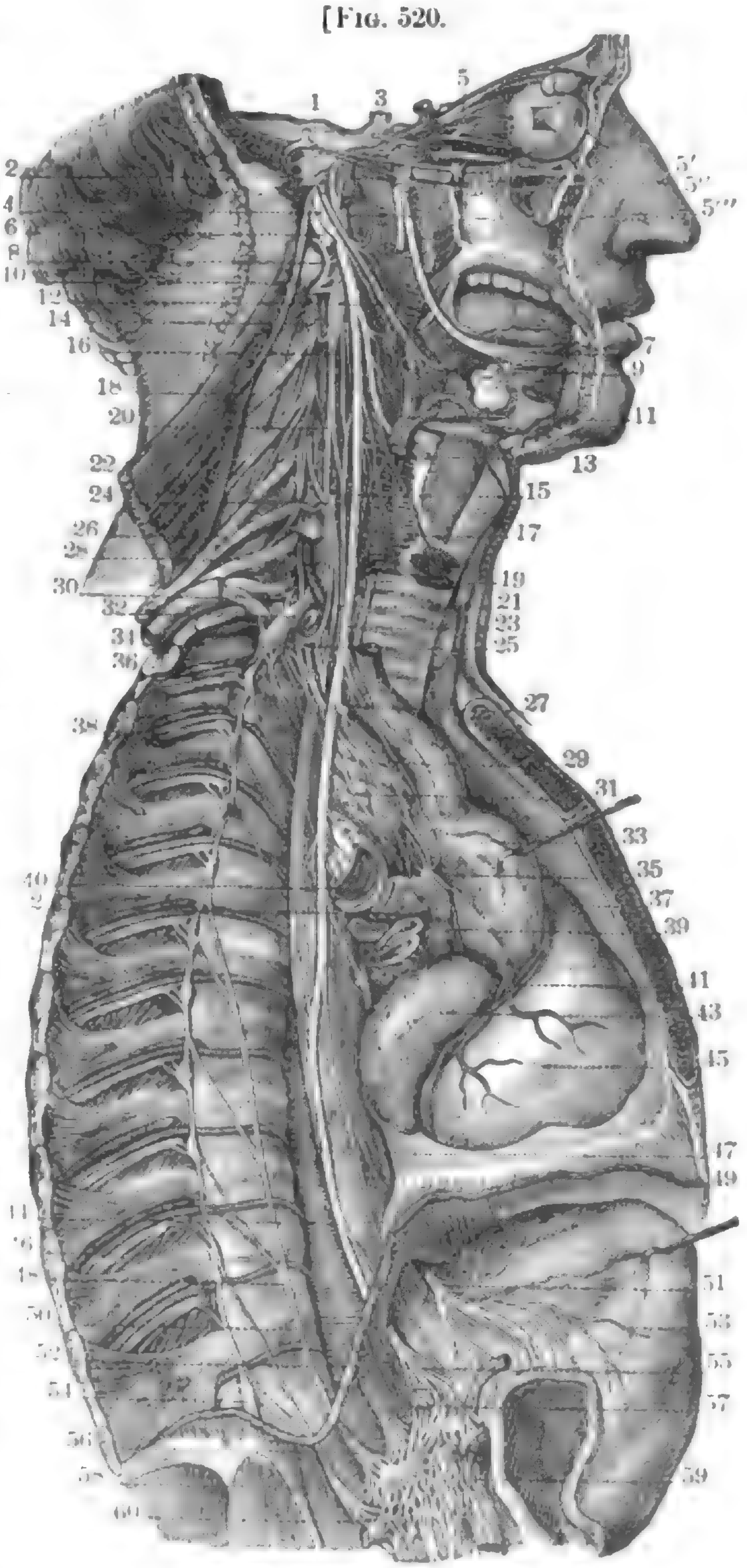

Cervical and Thoracic Portion of the Sympathetic.

1. *Two filaments from the facial, one to the spheno-palatine and the other to the otic ganglion.*
2. Nerve of Jacobson.
3. Motor oculi externus.
4. Right pneumogastric.
5. *Ophthalmic ganglion, receiving a motor filament from the motor oculi communis and a sensory filament from the nasal branch of the fifth.*
5′. *Spheno-palatine ganglion.*
5″. *Otic ganglion.*
5‴. *Branches from superior cervical ganglion to the carotid.*
6. Divided trunk of the sublingual.
7. Lingual branch of the fifth nerve.
8. *Anterior branches of the upper four cervical nerves, sending filaments to the superior cervical sympathetic ganglion.*
9. *Submaxillary ganglion.*
10. Spinal accessory.
11. Superior laryngeal nerve.
12. Glosso-pharyngeal.
13. Superior laryngeal nerve.
14. *Superior cervical ganglion.*
15. *Superior cardiac nerve.*
16. *Chain of ganglia of the sympathetic.*
17. External laryngeal nerve.
18. *Anterior branches of the upper four cervical nerves, sending filaments to the superior cervical sympathetic ganglion.*
19. Recurrent laryngeal nerve.
20. *Cord connecting the superior and middle sympathetic ganglia.*
21. *Middle cardiac nerve.*
22. *Anterior branches of the upper four cervical nerves, sending filaments to the superior cervical sympathetic ganglion.*
23. Right pneumogastric.
24. *Middle cervical ganglion.*
25. *Filaments connecting inferior cervical ganglion with the middle ganglion.*
26. *Anterior branches of the fifth and sixth cervical nerve sending filaments to the middle cervical ganglion.*
27. Recurrent laryngeal nerve.
28. *Anterior branches of the seventh and eighth cervical and the first dorsal nerves, sending filaments to the inferior cervical ganglion.*
29. *Inferior cardiac nerve.*
30. *Anterior branches of the seventh and eighth cervical and the first dorsal nerves, sending filaments to the inferior cervical ganglion.*
31. *Cardiac plexus.*
32. *Filaments connecting inferior cervical ganglion with the middle ganglion.*
33. Arch of the aorta.
34. *Inferior cervical ganglion.*
35. *Ganglion of the cardiac plexus.*
36. *Chain of ganglia of the sympathetic.*
37. Pulmonary artery.
38. *Intercostal nerves with their two filaments of communication with the thoracic ganglia.*
39. *Cardiac plexus.*
40. *Section of the right bronchus.*
41. *Nerve following the right coronary artery.*
42. Pulmonary artery.
43. Right auricle.
44. Right pneumogastric.
45. Right ventricle.
46. *Intercostal nerves with their two filaments of communication with the thoracic ganglia.*
47. Right pneumogastric.
48. *Great splanchnic nerve.*
49. Section of the Diaphragm.
50. *Great splanchnic nerve.*
51. Right pneumogastric.
52. Section of the Diaphragm.
53. Right half of the stomach.
54. *Chain of ganglia of the sympathetic.*
55. Left pneumogastric.
56. *Great splanchnic nerve.*
57. Lower end of the phrenic nerve.
58. *Lesser splanchnic nerve.*
59. *Solar plexus.*
60. *Solar plexus* (Sappey).]

The **Superior Cervical Ganglion,** the largest of the three, is placed opposite the second and third cervical vertebræ, and sometimes as low as the fourth or fifth.

It is of a reddish-gray color and usually fusiform in shape; sometimes broad, and occasionally constricted at intervals, so as to give rise to the opinion that it consists of the coalescence of several smaller ganglia. It is in relation in front with the sheath of the internal carotid artery and internal jugular vein; behind it lies on the Rectus capitis anticus major muscle.

Its branches may be divided into superior, inferior, external, internal, and anterior.

The **superior branch** appears to be a direct continuation of the ganglion. It is soft in texture and of a reddish color. It ascends by the side of the internal carotid artery, and, entering the carotid canal in the temporal bone, divides into two branches, which lie one on the outer and the other on the inner side of that vessel.

[Fig. 521.

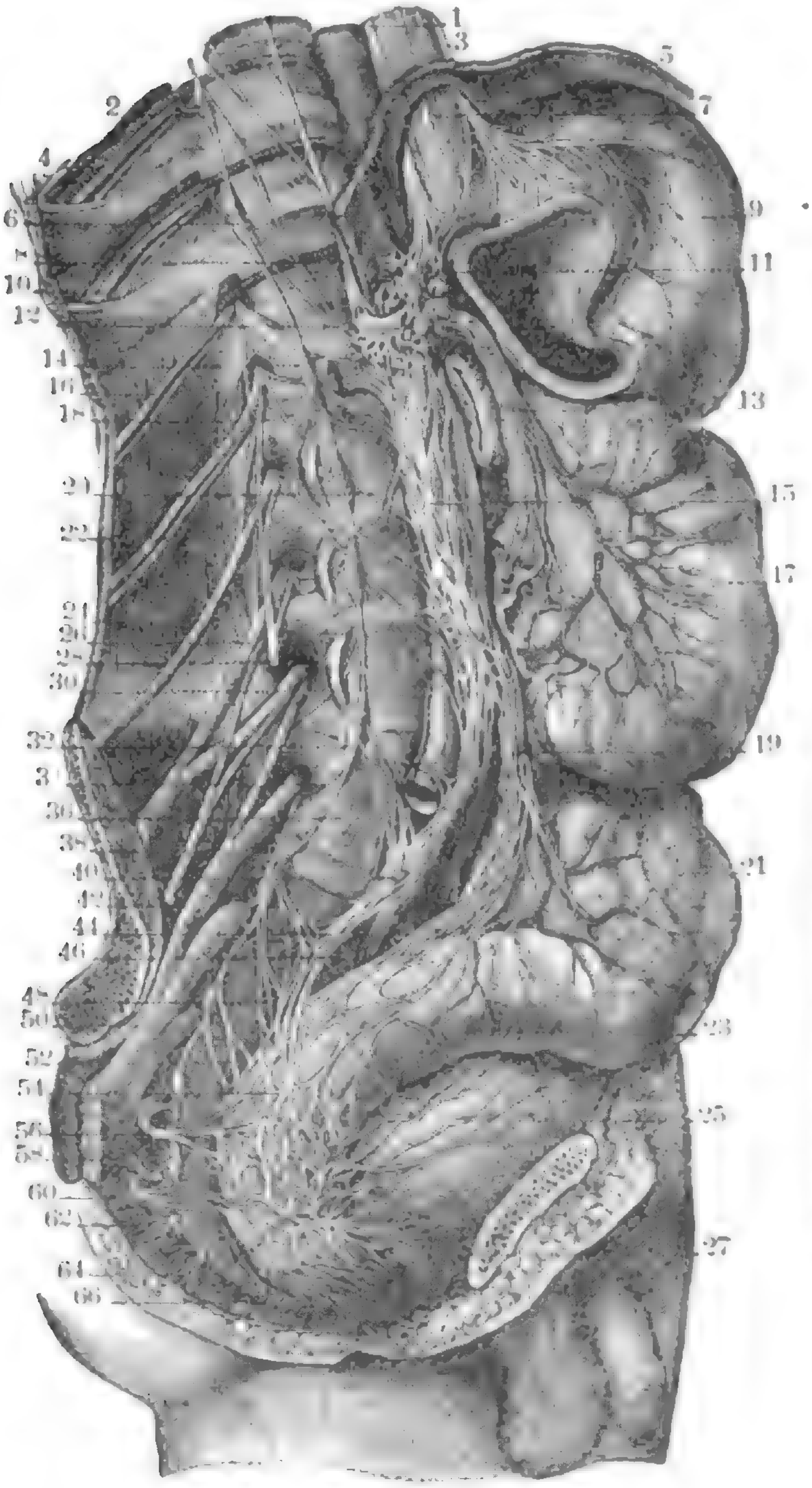

Lumbar and Sacral Portions of the Sympathetic.

1. Lower end of the right pneumogastric.
2. *Eleventh thoracic ganglion.*
3. Lower end of the left pneumogastric.
4. Tenth dorsal nerve.
5. Section of the Diaphragm.
6. *Twelfth thoracic ganglion.*
7. Lower end of the œsophagus.
8. *Lower end of the great splanchnic nerve.*
9. Left half of the stomach.
10. Eleventh dorsal nerve.
11. *Solar plexus.*
12. *Lower end of the lesser splanchnic nerve.*
13. *Superior mesenteric plexus.*
14. *First lumbar ganglion.*
15. *Aortic lumbar plexus.*
16. Twelfth dorsal nerve.
17. Small intestine.
18. *Branch from lumbar ganglion.*
19. *Inferior mesenteric plexus.*
20. *Branch from lumbar ganglion.*
21. Sigmoid flexure of the colon.
22. Lumbar nerve.
23. Rectum.
24. Lumbar nerve.
25. Bladder.
26. Lumbar nerve.
27. Prostate.

28, 30. Lumbar nerves.
32. *Fourth lumbar ganglion.*
34, 36. *Branches from the lumbar ganglia.*
38. Sacral nerve.
40. *Aortic lumbar plexus.*
42. *Sacral portion of the sympathetic.*
44, 46. *Aortic lumbar plexus.*
48. *Hypogastric plexus.*
50. *Sacral nerves.*
52, 54, 56. *Hypogastric plexus.*
58. *Sacral portion of the sympathetic.*
60. *Hypogastric plexus.*
62, 64. Sacral nerves.
66. *Hypogastric plexus* (Sappey).]

The *outer branch*, the larger of the two, distributes filaments to the internal carotid artery and forms the *carotid plexus*.

The *inner branch* also distributes filaments to the internal carotid, and, continuing onward, forms the *cavernous plexus*.

CAROTID PLEXUS.

The carotid plexus is situated on the outer side of the internal carotid. Filaments from this plexus occasionally form a small gangliform swelling on the under surface of the artery, which is called the carotid ganglion. The carotid plexus communicates with the Gasserian ganglion, with the sixth nerve and the spheno-palatine ganglion, and distributes filaments to the wall of the carotid artery and to the dura mater (Valentin); while in the carotid canal it communicates with Jacobson's nerve, the tympanic branch of the glosso-pharyngeal.

The *communicating branches* with the sixth nerve consist of one or two filaments which join that nerve as it lies upon the outer side of the internal carotid. Other filaments are also connected with the Gasserian ganglion. The communication with the spheno-palatine ganglion is effected by a branch, the *deep petrosal*, which is given off from the plexus on the outer side of the artery, and which passes through the cartilage, filling up the foramen lacerum medium, and joins the great superficial petrosal to form the Vidian nerve. This nerve then proceeds along the pterygoid or Vidian canal to the spheno-palatine ganglion. The communication with Jacobson's nerve is effected by a branch which passes backward to join the tympanic plexus.

CAVERNOUS PLEXUS.

The cavernous plexus is situated below and internal to that part of the internal carotid which is placed by the side of the sella Turcica in the cavernous sinus, and is formed chiefly by the internal division of the ascending branch from the superior cervical ganglion. It communicates with the third, fourth, fifth, and sixth nerves and with the ophthalmic ganglion, and distributes filaments to the wall of the internal carotid. The branch of communication with the third nerve joins it at its point of division; the branch to the fourth nerve joins it as it lies on the outer wall of the cavernous sinus; other filaments are connected with the under surface of the trunk of the ophthalmic nerve; and a second filament of communication joins the sixth nerve.

The filament of connection with the ophthalmic ganglion arises from the anterior part of the cavernous plexus; it accompanies the nasal nerve or continues forward as a separate branch.

The terminal filaments from the carotid and cavernous plexuses are prolonged along the internal carotid, forming plexuses which entwine round the cerebral and ophthalmic arteries; along the former vessels they may be traced on to the pia mater, along the latter into the orbit, where they accompany each of the subdivisions of the vessel, a separate plexus passing with the arteria centralis retinæ into the interior of the eyeball. The filaments prolonged on to the anterior communicating artery form a small ganglion, *the ganglion of Ribes*,[1] which serves, as mentioned above, to connect the sympathetic nerves of the right and left sides.

The **inferior or descending branch** of the superior cervical ganglion communicates with the middle cervical ganglion.

The **external branches** are numerous, and communicate with the cranial nerves and with the four upper spinal nerves. Sometimes the branch to the fourth spinal nerve may come from the cord connecting the upper and middle cervical ganglia. The branches of communication with the cranial nerves consist of delicate filaments which pass from the superior cervical ganglion to the ganglion of the trunk of the pneumogastric and to the twelfth nerve. A separate filament from the cervical ganglion subdivides and joins the petrosal ganglion of the glosso-pharyngeal and the ganglion of the root of the pneumogastric in the jugular foramen.

The **internal branches** are three in number—the *pharyngeal*, *laryngeal*, and *superior cardiac nerve*. The *pharyngeal* branches pass inward to the side of the pharynx, where they join with branches from the pneumogastric, glosso-pharyngeal, and external laryngeal nerves to form the *pharyngeal plexus.* The *laryngeal* branches unite with the superior laryngeal nerve and its branches.

---

[1] The existence of this ganglion is doubted by some observers.

The *superior cardiac nerve* (*nervus superficialis cordis*) arises by two or more branches from the superior cervical ganglion, and occasionally receives a filament from the cord of communication between the first and second cervical ganglia. It runs down the neck behind the common carotid artery, lying upon the Longus colli muscle, and crosses in front of the inferior thyroid artery and recurrent laryngeal nerve.

The *right superior cardiac nerve*, at the root of the neck, passes either in front of or behind the subclavian artery, and along the arteria innominata to the back part of the arch of the aorta, where it joins the deep cardiac plexus. This nerve in its course is connected with other branches of the sympathetic; about the middle of the neck it receives filaments from the external laryngeal nerve; lower down one or two twigs from the pneumogastric; and as it enters the thorax it joins with the recurrent laryngeal. Filaments from this nerve communicate with the thyroid branches from the middle cervical ganglion and accompany these nerves to the thyroid body.

The *left superior cardiac nerve*, in the chest, runs by the side of the left carotid artery and in front of the arch of the aorta to the superficial cardiac plexus, but occasionally it passes behind the aorta and terminates in the deep cardiac plexus.

The **anterior branches** ramify upon the external carotid artery and its branches, forming round each a delicate plexus, on the nerves composing which small ganglia are occasionally found. These ganglia have been named, according to their position, intercarotid[1] (placed at the angle of bifurcation of the common carotid), lingual, temporal, and pharyngeal. The plexuses accompanying some of these arteries have important communications with other nerves. That surrounding the external carotid is connected with the branch of the facial nerve to the Stylo-hyoid muscle; that surrounding the facial communicates with the submaxillary ganglion by one or two filaments; and that accompanying the middle meningeal artery sends offsets which pass to the otic ganglion and to the intumescentia gangliformis of the facial nerve (external petrosal).

The **Middle Cervical Ganglion** (*thyroid ganglion*) is the smallest of the three cervical ganglia, and is occasionally altogether wanting. It is placed opposite the fifth cervical vertebra, usually upon or close to the inferior thyroid artery; hence the name "thyroid ganglion" assigned to it by Haller.

Its **superior branches** ascend to communicate with the superior cervical ganglion.

Its **inferior branches** descend to communicate with the inferior cervical ganglion.

Its **external branches** pass outward to join the fifth and sixth spinal nerves. These branches are not constantly found.

Its **internal branches** are the thyroid and the middle cardiac nerve.

The *thyroid branches* are small filaments which accompany the inferior thyroid artery to the thyroid gland; they communicate on the artery with the superior cardiac nerve, and in the gland with branches from the recurrent and external laryngeal nerves.

The *middle cardiac nerve* (*nervus cardiacus magnus*), the largest of the three cardiac nerves, arises from the middle cervical ganglion or from the cord between the middle and inferior ganglia. On the right side it descends behind the common carotid artery, and at the root of the neck passes either in front of or behind the subclavian artery; it then descends on the trachea, receives a few filaments from the recurrent laryngeal nerve, and joins the deep cardiac plexus. In the neck it communicates with the superior cardiac and recurrent laryngeal nerves. On the left side the middle cardiac nerve enters the chest between the left carotid and subclavian arteries, and joins the left side of the deep cardiac plexus.

---

[1] This ganglion is of the same structure as the coccygeal gland (Luschka).

The **Inferior Cervical Ganglion** is situated between the base of the transverse process of the last cervical vertebra and the neck of the first rib, on the inner side of the superior intercostal artery. Its form is irregular; it is larger in size than the preceding and frequently joined with the first thoracic ganglion.

Its **superior branches** communicate with the middle cervical ganglion.

Its **inferior branches** descend, some in front of, others behind, the subclavian artery to join the first thoracic ganglion. The most important of these branches constitutes the inferior cardiac nerve.

The *inferior cardiac nerve* (*nervus cardiacus minor*) arises from the inferior cervical or first thoracic ganglion. It passes down behind the subclavian artery and along the front of the trachea to join the deep cardiac plexus. It communicates freely behind the subclavian artery with the recurrent laryngeal and middle cardiac nerves.

The **external branches** consist of several filaments, some of which communicate with the seventh and eighth spinal nerves; others accompany the vertebral artery along the vertebral canal, forming a plexus round the vessel, supplying it with filaments and communicating with the cervical spinal nerves as high as the fourth.

THORACIC PORTION OF THE GANGLIATED CORD.

The thoracic portion of the gangliated cord consists of a series of ganglia which usually correspond in number to that of the vertebræ, but from the occasional coalescence of two their number is uncertain. These ganglia are placed on each side of the spine, resting against the heads of the ribs and covered by the pleura costalis: the last two are, however, anterior to the rest, being placed on the side of the bodies of the vertebræ. The ganglia are small in size and of a grayish color. The first, larger than the rest, is of an elongated form and usually blended with the last cervical. They are connected together by cord-like prolongations from their substance.

The **external branches** from each ganglion, usually two in number, communicate with each of the dorsal spinal nerves.

The **internal branches** *from the six upper ganglia* are very small; they supply filaments to the thoracic aorta and its branches, besides small branches to the bodies of the vertebræ and their ligaments. Branches from the third and fourth ganglia form part of the posterior pulmonary plexus.

The *internal branches from the six lower ganglia* are large and white in color; they distribute filaments to the aorta and unite to form the three splanchnic nerves. These are named the *great*, the *lesser*, and the *smallest* or *renal splanchnic*.

The *great splanchnic nerve* is of a white color, firm in texture, and bears a marked contrast to the ganglionic nerves. It is formed by branches from the thoracic ganglia between the sixth and tenth, receiving filaments (according to Dr. Beck) from all the thoracic ganglia above the sixth. These roots unite to form a large round cord of considerable size. It descends obliquely inward in front of the bodies of the vertebræ along the posterior mediastinum, perforates the crus of the Diaphragm, and terminates in the semilunar ganglion, distributing filaments to the renal and suprarenal plexus.

The *lesser splanchnic nerve* is formed by filaments from the tenth and eleventh ganglia and from the cord between them. It pierces the Diaphragm with the preceding nerve, and joins the cœliac plexus. It communicates in the chest with the great splanchnic nerve, and occasionally sends filaments to the renal plexus.

The *smallest* or *renal splanchnic nerve* arises from the last ganglion, and, piercing the Diaphragm, terminates in the renal plexus and lower part of the cœliac plexus. It occasionally communicates with the preceding nerve.

A striking analogy appears to exist between the splanchnic and the cardiac nerves. The cardiac nerves are three in number: they arise from the three cervical ganglia, and are distributed to a large and important organ in the thoracic cavity. The splanchnic nerves, also three in number, are connected probably with all the dorsal ganglia, and are distributed to important organs in the abdominal cavity.

THE LUMBAR PORTION OF THE GANGLIATED CORD.

The lumbar portion of the gangliated cord is situated in front of the vertebral column, along the inner margin of the Psoas muscle. It consists usually of four ganglia connected together by interganglionic cords. The ganglia are of small size, of a grayish color, shaped like a barleycorn, and placed much nearer the median line than the thoracic ganglia.

The **superior** and **inferior branches** of the lumbar ganglia serve as communicating branches between the chain of ganglia in this region. They are usually single and of a white color.

The **external branches** communicate with the lumbar spinal nerves. From the situation of the lumbar ganglia these branches are longer than in the other regions. They are usually two in number from each ganglion, and accompany the lumbar arteries around the sides of the bodies of the vertebræ, passing beneath the fibrous arches from which some of the fibres of the Psoas muscle arise.

The **internal branches** pass inward in front of the aorta and form the aortic plexus. Other branches descend in front of the common iliac arteries, and join, over the promontory of the sacrum, to form the hypogastric plexus. Numerous delicate filaments are also distributed to the bodies of the vertebræ and the ligaments connecting them.

PELVIC PORTION OF THE GANGLIATED CORD.

The pelvic portion of the gangliated cord is situated in front of the sacrum, along the inner side of the anterior sacral foramina. It consists of four or five small ganglia on each side connected together by interganglionic cords. Below, these cords converge and unite on the front of the coccyx by means of a small ganglion (*the coccygeal ganglion* or *ganglion impar*).

The **superior** and **inferior branches** are the cords of communication between the ganglia above and below.

The **external branches**, exceedingly short, communicate with the sacral nerves. They are two in number from each ganglion. The coccygeal nerve communicates either with the last sacral or coccygeal ganglion.

The **internal branches** communicate, on the front of the sacrum, with the corresponding branches from the opposite side; some, from the first two ganglia, pass to join the pelvic plexus, and others form a plexus which accompanies the middle sacral artery.

THE GREAT PLEXUSES OF THE SYMPATHETIC.

The Great Plexuses of the Sympathetic are the large aggregations of nerves and ganglia above alluded to, and situated in the thoracic, abdominal, and pelvic cavities respectively. From them are derived the branches which supply the viscera.

THE CARDIAC PLEXUS.

The cardiac plexus is situated at the base of the heart, and is divided into a *superficial* part, which lies in the concavity of the arch of the aorta, and a *deep* part, which lies between the trachea and aorta.

The **Great** or **Deep Cardiac Plexus** (*plexus magnus profundus*, Scarpa) is situated in front of the trachea at its bifurcation, above the point of division of the pulmonary artery and behind the arch of the aorta. It is formed by the cardiac nerves derived from the cervical ganglia of the sympathetic and the cardiac branches of the recurrent laryngeal and pneumogastric. The only cardiac nerves which do not enter into the formation of this plexus are the left superior cardiac nerve and the left inferior cervical cardiac branch from the pneumogastric. The branches derived from the great cardiac plexus form the posterior coronary plexus and part of the anterior coronary plexus, whilst a few filaments proceed to the pulmonary plexuses and to the auricles of the heart.

The branches from the *right side* of this plexus pass, some in front of, and others behind, the right pulmonary artery; the former, the more numerous, transmit a few filaments to the anterior pulmonary plexus, and are continued along the trunk of the pulmonary artery to form part of the anterior coronary plexus; those behind the pulmonary artery distribute a few filaments to the right auricle and form part of the posterior coronary plexus.

The branches from the *left side* of the deep cardiac plexus distribute a few filaments to the left auricle of the heart and the anterior pulmonary plexus, and then pass on to form the greater part of the posterior coronary plexus, a few branches passing to the superficial cardiac plexus.

The **Superficial (Anterior) Cardiac Plexus** lies beneath the arch of the aorta in front of the right pulmonary artery. It is formed by the left superior cardiac nerve, the left (and occasionally the right) inferior cervical cardiac branches of the pneumogastric, and filaments from the deep cardiac plexus. A small ganglion (*cardiac ganglion of Wrisberg*) is occasionally found connected with these nerves at their point of junction. This ganglion, when present, is situated immediately beneath the arch of the aorta on the right side of the ductus arteriosus. The superficial cardiac plexus forms the chief part of the anterior coronary plexus, and several filaments pass along the pulmonary artery to the left anterior pulmonary plexus.

The **posterior coronary plexus** is chiefly formed by filaments prolonged from the left side of the deep cardiac plexus, and by a few from the right side. It surrounds the branches of the coronary artery at the back of the heart, and its filaments are distributed with those vessels to the muscular substance of the ventricles.

The **anterior coronary plexus** is formed chiefly from the superficial cardiac plexus, but receives filaments from the deep cardiac plexus. Passing forward between the aorta and pulmonary artery, it accompanies the left coronary artery on the anterior surface of the heart.

Valentin has described nervous filaments ramifying under the endocardium; and Remak has found in several Mammalia numerous small ganglia on the cardiac nerves, both on the surface of the heart and in its muscular substance. The elaborate dissections of the late Dr. Robert Lee have demonstrated without any doubt the existence of a dense mesh of nerves, distributed both to the surface and in the substance of the heart, having numerous ganglia developed upon them [similar to those of the uterus (Fig. 522)].

THE EPIGASTRIC OR SOLAR PLEXUS.

The **Epigastric** or **Solar Plexus** supplies all the viscera in the abdominal cavity. It consists of a great network of nerves and ganglia situated behind the stomach and in front of the aorta and crura of the Diaphragm. It surrounds the cœliac axis and root of the superior mesenteric artery, extending downward as low as the pancreas and outward to the suprarenal capsules. This plexus and the ganglia connected with it receive the great splanchnic nerve of both sides and some filaments from the right pneumogastric. It distributes filaments which accompany, under the name of plexuses, all the branches from the front of the abdominal aorta.

The **semilunar ganglia** of the solar plexus, two in number, one on each side, are the largest ganglia in the body. They are large, irregular gangliform masses formed by the aggregation of smaller ganglia, having interspaces between them. They are situated in front of the crura of the Diaphragm, close to the suprarenal capsules: the one on the right side lies beneath the inferior vena cava; the upper part of each ganglion is joined by the greater splanchnic nerve, and to the inner side of each the branches of the solar plexus are connected.

From the solar plexus are derived the following:

Phrenic or diaphragmatic plexus.
Suprarenal plexus.
Renal plexus.
Spermatic plexus.
Cœliac plexus.
Superior mesenteric plexus.
Aortic plexus.

The **phrenic plexus** accompanies the phrenic artery to the Diaphragm, which it supplies, some filaments passing to the suprarenal capsule. It arises from the upper part of the semilunar ganglion, and is larger on the right than on the left side. It receives one or two branches from the phrenic nerve. In connection with this plexus, on the right side, at its point of junction with the phrenic nerve, is a small ganglion (*ganglion diaphragmaticum*). This ganglion is placed on the under surface of the Diaphragm near the suprarenal capsule. Its branches are distributed to the inferior vena cava, suprarenal capsule, and the hepatic plexus. There is no ganglion on the left side.

The **suprarenal plexus** is formed by branches from the solar plexus, from the semilunar ganglion, and from the phrenic and great splanchnic nerves, a ganglion being formed at the point of junction of the latter nerve. It supplies the suprarenal capsule. The branches of this plexus are remarkable for their large size in comparison with the size of the organ they supply.

The **renal plexus** is formed by filaments from the solar plexus, the outer part of the semilunar ganglion, and the aortic plexus. It is also joined by filaments from the lesser and smallest splanchnic nerves. The nerves from these sources, fifteen or twenty in number, have numerous ganglia developed upon them. They accompany the branches of the renal artery into the kidney, some filaments on the right side being distributed to the inferior vena cava, and others to the spermatic plexus on both sides.

The **spermatic plexus** is derived from the renal plexus, receiving branches from the aortic plexus. It accompanies the spermatic vessels to the testes.

In the female the **ovarian plexus** is distributed to the ovaries and fundus of the uterus.

The **cœliac plexus**, of large size, is a direct continuation from the solar plexus: it surrounds the cœliac axis and subdivides into the gastric, hepatic, and splenic plexuses. It receives branches from the lesser splanchnic nerves, and on the left side a filament from the right pneumogastric.

The *gastric* or *coronary plexus* accompanies the gastric artery along the lesser curvature of the stomach and joins with branches from the left pneumogastric nerve. It is distributed to the stomach.

The *hepatic plexus*, the largest offset from the cœliac plexus, receives filaments from the left pneumogastric and right phrenic nerves. It accompanies the hepatic artery, ramifying in the substance of the liver, upon its branches, and upon those of the vena portæ.

Branches from this plexus accompany all the divisions of the hepatic artery. Thus there is a *pyloric* plexus accompanying the pyloric branch of the hepatic which joins with the gastric plexus and pneumogastric nerves. There is also a *gastro-duodenal* plexus, which subdivides into the pancreatico-duodenal plexus, which accompanies the pancreatico-duodenal artery to supply the pancreas and duodenum, joining with branches from the mesenteric plexus; and a *gastro-epiploic* plexus, which accompanies the right gastro-epiploic artery along the greater curvature of the stomach and anastomoses with branches from the splenic plexus. A *cystic* plexus, which supplies the gall-bladder, also arises from the hepatic plexus near the liver.

The *splenic plexus* is formed by branches from the cœliac plexus, the left semilunar ganglia, and from the right pneumogastric nerve. It accompanies the splenic artery and its branches to the substance of the spleen, giving off in its course filaments to the pancreas (*pancreatic plexus*) and the *left gastro-epiploic plexus*, which accompanies the gastro-epiploica sinistra artery along the convex border of the stomach.

FIG. 522.

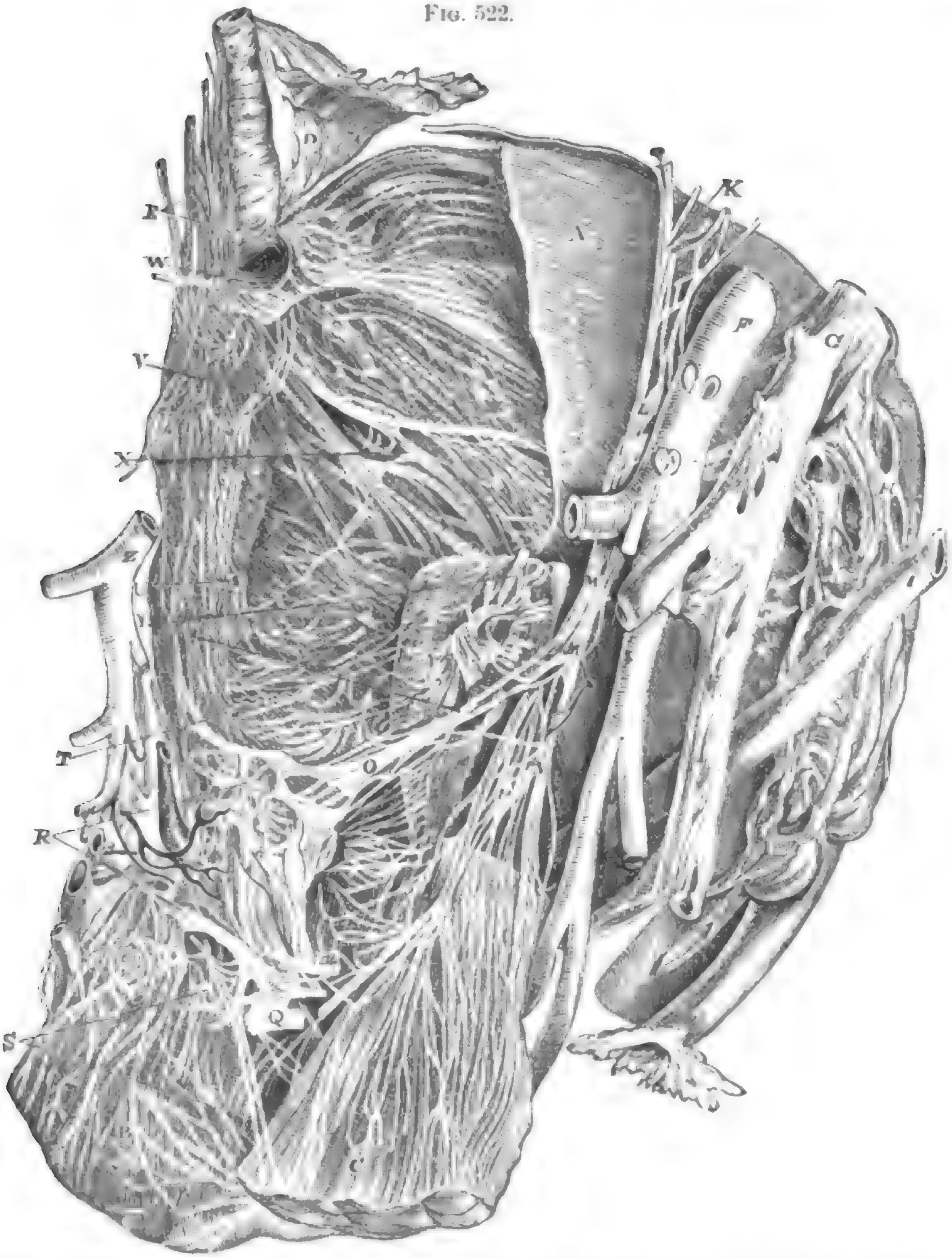

Ganglia and Nerves of the Gravid Uterus at the end of the Ninth Month (after Dr. R. Lee): A, the fundus and body of the uterus, having the peritoneum dissected off from the left side; B, the vagina, covered with nerves proceeding from the inferior border of the left hypogastric ganglion; C, the rectum; D, the left ovarium and Fallopian tube; E, the trunk of the left spermatic vein and artery surrounded by the left spermatic ganglion; F, the aorta divided a little above the origin of the right spermatic artery, and about three inches above its division into the two common iliac arteries; G, the vena cava; H, trunk of the right spermatic vein entering the vena cava; I, right ureter; K, the two cords of the great sympathetic nerve, passing down along the front of the aorta; L, trunk of the inferior mesenteric artery, passing off from the aorta and covered with a great plexus of nerves sent off from the left and right cords of the great sympathetic; M, M, the two cords of the great sympathetic, passing down below the bifurcation of the aorta to the point where they separate into the right and left hypogastric nerves; N, the right hypogastric nerve with its artery injected proceeding to the neck of the uterus, to terminate in the right hypogastric ganglion; O, the left hypogastric nerve where it is entering the left hypogastric ganglion and giving off branches to the left subperitoneal ganglion; P, hemorrhoidal nerves, accompanying the hemorrhoidal artery and proceeding from the great plexus which surrounds the inferior mesenteric artery; Q, the sacral nerves, entering the whole outer surface of the hypogastric ganglion; R, the left hypogastric ganglion, with its arteries injected; S, the nerves of the vagina; T, nerves, with an injected artery proceeding from the upper part of the left hypogastric ganglion along the body of the uterus and terminating in the left spermatic ganglion; U, continuation of these nerves and the branches which they give off to the subperitoneal plexuses; V, the same nerves passing upward beneath the subperitoneal plexuses, and anastomosing freely with them; W, the left spermatic ganglion, in which the nerves and artery from the hypogastric ganglion and the branches of the left subperitoneal plexuses terminate, and from which the nerves of the fundus uteri are supplied; X, the left subperitoneal plexuses covering the body of the uterus; Y, the left subperitoneal ganglion, with numerous branches of nerves extending between it and the left hypogastric nerve and ganglion; Z, the left common iliac artery cut across and turned aside, that the left hypogastric nerve and ganglion might be traced and exposed.

The **superior mesenteric plexus** is a continuation of the lower part of the great solar plexus, receiving a branch from the junction of the right pneumogastric nerve with the cœliac plexus. It surrounds the superior mesenteric artery, which it accompanies into the mesentery, and divides into a number of secondary plexuses which are distributed to all the parts supplied by the artery—viz. pancreatic branches to the pancreas; intestinal branches which supply the whole of the small intestine; and ileo-colic, right colic, and middle colic branches which supply the corresponding parts of the great intestine. The nerves composing this plexus are white in color and firm in texture, and have numerous ganglia developed upon them near their origin.

The **aortic plexus** is formed by branches derived on each side from the semilunar ganglia and renal plexuses, receiving filaments from the solar plexus and some of the lumbar ganglia. It is situated upon the sides and front of the aorta, between the origins of the superior and inferior mesenteric arteries. From this plexus arise the inferior mesenteric, part of the spermatic, and the hypogastric plexuses, and it distributes filaments to the inferior vena cava.

The *inferior mesenteric plexus* is derived chiefly from the left side of the aortic plexus. It surrounds the inferior mesenteric artery, and divides into a number of secondary plexuses, which are distributed to all the parts supplied by the artery—viz. the left colic and sigmoid plexuses, which supply the descending and sigmoid flexure of the colon, and the superior hemorrhoidal plexus, which supplies the upper part of the rectum and joins in the pelvis with branches from the left hypogastric plexus.

HYPOGASTRIC PLEXUS.

The **Hypogastric Plexus** supplies the viscera of the pelvic cavity. It is situated in front of the promontory of the sacrum between the two common iliac arteries, and is formed by the union of numerous filaments which descend on each side from the aortic plexus and from the lumbar ganglia. This plexus contains no ganglia, and bifurcates below into two lateral portions, which form the *pelvic plexuses.*

PELVIC PLEXUS.

The **Pelvic Plexus** (sometimes called *inferior hypogastric*) is situated at the side of the rectum and bladder in the male, and at the side of the rectum, vagina, and bladder in the female. It is formed by a continuation of the hypogastric plexus, by branches from the second, third, and fourth sacral nerves, and by a few filaments from the first two sacral ganglia. At the point of junction of these nerves small ganglia are found. From this plexus numerous branches are distributed to all the viscera of the pelvis. They accompany the branches of the internal iliac artery.

The **Inferior Hemorrhoidal Plexus** arises from the back part of the pelvic plexus. It supplies the rectum, joining with branches of the superior hemorrhoidal plexus.

The **Vesical Plexus** arises from the fore part of the pelvic plexus. The nerves composing it are numerous and contain a large proportion of spinal nerve-fibres. They accompany the vesical arteries and are distributed at the side and base of the bladder. Numerous filaments also pass to the vesiculæ seminales and vas deferens; those accompanying the vas deferens join, on the spermatic cord, with branches from the spermatic plexus.

The **Prostatic Plexus** is continued from the lower part of the pelvic plexus. The nerves composing it are of large size. They are distributed to the prostate gland, vesiculæ seminales, and erectile structure of the penis. The nerves supplying the erectile structure of the penis consist of two sets, the small and large cavernous nerves. They are slender filaments, which arise from the fore part of the prostatic plexus, and after joining with branches from the internal pudic nerve pass forward beneath the pubic arch.

The *small cavernous nerves* perforate the fibrous covering of the penis near its roots.

The *large cavernous nerve* passes forward along the dorsum of the penis, joins with the dorsal branch of the pudic nerve, and is distributed to the corpus cavernosum and spongiosum.

The **Vaginal Plexus** arises from the lower part of the pelvic plexus. It is lost on the walls of the vagina, being distributed to the erectile tissue at its anterior part and to the mucous membrane. The nerves composing this plexus contain, like the vesical, a large proportion of spinal nerve-fibres.

The **Uterine Plexus** arises from the upper part of the pelvic plexus, above the point where the branches from the sacral nerves join the plexus. Its branches accompany the uterine arteries to the side of the organ between the layers of the broad ligament, and are distributed to the cervix and lower part of the body of the uterus, penetrating its substance.

Other filaments pass separately to the body of the uterus and Fallopian tube.

Branches from the hypogastric plexus accompany the uterine arteries into the substance of the uterus. Upon these filaments ganglionic enlargements are found.

(For a detailed account of the supply of nerves to the uterus, and for a description of the changes which these nerves and their ganglia undergo during pregnancy, the reader is referred to the papers on *The Anatomy of the Nerves of the Uterus*, published by Dr. Robert Lee. [A similar work has been published by the same author on the *Nerves of the Heart*.])

Organs of Sense.

THE organs of the senses are five in number—viz. those of touch, of taste, of smell, of hearing, and of sight. The skin, which is the principal seat of the sense of touch, has been described in the chapter on General Anatomy.

THE TONGUE.

The **Tongue** is the organ of the special sense of taste. It is situated in the floor of the mouth, in the interval between the two lateral portions of the body of the lower jaw. Its base or root is directed backward, and connected with the os hyoides by numerous muscles, with the epiglottis by three folds of mucous membrane which form the *glosso-epiglottic ligaments*, and with the soft palate by means

FIG. 523.

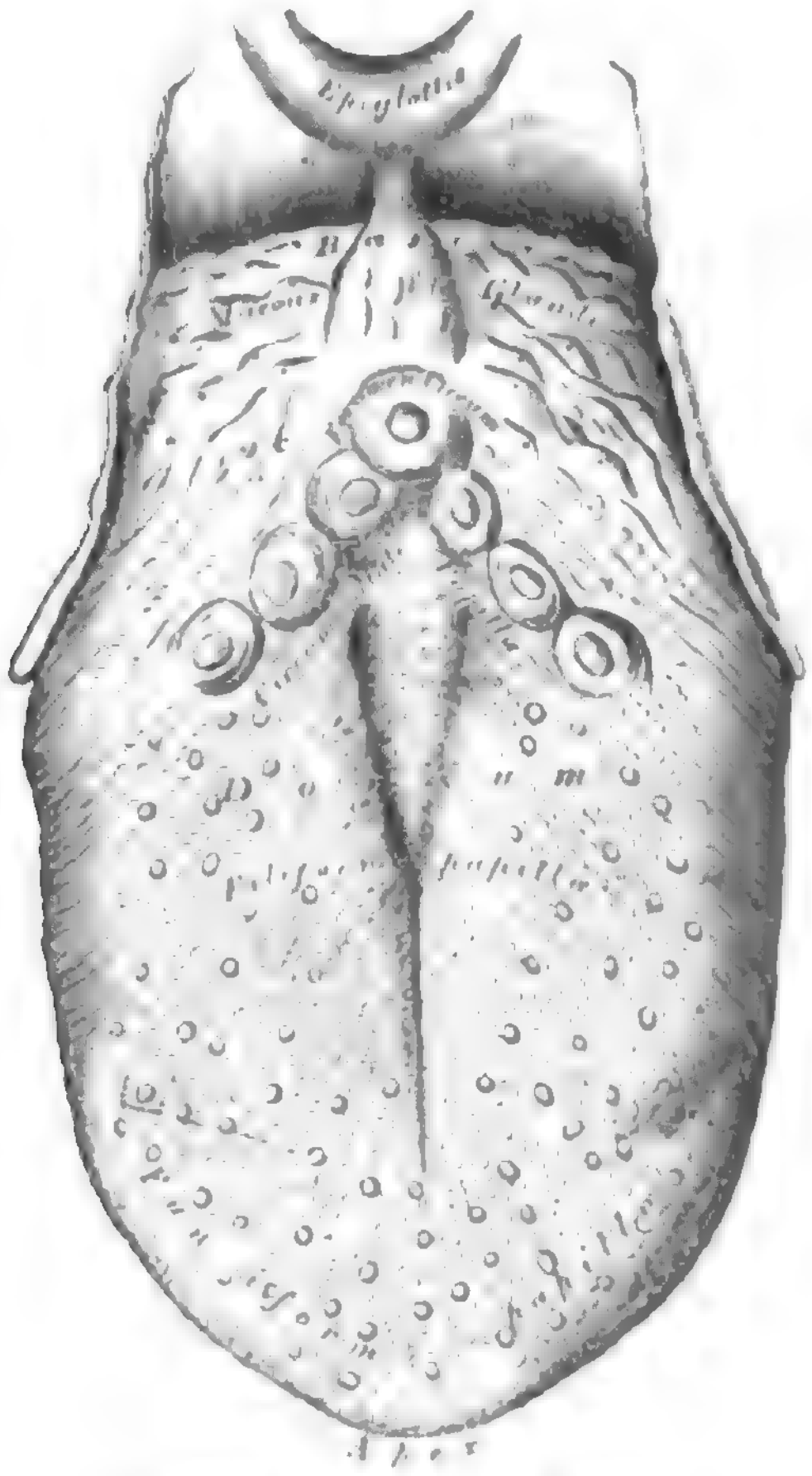
Epiglottis
Mucous Glands
Apex

Upper Surface of the Tongue.

FIG. 524.


Filiform
Art'y
Vein

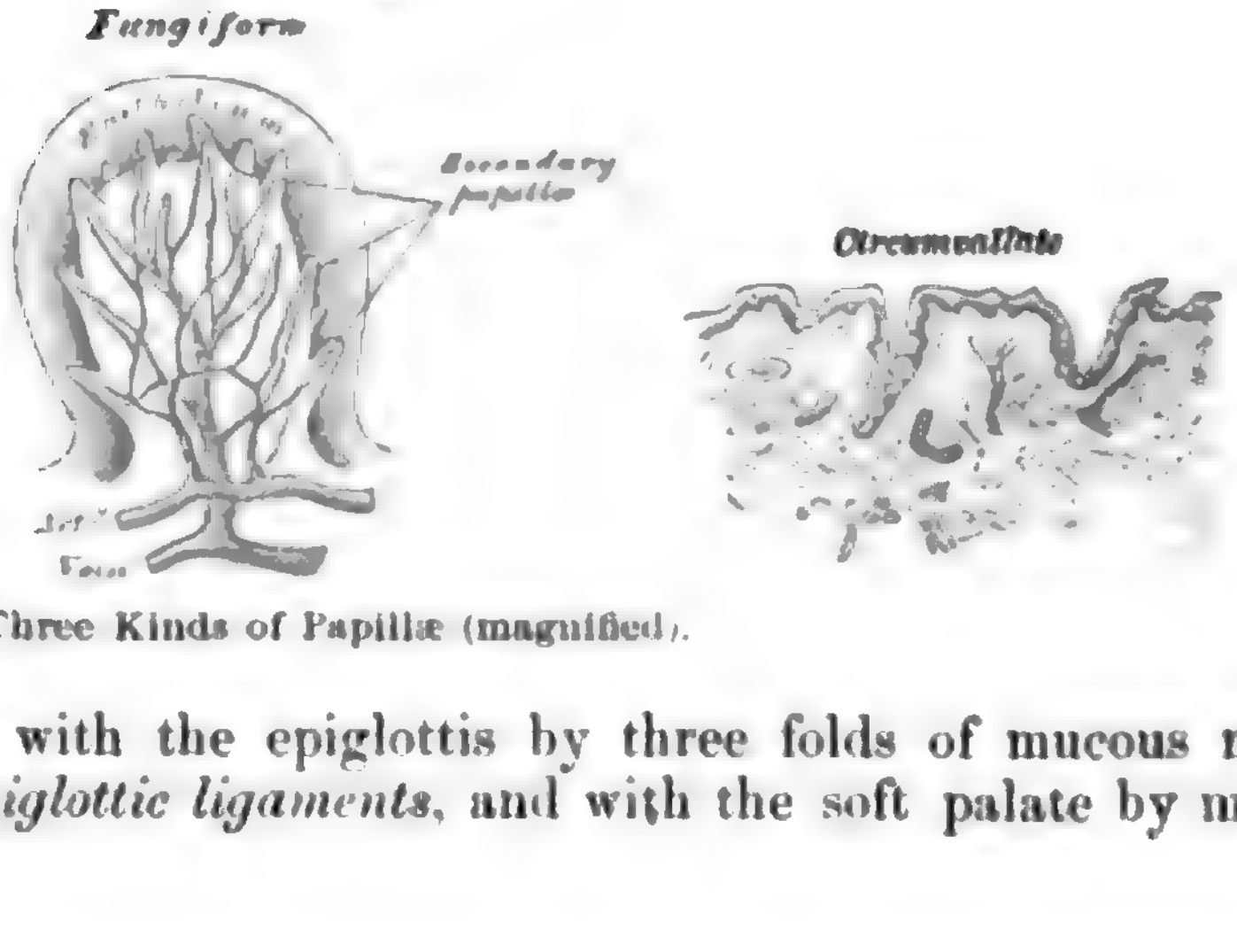
Fungiform
Secondary papillæ
Circumvallate

The Three Kinds of Papillæ (magnified).

of the anterior pillars of the fauces. Its apex or tip, thin and narrow, is directed forward against the inner surface of the lower incisor teeth. The under surface of the tongue is connected with the lower jaw by the Genio-hyo-glossi muscles; from its sides the mucous membrane is reflected to the inner surface of the gums; and in front a distinct fold of that membrane, the *frænum linguæ*, is formed beneath its under surface.

The *tip* of the tongue, part of the under surface, its sides, and dorsum are free.

The dorsum of the tongue is convex, marked along the middle line by a raphé, which divides it into two symmetrical halves; this raphé terminates behind about half an inch from the base of the organ, a little in front of a depression, the *foramen cæcum.* The anterior two-thirds of this surface are rough and covered with papillæ; the posterior third is smoother and covered by the projecting orifices of numerous muciparous glands.

The **mucous membrane** invests the entire extent of the free surface of the tongue. On the under surface of the organ it is thin and smooth, and may be traced on either side of the frænum through the ducts of the submaxillary glands, and between the sides of the tongue and the lower jaw through the ducts of the sublingual glands. As it passes over the borders of the organ it gradually assumes its papillary character.

Structure.—The mucous membrane of the tongue differs in structure in several respects from that of other parts. That covering the under surface of the organ is identical in structure with that lining the rest of the oral cavity. The mucous membrane on the anterior part of the dorsum of the tongue is thin and intimately adherent to the muscular tissue, whilst that at the root is much thicker and looser. It consists of a layer of connective tissue, the *corium* or *mucosa*, supporting numerous *papillæ*, and covered, as well as the papillæ, with *epithelium.*

The *corium* consists of a dense network of fibrous connective tissue, with numerous elastic fibres, firmly connected with the fibrous tissue forming the septa between the muscular bundles of the tongue. It contains the ramifications of the numerous vessels and nerves from which the papillæ are supplied, and large plexuses of lymphatic vessels.

The *papillæ* consist of papillary projections of the corium, and like it are made up of fibrous connective tissue, which forms a matrix supporting a complex loop of capillary blood-vessels and covered with epithelium.

The *papillæ* of the tongue are thickly distributed over the anterior two-thirds of its upper surface, giving to it its characteristic roughness. The principal varieties are the papillæ maximæ (*circumvallatæ*), papillæ mediæ (*fungiformes*), and papillæ minimæ (*conicæ* or *filiformes*).

The *papillæ maximæ* (circumvallatæ) are of large size and vary from eight to ten in number. They are situated at the back part of the dorsum of the tongue, near its base, forming a row on each side, which, running backward and inward, meet in the middle line like the two lines of the letter V inverted. Each papilla consists of a central flattened projection of mucous membrane, from $\frac{1}{24}$ to $\frac{1}{12}$ of an inch wide, attached to the bottom of a cup-shaped depression of the mucous membrane; the papilla is in shape like a truncated cone, the smaller end being directed downward and attached to the tongue, the broader part or base projecting on the surface and being studded with numerous small secondary papillæ, which, however, are covered by a smooth layer of the epithelium. The cup-shaped depression forms a kind of fossa round the papilla, having a circular margin of about the same elevation covered with smaller papillæ. At the point of junction of the two rows of papillæ is the deep depression, the *foramen cæcum*, mentioned above.

The *papillæ mediæ* (fungiformes), more numerous than the preceding, are scattered irregularly and sparingly over the dorsum of the tongue, but are found chiefly at its sides and apex. They are easily recognized among the other papillæ by their large size, rounded eminences, and deep-red color. They are narrow at their attachment to the tongue, but broad and rounded at their free extremities, and covered with secondary papillæ. Their epithelial investment is very thin.

The *papillæ minimæ* (conicæ or filiformes) cover the anterior two-thirds of the dorsum of the tongue. They are very minute, more or less conical or filiform in shape, and arranged in lines corresponding in direction with the two rows of the papillæ circumvallatæ, excepting at the apex of the organ, where their direction is transverse. They have projecting from their apices numerous filiform processes or secondary papillæ, which are of a whitish tint, owing to the thickness and density of the epithelium of which they are composed, and which has here undergone a peculiar modification, the cells having become cornified and elongated into dense, imbricated, brush-like processes. They contain also a number of elastic fibres, which render them firmer and more elastic than the papillæ of mucous membrane generally.

Simple papillæ, similar to those of the skin, are disposed very unequally among the compound forms, and exist sparingly on the surface of the tongue behind the circumvallate variety, buried under a layer of epithelium.

Structure of the Papillæ.—The papillæ apparently resemble in structure those of the cutis, consisting of a cone-shaped projection of connective tissue covered with a thick layer of squamous epithelium, and contain one or more capillary loops, amongst which nerves are distributed in great abundance. If the epithelium is removed, it will be found that they are not simple elevations like the papillæ of the skin, for the surface of each is studded with minute conical processes of the mucous membrane, which form secondary papillæ (Todd and Bowman). In the papillæ circumvallatæ the nerves are numerous and of large size; in the papillæ fungiformes they are also numerous, and terminate in a plexiform network, from which brush-like branches proceed; in the papillæ filiformes their mode of termination is uncertain. Buried in the epidermis of the papillæ circumvallatæ and in some of the fungiformes certain peculiar bodies called *taste-goblets* have been described.[1] They are flask-like in shape, their broad base resting on the corium, and their neck opening by an orifice between the cells of the epithelium. They are formed by two kinds of cells: the exterior (cortical), which are arranged in several layers, being spindle-shaped and flattened, and in contact by their edges, the tapering extremities extending from the base to the apex of the organ. They thus enclose the central cells (gustatory cells), which are also spindle-shaped, but not flattened, and have a large spherical nucleus about the middle of the cell. Both extremities are filamentous: the inner process is described as continuous with the terminal fibril of a nerve, while the outer one projects as an extremely fine hair through the orifice of the taste-goblet.[2]

FIG. 525.

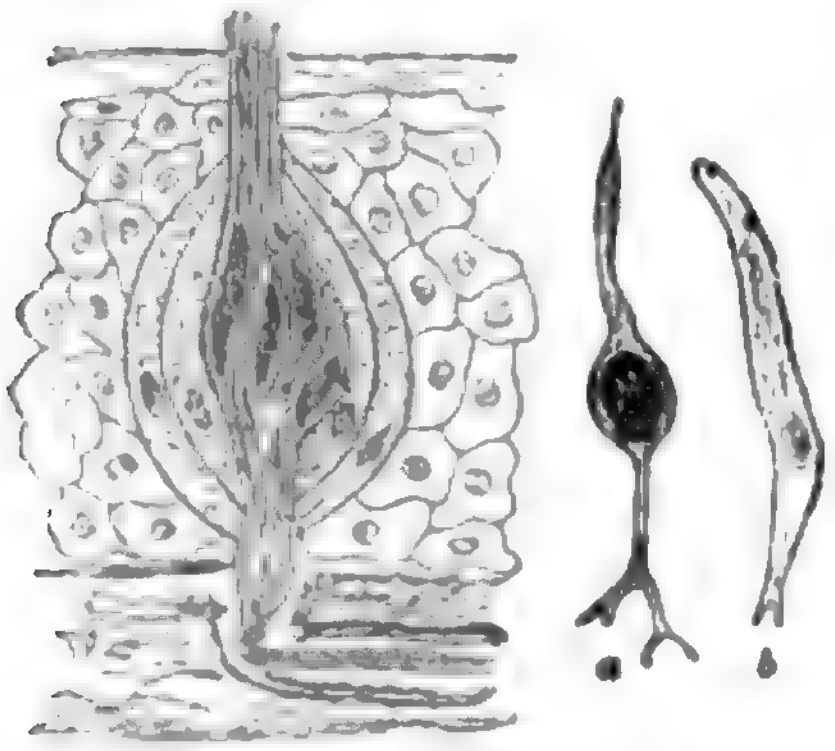

Taste-goblets: *a*, central cell; *b*, cortical cell.

Besides the papillæ, the mucous membrane of the tongue is provided with glands, and at the posterior part contains large quantities of lymphoid tissue.

There are two varieties of glands present in the tongue, the *mucous* and *serous*.

The *mucous* are similar in structure to the labial and buccal glands. They are found all over the surface of the mucous membrane of the tongue, except in the immediate vicinity of the taste-goblets; chiefly at the back, but also at the apex and marginal parts. In connection with these glands a special one has been described by Blandin and Nuhn. It is situated near the apex of the tongue on either side of the frænum, and is covered over by a fasciculus of muscular fibre derived from the Stylo-glossus and Inferior lingualis. It is from half an inch to nearly an inch long, and about the third of an inch broad. It has from four to six orifices, which open on the under surface of the apex.

The *serous glands* occur only at the back of the tongue in the neighborhood of the taste-goblets, their ducts opening for the most part into the fossæ of the circumvallate papillæ. These glands are racemose, the duct branching into several minute ducts, which terminate in alveoli lined by a single layer of more or less columnar epithelium. Their secretion is of a watery nature, and probably assists in the distribution of the substance to be tasted over the taste-area (Ebner).

---

[1] These bodies are also found in considerable numbers at the side of the base of the tongue, just in front of the anterior pillars of the fauces.

[2] See Engelmann, in *Stricker's Handbook* (New Syd. Soc. Trans.), vol. iii. p. 2.

The *lymphoid tissue* is situated, for the most part, at the back of the tongue, between the epiglottis and the circumvallate papillæ, and is collected at numerous points into distinct masses known as *follicles*. Here and there in this situation are depressions in the mucous membrane surrounded by nodules of lymphoid tissue, similar to the structure found in the tonsil: into them open some of the ducts of the mucous glands.

The *epithelium* is of the scaly variety, like that of the epidermis. It covers the free surface of the tongue, as may be easily demonstrated by maceration or boiling, when it can be detached entire; it is much thinner than in the skin: the intervals between the large papillæ are not filled up by it, but each papilla has a separate investment from root to summit. The deepest cells may sometimes be detached as a separate layer, corresponding to the rete mucosum, but they never contain coloring matter.

The tongue consists of two symmetrical halves, separated from each other in the middle line by a fibrous septum. Each half is composed of muscular fibres arranged in various directions, containing much interposed fat and supplied by vessels and nerves, and partly invested by mucous membrane and a submucous fibrous stratum. Into the latter the muscular fibres are inserted that pass to the surface. It is thicker behind than in front, and is continuous with the sheaths of the muscles attached to it.

The *fibrous septum* consists of a vertical layer of fibrous tissue extending throughout the entire length of the middle line of the tongue from the base to the apex. It is thicker behind than in front, and occasionally contains a small fibro-cartilage about a quarter of an inch in length. It is well displayed by making a vertical section across the organ [Fig. 294, p. 391]. Another strong, fibrous lamina, termed the *hypoglossal membrane*, connects the under surface of the base of the tongue to the body of the hyoid bone. This membrane receives in front some of the fibres of the Genio-hyo-glossi.

Each half of the tongue consists of extrinsic and intrinsic muscles. The former have been already described; they are the Hyo-glossus, Genio-hyo-glossus, Stylo-glossus, Palato-glossus, and part of the Superior constrictor. The intrinsic muscular fibres are described along with the Lingualis on p. 391.

The *arteries* of the tongue are derived from the lingual, the facial, and ascending pharyngeal.

The *nerves* of the tongue are four in number in each half: the gustatory branch of the fifth, which is distributed to the papillæ at the fore part and sides of the tongue; the lingual branch of the glosso-pharyngeal, which is distributed to the mucous membrane at the base and side of the tongue and to the papillæ circumvallatæ; the hypoglossal nerve, which is distributed to the muscular substance of the tongue; and the chorda tympani, to the Lingualis muscle. The glosso-pharyngeal branch is the special nerve of the sense of taste; the gustatory is the nerve of common sensation, and may possibly be concerned in the sense of taste: and the hypoglossal is the motor nerve of the tongue.

THE NOSE.

The nose is the special organ of the sense of smell: by means of the peculiar properties of its nerves it protects the lungs from the inhalation of deleterious gases and assists the organ of taste in discriminating the properties of food.

The organ of smell consists of two parts—one external, the *nose;* the other internal, the *nasal fossæ*.

The *nose* is the more anterior and prominent part of the organ of smell. It is of a triangular form, directed vertically downward, and projects from the centre of the face immediately above the upper lip. Its summit or root is connected directly with the forehead. Its inferior part, the base of the nose, presents two elliptical orifices, the nostrils, separated from each other by an antero-posterior septum, the *columna*. The margins of these orifices are provided with a number of stiff hairs, or *vibrissæ*, which arrest the passage of foreign substances carried with the current of air intended for respiration. The lateral surfaces of the nose form by their union *the dorsum*, the direction of which varies considerably in different individuals. The dorsum terminates below in a rounded eminence, the *lobe* of the nose.

The nose is composed of a framework of bones and cartilages, the latter being slightly acted upon by certain muscles. It is covered externally by the integument, internally by mucous membrane, and supplied with vessels and nerves.

FIG. 526.

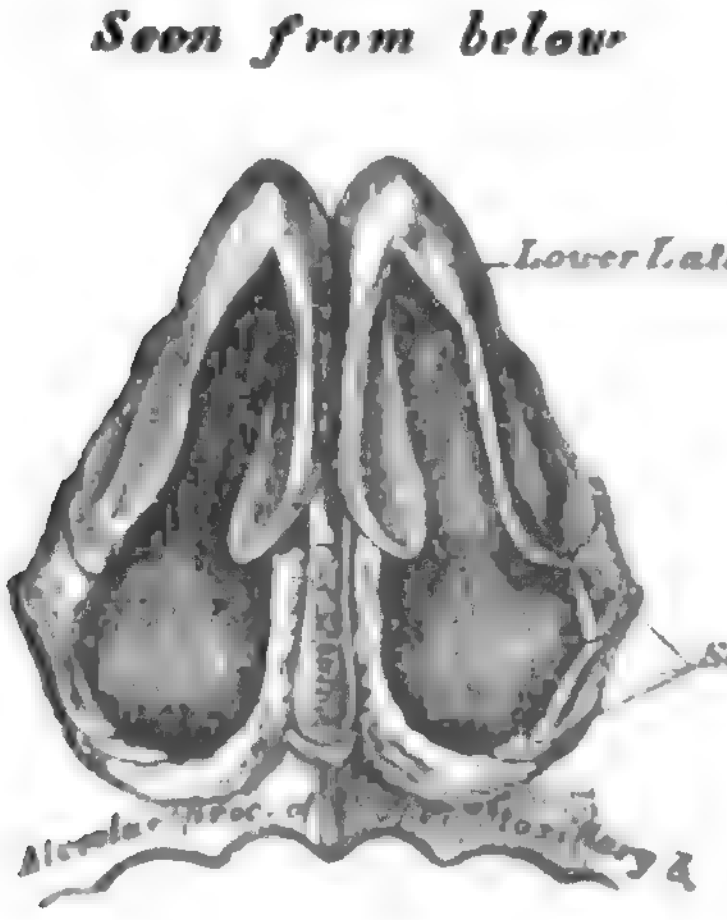

FIG. 527.

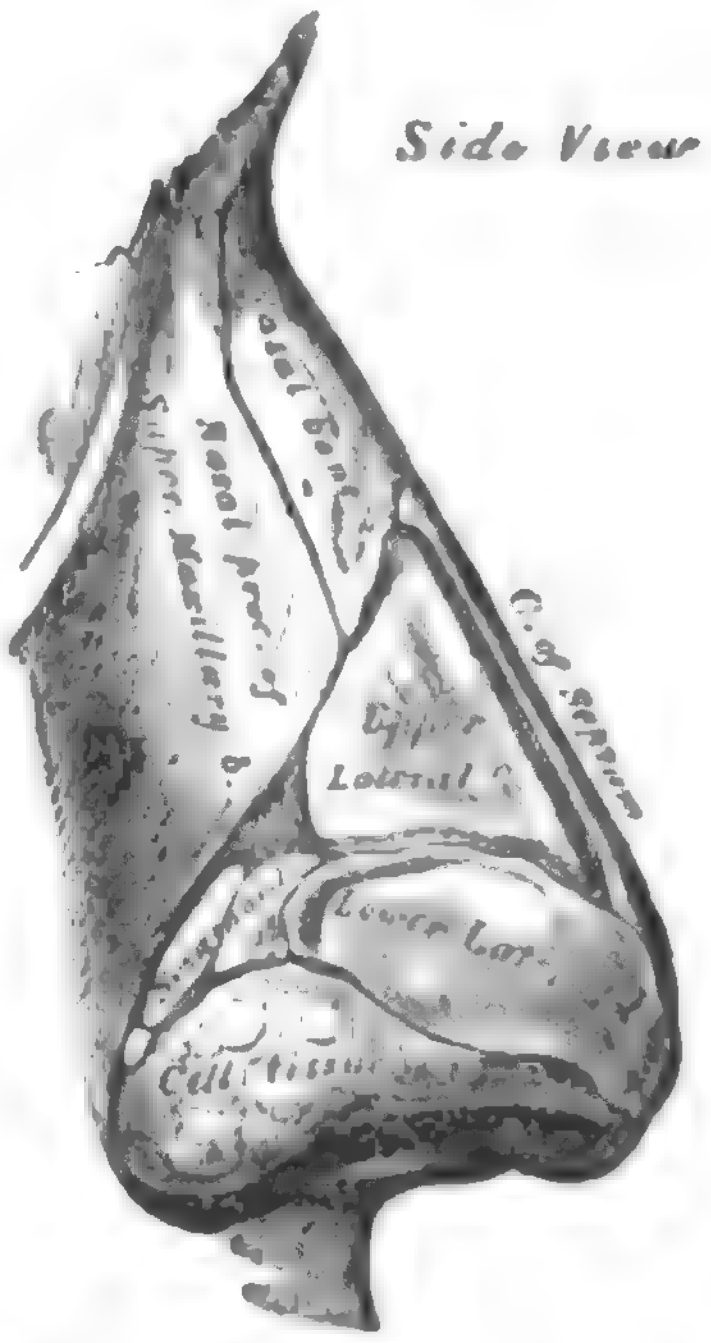

Cartilages of the Nose.

The *bony framework* occupies the upper part of the organ: it consists of the nasal bones and the nasal processes of the superior maxillary.

The *cartilaginous framework* consists of five pieces—the two upper and the two lower lateral cartilages, and the cartilage of the septum.

The *upper lateral cartilages* are situated below the free margin of the nasal bones; each cartilage is flattened and triangular in shape. Its anterior margin is thicker than the posterior and connected with the fibro-cartilage of the septum. Its posterior margin is attached to the nasal process of the superior maxillary and nasal bones. Its inferior margin is connected by fibrous tissue with the lower lateral cartilage: one surface is turned outward, the other inward toward the nasal cavity.

The *lower lateral cartilages* are two thin, flexible plates, situated immediately below the preceding, and bent upon themselves[1] in such a manner as to form the inner and outer walls of each orifice of the nostril. The portion which forms the inner wall, thicker than the rest, is loosely connected with the same part of the opposite cartilage and forms a small part of the columna. Its outer extremity, free, rounded, and projecting, forms, with the thickened integument and subjacent tissue, the lobe of the nose. The part which forms the outer wall is curved to correspond with the ala of the nose: it is oval and flattened, narrow behind, where it is connected with the nasal process of the superior maxilla by a tough fibrous membrane in which are found three or four small cartilaginous plates (sesamoid cartilages)—*cartilagines minores.* Above it is connected to the upper lateral cartilage and front part of the cartilage of the septum; below it is separated from the margin of the nostril by dense cellular tissue; and in front it forms, with its fellow, the prominence of the tip of the nose.

---

[1] [Hence the bilobed tip of the nose in some persons, in whom the furrow between the two cartilages is marked.]

The *cartilage of the septum* is somewhat quadrilateral in form, thicker at its margins than at its centre, and completes the separation between the nasal fossæ in front. Its anterior margin, thickest above, is connected from above downward with the nasal bones, the front part of the two upper lateral cartilages, and the inner portion of the two lower lateral cartilages. Its posterior margin is connected with the perpendicular lamella of the ethmoid; its inferior margin, with the vomer and the palate processes of the superior maxillary bones.

Fig. 528.

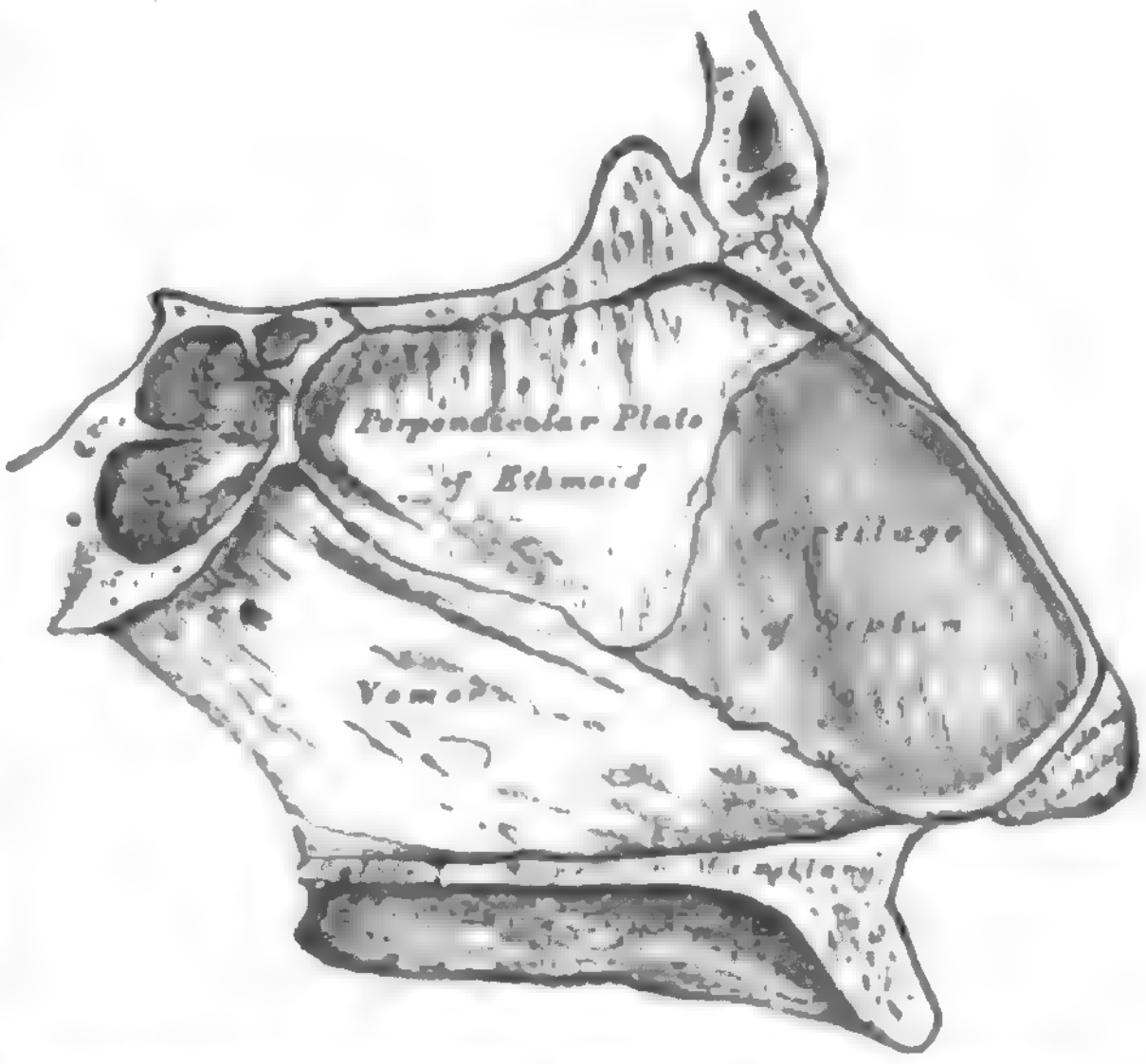

Bones and Cartilages of Septum of Nose, right side.

These various cartilages are connected to each other and to the bones by a tough, fibrous membrane, the perichondrium, which allows the utmost facility of movement between them.

The *muscles of the nose* are situated immediately beneath the integument: they are (on each side) the Pyramidalis nasi, the Levator labii superioris alæque nasi, the Dilatator naris, anterior and posterior, the Compressor nasi, the Compressor narium minor, and the Depressor alæ nasi. They have been described above (p. 374).

The *integument* covering the dorsum and sides of the nose is thin and loosely connected with the subjacent parts; but where it forms the tip or lobe and the alæ of the nose it is thicker and more firmly adherent. It is furnished with a large number of sebaceous follicles, the orifices of which are usually very distinct.

The *mucous membrane* lining the interior of the nose is continuous with the skin externally and with that which lines the nasal fossæ within.

The *arteries of the nose* are the lateralis nasi from the facial, and the nasal artery of the septum from the superior coronary, which supplies the alæ and septum, the sides and dorsum being supplied from the nasal branch of the ophthalmic and the infraorbital.

The *veins of the nose* terminate in the facial and ophthalmic.

The *nerves of the nose* are branches from the facial, infraorbital, and infratrochlear, and a filament from the nasal branch of the ophthalmic.

NASAL FOSSÆ.

The nasal fossæ are two irregular cavities situated in the middle of the face and extending from before backward. They open in front by the two anterior nares, and terminate in the pharynx behind by the posterior nares. The boundaries of these cavities and the openings which are connected with them as they exist in the skeleton have been already described (pp. 215–219, Figs. 181–184).

The *mucous membrane* lining the nasal fossæ is called the *pituitary*, from the nature of its secretion, or *Schneiderian*, from Schneider, the first anatomist who showed that the secretion proceeded from the mucous membrane, and not, as was previously imagined, from the brain. It is intimately adherent to the periosteum or perichondrium, over which it lies. It is continuous externally with the skin through the anterior nares, and with the mucous membrane of the pharynx through the posterior nares. From the nasal fossæ its continuity may be traced with the conjunctiva through the nasal duct and lachrymal canals; with the lining membrane of the tympanum and mastoid cells, through the Eustachian tube; and with the frontal, ethmoidal, and sphenoidal sinuses and the antrum of Highmore, through the several openings in the meatuses. The mucous membrane is thickest and most vascular over the turbinated bones. It is also thick over the septum, but in the intervals between the spongy bones and on the floor of the nasal fossæ it is very thin. Where it lines the various sinuses and the antrum of Highmore it is thin and pale.

The *epithelium* differs in its character according to the functions of the part of the nose in which it is found. Near the orifice of the nostril, where common sensation is chiefly or alone required, the epithelium is of the ordinary pavement or scaly variety. In the rest of the cavity, below the distribution of the olfactory nerves—*i. e.* in the respiratory portion of the nasal cavity—the epithelium is columnar and ciliated. This is the case also in the sinuses of the nose. In the olfactory region —*i. e.* the region in which the terminal filaments from the olfactory bulb are distributed (see p. 716)—the epithelial cells are columnar and non-ciliated: their free surface presents a sharp outline, and their deep extremity is prolonged into a process which runs inward, branching to communicate with similar processes from neighboring cells, so as to form a network in the deep part of the mucous membrane. Lying between them are cells (termed by Max Schultze *olfactory cells*) which consist of a nucleated body and two processes, of which one runs outward between the columnar epithelial cells and terminates at the level of the surface of the mucous membrane; the other (the deep) process runs inward, is frequently beaded like a nerve-fibre, and is believed by most observers to be in connection with one of the terminal filaments of the olfactory nerve.

The mucous membrane is pigmented in the olfactory, but not in the other regions, being of a light-yellow color, at least in the white races.[1]

This membrane is also provided with a nearly continuous layer of branched mucous glands, the ducts of which open upon its surface. They are most numerous at the middle and back parts of the nasal fossæ and largest at the lower and back part of the septum.

Owing to the great thickness of this membrane the nasal fossæ are much narrower, and the turbinated bones, especially the lower ones, appear larger and more prominent, than in the skeleton. From the same circumstance also the various apertures communicating with the meatuses are either narrowed or completely closed.

In the *superior meatus* the aperture of communication with the posterior ethmoidal cells is considerably diminished in size and the spheno-palatine foramen completely covered in.

In the *middle meatus* the opening of the infundibulum is partially hidden by a projecting fold of mucous membrane, and the orifice of the antrum is contracted to a small circular aperture much narrower than in the skeleton.

In the *inferior meatus* the orifice of the nasal duct is partially hidden by either a single or double valvular mucous fold, and the anterior palatine canal either completely closed in or a tubular cul-de-sac of mucous membrane is continued a short distance into it.

In *the roof* the opening leading to the sphenoidal sinus is narrowed and the apertures in the cribriform plate of the ethmoid completely closed in.

The *arteries of the nasal fossæ* are the anterior and posterior ethmoidal, from the ophthalmic, which supply the ethmoidal cells, frontal sinuses, and roof of the nose; a minute twig from the small meningeal; the spheno-palatine, from the internal maxillary, which supplies the mucous membrane covering the spongy bones, the meatuses, and septum; and the alveolar branch of the internal maxillary, which supplies the lining membrane of the antrum. The ramifications of these vessels form a close, plexiform network beneath and in the substance of the mucous membrane.

---

[1] An interesting speculation has been suggested by Dr. W. Ogle (*Med.-Chir. Trans.*, vol. liii. 277) as to the possible connection between the presence and abundance of this pigment and the perfection of the sense of smell.

Fig. 529.

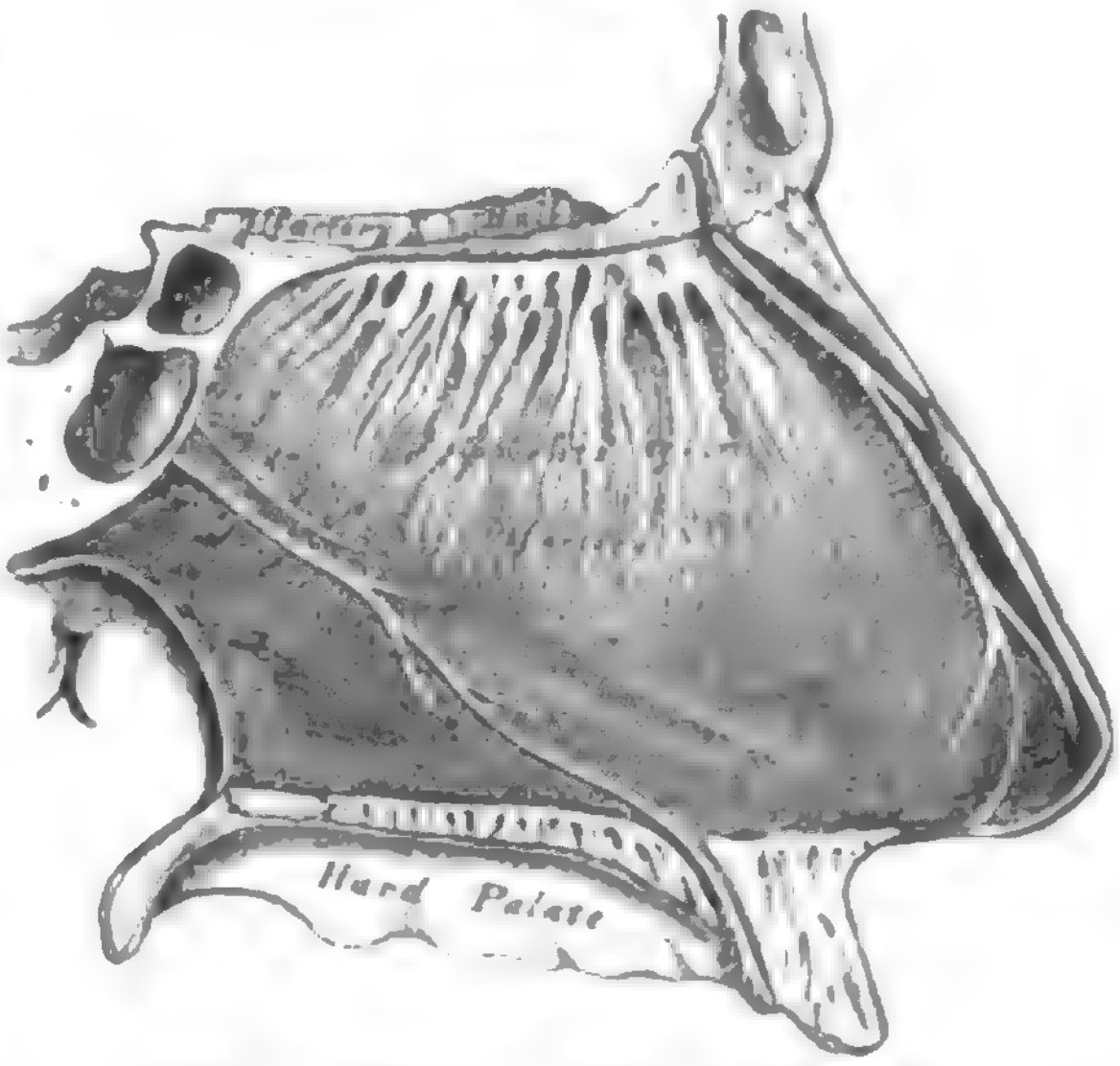

Nerves of Septum of Nose, right side.

The *veins of the nasal fossæ* form a close network beneath the mucous membrane. They pass, some with the veins accompanying the spheno-palatine artery, through the spheno-palatine foramen, and others through the alveolar branch to join the facial vein; some accompany the ethmoidal arteries and terminate in the ophthalmic vein; and, lastly, a few communicate with the veins in the interior of the skull through the foramina in the cribriform plate of the ethmoid bone and the foramen cæcum.

The *nerves* are—the olfactory, the nasal branch of the ophthalmic, filaments from the anterior dental branch of the superior maxillary, the Vidian, naso-palatine, descending anterior palatine, and nasal branches of Meckel's ganglion.

The *olfactory*, the special nerve of the sense of smell, is distributed over the upper third of the septum and over the surface of the superior and middle spongy bones.

The *nasal branch of the ophthalmic* distributes filaments to the upper and anterior part of the septum and outer wall of the nasal fossæ.

Filaments from the anterior dental branch of the superior maxillary supply the inferior meatus and inferior turbinated bone.

The *Vidian nerve* supplies the upper and back part of the septum and superior spongy bone, and the upper anterior nasal branches from the spheno-palatine ganglion have a similar distribution.

The *naso-palatine nerve* supplies the middle of the septum.

The *larger* or *anterior palatine nerve* supplies the middle and lower spongy bones.

THE EYE.

[*Dissection.*—The student should procure a few fresh bullocks' or sheep's eyes, with the muscles, lids, etc. The muscles and adnexa should be dissected first, and then the ball. Sections also should be made both antero-posteriorly and transversely through the entire ball.]

The eyeball is contained in the cavity of the orbit. In this situation it is securely protected from injury, whilst its position is such as to ensure the most extensive range of sight. It is acted upon by numerous muscles, by which it is capable of being directed to any part; supplied by vessels and nerves; and is additionally protected in front by several appendages, such as the eyebrow, eyelids, etc. [The muscles and the optic nerve have already been described at pp. 371 and 717.]

The eyeball is imbedded in the fat of the orbit, but is surrounded by a thin membranous sac which isolates it, so as to allow of free movement. This membranous sac is named the *capsule of Tenon* or *tunica vaginalis oculi.* It may be regarded as a distinct serous membrane consisting of a parietal and visceral layer. The latter invests the posterior part of the globe from the ciliary margin of the cornea backward to the entrance of the optic nerve, and is connected to it by very delicate connective tissue; the former (parietal) lines the hollow in the fat in which the eyeball is imbedded. Both layers are lined on their free surfaces by flattened endothelial cells. The cavity between them is continuous with the spaces between the different layers of the sheath of the optic nerve—that is to say, with the *subarachnoidean* between the pia matral and the arachnoid sheath, and the *subdural* between the arachnoid and dural sheath—and into it empty the lymphatic vessels of the sclerotic. The capsule is pierced by the muscles of the eyeball near their insertion, and sends tubular prolongations on them which become continuous with the sheath of the muscles. From the outer surface of these sheaths expansions, consisting of elastic fibres and muscle-cells, are given off to the margin of the orbit, which serve to limit the degree of contraction of the muscles.[1]

The eyeball is composed of segments of two spheres of different sizes. The anterior segment is one of a small sphere and forms about one-sixth of the eyeball. It is more prominent than the posterior segment, which is one of a much larger sphere and forms about five-sixths of the globe. The segment of the larger sphere is opaque, and formed by the sclerotic, the tunic of protection to the eyeball: the smaller sphere is transparent, and formed by the cornea. The axes of the eyeballs are nearly parallel, and do not correspond to the axes of the orbits, which are directed outward. The optic nerves follow the direction of the axes of the orbits and enter the eyeball a little to their inner or nasal side. The eyeball measures rather more in its transverse and vertical diameters than in its antero-posterior, the former diameters amounting to about an inch, the latter to about nine-tenths of an inch.

The eyeball is composed of several investing ***tunics***, and of fluid and solid refracting media called *humors*.

The tunics are three in number:

1. Sclerotic and Cornea.
2. Choroid, Iris, and Ciliary Processes.
3. Retina.

The refracting media or humors are also three:

Aqueous.   Crystalline (lens) and Capsule.   Vitreous.

The sclerotic and cornea form the external tunic of the eyeball; they are essentially fibrous in structure, the sclerotic being opaque and forming the posterior five-sixths of the globe; the cornea, which forms the remaining sixth, being transparent.

The **Sclerotic** (σκληρός, hard) (Fig. 530) has received its name from its extreme density and hardness; it is a firm, unyielding, fibrous membrane, serving to maintain the form of the globe. It is much thicker behind than in front. Its *external surface* is of a white color, quite smooth, except at the points where the Recti and Obliqui muscles are inserted into it, and covered for part of its extent by the conjunctival membrane, hence the whiteness and brilliancy of the front of the eyeball. Its *inner surface* is stained of a brown color, marked by grooves, in which are lodged the ciliary nerves, and connected by an exceedingly fine cellular tissue (*lamina fusca*) with the outer surface of the choroid. Behind, it is pierced by the optic nerve a little to its inner or nasal side, and is continuous with the fibrous sheath of the nerve, which is derived from the dura mater. At the point where the optic nerve passes through the sclerotic this membrane forms a thin cribriform lamina (the *lamina cribrosa*); the minute orifices in this layer serve for the transmission of the nervous filaments, and the fibrous septa dividing them from one another are continuous with the membranous processes which separate the bundles of nerve-fibres. One of these openings, larger than the rest, occupies the centre of the lamella; it is called the *porus opticus*, and transmits the arteria centralis retinæ to the interior of the eyeball. Around the cribriform lamella are numerous small apertures for the transmission of the ciliary vessels and nerves. In front the sclerotic is continuous with the cornea by direct continuity of tissue, but the opaque sclerotic overlaps the cornea rather more on its outer than on its inner surface.

Structure.—The sclerotic is formed of white fibrous tissue intermixed with fine elastic fibres, and of flattened connective-tissue corpuscles, some of which are pigmented, contained in cell-spaces between the fibres. These fibres are aggregated into bundles which are arranged chiefly in a longitudinal direction. It yields gelatin on boiling. Its vessels are not numerous, the capillaries being of small size, uniting at long and wide intervals. The existence of nerves in it is doubtful.

---

[1] See a paper by Mr. C. B. Lockwood (*Journal of Anatomy and Physiology*, vol xx. Part I. p. 1).

The **Cornea** is the projecting transparent part of the external tunic of the eyeball and forms the anterior sixth of the globe. It is not quite circular, being a little broader in the transverse than in the vertical direction, in consequence of the sclerotic overlapping the margin above and below. It is convex anteriorly, and projects forward from the sclerotic in the same manner that a watch-glass does from its case. Its degree of curvature varies in different individuals and in the same individual at different periods of life, it being more prominent in youth than in advanced life, when it becomes flattened. The cornea is dense and of uniform thickness throughout; its posterior surface is perfectly circular in outline, and exceeds the anterior surface slightly in extent, from the latter being overlapped by the sclerotic.

[FIG. 530.

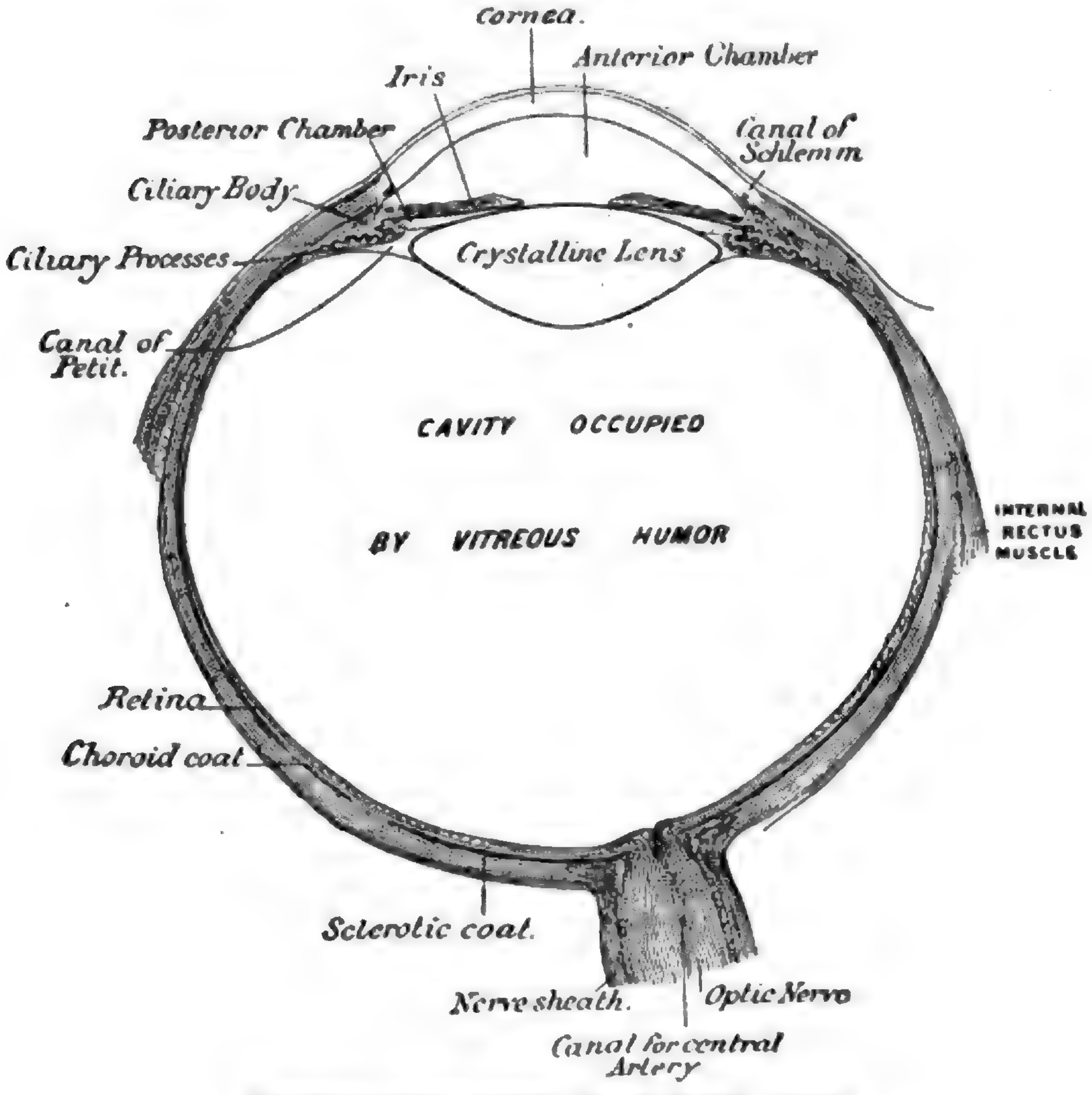
Cornea.
Anterior Chamber
Iris
Posterior Chamber
Canal of Schlemm
Ciliary Body
Ciliary Processes
Crystalline Lens
Canal of Petit.
CAVITY OCCUPIED BY VITREOUS HUMOR
INTERNAL RECTUS MUSCLE
Retina
Choroid coat
Sclerotic coat.
Nerve sheath.
Optic Nerve
Canal for central Artery

Horizontal Section through the Left Eyeball (Allen).]

Structure.—The cornea consists of four layers—namely, (1) several strata of epithelial cells continuous with those of the conjunctiva; (2) a thick central fibrous structure, the *cornea proper;* (3) a homogeneous elastic lamina; and (4) a single layer of epithelial cells, forming part of the lining membrane of the anterior chamber of the eyeball. The name of *membrane of Descemet* or *Demours* is given to this posterior elastic lamina and its epithelial coating.

The *conjunctival epithelium*, which covers the front of the cornea proper, consists of several strata of epithelial cells. The lowermost cells are columnar: then follow two or three layers of polyhedral cells, some of which present ridges and furrows similar to those found in the cuticle. Lastly, there are three or four layers of scaly epithelium with flattened nuclei. [This layer is very evident on scraping the cornea of a bullock's eye.]

The *proper substance* of the cornea is fibrous, tough, unyielding, perfectly transparent, and continuous with the sclerotic, with which it is in structure identical. It is composed of about sixty flattened lamellæ superimposed one on another. These lamellæ are made up of bundles of fibrous connective tissue, the fibres of which are directly continuous with the fibres of the sclerotic. The fibres of each lamella are for the most part parallel with each other, those of alternating lamellæ at right angles to each other. Fibres, however, frequently pass from one lamella to the next.

The lamellæ are connected with each other by an interstitial cement-substance, in which are spaces, the *corneal spaces.* The spaces are stellate in shape and have numerous offsets, by which they communicate with other spaces. Each space contains a cell, the *corneal corpuscle*, which resembles in form the space in which it is contained, but does not entirely fill it.

Immediately beneath the conjunctival epithelium the cornea proper presents certain characteristic differences which have led some anatomists to regard it as a distinct membrane, and it has been named by Bowman the *anterior elastic lamina.* It differs, however, from the true elastic lamina or membrane of Descemet in many essential particulars, presenting evidence of fibrillar structure, and not having the same tendency to curl inward or to undergo fracture when detached from the other layers of the cornea. It consists of extremely closely interwoven fibrils similar to those found in the rest of the cornea proper, but contains no corneal corpuscles. It seems therefore more proper to regard it as a part of the proper tissue of the cornea.[1]

The *posterior elastic lamina*, which covers the proper structure of the cornea behind, presents no structure recognizable under the microscope. It consists of a hard, elastic, and perfectly transparent homogeneous membrane of extreme thinness, which is not rendered opaque by either water, alcohol, or acids. It is very brittle, but its most remarkable properties are its extreme elasticity and the tendency which it presents to curl up or roll upon itself, with the attached surface innermost, when separate from the proper substance of the cornea. Its use appears to be (as suggested by Dr. Jacob) "to preserve the requisite permanent correct curvature of the flaccid cornea proper."

The *epithelial lining* of the aqueous chamber covers the posterior surface of the posterior elastic lamina. It consists of a single layer of polygonal transparent nucleated cells similar to those found lining other serous cavities.

ARTERIES AND NERVES.—The cornea is a non-vascular structure, the capillary vessels terminating in loops at its circumference. Lymphatic vessels have not as yet been demonstrated in it, but are represented by the channels in which the bundles of nerves meet; these are lined by an endothelium and are continuous with the cell-spaces. The nerves are numerous, twenty-four to thirty-six in number (Kölliker), forty to forty-five (Waldeyer and Sämisch); they are derived from the ciliary nerves and enter the laminated tissue of the cornea. They ramify throughout its substance in a delicate network, and their terminal filaments form a firm and closer plexus on the surface of the cornea proper beneath the epithelium. This is termed the *subepithelial* plexus, and from it fibrils are given off which ramify between the epithelial cells, forming a network which is termed the *intra-epithelial* plexus.

Dissection.—In order to separate the sclerotic and cornea, so as to expose the second tunic, the eyeball should be immersed in a small vessel of water. A fold of the sclerotic near its anterior part having been pinched up—an operation not easily performed, from the extreme tension of the membrane—it should be divided with a pair of blunt-pointed scissors. As soon as the choroid is exposed, the end of a blowpipe should be introduced into the orifice and a stream of air forced into it, so as to separate the slight cellular connection between the sclerotic and choroid. [All this is needless trouble. A bullock's eye, which should be fresh, is tightly held in the left hand; the sclerotic then is carefully incised in the equator of the globe by repeated light cuts, till the black choroid is seen. One blade of a probe-pointed pair of scissors is now

---

[1] This layer has been called by Reichert the "anterior limiting layer"—a name which appears more applicable to it than that of "anterior elastic lamina."

introduced flatwise between the sclerotic and choroid, hugging the sclerotic, and turned in the proper position, when the sclerotic is easily divided, a little at a time. It is not needful to put it in water or use the blowpipe.] The sclerotic should now be divided around its entire circumference [at the equator], and may be removed in separate portions. The front segment being then drawn forward, the handle of the scalpel should be pressed gently against it at its connection with the iris, and, the two being separated, a quantity of perfectly transparent fluid will escape; this is the aqueous humor. In the course of the dissection the ciliary nerves may be seen lying in the loose cellular tissue between the choroid and sclerotic, or contained in delicate grooves on the inner surface of the latter membrane.

Second Tunic.—This is formed by the choroid behind, the iris and ciliary processes in front, and by the ciliary ligament and Ciliary muscle at the point of junction of the sclerotic and cornea.

The choroid is the vascular and pigmentary tunic of the eyeball investing the posterior five-sixths of the globe, and extending as far forward as the cornea, the ciliary processes being appendages of the choroid developed from its inner surface in front. The iris is the circular muscular septum, which hangs vertically behind the cornea, presenting in its centre a large circular aperture, the pupil. The ciliary ligament and Ciliary muscle form the white ring observed at the point where the choroid and iris join with each other and with the sclerotic and cornea.

The **Choroid** is a thin, highly vascular membrane, of a dark-brown or chocolate color, which invests the posterior five-sixths of the central part of the globe. It is pierced behind by the optic nerve, and extends in front as far forward as the ciliary ligament, where it is connected with the iris and bends inward, forming on its inner surface a series of folds or plaitings, the *ciliary processes*. It is thicker behind than in front. Externally it is connected by a fine cellular web (*membrana fusca*) with the inner surface of the sclerotic. Its inner surface is smooth and lies in contact with the retina.

FIG. 531.

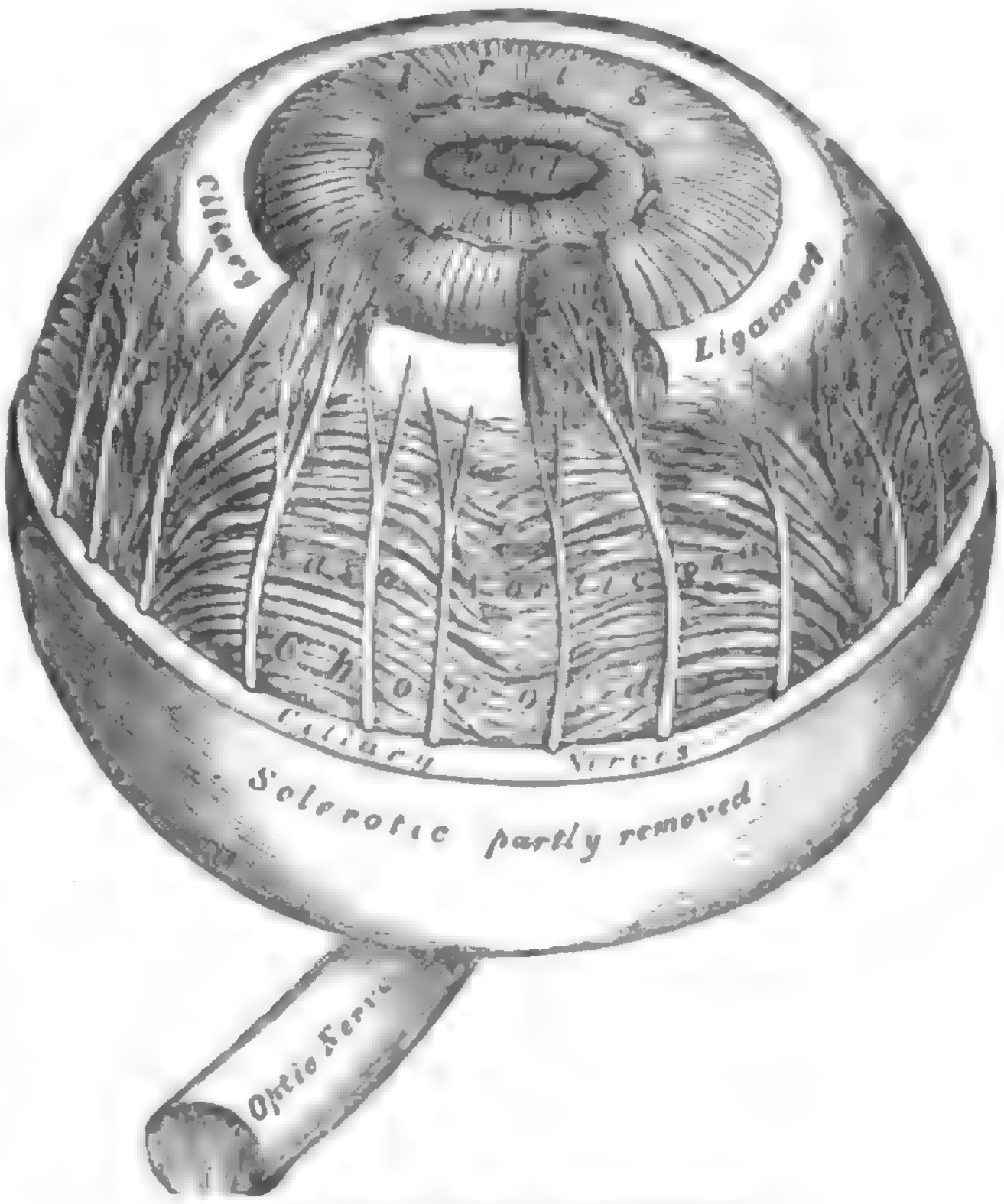

The Choroid and Iris (enlarged).

Structure.—The choroid consists mainly of a dense capillary plexus, and of small arteries and veins carrying the blood to and returning it from this plexus. On its external surface—*i. e.* the surface next the sclerotic—is a thin membrane of fine elastic fibres arranged in lamellæ, which are covered with endothelium and form spaces which communicate by perforations in the sclerotic, through which the vessels and nerves enter, with the capsule of Tenon. This layer is named the *lamina suprachoroidea*, and is continuous with the lamina fusca of the sclerotic.

Internal to this is the *choroid proper*, and, in consequence of the small arteries and veins being arranged on the outer surface of the capillary network, it is customary to describe this as consisting of two layers, the outermost composed of small arteries and veins, with pigment-cells interspersed between them, and the inner consisting of a capillary plexus. The *external layer* consists, in part, of the larger branches of the short ciliary arteries which run forward between the veins before they bend downward to terminate in the capillaries, but is formed principally of veins, which are named, from their distribution, *venæ verticosæ*. They converge to four or five equidistant trunks which pierce the sclerotic midway between the margin of the cornea and the entrance of the optic nerve. Interspersed between the vessels are lodged dark star-shaped pigment-cells, the fibrous offsets from which, communicating with similar branchings from neighboring cells, form a delicate network or stroma which toward the inner surface of the choroid loses its pigmentary character. The *internal layer* consists of an exceedingly fine capillary plexus formed by the short ciliary vessels, and is known as the *tunica Ruyschiana*. The network is close, and finer at the hinder part of the choroid than in front. About half an inch behind the cornea its meshes become larger, and are continuous with those of the ciliary processes. On the inner surface of this tunic is a very thin, structureless—or, according to Kölliker, faintly fibrous—membrane, called the *lamina vitrea;* it is closely connected with the stroma of the choroid and separates it from the pigmentary layer of the retina.

FIG. 532.

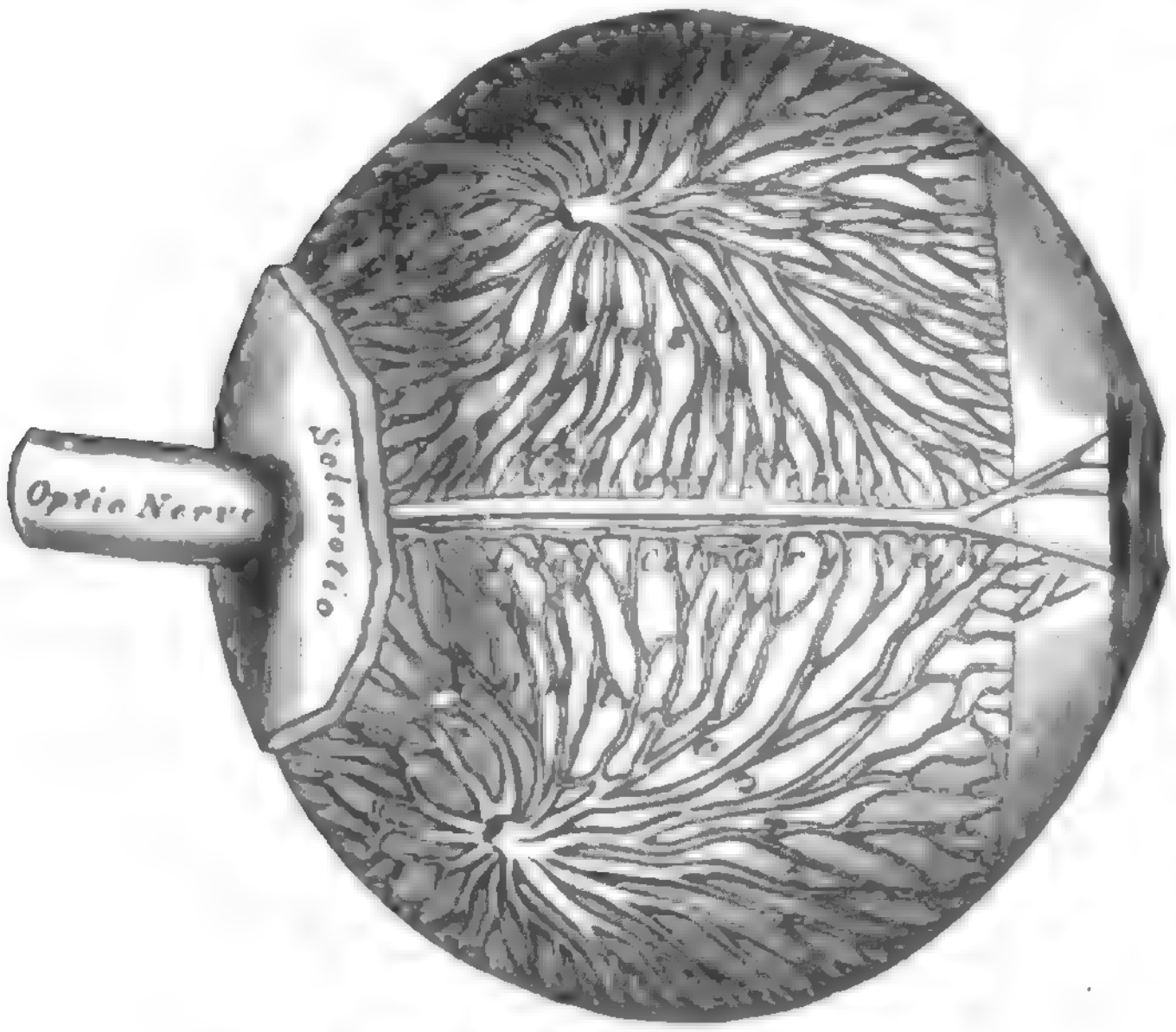

The Veins of the Choroid (enlarged).

The ciliary processes should now be examined. They may be exposed either by detaching the iris from its connection with the ciliary ligament, or by making a transverse section of the globe and examining them from behind.

The *Ciliary processes* are formed by the plaiting and folding inward of the various layers of the choroid (*i. e.* the choroid proper and the lamina vitrea) at its anterior margin, and are received between corresponding foldings of the suspensory ligament of the lens, thus establishing a communication between the choroid and inner tunic of the eye. They are arranged in a circle, and form a sort of plaited frill behind the iris round the margin of the lens. They vary between sixty and eighty in number, lie side by side, and may be divided into large and small; the latter, consisting of about one-third of the entire number, are situated in the spaces between the former, but without regular alternation. The larger processes are each about one-tenth of an inch in length and hemispherical in shape, their periphery being attached to the ciliary ligament and continuous with the layers of the choroid: the opposite margin is free and rests upon the circumference of the lens. Their anterior surface is turned toward the back of the iris, with the circumference of which they are continuous. The posterior surface is closely connected with the suspensory ligament of the lens.

Structure.—The ciliary processes are similar in structure to the choroid: the vessels are larger, having chiefly a longitudinal direction. They are covered on their inner surface with a layer of black pigment-cells continuous with the cells of the pigmentary layer of the retina, and in their stroma are also other, stellate, pigment-cells, which, however, are not so numerous as in the choroid itself, and toward the free extremities of the folds are devoid of pigment.

The **Iris** (*iris*, a rainbow) has received its name from its various colors in different individuals. It is a thin, circular-shaped, contractile curtain suspended in the aqueous humor behind the cornea and in front of the lens, being perforated a little to the nasal side of its centre by a circular aperture, the *pupil*, for the transmission of light. By its circumference it is intimately connected with the choroid; external to this is the ciliary ligament, by which it is connected to the sclerotic and cornea; its inner edge forms the margin of the pupil; its surfaces are flattened and look forward and backward, the anterior surface toward the cornea, the posterior toward the ciliary processes and lens. [The iris at the pupillary border is in contact with the lens (Fig. 530). Hence the readiness with which, in iritis, adhesions form between the iris and lens.] The circumference of the iris is connected to the cornea by a reticular structure denominated the *ligamentum pectinatum iridis*. This reticular structure is derived from the membrane of Descemet, which at the margin of the cornea breaks up into fibres; some of these are continued into the front of the iris, others are connected with the fore part of the choroid and sclerotic. These fibres form a reticulated structure at the outer angle of the anterior chamber, the intervals between the fibres forming small cavernous spaces (the *spaces of Fontana*). These little recesses communicate with a somewhat larger space in the substance of the sclerotic close to its junction with the cornea. This is the *canal of Schlemm*, or *sinus circularis iridis*, and according to Schwalbe and Waldeyer is a lymph-canal, but according to the more recent investigations of Leber is a venous sinus. The anterior surface of the iris is variously colored in different individuals, and marked by lines which converge toward the pupil. The posterior surface is of a deep purple tint, from being covered by dark pigment; it is hence named *uvea*, from its resemblance in color to a ripe grape.

Fig. 533.

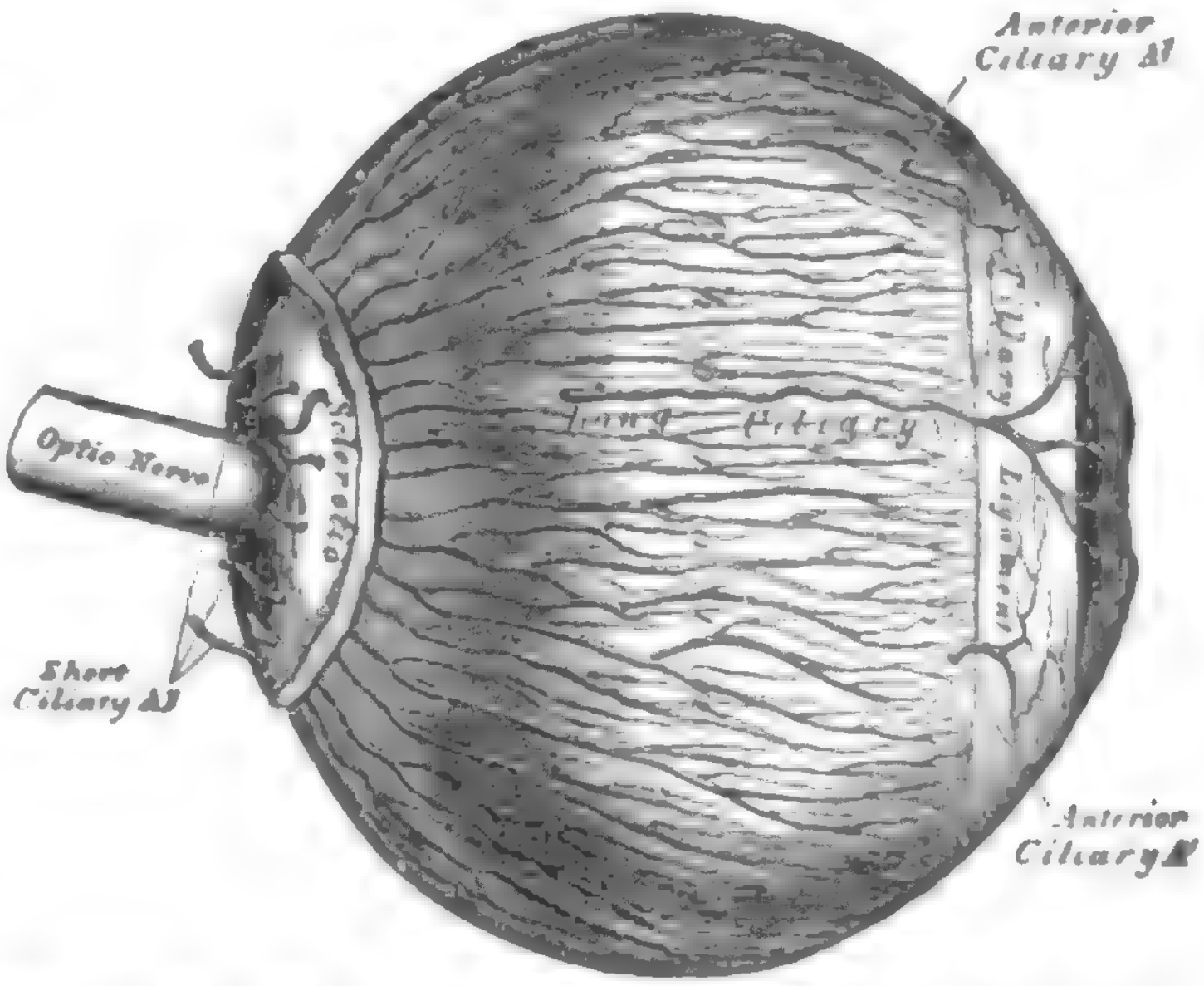

The Arteries of the Choroid and Iris; the sclerotic has been mostly removed (enlarged).

Structure.—The iris is composed of the following structures:

1. In front is a layer of polyhedral cells on a delicate hyaline basement-membrane. This layer is continuous with the epithelial layer of the membrane of Descemet, and in men with dark-colored irides the cells contain pigment-granules.

2. *Stroma.*—The stroma consists of fibres and cells. The former are made up of fine delicate bundles of fibrous tissue, of which some few fibres have a circular direction at the circumference of the iris, but the chief mass consists of fibres radiating toward the pupil. They form, by their interlacement, a delicate mesh in which the vessels and nerves are contained. Interspersed between the bundles of connective tissue are numerous branched cells with fine processes. Many of them in dark eyes contain pigment-granules, but in blue eyes and the pink eyes of albinos they are unpigmented.

3. The *muscular fibre* is involuntary, and consists of circular and radiating fibres. The *circular fibres* (sphincter of the pupil) surround the margin of the pupil on the posterior surface of the iris like a sphincter, forming a narrow band about one-thirtieth of an inch in width, those near the free margin being closely aggregated, those more external somewhat separated and forming less complete circles. The *radiating fibres* (dilator of the pupil) converge from the circumference toward the centre, and blend with the circular fibres near the margin of the pupil.

4. *Pigment.*—The situation of the pigment-cells differs in different irides. In the various shades of blue eyes the only pigment-cells are several layers of small round or polyhedral cells filled with dark pigment, situated on the posterior surface of the iris and continuous with the pigmentary covering of the ciliary processes. The color of the eye in these individuals is due to this coloring-matter showing more or less through the texture of the iris. In the albino even this pigment is absent. In the gray, brown, and black eye there are, as mentioned above, pigment-granules

to be found in the cells of the stroma and in the epithelial layer on the front of the iris, to which the color of the eye is due.

The *arteries of the iris* are derived from the long and anterior ciliary and from the vessels of the ciliary processes. (See p. 532.)

The *nerves of the iris* are derived from the ciliary branches of the lenticular ganglion and the long ciliary from the nasal branch of the ophthalmic division of the fifth. After reaching the iris in the manner described above (p. 654) they form a plexus around the attached margin of the iris; from this are derived non-medullated fibres which terminate in the circular and radiating muscular fibres. Their exact mode of termination has not been ascertained. Other fibres from the plexus terminate in a network on the anterior surface of the iris. The fibres derived from the motor root of the lenticular ganglion (third nerve) supply the circular fibres, while those derived from the sympathetic supply the radiating fibres.

Membrana Pupillaris.—In *the fœtus* the pupil is closed by a delicate, transparent vascular membrane, the *membrana pupillaris*, which divides the space into which the iris is suspended into two distinct chambers. This membrane contains numerous minute vessels continued from the margin of the iris to those on the front part of the capsule of the lens. These vessels have a looped arrangement, converging toward each other without anastomosing. Between the seventh and eighth month the membrane begins to disappear by its gradual absorption from the centre toward the circumference, and at birth only a few fragments remain. It is said sometimes to remain permanent and produce blindness.

The *Ciliary muscle* (Bowman) consists of unstriped fibres: it forms a grayish, semi-transparent, circular band, about one-eighth of an inch broad, on the outer surface of the fore part of the choroid. It is thickest in front and gradually becomes thinner behind. It consists of two sets of fibres, radiating and circular. The former, much the more numerous, arise at the point of junction of the cornea and sclerotic, and, passing backward, are attached to the choroid opposite to the ciliary processes. The circular fibres are internal to the radiating ones, and to some extent unconnected with them, and have a circular course around the insertion of the iris. They are sometimes called the "ring muscle" of Müller, and were formerly described as the ciliary ligament. The Ciliary muscle is admitted to be the chief agent in accommodation—*i. e.* in adjusting the eye to the vision of near objects. Mr. Bowman believed that this was effected by its compressing the vitreous body, and so causing the lens to advance; but the view which now prevails is that the contraction of the muscle by drawing on the ciliary processes relaxes the suspensory ligament of the lens, thus allowing the anterior surface of the lens to become more convex. The pupil is at the same time slightly contracted.[1]

FIG. 534.

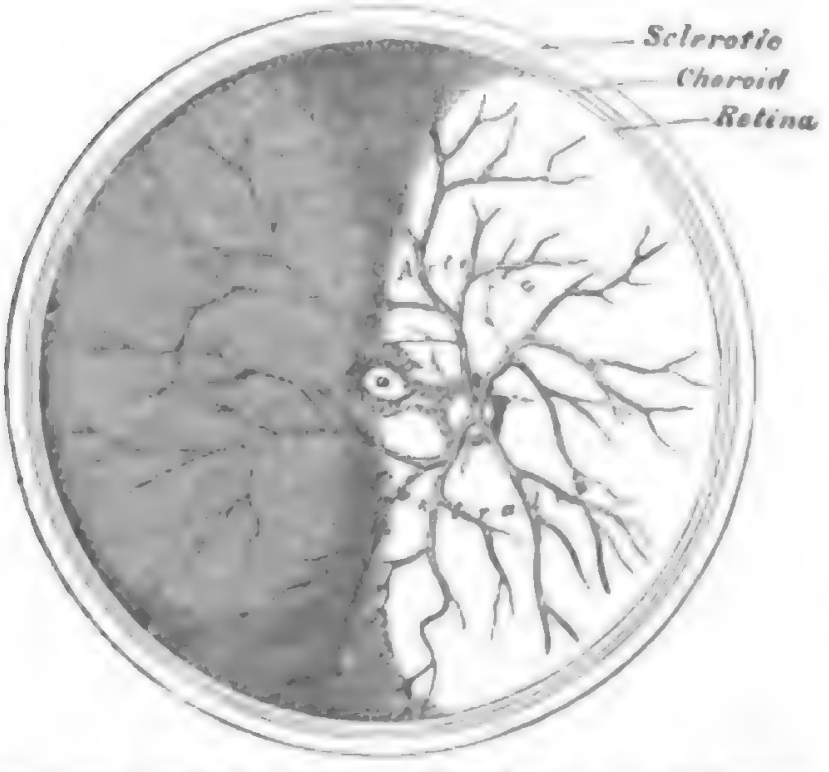

The Arteria Centralis Retinæ, Yellow Spot, etc., the anterior half of the eyeball being removed (enlarged).

The **Retina** may be exposed by carefully removing the choroid from its external surface. It is a delicate nervous membrane, upon the surface of which the images of external objects are received. Its outer surface is in contact with the choroid, its inner surface with the vitreous body. Behind it is continuous with the optic nerve; it gradually diminishes in thickness from behind forward, and in front extends nearly as far forward as the ciliary ligament, where it terminates by a jagged margin, the *ora serrata*. It is soft and semi-transparent in the fresh state, but soon becomes clouded, opaque, and of a pinkish tint. Exactly in the centre of the posterior part of the retina, and at a point corresponding to the axis of the eye, in which the sense of vision is most perfect, is a round, elevated, yellowish spot, called, after its discoverer, the *yellow spot* or *limbus luteus* (*macula lutea*) of Sömmerring, having a central depression at its summit, the *fovea centralis*. The retina in the situation of the fovea centralis is exceedingly thin; so much so that the dark color of the choroid is distinctly seen through it, so that it presents more the appearance of a foramen, and hence the name "foramen of Sömmerring" at first given to it. It exists only in man, the Quadrumana, and some saurian reptiles. About one-tenth of an inch to the inner side of the yellow spot is the point of entrance of the optic nerve, the arteria centralis retinæ piercing its centre. This is the only part of the surface of the retina from which the power of vision is absent.

---

[1] See explanation and diagram in Power's *Illustrations of Some of the Principal Diseases of the Eye*, p. 590.

Structure.—The retina is an exceedingly complex structure, and when examined microscopically by means of sections made perpendicularly to its surface is found to consist of ten layers, which are named from within outward, as follows:

1. Membrana limitans interna.
2. Fibrous layer, consisting of nerve-fibres.
3. Vesicular layer, consisting of nerve-cells.
4. Inner molecular or granular layer.
5. Inner nuclear layer.
6. Outer molecular or granular layer.
7. Outer nuclear layer.
8. Membrana limitans externa.
9. Layer of rods and cones (Jacob's membrane).
10. Pigmentary layer.

1. The *membrana limitans interna* is the most internal layer of the retina, and is in contact with the hyaloid membrane of the vitreous humor. It is derived from the supporting framework of the retina, with which tissue it will be described.

FIG. 535.

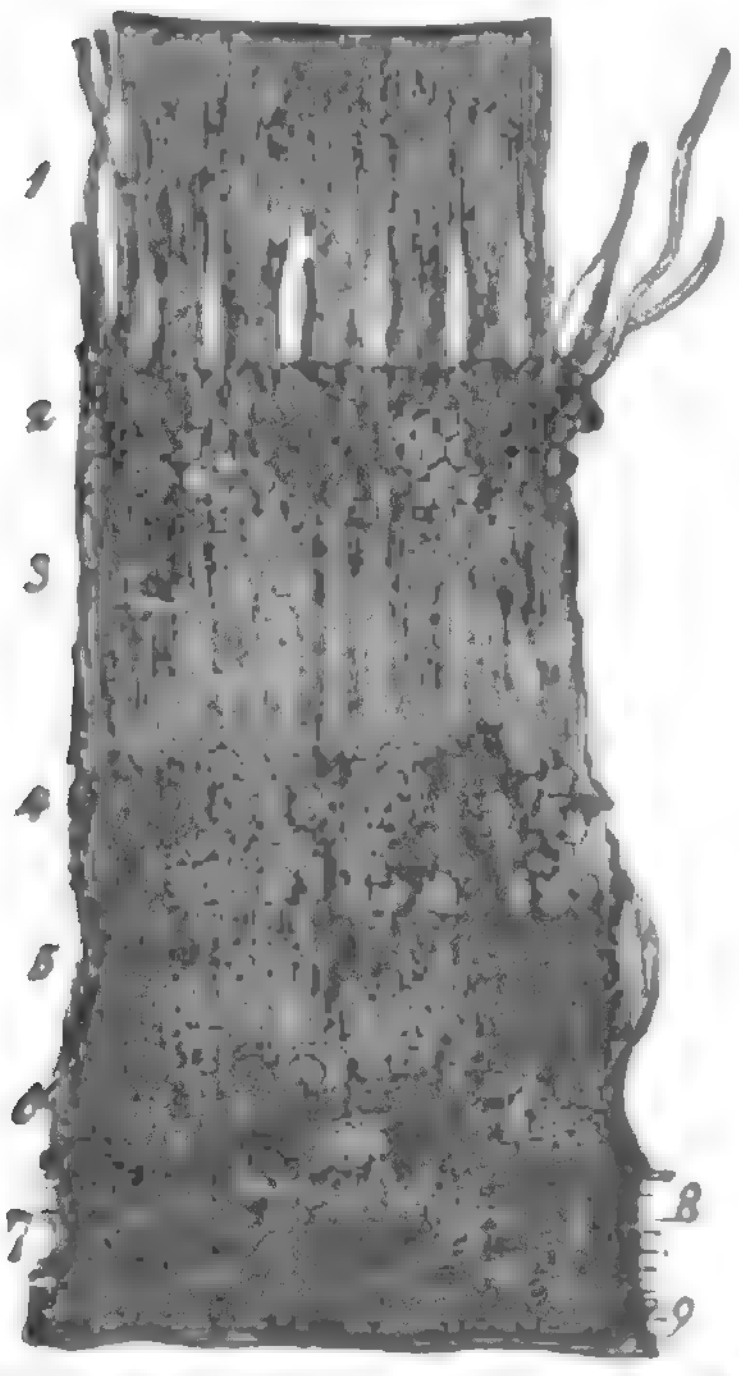

FIG. 536.



Vertical Sections of the Human Retina (Fig. 535, half an inch from the entrance of the optic nerve; Fig. 536, close to the latter): 1, layer of rods and cones (*columnar layer*), bounded underneath by the *membrana limitans externa;* 2, external nuclear layer; 3, outer molecular layer; 4, internal nuclear layer; 5, inner molecular layer; 6, layer of the ganglion-cells; 7, expansion of optic fibres; 8, sustentacular fibres of Müller; 9, their attachment to the membrana limitans interna.

2. *The fibrous layer* is made up of nerve-fibres, the direct continuation of the fibres of the optic nerve. This nerve therefore passes through all the other layers of the retina, except the one previously mentioned, to reach its destination in the fibrous layer. As the nerve passes through the lamina cribrosa of the sclerotic coat, the fibres of which it is composed lay aside their medullary sheaths, and are continued onward through the choroid and retina as simple axis-cylinders. When these non-medullated fibres reach the internal surface of the retina, they radiate from their point of entrance over the surface of the retina, grouped in bundles, and in many places, according to Michel, arranged in plexuses. The layer is thickest at the optic nerve entrance, and gradually diminishes in thickness toward the ora serrata.

3. *The vesicular layer* consists of a single layer of large ganglion-cells, except in the macula lutea, where there are several layers. The cells are somewhat flask-shaped, their rounded internal margin resting on the preceding layer and sending off a single process, which is prolonged into the fibrous layer and is believed to be continuous with a nerve-fibre. From the opposite extremity of the cell one or more thicker processes extend into the inner molecular layer, where they divide dichotomously and become lost in its reticulum, or, according to some, pass through this layer to reach the inner nuclear layer.

4. *The inner molecular layer* consists of a stratum of glandular-looking substance, from which circumstance it is sometimes called the "inner granular" layer. It is made up of a dense reticulum of minute fibrils, intermingled with the fine processes of the ganglion-cells and also processes derived from certain cells contained in the next layer, immediately to be described. No direct connection between these sets of processes has yet been demonstrated, but it is considered probable that they do communicate, and that there is therefore a direct connection between the ganglion-cells of the vesicular layer and the nuclear cells of the inner nuclear layer. Within the recticulum formed by these fibrils minute clear granules of unknown nature are imbedded.

5. *The inner nuclear layer* is made up of nuclear bodies, of which there are three different kinds: (1) A large number of oval nuclei, which are commonly regarded as bipolar nerve-cells, and are much more numerous than either of the other kind. They consist of a large oval nuclear body placed vertically to the surface, containing a distinct nucleolus: they are surrounded by a small amount of protoplasm, which is prolonged into two processes; one of these passes inward into the inner molecular layer, is varicose in appearance, and, as stated above, is believed to be continuous with the processes of the ganglion-cells; the other process passes outward into the outer molecular layer, and there bifurcates. According to some observers, the divisions thus formed communicate with the rod- and cone-fibres (Merkel). (2) At the innermost part of this inner nuclear layer is a stratum of cells which are not branched. (3) Some few cells are also found in this layer connected with the fibres of Müller, and will be described with those structures.

6. *The outer molecular layer* is much thinner than the inner molecular layer, but, like it, consists of a dense network of minute fibrils and presents the same granular appearance. It differs, however, from the inner molecular layer in containing branched stellate cells, the processes of which are extremely fine and exhibit varicosities like nerve-fibrils. They are therefore considered by Schultze to be ganglion-cells.

7. *The Outer Nuclear Layer.*—Like the inner nuclear layer, this layer contains several strata of clear oval nuclear bodies; they are of two kinds, and on account of their being respectively connected with the rods and cones of Jacob's membrane are named rod-granules and cone-granules. The *rod-granules* are much the more numerous and are placed at different levels throughout the layer. They present a peculiar cross-striped appearance, and have prolonged from either extremity a fine process: the outermost is continuous with a single rod of Jacob's membrane; the innermost passes inward toward the outer molecular layer and terminates in an enlarged extremity, from which are given off a number of minute fibrils, which enter the outer molecular layer. In its course it presents numerous varicosities.

The *cone-granules*, fewer in number than the rod-granules, are placed close to the membrana limitans externa and are closely connected with the cones of Jacob's membrane. They do not present any cross-striping, but contain a pyriform nucleus which almost completely fills the cell. From their inner extremity a thick process passes inward to the outer molecular layer, where, like the processes of the rod-cells, it terminates in an enlargement from which are given off numerous fine fibrils, which enter the outer molecular layer.

8. *The Membrana Limitans Externa.*—This layer, like the membrana limitans interna, is derived from the fibres of Müller, with which structures it will be described.

9. *Jacob's Membrane* (*Bacillary Layer*).—The elements which compose this layer are of two kinds, *rods* and *cones*, the former being much more numerous than the latter. The *rods* are solid, of nearly uniform size, and arranged perpendicularly to the surface. Each rod consists of two portions, an outer and inner, which are joined together by a cement-substance and are of about equal length. They differ from each other as regards refraction and in their behavior with coloring reagents, the inner portion becoming stained by carmine, iodine, etc., the outer portion remaining unstained. The outer portion of each rod is marked by transverse striæ, and is made up of a number of thin disks superimposed on one another. It also exhibits faint longitudinal markings. The inner portion of each rod at its inner extremity, where it is joined to the processes of the rod-granules, is indistinctly granular; at its outer extremity it presents a fine longitudinal striation, being composed of fine, bright, highly refracting fibrils.

FIG. 537.

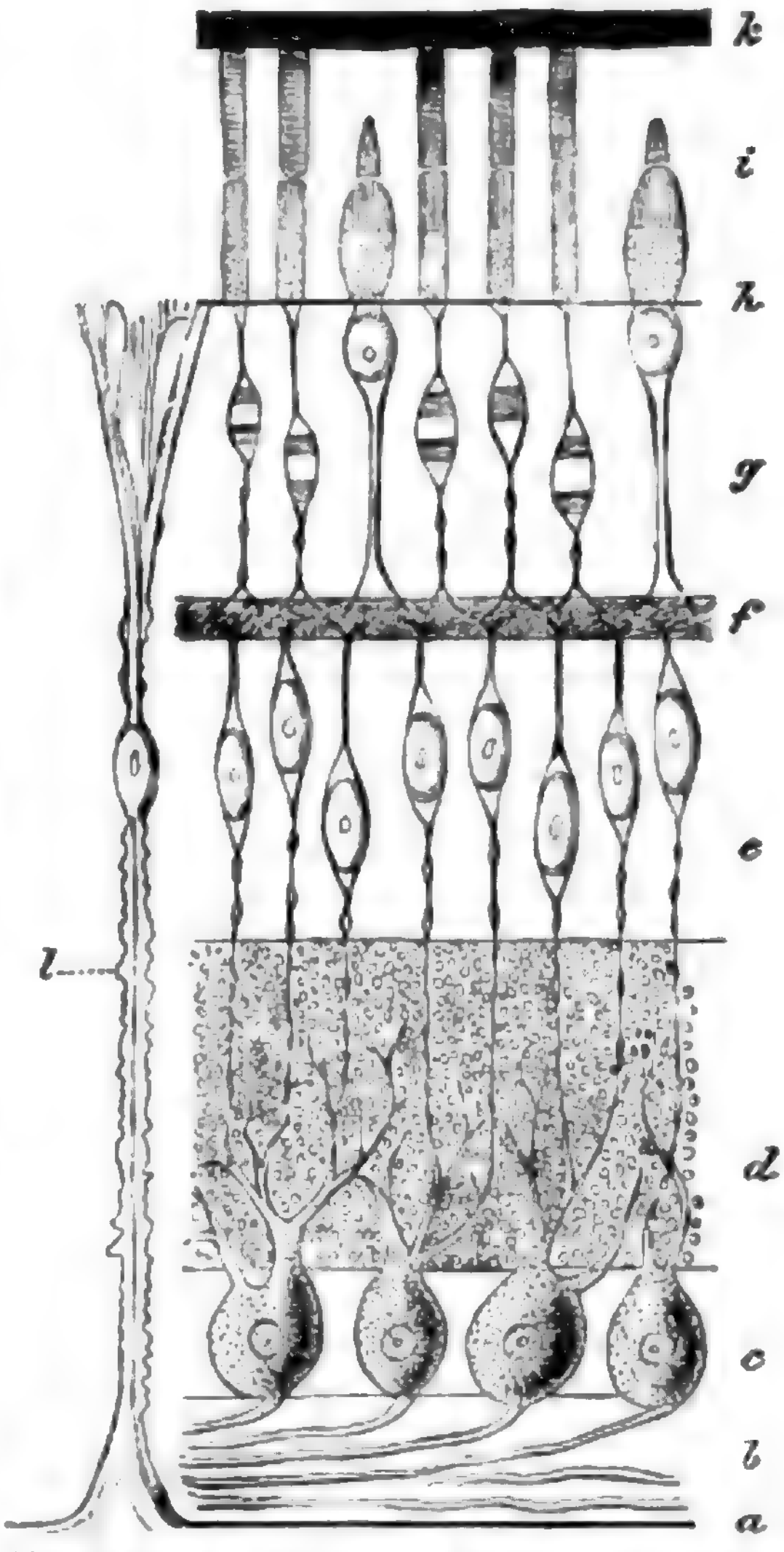

The Layers of the Retina (diagrammatic, after Schultze): *a*, membrana limitans interna; *b*, fibrous layer; *c*, vesicular layer; *d*, inner molecular layer; *e*, inner nuclear layer; *f*, outer molecular layer; *g*, outer nuclear layer; *h*, membrana limitans externa; *i*, Jacob's membrane; *k*, pigmentary layer; *l*, fibre of Müller.

The *cones* are conical or flask-shaped, their broad ends resting upon the membrana limitans externa, the narrow pointed extremity being turned to the choroid. Like the rods, they are made up of two portions, outer and inner, the outer portion being a short conical process which, like the outer segment of the rods, presents transverse striæ. The inner portion resembles the inner portion of the rods in structure, presenting an outer striated and an inner granular appearance, but differs from it in size, being bulged out laterally and presenting a flask shape.

10. *The Pigmentary Layer or Tapetum Nigrum.*—The most external layer of the retina, formerly regarded as a part of the choroid, consists of a single layer of hexagonal epithelium cells loaded with pigment-granules (Fig. 21, p. 50). In the eyes of albinos the cells of the pigmentary layer are present, but they contain no coloring matter. In many of the mammals also, as in the horse and many of the Carnivora, there is no pigment in the cells of this layer, and the choroid possesses a beautiful iridescent lustre, which is termed the *tapetum lucidum*.

Connective-tissue Framework of the Retina.—Almost all these layers of the retina are connected together by a sort of supporting connective tissue, which has been named the *fibres of Müller* or *radiating fibres*, from which the membrana limitans interna et externa are derived. These fibres are found stretched between the two limiting layers "as columns between a floor and a ceiling" and passing through all the nervous layers, except Jacob's membrane. They commence on the inner surface of the retina by a conical base, the edges of the bases of adjoining fibres being united, and thus forming a boundary-line, which is the membrana limitans interna. As they pass through the various layers they present a roughness of their surface, as if from a number of membranous processes abruptly broken off. By these they are continuous with the reticulum of the inner and outer molecular layer and with a sponge-like stroma in which the nuclei of the inner nuclear layers are imbedded. In the inner nuclear layer each fibre of Müller presents a clear oval nucleus, referred to above, which is sometimes situated at the side of, sometimes altogether within, the fibre. In the outer nuclear layer the fibre breaks up into fine lamellæ, which form a fenestrated or sponge-like tissue, in which the rod- and cone-granules are enclosed, and at the outer border of this layer these lamellæ unite along a definite line, forming the membrana limitans externa.

Macula Lutea and Fovea Centralis.—The structure of the retina at the yellow spot presents some modifications. In the macula lutea (1) the nerve-fibres are wanting as a continuous layer; (2) the vesicular layer consists of several strata of cells, instead of a single layer; (3) in Jacob's membrane there are no rods, but only cones, and these are longer and narrower than in other parts; and (4) in the outer nuclear layer there are only cone-fibres, which are very long and arranged in curved lines. At the fovea centralis the only parts which exist are the cones of Jacob's membrane; the outer nuclear layer, the cone-fibres of which are almost horizontal in direction; and an exceedingly thin inner granular layer. The color of the spot seems to imbue all the layers except Jacob's membrane; it is of a rich yellow, deepest toward the centre, and does not appear to consist of pigment-cells, but simply a staining of the constituent parts.

At the *ora serrata* the layers of the retina for the most part terminate abruptly, and the radiating fibres of Müller, covered by the pigmentary layer, can be traced forward, as the *pars ciliaris*, to the iris. The fibres of Müller here present the appearance of columnar epithelial cells arranged in a single stratum.

The *arteria centralis retinæ* with its accompanying vein pierces the optic nerve and enters the globe of the eye through the porus opticus. It immediately divides into four or five branches, which at first run between the hyaloid membrane and the nervous layer; but they soon enter the latter membrane and pass forward, dividing dichotomously. From these branches a minute capillary plexus is given off which does not extend beyond the inner nuclear layer.

HUMORS OF THE EYE.

The **Aqueous Humor** completely fills the anterior and posterior chambers of the eyeball. It is small in quantity (scarcely exceeding, according to Petit, four or five grains in weight), has an alkaline reaction, in composition is little more than water, less than one-fiftieth of its weight being solid matter, chiefly chloride of sodium.

The *anterior chamber* is the space bounded in front by the cornea, behind by the front of the iris. The *posterior chamber* was the name formerly given to a space which was believed to exist between the iris in front and the capsule of the lens, its suspensory ligament, and the ciliary processes behind. It is now known that the posterior surface of the iris is in immediate contact with the lens throughout the greater part of its extent. . The only space which remains to represent the posterior chamber is a narrow chink between the peripheral part of the iris, the suspensory ligament, and the ciliary processes.

In the adult these two chambers communicate through the pupil: but in the fœtus in the seventh month, when the pupil is closed by the membrana pupillaris, the two chambers are quite separate.

VITREOUS BODY.

The **Vitreous Body** forms about four-fifths of the entire globe. It fills the concavity of the retina, and is hollowed in front for the reception of the lens and its capsule. It is perfectly transparent, of the consistence of thin jelly, and consists of an albuminous fluid enclosed in a delicate transparent membrane, the *hyaloid*. This membrane invests the outer surface of the vitreous body; it is intimately connected in front with the suspensory ligament of the lens, and is continued into the back part of the capsule of the lens. It has been supposed by Hannover that from its inner surface numerous thin lamellæ are prolonged inward in a radiating manner, forming spaces in which the fluid is contained. In the adult these lamellæ cannot be detected even after careful microscopic examination, but in the fœtus a peculiar fibrous texture pervades the mass, the fibres joining at numerous points and presenting minute nuclear granules at their point of junction. In the centre of the vitreous humor, running from the position of the entrance of the optic nerve on the retina to the posterior surface of the lens, is a canal filled with fluid and lined by a prolongation of the hyaloid membrane. This is the *canal of Stilling*. It must not be confounded with the canal in the embryonic vitreous humor which conveys the minute artery from the central artery of the retina to the back of the lens. The fluid from the vitreous body resembles nearly pure water; it contains, however, some salts and a little albumen.

The hyaloid membrane encloses the whole of the vitreous humor except its anterior surface, which is hollowed out for the reception of the lens; it passes from the margin of this surface to the margin of the lens, forming the *suspensory ligament*. It is a delicate structureless membrane, except where it forms the suspensory ligament, where it contains longitudinal elastic fibres. Immediately beneath the hyaloid membrane are found small, granular nucleated cells which are said to be possessed of amœboid movements.

In the *fœtus* the centre of the vitreous humor presents a tubular canal, through which a minute artery passes along the vitreous body to the capsule of the lens. In the *adult* no vessels penetrate its substance, so that its nutrition must be carried on by the vessels of the retina and ciliary processes situated upon its exterior.

CRYSTALLINE LENS AND ITS CAPSULE.

[*Dissection.*—After dissecting away the anterior half of the sclerotic and the cornea of the bullock's eye, as directed on p. 808, the canal of Petit can be opened by a hook and a slender bent probe inserted into it. If the capsule on the anterior surface of the lens be torn across by a hook or divided by a knife, and the lens be gently pressed out, the edge of the capsule can be seized by a pair of forceps.]

The crystalline lens, enclosed in its capsule, is situated immediately behind the pupil, in front of the vitreous body, and surrounded by the ciliary processes, which slightly overlap its margin.

The *capsule of the lens* is a transparent, highly elastic, and brittle membrane which closely surrounds the lens. It rests behind in a depression in the fore part of the vitreous body: in front it is in contact with the free border of the iris [hence the ease with which adhesions form in iritis], this latter receding from it at the circumference, thus forming the posterior chamber of the eye; and it is retained in its position chiefly by the suspensory ligament of the lens. The capsule is much thicker in front than behind, structureless in texture, and when ruptured the edges roll up with the outer surface innermost, like the elastic lamina of the cornea. The anterior surface of the lens is connected to the inner surface of the capsule by a single layer of transparent, polygonal, nucleated cells. At the circumference of the lens these cells undergo a change in form: they become elongated, and Babucin states that he can trace the gradual transition of the cells into proper lens-fibres, with which they are directly continuous. There is no epithelium on the posterior surface.

In the fœtus a small branch from the arteria centralis retinæ runs forward, as already mentioned, through the vitreous humor to the posterior part of the capsule of the lens, where its branches radiate and form a plexiform network which covers its surface, and they are continuous round the margin of the capsule with the vessels of the pupillary membrane and with those of the iris. In the adult no vessels enter its substance.

FIG. 538.



The Crystalline Lens, hardened and divided (enlarged).

The *lens* is a transparent double-convex body, the convexity being greater on the posterior than on the anterior surface. It measures about a third of an inch in the transverse diameter and about one-fourth in the antero-posterior. It consists of concentric layers, of which the external in the fresh state are soft and easily detached; those beneath are firmer, the central ones forming a hardened nucleus. These laminæ are best demonstrated by boiling or immersion in alcohol. The same reagents demonstrate that the lens consists of three triangular segments, the sharp edges of which are directed toward the centre, the bases toward the circumference. The laminæ consist of minute parallel fibres which are hexagonal prisms, the edges being dentated, and the dentations fitting accurately into each other; their breadth is about $\frac{1}{5000}$ of an inch. They run from the sutures or lines of junction of the triangular segments on the one surface to the periphery of the lens, and, curving round its margin, they terminate at the line of junction of the segments on the other. No fibres pass from pole to pole, but they are arranged in such a way that fibres which commence near the pole on the one aspect of the lens—that is to say, near the apex of the triangular segment—terminate near the peripheral extremity of the plane on the other; that is to say, near the base of the triangular segment, and *vice versâ*. The fibres of the outer layers of the lens each contain a nucleus which together form a layer (nuclear layer) on the surface of the lens, most distinct toward its circumference. The meridians, or lines of junction of the three segments, are composed of an amorphous granular substance which sometimes becomes opaque, when the lines are seen forming a distinct star on the lens. The lines on one surface do not lie immediately opposite those on the other, but are intermediate.

The *changes produced in the lens by age* are the following:

In the *fœtus* its form is nearly spherical, its color of a slightly reddish tint; it is not perfectly transparent, and is so soft as to break down readily on the slightest pressure.

In the *adult* the posterior surface is more convex than the anterior; it is colorless, transparent, and firm in texture.

In *old age* it becomes flattened on both surfaces, slightly opaque, of an amber tint, and increases in density.

The *suspensory ligament of the lens* is a thin, transparent, membranous structure placed between the vitreous body and the ciliary processes of the choroid; it connects the anterior margin of the vitreous humor with the anterior surface of the lens near its circumference. It assists in retaining the lens in its position. Its outer surface presents a number of folds or plaitings in which the corresponding folds of the ciliary processes are received. These plaitings are arranged round the lens in a radiating form, and are stained by the pigment of the ciliary processes. It is a part of the hyaloid membrane, which, as described above, is continued forward to the anterior part of the margin of the lens. It is covered on its outer surface by the pars ciliaris, or connective-tissue framework of the retina, prolonged forward from the ora serrata. That portion of this membrane which intervenes between the ciliary processes and the capsule of the lens forms part of the boundary of the posterior chamber of the eye. The posterior surface of this layer is turned toward the vitreous humor, being separated from it at the circumference of the lens by a space called the canal of Petit.

The *canal of Petit* is about one-tenth of an inch wide. It is bounded in front by the suspensory ligament; behind by the vitreous humor, its base being formed by the capsule of the lens. When inflated with air it is sacculated at intervals, owing to the foldings on its anterior surface.

The *vessels of the globe of the eye* are the short, long, and anterior ciliary arteries and the arteria centralis retinæ.

The *short ciliary arteries* pierce the back part of the sclerotic, around the entrance of the optic nerve, and divide into branches which run parallel with the axis of the eyeball: they are distributed to the inner layer of the choroid and to the ciliary processes.

The *long ciliary arteries*, two in number, pierce the back part of the sclerotic and run forward, between that membrane and the choroid, to the Ciliary muscle, where they each divide into an upper and lower branch; these anastomose and form a vascular circle round the outer circumference of the iris; from this circle branches are given off, which unite near the margin of the pupil in a smaller vascular circle. These branches in their course supply the muscular structure.

The *anterior ciliary arteries*, five or six in number, are branches of the muscular and lachrymal branches of the ophthalmic. They pierce the eyeball at the anterior part of the sclerotic, immediately behind the margin of the cornea, and are distributed to the ciliary processes, some branches joining the great vascular circle of the iris.

The *arteria centralis retinæ* has been already described.

The *veins*, usually four in number, are formed mainly by branches from the surface of the choroid. They perforate the sclerotic midway between the cornea and the optic nerve and end in the ophthalmic vein.

The *nerves of the eyeball* are the optic, the long ciliary nerves from the nasal branch of the ophthalmic, and the short ciliary nerves from the ciliary ganglion.

APPENDAGES OF THE EYE.

The appendages of the eye (*tutamina oculi*) include the eyebrows, the eyelids, the conjunctiva, and the lachrymal apparatus—viz. the lachrymal gland, the lachrymal sac, and the nasal duct.

The **Eyebrows** (*supercilia*) are two arched eminences of integument which surmount the upper circumference of the orbit on each side and support numerous short, thick hairs directed obliquely on the surface. In structure the eyebrows consist of thickened integument connected beneath with the Orbicularis palpebrarum, Corrugator supercilii, and Occipito-frontalis muscles. These muscles serve by their action on this part to control to a certain extent the amount of light admitted into the eye.

The **Eyelids** (*palpebræ*) are two thin, movable folds placed in front of the eye, protecting it from injury by their closure. The upper lid is the larger and the more movable of the two, and is furnished with a separate elevator muscle, the *Levator palpebræ superioris*. When the eyelids are opened an elliptical space (*fissura palpebrarum*) is left between their margins, the angles of which correspond to the junction of the upper and lower lids, and are called *canthi*.

The *outer canthus* is more acute than the inner, and the lids here lie in close contact with the globe; but the *inner canthus* is prolonged for a short distance inward toward the nose, and the two lids are separated by a triangular space, the *lacus lachrymalis*. At the commencement of the lacus lachrymalis, on the margin of either eyelid, is a small conical elevation, the *lachrymal papilla*, or tubercle, the apex of which is pierced by a small orifice, the *punctum lachrymale*, the commencement of the lachrymal canal.

STRUCTURE OF THE EYELIDS.—The eyelids are composed of the following structures, taken in their order from without inward:

Integument, areolar tissue, fibres of the Orbicularis muscle, tarsal cartilage and its ligament, Meibomian glands, and conjunctiva. The upper lid has, in addition, the aponeurosis of the Levator palpebræ.

The *integument* is extremely thin, and continuous at the margin of the lids with the conjunctiva.

The *subcutaneous areolar tissue* is very lax and delicate, seldom contains any fat, and is extremely liable to serous infiltration.

The *fibres of the Orbicularis muscle*, where they cover the palpebræ, are thin, pale in color, and possess an involuntary action.

The *tarsal cartilages* are two thin elongated plates of dense connective tissue,[1] about an inch in length. They are placed one in each lid, contributing to their form and support.

The *superior*, the larger, is of a semilunar form, about one-third of an inch in breadth at the centre, and becoming gradually narrowed at each extremity. Into the anterior surface of this cartilage the aponeurosis of the Levator palpebræ is attached.

The *inferior* tarsal cartilage, the smaller, is thinner and of an elliptical form.

The *free* or *ciliary margin* of the cartilages is thick and presents a perfectly straight edge. The *attached* or *orbital margin* is connected to the circumference of the orbit by the fibrous membrane of the lids. The outer angle of each cartilage is attached to the malar bone by the external palpebral or tarsal ligament. The inner angles of the two cartilages terminate at the commencement of the lacus lachrymalis, being fixed to the margins of the orbit by the tendo oculi.

The *tarsal ligament* or *fibrous membrane of the lids* is a layer of fibrous membrane beneath the Orbicularis, attached externally to the margin of the orbit, and internally it passes over the anterior surface of the tarsal cartilage and is attached to its free margin. It is thickest and densest at the outer part of the orbit. This membrane serves to support the eyelids and retain the tarsal cartilages in their position.

The *Meibomian glands* (Fig. 539) are situated upon the inner surface of the eyelids, between the tarsal cartilages and conjunctiva, and may be distinctly seen through the mucous membrane on everting the eyelids, presenting the appearance of parallel strings of pearls. They are about thirty in number in the upper cartilage, and somewhat fewer in the lower. They are imbedded in grooves in the inner surface of the cartilages, and correspond in length with the breadth of each cartilage; they are consequently longer in the upper than in the lower eyelid. Their ducts open on the free margin of the lids by minute foramina which correspond in number to the follicles. These glands are a variety of the cutaneous sebaceous glands, each consisting of a single straight tube or follicle having a cæcal termination, into which open a number of small secondary follicles. The tubes consist of basement membrane covered by a layer of scaly epithelium; the secondary follicles are lined by a layer of polyhedral cells continuous with the cells of the tube. The remainder of the follicle is filled with large polyhedral cells charged with fat. They are thus identical in structure with the sebaceous glands. The peculiar parallel arrangement of these glands side by side forms a smooth layer adapted to the surface of the globe, over which they constantly glide. The use of their secretion is to prevent adhesion of the lids.

Fig. 539.

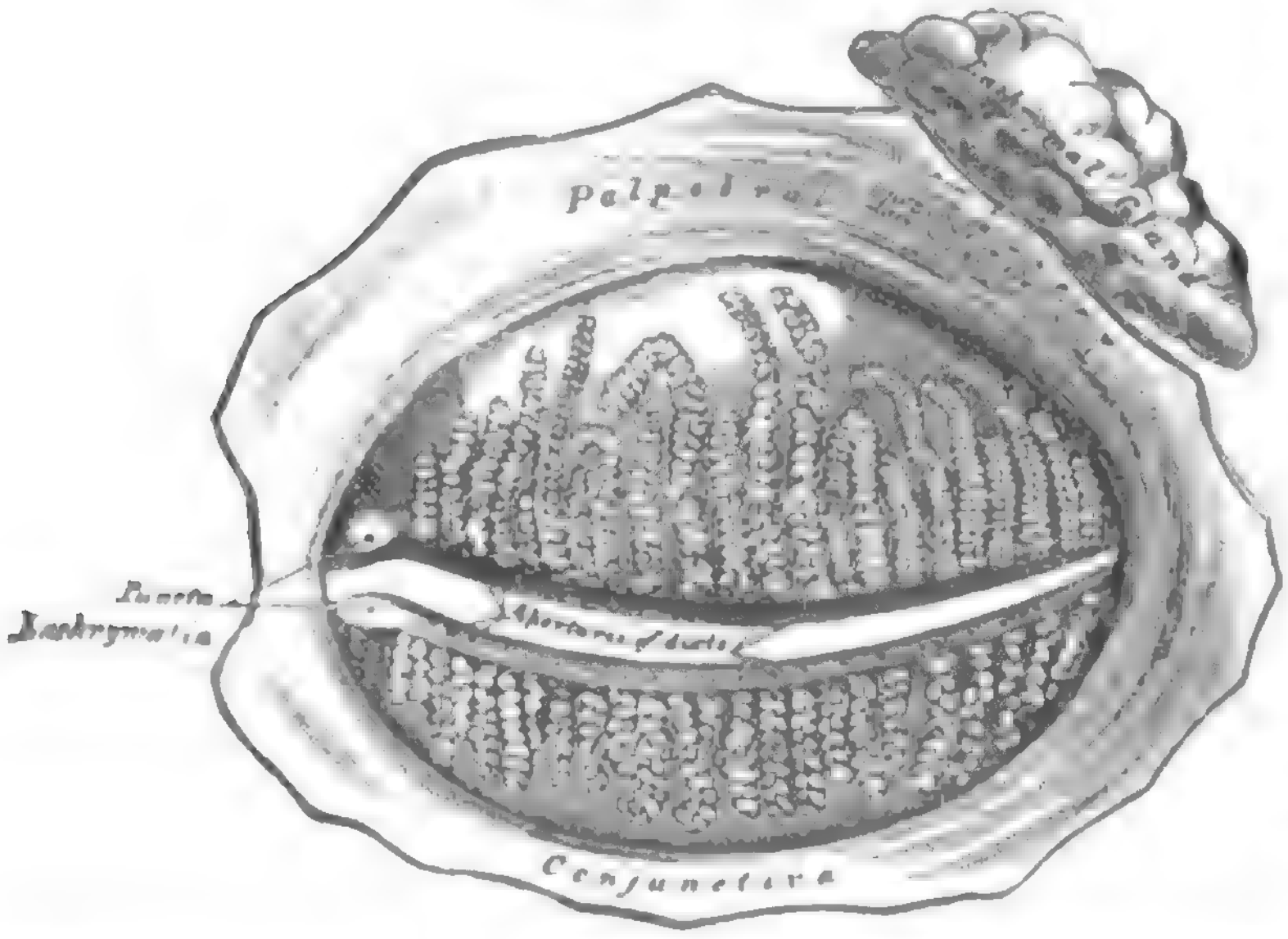

The Meibomian Glands, etc., seen from the inner surface of the eyelids.

---

[1] Recent observations have proved that the so-called "tarsal cartilages" do not contain any cartilage-cells and that the name is a misnomer.

The *eyelashes* (*cilia*) are attached to the free edges of the eyelids; they are short, thick, curved hairs arranged in a double or triple row at the margin of the lids: those of the upper lid, more numerous and longer than the lower, curve upward; those of the lower lid curve downward, so that they do not interlace in closing the lids.

The **Conjunctiva** is the mucous membrane of the eye. It lines the inner surface of the eyelids and is reflected over the fore part of the sclerotic and cornea. In each of these situations its structure presents some peculiarities.

The *palpebral portion of the conjunctiva* is thick, opaque, highly vascular, and covered with numerous papillæ, which in the disease called *granular lids* become greatly hypertrophied. At the margin of the lids it becomes continuous with the lining membrane of the ducts of the Meibomian glands, and through the lachrymal canals with the lining membrane of the lachrymal sac and nasal duct. At the outer angle of the upper lid it may be traced along the lachrymal ducts into the lachrymal gland, and at the inner angle of the eye it forms a semilunar fold, the *plica semilunaris.* The folds formed by the reflection of the conjunctiva from the lids on to the eye are called the *superior* and *inferior palpebral folds*, the former being the deeper of the two. Upon the *sclerotic* the conjunctiva is loosely connected to the globe: it becomes thinner, loses its papillary structure, is transparent, and only slightly vascular in health. Upon the *cornea* the conjunctiva consists only of epithelium, constituting the anterior layer of the cornea (conjunctival epithelium) already described. (See p. 807.) The deeper parts of the palpebral conjunctiva present, according to Henle, a considerable proportion of lymphoid tissue. *Lymphatics* arise in the conjunctiva in a delicate zone around the cornea, from which the vessels run to the ocular conjunctiva.

At the point of reflection of the conjunctiva from the lid on to the globe of the eye, termed the *fornix conjunctivæ*, are a number of mucous glands which are much convoluted. They are chiefly found in the upper lid. Other glands, analogous to lymphoid follicles and called by Henle "*trachoma glands*," are found in the conjunctiva, and, according to Stromeyer, are chiefly situated near the inner canthus of the eye. They were first described by Brush, in his description of Peyer's patches of the small intestines, as "identical structures existing in the under eyelid of the ox."

The nerves in the conjunctiva are numerous and form rich plexuses. According to Krause, they terminate in a peculiar form of tactile corpuscle which he terms "terminal bulb."

The *caruncula lachrymalis* is a small, reddish, conical-shaped body situated at the inner canthus of the eye and filling up the small triangular space in this situation, the *lacus lachrymalis.* It consists of a cluster of follicles similar in structure to the Meibomian, covered with mucous membrane, and is the source of the whitish secretion which constantly collects at the inner angle of the eye. A few slender hairs are attached to its surface. On the outer side of the caruncula is a slight semilunar fold of mucous membrane, the concavity of which is directed toward the cornea; it is called the *plica semilunaris.* Müller found smooth muscular fibres in this fold, and in some of the domestic animals a thin plate of cartilage has been discovered. This structure is considered to be the rudiment of the third eyelid in birds, the *membrana nictitans.*

LACHRYMAL APPARATUS (Fig. 540).

The lachrymal apparatus consists of the lachrymal gland, which secretes the tears, and its excretory ducts, which convey the fluid to the surface of the eye. This fluid is carried away by the lachrymal canals into the lachrymal sac and along the nasal duct into the cavity of the nose.

The **Lachrymal Gland** is lodged in a depression at the outer angle of the orbit, on the inner side of the external angular process of the frontal bone. It is of an oval form, about the size and shape of an almond. Its upper convex surface is in contact with the periosteum of the orbit, to which it is connected by a few fibrous bands. Its under concave surface rests upon the convexity of the eyeball and upon the Superior and External recti muscles. Its vessels and nerves enter its posterior border, whilst its anterior margin is closely adherent to the back part of the upper eyelid, and is covered on its inner surface by a reflection of the conjunctiva. The fore part of the gland is separated from the rest by a fibrous septum; hence it is sometimes described as a separate lobe, called the *palpebral portion of the gland* (*accessory gland of Rosenmüller*). In structure and general appearance the lachrymal resembles the salivary glands (p. 852). The histological characters are those of an albuminous gland. In the recent state the cells are so crowded with granules that their limits can hardly be defined. They contain an oval nucleus and the cell-protoplasm is finely fibrillated. Its ducts, about seven in number, run obliquely beneath the mucous membrane for a short distance, and, separating from each other, open by a series of minute orifices on the upper and outer half of the conjunctiva, near its reflection on to the globe. These orifices are arranged in a row, so as to disperse the secretion over the surface of the membrane.

FIG. 540.

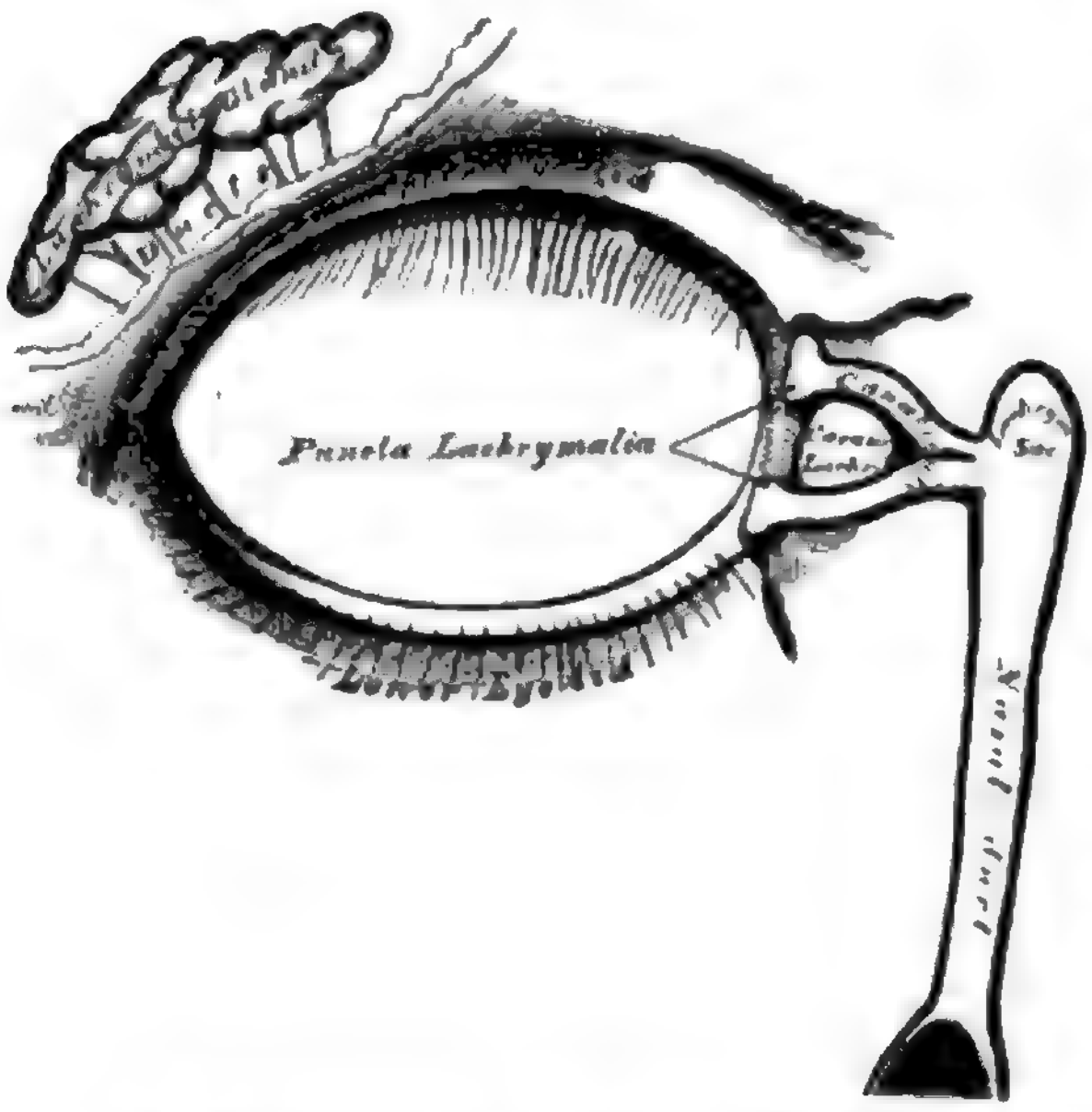

The Lachrymal Apparatus, right side.

The **Lachrymal Canals** commence at the minute orifices, *puncta lachrymalia*, seen on the margin of the lids at the outer extremity of the lacus lachrymalis. They commence on the summit of a slightly elevated papilla, the *papilla lachrymalis*, and lead into minute canals, the *canaliculi*, which proceed inward to terminate in the lachrymal sac. The *superior canal*, the smaller and shorter of the two, at first ascends, and then bends at an acute angle, and passes inward and downward to the lachrymal sac. The *inferior canal* at first descends, and then, abruptly changing its course, passes almost horizontally inward. They are dense and elastic in structure and somewhat dilated at their angle. [A fine probe should be passed into them to appreciate their length and direction.]

The **Lachrymal Sac** is the upper dilated extremity of the nasal duct, and is lodged in a deep groove formed by the lachrymal bone and nasal process of the superior maxillary. It is oval in form, its upper extremity being closed in and rounded, whilst below it is continued into the nasal duct. It is covered by a fibrous expansion derived from the tendo oculi, and on the inner side it is crossed by the Tensor tarsi muscle [or muscle of Horner, p. 371], which is attached to the ridge on the lachrymal bone. In structure it consists of a fibrous elastic coat lined internally by mucous membrane, the latter being continuous through the canaliculi with the mucous lining of the conjunctiva, and through the nasal duct with the pituitary membrane of the nose.

The **Nasal Duct** is a membranous canal about three-quarters of an inch in length which extends from the lower part of the lachrymal sac to the inferior meatus of the nose, where it terminates by a somewhat expanded orifice, provided with an imperfect valve, *the valve of Hasner*, formed by the mucous membrane. It is contained in an osseous canal formed by the superior maxillary, the lachrymal, and the inferior turbinated bones, is narrower in the middle than at each extremity, and takes a direction downward, backward, and a little outward. It is lined by mucous membrane, which is continuous below with the pituitary lining of the nose. In the canaliculi this membrane is provided with scaly epithelium, but in the lachrymal sac and nasal duct the epithelium is ciliated, as in the nose.

THE EAR.

The organ of hearing is divisible into three parts: the external ear, the middle ear or tympanum, and the internal ear or labyrinth.

The **External Ear** consists of an expanded portion named *pinna* or *auricle*, and the auditory canal, or *meatus*. The former serves to collect the vibrations of the air by which sound is produced, and the latter conducts those vibrations to the tympanum.

The **Pinna** or **Auricle** (Fig. 541) is formed by a layer of yellow fibro-cartilage covered with integument, and connected to the commencement of the auditory canal: it is of an ovoid form, its surface uneven, with its larger end directed upward. Its outer surface is irregularly concave, directed slightly forward, and presents numerous eminences and depressions which result from the foldings of its fibro-cartilaginous element. To each of these names have been assigned. Thus the external prominent rim of the auricle is called the *helix*. Another curved prominence parallel with, and in front of, the helix is called the *antihelix;* this bifurcates above, so as to enclose a triangular depression, the *fossa of the antihelix*. The narrow curved depression between the helix and antihelix is called the *fossa of the helix* (*fossa innominata* or *scaphoidea*); the antihelix describes a curve round a deep, capacious cavity, the *concha*, which is partially divided into two parts by the commencement of the helix. In front of the concha and projecting backward over the meatus is a small pointed eminence, the *tragus*, so called from its being generally covered on its under surface with a tuft of hair resembling a goat's beard. Opposite the tragus, and separated from it by a deep notch (*incisura intertragica*), is a small tubercle, the *antitragus*. Below this is the *lobule*, composed of tough areolar and adipose tissue, wanting the firmness and elasticity of the rest of the pinna.

Fig. 541.

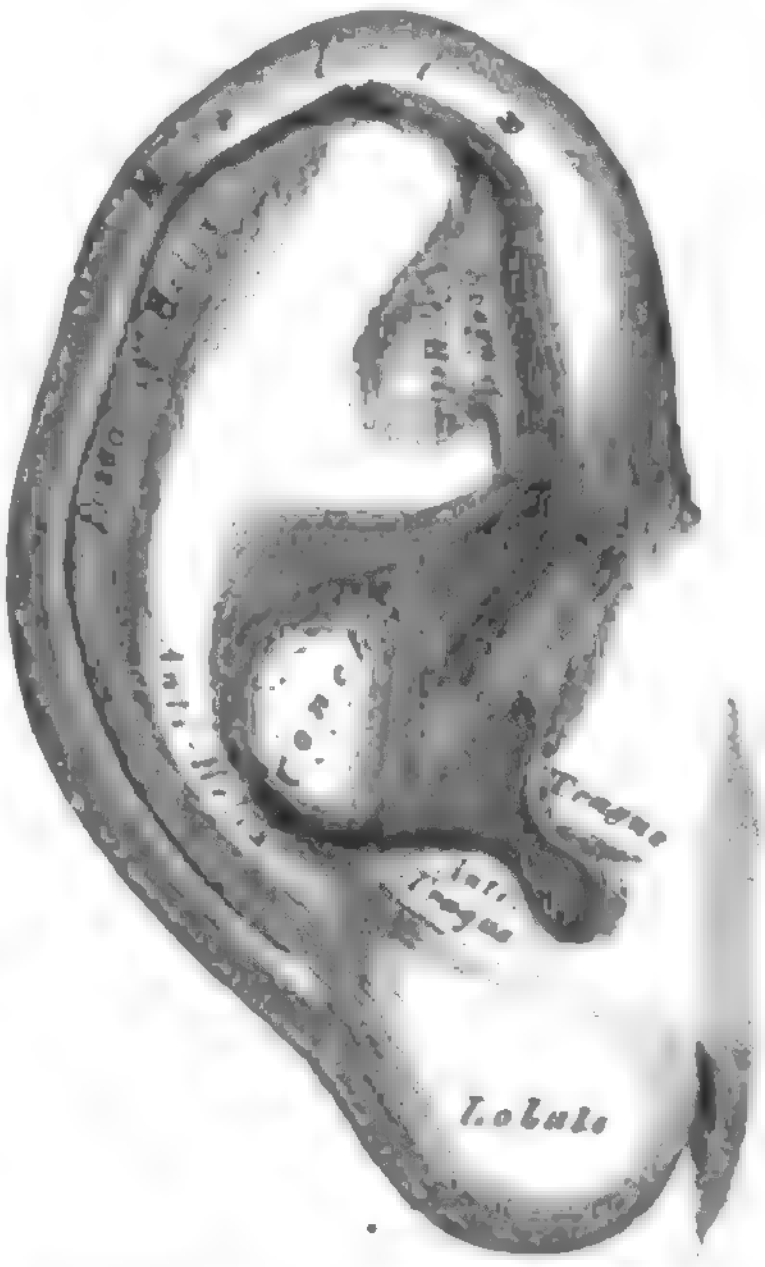

The Pinna, or Auricle, outer surface.

Structure of the Pinna.—The pinna is composed of a thin plate of yellow fibro-cartilage covered with integument and connected to the surrounding parts by ligaments and a few muscular fibres.

The *integument* is thin, closely adherent to the cartilage, and furnished with sebaceous glands, which are most numerous in the concha and scaphoid fossa.

The *cartilage of the pinna* consists of one single piece; it gives form to this part of the ear, and upon its surface are found all the eminences and depressions above described. It does not enter into the construction of all parts of the auricle; thus it does not form a constituent part of the lobule; it is deficient also between the tragus and beginning of the helix, the notch between them being filled up by dense fibrous tissue. At the front part of the pinna, where the helix bends upward, is a small projection of cartilage called the *process of the helix*. The cartilage of the pinna presents several intervals or fissures in its substance which partially separate the different parts. The fissure of the helix is a short vertical slit situated at the fore part of the pinna, immediately behind a small conical projection of cartilage, opposite the first curve of the helix (process of the helix). Another fissure, the fissure of the tragus, is seen upon the anterior surface of the tragus. The antihelix is divided below by a deep fissure into two parts: one part terminates by a pointed, tail-like extremity (*processus caudatus*); the other is continuous with the antitragus. The cartilage of the pinna is very pliable, elastic, of a yellowish color, and belongs to that form of cartilage which is known under the name of yellow fibro-cartilage.

The *ligaments of the pinna* consist of two sets: 1, those connecting it to the side of the head; 2, those connecting the various parts of its cartilage together.

The former, the most important, are two in number, anterior and posterior. The *anterior ligament* extends from the process of the helix to the root of the zygoma. The *posterior ligament* passes from the posterior surface of the concha to the outer surface of the mastoid process of the temporal bone. A few fibres connect the tragus to the root of the zygoma.

The ligaments connecting the various parts of the cartilage together are also two in number. Of these, one is a strong fibrous band stretching across from the tragus to the commencement of the helix, completing the meatus in front and partly encircling the boundary of the concha; the other extends between the concha and the processus caudatus.

The *muscles of the pinna* (Fig. 542), like the ligaments, consist of two sets: 1, those which connect it with the side of the head, moving the pinna as a whole—viz. the Attollens, Attrahens, and Retrahens aurem (p. 369); and 2, the proper muscles of the pinna, which extend from one part of the auricle to another. These are the

Helicis major.
Helicis minor.
Tragicus.
Antitragicus.
Transversus auriculæ.
Obliquus auris.

The *M. Helicis major* is a narrow vertical band of muscular fibres situated upon the anterior margin of the helix. It arises below from the process of the helix, and is inserted into the anterior border of the helix just where it is about to curve backward. It is pretty constant in its existence.

Fig. 542.

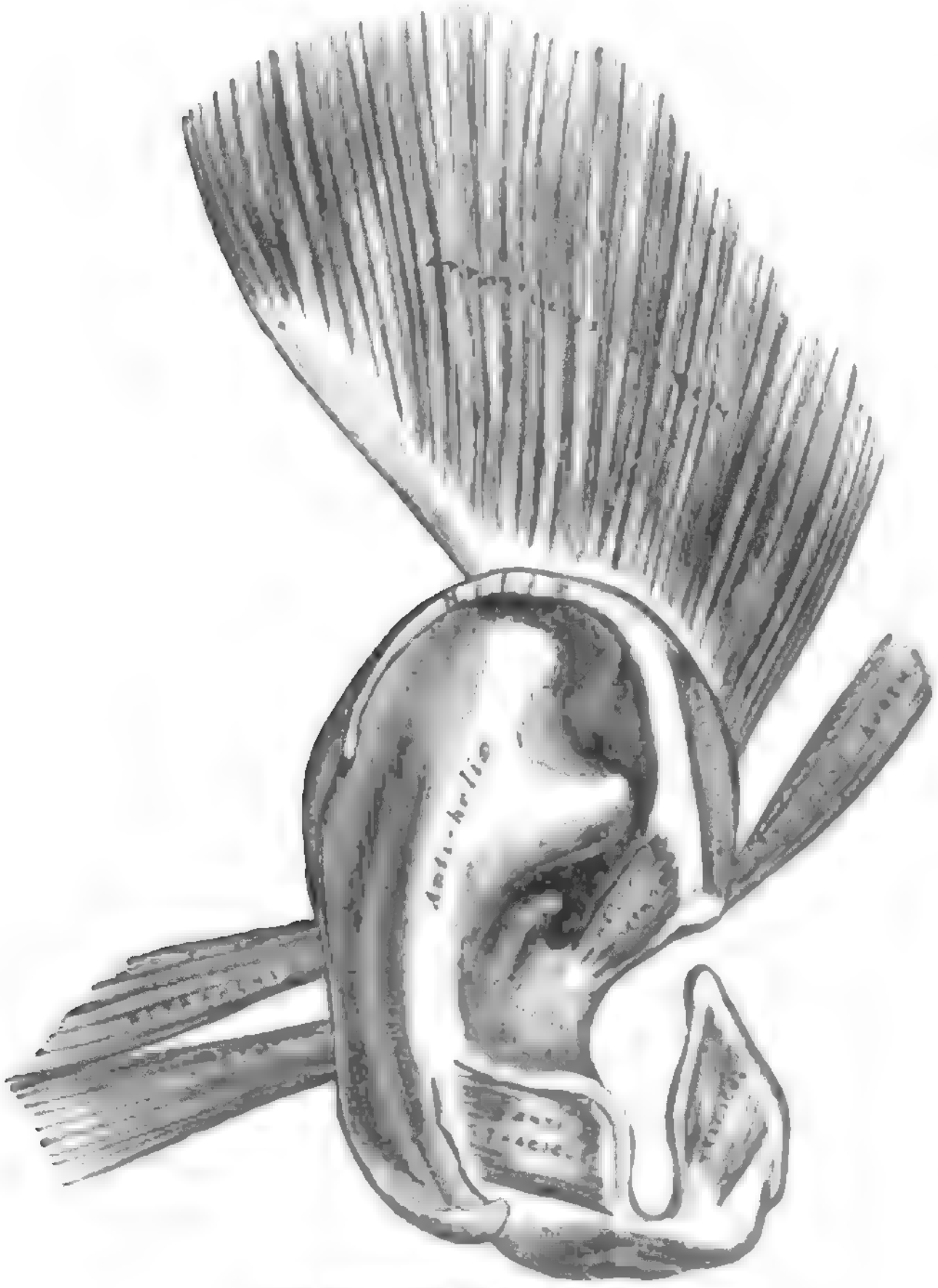

The Muscles of the Pinna.

The *M. Helicis minor* is an oblique fasciculus attached to that part of the helix which commences from the bottom of the concha.

The *Tragicus* is a short, flattened band of muscular fibres situated upon the outer surface of the tragus, the direction of its fibres being vertical.

The *Antitragicus* arises from the outer part of the antitragus: its fibres are inserted into the processus caudatus of the helix. This muscle is usually very distinct.

The *Transversus auriculæ* is placed on the cranial surface of the pinna. It consists of radiating fibres, partly tendinous and partly muscular, extending from the convexity of the concha to the prominence corresponding with the groove of the helix.

The *Obliquus auris* (Todd) consists of a few fibres extending from the upper and back part of the concha to the convexity immediately above it.

The *arteries of the pinna* are the posterior auricular, from the external carotid; the anterior auricular, from the temporal; and an auricular branch, from the occipital artery.

The *veins* accompany the corresponding arteries.

The *nerves* are the auricularis magnus, from the cervical plexus; the posterior auricular, from the facial; the auricular branch of the pneumogastric; the auriculo-temporal branch of the inferior maxillary nerve; the occipitalis minor, from the cervical plexus; and the occipitalis major or internal branch of the posterior division of the second cervical nerve.

[The student who will take a little trouble in noticing the ears of the persons whom he meets from day to day will be greatly interested and surprised to see how much the auricle varies. It may be a thick and clumsy ear or a beautifully delicate one; long and narrow or short and broad; may have a neatly-formed and distinct lobule, or one that is heavy, ungainly, and united to the cheek so as hardly to form a separate part of the auricle; may hug the head closely or flare outward so as to form almost two wings to the head. In art, and especially in medallion portraits, in which the ear is a marked (because central) feature, the auricle is of great importance. The little muscles of the auricle, though so rudimentary, can be readily called into action by the battery.]

The **Auditory Canal** (*meatus auditorius externus*) (Fig. 543) extends from the bottom of the concha to the membrana tympani. It is about an inch and a quarter in length, its direction is obliquely forward and inward, and it is slightly curved upon itself, so as to be higher in the middle than at either extremity. It forms an oval cylindrical canal, the greatest diameter being in the vertical direction at the external orifice, but in the transverse direction at the tympanic end. The calibre of the canal is narrowest about the middle. The membrana tympani, which occupies the termination of the meatus, is obliquely directed, in consequence of which the floor of the canal is longer than the roof, and the anterior wall longer than the posterior. The auditory canal is formed partly by cartilage and membrane and partly by bone.

Fig. 543.

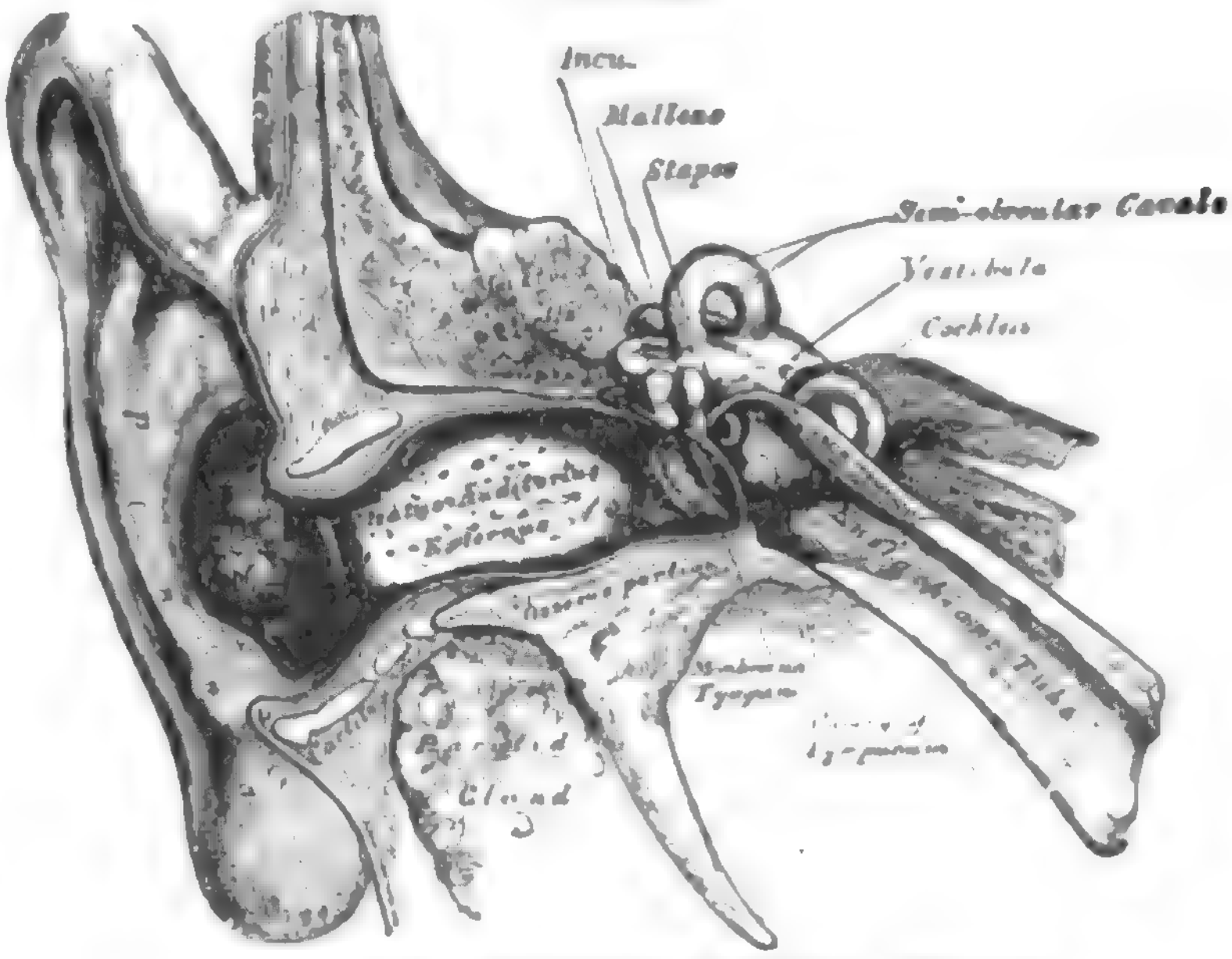

A Front View of the Organ of Hearing, right side.

The *cartilaginous portion* is about half an inch in length, being rather less than half the canal; it is formed by the cartilage of the concha and tragus, prolonged inward and firmly attached to the circumference of the auditory process. The cartilage is deficient at its upper and back part, its place being supplied by fibrous membrane. This part of the canal is rendered extremely movable by two or three deep fissures (*incisuræ Santorini*) which extend through the cartilage in a vertical direction.

The *osseous portion* is about three-quarters of an inch in length, and narrower than the cartilaginous portion. It is directed inward and a little forward, forming a slight curve in its course, the convexity of which is upward and backward. Its inner end, which communicates in the dry bone with the cavity of the tympanum, is smaller than the outer, and sloped, the anterior wall projecting beyond the posterior about two lines; it is marked, except at its upper part, by a narrow groove for the insertion of the membrana tympani. Its outer end is dilated and rough, in the greater part of its circumference, for the attachment of the cartilage of the pinna. Its vertical transverse section is oval, the greatest diameter being from above downward. The front and lower parts of this canal are formed by a curved plate of bone, which in the fœtus exists as a separate ring (tympanic bone) incomplete at its upper part.

The *skin* lining the meatus is very thin, adheres closely to the cartilaginous and osseous portion of the tube, and covers the surface of the membrana tympani, forming its outer layer. After maceration the thin pouch of epidermis, when withdrawn, preserves the form of the meatus. The skin near its orifice is furnished with hairs and sebaceous glands. In the thick subcutaneous tissue of the cartilaginous part of the meatus are numerous ceruminous glands which secrete the ear-wax: their ducts open on the surface of the skin.

The *arteries* supplying the meatus are branches from the posterior auricular, internal maxillary, and temporal.

The *nerves* are chiefly derived from the auriculo-temporal branch of the inferior maxillary nerve.

MIDDLE EAR, OR TYMPANUM.

The **Middle Ear,** or **Tympanum** [τυμπανον, a drum], is an irregular cavity compressed from without inward, and situated within the petrous bone. It is placed above the jugular fossa, the carotid canal lying in front, the mastoid cells behind, the meatus auditorius externally, and the labyrinth internally. It is filled with air, and communicates with the pharynx by the Eustachian tube. The tympanum is traversed by a chain of movable bones, which connect the membrana tympani with the labyrinth, and serve to convey the vibrations communicated to the membrana tympani across the cavity of the tympanum to the internal ear.

The *cavity of the tympanum* measures about five lines from before backward, three lines in the vertical direction, and between two and three in the transverse, being a little broader behind and above than it is below and in front. It is bounded externally by the membrana tympani and meatus; internally by the outer surface of the internal ear; and communicates behind with the mastoid cells, and in front with the Eustachian tube and canal for the Tensor tympani. Its roof and floor are formed by thin osseous laminæ, the one forming the roof being a thin plate situated on the anterior surface of the petrous bone close to its angle of junction with the squamous portion of the temporal bone.

The **roof** is broad, flattened, and formed of a thin plate of bone, which separates the cranial and tympanic cavities.

The **floor** is narrow and corresponds to the jugular fossa, which lies beneath. It presents near the inner wall a small aperture for the passage of Jacobson's nerve.

The **outer wall** is formed mainly by the membrana tympani, partly by the ring of bone into which this membrane is inserted. It presents three small apertures—the iter chordæ posterius, the Glaserian fissure, and the iter chordæ anterius.

The *aperture of the iter chordæ posterius* is in the angle of junction between the posterior and external walls of the tympanum, immediately behind the membrana tympani and on a level with its centre; it leads into a minute canal which descends in front of the aquæductus Fallopii and terminates in that canal near the stylo-mastoid foramen. Through it the chorda tympani nerve enters the tympanum.

The *Glaserian fissure* opens just above and in front of the ring of bone into which the membrana tympani is inserted; in this situation it is a mere slit about a line in length. It lodges the long process of the malleus and gives passage to some tympanic vessels.

The *aperture of the iter chordæ anterius* is seen just above the preceding fissure; it leads into a canal (*canal of Huguier*) which runs parallel with the Glaserian fissure. Through it the chorda tympani nerve leaves the tympanum.

The **internal wall of the tympanum** (Fig. 544) is vertical in direction and looks directly outward. It presents for examination the following parts:

Fenestra ovalis.
Fenestra rotunda.
Promontory.
Ridge of the aquæductus Fallopii.
Pyramid.
Opening for the Stapedius.

The *fenestra ovalis* is a reniform opening leading from the tympanum into the vestibule; its long diameter is directed horizontally, and its convex border is upward. The opening in the recent state is occupied by the base of the stapes, which is connected to the margin of the foramen by an annular ligament.

The *fenestra rotunda* is an aperture placed at the bottom of a funnel-shaped depression leading into the cochlea. It is situated below and rather behind the fenestra ovalis, from which it is separated by a rounded elevation, the *promontory;* it is closed in the recent state by a membrane (*membrana tympani secundaria*, Scarpa). This membrane is concave toward the tympanum, convex toward the cochlea. It consists of three layers: the external, or mucous, derived from the mucous lining of the tympanum; the internal, or serous, from the lining membrane of the cochlea; and an intermediate or fibrous layer.

FIG. 544.

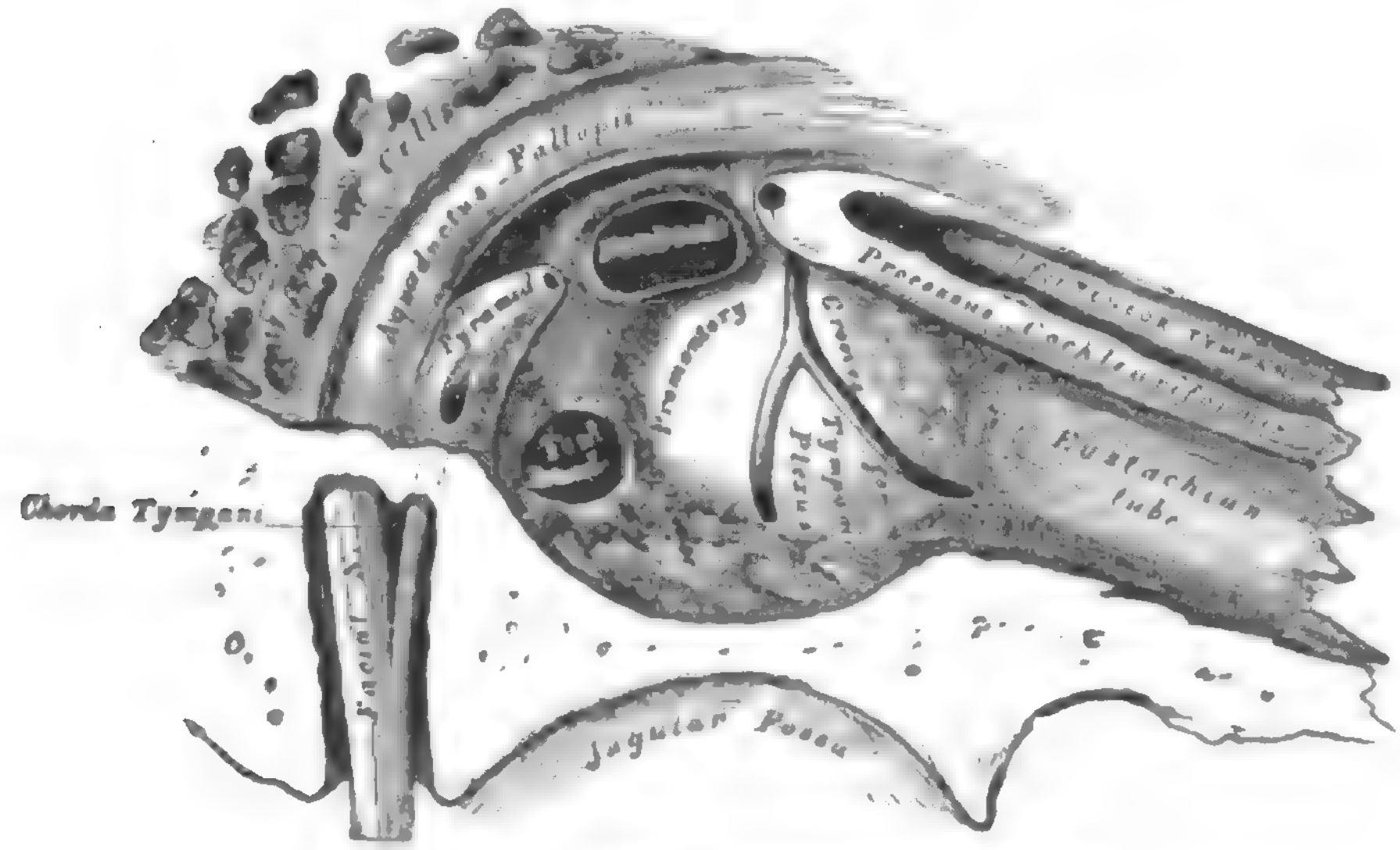

View of Inner Wall of Tympanum (enlarged).

The *promontory* is a rounded hollow prominence formed by the projection outward of the first turn of the cochlea; it is placed between the fenestræ, and is furrowed on its surface by three small grooves which lodge branches of the tympanic plexus.

The *rounded eminence of the aquæductus Fallopii*, the prominence of the bony canal in which the portio dura [facial nerve] is contained, traverses the inner wall of the tympanum above the fenestra ovalis, and behind that opening curves nearly vertically downward along the posterior wall.

The *pyramid* is a conical eminence situated immediately behind the fenestra ovalis and in front of the vertical portion of the eminence above described; it is hollow in the interior, and contains the Stapedius muscle; its summit projects forward toward the fenestra ovalis, and presents a small aperture which transmits the tendon of the muscle. The cavity in the pyramid is prolonged into a minute canal which communicates with the aquæductus Fallopii and transmits the nerve which supplies the Stapedius.

The **posterior wall of the tympanum** is wider above than below, and presents for examination the

Openings of the mastoid cells [Fig. 143, p. 172].

These consist of one large irregular aperture and several smaller openings situated at the upper part of the posterior wall; they lead into canals which communicate with large irregular cavities contained in the interior of the mastoid process. These cavities vary considerably in number, size, and form; they are lined by mucous membrane continuous with that covering the cavity of the tympanum. [The ease with which an inflammation of the middle ear may extend into the mastoid cells and produce "mastoid disease," and even lead to thrombosis of the lateral sinus and to abscesses of the brain, is now readily appreciated.]

The **anterior wall of the tympanum** is wider above than below; it corresponds with the carotid canal, from which it is separated by a thin plate of bone perforated by the tympanic branch of the internal carotid. It presents for examination the

Canal for the Tensor tympani. Orifices of the Eustachian tube.
The processus cochleariformis.

The orifice of the canal for the Tensor tympani and the orifice of the Eustachian tube are situated at the upper part of the anterior wall, being separated from each other by a thin, delicate, horizontal plate of bone, the *processus cochleariformis.* These canals run from the tympanum forward, inward, and a little downward to the retiring angle between the squamous and petrous portions of the temporal bone.

The *canal for the Tensor tympani* is the superior and the smaller of the two; it is rounded, and lies beneath the upper surface of the petrous bone close to the hiatus Fallopii. The tympanic end of this canal forms a conical eminence which is prolonged backward into the cavity of the tympanum, and is perforated at its summit by an aperture which transmits the tendon of the muscle contained in it. This eminence is sometimes called the *anterior pyramid.* The canal contains the Tensor tympani muscle.

The *Eustachian tube* is the channel through which the tympanum communicates with the pharynx. Its length is from an inch and a half to two inches, and its direction downward, forward, and inward. It is formed partly of bone, partly of cartilage and fibrous tissue.

[FIG. 545.

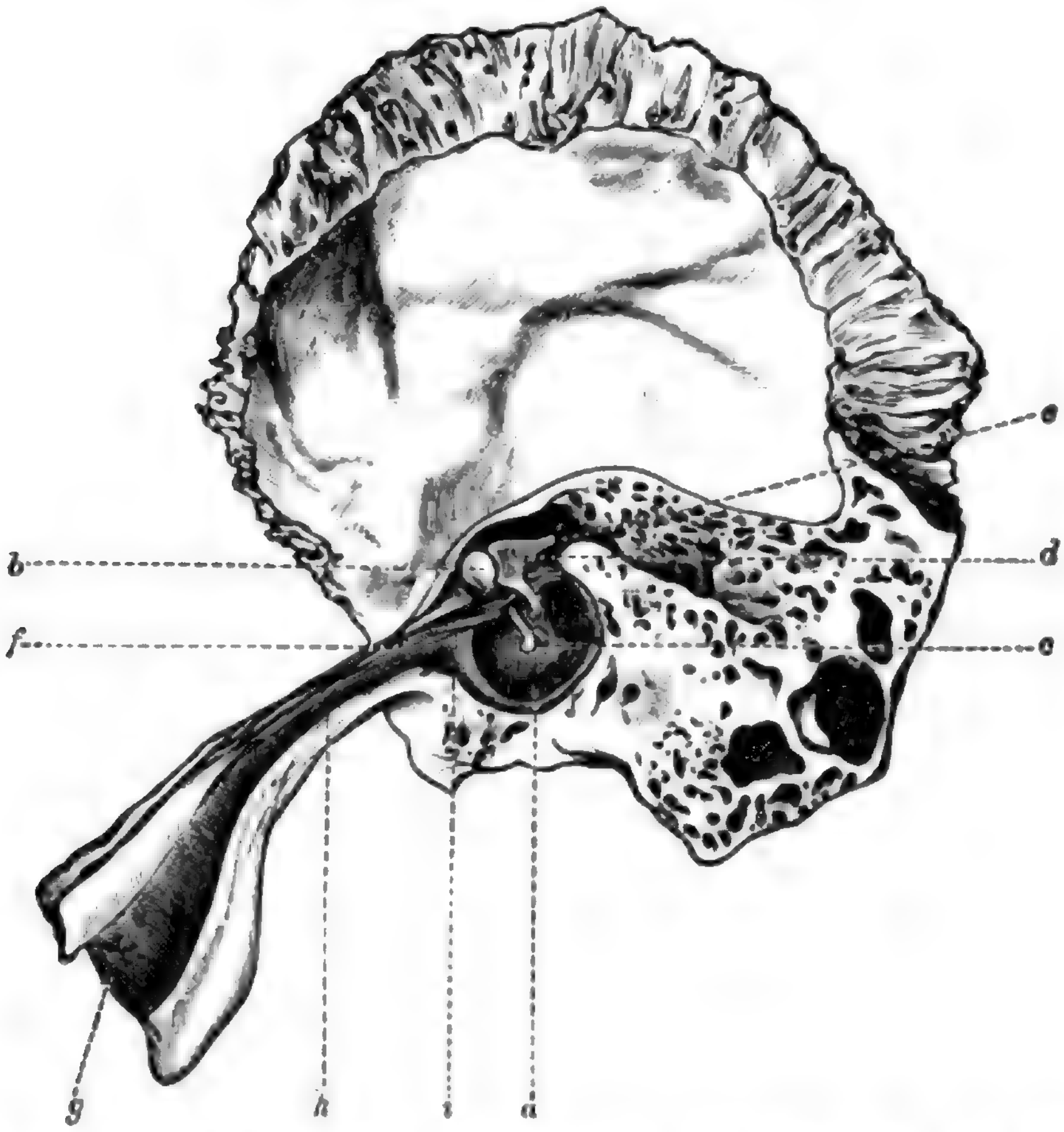

Vertical Section of the Right Eustachian Tube, Tympanic Cavity, and Mastoid Cells, with inner surface of the squama above, viewed from within: *a*, membrana tympani; *b*, head of malleus; *c*, end of the manubrium mallei; *d*, incus; *e*, short process of incus; *f*, Tensor tympani muscle; *g*, faucial opening of the Eustachian tube; *h*, isthmus tubæ; *i*, tympanic mouth of Eustachian tube.]

The *osseous portion* is about half an inch in length. It commences in the lower part of the anterior wall of the tympanum, below the processus cochleariformis, and, gradually narrowing, terminates in an oval dilated opening at the angle of junction of the petrous and squamous portions, its extremity presenting a jagged margin which serves for the attachment of the cartilaginous portion.

The *cartilaginous portion*, about an inch in length, is formed of a triangular plate of elastic fibro-cartilage curled upon itself, an interval being left below between the margins of the cartilage, which is completed by fibrous tissue. Its canal is narrow behind, wide, expanded, and somewhat trumpet-shaped in front, terminating by an oval orifice at the upper part and side of the pharynx, behind the back part of the inferior meatus [Fig. 184, p. 218]. Through this canal the mucous membrane of the pharynx is continuous with that which lines the tympanum. The mucous membrane is covered with ciliated epithelium.

The **Membrana tympani** separates the cavity of the tympanum from the bottom of the external meatus. It is a thin, semi-transparent membrane, nearly oval in form, somewhat broader above than below, and directed very obliquely downward and inward. Its circumference is contained in a groove at the inner end of the meatus, which skirts the circumference of this part, excepting above. The handle of the malleus descends vertically between the inner and middle layers of this membrane as far down as its centre, where it is firmly attached, drawing the membrane inward, so that its outer surface is concave, its inner convex.

Structure.—This membrane is composed of three layers—an external (cuticular), a middle (fibrous), and an internal (mucous). The *cuticular lining* is derived from the integument lining the meatus. The *fibrous layer* consists of fibrous and elastic tissues; some of the fibres radiate from near the centre to the circumference; others are arranged in the form of a dense circular ring around the attached margin of the membrane. The *mucous lining* is derived from the mucous lining of the tympanum. The vessels pass to the membrana tympani along the handle of the malleus and are distributed between its layers.

OSSICLES OF THE TYMPANUM (Fig. 546).

The tympanum is traversed by a chain of movable bones three in number—the *malleus*, *incus*, and *stapes*. The former is attached to the membrana tympani, the latter to the fenestra ovalis, the incus being placed between the two, to both of which it is connected by delicate articulations.

The **Malleus**, so named from its fancied resemblance to a hammer, consists of a head, neck, and three processes—the handle or manubrium, the processus gracilis, and the processus brevis.

The *head* is the large upper extremity of the bone; it is oval in shape, and articulates posteriorly with the incus, being free in the rest of its extent.

The *neck* is the narrow, contracted part just beneath the head, and below this is a prominence to which the various processes are attached.

FIG. 546.

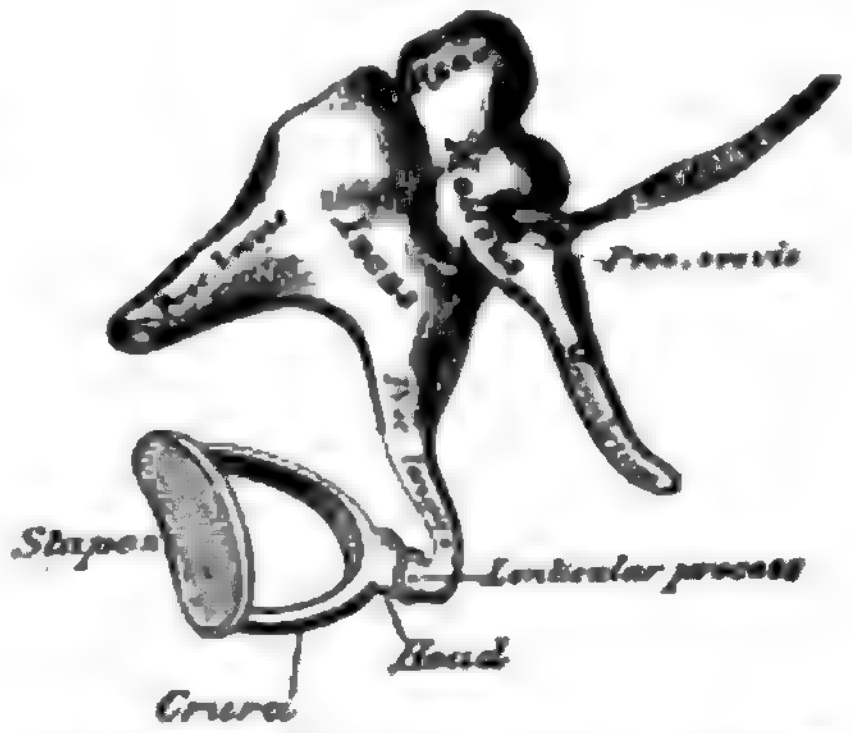

The Small Bones of the Ear, seen from the outside (enlarged).

The *manubrium* is a vertical process of bone which is connected by its outer margin with the membrana tympani. It decreases in size toward its extremity, where it is curved slightly forward and flattened from within outward. On the inner side, near its upper end, is a slight projection into which the tendon of the Tensor tympani is inserted.

The *processus gracilis* is a long and very delicate process which passes from the eminence below the neck forward and outward to the Glaserian fissure, to which it is connected by bone and ligamentous fibres.

The *processus brevis* is a slight conical projection which springs from the root of the manubrium and lies in contact with the membrana tympani.

The **Incus** has received its name from its supposed resemblance to an anvil, but it is more like a bicuspid tooth with two roots, which differ in length and are widely separated from each other. It consists of a body and two processes.

The *body* is somewhat quadrilateral, but compressed laterally. On the anterior surface of its summit is a deeply concavo-convex facet, which articulates with the malleus; in the fresh state it is covered with cartilage and lined with synovial membrane.

The two processes diverge from each other nearly at right angles.

The *short process*, somewhat conical in shape, projects nearly horizontally backward, and is attached to the margin of the opening leading into the mastoid cells by ligamentous fibres.

The *long process*, longer and more slender than the preceding, descends nearly vertically behind and parallel to the handle of the malleus, and, bending inward, terminates in a rounded globular projection, the *os orbiculare*, or lenticular process, which is tipped with cartilage and articulates with the head of the stapes. In the fœtus the os orbiculare exists as a separate bone, but becomes united to the long process of the incus in the adult.

The **Stapes**, so called from its close resemblance to a stirrup, consists of a head, neck, two branches, and a base.

The *head* presents a depression tipped with cartilage which articulates with the os orbiculare.

The *neck*, the constricted part of the bone below the head, receives the insertion of the Stapedius muscle.

The *two branches* (*crura*) diverge from the neck, and are connected at their extremities by a flattened, oval-shaped plate (the *base*), which forms the foot of the stirrup and is fixed to the margin of the fenestra ovalis by ligamentous fibres.

Ligaments of the Ossicula.—These small bones are connected with each other and with the walls of the tympanum by ligaments, and moved by small muscles. The articular surfaces of the malleus and incus and the orbicular process of the incus and head of the stapes are covered with cartilage, connected together by delicate capsular ligaments, and lined by synovial membrane. The ligaments connecting the ossicula with the walls of the tympanum are four in number—two for the malleus, one for the incus, and one for the stapes.

The *anterior ligament of the malleus* was formerly described by Sömmerring as a muscle (*Laxator tympani*). It is now, however, believed by most observers to consist of ligamentous fibres only. It is attached by one extremity to the neck of the malleus, just above the processus gracilis, and by the other to the anterior wall of the tympanum close to the Glaserian fissure, some of its fibres being prolonged through the fissure.

The *suspensory ligament of the malleus* is a delicate, round bundle of fibres which descends perpendicularly from the roof of the tympanum to the head of the malleus.

The *posterior ligament of the incus* is a short, thick, ligamentous band which connects the extremity of the short process of the incus to the posterior wall of the tympanum, near the margin of the opening of the mastoid cells.

The *annular ligament of the stapes* connects the circumference of the base of this bone to the margin of the fenestra ovalis.

A *suspensory ligament of the incus* has been described by Arnold as descending from the roof of the tympanum to the upper part of the incus near its articulation with the malleus.

The **muscles of the tympanum** are two:

Tensor tympani. Stapedius.

The *Tensor tympani*, the largest, is contained in the bony canal above the osseous portion of the Eustachian tube, from which it is separated by the processus cochleariformis. It arises from the under surface of the petrous bone, from the cartilaginous portion of the Eustachian tube, and from the osseous canal in which it is contained. Passing backward through the canal, it terminates in a slender tendon which enters the tympanum and makes a sharp bend outward round the extremity of the processus cochleariformis, and is inserted into the handle of the malleus near its root. It is supplied by a branch from the otic ganglion.

The *Stapedius* arises from the sides of a conical cavity hollowed out of the interior of the pyramid: its tendon emerges from the orifice at the apex of the pyramid, and, passing forward, is inserted into the neck of the stapes. Its surface is aponeurotic, its interior fleshy, and its tendon occasionally contains a slender bony spine, which is constant in some Mammalia. It is supplied by the tympanic branch of the facial nerve.

ACTIONS.—The Tensor tympani draws the membrana tympani inward, and thus heightens its tension. The Stapedius draws the head of the stapes backward, and thus causes the base of the bone to rotate on a vertical axis drawn through its own centre: in doing this the back part of the base would be pressed inward toward the vestibule, while the fore part would be drawn from it. It probably compresses the contents of the vestibule.

The **mucous membrane of the tympanum** is thin, slightly vascular, and continuous with the mucous membrane of the pharynx through the Eustachian tube. It invests the ossicula and the muscles and nerves contained in the tympanic cavity, forms the internal layer of the membrana tympani, covers the foramen rotundum, and is reflected into the mastoid cells, which it lines throughout. In the tympanum and mastoid cells this membrane is pale, thin, slightly vascular, and covered with ciliated epithelium. In the osseous portion of the Eustachian tube the membrane is thin, but in the cartilaginous portion it is very thick, highly vascular, covered with laminar ciliated epithelium, and provided with numerous mucous glands.

The **arteries supplying the tympanum** are five in number. Two of them are larger than the rest—viz. the tympanic branch of the internal maxillary, which supplies the membrana tympani, and the stylo-mastoid branch of the posterior auricular, which supplies the back part of the tympanum and mastoid cells. The smaller branches are—the petrosal branch of the middle meningeal, which enters through the hiatus Fallopii, a branch from the ascending pharyngeal, which passes up the Eustachian tube, and the tympanic branch from the internal carotid, given off in the carotid canal and perforating the thin anterior wall of the tympanum.

The **veins of the tympanum** terminate in the middle meningeal and pharyngeal veins, and through these in the internal jugular.

The **nerves of the tympanum** may be divided into—1, those supplying the muscles; 2, those distributed to the lining membrane; 3, branches communicating with other nerves.

Nerves to Muscles.—The Tensor tympani is supplied by a branch from the otic ganglion; the Stapedius by the tympanic branch of the facial (Sömmerring).

The *nerves distributed to the lining membrane* are derived from the tympanic plexus.

The *communications* which take place in the tympanum are between the tympanic branch of the glosso-pharyngeal with the sympathetic and with filaments derived from the intumescentia gangliformis of the facial.

The *tympanic branch of the glosso-pharyngeal* (Jacobson's nerve) enters the tympanum by an aperture in its floor close to the inner wall, and ascends on to the promontory. It distributes branches to the fenestra rotunda, fenestra ovalis, and to the lining membrane of the tympanum and Eustachian tube, and divides into three branches of communication, which are contained in grooves on the promontory. One of these arches forward and downward to the carotid canal to join the carotid plexus. A second runs forward and upward to join the greater superficial petrosal nerve as it lies in the hiatus Fallopii. The third branch runs upward through the substance of the petrous portion of the temporal bone. In its course it passes by the ganglionic enlargement of the facial nerve, and, receiving a connecting filament from it, becomes the lesser superficial petrosal nerve, which joins the otic ganglion.

The *chorda tympani* quits the facial near the stylo-mastoid foramen, enters the tympanum at the base of the pyramid, and arches forward across its cavity, between the handle of the malleus and long process of the incus, to the iter chordæ anterius, through which it enters the canal of Huguier. It is invested by a reflection of the lining membrane of the tympanum.

INTERNAL EAR OR LABYRINTH.

The **Internal Ear** is the essential part of the organ, receiving the ultimate distribution of the auditory nerve. It is called the **labyrinth,** from the complexity of its shape, and consists of three parts—the *vestibule, semicircular canals*, and *cochlea*. It is formed by a series of cavities channelled out of the substance of the petrous bone, communicating externally with the cavity of the tympanum through the fenestra ovalis and rotunda, and internally with the meatus auditorius internus, which contains the auditory nerve. Within the osseous labyrinth is contained the membranous labyrinth, upon which the ramifications of the auditory nerve are distributed.

The **Vestibule** (Fig. 547) is the common central cavity of communication between the parts of the internal ear. It is situated on the inner side of the tympanum, behind the cochlea, and in front of the semicircular canals. It is somewhat ovoidal in shape from before backward, flattened from within outward, and measures about one-fifth of an inch from before backward as well as from above downward, being narrower from without inward. On its *outer* or *tympanic wall* is the fenestra ovalis, closed in the recent state by the base of the stapes, and its annular ligament. On its *inner wall,* at the fore part, is a small circular depression, *fovea hemispherica,* which is perforated at its anterior and inferior part by several minute holes (*macula cribrosa*) for the passage of the filaments of the auditory nerve; and behind this depression is a vertical ridge, the *pyramidal eminence* (*crista vestibuli*). At the hinder part of the inner wall is the orifice of the *aquæductus vestibuli,* which extends to the posterior surface of the petrous portion of the temporal bone. It transmits a small vein, and, according to some, contains a tubular prolongation of the lining membrane of the vestibule, which ends in a cul-de-sac between the layers of the dura mater within the cranial cavity. On the *upper wall* or *roof* is a transversely-oval depression, *fovea semi-elliptica,* separated from the fovea hemispherica by the pyramidal eminence already mentioned. Behind, the semicircular canals open into the vestibule by five orifices. In front is a large oval opening which communicates with the scala vestibuli of the cochlea by a single orifice, *apertura scalæ vestibuli cochleæ.*

FIG. 547.

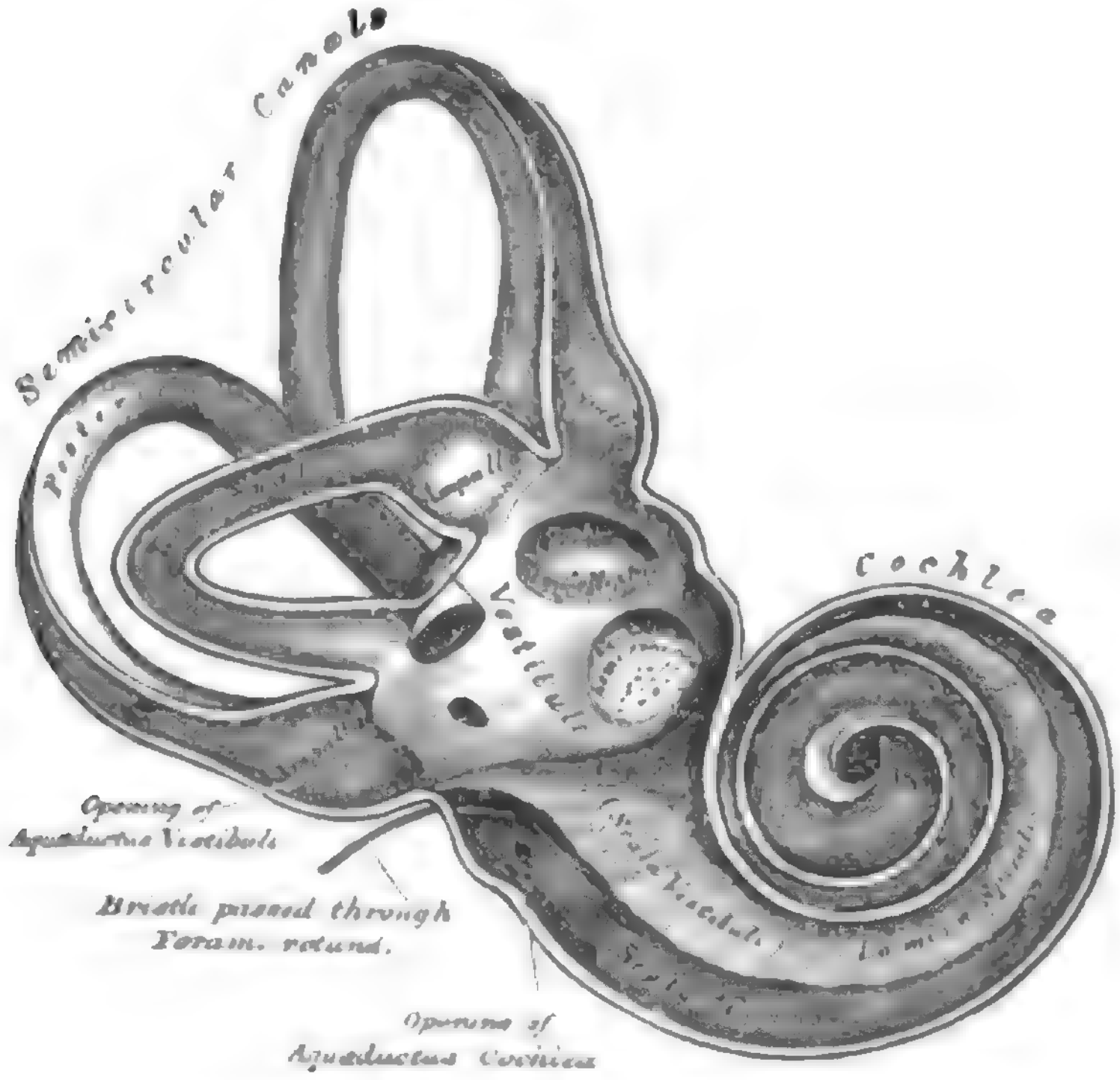
Semicircular Canals
Cochlea
Vestibule
Opening of Aquæductus Vestibuli
Bristle passed through Foram. rotund.
Scala Vestibuli
Lamina Spiralis
Opening of Aquæductus Cochleæ

The Osseous Labyrinth laid open (enlarged).

The **Semicircular Canals** are three bony canals situated above and behind the vestibule. They are of unequal length, compressed from side to side, and describe the greater part of a circle. They measure about one-twentieth of an inch in diameter, and each presents a dilatation at one end, called the *ampulla*, which measures more than twice the diameter of the tube. These canals open into the vestibule by five orifices, one of the apertures being common to two of the canals.

The *superior semicircular canal* is vertical in direction, and stretches across the petrous portion of the temporal bone at right angles to its posterior surface; its arch forms a round projection on the anterior surface of the petrous bone. It describes about two-thirds of a circle. Its outer extremity, which is ampullated, commences by a distinct orifice in the upper part of the vestibule; the opposite end of the canal, which is not dilated, joins with the corresponding part of the posterior canal and opens by a common orifice with it in the back part of the vestibule.

The *posterior semicircular canal*, also vertical in direction, is directed backward nearly parallel to the posterior surface of the petrous bone: it is the longest of the three, its ampullated end commencing at the lower and back part of the vestibule, its opposite end joining to form the common canal already mentioned.

The *external* or *horizontal canal* is the shortest of the three, its arch being directed outward and backward; thus each semicircular canal stands at right angles to the other two. Its ampullated end corresponds to the upper and outer angle of the vestibule, just above the fenestra ovalis; its opposite end opens by a distinct orifice at the upper and back part of the vestibule.

The **Cochlea** bears some resemblance to a common snail-shell: it forms the anterior part of the labyrinth, is conical in form, and placed almost horizontally in front of the vestibule; its apex is directed forward and outward toward the upper and front part of the inner wall of the tympanum; its base corresponds with the anterior depression at the bottom of the internal auditory meatus, and is perforated by numerous apertures for the passage of the cochlear branch of the auditory nerve. It measures about a quarter of an inch in length, and its breadth toward the base is about the same. It consists of a conical-shaped central axis, the *modiolus* or *columella;* of a canal wound spirally round the axis for two turns and a half from the base to the apex; and of a delicate lamina (the *lamina spiralis*) contained within the canal, which follows its windings and partially subdivides it into two.

The *central axis*, or *modiolus*, is conical in form, and extends from the base to the apex of the cochlea. Its base is broad, corresponds with the first turn of the cochlea, and is perforated by numerous orifices, which transmit filaments of the cochlear branch of the auditory nerve; the axis diminishes rapidly in size in the second coil, and terminates within the last half-coil, or *cupola*, in an expanded, delicate, bony lamella which resembles the half of a funnel divided longitudinally, and is called the *infundibulum;* the broad part of this funnel is directed toward the summit of the cochlea, and blends with the cupola or last half-turn of the spiral canal of the cochlea. At this point the two larger scalæ of the cochlea, the scala tympani and scala vestibuli, communicate by an opening called the *helicotrema*. The outer surface of the modiolus forms part of the wall of the spiral canal, and is dense in structure; but its centre is channelled, as far as the last half-coil, by numerous branching canals, which transmit nervous filaments in regular succession into the canal of the cochlea or on to the surface of the lamina spiralis. One of these, larger than the rest, occupies the centre of the modiolus, and is named the *canalis centralis modioli;* it extends from the base to the extremity of the modiolus, and transmits a small nerve and artery (*arteria centralis modioli*).

The *spiral canal* (Fig. 548) takes two turns and a half round the modiolus. It is about an inch and a half in length, measured along its outer wall, and diminishes gradually in size from the base to the summit, where it terminates in a cul-de-sac, the *cupola*, which forms the apex of the cochlea. The commencement of this canal is about the tenth of an inch in diameter; it diverges from the modiolus toward the tympanum and vestibule, and presents three openings: one, the *fenestra rotunda*, communicates with the tympanum; in the recent state this aperture is closed by a membrane, the *membrana tympani secundaria.* Another aperture, of an oval form, enters the vestibule. The third is the aperture of the *aquæductus cochleæ*, leading to a minute funnel-shaped canal which opens on the basilar surface of the petrous bone and transmits a small vein.

FIG. 548.

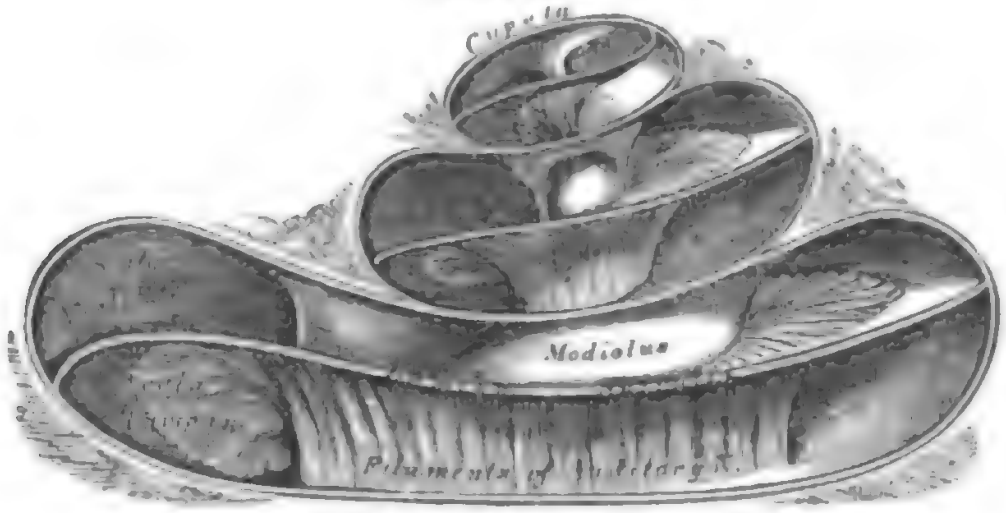

The Cochlea laid open (enlarged).

The interior of the spiral canal (Fig. 549) is partially divided into two, in the dry state, by a thin bony plate, the *lamina spiralis* [L. S.], which consists of two thin lamellæ of bone, between which are numerous canals for the passage of nerve-fibres. This lamina projects from the modiolus into the canal, but does not reach more than halfway toward the outer wall of the tube. From its extremity a thin membrane extends to the outer wall, and completes the division of the canal into an upper compartment, the *scala vestibuli* [S. V.], and a lower one, the *scala tympani* [S. T.]. By a second membrane a portion of the upper of these two canals is cut off from the rest, constituting the *scala media* [S. M.]. The lamina spiralis ends above in a hook-shaped process, which partly bounds the helicotrema. At the point where the osseous lamina is attached to the modiolus is a small canal which winds round the modiolus, and was denominated by Rosenthal the *canalis spiralis modioli:* it is occupied by a swelling of the cochlear nerve, in which ganglion-cells are found,

FIG. 549.

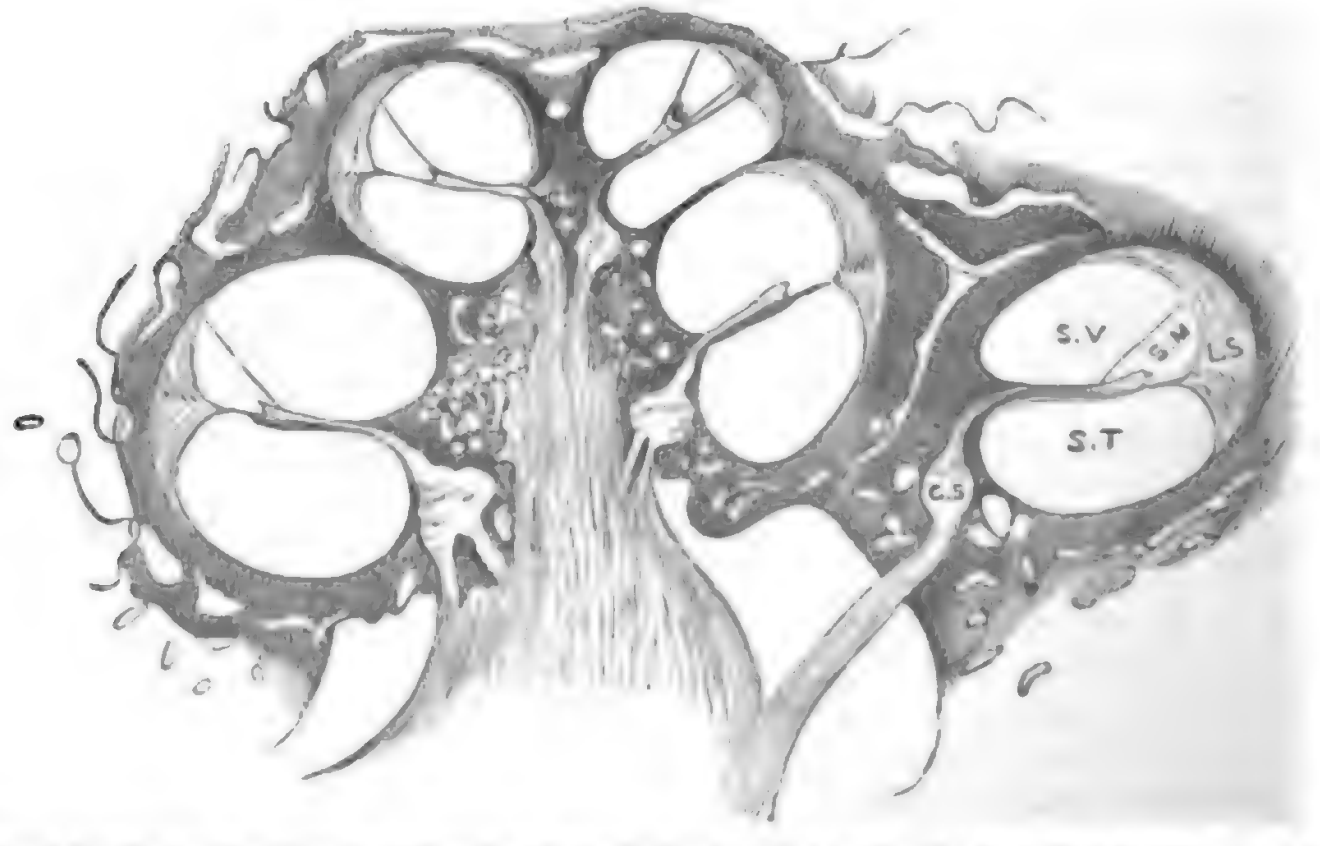

Longitudinal Section of the Cochlea, showing the relations of the scalæ, the ganglion spirale, etc.: S. V., scala vestibuli; S. T., scala tympani; S. M., scala media; L. S., ligamentum spirale; G. S., ganglion spirale. [The membrane of Reissner is intentionally omitted in the second turn to the right. See note (¹) on p. 835.]

the *ganglion spirale* [G. S.], from which the nerves pass to the osseous lamina and organ of Corti.

The osseous lamina, as above stated, extends only part of the distance between the modiolus and the outer bony wall of the cochlea. Near its outer end the periosteum on the upper or vestibular surface of the lamina swells up into an elevation which is called the *limbus laminæ spiralis* ("denticulate lamina" of Todd and Bowman). The lamina spiralis terminates in a grooved extremity, the *sulcus spiralis*, which presents the form of the letter ⊂: the upper part of the letter, being formed by the overhanging extremity of the limbus, is named the *labium vestibulare;* the lower part, prolonged and tapering, is called the *labium tympanicum* (Fig. 550).

Fig. 550.

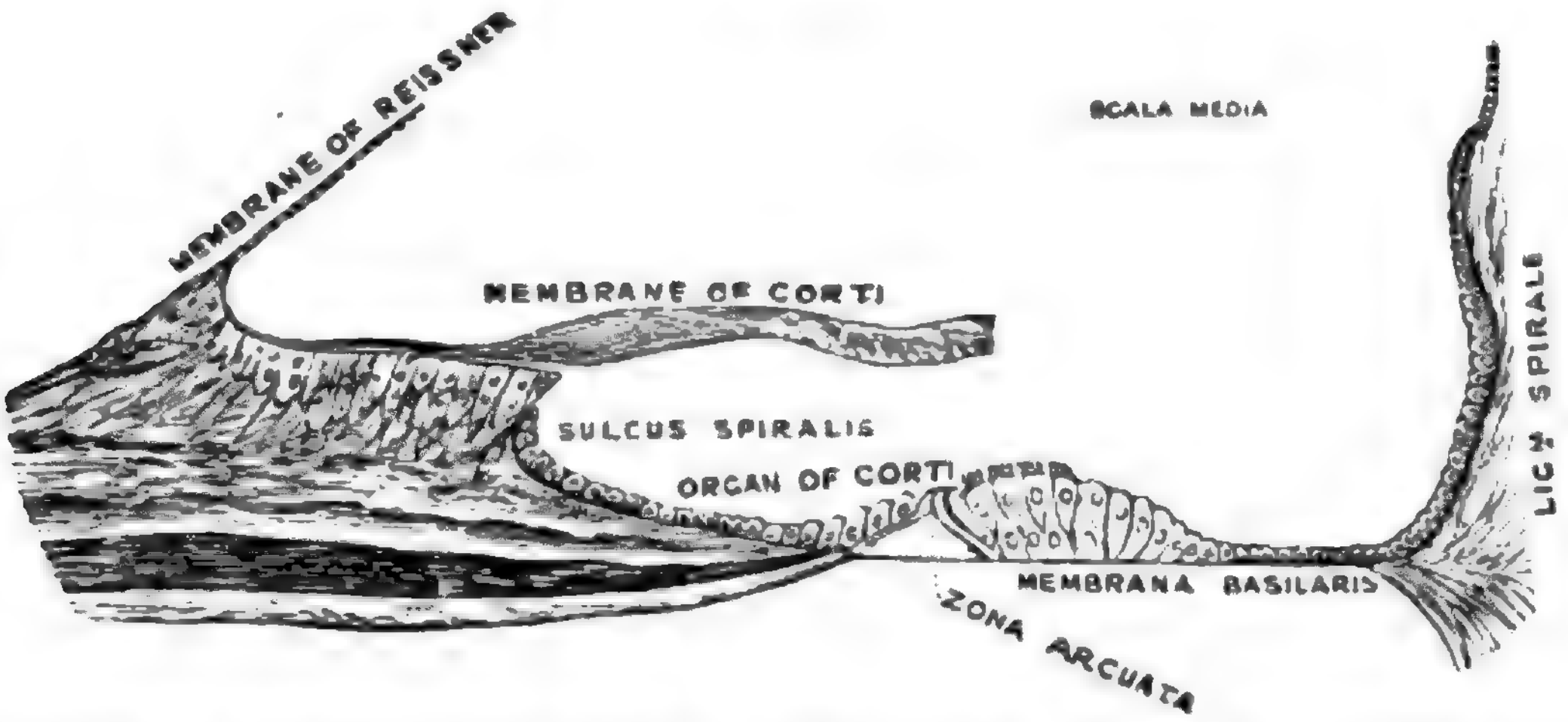

Floor of Scala Media, showing the Organ of Corti, etc. [Only part of the Membrane of Reissner is represented.]

From the labium tympanicum a thin membrane extends over to the bony wall of the cochlea, completing the scala tympani. This membrane is called the *membrana basilaris.* At its outer attachment it swells out so as to form a thick triangular structure which was regarded as a muscle by Todd and Bowman (cochlearis), but is now recognized as ligamentous—the *ligamentum spirale.* Between the labium vestibulare and the attachment of the membrane of Reissner, presently to be described, a very delicate membrane extends over to the outer wall of the cochlea, running nearly parallel to the membrana basilaris. It was described by Corti, and covers over the organ which is called after his name, and is therefore called *membrana tectoria*, or *membrane of Corti.* Farther inward, near the commencement of the limbus laminæ spiralis, another delicate membrane, the *membrane of Reissner*, is attached to the vestibular surface of the periosteum of the osseous lamina and stretches across to the outer wall of the cochlea. The canal which lies below the osseous lamina and membrana basilaris is the *scala tympani;* that which is bounded by the osseous lamina and membrane of Reissner, the *scala vestibuli;* while the space between the membrane of Reissner and membrana basilaris is generally described as the *scala media*, *canalis membranacea*, or *canalis cochleæ;* and this is the nomenclature which will be used here. Others, however, apply the name *canalis cochleæ* only to the canal lying between the membrane of Reissner and the "membrane of Corti," which contains no object for description, while the space lying between the "membrane of Corti" and the membrana basilaris is described by itself as a fourth canal—the ductus cochlearis or ductus auditorius.[1] The latter is the space in which the *organ of Corti*[2] is contained. This organ (Fig. 550) is situated upon the membrana basilaris, and appears at first sight as a papilla winding spirally with the turns of this membrane throughout the whole length of the cochlea, from which circumstance it has been designated the *papilla spiralis*. More accurately viewed, it is seen to be composed of a remarkable arrangement of cells which may be likened to the keyboard of a pianoforte. Of these cells, the two central ones are rod-like bodies, and are called the inner and outer *rods of Corti*. They are placed erect on the basilar membrane at some little distance from each other, the space between them being denominated the *zona arcuata;* they are inclined toward each other, so as to meet at their opposite extremities and form a series of arches roofing over the zona arcuata, thus forming a minute tunnel between them and the basilar membrane, which ascends spirally through the whole length of the cochlea. They are estimated at over three thousand in number.

---

[1] In reading the older descriptions of the organ of hearing the student must bear in mind that the membranes bounding the ductus auditorius, together with the organ contained between them, were described together as the "lamina spiralis membranacea," while the membrane of Reissner was not recognized, the parts being, in fact, as shown in the second turn of the cochlea on the right hand of Fig. 549.

[2] Corti's original paper is in the *Zeitschrift f. Wissen. Zool.*, iii. 109.

The inner rods, which are more numerous than the outer ones, rest on the basilar membrane close to the labium tympanicum; they project obliquely forward and outward, and terminate above in expanded extremities which resemble in shape the head of the human ulna with its sigmoid cavity, coronoid and olecranon processes. On the outer side of the rod, in the angle formed between it and the basilar membrane, is a protoplasmic cell, whilst on the inner side is a row of epithelial cells surmounted by a brush of fine, stiff, hair-like processes, these cells being continuous with the cubical cells lining the sulcus spiralis.

The outer rods also rest by a broad foot on the basilar membrane; they incline forward and inward, and their upper extremity resembles the head and bill of a swan, the head fitting into the concavity—the analogue of the sigmoid cavity—of one or more of the internal rods, and the bill resting against the phalanges of the lamina reticularis, presently to be described.

In the head of these outer rods is an oval portion where the fibres of which the rod appears to be composed are deficient, and which stains more deeply with carmine than the rest of the rod. This is supposed to represent the nucleus of the cell from which the rod was originally developed. At the base of the rod, on its internal side—that is to say, in the angle formed by the rod with the basilar membrane—is a similar protoplasmic cell to that found on the outer side of the base of the inner rod; whilst external to the outer rod are three or four successive rows of epithelial cells, more elongated than those found on the internal side of the inner rod, but like them furnished with minute hairs or cilia. These are termed the *outer hair-cells*, in contradistinction to the inner set, which are termed the *inner hair-cells*. They are attached by their bases to the basilar membrane, whilst from the opposite extremity a brush of hairs or cilia projects through the reticular membrane. They are continuous externally with the cubical cells on the lateral part of the basilar membrane.

The *reticular lamina* or *membrane* of Kölliker is a delicate framework perforated by rounded holes. It extends from the inner rods of Corti to the external row of the outer hair-cells, and is formed by several rows of "minute fiddle-shaped cuticular structures" called *phalanges*, between which are holes for the projection of the ciliæ of the outer hair-cells.

Covering over these structures, but not touching them, is the membrana tectoria, or membrane of Corti, which is attached to the vestibular surface of the lamina spiralis close to the attachment of the membrane of Reissner; it courses over the denticulate lamina, and, passing outward parallel to the basilar membrane, is blended with the ligamentum spirale on the outer wall of the spiral canal.[1]

The *inner surface* of the osseous labyrinth is lined by an exceedingly thin fibroserous membrane, analogous to the periosteum, from its close adhesion to the inner surfaces of these cavities, and performing the office of a serous membrane by its free surface. It lines the vestibule, and from this cavity is continued into the semicircular canals and the scala vestibuli of the cochlea, and through the helicotrema into the scala tympani. A delicate tubular process is prolonged along the aqueduct of the vestibule to the inner surface of the dura mater. This membrane is continued across the fenestra ovalis and rotunda, and consequently has no communication with the lining membrane of the tympanum. Its attached surface is rough and fibrous and closely adherent to the bone; its free surface is smooth and pale, covered with a layer of epithelium, and secretes a thin, limpid fluid, the *aqua labyrinthi, liquor Cotunnii*, or *perilymph* (Blainville).

---

[1] In Fig. 550 only the inner half of the membrane is represented.

The scala media is closed above and below. The upper blind extremity is attached to the cupola at the upper part of the helicotrema; the lower end fits into the angle at the commencement of the osseous lamina on the floor of the vestibule. Near this blind extremity the scala media receives the *canalis reuniens* (Fig. 551), a very delicate canal by which the ductus cochlearis is brought into continuity with the saccule.

THE MEMBRANOUS LABYRINTH.

FIG. 551.

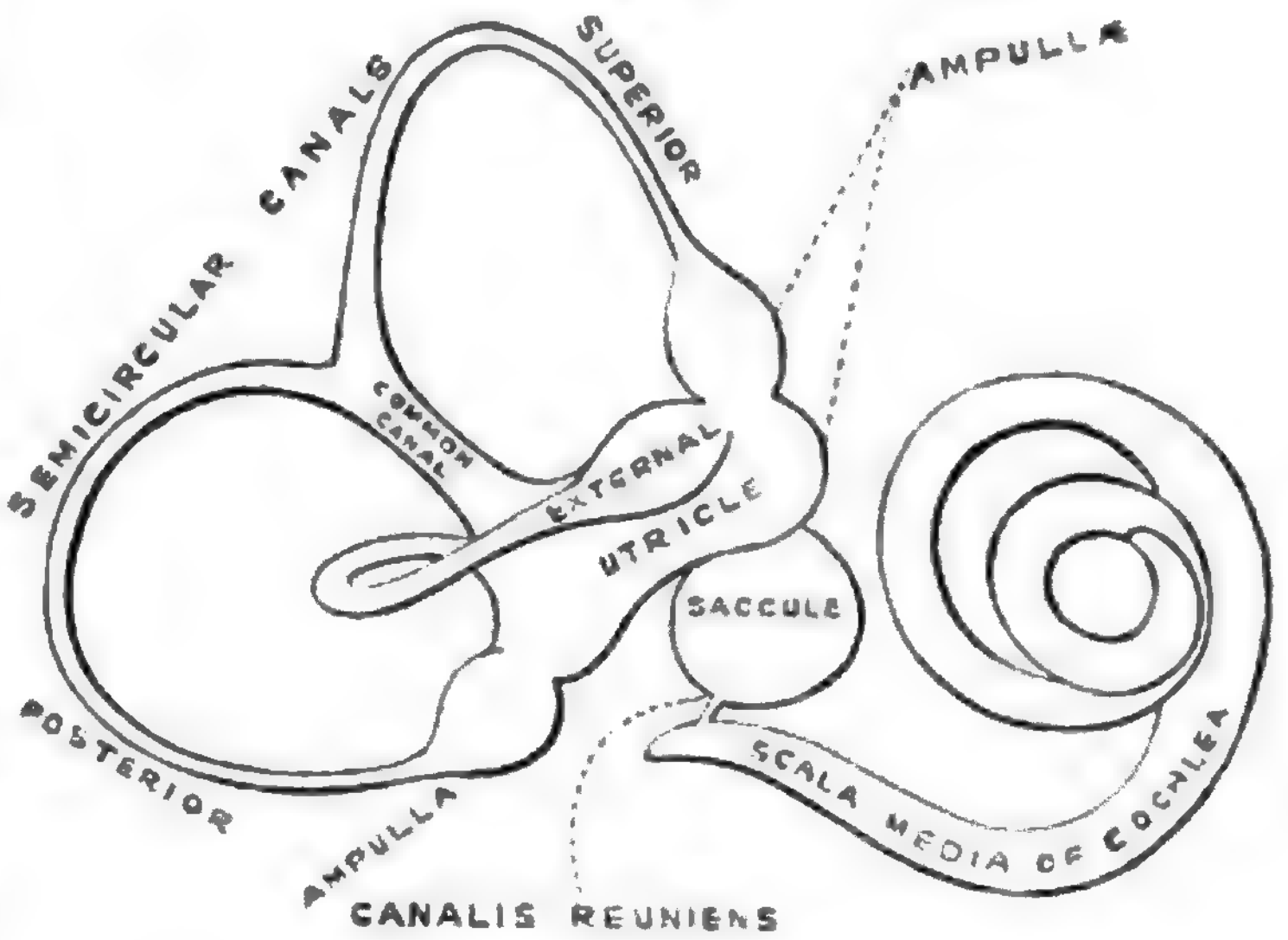

The Membranous Labyrinth (enlarged 4 diameters).

The membranous labyrinth (Fig. 551) is a closed membranous sac [belonging to the lymphatic system], containing fluid, on the walls of which the ramifications of the auditory nerve are distributed. It has the same general form as the vestibule and semicircular canals, in which it is enclosed, but is considerably smaller, and separated from their lining membrane by the perilymph.

The *vestibular portion* consists of two sacs, the utricle and the saccule.

The *utricle* [diminutive of *uter*, a bag or bottle] is the larger of the two, of an oblong form, compressed laterally, and occupies the upper and back part of the vestibule, lying in contact with the fovea semi-elliptica. Numerous filaments of the auditory nerve are distributed on the wall of this sac, and its cavity communicates behind with the membranous semicircular canals by five orifices.

The *saccule* is the smaller of the two vestibular sacs; it is globular in form, lies in the fovea hemispherica near the opening of the vestibular scala of the cochlea, and receives numerous nervous filaments which enter from the bottom of the depression in which it is contained. Its cavity is apparently distinct from that of the utricle.

The *membranous semicircular canals* are about one-third the diameter of the osseous canals, but in number, shape, and general form they are precisely similar; they are hollow, and open by five orifices into the utricle, one opening being common to two canals. Their ampullæ are thicker than the rest of the tubes, and nearly fill the cavities in which they are contained.

The membranous labyrinth is held in its position by numerous fibrous bands which stretch across the space between the membranous and bony labyrinths. These fibrous bands convey the blood-vessels and nervous filaments distributed to the utricle, to the saccule, and to the ampulla of each canal. The nerves enter the vestibule through the minute apertures on its inner wall.

Structure.—The wall of the membranous labyrinth is semi-transparent and consists of three layers. The *outer layer* is a loose and flocculent structure, apparently composed of ordinary fibrous tissue, containing blood-vessels and numerous pigment-cells analogous to those in the pigment-coat of the retina. The *middle layer*, thicker and more transparent, bears some resemblance to the hyaloid membrane, but it presents on its internal surface numerous papilliform projections, and in parts marks of longitudinal fibrillation and elongated nuclei on the addition of acetic acid.

The *inner layer* is formed of polygonal nucleated epithelial cells, which secrete the endolymph.

The *endolymph* (*liquor Scarpæ*) is a limpid serous fluid which fills the membranous labyrinth; in composition it closely resembles the perilymph.

The *otoliths* are two small rounded bodies, consisting of a mass of minute crystalline grains of carbonate of lime, held together in a mesh of delicate fibrous tissue, and contained in the wall of the utricle and saccule opposite the distribution of the nerves. A calcareous material is also, according to Bowman, sparingly scattered in the cells lining the ampulla of each semicircular canal.

The *arteries of the labyrinth* are the internal auditory, from the basilar; the stylo-mastoid, from the posterior auricular; and occasionally branches from the occipital. The internal auditory divides at the bottom of the internal meatus into two branches—cochlear and vestibular.

The cochlear branch subdivides into from twelve to fourteen twigs, which traverse the canals in the modiolus, and are distributed, in the form of a capillary network, in the substance of the lamina spiralis.

The vestibular branches accompany the nerves, and are distributed, in the form of a minute capillary network, in the substance of the membranous labyrinth.

The *veins* (auditory) of the vestibule and semicircular canals accompany the arteries, and, receiving those of the cochlea at the base of the modiolus, terminate in the superior petrosal sinus.

The *auditory nerve*, the special nerve of the sense of hearing, divides at the bottom of the internal auditory meatus into two branches—the cochlear and vestibular. The trunk of the nerve, as well as the branches, contains numerous ganglion-cells with caudate prolongations.

The *vestibular nerve*, the posterior of the two, divides into three branches—superior, middle, and inferior.

The superior vestibular branch, the largest, divides into numerous filaments, which pass through minute openings at the upper and back part of the cul-de-sac at the bottom of the meatus, and, entering the vestibule, are distributed to the utricle and to the ampulla of the external and superior semicircular canals.

The middle vestibular branch consists of numerous filaments, which enter the vestibule by a smaller cluster of foramina placed below those above mentioned, and which correspond to the bottom of the fovea hemispherica; they are distributed to the saccule.

The inferior and smallest branch passes backward in a canal behind the foramina for the nerves of the saccule, and is distributed to the ampulla of the posterior semicircular canal.

The nervous filaments enter the ampullary enlargements at a deep depression seen on their external surface, with a corresponding elevation when seen from within, the nerve-fibres ending in loops and in free extremities. In the utricle and saccule the nerve-fibres spread out, some blending with the calcareous matter, others radiating on the inner surface of the wall of each cavity, becoming blended with a layer of nucleated cells and terminating in a thin fibrous film.

The *cochlear nerve* divides into numerous filaments at the base of the modiolus, which ascend along its canals, and then, bending outward at right angles, pass between the plates of the bony lamina spiralis close to its tympanic surface. Between the plates of the spiral lamina the nerves form a plexus which contains ganglion-cells forming the ganglion spirale. From this ganglion delicate filaments pass between the layers of the osseous lamina to the sulcus spirale, and pass outward to the organ of Corti. Their exact termination is uncertain. Waldeyer describes them as collected into two groups, one group ending in the outer and the other in the inner hair-cells.

Organs of Digestion.

THE apparatus for the digestion of the food consists of the alimentary canal and of certain accessory organs.

The **Alimentary Canal** is a musculo-membranous tube about thirty feet in length, extending from the mouth to the anus and lined throughout its entire extent by mucous membrane. It has received different names in the various parts of its course. At its commencement, the mouth, we find provision made for the mechanical division of the food (*mastication*), and for its admixture with a fluid secreted by the salivary glands (*insalivation*); beyond this are the organs of deglutition, the pharynx and the œsophagus, which convey the food into that part of the alimentary canal (the stomach) in which the principal chemical changes occur and in which the reduction and solution of the food take place; in the small intestines the nutritive principles of the food (the *chyle*) are separated, by its admixture with the bile and pancreatic fluid, from that portion which passes into the large intestine, most of which is expelled from the system.

Alimentary Canal.

		Duodenum.
Mouth.	Small intestine . . .	Jejunum.
Pharynx.		Ileum.
Œsophagus.		Cæcum.
Stomach.	Large intestine . . .	Colon.
		Rectum.

Accessory Organs.

Teeth.		
	Parotid.	Liver.
Salivary glands	Submaxillary.	Pancreas.
	Sublingual.	Spleen.

The **Mouth** (*oral* or *buccal cavity*) (Fig. 552) is placed at the commencement of the alimentary canal; it is a nearly oval-shaped cavity in which the mastication of the food takes place. It is bounded in front by the lips; laterally by the cheeks and the alveolar processes of the upper and lower jaws; above by the hard palate and teeth of the upper jaw; below by the tongue and by the mucous membrane stretched between the under surface of that organ and the inner surface of the jaws, and by the teeth of the lower jaw; behind by the soft palate and fauces.

The *mucous membrane* lining the mouth is continuous with the integument at the free margin of the lips, and with the mucous lining of the fauces behind; it is of a rose-pink tinge during life, and very thick where it covers the hard parts bounding the cavity. It is covered by scaly stratified epithelium.

The **Lips** are two fleshy folds which surround the orifice of the mouth, formed externally of integument and internally of mucous membrane, between which are found the Orbicularis oris muscle, the coronary vessels, some nerves, areolar tissue and fat, and numerous small labial glands. The inner surface of each lip is connected in the middle line to the gum of the corresponding jaw by a fold of mucous membrane, the *frænum labii superioris* and *inferioris*, the former being the larger of the two [and can be well appreciated by pressing the tip of the tongue between the upper lip and the teeth].

The *labial glands* are situated between the mucous membrane and the Orbicularis oris, around the orifice of the mouth. They are rounded in form, about the size of small peas, their ducts opening by small orifices upon the mucous membrane. In structure they resemble the other salivary glands.

FIG. 552.

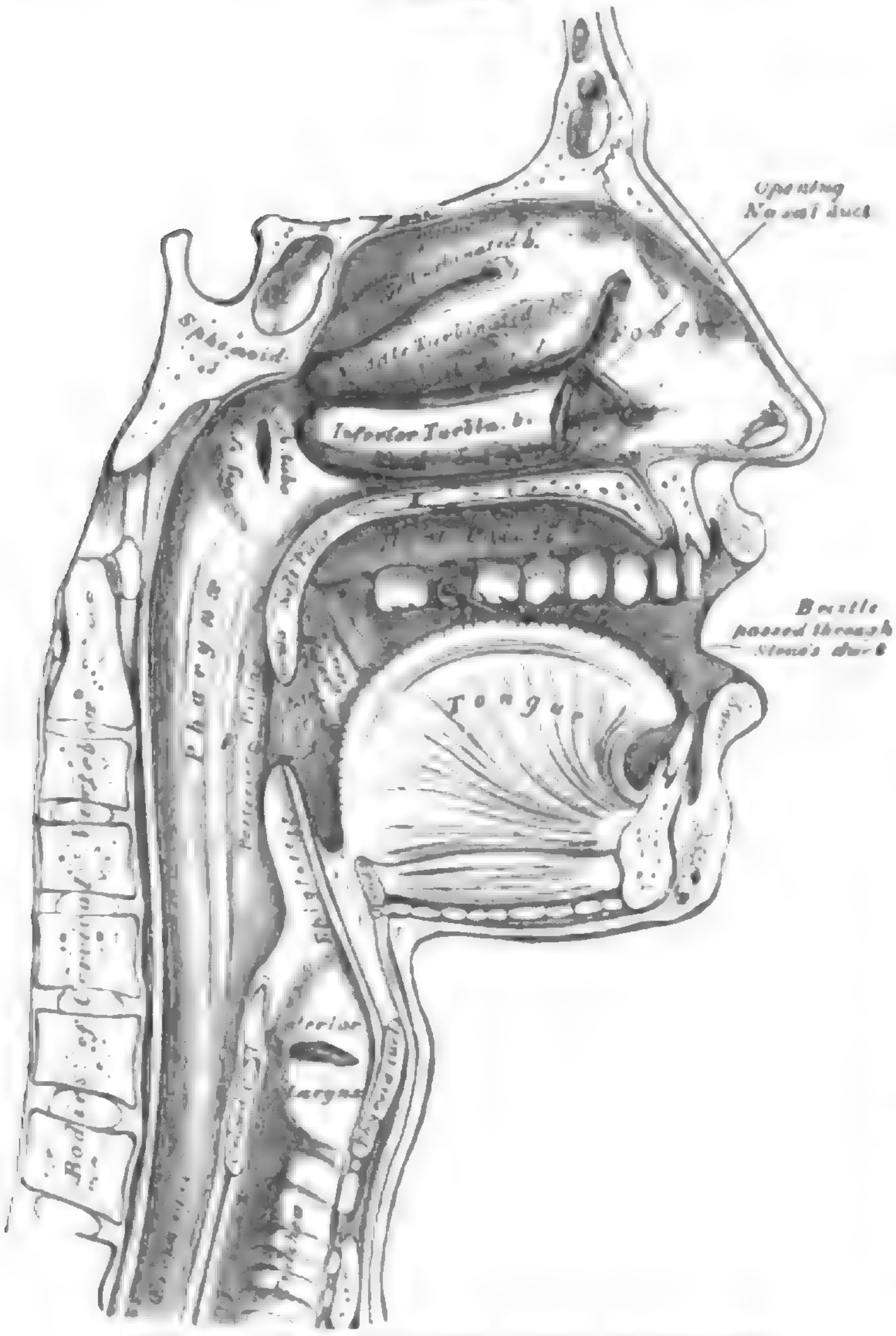

Sectional View of the Nose, Mouth, Pharynx, etc.

The **Cheeks** form the sides of the face and are continuous in front with the lips. They are composed externally of integument, internally of mucous membrane, and between the two of a muscular stratum, besides a large quantity of fat, areolar tissue, vessels, nerves, and buccal glands.

The *mucous membrane* lining the cheek is reflected above and below upon the gums, and is continuous behind with the lining membrane of the soft palate. Opposite the second molar tooth of the upper jaw is a papilla, the summit of which presents the aperture of the duct of the parotid gland. The principal muscle of the cheek is the Buccinator; but numerous other muscles enter into its formation—viz. the Zygomatici, Masseter, and Platysma myoides.

The *buccal glands* are placed between the mucous membrane and Buccinator muscle: they are similar in structure to the labial glands, but smaller. Two or three of larger size than the rest are placed between the Masseter and Buccinator muscles; their ducts open into the mouth opposite the last molar tooth. They are called *molar glands.*

The **Gums** are composed of a dense fibrous tissue closely connected to the periosteum of the alveolar processes, and surrounding the necks of the teeth. They are covered by smooth and vascular mucous membrane, which is remarkable for its limited sensibility. Around the necks of the teeth this membrane presents numerous fine papillæ, and from this point it is reflected into the alveolus, where it is continuous with the periosteal membrane lining that cavity.

THE TEETH.

The human subject is provided with two sets of teeth, which make their appearance at different periods of life. The first set appear in childhood, and are called the *temporary*, *deciduous*, or *milk teeth*. The second set, which also appear at an early period, continue until old age, and are named *permanent.*

The *temporary teeth* are twenty in number—four incisors, two canine, and four molars in each jaw.

The *permanent teeth* are thirty-two in number—four incisors (two central and two lateral), two canine, four bicuspids, and six molars in each jaw.

General Characters.—Each tooth consists of three portions: the *crown*, or *body*, projecting above the gum; the *root*, or *fang*, entirely concealed within the alveolus; and the *neck*, the constricted portion, between the other two.

The *roots of the teeth* are firmly implanted within the alveoli; these depressions are lined with periosteum, which is reflected on to the tooth at the point of the fang, and covers it as far as the neck. At the margin of the alveolus the periosteum becomes continuous with the fibrous structure of the gums.

PERMANENT TEETH.

The **Incisors**, or cutting teeth, are so named from their presenting a sharp cutting edge adapted for cutting the food. They are eight in number, and form the four front teeth in each jaw.

The *crown* is directed vertically, and is wedge-like in form, being bevelled at the expense of its posterior surface, so as to terminate in a sharp horizontal cutting edge, which before being subject to attrition presents three small prominent points. It is convex, smooth, and highly polished in front; slightly concave behind, where it is frequently marked by slight longitudinal furrows.

The *neck* is constricted.

The *fang* is long, single, conical, transversely flattened, thicker before than behind, and slightly grooved on each side in the longitudinal direction.

The *incisors of the upper jaw* are altogether larger and stronger than those of the lower jaw. They are directed obliquely downward and forward. The two central ones are larger than the two lateral, and their free edges are sharp and chisel-like, being bevelled at the expense of their posterior edge: the root is more rounded.

The *incisors of the lower jaw* are smaller than the upper: the two central ones are smaller than the two lateral, and are the smallest of all the incisor teeth.

The **Canine Teeth** (*cuspidati*) are four in number, two in the upper and two in the lower jaw, one being placed behind each lateral incisor. They are larger and stronger than the incisors, especially the root, which sinks deeply into the jaw and causes a well-marked prominence upon its surface.

The *crown* is large and conical, very convex in front, a little hollowed and uneven posteriorly, and tapering to a blunted point or cusp which rises above the level of the other teeth.

The *root* is single, but longer and thicker than that of the incisors, conical in form, compressed laterally, and marked by a slight groove on each side.

The *upper canine teeth* (vulgarly called eye-teeth) are larger and longer than the two lower, and situated a little behind them.

The *lower canine teeth* are placed in front of the upper, so that their summits correspond to the interval between the upper canine tooth and the neighboring incisors on each side.

The **Bicuspid Teeth** (premolars, small or false molars) are eight in number—four in each jaw, two being placed immediately behind each of the canine teeth. They are smaller and shorter than the canine.

The *crown* is compressed from without inward and surmounted by two pyramidal eminences or cusps separated by a groove; hence their name, *bicuspidati*. The outer of these cusps is larger and more prominent than the inner.

The *neck* is oval.

The *root* is generally single, compressed, and presents a deep groove on each side, which indicates a tendency in the root to become double. The apex is generally bifid.

The *upper bicuspids* are larger, and present a greater tendency to the division of their roots, than the lower; this is especially marked in the second upper bicuspid.

The **Molar Teeth** (*multicuspidati*, true or enlarged molars) are the largest of the permanent set, and are adapted, from the great breadth of their crowns, for grinding and pounding the food. They are twelve in number—six in each jaw, three being placed behind each of the posterior bicuspids.

The *crown* is nearly cubical in form, rounded on each of its lateral surfaces, flattened in front and behind, the upper surface being surmounted by four or five tubercles or cusps (four in the upper, five in the lower molars) separated from each other by a crucial depression; hence their name, *multicuspidati.*

Fig. 553.

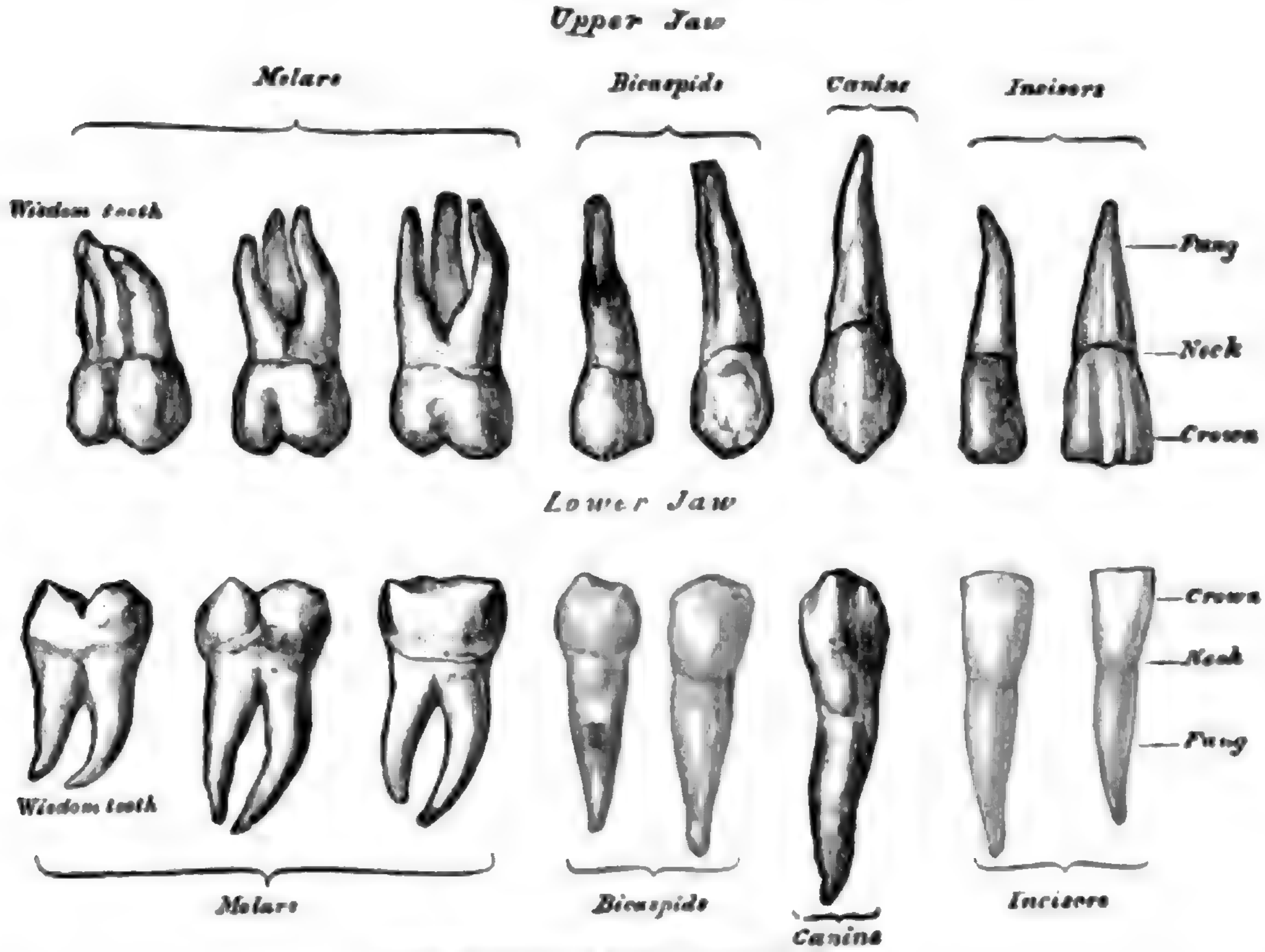
Upper Jaw
Molars
Bicuspids
Canine
Incisors
Wisdom tooth
Fang
Neck
Crown
Lower Jaw
Crown
Neck
Fang
Wisdom tooth
Molars
Bicuspids
Canine
Incisors

The Permanent Teeth, external view.

The *neck* is distinct, large, and rounded.

The *root* is subdivided into from two to five fangs, each of which presents an aperture at its summit.

The *first molar tooth* is the largest and broadest of all; its crown has usually five cusps, three outer and two inner. In the upper jaw the root consists of three fangs, widely separated from each other, two being external, the other internal.

[Fig. 554.

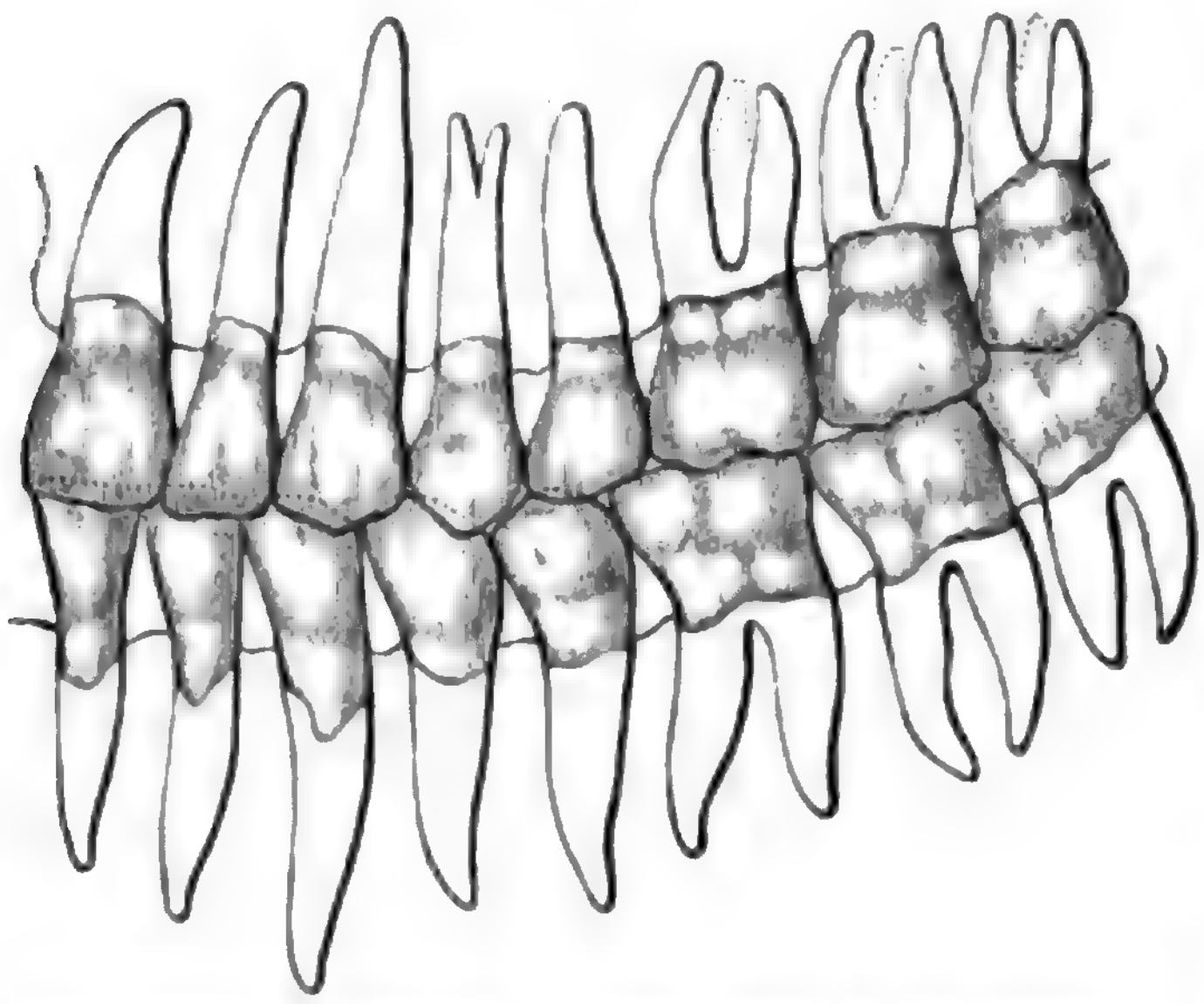

Showing the "occlusion" or apposition of the permanent teeth (Litch).]

The latter is the largest and longest, slightly grooved, and sometimes bifid. In the lower jaw the root consists of two fangs, one being placed in front, the other behind: they are both compressed from before backward, and grooved on their contiguous faces, indicating a tendency to division.

The *second molar* is a little smaller than the first.

The crown has four cusps in the upper and five in the lower jaw.

The root has three fangs in the upper jaw and two in the lower, the characters of which are similar to the preceding tooth.

The *third molar tooth* is called the *wisdom tooth* (*dens sapientiæ*), from its late appearance through the gum. It is smaller than the others, and its axis is directed inward.

The crown is small and rounded and furnished with three tubercles.

The root is generally single, short, conical, slightly curved, and grooved so as to present traces of a subdivision into three fangs in the upper and two in the lower jaw.

[Fig. 554 well shows the "occlusion" or apposition of the teeth. It will be noticed that the upper teeth overlap the lower ones in front, while the surfaces of the molar teeth are in contact. No tooth is exactly apposed to its fellow in the other jaw, but each one has a bearing on two opposite teeth, except in the case of the wisdom teeth (third molars). This contributes to efficient mastication, and when one tooth is lost its fellow of the opposite jaw still partially retains its usefulness.]

TEMPORARY TEETH.

The **Temporary,** or **Milk Teeth,** are smaller, but resemble in form those of the permanent set. The hinder of the two temporary molars is the largest of all the milk teeth, and is succeeded by the second permanent bicuspid. The first upper molar has only three cusps—two external, one internal; the second upper molar has four cusps. The first lower molar has four cusps; the second lower molar has five. The fangs of the temporary molar teeth are smaller and more diverging than those of the permanent set, but in other respects bear a strong resemblance to them.

FIG. 555.

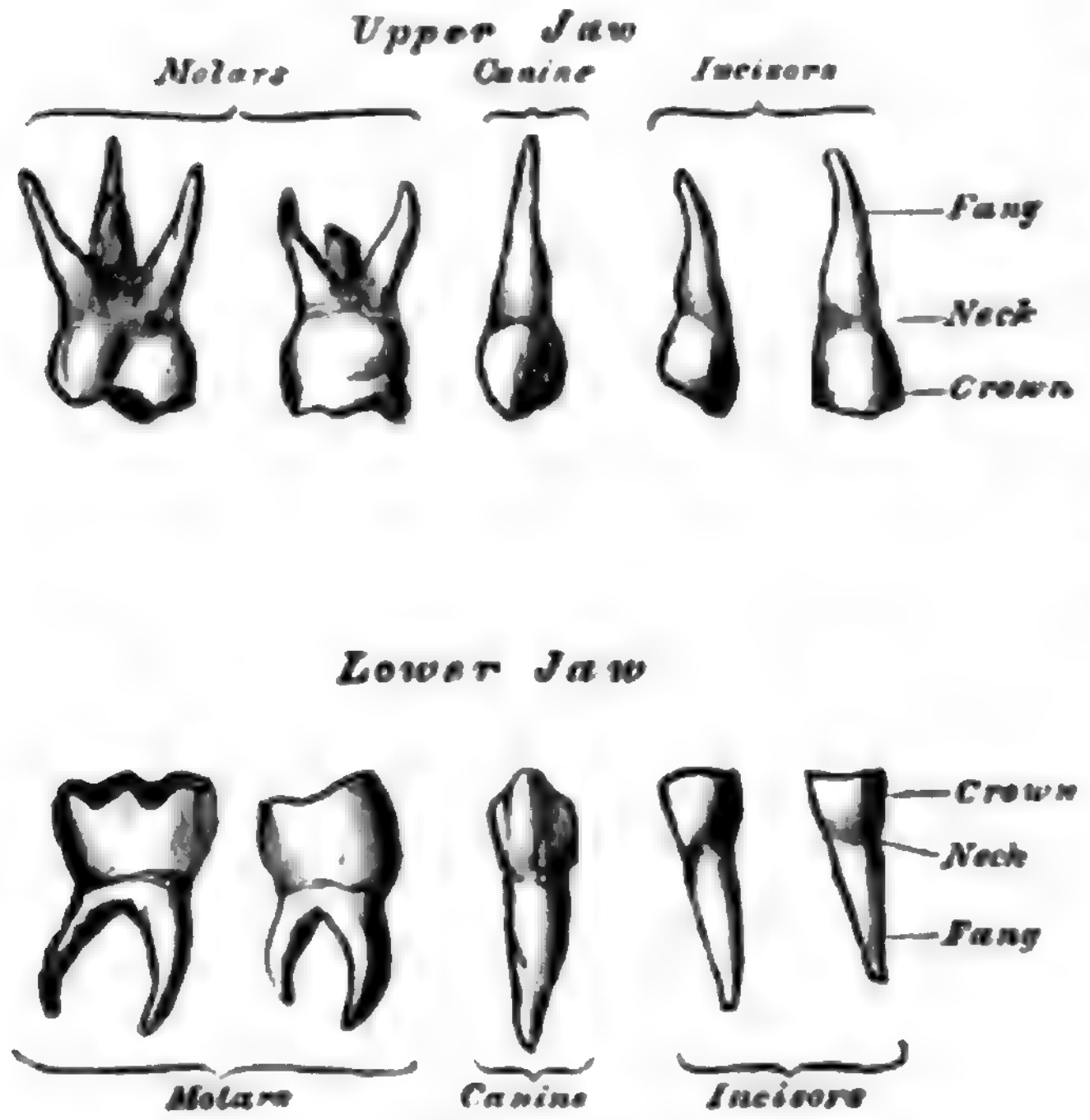

The Temporary, or Milk Teeth, external view.

FIG. 556.

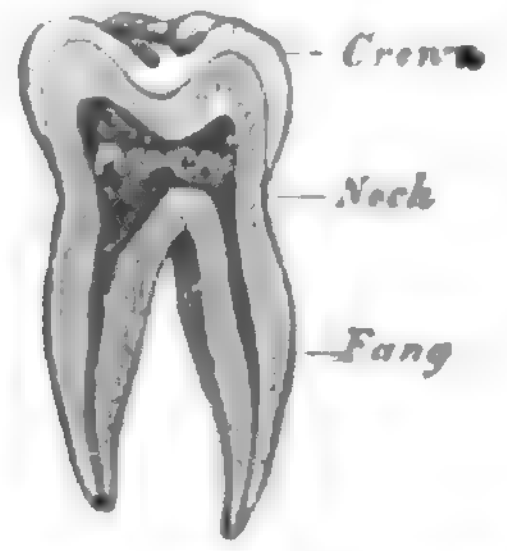

Vertical Section of a Molar Tooth.

Structure.—On making a vertical section of a tooth (Fig. 556) a hollow cavity will be found in the interior. This cavity is situated at the base of the crown, and is continuous with a canal which traverses the centre of each fang and opens by a minute orifice at its extremity. The shape of the cavity corresponds somewhat with that of the tooth; it forms what is called the *pulp-cavity*, and contains a soft, highly vascular, and sensitive substance, the *dental pulp*. The pulp consists of a loose connective tissue and cells; it is richly supplied with vessels and nerves, which enter the cavity through the small aperture at the point of each fang. The cells of the pulp are partly found permeating the connective tissue, and partly arranged as a layer on the wall of the pulp-cavity. These latter cells are of two kinds: some, columnar in shape, are named the *odontoblasts of Waldeyer*, and will be referred to hereafter; others, fusiform in shape, are wedged in between the columnar cells, and have two fine processes, the outer or distal one passing into a dentine tubule, the inner being continuous with the processes of the connective-tissue cells of the pulp-matrix. According to some anatomists the processes of the odontoblasts are also continued into the dentine tubuli.

The solid portion of the tooth consists of three distinct structures—viz. the proper dental substance, which forms the larger portion of the tooth, the *ivory*, or *dentine;* a layer which covers the exposed part of the crown, the *enamel;* and a thin layer, which is disposed on the surface of the fang, the *cement*, or *crusta petrosa*.

The **Ivory**, or **Dentine** (Fig. 557), forms the principal mass of a tooth; in its central part is the cavity enclosing the pulp. It is a modification of osseous tissue, from which it differs, however, in structure and chemical composition. On examination with the microscope it is seen to consist of a number of minute wavy and branching tubes having distinct parietes. They are called the *dental tubuli*, and are imbedded in a dense homogeneous substance, the *intertubular tissue*.

The *dental tubuli* are placed parallel with one another, and open at their inner ends into the pulp-cavity. In their course to the periphery they present two or three curves, and are twisted on themselves in a spiral direction. The direction of these tubes varies; they are vertical in the upper portion of the crown, oblique in the neck and upper part of the root, and toward the lower part of the root they are inclined downward. The tubuli, at their commencement, are about $\frac{1}{4500}$ of an inch in diameter; in their course they divide and subdivide dichotomously, so as to give to the cut surface of the dentine a striated appearance. From the sides of the tubes, especially in the fang, ramifications of extreme minuteness are given off, which join together in loops in the intertubular substance or terminate in small dilatations from which branches are given off. Near the periphery of the dentine the finer ramifications of the tubuli terminate in a layer of irregular branched spaces which communicate with each other. These are called the *interglobular spaces* of Czermak or the *granular layer* of Purkinje (Fig. 558). The dental tubuli have comparatively thick walls, and contain slender cylindrical prolongations from the cells of the pulp-tissue, first described by Mr. Tomes, and named Tomes's fibres or dentinal fibres. These

FIG. 557.

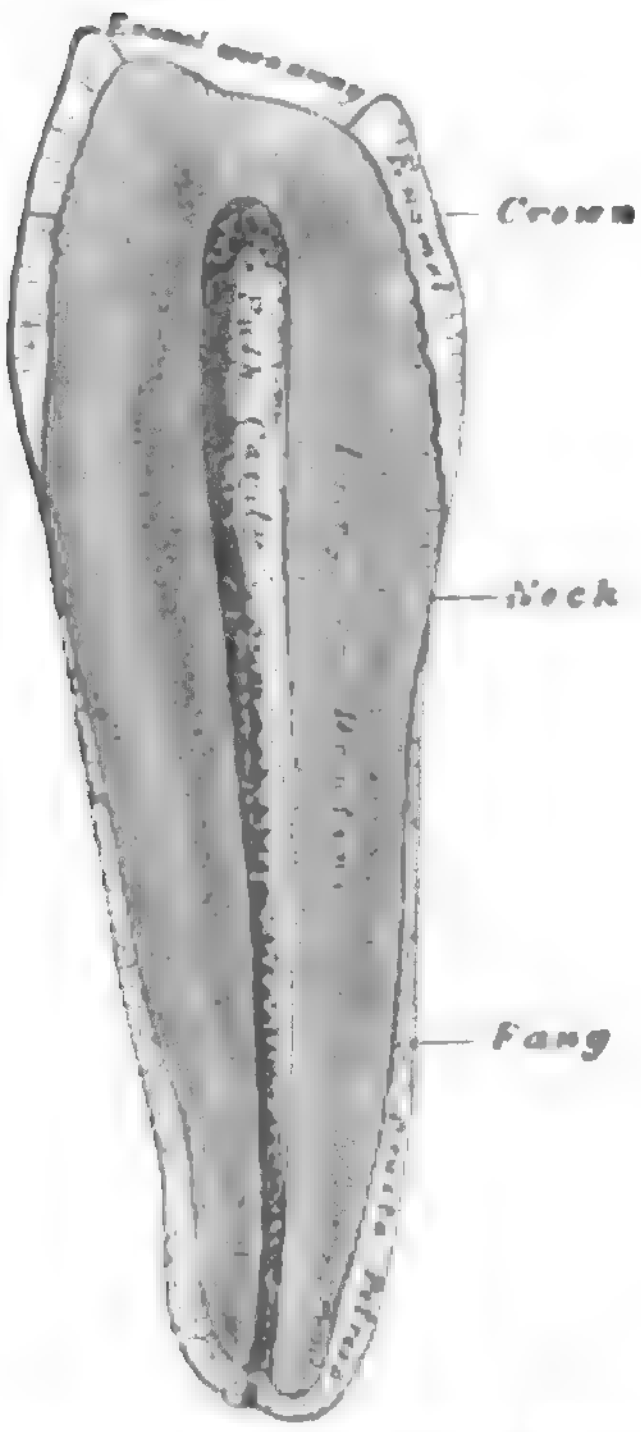

Vertical Section of a Bicuspid Tooth (magnified).

FIG. 558.

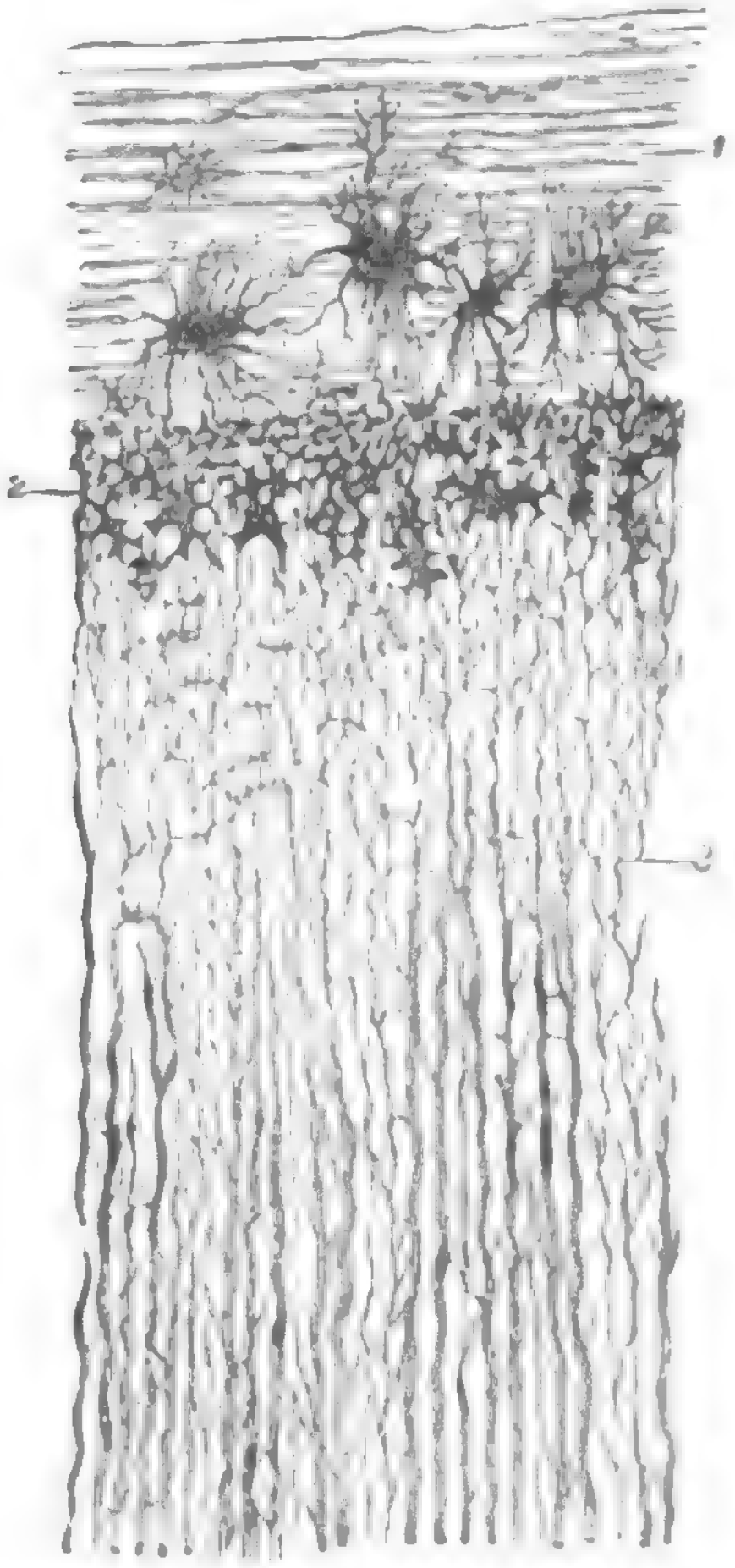

Canine Tooth of Man, presenting a transverse section of a portion of the root: 1, cement with large lacunæ and parallel striæ; 2, interglobular spaces; 3, dental tubules (magnified 300 diams.).

dentinal fibres are analogous to the soft contents of the canaliculi of bone. Between Tomes's fibres and the ivory of the canals there is an elastic homogeneous membrane which resists the action of acids—the *dentinal sheath* of Neumann.

The *intertubular substance* is translucent, finely granular, and contains the chief part of the earthy matter of the dentine. After the earthy matter has been removed by steeping a tooth in weak acid, the animal basis remaining may be torn into laminæ which run parallel with the pulp-cavity across the direction of the tubes. A section of dentine often displays a series of somewhat parallel lines—the *incremental lines* of Salter. These lines are composed of a number of masses of imperfectly calcified dentine arranged in layers. In consequence of the imperfection in the calcifying process little irregular cavities are left, termed *interglobular spaces*, similar to those in the granular layer, but larger, and have received their name from the fact that they are surrounded by minute nodules or globules of dentine.

Other curved lines may be seen parallel to the surface. These are the *lines of Schreger*, and are due to the optical effect of simultaneous curvature of the dentinal fibres.

Chemical Composition.—According to Berzelius and Bibra, dentine consists of 28 parts of animal and 72 of earthy matter. The animal matter is resolvable by boiling into gelatin. The earthy matter consists of phosphate of lime, carbonate of lime, a trace of fluoride of calcium, phosphate of magnesia, and other salts.

The **Enamel** is the hardest and most compact part of a tooth, and forms a thin crust over the exposed part of the crown as far as the commencement of the fang. It is thickest on the grinding surface of the crown until worn away by attrition, and becomes thinner toward the neck. It consists of a congeries of minute hexagonal rods. They lie parallel with one another, resting by one extremity upon the dentine, which presents a number of minute depressions for their reception, and forming the free surface of the crown by the other extremity. These fibres are directed vertically on the summit of the crown, horizontally at the sides; they are about the $\frac{1}{5500}$ of an inch in diameter, and pursue a more or less wavy course. The enamel is marked by a series of undulating lines, which cross each other or "decussate;" these lines are doubtless formed by the variation in the course of the enamel-rods. Another series of lines, colored brown, probably from the presence of pigment, and denominated the *parallel striæ* of Retzius, are seen on a section of the enamel. Their exact significance is uncertain.

Numerous minute interstices intervene between the enamel-fibres near their dentinal surface—a provision calculated to allow of the permeation of fluids from the dentinal tubule into the substance of the enamel. The enamel-rods consist of solid hexagonal or four-sided prisms connected by their surfaces and ends and filled with calcareous matter. If the latter be removed by weak acid from newly-formed or growing enamel, it will be found to present a network of delicate prismatic cells of animal matter. It is a disputed point whether the dentinal fibres penetrate a certain distance between the rods of the enamel or no. No nutritive canals exist in the enamel.

CHEMICAL COMPOSITION.—According to Bibra, enamel consists of 96.5 per cent. of earthy matter and 3.5 per cent. of animal matter. The earthy matter consists of phosphate of lime, with traces of fluoride of calcium, carbonate of lime, phosphate of magnesia, and other salts.

The **cortical substance**, or cement (*crusta petrosa*), is disposed as a thin layer on the roots of the teeth from the termination of the enamel as far as the apex of the fang, where it is usually very thick. In structure and chemical composition it resembles bone. It contains, sparingly, the lacunæ and canaliculi which characterize true bone; the lacunæ placed near the surface have the canaliculi radiating from the side of the lacunæ toward the periodontal membrane, and those more deeply placed join with the adjacent dental tubuli. In the thicker portions of the crusta petrosa the lamellæ and Haversian canals peculiar to bone are also found. As age advances the cement increases in thickness, and gives rise to those bony growths, or exostoses, so common in the teeth of the aged; the pulp-cavity becomes also partially filled up by a hard substance intermediate in structure between dentine and bone (*osteo-dentine*, Owen; *secondary dentine*, Tomes). It appears to be formed by a slow conversion of the dental pulp, which shrinks, or even disappears.

DEVELOPMENT OF THE TEETH.

In describing the development of the teeth we have first to consider the mode of formation of the temporary or milk teeth, and then that of the permanent series.

Development of the Temporary Teeth.—The development of these teeth in the fœtus begins at a very early period. About the seventh week the margin of the jaw presents a slight longitudinal depression or groove with rounded borders. This is termed the *primitive dental groove* of Goodsir, and is caused by an involution of the epithelium of the oral cavity into the subjacent connective tissue. The projecting borders of the groove are called the *dental ridges*. The groove consists, therefore, superficially, of a collection of epithelial cells, beneath which is a gelatinous connective tissue, which is taken to represent the corium and connective tissue of the mucous membrane, and deeper than this is the ossifying substance of the jaw. The essential structures of the teeth are derived from these two elements—the enamel from the epithelium which covers the surface of the dental groove, the dentine and crusta petrosa from the deeper structures.

First, as to the enamel. The primitive dental groove increases in size and becomes filled up and covered in by the epithelium, which becomes greatly increased in quantity, so that the groove is only indicated by a shallow superficial furrow. As the dental ridges—that is to say, the sides of the groove—rise up, the epithelial mass, which is named the *enamel-germ*, seems to pass deeper and deeper into the substance of the jaw, and at lasts meets with the papilla, presently to be described. The lower part of this mass of epithelial cells—that is, the part farthest from the margin of the jaw—spreads out in all directions, and the epithelial cells here increase in number. The mass thus assumes a flask shape, which is connected by a narrow neck, formed by the dental ridges, with the epithelial lining of the mouth. It may now be compared to a tubular gland, consisting of a dilated extremity filled with epithelium and opening by a narrow duct, also filled with epithelium, on the margin of the jaw. This narrow, constricted portion is called the *neck of the enamel-organ*, and is of importance as being the part from which the enamel-organ of the future permanent tooth is derived. The lower expanded portion of the mass of epithelial cells, the body of the flask, now inclines outward, so as to form an angle with the neck or more superficial part.

In the soft connective tissue beneath this mass of epithelial cells a small papilla arises by an increased development and growth of the corpuscles of the part. The first appearance of this is the formation, just below the enamel-germ, of a dark semilunar area, which appears to embrace the bottom of the dental groove. From the centre of the concavity of this a ridge—subsequently differentiated into papillæ—corresponding to the different teeth springs up. It grows upward, becomes vascular, and comes in contact with the epithelial cells of the enamel-germ, and is received into a dimple on its under surface. By its continued growth it pushes its way up into the enamel-germ, which becomes folded over it like a hood or cap. We have, then, at this stage, a vascular papilla which has already begun to assume somewhat the shape of the crown of the future tooth, surmounted by a sort of dome or cap of epithelial cells, which were originally the cells contained in the lower or expanded part of the flask-shaped primitive dental groove (Fig. 559). These cells now undergo a differentiation into three classes or varieties. Those which are in contact with the papilla, and which are continuous through the neck of the enamel-germ with the deepest layer of cells of the oral epithelium, become elongated, and form a layer of well-marked and regular columnar epithelium coating the papilla. These are named the *internal enamel epithelium*. The outer layer of cells of the enamel-germ, which are in contact with the inner surface of the dentinal sac, presently to be described, are much shorter, cubical in form, and are named the *external enamel epithelium*. All the intermediate round cells of the enamel-germ between these two layers undergo a peculiar change. They become stellate in shape, and their processes unite to form a network which resembles gelatinous connective tissue.

While these changes have been going on the two horns of the semilunar mass, before spoken of as embracing the enamel-germ, and from which the papilla was derived, extend upward, surrounding the rudimentary tooth and becoming converted into a vascular membrane, constituting a sac—the *dentinal sac*—which encloses the tooth. As they grow upward the two horns approach each other, and, penetrating the dental ridges or lips of the primitive groove, they cause the neck of the enamel-organ to atrophy and disappear, so that all communication between the enamel-germ and the superficial epithelium is cut off.

FIG. 559.

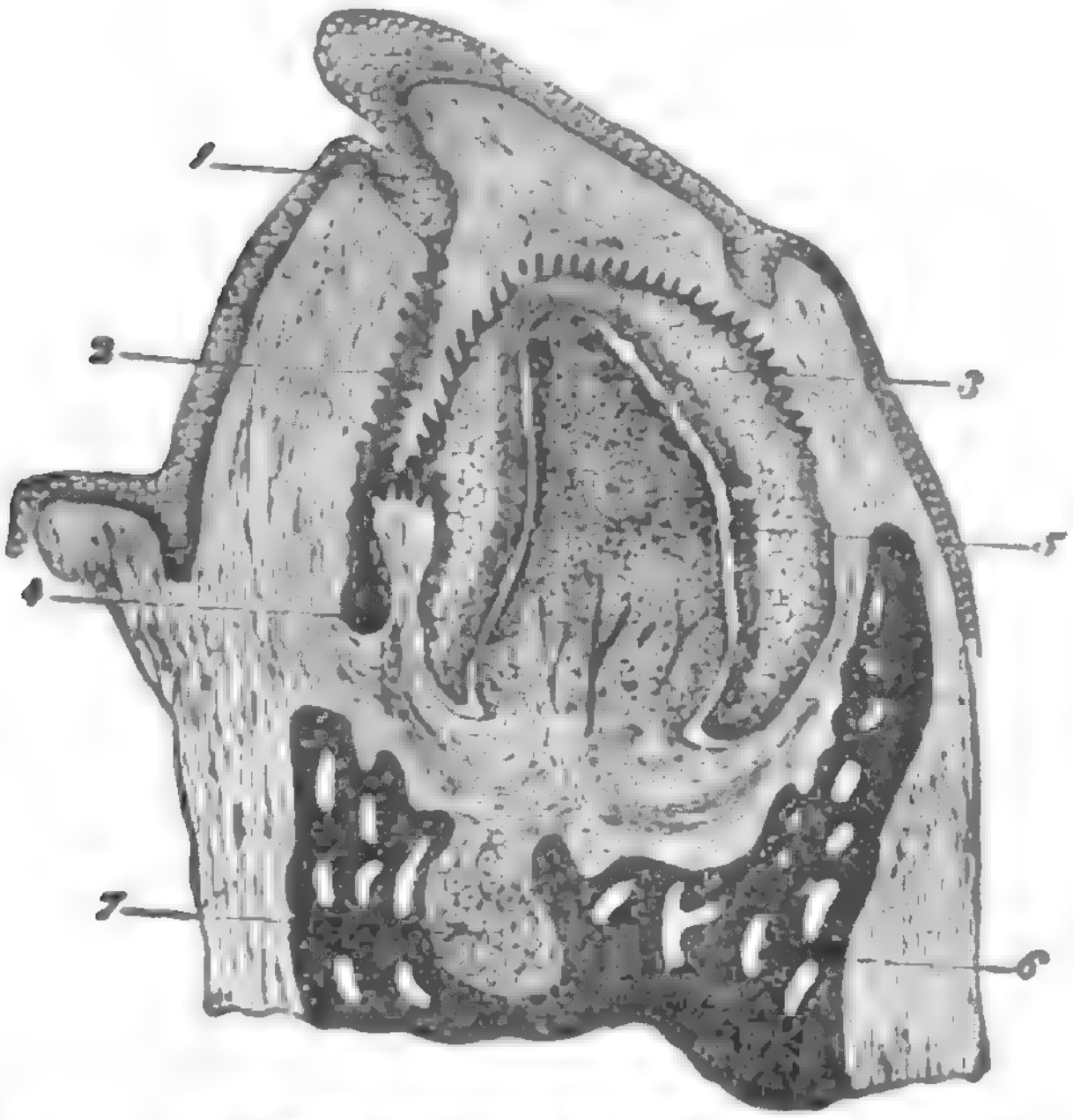

Vertical Section of the Inferior Maxilla of an Early Human Fœtus (magnified 25 diams.): 1, dental groove; 2, remains of the enamel-germ; 3, enamel-organ presenting externally epithelium, as also where it forms the enamel-germ of the papillæ of the dental sacculus; 4, secondary enamel-germ—rudiment of the permanent tooth; 5, dental germ; 6, lower jaw; 7, Meckel's cartilage.

FIG. 560.

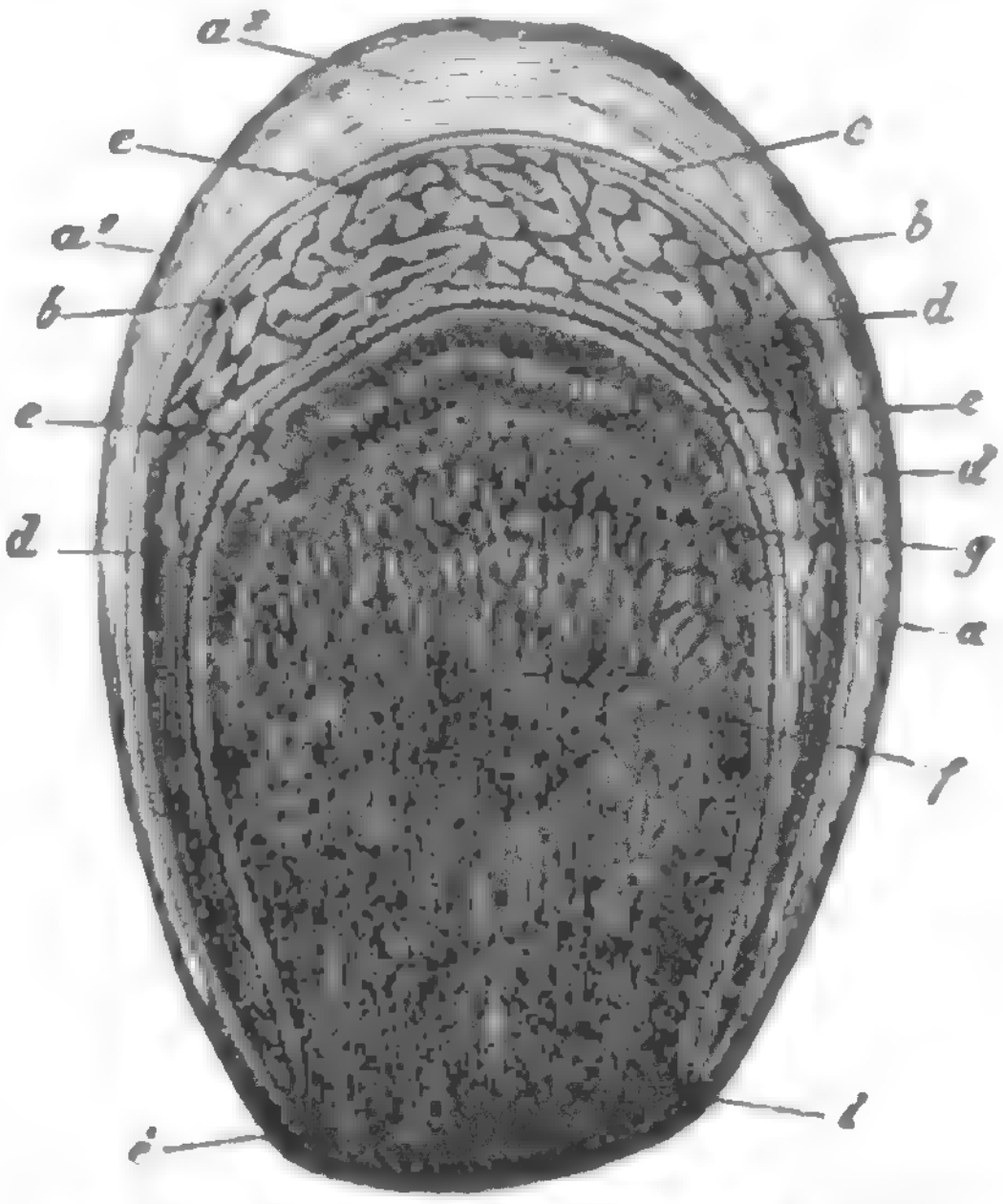

Dental Sac of a Human Embryo at an Advanced Stage of Development, partly diagrammatic: *a*, wall of the sac, formed of connective tissue, with its outer stratum, a^1, and its inner, a^2: *b*, enamel-organ, with its papillary and parietal layer of cells; *c*, *d*, the enamel-membrane and enamel-prisms; *e*, dentine cells; *f*, dental germ and capillaries; *g*, *i*, transition of the wall of the follicle into the tissue of the dental germ.

We have now a vascular papilla surmounted by an inverted cap or capsule of epithelial cells, the whole being surrounded by a membranous sac. The cap or capsule consists of an internal layer of cells—the internal enamel epithelium—in contact with the papilla; of an external layer of cells—the external enamel epithelium—lining the interior of the dentinal capsule; and of an intermediate mass of stellate cells with anastomosing processes (Fig. 560). The enamel is formed exclusively from the internal enamel epithelium, the columnar cells of which undergo direct calcification and become elongated into the hexagonal rods of the enamel. The intermediate cells atrophy and disappear, so that the calcified internal enamel epithelium and the external enamel epithelium come into close apposition, and the cells of this latter layer form a distinct membrane, named the *cuticula dentis* or *Nasmyth's membrane*, which long remains perceptible, and after the tooth has emerged from the gums forms a horny layer which may be separated from the calcified mass below by the action of strong acids. It is marked by the hexagonal impressions of the enamel-prisms, and when stained by nitrate of silver shows the characteristic appearance of epithelium. It soon, however, wears away from the surface of the tooth.

Formation of the Dentine.—While these changes are taking place in the epithelium to form the enamel, contemporaneous changes are occurring in the blastema or corium which result in the formation of the dentine and cement. As before stated, the first germ of the dentine consists in the formation of a dark semilunar area around the bottom of the dental groove. From the middle of this a projection springs up, at first in the form of a ridge, which extends along the whole length of the jaw. The ridge becomes subsequently divided into papillæ, corresponding in number to the teeth, by the atrophy of the intervening parts. The papillæ grow upward into the enamel-organ, and become coated by it and enclosed in a vascular connective tissue, the dentinal sac, in the manner above described. They then constitute the formative pulp from which the dentine and permanent pulp are derived. Each papilla consists of rounded cells and is very vascular, and soon begins to assume the shape of the tooth which is to be developed from it. The next step is the formation of the odontoblasts, which have a relation to the development of the teeth similar to that of the osteoblasts in the formation of bone. They are formed first from the cells of the periphery of the papilla, which become enlarged and of an elongated form and provided with numerous processes. These processes as they grow become calcified externally, the calcified portion forming the walls of the dentinal tubules, and the uncalcified axial portion the dentinal fibres (Tomes's fibres) which are contained within the tubules. In addition to this the lateral processes from the odontoblasts form the branches of anastomosis whereby the dentinal canals communicate. In this way the peripheral layer of the papilla becomes coated with a solid shell of dentine, on the inner surface of which a second layer of odontoblast is arranged, and in its turn calcifies; and thus the process goes on through the entire thickness of the dentine, the processes of one odontoblast being directly continuous with those in succeeding layers, so that each dental fibre must be regarded as formed by several continuous odontoblasts. The central part of the papilla does not undergo calcification; its cells proliferate, nerve-fibres are developed in it, and it remains persistent as the pulp of the tooth. The *cement* is formed from the wall of the dentinal sac, which is developed from the two horns of the semilunar mass at the bottom of the dental groove from which the papilla originally sprung. So that the dentine and cement may be said to originate from analogous structures. In this membranous sac ossification goes on in a manner identical with the intramembranous ossification of bone, and the cement formed is merely ordinary bone, containing canaliculi and lacunæ.

The germs of the milk teeth make their appearance in the following order: At the seventh week the germ of the first molar of the upper jaw appears; at the eighth week, that for the canine tooth is developed; the two incisor papillæ appear about the ninth week (the central preceding the lateral); lastly, the second molar papilla is seen at the tenth week behind the anterior molar. The teeth of the lower jaw appear rather later, the first molar papilla being only just visible at the seventh week, and the second molar papilla not being developed before the eleventh week.

Development of the Permanent Teeth.—The permanent teeth, as regards their development, may be divided into two sets: (1) those which replace the temporary teeth, and, like them, are ten in number: these are the *successional permanent teeth;* and (2) those which have no temporary predecessors, but are superadded at the back of the dental series. These are three in number on either side in either jaw, and are termed the *superadded permanent teeth.* They are the three molars of the permanent set, the molars of the temporary set being replaced by the premolars or bicuspids of the permanent set. The development of the successional permanent teeth—the ten anterior ones in either jaw—will be first considered. In the neck of the enamel-organ of the temporary tooth, prior to the meeting of the two dental ridges and the obliteration of this portion of the primitive dental groove, an indentation of the epithelium takes place in the layer of cells forming the posterior wall of the neck of the sac. This forms a groove or indentation similar to the groove in the oral epithelium of the margin of the jaw which formed the primitive dental groove, and from its resemblance is termed by Goodsir the *secondary dental* *groove*. These grooves or depressions are ten in number in each jaw, and are formed successively from before backward. They become filled with epithelial cells, and recede into the substance of the gum behind the germs of the temporary teeth. They constitute the enamel-germs of the permanent teeth. As they recede they become flask-shaped from an expansion of their distal extremity, and finally meet a papilla which has been formed in the corium, just in the same manner as was the case in the temporary teeth. The apex of the papilla indentates the enamel-germ, which encloses it, and, forming a cap for it, undergoes analogous changes to those described in the development of the milk teeth, and becomes converted into the enamel, whilst the papilla forms the dentine of the permanent tooth. In its development it becomes enclosed in a dental sac which adheres to the back of the sac of the temporary tooth. The sac of each permanent tooth remains connected with the fibrous tissue of the gum by a slender band or *gubernaculum*, which passes to the margin of the jaw behind the corresponding milk tooth.

The *superadded permanent teeth*—three on each side in each jaw—arise from successive extensions backward of the back part of the enamel-germ of the immediately preceding tooth. During the fourth month that portion of the enamel-germ of the last temporary molar tooth which lies behind the tooth, and which has remained unobliterated, is prolonged backward and forms the enamel-germ of the first permanent molar into which a papilla projects. From this tooth in a similar manner, about the seventh month after birth, the second molar is formed; and about the third year the third molar is formed by an extension backward of the enamel-germ of the second molar.

Eruption.—When the calcification of the different tissues of the tooth is sufficiently advanced to enable it to bear the pressure to which it will be afterward subjected, its eruption takes place, the tooth making its way through the gum. The gum is absorbed by the pressure of the crown of the tooth against it, which is itself pressed up by the increasing size of the fang. At the same time the septa between the dental sacs, at first fibrous in structure, ossify and constitute the alveoli; these firmly embrace the necks of the teeth and afford them a solid basis of support.

[FIG. 561.

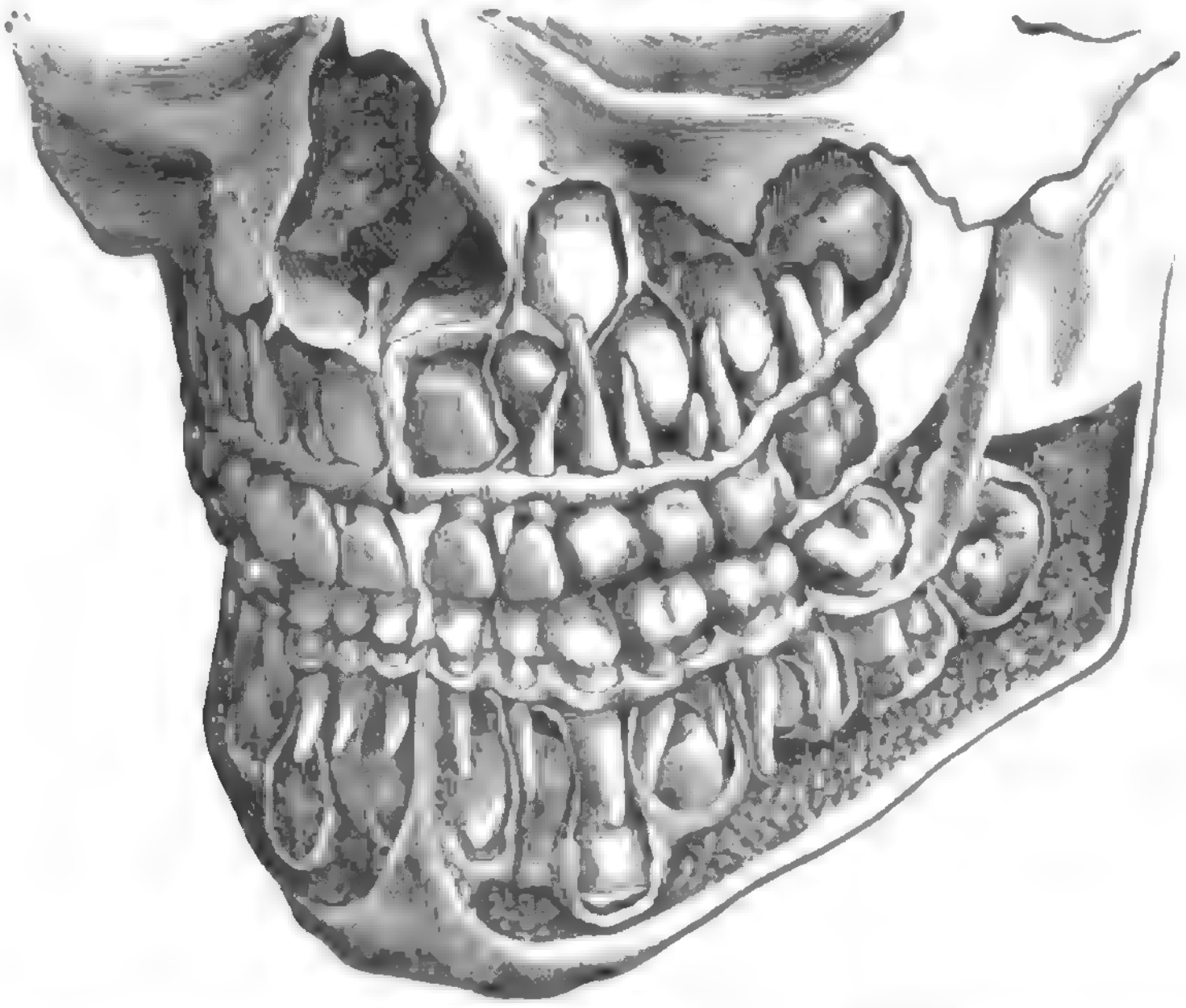

The above figure shows the Denture of a Child about Seven Years Old. The "sixth-year molars" have already appeared. The other permanent teeth are seen partially developed and concealed in the two jaw-bones (Litch).]

The eruption of the temporary teeth commences at the seventh month, and is complete about the end of the second year, those of the lower jaw preceding the upper.

The periods for the eruption of the temporary set are—

7th month, central incisors.
7th to 10th month, lateral incisors.
12th to 14th month, anterior molars.
14th to 20th month, canine.
18th to 36th month, posterior molars.

Calcification of the permanent teeth commences a little before birth, and proceeds in the following order in the upper jaw, in the lower jaw a little earlier: First molar, fifth or sixth month; the central incisor a little later; lateral incisors and canine about the eighth or ninth month; the bicuspids at the second year; second molar fifth or sixth year; wisdom tooth about the twelfth year.

Previous to the permanent teeth penetrating the gum the bony partitions which separate their sacs from the deciduous teeth are absorbed, the fangs of the temporary teeth disappear by absorption through the agency of particular multinucleated cells called *odontoclasts* which are developed at the time in the neighborhood of the fang, and the permanent teeth become placed under the loose crowns of the deciduous teeth; the latter finally become detached, and the permanent teeth take their place in the mouth.

The eruption of the permanent teeth takes place at the following periods, the teeth of the lower jaw preceding those of the upper by a short interval:

6½ years, first molars.
7th year, two middle incisors.
8th year, two lateral incisors.
9th year, first bicuspid.
10th year, second bicuspid.
11th to 12th year, canine.
12th to 13th year, second molars.
17th to 21st year, wisdom teeth.

[As they are very liable to decay unless they receive proper attention and care, it is important that the student should notice that the first permanent molars (generally called the "sixth-year molars") make their eruption *before* the incisors.]

THE PALATE.

The **Palate** [Fig. 552, p. 840] forms the roof of the mouth: it consists of two portions, the hard palate in front, the soft palate behind. [The line of junction of the two can be easily felt, and also is marked to the eye by a different color. The soft palate makes nearly half of the roof of the mouth.]

The **hard palate** is bounded in front and at the sides by the alveolar arches and gums; behind, it is continuous with the soft palate. It is covered by a dense structure formed by the periosteum and mucous membrane of the mouth, which are intimately adherent together. Along the middle line is a linear ridge or raphé, which terminates anteriorly in a small papilla corresponding with the inferior opening of the anterior palatine fossa. This papilla receives filaments from the naso-palatine and anterior palatine nerves. On either side and in front of the raphé the mucous membrane is thick, pale in color, and corrugated; behind, it is thin, smooth, and of a deeper color: it is covered with squamous epithelium, and furnished with numerous glands (palatal glands) which lie between the mucous membrane and the surface of the bone.

The **soft palate** (*velum pendulum palati*) is a movable fold suspended from the posterior border of the hard palate and forming an incomplete septum between the mouth and pharynx. It consists of a fold of mucous membrane enclosing muscular fibres, an aponeurosis, vessels, nerves, adenoid tissue, and mucous glands. When occupying its usual position (*i. e.* relaxed and pendent), its anterior surface is concave, continuous with the roof of the mouth, and marked by a median ridge or raphé, which indicates its original separation into two lateral halves. Its posterior surface is convex, and continuous with the mucous membrane covering the floor of the posterior nares. Its upper border is attached to the posterior margin of the hard palate, and its sides are blended with the pharynx. Its lower border is free.

Hanging from the middle of its lower border is a small conical-shaped pendulous process, the *uvula*, and arching outward and downward from the base of the uvula on each side are two curved folds of mucous membrane containing muscular fibres, called the *arches* or *pillars of the soft palate.*

The *anterior pillars* run downward, outward, and forward to the sides of the base of the tongue, and are formed by the projection of the Palato-glossi muscles, covered by mucous membrane.

The *posterior pillars* are nearer to each other and larger than the anterior; they run downward, outward, and backward to the sides of the pharynx, and are formed by the projection of the Palato-pharyngei muscles, covered by mucous membrane. The anterior and posterior pillars are separated below by a triangular interval in which the tonsil is lodged.

The space left between the arches of the palate on the two sides is called the *isthmus of the fauces.* It is bounded above by the free margin of the palate, below by the tongue, and on each side by the pillars of the soft palate and the tonsil.

The *mucous membrane* of the soft palate is thin, and covered with squamous epithelium on both surfaces, excepting near the orifice of the Eustachian tube, where it is columnar and ciliated.[1] Beneath the mucous membrane, on the oral surface of the soft palate, is a considerable amount of adenoid tissue. The palatine glands form a continuous layer on its posterior surface and around the uvula.

The *aponeurosis* of the soft palate is a thin but firm fibrous layer attached above to the hard palate and becoming thinner toward the free margin of the velum. It is blended with the aponeurotic tendon of the Tensor palati muscle.

The *muscles* of the soft palate are five on each side—the Levator palati, Tensor palati, Palato-glossus, Palato-pharyngeus, and Azygos uvulæ [or Levator uvulæ] (see p. 394). The following is the relative position of these structures in a dissection of the soft palate from the posterior or nasal to the anterior or oral surface: Immediately beneath the nasal mucous membrane is a thin stratum of muscular fibres, the posterior fasciculus of the Palato-pharyngeus muscle joining with its fellow of the opposite side in the middle line. Beneath this is the Azygos uvulæ, consisting of two rounded fleshy fasciculi placed side by side in the median line of the soft palate. Next comes the aponeurosis of the Levator palati joining with the muscle of the opposite side in the middle line. Fourthly, the anterior fasciculus of the Palato-pharyngeus, thicker than the posterior and separating the Levator palati from the next muscle, the Tensor palati. This muscle terminates in a tendon which, after winding round the hamular process, expands into a broad aponeurosis in the soft palate anterior to the other muscles which have been enumerated. Finally, we have a thin muscular stratum, the Palato-glossus muscle, placed in front of the aponeurosis of the Tensor palati, and separated from the oral mucous membrane by adenoid tissue.

The **Tonsils** (*amygdalæ*) are two glandular organs situated one on each side of the fauces, between the anterior and posterior pillars of the soft palate. They are of a rounded form, and vary considerably in size in different individuals. Externally the tonsil is in relation with the inner surface of the Superior constrictor, which separates it from the internal carotid and ascending pharyngeal arteries. It corresponds to the angle of the lower jaw. Its *inner surface* presents from twelve to fifteen orifices leading into small recesses, from which numerous follicles branch out into the substance of the gland. These follicles are lined by a continuation of the mucous membrane of the pharynx, covered with epithelium; around each follicle is a layer of closed capsules imbedded in the submucous tissue. These capsules are analogous to those of Peyer's glands, consisting of adenoid tissue. No openings from the capsules into the follicles can be recognized. They contain a thick grayish secretion.

The *arteries* supplying the tonsil are the dorsalis linguæ from the lingual, the ascending palatine and tonsillar from the facial, the ascending pharyngeal from the external carotid, the descending palatine branch of the internal maxillary, and a twig from the small meningeal.

---

[1] According to Klein, the mucous membrane on the nasal surface of the soft palate is in the fœtus covered throughout by columnar ciliated epithelium.

The *veins* terminate in the tonsillar plexus, on the outer side of the tonsil.

The *nerves* are derived from Meckel's ganglion and from the glosso-pharyngeal.

THE SALIVARY GLANDS (Fig. 562).

The principal salivary glands communicating with the mouth and pouring their secretion into its cavity are the parotid, submaxillary, and sublingual.

The **Parotid Gland,** so called from being placed near the ear (*παρά*, near; *οὖς*, *ὠτός*, the ear), the largest of the three salivary glands, varying in weight from half an ounce to an ounce. It lies upon the side of the face immediately below and in front of the external ear. It is limited above by the zygoma; below by the angle of the jaw and by a line drawn between it and the mastoid process; anteriorly it extends to a variable extent over the Masseter muscle; posteriorly it is bounded by the external meatus, the mastoid process, and the Sterno-mastoid and Digastric muscles, slighly overlapping the former.

Fig. 562.

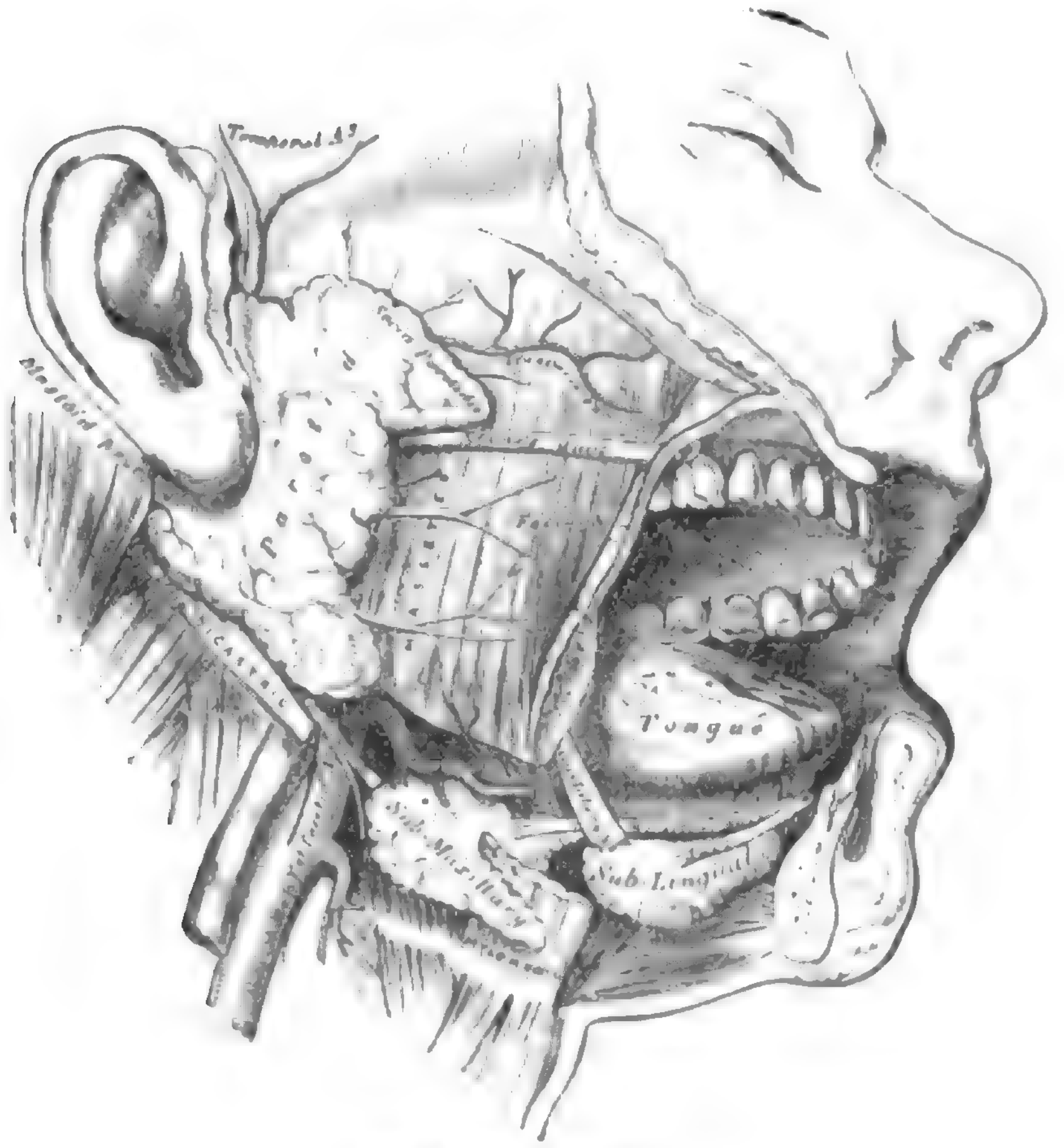

The Salivary Glands.

Its *anterior surface* is grooved to embrace the posterior margin of the ramus of the lower jaw, and advances forward beneath the ramus between the two Pterygoid muscles. Its outer surface, slightly lobulated, is covered by the integument and fascia, and has one or two lymphatic glands resting on it. Its inner surface extends deeply into the neck by means of two large processes, one of which dips behind the styloid process and projects beneath the mastoid process and the Sterno-mastoid muscle; the other is situated in front of the styloid process, and passes into the back part of the glenoid fossa behind the articulation of the lower jaw. Imbedded in its substance is the external carotid artery, which ascends behind the ramus of the jaw; the posterior auricular artery emerges from the gland behind, the temporal artery above, the transverse facial in front, and the internal maxillary winds through it inward, behind the neck of the jaw. Superficial to the external carotid is the trunk formed by the union of the temporal and internal maxillary veins; a branch connecting this trunk with the internal jugular also passes through the gland. It is also traversed, from before backward, by the facial nerve and its branches, which emerge at its anterior border; branches of the great auricular nerve pierce the gland to join the facial, and the auriculo-temporal branch of the inferior maxillary nerve lies above the upper part of the gland. The internal carotid artery and internal jugular vein lie close to its deep surface.

The **Duct of the Parotid Gland** (*Stenson's* [more commonly, but less correctly, called "Steno's"]) is about two inches and a half in length. Its canal is about the size of a crow-quill. It opens upon the inner surface of the cheek by a small orifice opposite the second molar tooth of the upper jaw; and from this orifice it may be traced obliquely for a short distance beneath the mucous membrane, and thence through the substance of the Buccinator muscle and across the Masseter to the anterior border of the gland, in the substance of which it commences by numerous branches. The direction of the duct corresponds to a line drawn across the face about a finger's breadth below the zygoma, from the lower part of the concha to midway between the free margin of the upper lip and the ala of the nose. While crossing the Masseter it receives the duct of a small detached portion of the gland, *socia parotidis*, which occasionally exists as a separate lobe just beneath the zygomatic arch. The parotid duct is dense, of considerable thickness; it consists of an external or fibrous coat of considerable density containing contractile fibres, and of an internal or mucous coat lined with short columnar epithelium.

VESSELS AND NERVES.—The *arteries* supplying the parotid gland are derived from the external carotid and from the branches given off by that vessel in or near its substance. The *veins* empty themselves into the External jugular through some of its tributaries. The *lymphatics* terminate in the superficial and deep cervical glands, passing in their course through two or three lymphatic glands placed on the surface and in the substance of the parotid. The *nerves* are derived from the carotid plexus of the sympathetic, the facial, and the superficial temporal branches of the auriculo-temporal and great auricular nerves.

The **Submaxillary Gland** is situated below the jaw, in the anterior part of the submaxillary triangle of the neck. It is irregular in form and weighs about two drachms. It is covered by the integument, Platysma, deep cervical fascia, and the body of the lower jaw, corresponding to a depression on the inner surface of that bone, and lies upon the Mylo-hyoid, Hyo-glossus, and Stylo-glossus muscles, a portion of the gland passing beneath the posterior border of the Mylo-hyoid. In front of it is the anterior belly of the Digastric; behind, it is separated from the parotid gland by the stylo-maxillary ligament, and from the sublingual gland in front by the Mylo-hyoid muscle. The facial artery lies imbedded in a groove in its posterior and upper border.

FIG. 563.

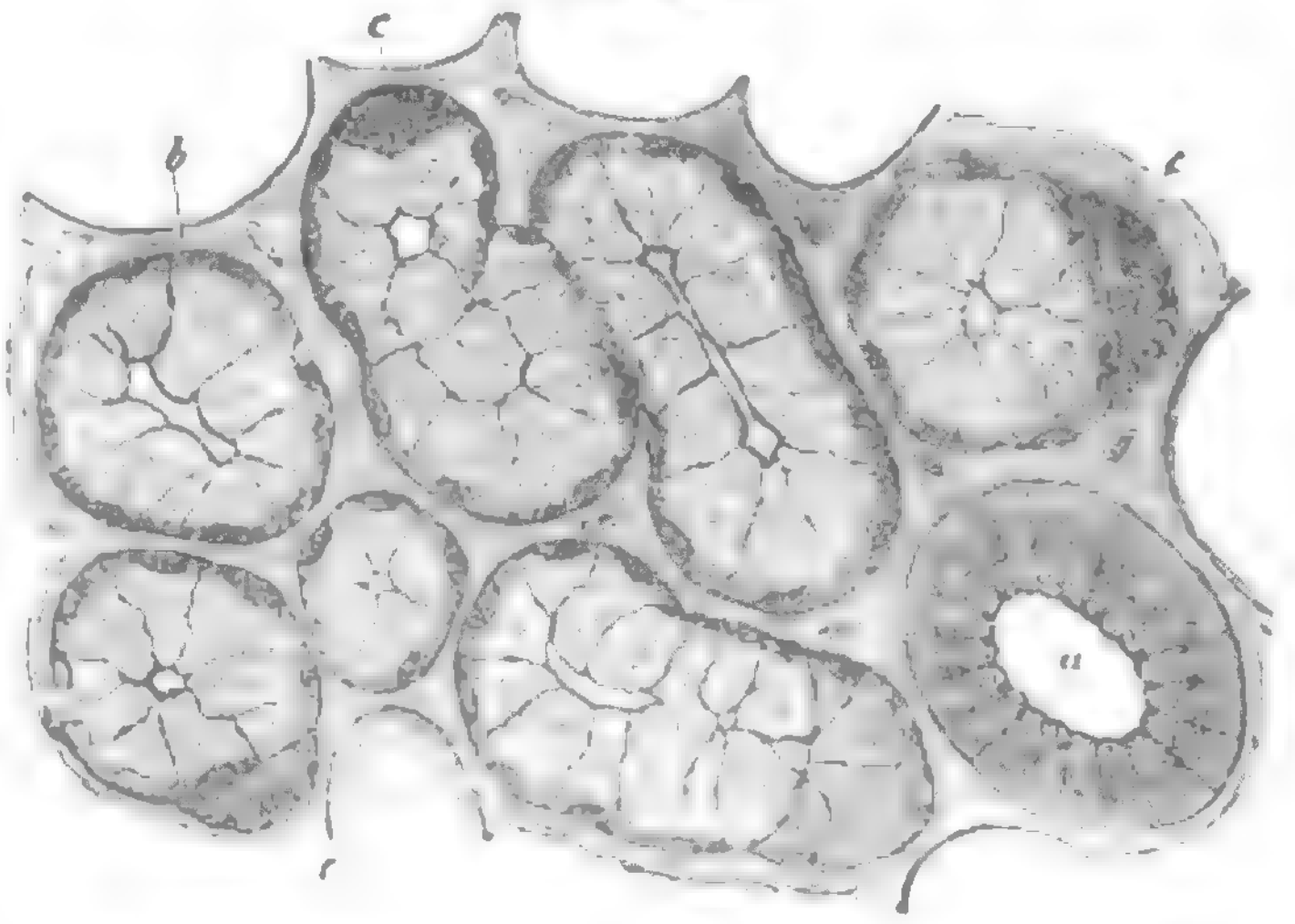

A Highly-magnified Section of the Submaxillary Gland of the Dog, stained with carmine (Kölliker): *a*, cross-section of small salivary duct; *b*, an alveolus containing salivary cells; *c*, crescent of Gianuzzi.

The **Duct of the Submaxillary Gland** (*Wharton's*) is about two inches in length, and its walls are much thinner than those of the parotid duct. It opens by a narrow orifice on the summit of a small papilla at the side of the frænum linguæ. Traced from thence, it is found to pass between the sublingual gland and the Genio-hyo-glossus muscle, then backward and outward between the Mylo-hyoid and the Hyo-glossus and Genio-hyo-glossus muscles, to the deep portion of the gland, where it commences by numerous branches. On the Hyo-glossus muscle it lies between the gustatory and hypoglossal nerves, but at the anterior border of the muscle it crosses beneath the gustatory nerve, and is then placed above it.

Vessels and Nerves.—The *arteries* supplying the submaxillary gland are branches of the facial and lingual. Its *veins* follow the course of the arteries. The *nerves* are derived from the submaxillary ganglion, through which it receives filaments from the chorda tympani of the facial and gustatory branch of the inferior maxillary, from the mylo-hyoid branch of the inferior dental, and from the sympathetic.

The **Sublingual Gland** is the smallest of the salivary glands. It is situated beneath the mucous membrane of the floor of the mouth, at the side of the frænum linguæ, in contact with the inner surface of the lower jaw, close to the symphysis. It is narrow, flattened, in shape somewhat like an almond, and weighs about a drachm. It is in relation *above* with the mucous membrane; *below* with the Mylo-hyoid muscle; *in front* with the depression on the side of the symphysis of the lower jaw and with its fellow of the opposite side; *behind* with the deep part of the submaxillary gland; and *internally* with the Genio-hyo-glossus, from which it is separated by the lingual nerve and Wharton's duct. Its excretory ducts (*ducts of Rivini*), from eight to twenty in number, open separately into the mouth, on the elevated crest of the mucous membrane caused by the projection of the gland on either side of the frænum linguæ. One or more join to form a tube which opens into the Whartonian duct; this is called the *duct of Bartholin.*

Vessels and Nerves.—The sublingual gland is supplied with blood from the sublingual and submental arteries. Its nerves are derived from the gustatory.

Structure.—The salivary are compound racemose glands, consisting of numerous lobes which are made up of smaller lobules connected together by dense areolar tissue, vessels, and ducts. Each lobule consists of the ramifications of a single duct, "branching frequently in a tree-like manner," the branches terminating in dilated ends or alveoli on which the capillaries are distributed. These alveoli, however, as Pflüger points out, are not necessarily spherical, though sometimes they assume that form; sometimes they are perfectly cylindrical, and very often they are mutually compressed. The alveoli are enclosed by a basement membrane which is continuous with the membrana propria of the duct. It presents a peculiar reticulated structure, having the appearance of a basket with open meshes, and consisting of a network of branched and flattened nucleated cells.

The alveoli of the salivary glands are of two kinds, which differ both in the appearance of their secreting cells, in their size, and in the nature of their secretion. The one variety secretes a ropy fluid which contains mucin, and have therefore been named the *mucous*, whilst the other secretes a thinner and more watery fluid which contains serum-albumen, and have been named *serous* or *albuminous.* The sublingual gland may be regarded as an example of the former variety, the parotid of the latter. The submaxillary is of the mixed variety, containing both mucous and serous alveoli, the latter, however, preponderating.

Both alveoli are lined by cells, and it is by the character of these cells that the nature of the gland is chiefly to be determined. In addition, however, the alveoli of the serous glands are smaller than those of the mucous ones.

The cells in the **mucous alveoli** are spheroidal in shape, glassy, transparent, and dimly striated in appearance. The nucleus is usually situated in the part of the cell which is next the basement membrane, against which it is sometimes flattened. The most remarkable peculiarity presented by these cells is, that they give off an extremely fine process, which is curved in a direction parallel to the surface of the alveolus, lies in contact with the membrana propria, and overlaps the processes of neighboring cells. The cells contain a quantity of mucin, to which their clear, transparent appearance is due.

Here and there in the alveoli are seen peculiar half-moon-shaped bodies lying between the cells and the membrana propria of the alveolus. They are termed the *crescents of Gianuzzi* or the *demilunes of Heidenhain* (Fig. 563), and are regarded by Pflüger as due to post-mortem change; but by most other later observers they are believed to be composed of polyhedral granular cells, which Heidenhain regards as young epithelial cells destined to supply the place of those salivary cells which have undergone disintegration. This view, however, is not accepted by Klein.

Fig. 564.

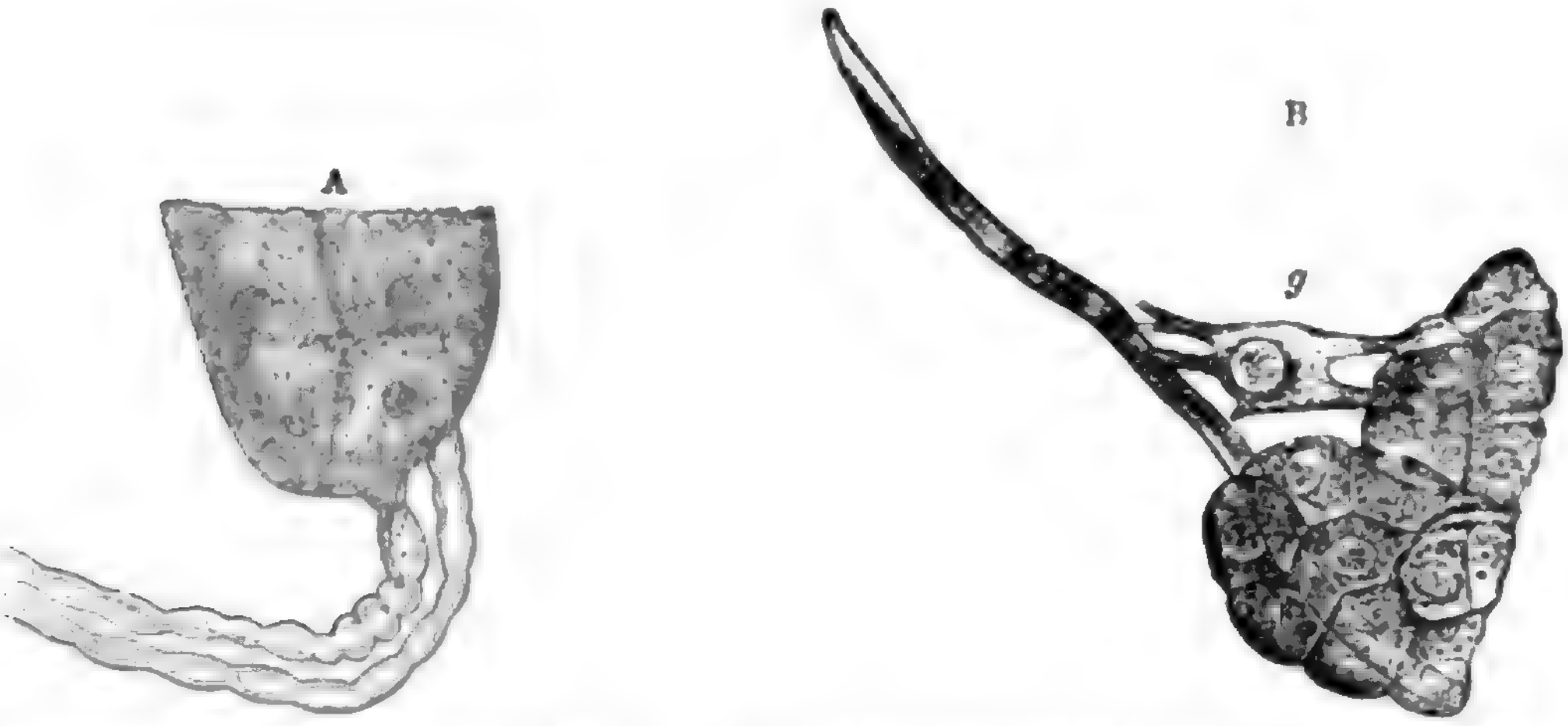

A, direct passage of nerve into a salivary cell. B, by the medium of a multipolar ganglion-cell, *g*.
Illustrating Pflüger's Views of the Termination of the Nerves in the Alveolar Cells (from Stricker's *Handbook*).

Serous Alveoli.—In the serous alveoli the cells almost completely fill the cavity, so that there is hardly any lumen perceptible. Instead of presenting the clear transparent appearance of the cells of the mucous alveoli, they present a granular appearance, due to distinct granules of an albuminous nature imbedded in a closely-reticulated protoplasm. The ducts which originate out of the alveoli are lined at their commencement by epithelium which differs little from the pavement type. As the ducts enlarge the epithelial cells change to the columnar type, and they are described by Pflüger as attached to the basement membrane by a brush of fine hair-like processes, which he believes to be continuous with the nerve-fibres. Other anatomists regard these cells as merely striated on their deep surface. The ducts do not spring only from the alveoli, for between the cells of the alveolus itself a fine branching network is found, which is either a lymphoid tissue continuous with the sheath of the duct or a system of branching tubes by which the ducts commence between the salivary cells (Fig. 565), as the biliary ducts are said to commence between the hepatic cells. The ducts have also diverticular passages lined with columnar epithelium; and it seems that the secretion goes on in these diverticula and in the wider portions of the ducts where the columnar epithelium exists, as well as in the alveoli. The lobules of the salivary glands are richly supplied with blood-vessels, which form a dense network in the interalveolar spaces. Fine plexuses of nerves are also formed in the interlobular tissue. Pflüger describes the nerves as being directly continuous with the salivary cells of the alveolus, the nerve sometimes passing through a ganglion-cell just before joining the alveolus (Fig. 564, A and B).

Fig. 565.

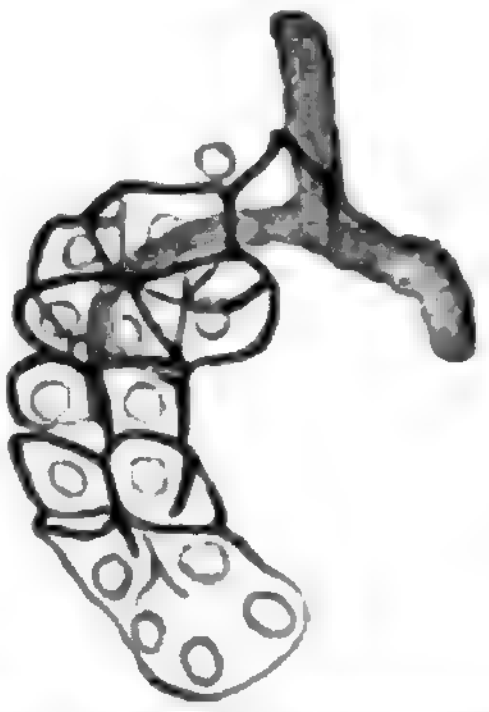

An Alveolus of a Compound Racemose Gland, injected from the Excretory Duct (highly magnified). Hardly anything but the dark injecting fluid is shown; the alveolar cells and nuclei are only faintly indicated; those of the duct are not represented at all. The injection is seen filling the central cavity of the alveolus, and passing from this in fine channels (represented by black reticulating lines) between and around the cells (after Saviotti).

In the submaxillary and sublingual glands the lobes are larger and more loosely united than in the parotid.

Mucous Glands.—Besides the salivary glands proper, numerous other glands are found in the mouth. They appear to secrete mucus only, which serves to keep the mouth moist during the intervals of the salivary secretion, and which is mixed with that secretion in swallowing. Many of these glands are found at the posterior part of the dorsum of the tongue, behind the circumvallate papillæ, and also along its margins as far forward as the apex.[1] Others lie around and in the tonsil between its crypts, and a large number in the soft palate. These glands are of the ordinary compound racemose type.

THE PHARYNX.

The **Pharynx** is that part of the alimentary canal which is placed behind the nose, mouth, and larynx. It is a musculo-membranous sac, somewhat conical in form, with the base upward and the apex downward, extending from the under surface of the skull to the cricoid cartilage in front and the intervertebral disk between the fifth and sixth cervical vertebræ behind. [Its upper and lower portions are often and conveniently named the naso-pharynx and the oro-pharynx.]

The pharynx is about four inches and a half in length, and broader in the transverse than in the antero-posterior diameter. Its greatest breadth is opposite the cornua of the hyoid bone, its narrowest point at its termination in the œsophagus. It is limited *above* by the body of the sphenoid and basilar process of the occipital bone; *below* it is continuous with the œsophagus; *posteriorly* it is connected by loose areolar tissue with the cervical portion of the vertebral column and the Longi colli and Recti capitis antici muscles; *anteriorly* it is incomplete, and is attached in succession to the internal pterygoid plate, the pterygo-maxillary ligament, the lower jaw, the tongue, hyoid bone, and larynx; *laterally* it is connected to the styloid processes and their muscles, and is in contact with the common and internal carotid arteries, the internal jugular veins, and the glosso-pharyngeal, pneumogastric, hypoglossal, and sympathetic nerves, and above with a small part of the Internal pterygoid muscles.

It has seven openings communicating with it: the two posterior nares, the two Eustachian tubes, the mouth, larynx, and œsophagus.

The *posterior nares* are the two large apertures situated at the upper part of the anterior wall of the pharynx.

The *two Eustachian tubes* open one at each side of the upper part of the pharynx, at the back part of the inferior meatus.

Below the nasal fossæ are the posterior surface of the soft palate and uvula, the large aperture of the *mouth*, the base of the tongue, the epiglottis, and the cordiform opening of the *larynx*.

The *œsophageal opening* is the lower contracted portion of the pharynx.

Structure.—The pharynx is composed of three coats—mucous, fibrous, and muscular.

The *fibrous coat* is situated between the mucous and muscular layers, and is called the *pharyngeal aponeurosis*. It is thick above, where the muscular fibres are wanting, and is firmly connected to the basilar process of the occipital and petrous portion of the temporal bones. As it descends it diminishes in thickness and is gradually lost. It is strengthened posteriorly by a strong fibrous band, which is attached above to the pharyngeal spine on the under surface of the basilar portion of the occipital bone, and passes downward, forming a median raphé which gives attachment to the Constrictor muscles of the pharynx.

The *mucous coat* is continuous with that lining the Eustachian tubes, the nares, the mouth, and the larynx. It is covered by columnar ciliated epithelium as low down as on a level with the floor of the nares; below that point the epithelium is of the squamous variety. Beneath the mucous membrane are found racemose mucous glands; they are especially numerous at the upper part of the pharynx around the orifices of the Eustachian tubes. Throughout the pharynx are also numerous crypts or recesses, the walls of which are surrounded by lymphoid tissue similar to what is found in the tonsils. Across the back part of the pharyngeal cavity, between the two Eustachian tubes, a considerable mass of this tissue exists, and has been named the *pharyngeal tonsil.*

---

[1] It has been recently shown by Ebner that many of these glands open into the trenches around the circumvallate papillæ, and that their secretion is more watery than that of ordinary mucous glands. He supposes that they assist in the more rapid distribution of the substance to be tasted over the region where the special apparatus of the sense of taste is situated.

The *muscular coat* has been already described (p. 392).

THE ŒSOPHAGUS.

The **Œsophagus** or **Gullet** is a muscular canal, about nine inches in length, extending from the pharynx to the stomach. It commences at the upper border of the cricoid cartilage, opposite the intervertebral disk between the fifth and sixth cervical vertebræ, descends along the front of the spine through the posterior mediastinum, passes through the Diaphragm, and, entering the abdomen, terminates at the cardiac orifice of the stomach opposite the ninth dorsal vertebra. The general direction of the œsophagus is vertical, but it presents two or three slight curvatures in its course. At its commencement it is placed in the median line, but it inclines to the left side as far as the root of the neck, gradually passes to the middle line again, and finally again deviates to the left as it passes forward to the œsophageal opening of the Diaphragm. The œsophagus also presents an antero-posterior flexure corresponding to the curvature of the cervical and thoracic portions of the spine. It is the narrowest part of the alimentary canal, being most contracted at its commencement and at the point where it passes through the Diaphragm.

RELATIONS.—In the *neck* the œsophagus is in relation, *in front*, with the trachea, and at the lower part of the neck, where it projects to the left side, with the thyroid gland and thoracic duct; *behind* it rests upon the vertebral column and Longus colli muscle; on *each side* it is in relation with the common carotid artery (especially the left, as it inclines to that side) and part of the lateral lobes of the thyroid gland; the recurrent laryngeal nerves ascend between it and the trachea.

In the *thorax* it is at first situated a little to the left of the median line; it then passes behind the left side of the transverse part of the aortic arch, and descends in the posterior mediastinum, along the right side of the aorta, nearly to the Diaphragm, where it passes in front and a little to the left of the artery previous to entering the abdomen. It is in relation *in front* with the trachea, the arch of the aorta, left carotid, and left subclavian arteries, the left bronchus, and the posterior surface of the pericardium; *behind* it rests upon the vertebral column, the Longus colli, and the intercostal vessels, and below, near the Diaphragm, upon the front of the aorta; *laterally* it is covered by the pleuræ: the vena azygos major lies on the right and the descending aorta on the left side. The pneumogastric nerves descend in close contact with it, the right nerve passing down behind and the left nerve in front of it.

Surgical Anatomy.—The relations of the œsophagus are of considerable practical interest to the surgeon, as he is frequently required, in cases of stricture of this tube, to dilate the canal by a bougie, when it is of importance that the direction of the œsophagus and its relations to surrounding parts should be remembered. In cases of malignant disease of the œsophagus, where its tissues have become softened from infiltration of the morbid deposit, the greatest care is requisite in directing the bougie through the strictured part, as a false passage may easily be made, and the instrument may pass into the mediastinum or into one or the other pleural cavity, or even into the pericardium.

The student should also remember that contraction of the œsophagus and consequent symptoms of stricture are occasionally produced by an aneurism of some part of the aorta pressing upon this tube. In such a case the passage of a bougie could only hasten the fatal issue.

It occasionally happens that a foreign body becomes impacted in the œsophagus which can neither be brought upward nor moved downward. When all ordinary means for its removal have failed, excision is the only resource. This, of course, can only be performed when it is not very low down. If the foreign body is allowed to remain, extensive inflammation and ulceration of the œsophagus may ensue. In one case the foreign body ultimately penetrated the intervertebral substance, and destroyed life by inflammation of the membranes and substance of the cord.

The operation of œsophagotomy is thus performed: The patient being placed upon his back, with the head and shoulders slightly elevated, an incision about four inches in length should be made on the left side of the trachea, from the thyroid cartilage downward, dividing the skin and Platysma. The edges of the wound being separated, the Omo-hyoid muscle should, if necessary, be divided, and the fibres of the Sterno-hyoid and Sterno-thyroid muscles drawn inward; the sheath of the carotid vessels, being exposed, should be drawn outward and retained in that position by retractors: the œsophagus will then be exposed, and should be divided over the foreign body, which should then be removed. Great care is necessary to avoid wounding the thyroid vessels, the thyroid gland, and the laryngeal nerves.

Structure.—The œsophagus has three coats—an external or muscular, a middle or areolar, and an internal or mucous coat.

The *muscular coat* is composed of two planes of fibres of considerable thickness—an external longitudinal and an internal circular.

The *longitudinal fibres* are arranged at the commencement of the tube in three fasciculi: one in front, which is attached to the vertical ridge on the posterior surface of the cricoid cartilage; and one at each side, which are continuous with the fibres of the Inferior constrictor: as they descend they blend together and form a uniform layer, which covers the outer surface of the tube.

The *circular fibres* are continuous above with the Inferior constrictor; their direction is transverse at the upper and lower parts of the tube, but oblique in the central part.[1]

The muscular fibres in the upper part of the œsophagus are of a red color, and consist chiefly of the striped variety; but below they consist entirely of the involuntary muscular fibre.

The *areolar coat* connects loosely the mucous and muscular coats.

The *mucous coat* is thick, of a reddish color above and pale below. It is disposed in longitudinal folds, which disappear on distension of the tube. Its surface is studded with minute papillæ, and it is covered throughout with a thick layer of stratified pavement epithelium. Beneath the mucous membrane, between it and the areolar coat, is a layer of longitudinally arranged non-striped muscular fibres. This is the *muscularis mucosæ*. [See Fig. 576, *m*, p. 876.] At the commencement it is absent or only represented by a few scattered bundles; lower down it forms a considerable stratum.

The *œsophageal glands* are numerous small compound racemose glands scattered throughout the tube; they are lodged in the submucous tissue, and open upon the surface by a long excretory duct. They are most numerous at the lower part of the tube, where they form a ring round the cardiac orifice.

THE ABDOMEN.

The **Abdomen** is the largest cavity in the body. It is of an oval form, the extremities of the oval being directed upward and downward; the upper one being formed by the under surface of the Diaphragm, the lower by the upper concave surface of the Levator ani. In order to facilitate description it is artificially divided into two parts—an upper and larger part, the *abdomen proper*, and a lower and smaller part, the *pelvis*. These two cavities are not separated from each other, but the limit between them is marked by the brim of the true pelvis. The space is wider above than below, and measures more in the vertical than in the transverse diameter.

Boundaries.—The **abdomen proper** is bounded in *front* and at the *sides* by the lower ribs, the abdominal muscles, and the venter ilii; *behind* by the vertebral column and the Psoas and Quadratus lumborum muscles; *above* by the Diaphragm; *below* by the brim of the pelvis. The muscles forming the boundaries of the cavity are lined upon their inner surface by a layer of fascia, differently arranged according to the part to which it is attached.

---

[1] Accessory slips of muscular fibres are described by Dr. Cunningham as passing between the œsophagus and the pleura where it covers the thoracic aorta (almost always), or the root of the left bronchus (usually), or the back of the pericardium, or corner of the mediastinum (more rarely), as well as other still more rare accessory fibres (*Journal of Anat. and Phys.*, vol. x, p. 320).

The abdomen contains the greater part of the alimentary canal, some of the accessory organs to digestion—viz. the liver, pancreas, and spleen—and the kidneys and suprarenal capsules. Most of these structures, as well as the wall of the cavity in which they are contained, are covered by an extensive and complicated serous membrane, the *peritoneum.*

The *apertures* found in the walls of the abdomen for the transmission of structures to or from it are the *umbilicus*, for the transmission (in the fœtus) of the umbilical vessels; the *caval opening* in the Diaphragm, for the transmission of the inferior vena cava; the *aortic opening*, for the passage of the aorta, vena azygos, and thoracic duct; and the *œsophageal opening*, for the œsophagus and pneumogastric nerves. *Below*, there are two apertures on each side—one for the passage of the femoral vessels, and the other for the transmission of the spermatic cord in the male and the round ligament in the female.

FIG. 566.

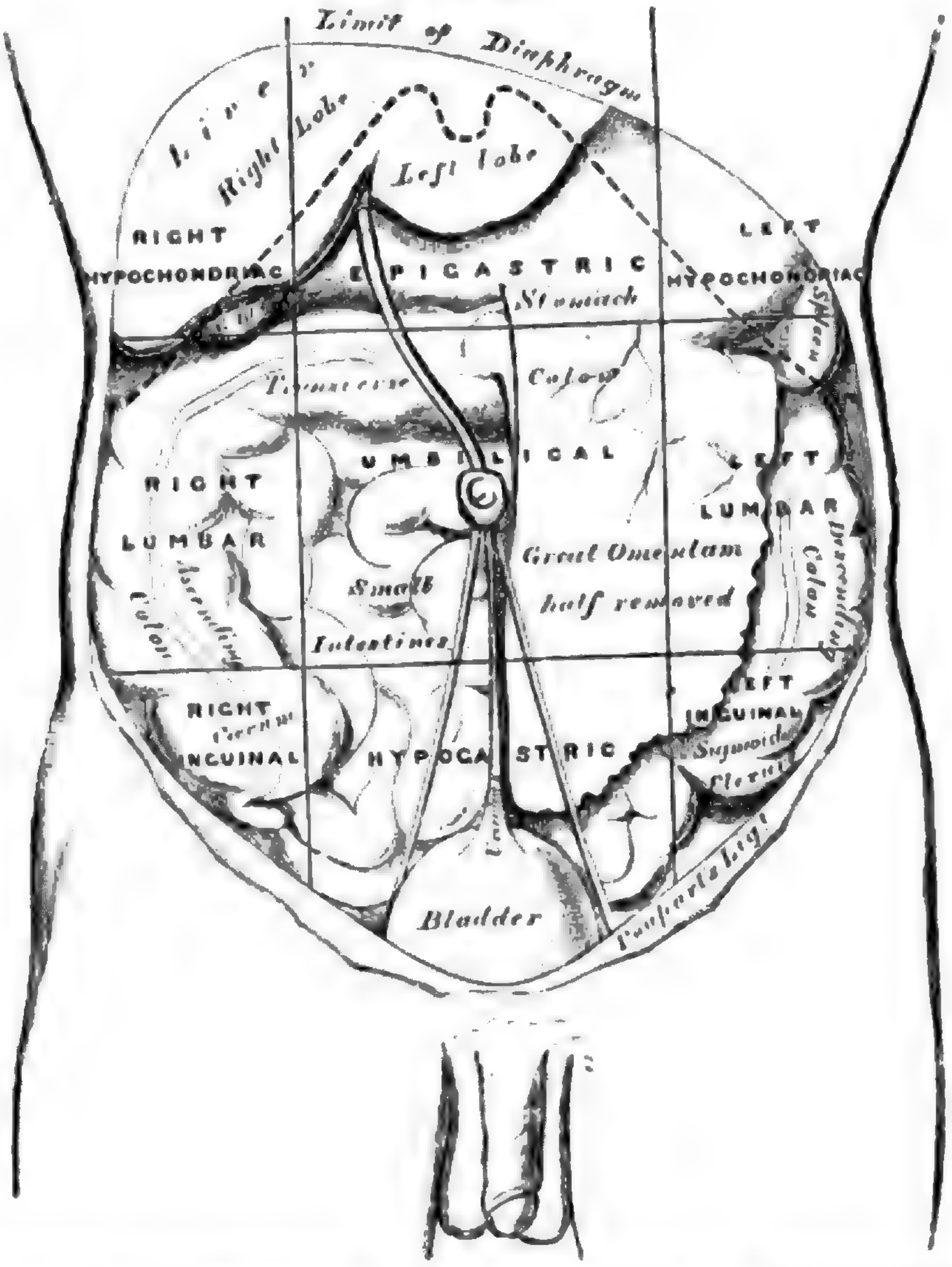
Limit of Diaphragm
Liver
Right Lobe
Left lobe
RIGHT HYPOCHONDRIAC
EPIGASTRIC
LEFT HYPOCHONDRIAC
Stomach
Spleen
Transverse
Colon
UMBILICAL
RIGHT LUMBAR
LEFT LUMBAR
Ascending Colon
Great Omentum half removed
Descending Colon
Small Intestines
RIGHT INGUINAL
Cæcum
HYPOGASTRIC
LEFT INGUINAL
Sigmoid Flexure
Poupart's Ligt
Bladder

The Regions of the Abdomen and their Contents (edge of costal cartilages in dotted outline).

REGIONS.—For convenience of description of the viscera, as well as of reference to the morbid condition of the contained parts, the abdomen is artifically divided into nine regions. Thus, if two circular lines are drawn round the body, the one parallel with the cartilages of the ninth ribs and the other with the highest point of the crests of the ilia, the abdominal cavity is divided into three zones—an upper, a middle, and a lower. If two parallel lines are drawn from the cartilage of the eighth rib on each side down to the centre of Poupart's ligament, each of these zones is subdivided into three parts, a middle and two lateral.

The middle region of the upper zone is called the *epigastric* (ἐπὶ, over; γαστήρ, the stomach), and the two lateral regions, the *right* and *left hypochondriac* (ὑπό, under; χόνδροι, the cartilages). The central region of the middle zone is the umbilical, and the two lateral regions the *right* and *left lumbar*. The middle region of the lower zone is the *hypogastric* or *pubic region*, and the lateral regions are the *right* and *left inguinal* or *iliac*. The viscera contained in these different regions are the following (Fig. 566):

Right Hypochondriac. The right lobe of the liver and the gall-bladder, hepatic flexure of the colon, and part of the right kidney.	*Epigastric Region.* The middle and pyloric end of the stomach, left lobe of the liver, and lobulus Spigelii, the pancreas, the duodenum, parts of the kidneys and the suprarenal capsules [aorta and branches, vena cava, semilunar ganglia, thoracic duct].	*Left Hypochondriac.* The splenic end of the stomach, the spleen and extremity of the pancreas, the splenic flexure of the colon, and part of the left kidney.
Right Lumbar. Ascending colon, part of the right kidney, and some convolutions of the small intestines.	*Umbilical Region.* The transverse colon, part of the great omentum and mesentery, transverse part of the duodenum, and some convolutions of the jejunum and ileum, part of both kidneys [and the receptaculum chyli].	*Left Lumbar.* Descending colon, part of the omentum, part of the left kidney, and some convolutions of the small intestines.
Right Inguinal (Iliac). The cæcum, appendix cæci [ureter, spermatic vessels].	*Hypogastric Region.* Convolutions of the small intestines, the bladder in children, and in adults if distended, and the uterus during pregnancy [often the cæcum, appendix vermiformis, and sigmoid flexure of colon].	*Left Inguinal (Iliac).* Sigmoid flexure of the colon [ureter, spermatic vessels].

THE PERITONEUM.

The *peritoneum* (περιτείνειν, to extend around) is a serous membrane [belonging really, as has been already explained (p. 84), to the lymphatic system], and partially invests all the viscera contained in the abdominal and pelvic cavities. In consequence of the number and different shapes of these viscera the reflections of the peritoneum, as it invests them, are exceedingly complex and difficult to understand.

The peritoneum partially invests all the viscera contained in the abdominal and pelvic cavities, forming the visceral layer of the membrane; it is then reflected upon the internal surface of the parietes of those cavities, forming the parietal layer. The *free* surface of the peritoneum is smooth, moist, and covered by a layer of flattened endothelial cells; its *attached* surface is rough, being connected to the viscera and inner surface of the parietes by means of areolar tissue called the *subperitoneal areolar tissue*. The parietal portion is loosely connected with the fascia lining the abdomen and pelvis, but more closely to the under surface of the Diaphragm and in the middle line of the abdomen.

In order to get first a general idea of the peritoneum and its reflections, the student should bear in mind that all the abdominal and pelvic viscera are placed external to it, and that it is a shut sac superimposed upon the viscera.[1]

---

[1] We may disregard, for the present, the fact that the peritoneum in the female is not an absolutely closed sac, since the Fallopian tubes open into it at their free extremities.

Let the student imagine that all the viscera are in their proper positions in the abdominal cavity, but uninvested by peritoneum. Upon the top of them is placed a large closed sac or bladder, the walls of which are of extreme thinness, and wherever there is a cleft between two viscera a process of peritoneum derived from the part of the sac in contact with the viscera is tucked in between them, so as to cover the adjacent surfaces of the two viscera and separate them from each other, and at the same time, by becoming adherent to the viscera, form an investment for them. Thus in Fig. 567 such a diverticulum or process may be seen tucked in between the under surface of the liver and the upper surface of the stomach, and, extending between the two as far backward as the portal vein, hepatic artery, and hepatic duct, which it covers on their anterior surfaces, forming the anterior layer of what is termed the lesser omentum.

FIG. 567.

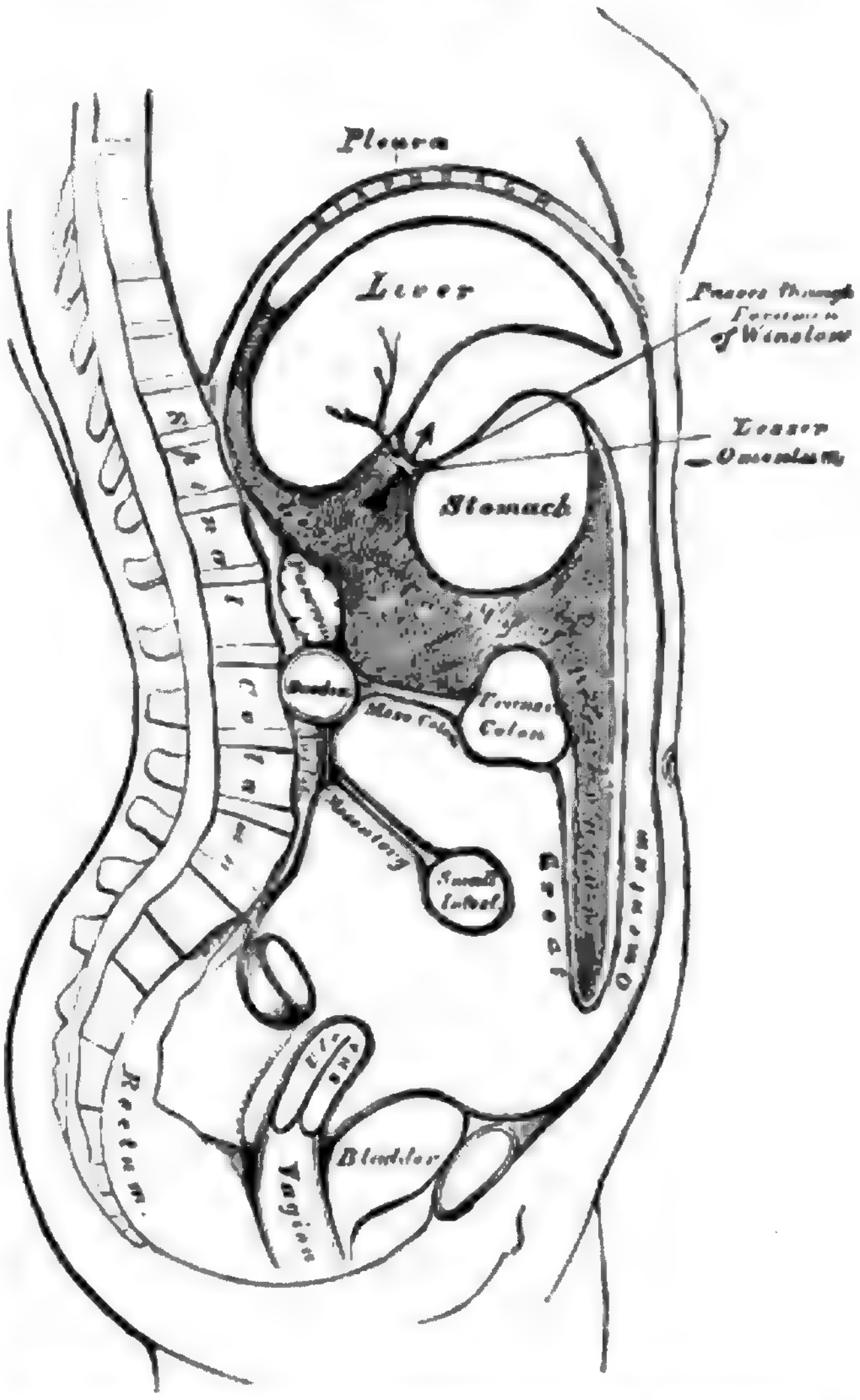

The Reflections of the Peritoneum, as seen in a vertical section of the abdomen.

The first of these diverticula or processes which must be alluded to, because it is the largest, is one which is tucked in round the hepatic artery as it passes forward and upward to the liver and afterward expands into a large sac or bag, which covers the posterior surface of the liver and stomach and the front of the upper part of the posterior wall of the abdomen, separating these structures from each other. This large cul-de-sac of peritoneum is called the *lesser cavity of the peritoneum*, but is only a part of the general cavity, differentiated from it by the constriction produced at the situation of the hepatic artery. In this respect the peritoneum may be compared to an hour-glass with two unequal globes, the smaller one constituting the lesser cavity of the peritoneum, the larger one the greater cavity, and the constriction where the two globes communicate corresponding to the constriction in the peritoneum where it hooks round the hepatic artery. This constriction is called the foramen of Winslow.

A process of this lesser bag of the peritoneum is pushed backward and upward behind the liver, extending as far as the under surface of the Diaphragm, the posterior part of which it covers. At its extremity this process is in contact with a process of the greater bag of the peritoneum, which is pushed in from the front, in the cleft between the upper surface of the liver and the under surface of the Diaphragm. Where these two layers are in contact (passing down from the Diaphragm to the liver) they form some of the ligaments of the liver, thus supporting and holding it in position. A second process of the lesser bag of the peritoneum is pushed forward on the under surface of the liver, which it invests as far as the transverse fissure; here it takes a sudden turn downward to the lesser curvature of the stomach and forms the posterior layer of the gastro-hepatic or lesser omentum. Between the transverse fissure of the liver and the lesser curvature of the stomach it is in contact with the greater bag of the peritoneum, a process of which is sent inward between the liver and stomach from the front. Between the two layers are situated the hepatic artery, the portal vein, and the hepatic duct. A third process of the lesser bag passes from the great curvature of the stomach in front of the small intestines for a variable distance, and, being reflected upon itself, ascends to the upper surface of the transverse colon. In doing this it forms a loose fold lying between the small intestine and the abdominal wall, but contained between two layers of the greater bag, which are reflected in a similar way to the *under* surface of the transverse colon from the greater curvature of the stomach.

This process of the lesser bag, after investing the upper surface of the transverse colon, passes back to the spine, forming the upper layer of the transverse mesocolon, and, ascending in front of the pancreas and crura of the Diaphragm, reaches the under surface of the Diaphragm, where it is continuous with the process of the lesser bag, which we have seen lining the under surface of the posterior part of this muscle. Thus the lesser cavity of the peritoneum is seen to be a complete sac or bag, separating the back and part of the under surface of the liver, the posterior wall of the stomach, and the upper surface of the transverse colon from the back part of the under surface of the Diaphragm and the upper part of the posterior wall of the abdomen.

The *greater cavity* of the peritoneum separates the anterior surfaces of the viscera from the front wall of the abdomen, so that in our comparison of the two cavities to an hour-glass it must be borne in mind that they are not in the same straight line as the two globes of the hour-glass; but that at the point of constriction the smaller cavity is bent round the hepatic artery, so as to lie behind the greater cavity.

The greater sac of the peritoneum is placed in front of the viscera, one layer being in contact with them, the other lining the inner surface of the anterior wall of the abdomen. The layer which is in relation with the viscera sends backward diverticula which pass between the various organs, and in certain places comes in contact with the peritoneum, forming the lesser bag in the manner described above. Thus we have one of these diverticula sent backward between the liver and Diaphragm, covering the anterior part of the under surface of the Diaphragm until it meets the peritoneum of the lesser cavity, and covering the upper surface of the liver as far backward as the ligaments. The extremity of this diverticulum is in contact with a similar diverticulum of the lesser bag, already described, and the two layers, when in apposition, form the coronary and lateral ligaments of the liver. Another process is sent backward between the under surface of the liver and the stomach to meet a similar process of the lesser cavity prolonged from behind forward. Where the two are in apposition the lesser or gastro-hepatic omentum is formed. A third diverticulum is carried backward to the posterior wall of the abdomen between the transverse colon and the small intestine. This prolongation covers the under surface of the transverse colon, and forms the under layer of the transverse mesocolon and the upper layer of the mesentery; by its extremity it is in contact with the posterior wall of the abdomen and covers a part of the abdominal aorta. Between the greater curvature of the stomach and the transverse colon there is a fold or reduplication of the peritoneum which contains between its layers a similar fold from the lesser cavity and forms the apron or great omentum. Another fold of the greater bag of the peritoneum is pushed backward to the spine between the small intestines and the pelvic viscera. This fold forms the lower layer of the mesentery, and by its extremity covers a considerable portion of the lower part of the abdominal wall and passes over the sacro-vertebral angle into the pelvis. From the lower layer of this process, which covers the upper part of the pelvic viscera, diverticula are sent *downward* between the pelvic viscera, separating them from one another; thus one is sent downward between the back of the rectum and the sacrum, another between the rectum and the bladder. In the female one is sent down between the rectum and uterus, another between the uterus and bladder. These, then, are the various diverticula sent off from the posterior layer of the greater bag of the peritoneum; the anterior layer simply lines the anterior wall of the abdomen, and is continuous at its extremities with the posterior layer.

The student will perhaps be better able to follow these various folds or reflections of the peritoneum by a reference to the accompanying plan (Fig. 568), which should be studied in conjunction with Fig. 567. He must not forget, however, that though the lesser and greater cavities of the peritoneum are here represented, for the sake of clearness, as quite distinct from each other, they are not really so, but that they both form part of one great cavity.

Fig. 568.

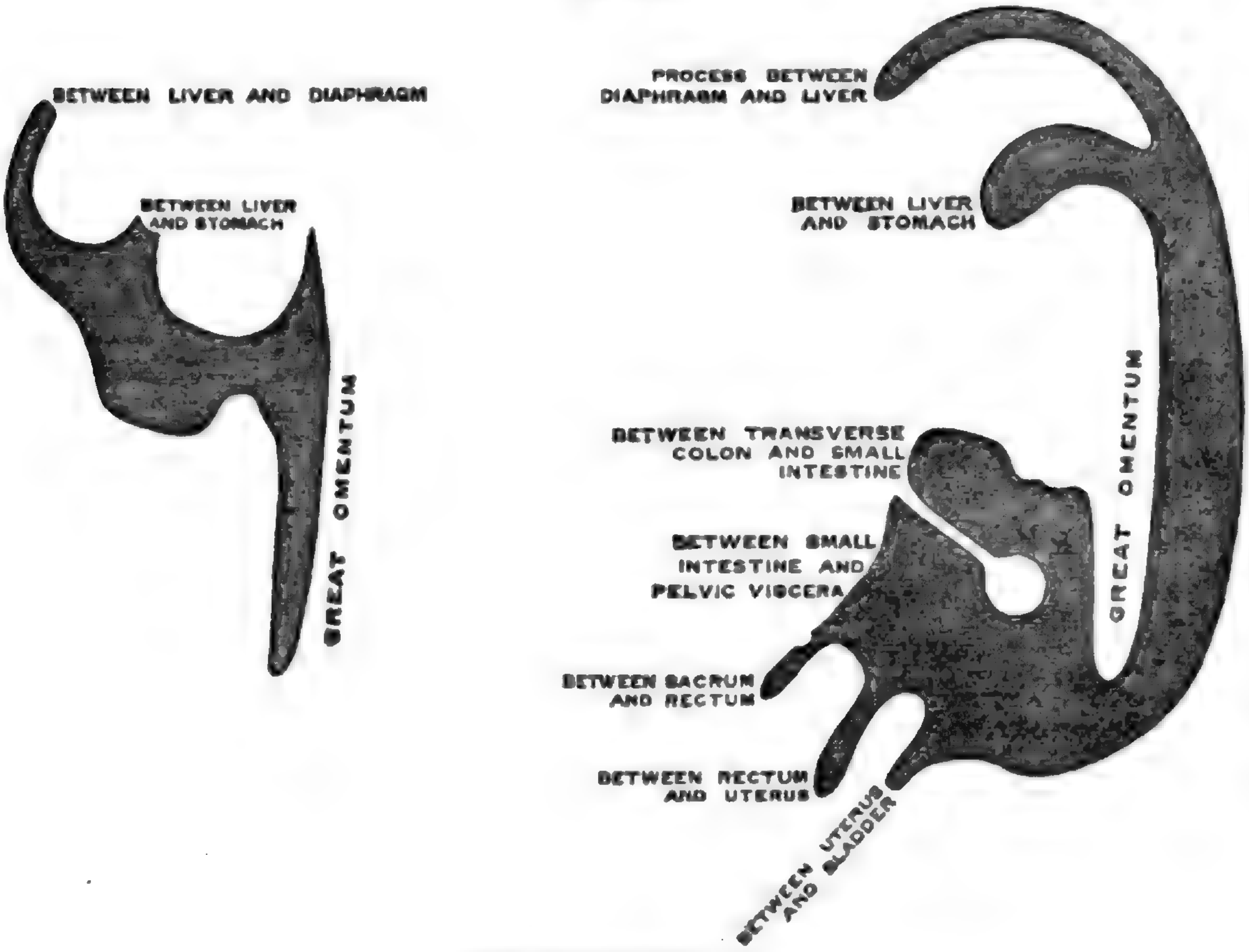
BETWEEN LIVER AND DIAPHRAGM
BETWEEN LIVER AND STOMACH
GREAT OMENTUM
PROCESS BETWEEN DIAPHRAGM AND LIVER
BETWEEN LIVER AND STOMACH
GREAT OMENTUM
BETWEEN TRANSVERSE COLON AND SMALL INTESTINE
BETWEEN SMALL INTESTINE AND PELVIC VISCERA
BETWEEN SACRUM AND RECTUM
BETWEEN RECTUM AND UTERUS
BETWEEN UTERUS AND BLADDER

Plan of the Peritoneum.

The reflections of the peritoneum may be traced in two different ways—either by considering the folds which form each cavity separately, or by describing them together.

According to the first plan (Fig. 567), the abdomen having been opened, the liver should be raised and supported in that position, and the stomach should be depressed, when a thin membranous layer is seen passing from the transverse fissure of the liver to the upper border of the stomach: this is the *lesser* or *gastro-hepatic omentum.* It consists of two delicate layers of peritoneum, an anterior and a posterior, between which are contained the hepatic vessels and nerves. Of these two layers, the anterior should first be traced, and then the posterior.

The *anterior layer* descends to the lesser curvature of the stomach, and covers its anterior surface as far as the great curvature: it descends for some distance in front of the small intestines, and, returning upon itself to the transverse colon, forms the *external layer of the great omentum;* it then covers the under surface of the transverse colon, and, passing to the back part of the abdominal cavity, forms the *inferior layer of the transverse mesocolon.* [In the fœtus (not to mention the still earlier and much simpler arrangement of the peritoneum) the layers of the great omentum follow the course shown in Fig. 569. According to Hansen.[1] there are here five layers, and not three, in front of the transverse colon, as in Fig. 567. In the adult, adhesion of the three posterior layers at the point 4 and above oblit-

---

[[1] Cruveilhier and See, *Anat. déscrip.*, ii. 534.]

[Fig. 569.

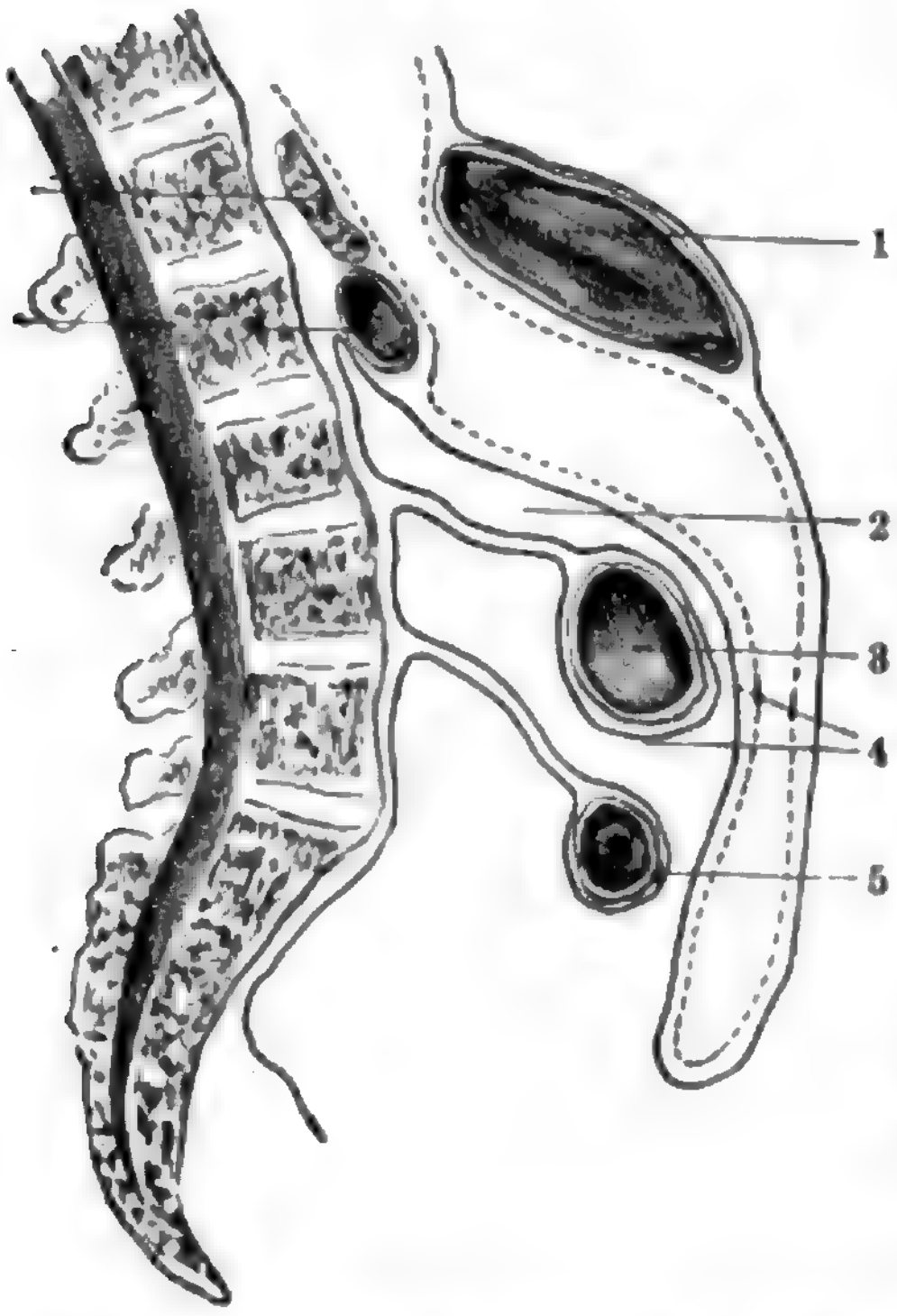

1, stomach; 2, cul-de-sac existing in fœtal life, but obliterated by agglutination in the adult; 3, transverse colon; 4, the two layers of peritoneum forming the cul-de-sac (2) become united thus far; 5, small intestine (Cruveilhier).]

erates the cul-de-sac 2 and produces the condition shown in the adult in Fig. 567. This is a process similar to the obliteration in the adult of the fœtal cul-de-sac of the tunica vaginalis testis.] It then descends in front of the duodenum, the aorta, and vena cava as far as the superior mesenteric artery, along which it passes to invest the small intestines, and, returning to the vertebral column, forms the *mesentery*, whilst on either side it covers the ascending and descending colon, and is thus continuous with the peritoneum lining the walls of the abdomen. From the root of the mesentery it descends along the front of the spine into the pelvis, and surrounds the upper part of the rectum, which it holds in its position by means of a distinct fold, the *mesorectum*. Its course in the male and female now differs.

In the *male* it forms a fold between the rectum and bladder, the *recto-vesical fold* [see Fig. 682, p. 1022], and ascends over the posterior surface of the latter organ as far as its summit.

In the *female* it descends into the pelvis in front of the rectum, forms a fold between the rectum and vagina, the *recto-vaginal fold* (pouch [or cul-de-sac] of Douglas), covers a small part of the posterior wall of the vagina, and passes on to the uterus, the fundus and body of which it covers. From the sides of the uterus it is reflected on each side to the wall of the pelvis, forming the broad ligaments; and from the anterior surface of the uterus it ascends upon the posterior wall of the bladder as far as its summit. From this point it may be traced as in the male, ascending upon the anterior parietes of the abdomen, to the under surface of the Diaphragm, from which it is reflected upon the liver, forming the upper layer of the coronary and the lateral and longitudinal ligaments. It then covers the upper and under surfaces of the liver, and at the transverse fissure becomes continuous with the anterior layer of the lesser omentum, the point whence its reflection was originally traced.

The *posterior layer* of the lesser omentum descends to the lesser curvature of the stomach, and covers its posterior surface as far as the great curvature; it then descends for some distance in front of the small intestines, and, returning upon itself to the transverse colon, forms the internal layer of the great omentum; it covers the upper surface of the transverse colon, and, passing backward to the spine, forms the upper layer of the transverse mesocolon. Ascending in front of the pancreas and crura of the Diaphragm, it lines the back part of the under surface of that muscle, from which it is reflected on to the posterior border of the liver, forming the inferior layer of the coronary ligament. From the under surface of the liver it may be traced to the transverse fissure, where it is continuous with the posterior layer of the lesser omentum, the point whence its reflection was originally traced.

The space included in the reflections of this layer of the peritoneum is called the *lesser cavity of the peritoneum* or *cavity of the great omentum*. It is bounded in *front* by the lesser omentum, the stomach, and the descending part of the great omentum; *behind* by the ascending part of the great omentum, the transverse colon, transverse mesocolon, and its ascending layer; *above* by the liver; and *below* by the folding of the great omentum. This space communicates with the general peritoneal cavity through the foramen of Winslow, which is situated behind the right (or free) border of the lesser omentum.

In order to trace the two layers together, we commence at the top of the abdominal cavity; that is to say, the under surface of the Diaphragm. This muscle is covered throughout the greater part of its extent by peritoneum, one layer extending from its anterior border backward, the other from its posterior border forward. Where the two layers meet they are reflected downward to the upper surface of the liver, forming the coronary and lateral ligaments of this organ. When these two layers reach the liver they again separate to enclose this viscus, the one passing in front and the other behind, and they meet again on its under surface at the transverse fissure. From this fissure they run downward to the lesser curvature of the stomach, forming the gastro-hepatic or lesser omentum, and enclosing the hepatic artery, the portal vein, and the hepatic duct, which are contained between the two folds in this situation. From the lesser curvature of the stomach, the two layers pass over the anterior and posterior surfaces of the viscus, enclosing it and meeting again at the greater curvature. From this point they pass down in front of the small intestines, between this tube and the abdominal wall, and are reflected on themselves, passing upward to the transverse colon and forming the apron or great omentum. This reflection, therefore, consists of *four* layers of peritoneum. When the two posterior layers of the great omentum in their reflection upward reach the transverse colon, they separate to enclose this portion of the intestinal tube, the one layer passing above it and the other below. They meet on its posterior surface and pass backward to the vertebral column, forming what is called the *transverse mesocolon.* [Cf. p. 866.] At this point the two layers separate. The one which formed the upper surface of the transverse mesocolon, and which belongs to the lesser cavity, passes upward in front of the pancreas and crura of the Diaphragm to the back part of the under surface of the Diaphragm, the point from which the description of this layer was commenced. The other, which formed the inferior layer of the transverse mesocolon, turns downward in front of the duodenum, aorta, and inferior vena cava, and can be traced as a single layer in the manner above described, investing the small intestines and forming the mesentery; then passing over the sacro-vertebral angle into the pelvis, the viscera of which it partially invests, and finally over the posterior surface of the front wall of the abdomen to the under surface of the Diaphragm, the point from which the description of this layer was commenced.

In addition to tracing the peritoneum vertically, as has now been done, it is necessary to trace it horizontally. If this is done below the transverse colon, a reference to Fig. 567 will show that the circle is extremely simple, as it includes only the greater bag of the peritoneum. Above the level of the transverse colon the arrangement is more complicated, on account of the existence of two sacs.

Starting from the linea alba, below the level of the transverse colon, and tracing the continuity in a horizontal direction to the right, we find the peritoneum covering the internal surface of the abdominal wall almost as far as the anterior border of the Quadratus lumborum muscle; it is there reflected over the sides and anterior surface of the cæcum and ascending colon, fixing them to the abdominal wall, thus forming the mesocæcum and the ascending mesocolon, from which it can be traced over the kidney to the front of the bodies of the vertebræ. It then passes along the mesenteric vessels to invest the small intestines, and back again to the spine, forming the mesentery, between the layers of which are contained the blood-vessels, nerves, lacteals, and glands. Lastly, it passes over the left kidney to the sides and anterior surface of the descending colon, forming the descending and sigmoid mesocolon, and, reaching the abdominal wall, it passes along it to the middle line of the abdomen.

Above the transverse colon (Fig. 570) the peritoneum can be traced, forming the greater and lesser cavities, and their communication through the foramen of Winslow can be demonstrated. Commencing in the middle line of the abdomen, the membrane may be traced lining its anterior wall, and on the right side sending a process backward to encircle the obliterated umbilical vein (the round ligament of the liver), forming the falciform or longitudinal ligament of the liver. Continuing its course to the right, it is reflected over the front of the upper part of the right kidney, across the vena cava inferior and aorta, and over the left kidney to the hilum of the spleen. From this point it is reflected on to the posterior surface of the stomach, which it covers, and from its right extremity it passes around the vessels passing to the transverse fissure of the liver, and back again to the stomach as the lesser omentum; and thus it forms the anterior boundary of the foramen of Winslow. It now covers the front of the stomach, and upon reaching the cardiac extremity it passes to the spleen, which it encloses, forming the gastro-splenic omentum. From the hilum of the spleen it turns backward to reach the abdominal wall, along which it courses to reach the median line of the abdomen.

Fig. 570.

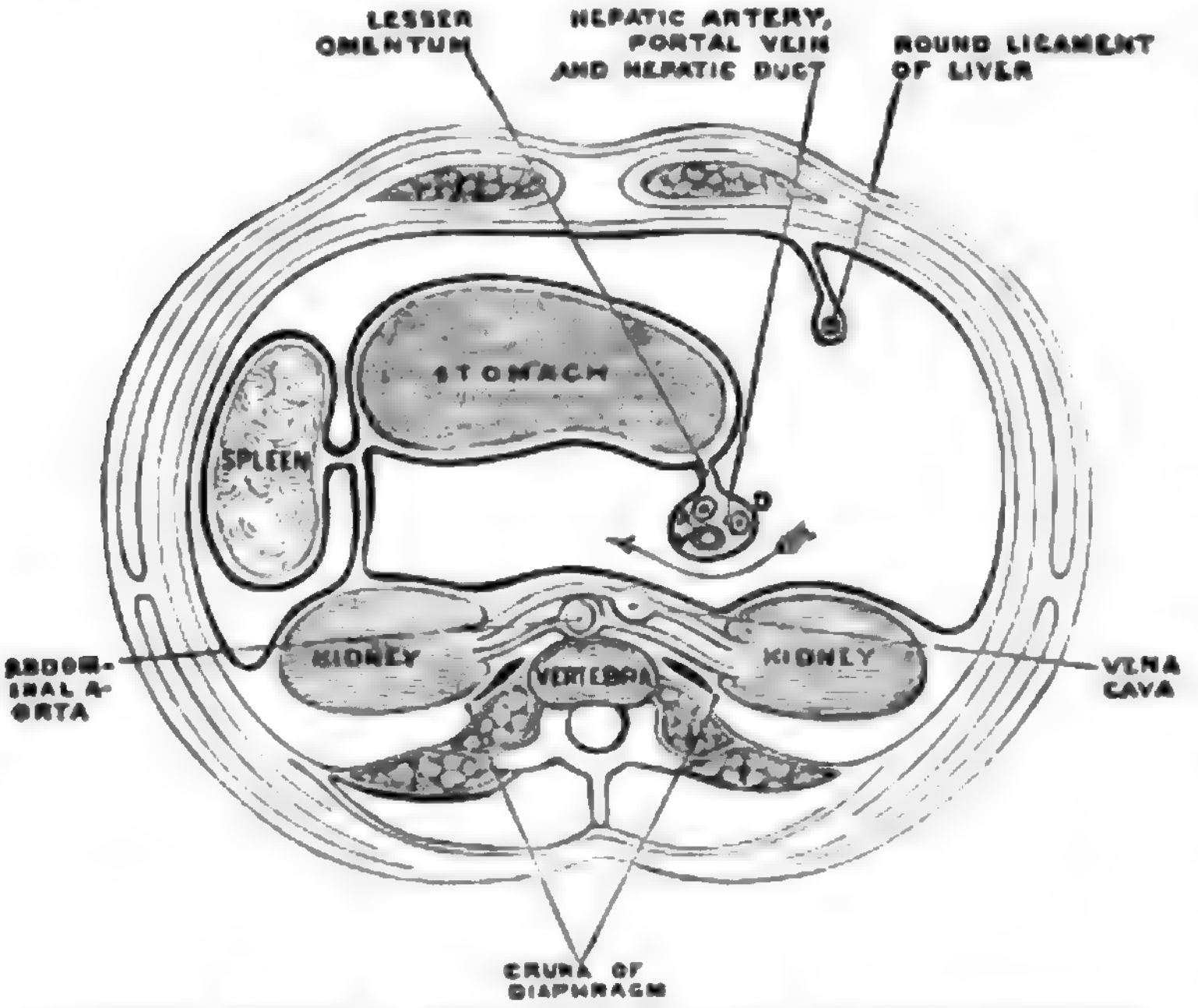

Transverse Section of Peritoneum (an arrow has been introduced into the foramen of Winslow).

The *foramen of Winslow* is bounded in *front* by the lesser omentum, enclosing the vena portæ and the hepatic artery and duct; *behind* by the inferior vena cava; *above* by the lobulus Spigelii; *below* by the hepatic artery curving forward from the cœliac axis.

The reflections of the peritoneum over the transverse colon are somewhat differently described by some authors (Luschka, Holden); and there is no doubt, as was long ago pointed out by Haller, that the arrangement in the fœtus is different from that which has been described above. In the fœtus, and even in the young child, the two ascending layers of the great omentum can be traced passing together *over* the transverse colon, instead of embracing it, as described above, and passing back to the spine as a double fold, which can be separated from the transverse colon and transverse mesocolon. Upon reaching the spine the two layers separate: the upper one (the inner of the two ascending layers of the great omentum) passes upward in front of the pancreas and crura of the Diaphragm, forming the posterior boundary of the lesser bag of the peritoneum, in a similar manner to the upper layer of the transverse mesocolon in the former description. The other fold (the outer of the ascending layer of the great omentum), after reaching the spine, is turned forward again on itself as far as the transverse colon, which it covers, and is again reflected back to the spine, to pass down in front of the aorta to form the mesentery, in a similar manner to the lower layer of the transverse mesocolon in the former description. Thus the transverse colon is invested by a distinct fold of peritoneum prolonged forward from the spine to surround it, in a very similar manner to the way in which the small intestines are surrounded.

In the adult, however, as a rule, this arrangement disappears. Probably adhesion of the layers of which the fœtal duplication is composed takes place, and then absorption, and thus the arrangement is brought about which has been described above as most frequently seen in the adult subject. It may be that the fœtal duplicature is "drawn or pushed forward from its place in the progress of visceral development, and thus effaced."[1]

The viscera thus shown to be almost entirely invested by peritoneum are the liver, stomach, spleen, first portion of the duodenum, the jejunum and ileum, the transverse colon, sigmoid flexure, upper half of the rectum, the uterus, and ovaries.

The viscera only partially invested by peritoneum are the descending and transverse portions of the duodenum, the cæcum, the ascending and descending colon, the middle portion of the rectum, and the upper part of the vagina and posterior wall of the bladder. The kidneys, suprarenal capsules, and pancreas are covered by the membrane without receiving any special investment from it.

---

[1] Quain's *Anatomy*, vol. ii. p. 485.

The lower end of the rectum, the neck, base, and anterior surface of the bladder, the whole of the front, and the lower part of the posterior wall of the vagina have no peritoneal covering.

Numerous folds are formed by the peritoneum, extending between the various organs. These serve to hold them in position, and at the same time enclose the vessels and nerves proceeding to each part. Some of the folds are called *ligaments*, from their serving to support the organs in position; others, which connect certain parts of the intestine with the abdominal wall, constitute the *mesenteries;* and lastly, those which proceed from the stomach to certain viscera in its neighborhood are called *omenta*.

The **Ligaments**, formed by folds of the peritoneum, include those of the liver, spleen, bladder, and uterus. They will be found described with their respective organs.

The **Omenta** are the lesser omentum, the great omentum, and the gastro-splenic omentum.

The *lesser omentum* (*gastro-hepatic*) is the duplicature which extends between the transverse fissure of the liver and the lesser curvature of the stomach. It is extremely thin, and consists, as before said, of two layers of peritoneum. At the left border its two layers pass on to the end of the œsophagus; but at the right border, where it is free, they are continuous, and form a free rounded margin, which contains between its layers the hepatic artery, the common bile-duct, the portal vein, lymphatics, and the hepatic plexus of nerves,—all these structures being enclosed in loose areolar tissue called *Glisson's capsule*. Between the layers where they are attached to the stomach lie the gastric artery and the pyloric branch of the hepatic, anastomosing with it.

The *great omentum* (*gastro-colic*) is the largest peritoneal fold. It consists of four layers of peritoneum, two of which descend from the stomach—one from its anterior, the other from its posterior, surface—and, uniting at its lower border, descend in front of the small intestines as low down as the pelvis; they then turn upon themselves and ascend again as far as the transverse colon, where they separate and enclose that part of the intestine. These separate layers may be easily demonstrated in the young subject, but in the adult they are more or less inseparably blended. The left border of the great omentum is continuous with the gastro-splenic omentum; its right border extends as far only as the duodenum. The great omentum is usually thin, presents a cribriform appearance, and always contains some adipose tissue, which, in fat subjects, accumulates in considerable quantity. Its use appears to be to protect the intestines from the cold and to facilitate their movement upon each other during their vermicular action. Between its two anterior layers is the anastomosis between the right and left gastro-epiploica arteries.

The *gastro-splenic omentum* is the fold which connects the concave surface of the spleen to the cul-de-sac of the stomach, being continuous by its lower border with the great omentum. It contains the splenic vessels and vasa brevia.

The **Mesenteries** are—the mesentery proper, the mesocæcum, the ascending, transverse, and descending mesocolon, the sigmoid mesocolon, and the mesorectum.

The *mesentery* (*μέσον, ἔντερον*), so called from being connected to the middle of the cylinder of the small intestine, is the broad fold of peritoneum which connects the convolutions of the jejunum and ileum with the posterior wall of the abdomen. Its *root*, the part connected with the vertebral column, is narrow, about six inches in length, and directed obliquely from the left side of the second lumbar vertebra to the right sacro-iliac symphysis (Fig. 571). Its intestinal border is much longer; and here its two layers separate so as to enclose the intestine and form its peritoneal coat. Its breadth, between its vertebral and intestinal border, is about four inches. Its *upper border* is continuous with the under surface of the transverse mesocolon;

its *lower border*, with the peritoneum covering the cæcum and ascending colon. It serves to retain the small intestines in their position, and contains between its layers the mesenteric vessels and nerves, the lacteal vessels, and mesenteric glands.

The *mesocæcum*, when it exists, serves to connect the back part of the cæcum with the right iliac fossa; more frequently the peritoneum passes merely in front of this portion of the large intestine.

The *ascending mesocolon* is the fold which connects the back part of the ascending colon with the posterior wall of the abdomen, and the *descending mesocolon* retains the descending colon in connection with the posterior abdominal wall; more

Fig. 571.

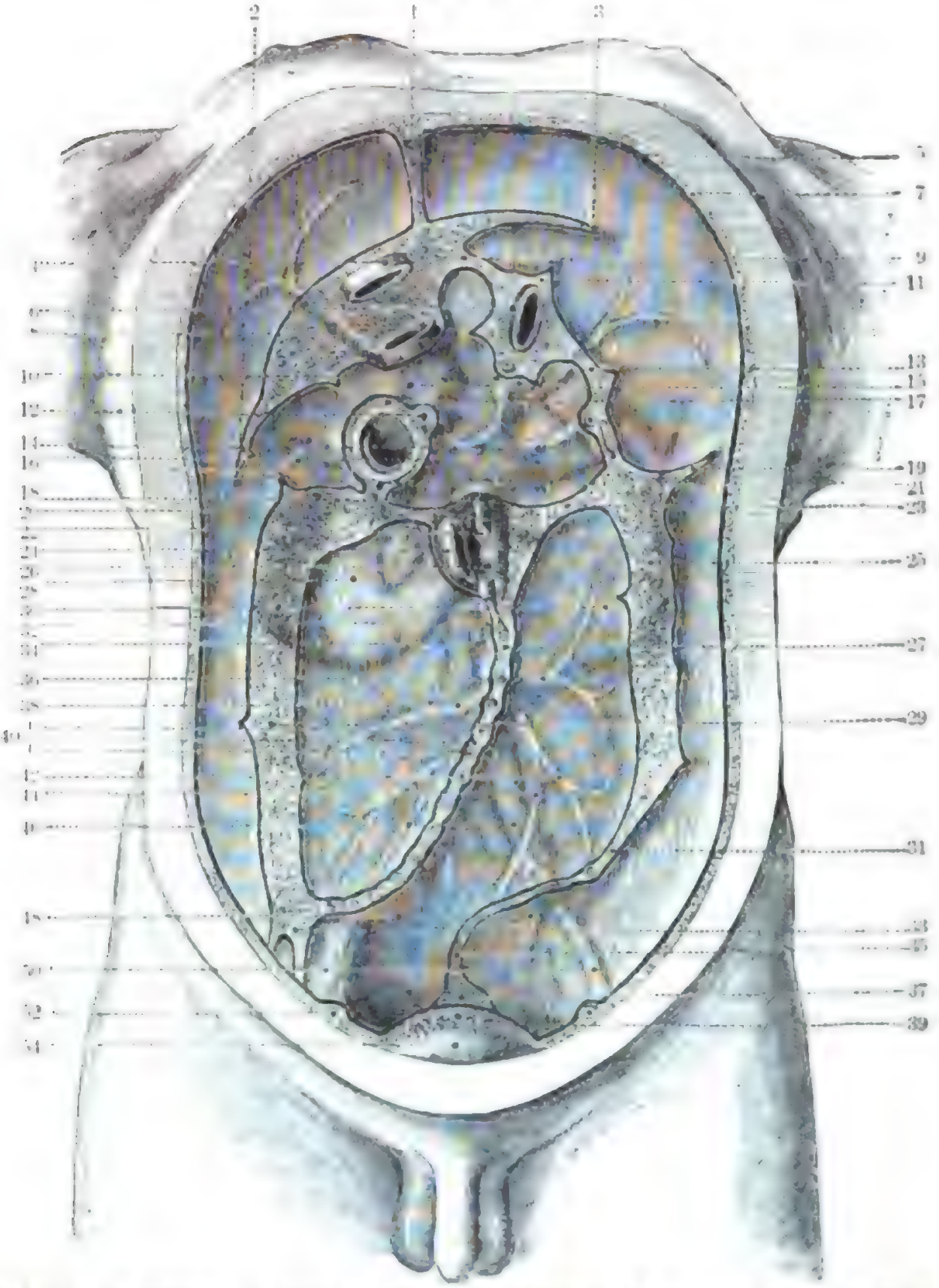

Diagram devised by Dr. Delépine to show the lines along which the Peritoneum leaves the Wall of the Abdomen to invest the Viscera: 1, falciform ligament of liver; 2, right lateral ligament of liver; 3, left lateral ligament of liver; 4, vena cava inferior; 5, peritoneum; 6, œsophagus; 7, extra-peritoneal tissue; 8, right phrenic artery; 9, diaphragmatic end of gastro-hepatic omentum; 10, coronary artery; 11, gastro-phrenic ligament; 12, hepatic artery; 13, gastro-splenic omentum; 14, splenic artery; 15, foramen of Winslow; 16, pancreas; 17, duodenum (first part); 18, inferior pancreas duodenum artery; 19, costo-colic ligament; 20, colica media; 21, dot between two anterior layers of great omentum; 22, superior mesenteric; 23, transverse mesocolon; 24, duodenum (third part); 25, bare surface for descending colon; 26, aorta; 27, the two layers of the mesentery proper; 28, duodenum (second part). 29, bare surface for ascending colon; 30, right and left kidneys; 31, sigmoid mesocolon; 32, superior mesenteric; 33, bare surface for cæcum; 34, aorta; 35, mesorectum; 36, colica sinistra; 37, bare surface for second part of rectum; 38, colica dextra; 39, left lateral false ligament of bladder; 40, vasa intestina; 42, sigmoid artery; 44, superior hemorrhoidal artery; 46, common iliac artery [right and left]; 48, internal iliac artery [right and left]; 50, external iliac artery [right and left]; 52, epigastric artery; 54, bladder.

frequently the peritoneum merely covers the anterior surface and sides of these two portions of the intestine. At the place where the transverse colon turns downward to form the descending colon a fold of peritoneum is continued upward to the under surface of the Diaphragm opposite the tenth and eleventh ribs. This is the *costo-colic ligament;* it passes below the spleen, and serves to support this organ and restrain its movements.

The *transverse mesocolon* is a broad fold which connects the transverse colon with the posterior wall of the abdomen. It is formed by the two ascending layers of the great omentum, which, after separating to surround the transverse colon, join behind it and are continued backward to the spine, where they diverge in front of the duodenum, as already mentioned. This fold contains between its layers the vessels which supply the transverse colon.

The *sigmoid mesocolon* is the fold of peritoneum which retains the sigmoid flexure in connection with the left iliac fossa.

The *mesorectum* is the narrow fold which connects the upper part of the rectum with the front of the sacrum. It contains the hemorrhoidal vessels.

The *appendices epiploicæ* are small pouches of the peritoneum filled with fat and situated along the colon and upper part of the rectum. They are chiefly appended to the transverse colon.

[It is especially important that the student notice the fact that the ascending and the descending colon, as a rule, are not covered by peritoneum posteriorly, and that the kidney lies behind the peritoneum and is not invested by it. The colon in these regions and the kidney are therefore accessible for operations without involving the peritoneum.]

THE STOMACH.

The **Stomach** is the principal organ of digestion. It is the most dilated part of the alimentary canal, serving for the solution and reduction of the food, which constitutes the process of chymification. It is situated in the left hypochondriac and epigastric regions. Its form is irregularly conical, curved upon itself, and presenting a rounded base turned to the left side. It is placed immediately behind the anterior wall of the abdomen, above the transverse colon, below the liver and the Diaphragm. Its size varies considerably in different subjects, and also according to its state of distension. When moderately full its transverse diameter is about twelve inches, its vertical diameter about four. Its weight, according to Clendenning, is about four ounces and a half. It presents for examination two extremities, two orifices, two borders, and two surfaces.

Its *left extremity* is called the *greater* or *splenic end.* This is the largest part of the stomach, and extends two or three inches to the left of the point of entrance of the œsophagus. This expanded part is called the great cul-de-sac, or *fundus.* It lies behind the lower ribs, in contact with the spleen, to which it is connected by the gastro-splenic omentum.

The *lesser* or *pyloric end* is much smaller than the fundus, and situated on a plane anterior and inferior to it. It lies in contact with the wall of the abdomen and the under surface of the liver. Its position on the surface of the body varies with the degree of distension of the organ. When the stomach is contracted and empty the pylorus lies immediately to the right of the linea alba, about two and a half or three inches below the end of the gladiolus; when it is fully distended it is moved considerably to the right and is situated near the end of the cartilage of the eighth rib.

The *œsophageal* or *cardiac orifice* communicates with the œsophagus; it is the highest part of the stomach and somewhat funnel-shaped. It is situated about an inch to the left of the sternum, behind the seventh costal cartilage of the left side.

The *pyloric orifice* communicates with the duodenum, the aperture being guarded by a kind of valve—the *pylorus.*

The *lesser curvature* extends between the œsophageal and pyloric orifices, along the upper border of the organ, and is connected to the under surface of the liver by the lesser omentum.

The *greater curvàture* extends between the same two points, along the lower border, and gives attachment to the great omentum. The surfaces of the organ are limited by these two curvatures.

The *anterior surface* is directed upward and forward, and is in relation with the Diaphragm, the under surface of the left lobe of the liver, and with the abdominal parietes in the epigastric region.

The *posterior surface* is directed downward and backward, and is in relation with the pancreas and great vessels of the abdomen, the crura of the Diaphragm, and the solar plexus.

The stomach is held in position by the lesser omentum, which extends from the transverse fissure of the liver to its lesser curvature, and by a fold of peritoneum which passes from the Diaphragm on to the œsophageal end of the stomach—the *gastro-phrenic ligament:* this constitutes the most fixed point of the stomach, whilst the pyloric end and greater curvature are the most movable parts; hence when the stomach becomes greatly distended the greater curvature is directed forward, whilst the anterior and posterior surfaces are directed, the former upward and the latter downward.[1]

Alterations in Position.—There is no organ in the body the position and connections of which present such frequent alterations as the stomach. *During inspiration* it is displaced downward by the descent of the Diaphragm, and elevated by the pressure of the abdominal muscles during expiration. Its position in relation to the surrounding viscera is also changed according to the empty or distended state of the organ. *When empty* it occupies only a small part of the left hypochondriac region, the spleen lying behind it; the left lobe of the liver covers it in front, and the under surface of the heart rests upon it above and in front, being separated from it by the left lobe of the liver, besides the Diaphragm and pericardium. This close relation between the stomach and the heart explains the fact that in gastralgia the pain is generally referred to the heart, and is often accompanied by palpitation and intermission of the pulse. *When the stomach is distended* the Diaphragm is forced upward, contracting the cavity of the chest; hence the dyspnœa complained of, from inspiration being impeded. The heart is also displaced upward; hence the oppression in this region and the palpitation experienced in extreme distension of the stomach. *Pressure from without*, as from tight-lacing, pushes the stomach down toward the pelvis. In disease also the position and connections of the organ may be greatly changed, from the accumulation of fluid in the chest or abdomen or from alteration in size of any of the surrounding viscera.

On looking into the pyloric end of the stomach the mucous membrane is found projecting inward in the front of a circular fold, the *pylorus*, leaving a narrow circular aperture, about half an inch in diameter, by which the stomach communicates with the duodenum.

---

[1] According to Dr. Lesshaft, the professor of anatomy at St. Petersburg, the statements current in anatomical textbooks regarding the normal position of the stomach are erroneous. He has made careful observations on the point in more than twelve hundred bodies, and has arrived at the following conclusions: The stomach does not, as is usually asserted, lie horizontally in the abdominal cavity, but vertically, so that the fundus touches the Diaphragm; the smaller curvature and pylorus are to the right, and the larger curvature is to the left. Its position is in the left hypochondrium, and the situation of the pylorus is in the vertical line formed by a continuation of the right margin of the sternum. If the stomach is enlarged, no one part can be alone displaced, but all parts are equally moved by the distension. The arrangement of the muscular fibres of the stomach is such that food entering it is moved toward the pylorus, where it can be most thoroughly mixed with the gastric juices; and it then passes back along the centre of the cavity to the fundus, where the resistance is least. This movement of the food along the wall to the pylorus and back again along the centre is rendered possible by the form of the organ, and it is probable that it is to this movement that the peculiar shape of the fundus is due. As is well known, the fundus is absent in newly-born children. Thus the shape of the stomach determines the long retention of food in the organ for the purposes of digestion, and its slow passage through the pylorus. If the transverse colon is distended with gas, it may rise to the left of the stomach as high as the fourth intercostal space, and even as high as the fourth rib. If the coils of the small intestine are similarly distended, the lower part of the stomach may be pressed forward and the stomach may assume a more oblique position. Even a large stomach, accustomed to dietetic repletion, maintains a vertical position, but the pylorus is moved a little upward and to the right (*Lancet*, March 11, 1882, p. 406).

On the subject of the position of the stomach the student may refer to a discussion at the International Congress [London, 1881], in which Dr. Lesshaft enunciated this same view. The general opinion of the anatomists present appeared to be that the main axis of the stomach was placed obliquely, and was therefore opposed to Dr. Lesshaft's views.

The *pylorus* is formed by a reduplication of the mucous membrane of the stomach, containing numerous muscular fibres, which are aggregated into a thick circular ring, the longitudinal fibres and serous membrane being continued over the fold without assisting in its formation. The aperture is occasionally oval. Sometimes the circular fold is replaced by two crescentic folds placed one above and the other below the pyloric orifice; and more rarely there is only one crescentic fold.

Structure.—The stomach consists of four coats—a serous, a muscular, an areolar, and a mucous coat—together with vessels and nerves.

The *serous coat* is derived from the peritoneum, and covers the entire surface of the organ, excepting along the greater and lesser curvatures at the points of attachment of the greater and lesser omenta; here the two layers of peritoneum leave a small triangular space, along which the nutrient vessels and nerves pass.

Fig. 572.

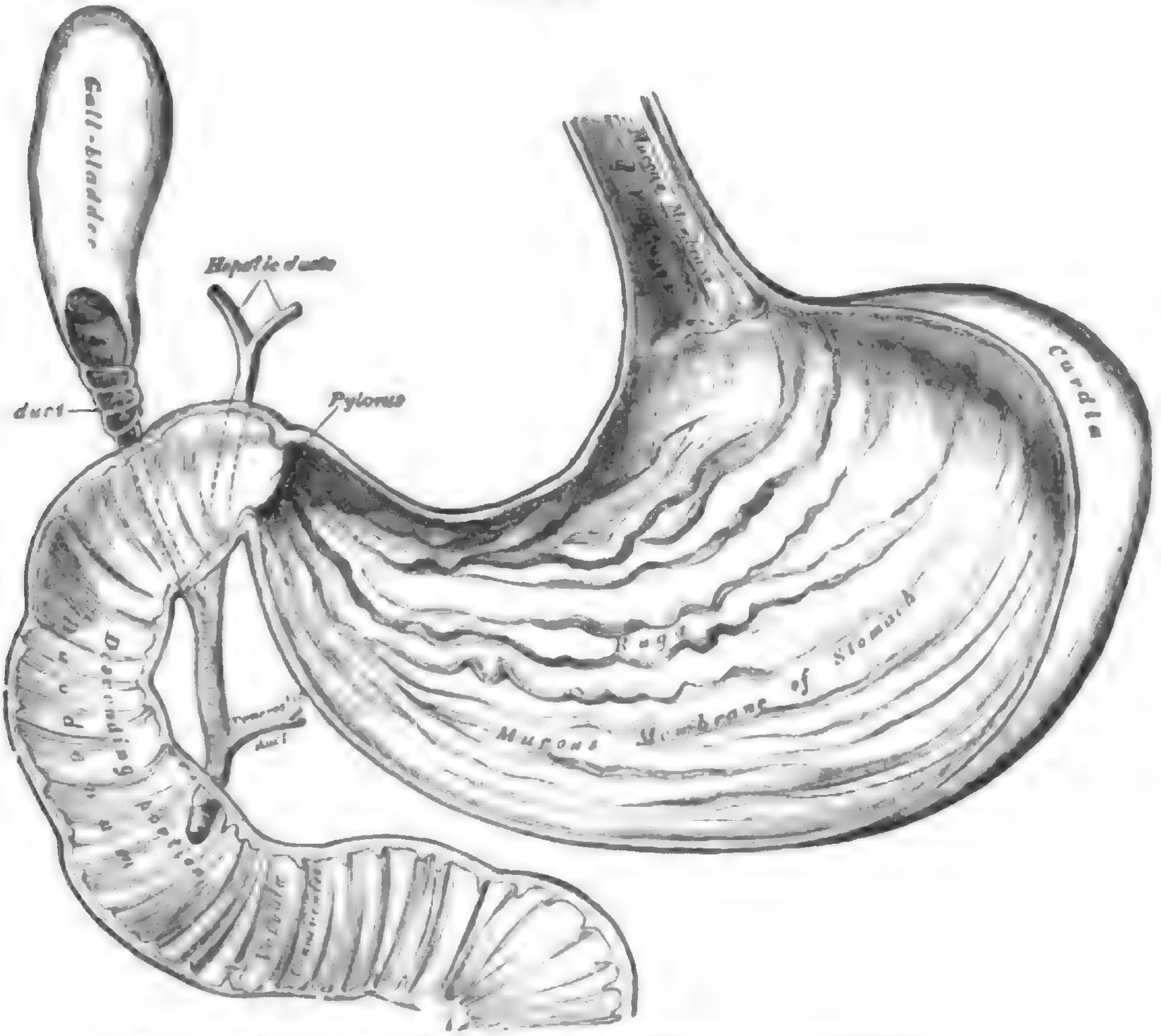

The Mucous Membrane of the Stomach and Duodenum, with the Bile-ducts.

The *muscular coat* (Fig. 573) is situated immediately beneath the serous covering. It consists of three sets of fibres—longitudinal, circular, and oblique.

The *longitudinal fibres* are most superficial; they are continuous with the longitudinal fibres of the œsophagus, radiating in a stellate manner from the cardiac orifice. They are most distinct along the curvatures, especially the lesser, but are very thinly distributed over the surfaces. At the pyloric end they are more thickly distributed, and continuous with the longitudinal fibres of the small intestine.

The *circular fibres* form a uniform layer over the whole extent of the stomach beneath the longitudinal fibres. At the pylorus they are most abundant, and are aggregated into a circular ring, which projects into the cavity, and forms, with the fold of mucous membrane covering its surface, the pyloric valve.

The *oblique fibres* are limited chiefly to the cardiac end of the stomach, where they are disposed as a thick uniform layer covering both surfaces, some passing obliquely from left to right, others from right to left, round the cardiac orifice. They are continuous with the circular fibres of the œsophagus.

The *areolar coat* consists of a loose, filamentous, areolar tissue connecting the mucous and muscular layers. It is sometimes called the *submucous coat.* It supports the blood-vessels previous to their distribution to the mucous membrane: hence it is sometimes called the *vascular coat.*

Fig. 573.

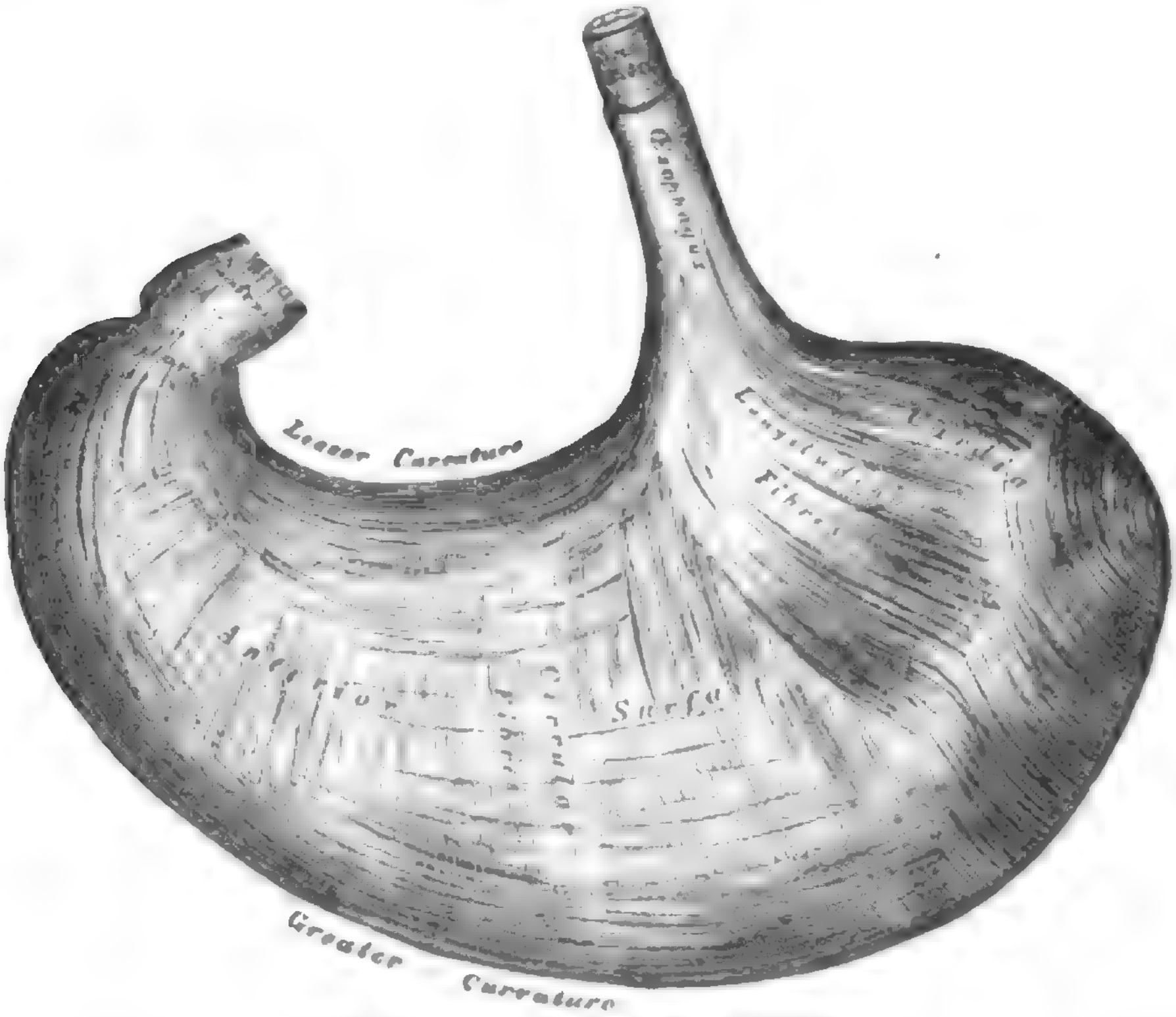

The Muscular Coat of the Stomach.

The *mucous membrane* is thick, its surface smooth, soft, and velvety. In the fresh state it is of a pinkish tinge at the pyloric end, and of a red or red-brown color over the rest of its surface. In infancy it is of a brighter hue, the vascular redness being more marked. It is thin at the cardiac extremity, but thicker toward the pylorus. During the contracted state of the organ it is thrown into numerous plaits or rugæ, which for the most part have a longitudinal direction, and are most marked toward the lesser end of the stomach and along the greater curvature (Fig. 572). These folds are entirely obliterated when the organ becomes distended.

Structure of the Mucous Membrane (Fig. 574).—When examined with a lens the inner surface of the mucous membrane presents a peculiar honeycomb appearance, from being covered with small shallow depressions or alveoli of a polygonal or hexagonal form, which vary from $\frac{1}{100}$ to $\frac{1}{200}$ of an inch in diameter and are separated by slightly elevated ridges. In the bottom of the alveoli are seen the orifices of minute tubes, the *gastric follicles*, which are situated perpendicularly side by side in the entire substance of the mucous membrane.

The gastric follicles are of two kinds, which differ from each other in structure, and it is believed also in the nature of their secretion. They are named respectively *pyloric* and *peptic* glands. They are both tubular in character and are formed of a delicate basement membrane, supporting epithelium. The basement membrane consists of flattened transparent epithelial cells, with processes which extend and support the epithelium. The *pyloric* glands are most numerous at the pyloric end of the stomach, and from this fact have received their name. They were formerly termed mucus-glands, and were supposed to secrete mucus; but, as Klein points out, "the cells are serous, not mucous, and the secretion of the glands cannot therefore be mucus." They consist of two or three short closed tubes opening into a common duct, the external orifice of which is situated at the bottom of an alveolus. The cæcal tubes are wavy, and are of about equal length with the duct. The tubes and duct are lined throughout with epithelium, the duct being lined by columnar cells continuous with the epithelium lining the surface of the mucous membrane of the stomach, the tubes with shorter and more cubical cells, which are finely granular. The *peptic* glands are found all over the surface of the stomach. Like the pyloric glands, they consist of a duct, into which open two or more cæcal tubes. The duct, however, in these glands is shorter than in the other variety, sometimes not amounting to more than one-sixth of the whole length of the gland; it is lined throughout by columnar epithelium. At the point where the terminal tubes open into the duct, and which is termed the neck, the epithelium alters, the cells becoming much shorter and opaque: the lumen also becomes suddenly constricted, and is continued down to the bottom of the tubes as a very fine channel. Here also are found, between the epithelium and the basement membrane, large spheroidal, coarsely granular cells which have been termed *peptic cells*, and which produce an outward bulging of the basement membrane. They are seen throughout the remainder of the tube at intervals, and give it a beaded or varicose appearance. Below the neck the terminal tubes, in addition to these isolated spheroidal cells, are occupied with finely granular, angular cells (columnar, Klein), leaving only a small channel in the centre. They are continuous with the short columnar cells of the neck, and are termed the *central* or *chief* cells, because they are believed to be principally concerned in the secretion of the gastric juice. The peptic cells, which were formerly supposed to possess this office, are now termed *parietal* cells. Between the glands the mucous membrane consists of a connective-tissue framework with lymphoid tissue. In places this latter tissue, especially in early life, is collected into little masses, which to a certain extent resemble the solitary glands of the intestine, and are by some termed the *lenticular* glands of the stomach. They are

FIG. 574.

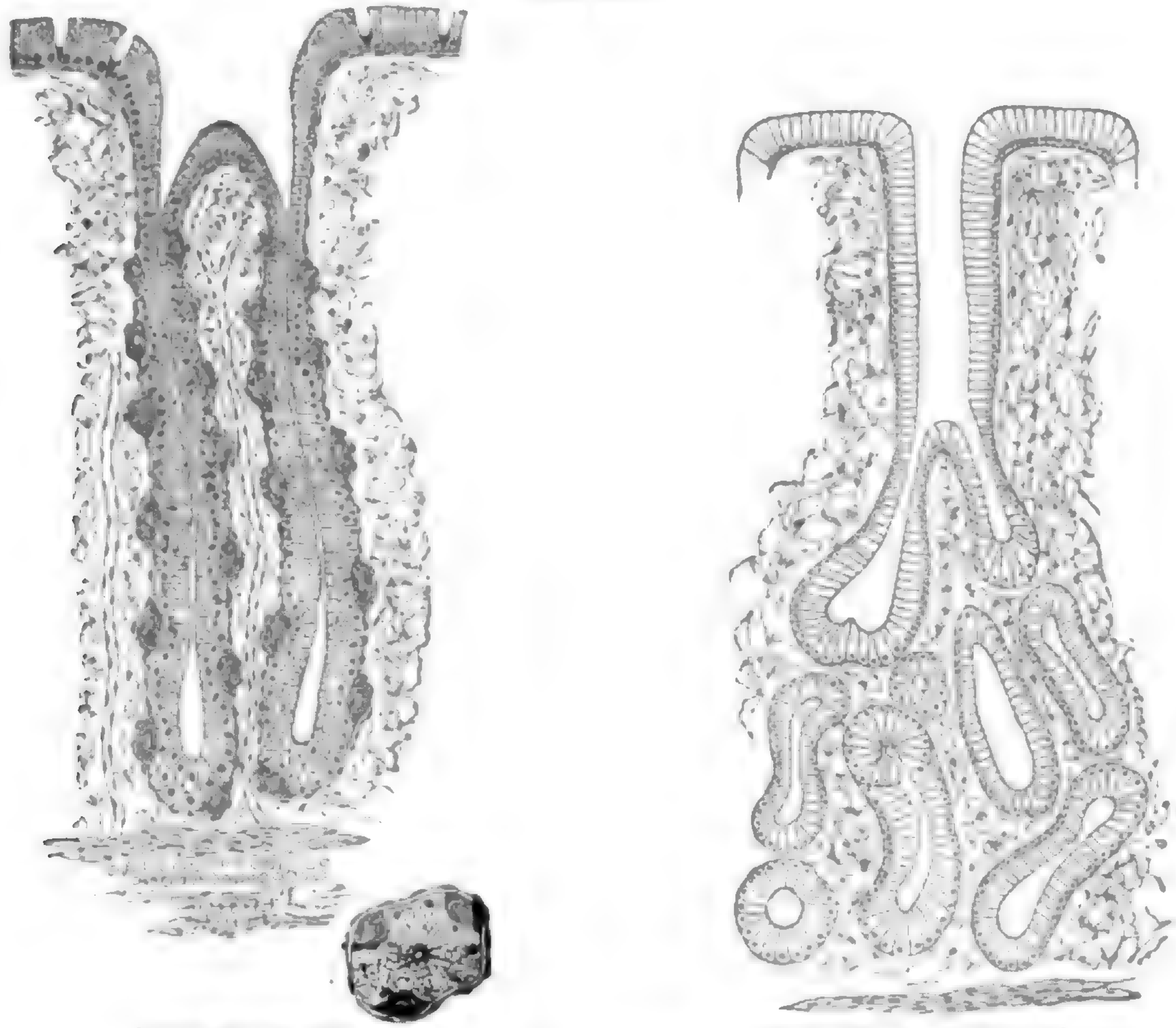

Peptic Gastric Gland. Pyloric Glands of Stomach.

Minute Anatomy of Mucous Membrane of Stomach.

not, however, so distinctly circumscribed as the solitary glands. The epithelium lining the mucous membrane of the stomach and its alveoli is of the columnar variety. Beneath the mucous membrane, and between it and the submucous coat, is a thin stratum of involuntary muscular fibre (muscularis mucosæ), which in some parts consists only of a single longitudinal layer; in others of two layers—an inner circular and an outer longitudinal.

VESSELS AND NERVES.—The arteries supplying the stomach are the gastric, the pyloric and right gastro-epiploic branches of the hepatic, the left gastro-epiploic and vasa brevia from the splenic. They supply the muscular coat, ramify in the submucous coat, and are finally distributed to the mucous membrane. The arrangement of the vessels in the mucous membrane is somewhat peculiar. The arteries break up at the base of the gastric tubules into a plexus of fine capillaries, which run upward between the tubules, anastomosing with each other and ending in a plexus of larger capillaries, which surround the mouths of the tubes and also form hexagonal meshes around the alveoli. From these latter the *veins* arise, and pursue a straight course back to the submucous tissue between the tubules, to terminate in the splenic and superior mesenteric veins and directly in the portal vein. The *lymphatics* are numerous: they consist of a superficial and deep set, which pass through the lymphatic glands found along the two curvatures of the organ. The *nerves* are the terminal branches of the right and left pneumogastric, the former being distributed upon the back, and the latter upon the front part of the organ. A great number of branches from the sympathetic also supply the organ.

THE SMALL INTESTINE.

The small intestine is that part of the alimentary canal in which the chyme is mixed with the bile, the pancreatic juice, and the secretions of the various glands imbedded in the mucous membrane of the intestine, and where the separation of the nutritive principle of the food, the chyle, is effected; this constitutes chylification.

The small intestine is a convoluted tube about twenty feet in length,[1] which gradually diminishes in size from its commencement to its termination. It is contained in the central and lower parts of the abdominal and pelvic cavities, surrounded above and at the sides by the large intestine; in relation in front with the great omentum and abdominal parietes; and connected to the spine by a fold of peritoneum, the mesentery. The small intestine is divisible into three portions—the duodenum, the jejunum, and the ileum.

The **Duodenum** has received its name from being about equal in length to the breadth of twelve fingers (eight or ten inches). It is the shortest, the widest, and the most fixed part of the small intestine; it has no mesentery, and is only partially covered by the peritoneum. Its course presents a remarkable curve, somewhat like a horseshoe in form, the convexity being directed toward the right and the concavity to the left, embracing the head of the pancreas. Commencing at the pylorus, it ascends obliquely upward, backward, and to the right, to the under surface of the liver; it then descends in front of the right kidney, and passes nearly transversely across the front of the spine, terminating in the jejunum on the left side of the second lumbar vertebra. Hence the duodenum has been divided into three portions—ascending, descending, and transverse.

The first or *ascending portion* (Fig. 575), about two inches in length, is free, movable, and nearly completely invested by the peritoneum, which forms the lesser omentum. It is in relation above and in front with the liver and neck of the gall-bladder; behind with the vessels which run between the layers of the lesser omentum—viz. the hepatic artery and duct and vena portæ. This portion of the intestine is usually found after death stained with bile, especially on its anterior surface.

---

[1] Treves states that in one hundred cases the average length of the small intestine in the adult male was 22 feet 6 inches, and in the adult female 23 feet 4 inches, but that it varies very much, the extremes in the male being 31 feet 10 inches in one case and 15 feet 6 inches in another—a difference of over 15 feet. He states that he has convinced himself that the length of the bowel is independent in the adult of age, height, and weight. [At birth he says the intestine is 9 feet 5 inches in length, and that during the first two months it grows about four feet in length. This should teach the special need of suitable diet and the danger of intestinal diseases during this early period of life.]

The second or *descending portion*, about three inches in length, is firmly fixed by the peritoneum and pancreas. It passes from the neck of the gall-bladder vertically downward, in front of the right kidney, as far as the third lumbar vertebra. It is covered by peritoneum only on its anterior surface. It is in relation in front with the right arch of the colon and the mesocolon; behind with the front of the right kidney; at its inner side is the head of the pancreas and the ductus communis choledochus. The common bile-duct and the pancreatic duct perforate the inner side of this portion of the intestine obliquely a little below its middle.

Fig. 575.

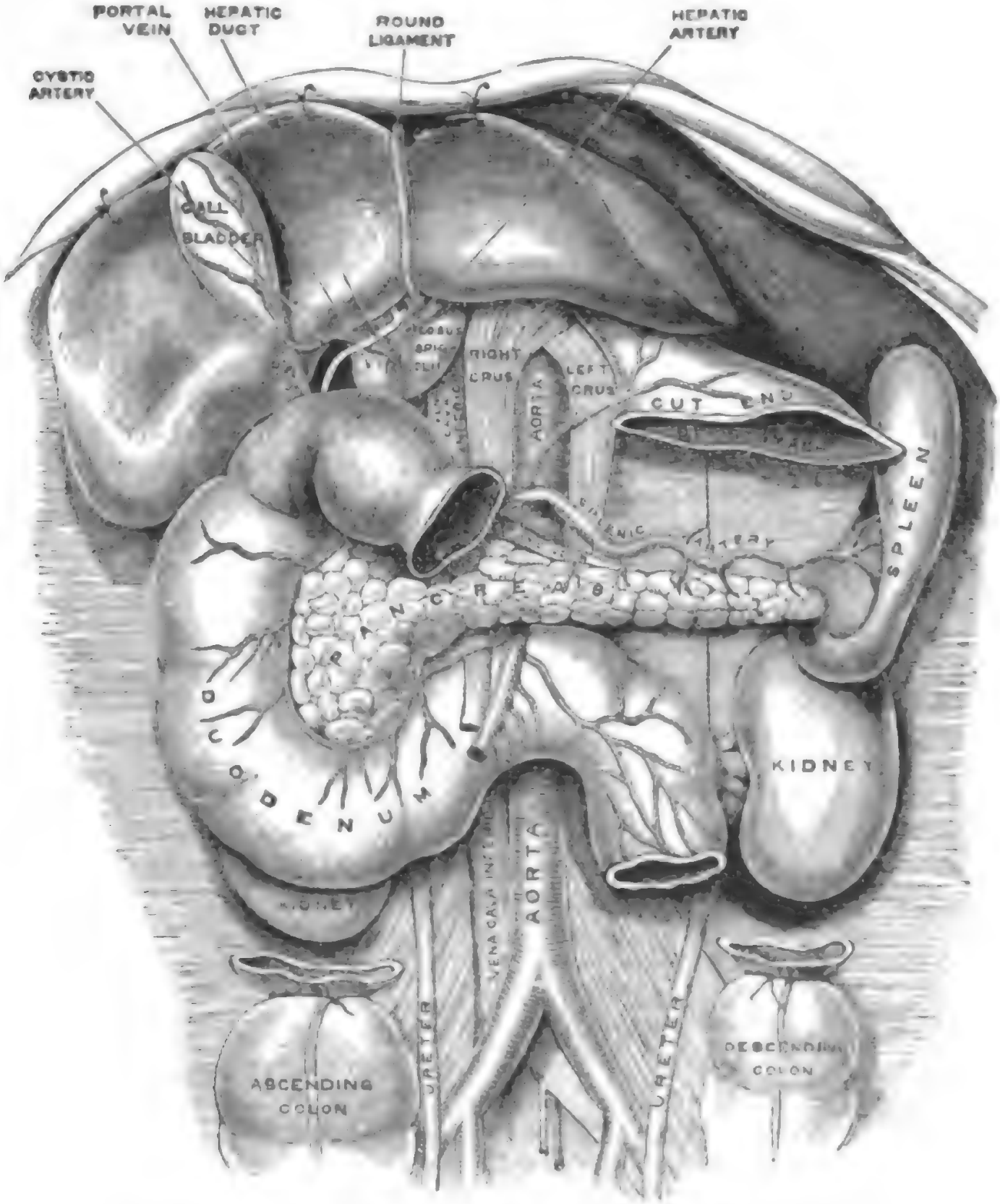
PORTAL VEIN
HEPATIC DUCT
ROUND LIGAMENT
HEPATIC ARTERY
CYSTIC ARTERY
GALL BLADDER
LOBUS SPIGELII
RIGHT CRUS
LEFT CRUS
AORTA
CUT END
SPLEEN
SPLENIC ARTERY
PANCREAS
DUODENUM
KIDNEY
KIDNEY
VENA CAVA INFERIOR
AORTA
URETER
URETER
ASCENDING COLON
DESCENDING COLON

Relations of the Duodenum (a portion of the stomach has been cut away).

The third or *transverse portion*, the longest and narrowest part of the duodenum, passes across the front of the spine, ascending from the third to the second lumbar vertebra, and terminating in the jejunum on the left side of that bone. In front, though at some distance from it, is the descending layer of the transverse mesocolon, or the divergence of the two layers of that structure, and it is crossed by the superior mesenteric vessels; behind it rests upon the aorta, the vena cava, and the crura of the Diaphragm; above it is the lower border of the pancreas, the superior mesenteric vessels passing forward between the two.[1]

VESSELS AND NERVES.—The *arteries* supplying the duodenum are the pyloric and pancreatico-duodenal branches of the hepatic and the inferior pancreatico-duodenal branch of the superior mesenteric. The *veins* terminate in the splenic and superior mesenteric. The *nerves* are derived from the solar plexus.

The **Jejunum** (*jejunus*, empty), so called from being usually found empty after death, includes the upper two-fifths of the rest of the small intestine. It commences at the duodenum on the left side of the second lumbar vertebra, and terminates in the ileum, its convolutions being chiefly confined to the umbilical and left iliac regions. The jejunum is wider, its coats thicker, more vascular, and of a deeper color than those of the ileum; but there is no characteristic mark to distinguish the termination of the one and the commencement of the other.

The **Ileum** (*εἰλεῖν*, to twist), so called from its numerous coils or convolutions, includes the remaining three-fifths of the small intestine. It occupies chiefly the umbilical, hypogastric, right iliac, and occasionally the pelvic regions, and terminates in the right iliac fossa by opening into the inner side of the commencement of the large intestine. The ileum is narrower, its coats thinner and less vascular, than those of the jejunum, a given length of it weighing less than the same length of the jejunum.

[FIG. 576.

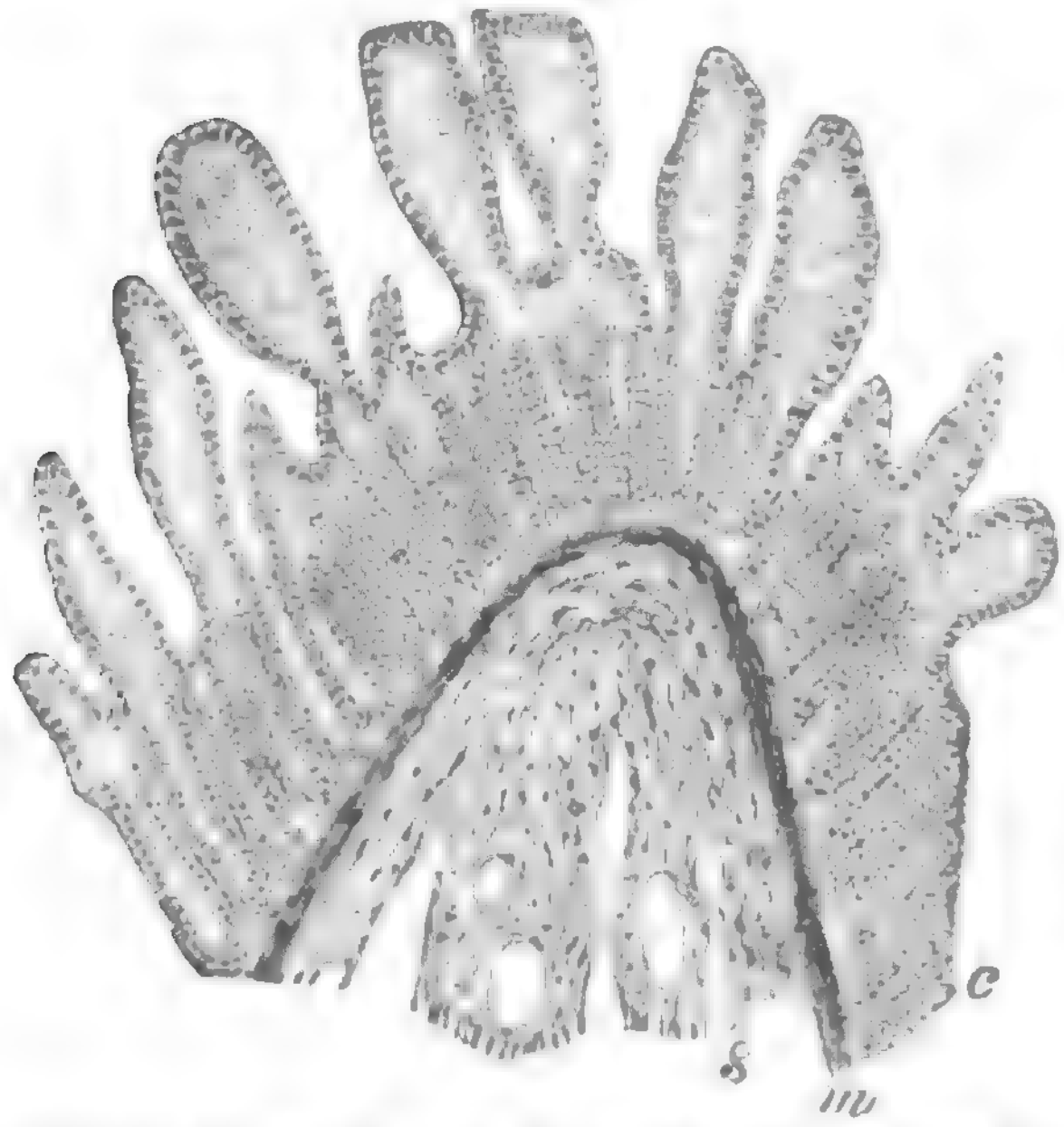

From a Vertical Section through a Fold of the Mucous Membrane of the Jejunum of a Dog: *c*, the mucosa, containing the crypts of Lieberkühn, and projecting as the villi; *m*, muscularis mucosæ; *s*, submucosa (Allen).]

Structure.—The wall of the small intestine is composed of four coats—serous, muscular, areolar, and mucous.

The *serous coat* is derived from the peritoneum. The first or ascending portion of the duodenum is almost completely surrounded by that membrane; the second or descending portion is covered by it only in front; and the third or transverse portion lies behind the descending layer of the transverse mesocolon, by which it is covered in front. The remaining portion of the small intestine is surrounded by the peritoneum, excepting along its attached or mesenteric border; here a space is left for the vessels and nerves to pass to the gut.

The *muscular coat* consists of two layers of fibres—an external or longitudinal, and an internal or circular layer. The *longitudinal* fibres are thinly scattered over the surface of the intestine, and are more distinct along its free border. The *circular* fibres form a thick, uniform layer; they surround the cylinder of the intestine in the greater part of its circumference, but do not form complete rings. The muscular coat is thicker at the upper than at the lower part of the small intestine.

The *areolar* or *submucous coat* connects together the mucous and muscular layers. It consists of loose, filamentous, areolar tissue which forms a nidus for the subdivision of the nutrient vessels previous to their distribution to the mucous surface.

---

[1] Dr. Bruce Young states that this description of the duodenum, which is the one usually adopted in our anatomical textbooks, is incorrect, as it makes no mention of a fourth or terminal vertical portion. If the point of junction of the jejunum and duodenum be considered to correspond to the spot where the gut receives a complete investment of peritoneum, then there is a fairly constant portion, about an inch in length, which ascends from the point where the duodenum is usually said to terminate, on the left side of the vertebral column, and which must be regarded as a fourth part of the duodenum. This portion is fixed in this position by a band which extends upward from it, obliquely across the aorta to the connective tissue around the cœliac axis and the left crus of the Diaphragm, and is termed the *musculus suspensorius duodeni*, from possessing, according to Trietz, plain muscular fibres mixed up with the fibrous tissue of which it is principally made up.

The *mucous membrane* is thick and highly vascular at the upper part of the small intestine, but somewhat paler and thinner below. It consists of the following structures: next the cellular or submucous coat is a layer of unstriped muscular fibre, the *muscularis mucosæ* (Fig. 576, *m*); internal to this is a quantity of retiform tissue, enclosing in its meshes lymph-corpuscles, and in which the blood-vessels and nerves ramify; lastly, a basement membrane, supporting a single layer of epithelial cells, which throughout the intestines are columnar in character. They are granular in appearance and possess a clear oval nucleus. At their superficial or unattached end they present a distinct layer of highly refracting material marked by vertical striæ, which were formerly believed to be minute channels, by which the chyle was taken up into the interior of the cell and by them transferred to the lacteal vessels of the mucous membrane.

The mucous membrane presents for examination the following structures contained within it or belonging to it:

Valvulæ conniventes.
Villi.

Glands.
- Simple follicles.
- Duodenal glands.
- Solitary glands.
- Agminate or Peyer's glands.

The **Valvulæ Conniventes** (valves of Kerkring) are reduplications or foldings of the mucous membrane and submucous tissue. Unlike the folds in the stomach, they are permanent, and are not obliterated when the intestine is distended. They extend transversely across the cylinder of the intestine for about one-half or two-thirds of its circumference. The larger folds are about two inches in length and one-third of an inch in depth at their broadest part, but the greater number are of smaller size. The larger and smaller folds alternate with each other. They are not found at the commencement of the duodenum, but begin to appear about one or two inches beyond the pylorus. In the lower part of the descending portion, below the point where the common choledic and pancreatic ducts enter the intestine, they are very large and closely approximated. In the transverse portion of the duodenum and upper half of the jejunum they are large and numerous; and from this point, down to the middle of the ileum, they diminish considerably in size. In the lower part of the ileum they almost entirely disappear; hence the comparative thinness of this portion of the intestine as compared with the duodenum and jejunum. The valvulæ conniventes retard the passage of the food along the intestines and afford a more extensive surface for absorption.

The **Villi** are minute, highly vascular processes projecting from the mucous membrane of the small intestine throughout its whole extent, and giving to its surface a velvety appearance. In shape some are triangular and laminated, others conical or cylindrical with clubbed or filiform extremities. They are largest and most numerous in the duodenum and jejunum, and become fewer and smaller in the ileum. Krause estimates their number in the upper part of the small intestine at from fifty to ninety in a square line, and in the lower part from forty to seventy, the total number for the whole length of the intestine being about four millions.

The structure of the villi has been studied recently by many eminent anatomists. We shall here follow the description of Dr. Watney,[1] whose researches have a most important bearing on the physiology of that which is the peculiar function of this part of the intestine, the absorption of fat.

The essential parts of a villus are the lacteal vessel, the blood-vessels, the epithelium, the basement membrane, and muscular tissue of the mucosa, these structures being supported and held together by retiform lymphoid tissue.

These structures are arranged in the following manner: Situated in the centre of the villus is the lacteal, terminating near the summit in a blind extremity; running along this vessel are unstriped muscular fibres; surrounding it is a plexus of capillary vessels, the whole being enclosed by a basement membrane supporting columnar epithelium. Those structures which are contained within the basement membrane—namely, the lacteal, the muscular tissue, and the blood-vessels—are surrounded and enclosed by a delicate reticulum which forms the matrix of the villus, and in the meshes of which are found large flattened cells with an oval nucleus, and in smaller numbers lymph-corpuscles. These latter are to be distinguished from the larger cells of the villus by their behavior with reagents, by their size, and by the shape of their nucleus, which is spherical. Transitional forms, however, of all kinds are met with between the lymph-corpuscle and the proper cells or the villus.

---

[1] *Phil. Trans.*, vol. clxvi. Pt. 2.

The *lacteals* are in some cases double, and in some animals multiple. Situated in the axis of the villi, they commence by dilated cæcal extremities near to, but not quite at, the summit of the villus. The walls are composed of a single layer of endothelial cells, the interstitial substance between the cells being continuous with the reticulum of the matrix.

The *muscular fibres* are derived from the muscularis mucosæ, and are arranged in bundles around the lacteal vessel, extending from the base to the summit of the villus, and giving off laterally individual muscle-cells, which are enclosed by the reticulum, and by it are attached to the basement membrane.

FIG. 577.

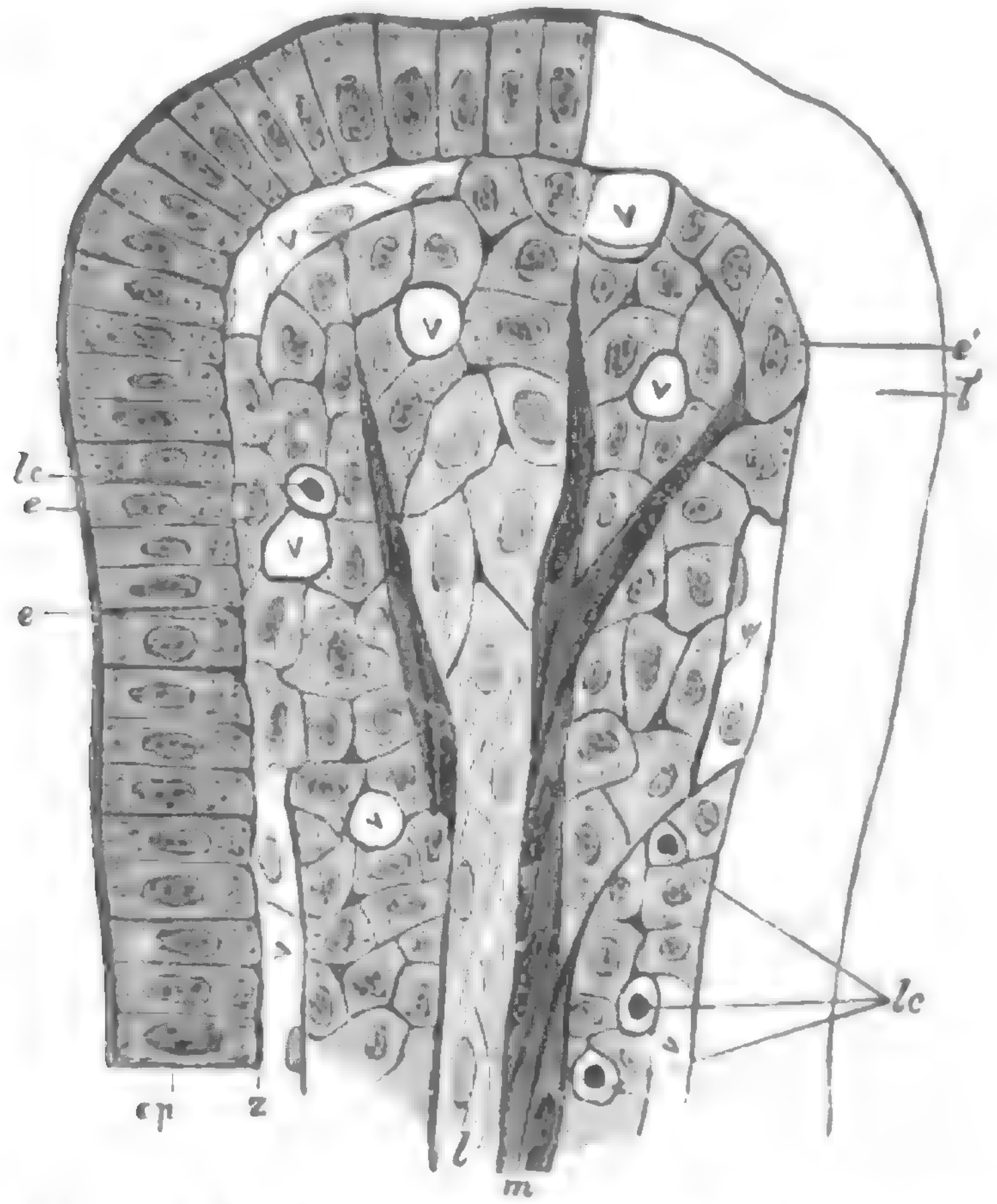

Diagrammatic Section of a Villus: *ep*, epithelium only partially shaded in; *l*, central chyle-vessel; the cells forming the vessel have been less shaded to distinguish them from the cells of the parenchyma of the villus; *m* muscle-fibres running up by the side of the chyle-vessel: it will be noticed that each muscle-fibre is surrounded by the reticulum, and by this reticulum the muscles are attached to the cells forming the membrana propria, as at *e'*, or to the reticulum of the villus; *lc*, lymph-corpuscles, marked by a spherical nucleus and a clear zone of protoplasm; *l'*, upper limit of the chyle-vessel; *e, e, e'*, cells forming the membrana propria: it will be seen that there is hardly any difference between the cells of the parenchyma, the endothelium of the *upper* part of the chyle-vessel, and the cells of the membrana propria; V, blood-vessels; *z*, dark line at the base of the epithelium formed by the reticulum. It will be seen that the reticulum penetrates between all the other elements of the villus: the reticulum contains thickenings or "nodal points." The diagram shows that the cells of the upper part of the villus are larger and contain a larger zone of protoplasm than those of the lower part. The cells of the upper part of the chyle-vessel differ somewhat from those of the lower part, in that they more nearly resemble the cells of the parenchyma.

The *blood-vessels* form a plexus between the lacteal and the basement membranes, and are enclosed in the reticular tissue; in the interstices of the capillary plexus which they form are contained the cells of the villus.

These structures are surrounded by the basement membrane, which is made up of a stratum of endothelial cells and upon which is placed a layer of columnar epithelium. The reticulum of the matrix is continuous through the basement membrane (that is, through the interstitial substance between the individual endothelial cells) with the interstitial cement substance of the columnar cells of the surface of the villus. Thus we are enabled to trace a direct continuity between the interior of the lacteal and the surface of the villus by means of the reticular tissue: and it is along this path that, according to Dr. Watney, the chyle passes in the process of absorption by the villi. That is to say, it passes through the interstitial substance between the epithelium cells, through the interstitial substance of the basement membrane, the reticulum of the matrix and the interstitial substance between the endothelial plates of the lacteal,—all which structures have been shown to be continuous with one another, and, being probably semifluid, do not offer any obstacle to the passage of the molecular basis of the chyle.

All these points are illustrated by the accompanying diagram by Dr. Watney (Fig. 577), for which I have to express my best thanks to him; and a comparison with Fig. 578 will show the chief points in which the new differs from the old description.

FIG. 578.

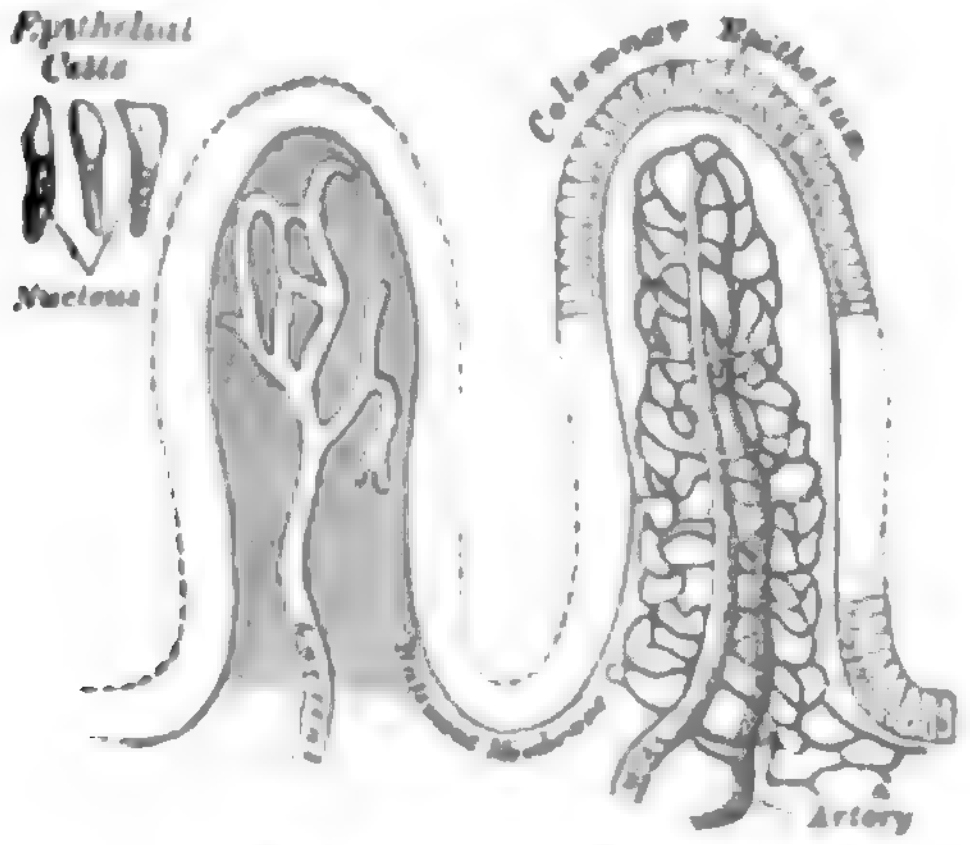

Two Villi (magnified).

FIG. 579.



Transverse Section of Crypts of Lieberkühn (Klein and Noble Smith).

The **Simple Follicles,** or *crypts of Lieberkühn* (Fig. 580), are found in considerable numbers over every part of the mucous membrane of the small intestine. They consist of minute tubular depressions of the mucous membrane arranged perpendicularly to the surface, upon which they open by small circular apertures. They may be seen with the aid of a lens, their orifices appearing as minute dots scattered between the villi. Their walls are thin, consisting of a layer of basement membrane (which is, in fact, an endothelial membrane), lined by columnar epithelium, and covered on their exterior by capillary vessels.

FIG. 580.



Longitudinal Section of Crypts of Lieberkuhn—goblet-cells seen among the columnar epithelial cells (Klein and Noble Smith).

The **Duodenal,** or **Brunner's Glands,** are limited to the duodenum and commencement of the jejunum. They are small, flattened, granular bodies imbedded in the submucous areolar tissue, and open upon the surface of the mucous membrane by minute excretory ducts. They are most numerous and largest near the pylorus. They may be compared to the elementary lobules of a salivary gland spread out over a broad surface instead of being collected in a mass. They consist of a number of tubular alveoli, lined by epithelium and opening by a single duct on the inner surface of the intestine.

FIG. 581.

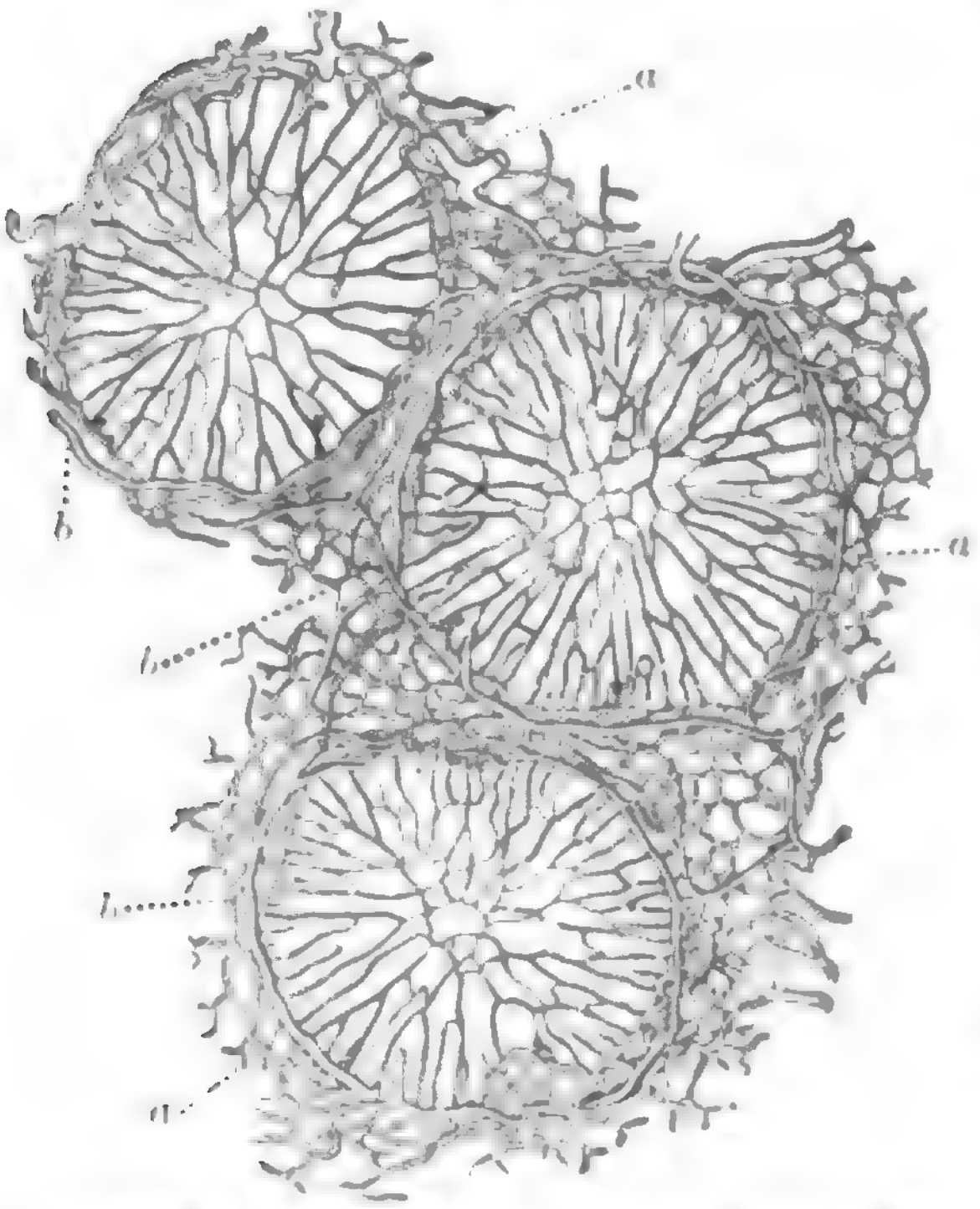

Transverse Section through the equatorial plane of three of Peyer's Follicles, from the Rabbit: *a*, capillary network; *b*, large circular vessels.

The **Solitary Glands** (*glandulæ solitariæ*) are found scattered throughout the mucous membrane of the small intestine, but are most numerous in the lower part of the ileum. They are small, round, whitish bodies, from half a line to a line in diameter. Their free surface is covered with villi, and each gland is surrounded by the openings of the follicles of Lieberkühn. They are now recognized as lymph-follicles, and consist of a dense interlacing retiform tissue, closely packed with lymph-corpuscles and permeated with an abundant capillary network (Fig. 581). The interspaces of the retiform tissue are continuous with larger lymph-spaces at the base of the gland through which they communicate with the lacteal system. They are situated partly in the submucous tissue, partly in the mucous membrane, where they form slight projections of its epithelial layer after having penetrated the muscularis mucosæ. The villi which are situated on them are generally absent from the very summit (or "cupola," as Frey calls it) of the gland.

Peyer's Glands [or **Patches**] (Figs. 581–584) may be regarded as aggregations of solitary glands, forming circular or oval patches from twenty to thirty in number, and varying in length from half an inch to four inches. They are largest and most numerous in the ileum. [Hence the tenderness in the right iliac fossa in typhoid fever, in which these patches are inflamed and ulcerated.] In the lower part of the jejunum

FIG. 582.

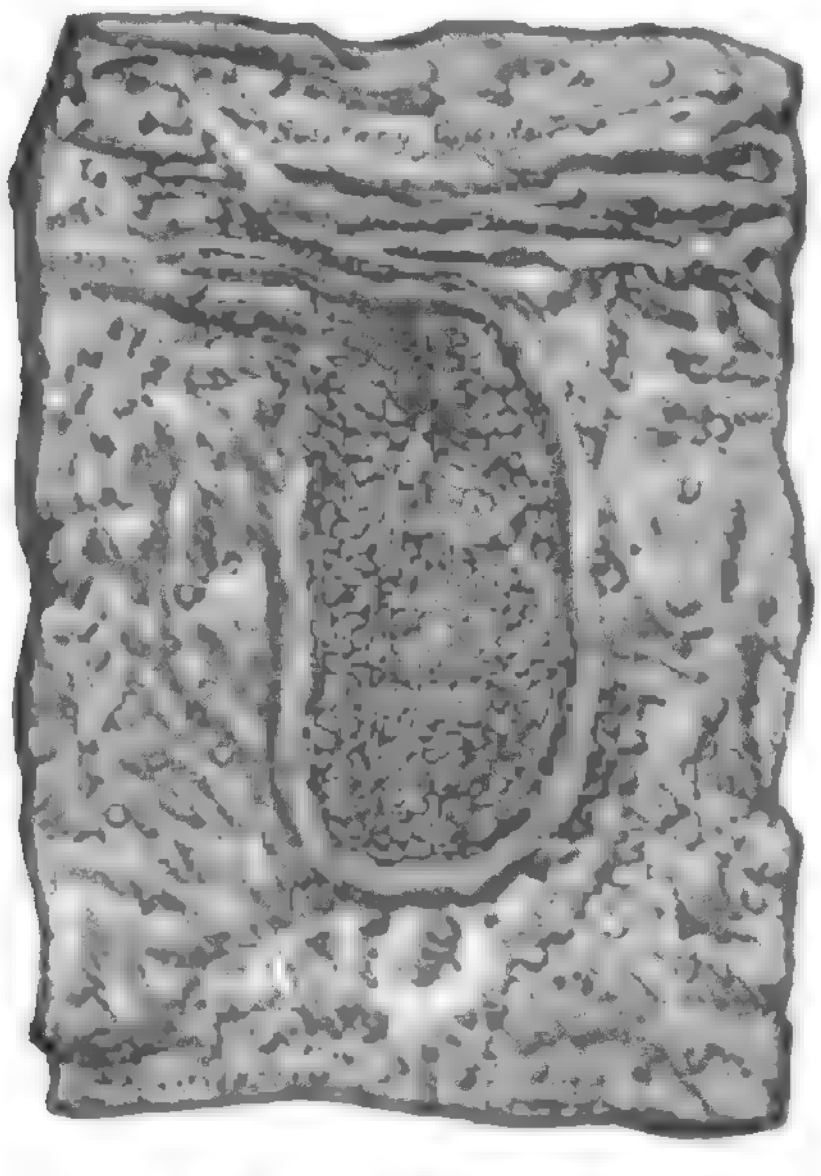

Patch of Peyer's Glands, from the lower part of the ileum.

FIG. 583.

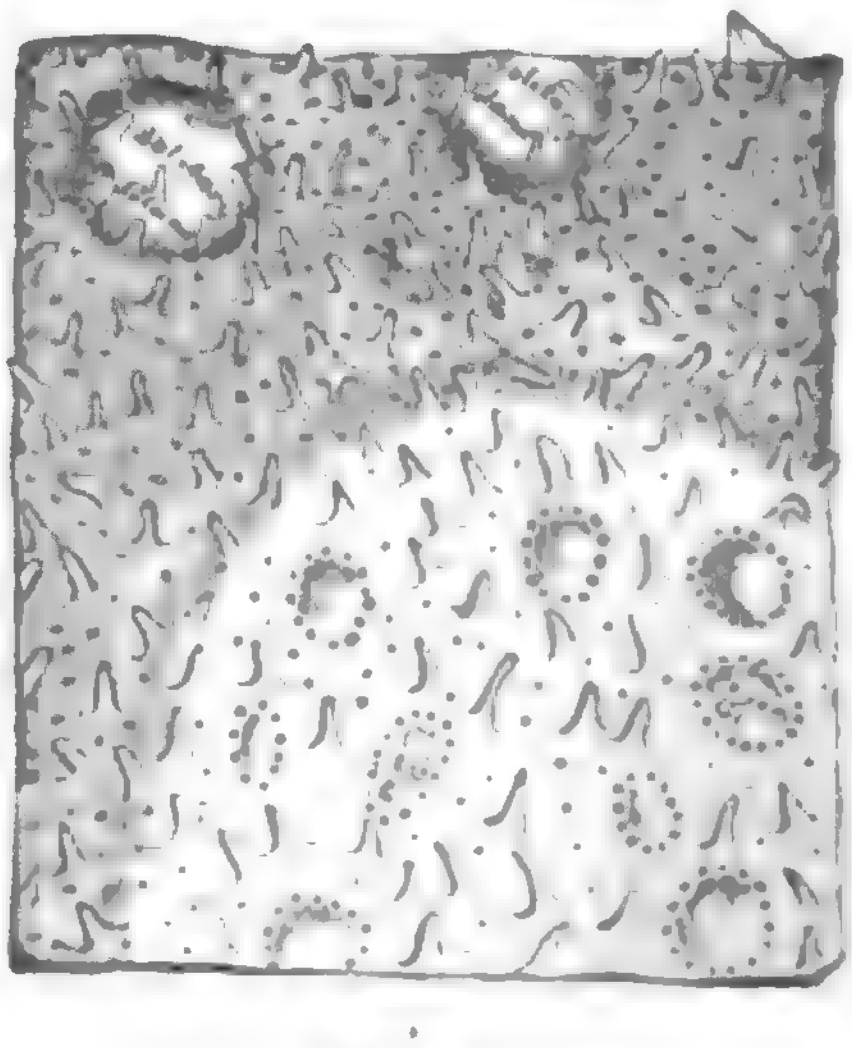

A Portion of Fig. 582 (magnified).

they are small, of a circular form, and few in number. They are occasionally seen in the duodenum. They are placed lengthwise in the intestine, covering the portion of the tube most distant from the attachment of the mesentery. Each patch is formed of a group of the above-described solitary glands covered with mucous membrane, and in almost every respect are similar in structure to them. They do not, however, as a rule, possess villi on their free surface. Each patch is surrounded by a circle of the crypts of Lieberkühn. They are best marked in the young subject, becoming indistinct in middle age, and sometimes altogether disappearing in advanced life. They are largely supplied with blood-vessels, which form an abundant plexus around each follicle, from which fine branches are given off which permeate the lymphoid tissue in the interior of the follicle.

FIG. 584.

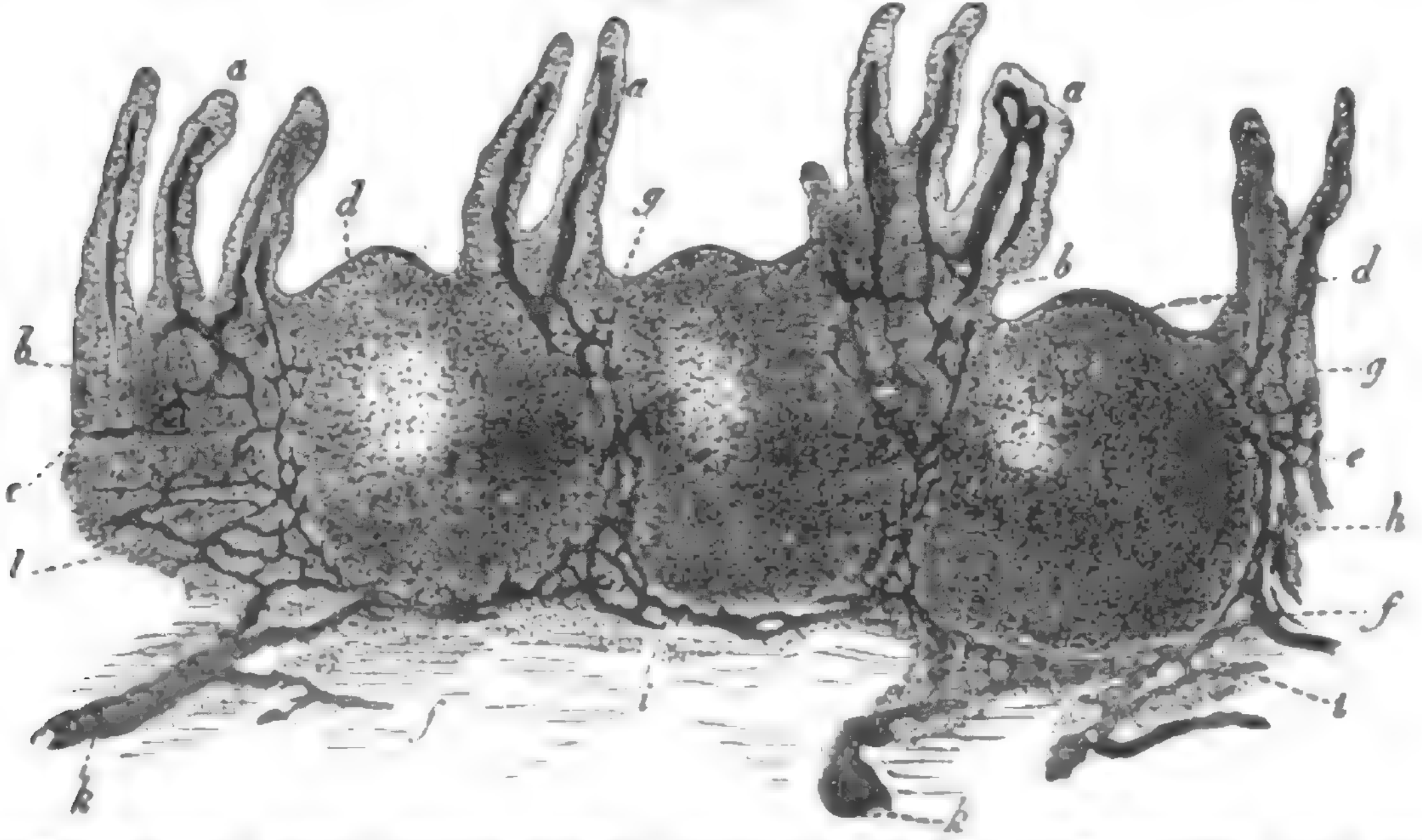

Vertical Section of one of Peyer's Patches, from Man, injected through the lymphatic canals: *a*, villi, with their chyle-passages; *b*, follicles of Lieberkühn; *c*, muscularis mucosæ; *d*, cupola or apex of solitary glands; *e*, mesial zone of glands; *f*, base of glands; *g*, points of exit of the chyle-passages from the villi, and entrance into the true mucous membrane; *h*, retiform arrangement of the lymphatics in the mesial zone; *i*, course of the latter at the base of the glands; *k*, confluence of the lymphatics opening into the vessels of the submucous tissue; *l*, follicular tissue of the latter.

THE LARGE INTESTINE.

The large intestine extends from the termination of the ileum to the anus. It is about five feet in length, being one-fifth of the whole extent of the intestinal canal.[1] It is largest at its commencement at the cæcum, and gradually diminishes as far as the rectum, where there is a dilatation of considerable size just above the anus. It differs from the small intestine in its greater size, its more fixed position, and its sacculated form. The large intestine in its course describes an arch which surrounds the convolutions of the small intestine. It commences in the right iliac fossa in a dilated part, the *cæcum*. It ascends through the right lumbar and hypochondriac regions to the under surface of the liver; passes transversely across the abdomen on the confines of the epigastric and umbilical regions to the left hypochondriac region: descends through the left lumbar region to the left iliac fossa, where it becomes convoluted and forms the sigmoid flexure; finally, it enters the pelvis and descends along its posterior wall to the anus. The large intestine is divided into the cæcum, colon, and rectum.

---

[1] At birth, Treves states, the large intestine is 1 foot and 10 inches in length, of which 10 inches go to the sigmoid flexure. In the first four months after birth the large intestine grows none in length, but a readjustment of its parts takes place without any disturbance of the peritoneum, such that then the sigmoid flexure measures only 6 inches, and the rest of the large bowel 1 foot 4 inches.]

The **Cæcum** (*cæcus*, blind) (Fig. 585) is the large blind pouch or cul-de-sac in which the large intestine commences. [Its full name is the **caput cæcum coli**; that is, the "blind". or closed "head of the colon." Its length is 2¼ inches and its breadth 3 inches.] It is the most dilated part of the tube, measuring about two and a half inches both in its vertical and transverse diameters. Its position varies somewhat; usually it is found lying upon the Psoas muscle, and so placed that its apex or lowest point is just projecting beyond the inner border of that muscle, corresponding to a point a little to the inner side of the middle of Poupart's ligament. Sometimes, however, it is situated external to this, in the right iliac fossa, in relation with the Iliacus muscle; and at other times it lies internal to both Psoas and Iliacus, either resting on the pelvic brim or altogether contained within the pelvis. It is entirely enveloped on all sides by peritoneum, which after enclosing it is reflected on to the posterior wall of the abdomen, being continuous with the ascending mesocolon when this fold exists. The cæcum, therefore, lies quite free in the abdominal cavity and enjoys a considerable amount of movement.[1]

FIG. 585.

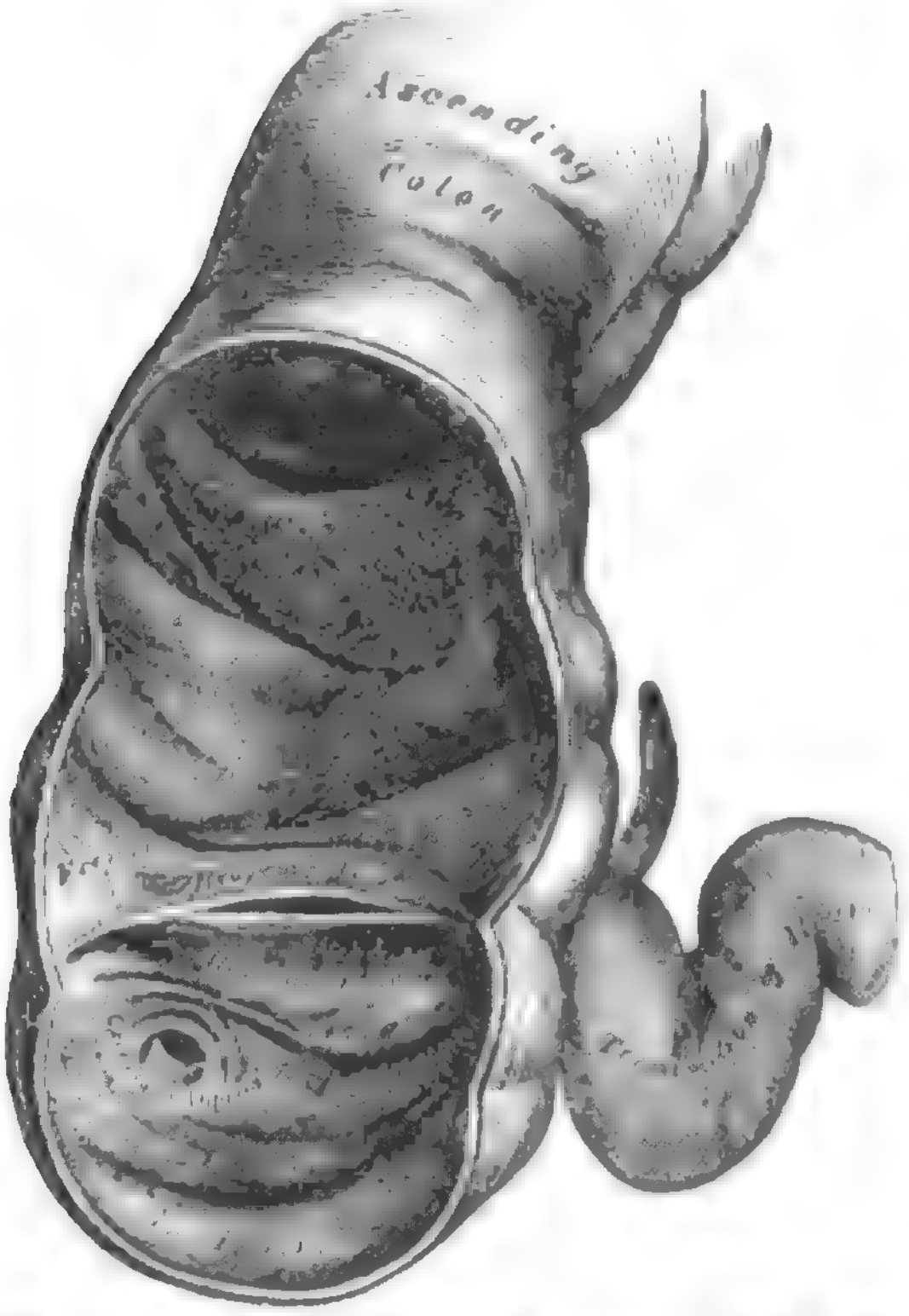

The Cæcum and Colon, laid open to show the Ileo-cæcal Valve.

Attached to its lower and back part is the **Appendix Vermiformis,** a long, narrow, worm-shaped tube, the rudiment of the lengthened cæcum found in all the Mammalia, except some of the higher apes and the wombat, in whom an appendix exists. The appendix varies from three to six inches in length, its average diameter being about equal to that of a goose-quill. It is usually directed upward and inward behind the cæcum, coiled upon itself, and terminates in a blunt point, being retained in its position by a fold of peritoneum which sometimes forms a mesentery for it. Its canal is small, and communicates with the cæcum by an orifice which is sometimes guarded with an incomplete valve. Its coats are thick and its mucous lining furnished with a large number of solitary glands.

[**Surgical Anatomy.**—The relations of the cæcum and the appendix should be carefully observed. Inflammation and perforation of the appendix from fecal concretions or foreign bodies, and inflammation of the caput coli (typhlitis, perityphlitis), are frequently seen, and often demand operation to give vent to the pus that forms. This, fortunately, is usually a limited abscess, though sometimes diffuse peritonitis is produced. It may usually be reached most readily by an incision an inch above Poupart's ligament, followed by a careful dissection into the iliac fossa and toward the pelvis, though sometimes it demands abdominal section in the middle line.

The cæcum is free and mobile, and sometimes, therefore, is found in a hernia.]

Ileo-cæcal Valve.—The lower end of the ileum terminates at the inner and back part of the large intestine, opposite the junction of the cæcum with the colon. At this point the mucous membrane forms two valvular folds which project into the large intestine and are separated from each other by a narrow elongated aperture. These folds form the ileo-cæcal valve (*valvula Bauhini*). Each fold is semilunar in form. The upper one, nearly horizontal in direction, is attached by its convex border to the point of junction of the ileum with the colon; the lower segment to the point of junction of the ileum with the cæcum. Their free concave margins

---

[1] The above description of the position of the cæcum is the one recently given by Mr. Treves in his Hunterian lectures. It differs from that usually found in the text-books of anatomy. There is no doubt that the description given by Mr. Treves is the correct one. [The variations in position of the cæcum are due to its mode of development.] [Matas (*N. O. Med. and Surg. Journ.*, Dec., 1887) has shown that, as early as 1861, Luschka pointed out the complete peritoneal investment of the cæcum, thus antedating Mr. Treves by twenty-four years. None the less credit, however, is due Mr. Treves for his valuable lectures.]

project into the intestine, separated from one another by a narrow slit-like aperture directed transversely. At each end of this aperture the two segments of the valve coalesce, and are continued as a narrow membranous ridge around the canal of the intestine for a short distance, forming the *fræna* or *retinacula* of the valve. The left end of this aperture is rounded; the right end is narrow and pointed.

Each segment of the valve is formed by a reduplication of the mucous membrane and of the circular muscular fibres of the intestine, the longitudinal fibres and peritoneum being continued uninterruptedly across from one intestine to the other. When these are divided or removed the ileum may be drawn outward, and all traces of the valve will be lost, the ileum appearing to open into the large intestine by a funnel-shaped orifice of large size.

The surface of each segment of the valve directed toward the ileum is covered with villi, and presents the characteristic structure of the mucous membrane of the small intestine; whilst that turned toward the large intestine is destitute of villi, and marked with the orifices of the numerous tubular glands peculiar to the membrane in the large intestine. These differences in structure continue as far as the free margin of the valve.

When the cæcum is distended the margins of the opening are approximated, so as to prevent any reflux into the ileum.

The **Colon** is divided into four parts—the ascending, transverse, descending, and the sigmoid flexure.

The **ascending colon** is smaller than the cæcum. It passes upward, from its commencement at the cæcum opposite the ileo-cæcal valve, to the under surface of the liver on the right of the gall-bladder, where it bends abruptly inward to the left, forming the *hepatic flexure*. It is retained in contact with the posterior wall of the abdomen by the peritoneum, which covers its anterior surface and sides, its posterior surface being connected by loose areolar tissue with the Quadratus lumborum, right kidney, and descending portion of the duodenum (Figs. 586, 587): sometimes the peritoneum almost completely invests it and forms a distinct but narrow mesocolon.[1] It is in relation in front with the convolutions of the ileum and the abdominal parietes; behind, it lies on the Quadratus lumborum muscle and right kidney.

The **transverse colon**, the longest part of the large intestine, passes transversely from right to left across the abdomen, opposite the confines of the epigastric and umbilical zones, into the left hypochondriac region, where it curves downward beneath the lower end of the spleen, forming the *splenic flexure*. In its course it describes an arch, the concavity of which is directed backward toward the vertebral column; hence the name, *transverse arch of the colon*. This is the most movable part of the colon, being almost completely invested by peritoneum, and connected to the spine behind by a large and wide duplicature of that membrane, the *transverse mesocolon*. It is in relation by its upper surface with the liver and gall-bladder, the great curvature of the stomach, and the lower end of the spleen; by its under surface with the small intestines; by its anterior surface with the anterior layers of the great omentum and the abdominal parietes; by its posterior surface with the transverse mesocolon and third portion of the duodenum.

The **descending colon** passes almost vertically downward through the left hypochondriac and lumbar regions to the upper part of the left iliac fossa, where it terminates in the sigmoid flexure. It is retained in position by the peritoneum, which covers its anterior surface and sides, its posterior surface being connected by areolar tissue with the left crus of the Diaphragm, the left kidney, and the Quadratus lumborum (Figs. 586, 587). It is smaller in calibre and more deeply placed than the ascending colon, and is more frequently covered with peritoneum on its posterior surface than the ascending colon (Treves). [It is very important to locate the colon accurately from the exterior in operations upon it. It lies half an inch behind the mid-point between the anterior and superior spines of the ilium.]

---

[1] Mr. Treves states that, after a careful examination of 100 subjects, he found that in 52 there was neither an ascending nor a descending mesocolon. In 22 there was a descending mesocolon, but no trace of a corresponding fold on the other side. In 14 subjects there was a mesocolon to both the ascending and the descending segments of the bowel; while in the remaining 12 there was an ascending mesocolon, but no corresponding fold on the left side. It follows, therefore, that in performing lumbar colotomy a mesocolon may be expected upon the left side in 36 per cent. of all cases, and on the right in 26 per cent. (*The Anatomy of the Intestinal Canal and Peritoneum in Man*, 1885, p. 55).

Fig. 586.

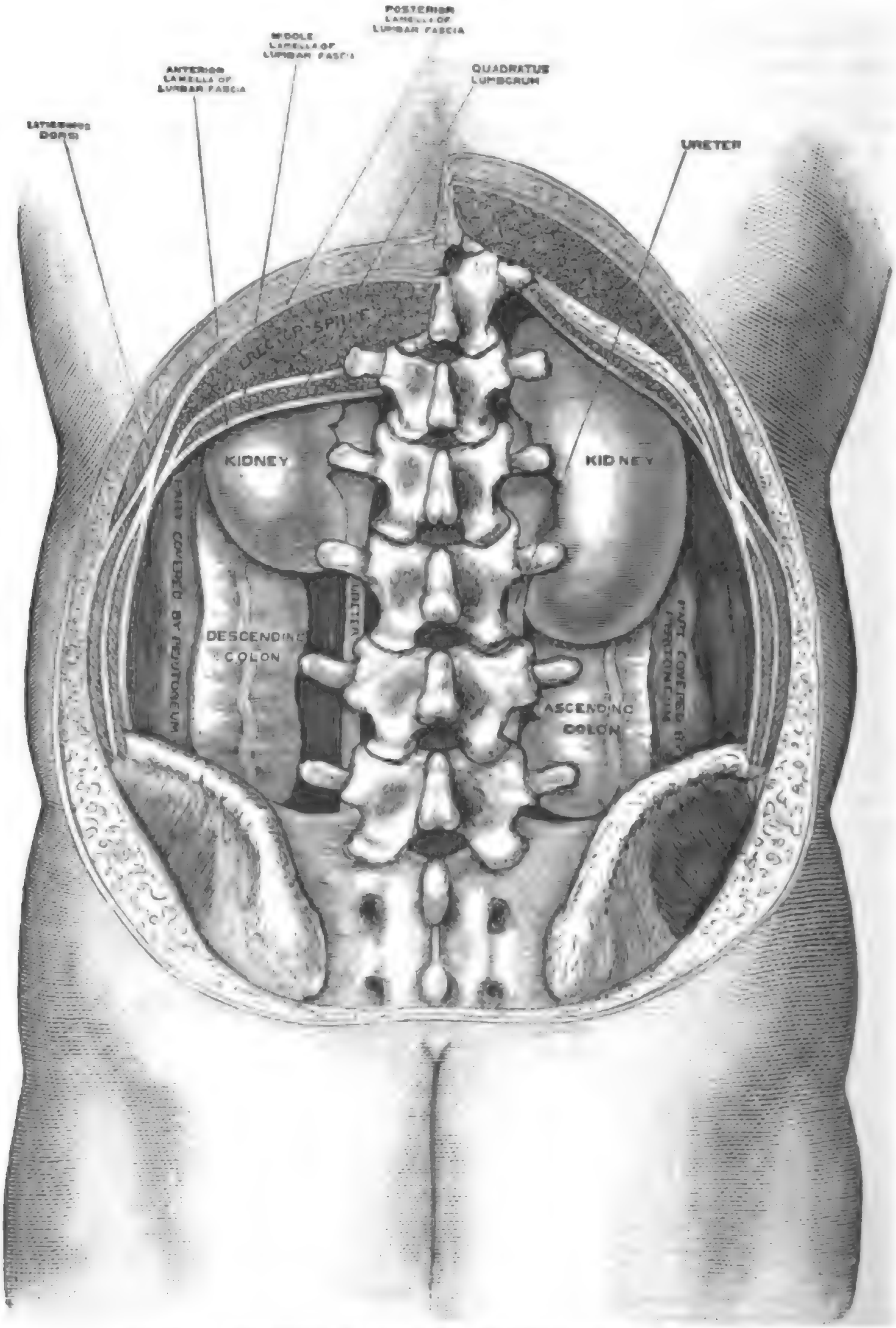
LATISSIMUS DORSI
ANTERIOR LAMELLA OF LUMBAR FASCIA
MIDDLE LAMELLA OF LUMBAR FASCIA
POSTERIOR LAMELLA OF LUMBAR FASCIA
QUADRATUS LUMBORUM
URETER
ERECTOR SPINAE
KIDNEY
KIDNEY
PART COVERED BY PERITONEUM
DESCENDING COLON
URETER
ASCENDING COLON
PART COVERED BY PERITONEUM

Diagram of the Relations of the Large Intestine and Kidney, from behind.

The **sigmoid flexure** is the narrowest part of the colon; it is situated in the left iliac fossa, commencing from the termination of the descending colon at the margin of the crest of the ilium, and ending in the rectum opposite the left sacro-iliac symphysis. It curves in the first place inward across the Psoas muscle; it then descends vertically along the left wall of the pelvis, and finally again passes

Fig. 587.

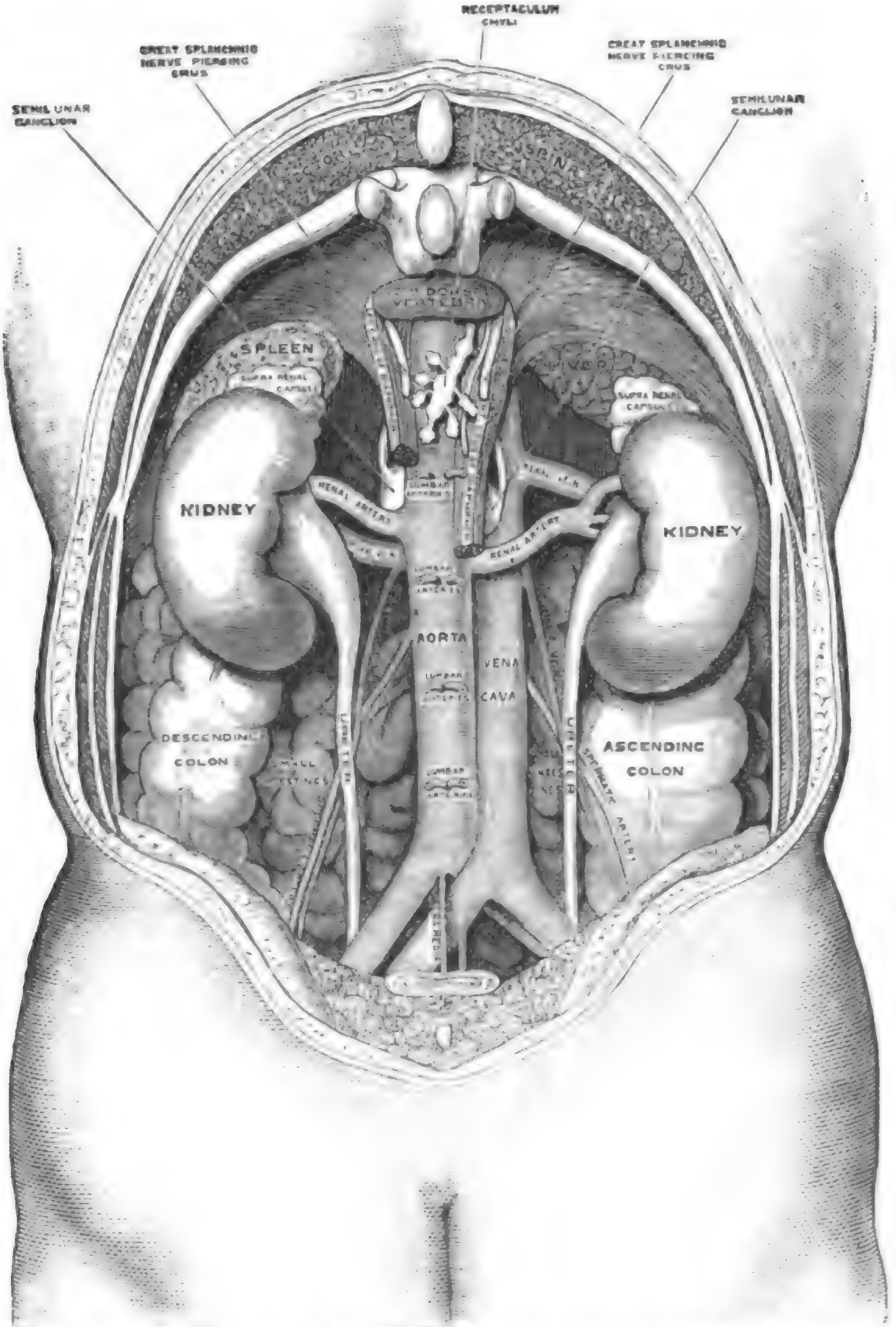
RECEPTACULUM CHYLI
GREAT SPLANCHNIC NERVE PIERCING CRUS
SEMILUNAR GANGLION
GREAT SPLANCHNIC NERVE PIERCING CRUS
SEMILUNAR GANGLION
DORSAL VERTEBRA
SPLEEN
SUPRA RENAL CAPSULE
LIVER
SUPRA RENAL CAPSULE
RENAL ARTERY
LUMBAR ARTERIES
RENAL VEIN
RENAL ARTERY
KIDNEY
KIDNEY
LUMBAR ARTERIES
AORTA
VENA CAVA
LUMBAR ARTERIES
URETER
URETER
DESCENDING COLON
SMALL INTESTINES
ASCENDING COLON
SPERMATIC ARTERY
LUMBAR ARTERIES

The Relations of the Viscera and Large Vessels of the Abdomen (seen from behind, the last dorsal vertebra being well raised).

inward to the left sacro-iliac joint, where it becomes the rectum. It is retained in its place by a loose fold of peritoneum, the *sigmoid mesocolon.* It is in relation in front with the small intestines and abdominal parietes.

[Treves defines the sigmoid flexure as that portion of the large bowel from the Psoas muscle to the third sacral vertebra. He includes, therefore, and properly, in the sigmoid flexure the first part of the rectum as usually described. It lies not in the left iliac fossa, but in the pelvis. It is not usually S- or Σ-shaped, but a large loop, 17½ inches long, more like the Greek Ω (omega), the top of the loop sometimes even touching the right side of the pelvis.]

The **Rectum** is the terminal part of the large intestine, and extends from the sigmoid flexure to the anus; it varies in length from six to eight inches, and has received its name from being less flexuous than any other part of the intestinal canal. It commences opposite the left sacro-iliac symphysis, passes obliquely downward from left to right to the middle of the sacrum, forming a gentle curve to the right side; it then descends in front of the lower part of the sacrum and coccyx, presenting a curve with its concavity forward, and near the extremity of the latter bone inclines backward to terminate at the anus. The rectum is, therefore, not straight, the upper part being directed obliquely from the left side to the median line, the middle portion being curved in the direction of the hollow of the sacrum and coccyx, and the lower portion presenting a short curve in the opposite direction. [This change of direction it is very important to remember in the introduction of the finger and of instruments into the rectum. For the first inch they should be introduced in the direction of the umbilicus, and then be directed into the hollow of the sacrum.] The rectum is cylindrical, not sacculated like the rest of the large intestine; it is narrower at its upper part than the sigmoid flexure, gradually increases in size as it descends, and immediately above the anus presents a considerable dilatation capable of acquiring an enormous size. The rectum is divided into three portions—upper, middle, and lower. [See the preceding paragraph.]

The *upper portion*, which includes about half the length of the tube, extends obliquely from the left sacro-iliac symphysis to the middle of the third piece of the sacrum. It is almost completely surrounded by peritoneum, and connected to the sacrum behind by a duplicature of that membrane, the *mesorectum.* It is in relation behind with the Pyriformis muscle, the sacral plexus of nerves, and the branches of the internal iliac artery of the left side, which separate it from the sacrum and sacro-iliac symphysis; in front it is separated, in the male, from the posterior surface of the bladder; in the female, from the posterior surface of the uterus and its appendages by some convolutions of the small intestine.

The *middle portion* of the rectum is about three inches in length, and extends as far as the tip of the coccyx. It is closely connected to the concavity of the sacrum, and covered by peritoneum only on the upper part of its anterior surface. It is in relation in front, in the male, with the triangular portion of the base of the bladder, the vesiculæ seminales, and vasa deferentia, more anteriorly with the under surface of the prostate. In the female it is adherent to the posterior wall of the vagina.

The *lower portion* is about an inch or an inch and a half in length; it curves backward at the fore part of the prostate gland and terminates at the anus. This portion of the intestine receives no peritoneal covering. [According to Dr. J. B. Roberts, the peritoneum extends, when the parts are *in situ*, to within 1½ to 2 inches of the anus, but when the parts are removed the distance is 3½ to 4¼ inches.] It is invested by the Internal sphincter, supported by the Levatores ani muscles, and surrounded at its termination by the External sphincter. In the male it is separated from the membranous portion and bulb of the urethra by a triangular space, and in the female a similar space intervenes between it and the vagina. This space forms by its base the perineum.

Structure.—The large intestine has four coats—serous, muscular, cellular, and mucous.

The *serous coat* is derived from the peritoneum, and invests the different portions of the large intestine to a variable extent. The cæcum is completely covered by the serous membrane. The ascending and descending colon are usually covered only in front.[1] The transverse colon is almost completely invested, the parts corresponding to the attachment of the great omentum and transverse mesocolon being alone excepted. The sigmoid flexure is nearly completely surrounded, the point corresponding to the attachment of the sigmoid mesocolon being excepted. The upper part of the rectum is almost completely invested by the peritoneum, the middle portion is covered only on its anterior surface, and the lower portion is entirely devoid of any serous covering. In the course of the colon and upper part of the rectum the peritoneal coat is thrown into a number of small pouches filled with fat, called *appendices epiploicæ.* They are chiefly appended to the transverse colon.

The *muscular coat* consists of an external longitudinal and an internal circular layer of muscular fibres.

The *longitudinal fibres* are not found as a uniform layer over the whole surface of the large intestine. In the cæcum and colon they are especially collected into three flat longitudinal bands, each being about half an inch in width. These bands commence at the attachment of the appendix vermiformis to the cæcum: one, the posterior, is placed along the attached border of the intestine; the anterior band, the largest, corresponds along the arch of the colon to the attachment of the great omentum, but is in front in the ascending and descending colon and sigmoid flexure; the third or lateral band is found on the inner side of the ascending and descending colon and on the under border of the transverse colon. These bands are nearly one-half shorter than the other parts of the intestine, and serve to produce the sacculi which are characteristic of the cæcum and colon; accordingly, when they are dissected off the tube can be lengthened and its sacculated character becomes lost. In the sigmoid flexure the longitudinal fibres become more scattered, but upon its lower part and around the rectum they spread out and form a thick uniform layer. [In lumbar colotomy the colon may be recognized by these longitudinal bands.]

The *circular fibres* form a thin layer over the cæcum and colon, being especially accumulated in the intervals between the sacculi; in the rectum they form a thick layer, especially at its lower end, where they become numerous and form the Internal sphincter.

The *areolar coat* connects the muscular and mucous layers closely together.

The *mucous membrane* in the cæcum and colon is pale and of a grayish or pale-yellow color. It is quite smooth, destitute of villi, and raised into numerous crescentic folds which correspond to the intervals between the sacculi. In the rectum it is thicker, of a darker color, more vascular, and connected loosely to the muscular coat, as in the œsophagus. When the lower part of the rectum is contracted its mucous membrane is thrown into a number of folds, some of which, near the anus, are longitudinal in direction and are effaced by the distension of the gut. Besides these there are certain permanent folds of a semilunar shape described by Mr. Houston.[2] They are usually three in number; sometimes a fourth is found, and occasionally only two are present. One is situated near the commencement of the rectum on the right side; another extends inward from the left side of the tube, opposite the middle of the sacrum; the largest and most constant one projects backward from the fore part of the rectum opposite the base of the bladder. When a fourth is present, it is situated about an inch above the anus on the back of the rectum. These folds are about half an inch in width and contain some of the circular fibres of the gut. In the empty state of the intestine they overlap each other, as Mr. Houston remarks, so effectually as to require considerable manœuvring to conduct a bougie or the finger along the canal of the intestine. Their use seems to be "to support the weight of fecal matter and prevent its urging toward the anus, where its presence always excites a sensation demanding its discharge."

As in the small intestine, the mucous membrane consists of a muscular layer, the

---

[1] See footnote p. 883.

[2] *Dub. Hosp. Reports,* vol. v. p. 163.

FIG. 588.

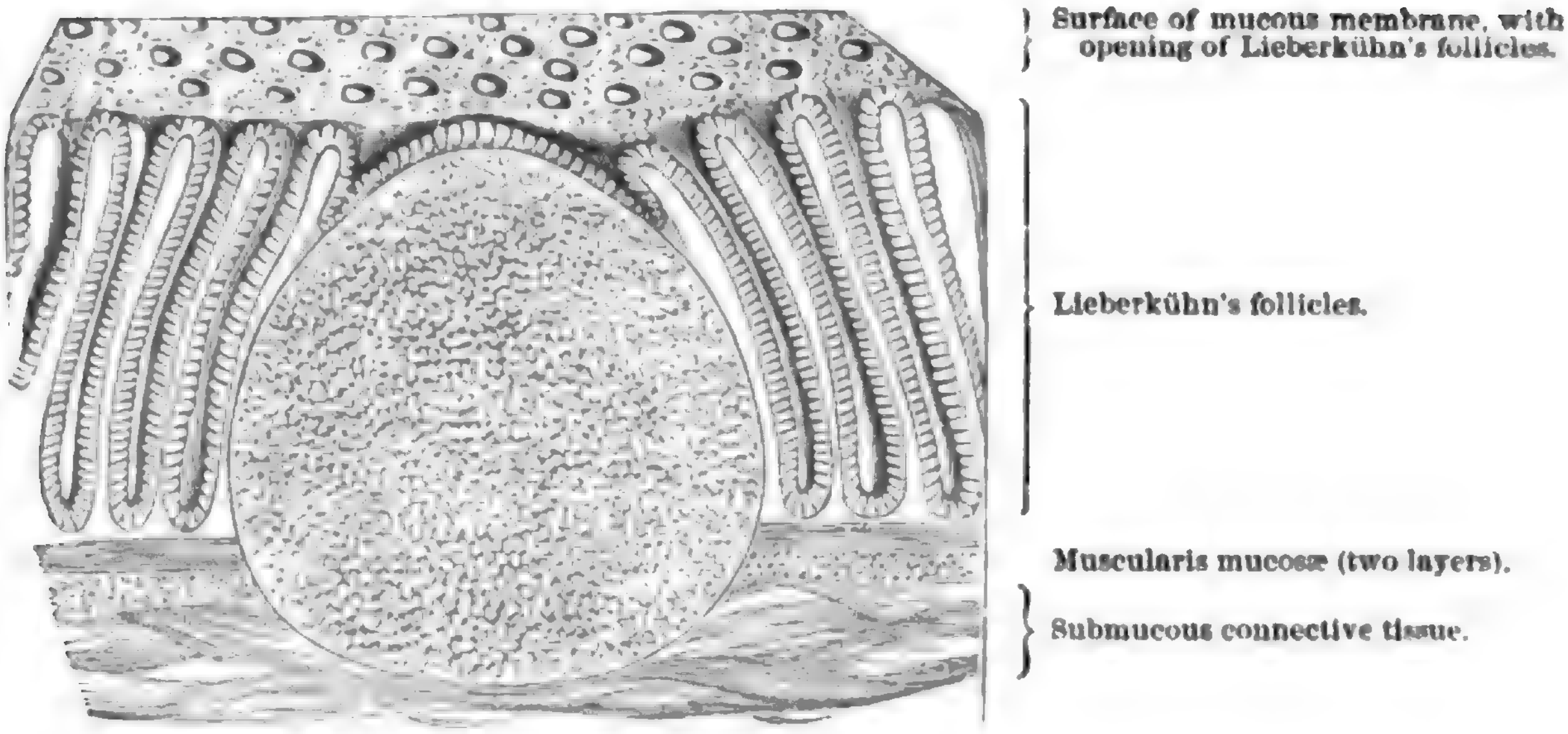
Surface of mucous membrane, with opening of Lieberkühn's follicles.
Lieberkühn's follicles.
Muscularis mucosæ (two layers).
Submucous connective tissue.

Solitary Gland.
Minute Structure of Large Intestine.

muscularis mucosæ; of a quantity of retiform tissue in which the vessels ramify: of a basement membrane and epithelium which is of the columnar variety, and exactly resembles the epithelium found in the small intestine. The mucous membrane of this portion of the bowel presents for examination simple follicles and solitary glands.

FIG. 589.

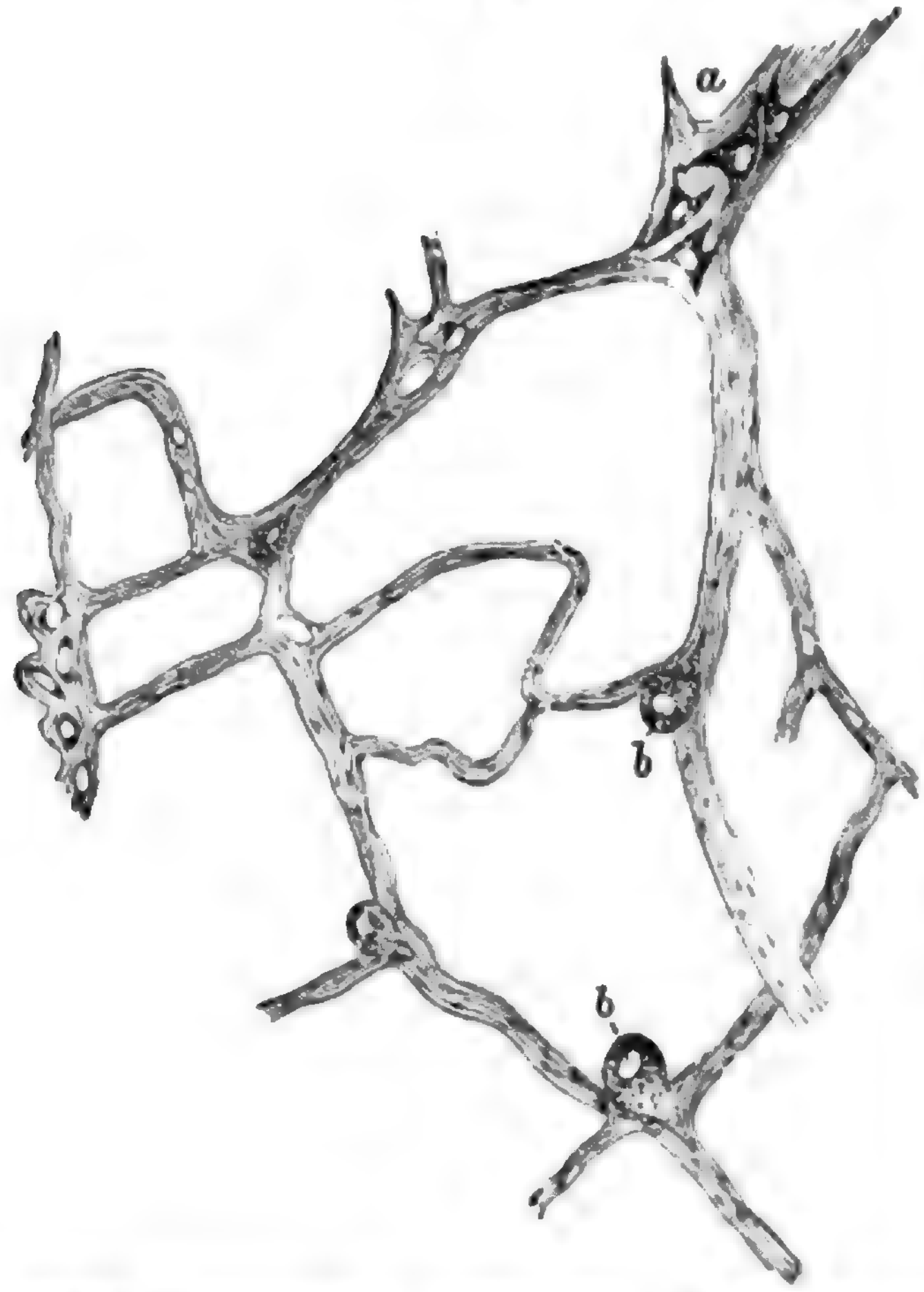

Meissner's Plexus (Klein and Noble Smith): *a*, groups of multipolar ganglion-cells, each with a clear nucleus, in the enlarged parts of the plexus; *b*, large single ganglion-cells, apparently unipolar, each with a clear nucleus connected with the branches of the plexus.

The *simple follicles* are minute tubular prolongations of the mucous membrane, arranged perpendicularly, side by side, over its entire surface; they are longer, more numerous, and placed in much closer apposition than those of the small intestine, and they open by minute rounded orifices upon the surface, giving it a cribriform appearance.

The *solitary glands* (Fig. 588) in the large intestine are most abundant in the *cæcum* and *appendix vermiformis*, but are irregularly scattered also over the rest of the intestine. They are similar to those of the small intestine.

The nerves of the intestine are derived from the plexuses of sympathetic nerves around the mesenteric arteries. From this source they run to a plexus of nerves and ganglia situated between the circular and longitudinal fibres (Auerbach's plexus), from which the nervous branches are distributed to the muscular coats of the intestine. From this plexus a secondary plexus is derived (Meissner's plexus), which is formed by branches which have perforated the circular muscular fibres (Fig. 589). This plexus lies between the muscular and mucous coats of the intestine. It is also gangliated, and from it the ultimate fibres pass to the muscularis mucosæ and to the mucous membrane.

THE LIVER.

The **Liver** is a glandular organ of large size intended mainly for the secretion of the bile, but effecting also important changes in certain constituents of the blood in their passage through the gland. It is situated in the right hypochondriac and epigastric regions [Figs. 308 and 309, p. 423], but in the child extends across the epigastrium into the left hypochondrium. It is the largest gland in the body, weighing from three to four pounds (from fifty to sixty ounces avoirdupois). It measures in its transverse diameter from ten to twelve inches, from six to seven in its antero-posterior, and is about three inches thick at the back part of the right lobe, which is the thickest part.

Its *upper* or *diaphragmatic surface* is convex, directed upward and forward, smooth, covered by peritoneum. It is in relation with the under surface of the Diaphragm, and below, to a small extent, with the abdominal parietes. The surface is divided into two unequal lobes, the right and left, by a fold of peritoneum, the *suspensory* or *broad ligament.*

Its *under* or *visceral surface* is concave, directed downward and backward, and in relation with the stomach and duodenum, the hepatic flexure of the colon, and the right kidney and suprarenal capsule. The surface is divided by a longitudinal fissure into a right and left lobe.

The *posterior border* is rounded and broad, and connected to the Diaphragm by the coronary ligament; it is in relation with the aorta, the inferior vena cava, and the crura of the Diaphragm.

The *anterior border* is thin and sharp, and marked, opposite the attachment of the broad ligament, by a deep notch. In adult males this border usually corresponds with the margin of the ribs, but in women and children it usually projects below the ribs.

The *right extremity* of the liver is thick and rounded, whilst the left is thin and flattened.

Changes of Position.—The student should make himself acquainted with the different circumstances under which the liver changes its position, as they are of importance in determining the existence of enlargement or other disease of the organ.

Its position varies according to the posture of the body; in the upright and sitting posture it usually recedes behind the ribs. Its position varies also with the ascent or descent of the Diaphragm. In a deep inspiration the liver descends below the ribs; in expiration it is raised to its ordinary level. Again, in emphysema, where the lungs are distended and the Diaphragm descends very low, the liver is pushed down; in some other diseases, as phthisis, where the Diaphragm is much arched, the liver rises very high up. Pressure from without, as in tight-lacing, by compressing the lower part of the chest displaces the liver considerably, its anterior edge often extending as low as the crest of the ilium, and its convex surface is often at the same time deeply indented from pressure of the ribs. Again, its position varies greatly according to the greater or less distension of the stomach and intestines. When the intestines are empty the liver descends in the abdomen, but when they are distended it is pushed upward. Its relations to surrounding organs may also be changed by the growth of tumors or by collections of fluid in the thoracic or abdominal cavities. ["Floating" or "wandering" liver, from great relaxation of its ligaments, is occasionally though rarely seen.]

LIGAMENTS.—The ligaments of the liver (Fig. 590) are five in number, four being formed of folds of peritoneum: the fifth, the *ligamentum teres*, is a round fibrous cord resulting from the obliteration of the umbilical vein. The ligaments are the longitudinal, two lateral, coronary, and round.

The *longitudinal ligament* (broad, falciform, or suspensory ligament) is a broad and thin antero-posterior peritoneal fold, falciform in shape, its base being directed forward, its apex backward. It is attached by one margin to the under surface of the Diaphragm and the posterior surface of the sheath of the right Rectus muscle as low down as the umbilicus; by its hepatic margin it extends from the notch on the anterior margin of the liver as far back as its posterior border. It consists of two layers of peritoneum closely united together. Its anterior free edge contains the round ligament between its layers.

The *lateral ligaments*, two in number, right and left, are triangular in shape. They are formed of two layers of peritoneum united, and extend from the sides of the Diaphragm to the adjacent margins of the posterior border of the organ. The left is the longer of the two, and lies in front of the œsophageal opening in the Diaphragm.

Fig. 590.

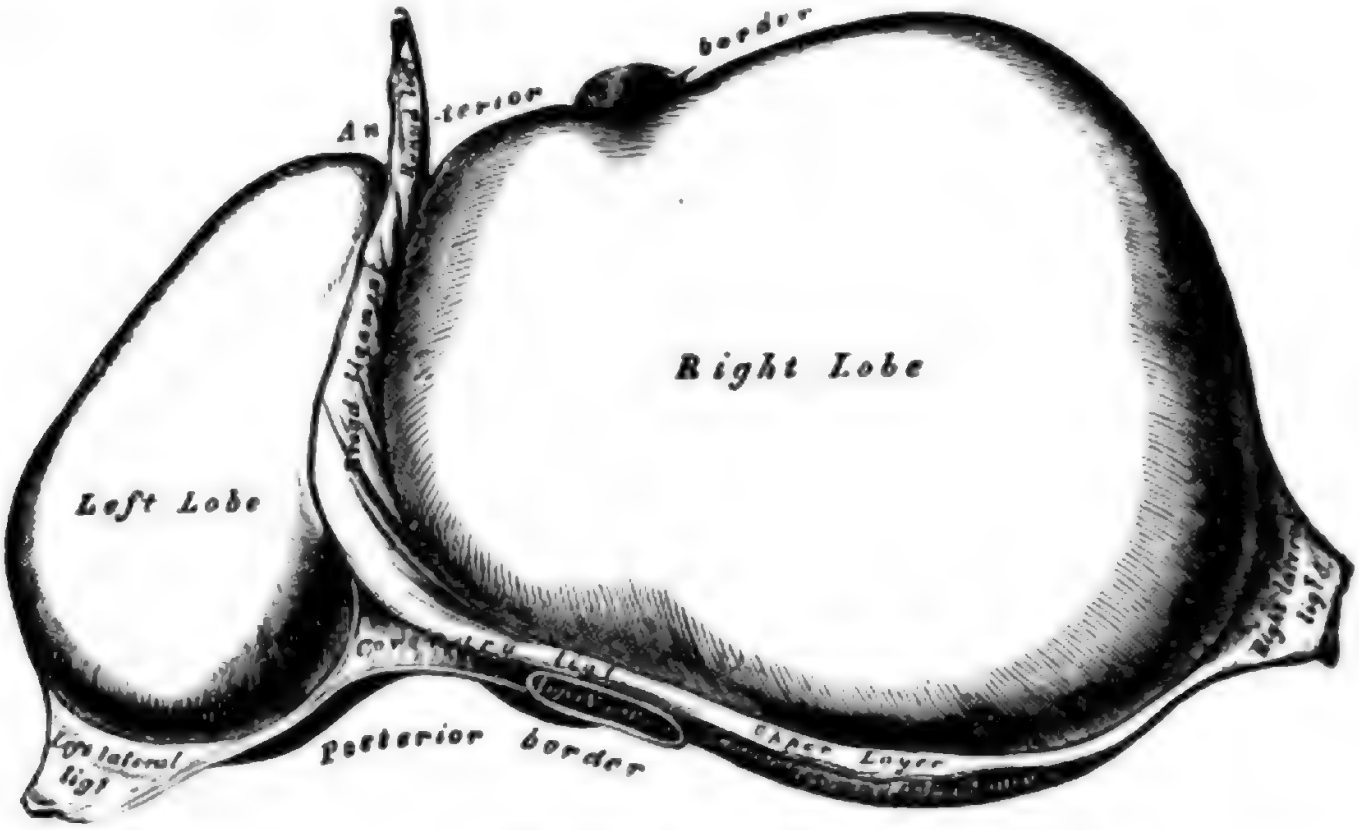
An-terior border
Round lig.
Right Lobe
Left Lobe
Coronary ligt
Posterior border
Upper Layer
Left lateral ligt
Right lateral ligt

The Liver, upper surface.

The *coronary ligament* connects the posterior border of the liver to the Diaphragm. It is formed by the reflection of the peritoneum from the Diaphragm on to the upper and lower margins of the posterior border of the organ. The coronary ligament consists of two layers, which are continuous on each side with the lateral ligaments and in front with the longitudinal ligament. Between the layers a large

Fig. 591.

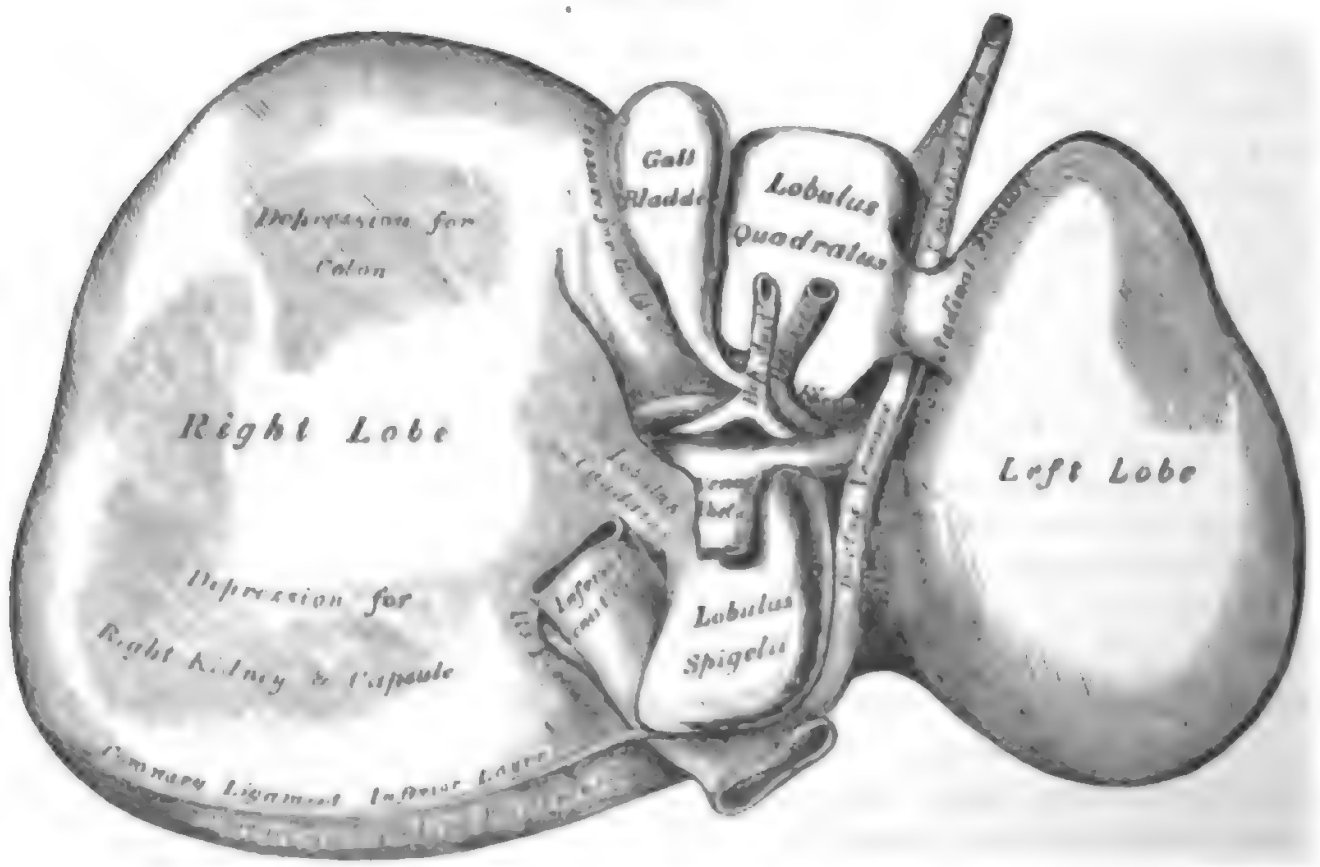
Gall Bladder
Lobulus Quadratus
Depression for Colon
Right Lobe
Left Lobe
Depression for Right Kidney & Capsule
Lobulus Spigelii
Coronary Ligament Inferior Layer

The Liver, under surface.

oval interspace is left uncovered by peritoneum and connected to the Diaphragm by firm areolar tissue. This space is subdivided near its left extremity into two parts by a deep notch (sometimes a canal), which lodges the inferior vena cava and into which open the hepatic veins.

The *round ligament* (Fig. 591) is a fibrous cord resulting from the obliteration of the umbilical vein. It ascends from the umbilicus, in the anterior free margin of the longitudinal ligament, to the notch in the anterior border of the liver, from which it may be traced along the longitudinal fissure on the under surface of the liver as far back as the inferior vena cava.

FISSURES (Fig. 591).—Five fissures are seen upon the under surface of the liver, which serve to divide it into five lobes. They are the longitudinal fissure, the fissure of the ductus venosus, the transverse fissure, the fissure for the gall-bladder, and the fissure for the inferior vena cava. They are arranged in the form of the letter A, the apex of the letter corresponding to the posterior margin of the liver, its base to the anterior free border. The connecting bar would represent the transverse fissure; the two converging limbs posterior to this would represent—the *left one*, the fissure for the ductus venosus; the *right one*, the fissure for the inferior vena cava; the two diverging limbs anterior to the cross-bar would represent the umbilical fissure (*left*) and the fissure for the gall-bladder (*right*).

The *longitudinal fissure* is a deep groove which extends from the notch on the anterior margin of the liver to the posterior border of the organ. It separates the right and left lobes; the transverse fissure joins it at right angles about one-third from its posterior extremity and divides it into two parts. The anterior half is called the *umbilical fissure;* it is deeper than the posterior part, and lodges the umbilical vein in the fœtus or its remains (the round ligament) in the adult. This fissure is often partially bridged over by a prolongation of the hepatic substance, the *pons hepatis.*

The *fissure of the ductus venosus* is the back part of the longitudinal fissure; it is shorter and shallower than the anterior portion. It lodges in the fœtus the ductus venosus, and in the adult a slender fibrous cord, the obliterated remains of that vessel.

The *transverse* or *portal fissure* is a short but deep fissure about two inches in length, extending transversely across the under surface of the right lobe nearer to its posterior than its anterior border. It joins nearly at right angles with the longitudinal fissure. By the older anatomists this fissure was considered the gateway (*porta*) of the liver; hence the large vein which enters at this point was called the *portal vein.* Besides this vein the fissure transmits the hepatic artery and nerves and the hepatic duct and lymphatics. At their entrance into the fissure the hepatic duct lies in front and to the right, the hepatic artery to the left, and the portal vein behind and between the duct and artery.

The *fissure for the gall-bladder* (*fossa cystis felleæ*) is a shallow, oblong fossa placed on the under surface of the right lobe parallel with the longitudinal fissure. It extends from the anterior free margin of the liver, which is occasionally notched for its reception, to near the right extremity of the transverse fissure.

The *fissure for the inferior vena cava* is a short, deep fissure, occasionally a complete canal, which extends obliquely upward from a little behind the right extremity of the transverse fissure to the posterior border of the liver, where it joins the fissure for the ductus venosus. On slitting open the inferior vena cava which is contained in it a deep fossa is seen, at the bottom of which the hepatic veins communicate with this vessel. This fissure is separated from the transverse fissure by the lobus caudatus and from the longitudinal fissure by the lobulus Spigelii.

LOBES.—The lobes of the liver, like the ligaments and fissures, are five in number—the right lobe, the left lobe, the lobus quadratus, the lobulus Spigelii, and the lobus caudatus.

The *right lobe* is much larger than the left, the proportion between them being as six to one. It occupies the right hypochondrium, and is separated from the left lobe, on its upper surface, by the longitudinal ligament; on its under surface, by the longitudinal fissure; and in front, by a deep notch. It is of a quadrilateral form, its under surface being marked by three fissures—the transverse fissure, the fissure for the gall-bladder, and the fissure for the inferior vena cava; and by two shallow impressions, one in front (*impressio colica*) for the hepatic flexure of the colon, and one behind (*impressio renalis*) for the right kidney and suprarenal capsule.

The *left lobe* is smaller and more flattened than the right. It is situated in the epigastric region. Its upper surface is convex; its under concave surface rests upon the front of the stomach, and its posterior border is in relation with the cardiac orifice of the stomach.

The *lobus quadratus*, or square lobe, is situated on the under surface of the right lobe, bounded in front by the free surface of the liver, behind by the transverse fissure, on the right by the fissure for the gall-bladder, and on the left by the umbilical fissure.

The *lobulus Spigelii* projects from the back part of the under surface of the right lobe. It is bounded in front by the transverse fissure, on the right by the fissure for the vena cava, and on the left by the fissure for the ductus venosus.

The *lobus caudatus*, or tailed lobe, is a small elevation of the hepatic substance extending obliquely outward from the base of the lobus Spigelii to the under surface of the right lobe. It separates the right extremity of the transverse fissure from the commencement of the fissure for the inferior vena cava.

VESSELS.—The vessels connected with the liver are also five in number: they are the hepatic artery, the portal vein, the hepatic vein, the hepatic duct, and the lymphatics.

The *hepatic artery* and *portal vein*, accompanied by numerous lymphatics and nerves, ascend to the transverse fissure between the layers of the gastro-hepatic omentum. The *hepatic duct*, lying in company with them, descends from the transverse fissure between the layers of the same omentum, and the relative position of the three structures is as follows: the hepatic duct lies to the right, the hepatic artery to the left, and the portal vein behind and between the other two. They are enveloped in a loose areolar tissue, the capsule of Glisson, which accompanies the vessels in their course through the *portal canals* in the interior of the organ.

The *hepatic veins* convey the blood from the liver. They commence in the substance of the organ, and proceed through it to the deep fossa in its posterior border, where they terminate, by three large and several smaller branches, in the inferior vena cava.

The hepatic veins have no cellular investment; consequently, their parietes are adherent to the walls of the canals through which they run, so that on a section of the organ these veins remain widely open and solitary, and may be easily distinguished from the branches of the portal vein, which are more or less collapsed and always accompanied by an artery and duct.

The *lymphatics* are large and numerous, consisting of a deep and superficial set. They have been already described.

NERVES.—The nerves of the liver are derived from the hepatic plexus of the sympathetic, from the pneumogastric nerves, especially the left, and from the right phrenic.

Structure.—The substance of the liver is composed of lobules held together by an extremely fine areolar tissue, and of the ramifications of the portal vein, hepatic duct, hepatic artery, hepatic veins, lymphatics, and nerves, the whole being invested by a serous and a fibrous coat.

The *serous coat* is derived from the peritoneum, and invests the entire surface of the organ, excepting at the attachment of its various ligaments and at the bottom of the different fissures, where it is deficient. It is intimately adherent to the fibrous coat.

The *fibrous coat* lies beneath the serous investment and covers the entire surface of the organ. It is difficult of demonstration excepting where the serous coat is deficient. At the transverse fissure it is continuous with the capsule of Glisson, and on the surface of the organ with the areolar tissue separating the lobules.

The *lobules* form the chief mass of the hepatic substance; they may be seen either on the surface of the organ or by making a section through the gland. They are small granular bodies about the size of a millet-seed, measuring from one-twentieth to one-tenth of an inch in diameter. In the human subject their outline is very irregular, but in some of the lower animals (for example, the pig) they are well defined, and when divided transversely have a polygonal outline. If divided longitudinally they are more or less foliated or oblong. The bases of the lobules are clustered round the smallest radicles (*sublobular*) of the hepatic veins, to which each is connected by means of a small branch which issues from the centre of the lobule (*intralobular*). The remaining part of the surface of each lobule is imperfectly isolated from the surrounding lobules by a thin stratum of areolar tissue, in which is contained a plexus of vessels (the *interlobular plexus*) and ducts. In some animals, as the pig, the lobules are completely isolated one from another by this interlobular connective tissue.

If one of the sublobular veins be laid open the bases of the lobules may be seen through the thin wall of the vein, on which they rest arranged in the form of a tessellated pavement, the centre of each polygonal space presenting a minute aperture, the mouth of an intralobular vein (Fig. 592).

Each lobule is composed of a mass of cells (*hepatic cells*), surrounded by a dense capillary plexus composed of vessels which penetrate from the circumference to the centre of the lobule, and terminate in a single straight vein which runs through its centre to open at its base into one of the radicles of the hepatic vein. Between the cells are also the minute commencements of the bile-ducts. Therefore in the lobule we have all the essentials of a secreting gland; that is to say, (1) *cells*, by which the secretion is formed; (2) *blood-vessels*, in close relation with the cells, containing the blood from which the secretion is derived; and (3) *ducts*, by which the secretion when formed is carried away. Each of these structures will have to be further considered.

Fig. 592.

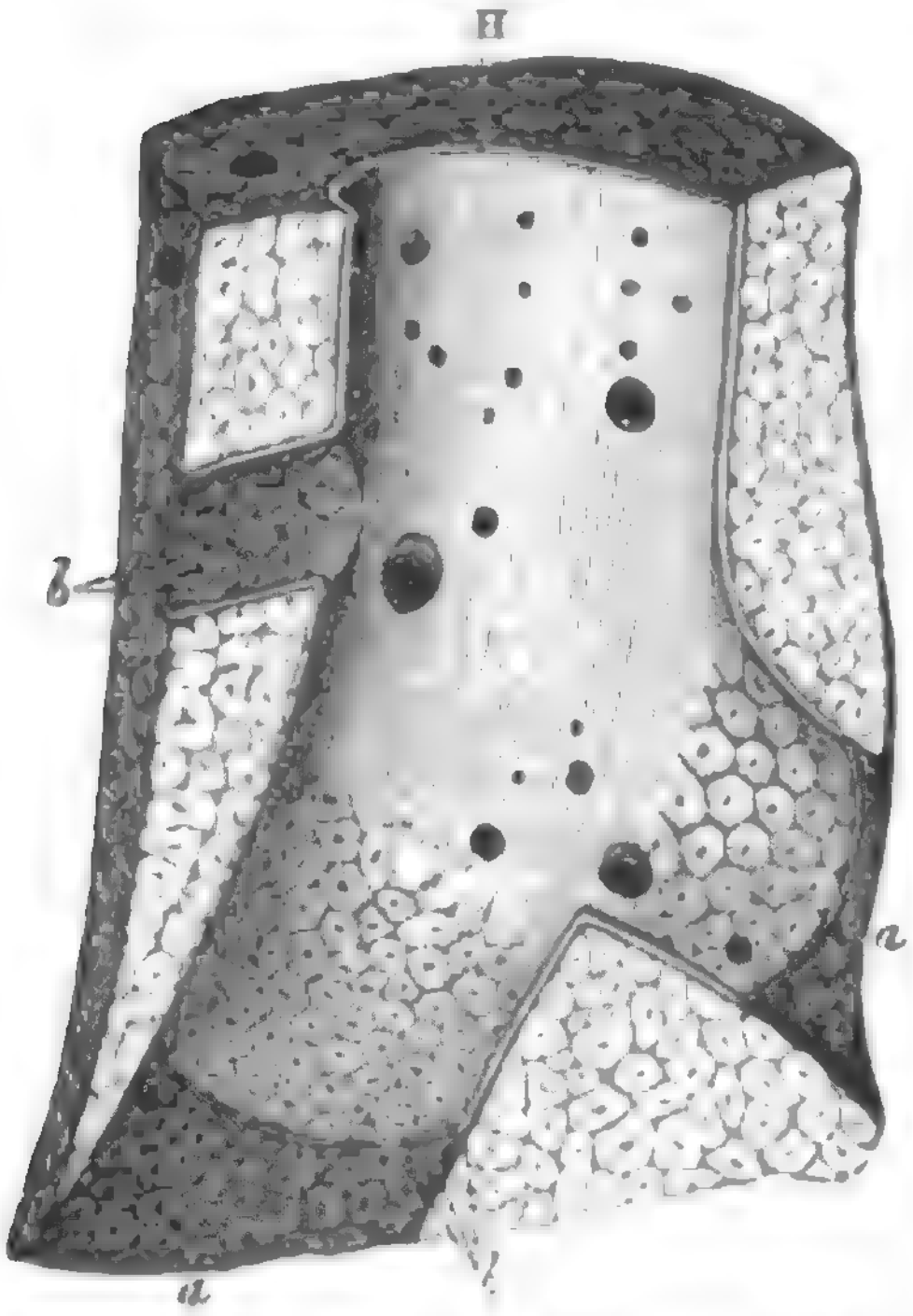

H, Longitudinal Section of an Hepatic Vein: *a*, portion of the canal from which the vein has been removed; *b*, orifices of ultimate twigs of the vein (intralobular), situated in the centre of the lobules (after Kiernan).

Fig. 593.

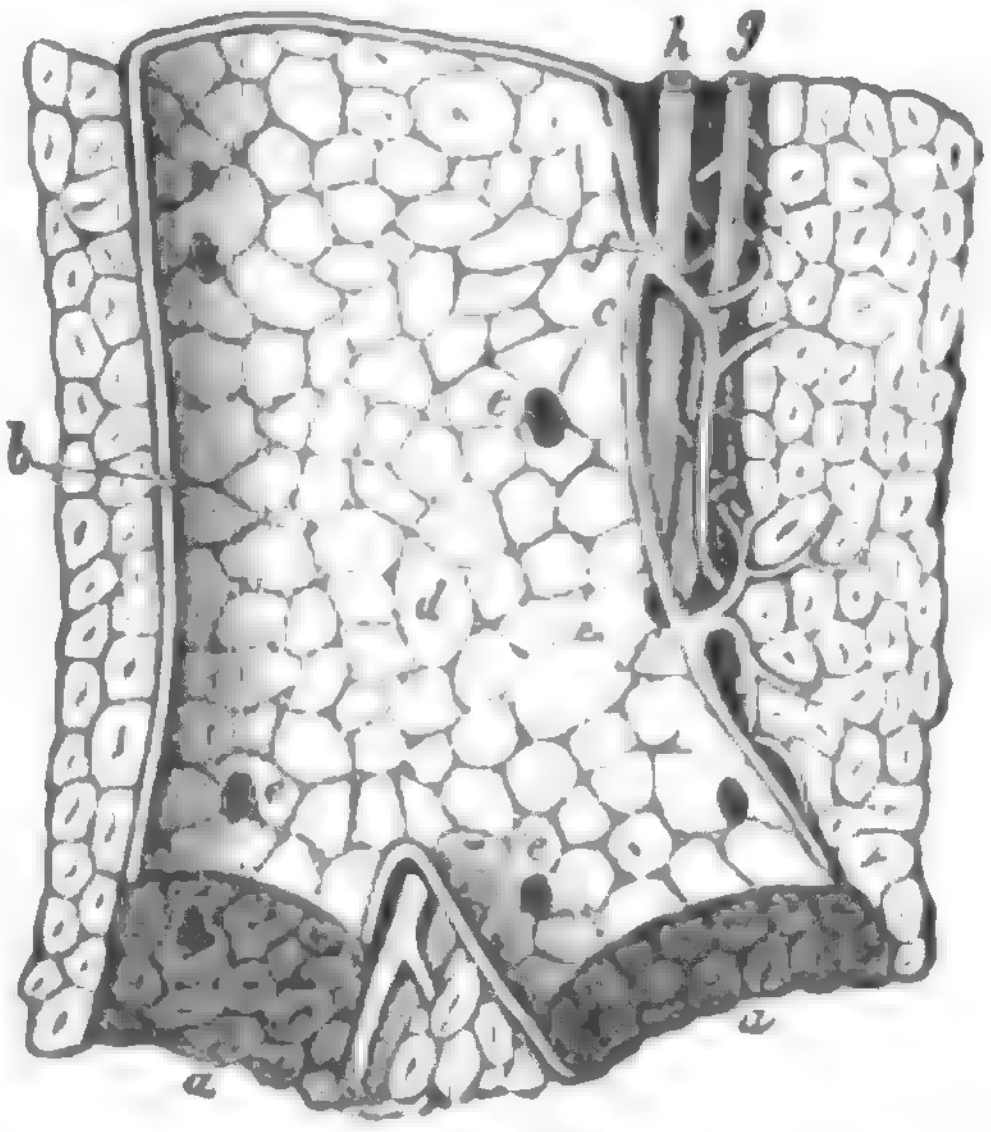

Longitudinal Section of a Small Portal Vein and Canal (after Kiernan): *a*, portions of the canal from which the vein has been removed; *b*, side of the portal vein in contact with the canal; *c*, the side of the vein which is separated from the canal by the hepatic artery and duct, with areolar tissue (Glisson's capsule); *d*, internal surface of the portal vein, through which are seen the outlines of the lobules and the openings, *e*, of the interlobular veins; *f*, vaginal veins of Kiernan; *g*, hepatic artery; *h*, hepatic duct.

1. *The hepatic cells* are of more or less spheroidal form, but may be rounded,

flattened, or many-sided from mutual compression. They vary in size from the $\frac{1}{1000}$ to the $\frac{1}{2000}$ of an inch in diameter. They consist of a honeycomb network (Klein) without any cell-wall, and contain one or sometimes two distinct nuclei. In the nucleus is a highly refracting nucleolus with granules. Imbedded in the honeycomb network are numerous yellow particles, the coloring matter of the bile, and oil-globules. The cells adhere together by their surfaces so as to form rows which radiate from the centre to the circumference of the lobules. As stated above, they are the chief agents in the secretion of the bile.

2. *The Blood-vessels.*—The blood in the capillary plexus around the liver-cells is brought to the liver principally by the portal vein, but also to a certain extent by the hepatic artery. For the sake of clearness the distribution of the blood derived from the hepatic artery may be considered first.

The hepatic artery, entering the liver at the transverse fissure with the portal vein and hepatic duct, ramifies with these vessels through the portal canals. It gives off *vaginal* branches which ramify in the capsule of Glisson, and appear to be destined chiefly for the nutrition of the coats of the large vessels, the ducts, and the investing membranes of the liver. It also gives off *capsular* branches which reach the surface of the organ, terminating in its fibrous coat in stellate plexuses. Finally, it gives off interlobular branches which form a plexus on the outer side of each lobule to supply its wall and the accompanying bile-ducts. From this offsets enter the lobule and end in the capillary network between the cells. Some anatomists, however, doubt whether it transmits any blood directly to the capillary network.

The *portal vein* (Fig. 593) also enters at the transverse fissure and runs through the portal canals enclosed in Glisson's capsule, dividing into branches in its course, which finally break up into a plexus (the *interlobular plexus*) in the interlobular spaces between the lobules. In their course they receive the vaginal and capsular veins, corresponding to the vaginal and capsular branches of the hepatic artery (Fig. 593). Thus it will be seen that all the blood carried to the liver by the portal vein and hepatic artery, except perhaps that derived from the interlobular branches of the hepatic artery, directly or indirectly finds its way into the interlobular plexus. From this plexus the blood is carried into the lobule by fine branches which pierce its wall, and then converge from the circumference to the centre of the lobule, forming a number of longitudinal vessels which are connected by transverse or horizontal branches (Fig. 594). In the interstices of the network of vessels thus formed are situated, as before said, the liver-cells; and here it is that, the blood being brought into intimate connection with the liver-cells, the bile is secreted. Arrived at the centre of the lobule, all these minute vessels empty themselves into one vein of considerable size which runs down the centre of the lobules from apex to base, and is called the *intralobular vein*. At the base of the lobule this vein opens directly into the *sublobular* vein, with which the lobule is connected, and which, as before mentioned, is a radicle of the hepatic vein. The sublobular veins, uniting into larger and larger trunks, end at last in the hepatic veins, which do not receive any intralob-

FIG. 594.

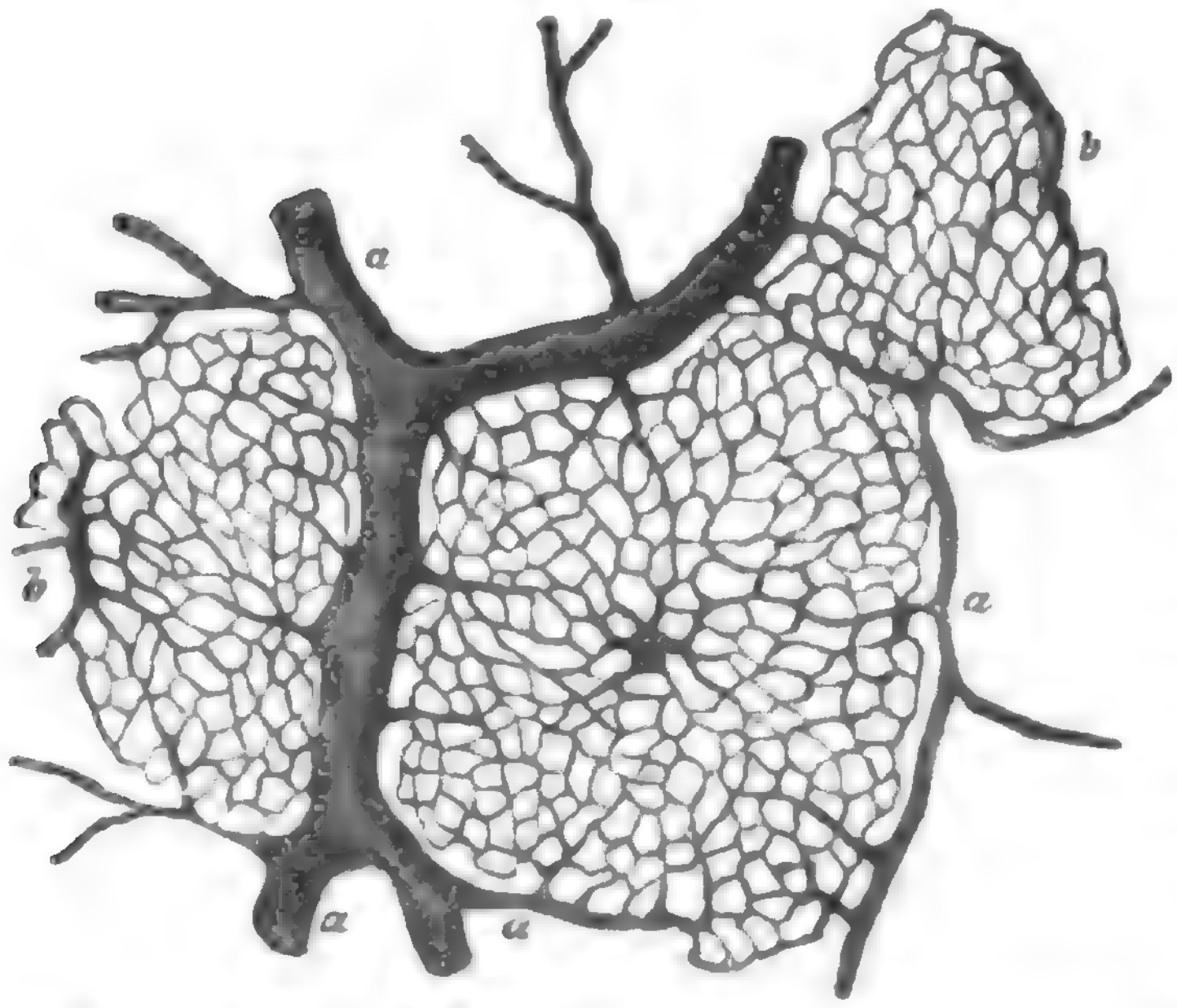

Horizontal Section of Liver (dog): the vena portæ has been injected: *a*, trunk of interlobular vein: *b*, trunk of intralobular vein. A dense system of capillary vessels lies between them.

ular veins. Finally, the hepatic veins, as mentioned at p. 634, converge to form three large trunks which open into the vena cava inferior, while that vessel is situated in the fissure appropriated to it at the back of the liver.

3. *The Ducts.*—Having shown how the blood is brought into intimate relation with the hepatic cells in order that the bile may be secreted, it remains now only to consider the way in which the secretion, having been formed, is carried away. Several views have prevailed as to the mode of origin of the hepatic ducts: it seems, however, to be clear that they commence by little passages which are formed between the cells, and which have been termed *intercellular biliary passages* or *bile-capillaries* (Fig. 595). These passages are merely little channels or interspaces left between the contiguous surfaces of two cells or in the angle where three or more liver-cells meet (Fig. 595, *c* and *d*), and it seems doubtful whether there is any delicate membrane forming the wall of the space. The channels thus formed radiate to the circumference of the lobule, and, piercing its wall, form a plexus (*interlobular*) between the lobules. From this plexus ducts are derived which pass into the portal canals, become enclosed in Glisson's capsule, and, accompanying the portal vein and hepatic artery (Fig. 596), join with other ducts to form two main trunks which leave the liver at the transverse fissure and by their union form the hepatic duct.

FIG. 595.

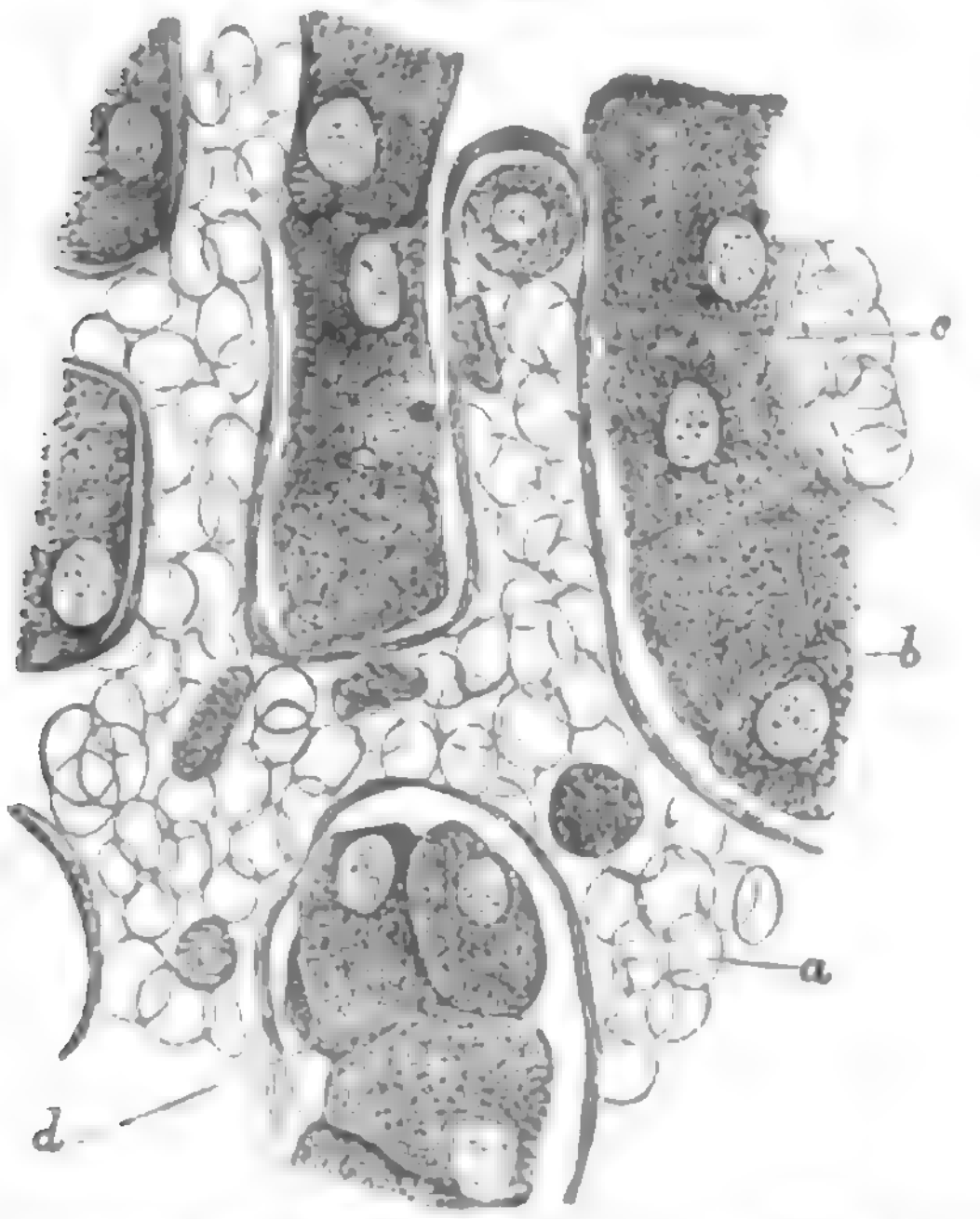

Microscopical Section from the Liver of a Child Three Months Old, hardened in chromic acid. The hepatic cells (*b*), with their single nuclei, are separated from the capillary wall by a small intervening space. The capillaries (*a*) contain closely compressed colored, and a few colorless, blood-corpuscles. A few elongated nuclei belonging to the capillary wall are seen. Within the line of junction (septum), between two hepatic cells, the transverse section of a biliary duct is seen as a small transparent space (*c*). There is also one at the angle, where several of these cells come into contact (*d*).

FIG. 596.

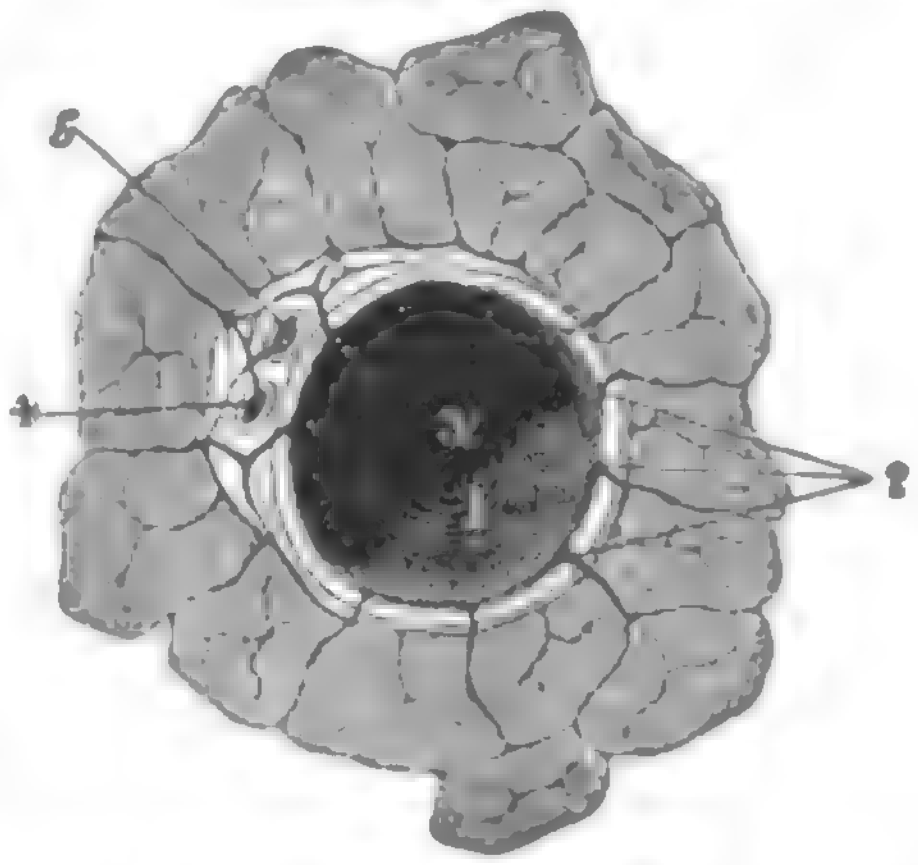

A Transverse Section of a Small Portal Canal and its Vessels (after Kiernan): 1, portal vein; 2, interlobular branches; 3, vaginal branches; 4, hepatic duct; 5, hepatic artery.

GALL-BLADDER.

The **Gall-bladder** is the reservoir for the bile; it is a conical or pear-shaped membranous sac lodged in a fossa on the under surface of the right lobe of the liver, and extending from near the right extremity of the transverse fissure to the anterior free margin of the organ. It is about four inches in length, one inch in breadth at its widest part, and holds from eight to ten drachms. It is divided into a fundus, body, and neck. The *fundus*, or broad extremity, is directed downward, forward, and to the right, and occasionally projects beyond the anterior border of the liver; the *body* and *neck* are directed upward and backward to the left. The gall-bladder is held in its position by the peritoneum, which in the majority of cases passes over its under surface, but the serous membrane occasionally invests the gall-bladder, which then is connected to the liver by a kind of mesentery.

RELATIONS.—The *body* of the gall-bladder is in relation, by its upper surface, with the liver, to which it is connected by areolar tissue and vessels; by its under surface with the first portion of the duodenum, occasionally the pyloric end of the stomach, and the hepatic flexure of the colon. The *fundus* is completely invested by peritoneum; it is in relation in front with the abdominal parietes, immediately below the ninth costal cartilage; behind with the transverse arch of the colon. The *neck* is narrow, and curves upon itself like the italic letter *f*; at its point of connection with the body and with the cystic duct it presents a well-marked constriction.

When the gall-bladder is distended with bile or calculi the fundus may be felt through the abdominal parietes, especially in an emaciated subject: the relations of this sac will also serve to explain the occasional occurrence of abdominal biliary fistulæ, through which biliary calculi may pass out, and of the passage of calculi from the gall-bladder into the stomach, duodenum, or colon, which occasionally happens. [The gall-bladder may be reached by laparotomy, and be opened (cholecystotomy) for removal of gall-stones, or may itself be entirely excised (cholecystectomy.[1] When the gall-bladder is distended, the fluid is usually not bile, but mucus secreted from its own mucous membrane.]

Structure.—The gall-bladder consists of three coats—serous, fibrous and muscular, and mucous.

The *external* or *serous coat* is derived from the peritoneum; it completely invests the fundus, but covers the body and neck only on their under surface.

The *middle* or *fibrous coat* is a thin but strong fibrous layer which forms the framework of the sac, consisting of dense fibres which interlace in all directions. Plain muscular fibres are also found in this coat, disposed chiefly in a longitudinal direction, a few running transversely.

The *internal* or *mucous coat* is loosely connected with the fibrous layer. It is generally tinged with a yellowish-brown color, and is everywhere elevated into minute rugæ by the union of which numerous meshes are formed, the depressed intervening spaces having a polygonal outline. The meshes are smaller at the fundus and neck, being most developed about the centre of the sac. Opposite the neck of the gall-bladder the mucous membrane projects inward so as to form a large valvular fold.

The mucous membrane is covered with columnar epithelium and secretes an abundance of thick, viscid mucus; it is continuous through the hepatic duct with the mucous membrane lining the ducts of the liver, and through the ductus communis choledochus with the mucous membrane of the alimentary canal.

The *Biliary Ducts* are the hepatic, the cystic, and the ductus communis choledochus.

The **hepatic duct** is formed of two trunks of nearly equal size which issue from the liver at the transverse fissure, one from the right, the other from the left lobe; these unite and pass downward and to the right for about an inch and a half, to join at an acute angle with the cystic duct, and so form the ductus communis choledochus.

The **cystic duct**, the smallest of the three biliary ducts, is about an inch in length. It passes obliquely downward and to the left from the neck of the gall-bladder, and joins the hepatic duct to form the common duct. It lies in the gastro-hepatic omentum in front of the vena portæ, the hepatic artery lying to its left side. The mucous membrane lining its interior is thrown into a series of crescentic folds; from five to twelve in number, which project into the duct in regular succession, and are directed obliquely round the tube, presenting much the appearance of a continuous spiral valve. They exist only in the human subject. When the duct has been distended the interspaces between the folds are dilated, so as to give to its exterior a sacculated appearance.

The **ductus communis choledochus**, the largest of the three, is the common excretory duct of the liver and gall-bladder. It is about three inches in length, of the diameter of a goose-quill, and formed by the junction of the cystic and hepatic ducts.

It descends along the right border of the lesser omentum behind the first por-

---

[[1] See two papers by the American Editor, *Amer. Journ. Med. Sci.*, Jan., 1879, and Oct., 1884.]

tion of the duodenum, in front of the vena portæ and to the right of the hepatic artery; it then passes between the pancreas and descending portion of the duodenum, and, running for a short distance along the right side of the pancreatic duct near its termination, passes with it obliquely between the mucous and muscular coats, the two opening by a common orifice upon the summit of a papilla situated at the inner side of the descending portion of the duodenum, a little below its middle.

Structure.—The coats of the biliary ducts are an external or fibrous and an internal or mucous. The fibrous coat is composed of a strong fibro-areolar tissue, with a certain amount of muscular tissue, arranged, for the most part, in a circular manner around the duct. The mucous coat is continuous with the lining membrane of the hepatic ducts and gall-bladder, and also with that of the duodenum, and, like the mucous membrane of these structures, its epithelium is of the columnar variety. It is provided with numerous mucous glands, which are lobulated and open by minute orifices which are scattered irregularly in the larger ducts. In the smaller ducts, which lie in the portal canals in the substance of the liver, are also a number of orifices disposed in two longitudinal rows, which were formerly regarded as the openings of mucus-glands, but are merely the orifices of tubular recesses, which occasionally anastomose and from the sides of which saccular dilatations are given off.

THE PANCREAS.

Dissection.—The pancreas may be exposed for dissection in three different ways: 1, by raising the liver, drawing down the stomach, and tearing through the gastro-hepatic omentum and the ascending layer of the transverse mesocolon; 2, by raising the stomach, the arch of the colon, and great omentum, and then dividing the inferior layer of the transverse mesocolon; 3, by dividing the two layers of peritoneum which descend from the great curvature of the stomach to form the great omentum, turning the stomach upward, and then cutting through the ascending layer of the transverse mesocolon. (See Fig. 567, p. 861.)

The **Pancreas** (*παν-χρέας*, all flesh) is a compound racemose gland analogous in its structure to the salivary glands. In shape it is transversely oblong, flattened from before backward, and bears some resemblance to a dog's tongue, its right extremity being broad and presenting a sort of angular bend from above downward, called the *head*, whilst its left extremity gradually tapers to form the tail, the intermediate portion being called the *body*. It is situated transversely across the posterior wall of the abdomen at the back of the epigastric and left hypochondriac regions. Its length varies from six to eight inches, its breadth is an inch and a half, and its thickness from half an inch to an inch, being greater at its right extremity and along its upper border. Its weight varies from two to three and a half ounces, but it may reach six ounces.

The *right extremity* or *head* of the pancreas (Fig. 597) is curved upon itself from above downward, and is embraced by the concavity of the duodenum. The common bile-duct descends behind between the duodenum and pancreas, and the pancreatico-duodenal artery descends in front between the same parts. On the posterior aspect of the pancreas is a lobular fold of the gland which passes transversely to the left behind the superior mesenteric vessels, and thus these vessels are embraced by the substance of the gland. It is sometimes detached from the rest of the gland, and is called the *lesser pancreas*.

The *lesser end* or *tail* of the pancreas is narrow; it extends to the left as far as the spleen, and is placed over the left kidney and suprarenal capsule.

The *body* of the pancreas is convex in front, and covered by the ascending layer of the transverse mesocolon and the posterior surface of the stomach.

The *posterior surface* is concave, and has the following structures interposed between it and the first lumbar vertebra: the superior mesenteric artery and vein, the inferior mesenteric vein, the commencement of the vena portæ, the vena cava, the aorta, the left renal vein, and the crura of the diaphragm.

The *upper border* is thick, and has resting upon it, near its centre, the cœliac axis; the splenic artery and vein are lodged in a deep groove or canal in this border; and to the right the first part of the duodenum and the hepatic artery are in relation with it.

The *lower border*, thinner than the upper, is separated from the transverse portion of the duodenum by the superior mesenteric artery and vein; to the left of these the inferior mesenteric vein ascends behind the pancreas to join the splenic vein.

The **pancreatic duct**, called the **canal of Wirsung**, from its discoverer, extends transversely from left to right through the substance of the pancreas, nearer to its lower than its upper border, and lying nearer its anterior than its posterior surface. In order to expose it the superficial portion of the gland must be removed. It commences by the junction of the small ducts of the lobules situated in the tail of the pancreas, and running from left to right; it constantly receives the ducts of the various lobules composing the gland, and, considerably augmented in size, then leaves the head of the pancreas. Descending slightly, it gets into relation with the common bile-duct, lying to its left side; and, passing very obliquely through the mucous and muscular coats of the duodenum, it terminates by an orifice common to it and the ductus communis choledochus upon the summit of an elevated papilla situated at the inner side of the descending portion of the duodenum, a little below its middle.

Fig. 597.

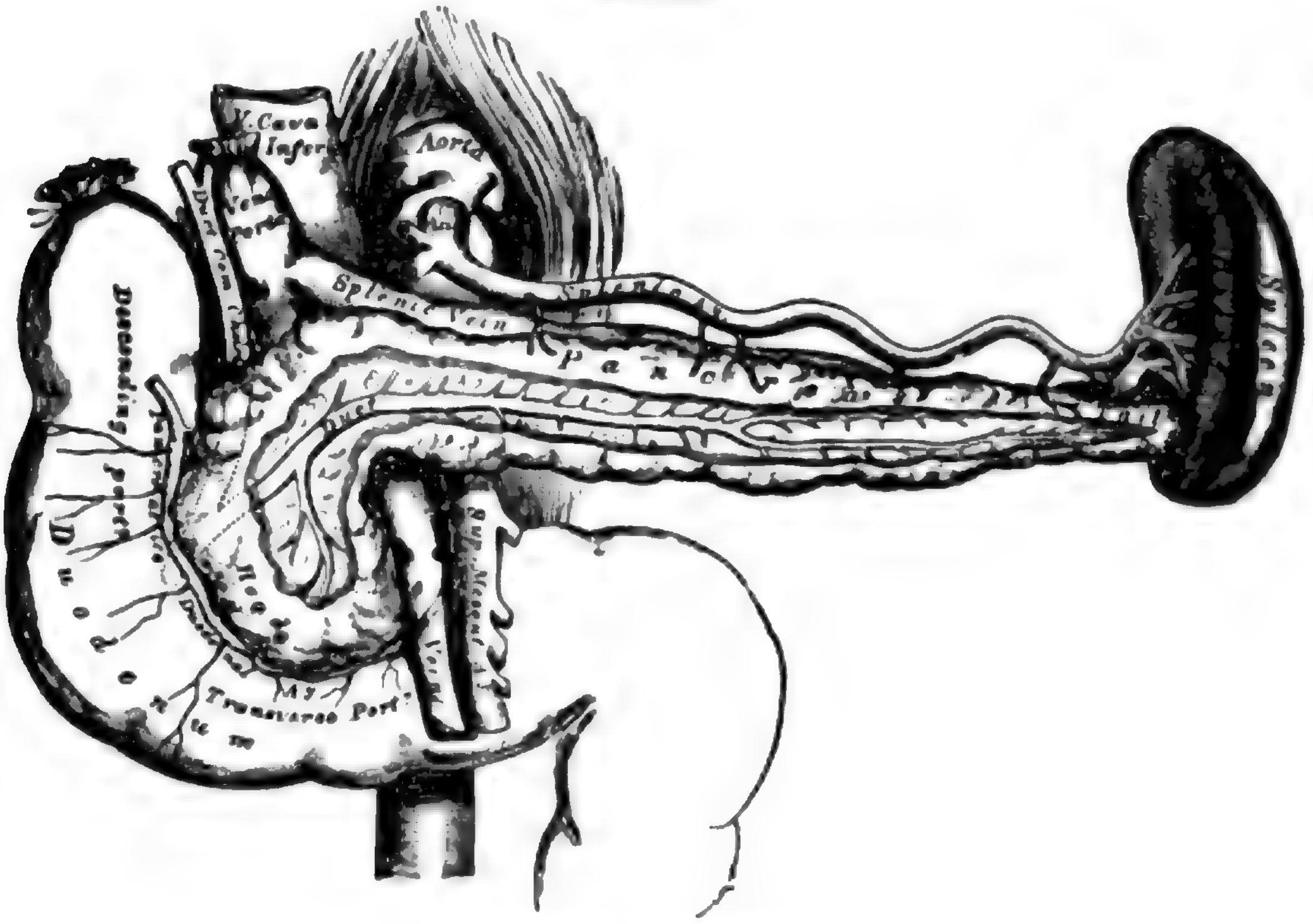

The Pancreas and its Relations.

Sometimes the pancreatic duct and ductus communis choledochus open separately into the duodenum. The excretory duct of the lesser pancreas is called the *ductus pancreaticus minor;* it opens into the main duct near the duodenum, and sometimes separately into that intestine, at a distance of an inch or more from the termination of the principal duct.

The pancreatic duct, near the duodenum, is about the size of an ordinary quill: its walls are thin, consisting of two coats, an external fibrous and an internal mucous; the latter is thin, smooth, and furnished near its termination with a few scattered follicles.

Sometimes the pancreatic duct is double up to its point of entrance into the duodenum.

In **structure** the pancreas resembles the salivary glands. It differs from them, however, in certain particulars, and is looser and softer in its texture. It is not enclosed in a distinct capsule, but is surrounded by areolar tissue, which dips down into its interior and connects together the various lobules of which it is composed. Each lobule, like the lobules of the salivary glands, consists of one of the ultimate ramifications of the pancreatic duct, terminating in a number of cæcal pouches or acini. The minute ducts are lined by short columnar epithelium, shorter than that found in the salivary ducts, and the acini are wavy and convoluted. They also are lined by columnar cells, which present certain characteristics, each cell showing an outer homogeneous or faintly striated portion, which becomes deeply stained with dyes, and contains the nucleus and an inner granular portion which does not easily stain. The lumen of the alveolus is hardly visible, being filled with an interstitial substance containing spindle-shaped cells, the *centro-acinar* cells of Langerhaus.

VESSELS AND NERVES.—The *arteries* of the pancreas are derived from the splenic and the pancreatico-duodenal branches of the hepatic and the superior mesenteric. Its *veins* open into the splenic and superior mesenteric veins. Its *lymphatics* terminate in the lumbar glands. Its *nerves* are filaments from the splenic plexus.

[For the surgery of the Pancreas the student is referred to Dr. N. Senn's elaborate paper, *Amer. Journ. Med. Sci.*, July, 1886.]

THE SPLEEN.

The **Spleen** was formerly classified, together with the thyroid, thymus, and suprarenal capsules, as one of the ductless or blood-glands. It possesses no excretory duct. It is of an oblong flattened form, soft, of very brittle consistence, highly vascular, of a dark bluish-red color, and situated in the left hypochondriac region, embracing the cardiac end of the stomach. It is invested by peritoneum, and connected with the stomach by the gastro-splenic omentum.

RELATIONS.—The *external surface* is convex, smooth, and in relation with the under surface of the Diaphragm, which separates it from the ninth, tenth, and eleventh ribs of the left side. The *internal surface* is slightly concave, and divided by a vertical fissure, the *hilum*, into an anterior or larger and a posterior or smaller portion. The hilum is pierced by several irregular apertures for the entrance and exit of vessels and nerves. At the margins of the hilum the two layers of peritoneum are reflected from the surface of the spleen on to the cardiac end of the stomach, forming the gastro-splenic omentum, which contains between its layers the splenic vessels and nerves and the vasa brevia. The internal surface is in relation in front with the great end of the stomach; below with the tail of the pancreas; and behind with the left crus of the Diaphragm and corresponding suprarenal capsule. The *upper end*, thick and rounded, is in relation with the Diaphragm, to which it is connected by a fold of peritoneum, the suspensory ligament. The *lower end* is pointed; it is in relation with the left extremity of the transverse arch of the colon. The *anterior margin* is free, rounded, and often notched, especially below. The *posterior margin* is rounded, and lies in relation with the left kidney, to which it is connected by loose areolar tissue.

The spleen is held in its position by two folds of peritoneum: one, the *gastro-splenic omentum*, connects it with the stomach; and the other, the *suspensory ligament*, with the under surface of the Diaphragm. It is also supported by the costo-colic ligament, upon which its lower end rests (see p. 869).

The size and weight of the spleen are liable to very extreme variations at different periods of life in different individuals and in the same individual under different conditions. In the *adult*, in whom it attains its greatest size, it is usually about five inches in length, three or four inches in breadth, and an inch or an inch and a half in thickness, and weighs about seven ounces. At *birth* its weight, in proportion to the entire body, is almost equal to what is observed in the adult, being as 1 to 350, whilst in the adult it varies from 1 to 320 and 400. In *old age* the organ not only decreases in weight, but decreases considerably in proportion to the entire body, being as 1 to 700. The size of the spleen is increased during and after digestion, and varies considerably according to the state of nutrition of the body, being large in highly-fed and small in starved animals. In intermittent and other fevers it becomes much enlarged, weighing occasionally from 18 to 20 pounds.

Structure.—The spleen is invested by two coats—an external serous and an internal fibro-elastic coat.

The *external* or *serous coat* is derived from the peritoneum; it is thin, smooth, and in the human subject intimately adherent to the fibro-elastic coat. It invests almost the entire organ, being reflected from it at the hilum on to the great end of the stomach, and at the upper end of the organ on to the Diaphragm.

The *fibro-elastic coat* forms the framework of the spleen. It invests the exterior of the organ, and at the hilum is reflected inward upon the vessels in the form of vaginæ or sheaths. From these sheaths, as well as from the inner surface of the fibro-elastic coat, numerous small fibrous bands, *trabeculæ* (Fig. 598), are given off in all directions; these, uniting, constitute the areolar framework of the spleen. The framework of the spleen resembles, therefore, a sponge-like material, consisting of a number of small spaces or *areolæ*, formed by the trabeculæ which are given off from the inner surface of the capsule or from the sheaths prolonged inward on the blood-vessels; and in these spaces or areolæ is contained the *splenic pulp*.

FIG. 598.

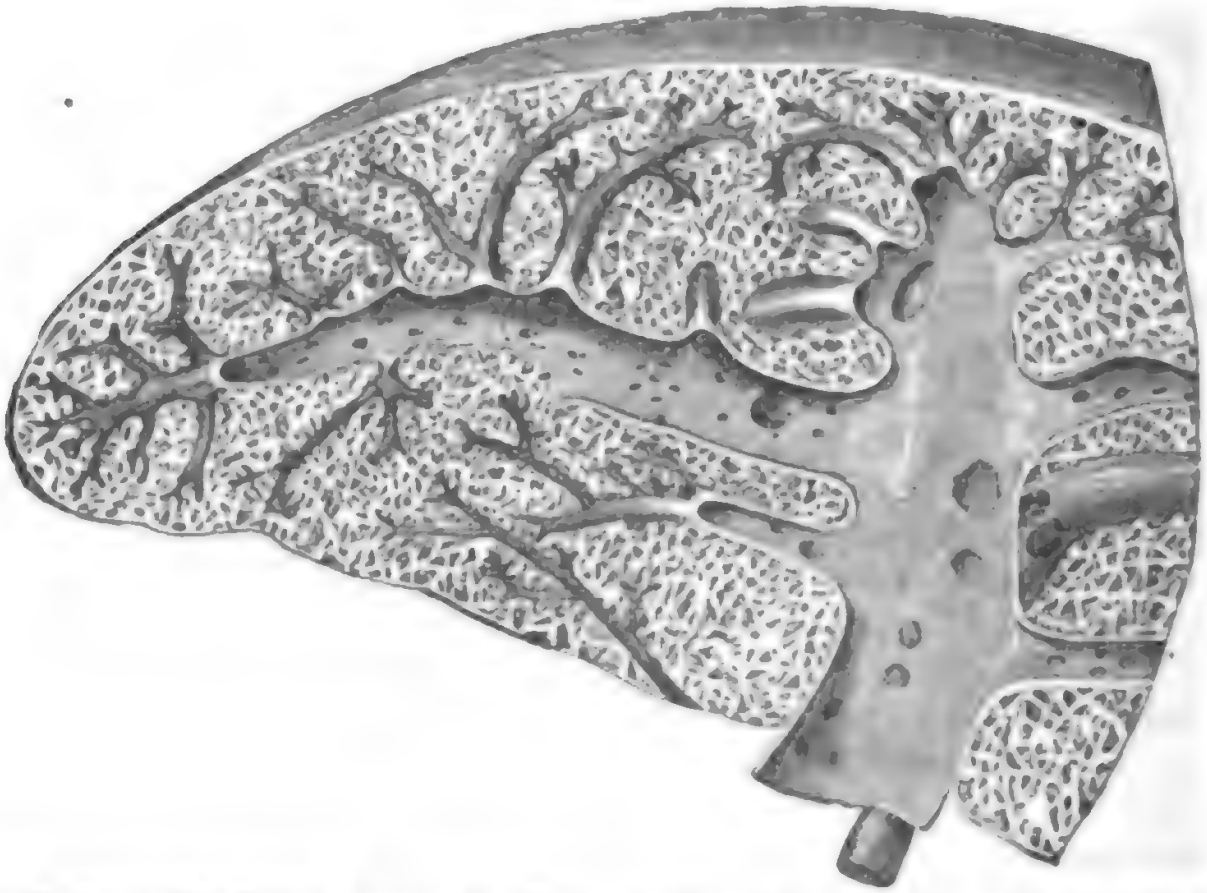

Transverse Section of the Spleen, showing the Trabecular Tissue and the Splenic Vein and its Branches.

The proper coat, the sheaths of the vessels, and the trabeculæ consist of a dense mesh of white and yellow elastic fibrous tissues, the latter considerably predominating. It is owing to the presence of this yellow tissue that the spleen possesses a considerable amount of elasticity to allow of the very great variations in size that it presents under certain circumstances. In some of the Mammalia, in addition to the usual constituents of this tunic, there are found numerous pale, flattened, spindle-shaped, nucleated fibres, like unstriped muscular fibres. It is probably owing to this structure that the spleen exhibits, when acted upon by the galvanic current, faint traces of contractility.

The *proper substance of the spleen* or *spleen-pulp* is a soft mass of a dark reddish-brown color, resembling grumous blood. When examined by means of a thin section under the microscope, it is found to consist of a number of branching cells and of an intercellular substance. The cells are connective-tissue corpuscles, and have been named the *sustentacular* or supporting cells of the pulp. The processes of these branching cells communicate with each other, thus forming a delicate reticulated tissue in the interior of the areolæ formed by the trabeculæ of the capsule, so that each primary space may be considered to be divided into a number of smaller spaces by the junction of these processes of the branching corpuscles. These secondary spaces contain blood, in which, however, the white corpuscles are found to be in larger proportions than they are in ordinary blood. The sustentacular cells are either small, uninucleated, or larger, multinucleated cells; they do not become deeply stained with carmine, like the cells of the Malpighian bodies, presently to be described (W. Müller), but like them they possess amœboid movements (Cohnheim). In many of them may be seen deep-red or reddish-yellow granules of various sizes, which present the characters of the hæmatin of the blood. Sometimes also unchanged blood-disks are seen included in these cells, but more frequently blood-disks are found which are altered both in form and color. In fact, blood-corpuscles in all stages of disintegration may be noticed to occur within them. Klein has recently pointed out that sometimes these cells, in the young spleen, contain a proliferating nucleus; that is to say, the nucleus is of large size and presents a number of knob-like projections, as if small nuclei were budding from it by a process of gemmation. This observation is of importance, as it may explain one possible source of the colorless blood-corpuscles.

The interspaces or areolæ formed by the framework of the spleen are thus filled by a delicate reticulum of branched connective-tissue corpuscles, the interstices of which are occupied by blood, and in which the blood-vessels terminate in the manner now to be described.

Blood-vessels of the Spleen.—The splenic artery is remarkable for its large size in proportion to the size of the organ, and also for its tortuous course. It divides into from four to six branches, which enter the hilum of the spleen and ramify throughout its substance (Fig. 599), receiving sheaths from an involution of the external fibrous tissue. Similar sheaths also invest the nerves and veins.

FIG. 599.

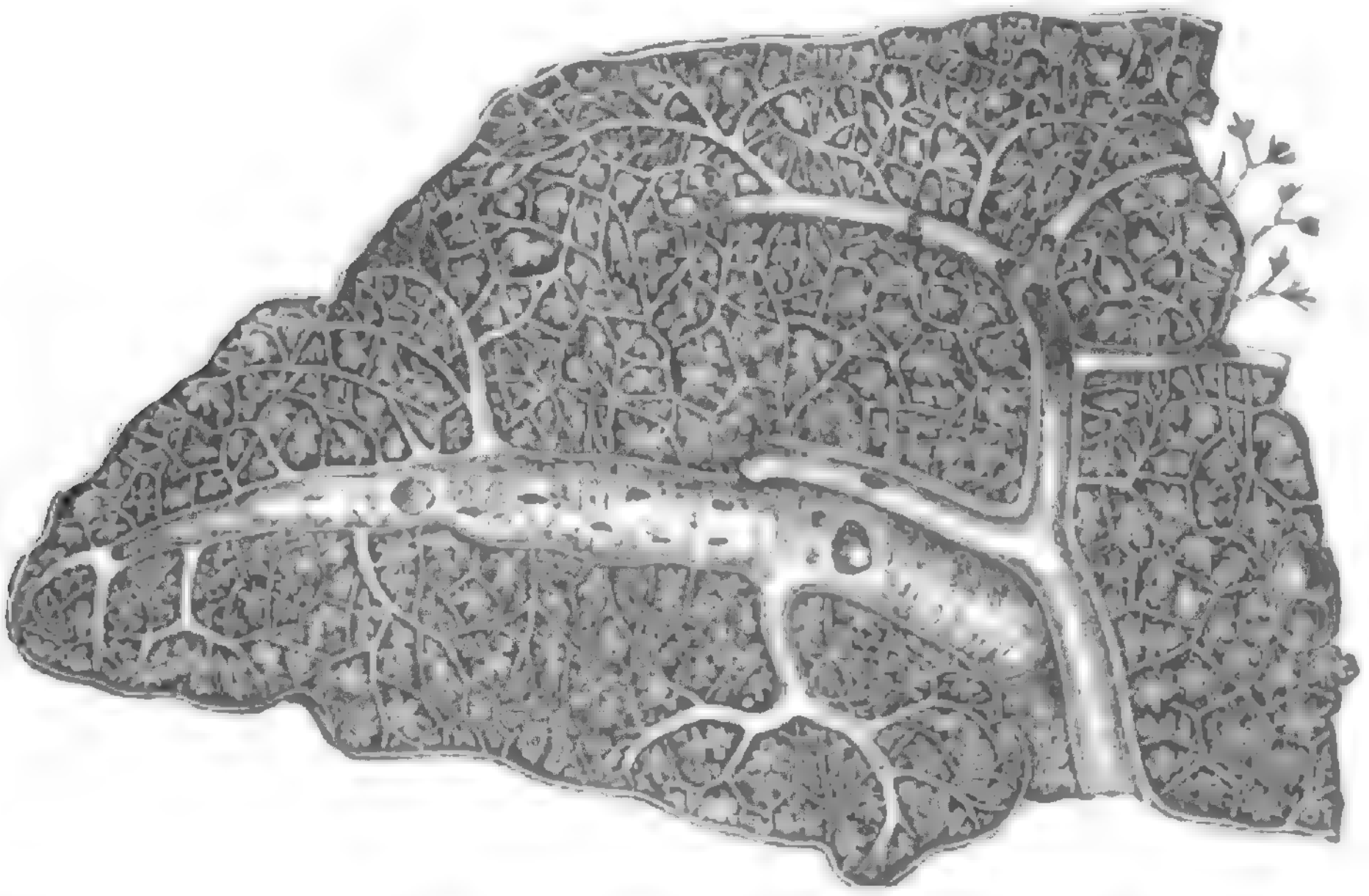

Transverse Section of the Human Spleen, showing the Distribution of the Splenic Artery and its Branches.

Each branch runs in the transverse axis of the organ from within outward, diminishing in size during its transit, and giving off in its passage smaller branches, some of which pass to the anterior, others to the posterior part. These ultimately leave the trabecular sheaths, and terminate in the proper substance of the spleen in small tufts or pencils of minute arterioles, which open into the interstices of the reticulum formed by the branched sustentacular cells. Each of the larger branches of the artery supplies chiefly that region of the organ in which the branch ramifies, having no anastomosis with the majority of the other branches.

The *arterioles*, supported by the minute trabeculæ, traverse the pulp in all directions in bundles or pencilii of straight vessels. Their external coat on leaving the trabecular sheaths consists of ordinary connective tissue, but it gradually undergoes a transformation, becomes much thickened, and converted into a lymphoid material.[1] This change is effected by the conversion of the connective tissue into a cytogenous tissue, the bundles of connective tissue becoming looser and laxer, their fibrils more delicate, and containing in their interstices an abundance of lymph-corpuscles (W. Müller). This lymphoid material is supplied with blood by minute vessels derived from the artery with which they are in contact, and which terminates by breaking up into a network of capillary vessels.

The altered coat of the arterioles, consisting of lymphoid tissue, presents here and there thickenings of a spheroidal shape—the *Malpighian bodies* of the spleen. These bodies vary in size from about the $\frac{1}{100}$ of an inch to the $\frac{1}{25}$ of an inch in diameter. They are merely local expansions or hyperplasiæ of the lymphoid tissue, of which the external coat of the smaller arteries of the spleen is formed. They are most frequently found surrounding the arteriole, which thus seems to tunnel them, but occasionally they grow from one side of the vessel only, and present the appearance of a sessile bud growing from the arterial wall. Klein, however, denies this, and says it is incorrect to describe the Malpighian bodies as isolated masses of adenoid tissue, but that they are always formed around an artery, though there is generally a greater amount on one side than the other, and that, therefore, in transverse sections the artery, in the majority of cases, is found in an excentric position. These bodies are visible to the naked eye on the surface of a fresh section of the organ, appearing as minute dots of a semi-opaque, whitish color in the dark substance of the pulp. In minute structure they resemble the adenoid tissue of lymphatic glands, consisting of a delicate reticulum, in the meshes of which lie ordinary lymphoid cells.

FIG. 600.

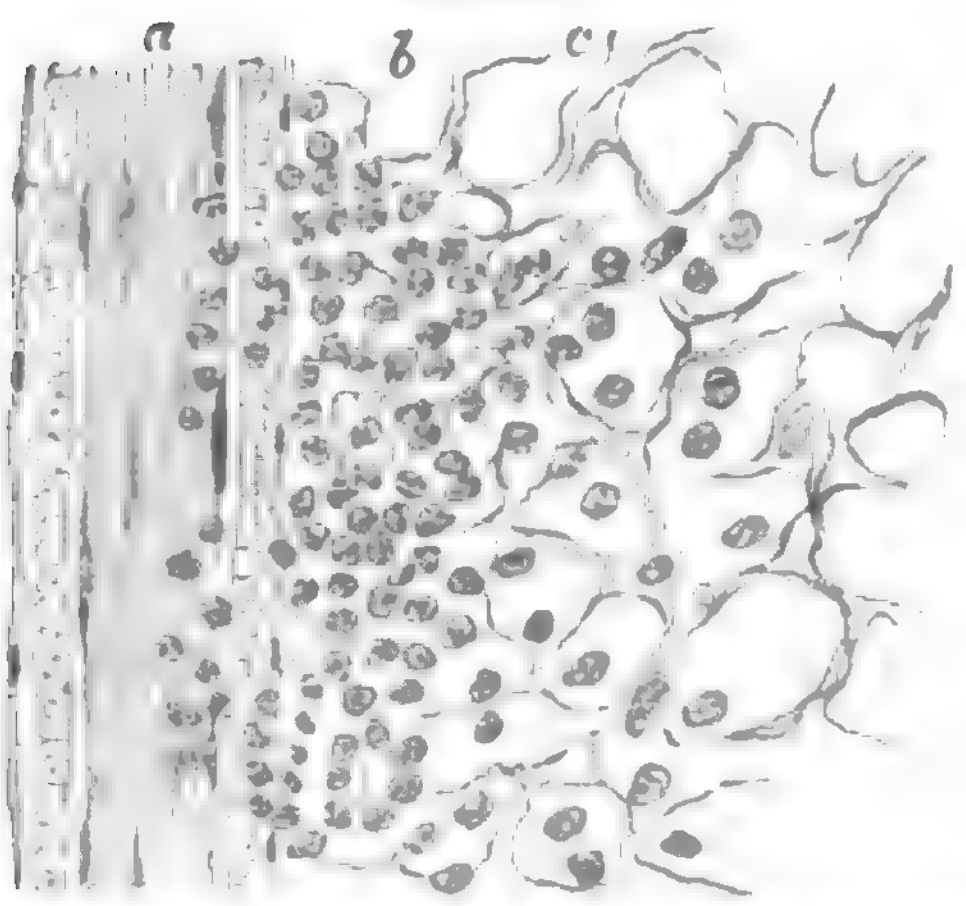

Part of a Malpighian Capsule of the Spleen of Man (Klein and Noble Smith): *a*, arterial branch in longitudinal section; *b*, adenoid tissue, still containing the lymph-corpuscles: only their nuclei are shown; *c*, adenoid reticulum, the lymph-corpuscles accidentally removed.

The reticulum of the tissue is made up of extremely delicate fibrils, and is comparatively open in the centre of the corpuscle, becoming closer at the periphery of the body. The cells which it encloses, like the supporting cells of the pulp, are possessed of amœboid movements, but when treated with carmine become deeply stained, and can thus easily be recognized from those of the pulp.

The arterioles terminate in capillaries which traverse the pulp in all directions; their walls become much attenuated, lose their tubular character, and the cells of the lymphoid tissue of which they are composed become altered, presenting a branched appearance and acquiring processes which are directly connected with the processes of the sustentacular cells of the pulp (Fig. 601). In this manner the capillary vessels terminate, and the blood flowing through them finds its way into the interstices of the reticulated tissue formed by the branched connective-tissue corpuscles of the splenic pulp. Thus the blood passing through the spleen is brought into intimate relation with the elements of the pulp, and no doubt undergoes important changes.

After these changes have taken place the blood is collected from the interstices of the tissue by the rootlets of the veins, which commence much in the same way as the arteries terminate. Where a vein is about to commence, the connective-tissue corpuscles of the pulp arrange themselves in rows in such a way as to form an elongated space or sinus. They become changed in shape, being elongated and spindle-shaped, and overlap each other at their extremities. They thus form a sort of endothelial lining of the path or sinus, which is the radicle of a vein. On the outer surface of these cells are seen delicate transverse lines or markings, which are due to minute elastic fibrillæ arranged in a circular manner around the sinus. Thus the channel obtains a continuous external investment, and gradually becomes converted into a small vein, which after a time presents a coat of ordinary connective tissue lined by a layer of fusiform epithelial cells, which are continuous with the supporting cells of the pulp. The smaller veins unite to form larger ones, which do not accompany the arteries, but soon enter the trabecular sheaths of the capsule, and by their junction form from four to six branches, which emerge from the hilum, and, uniting, form the splenic vein, the largest radicle of the vena portæ.

---

[1] According to Klein, it is the sheath of the small vessel which undergoes this transformation and forms a "solid mass of adenoid tissue which surrounds the vessel like a cylindrical sheath" (*Atlas of Histology*, p. 424).

Fig. 601.

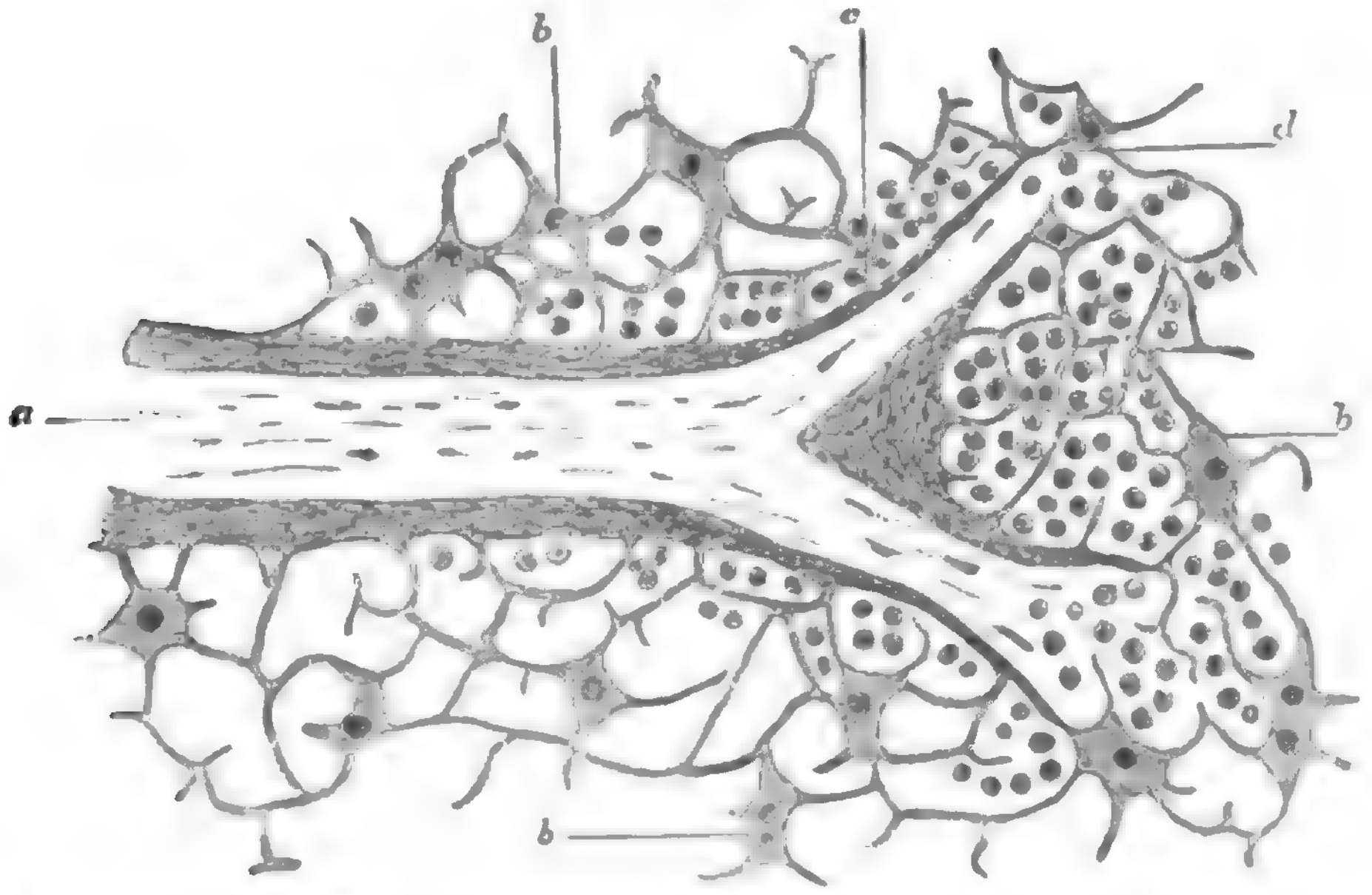

Section of Spleen, showing the Termination of the small Blood-vessels: *a*, **arterial branch in longitudinal section;** *b*, **supporting cells of spleen-pulp;** *c*, **coat of the vessels undergoing lymphoid change;** *d*, **coat of the vessel continuous with the processes of the supporting cells.**

The veins are remarkable for their numerous anastomoses, while the arteries hardly anastomose at all.

The lymphatics originate in two ways—*i. e.* from the sheaths of the arteries and in the trabeculæ. The former accompany the blood-vessels, the latter pass to the superficial lymphatic plexus which may be seen on the surface of the organ. The two sets communicate in the interior of the organ. They pass through the lymphatic glands at the hilum and terminate in the thoracic duct.

The *nerves* are derived from branches of the right and left semilunar ganglia and right pneumogastric nerve.

The Thorax.

THE **Thorax** is a conical framework formed partly of bones and partly of the soft tissues by which they are connected together. It is supported, and its back part is formed, by the middle or dorsal region of the spine. It is narrow above, broad below, flattened before and behind, and somewhat cordiform on a transverse section.

Boundaries.—The thorax is bounded in front by the sternum, the six upper costal cartilages, the ribs and intercostal muscles; at the sides by the ribs and intercostal muscles; and behind by the same structures and the dorsal portion of the vertebral column.

The *superior opening* of the thorax is bounded on each side by the first rib, in front by the upper border of the sternum, and behind by the first dorsal vertebra. It is broader from side to side than from before backward, and its direction is forward and upward. The upper border of the sternum is on a level, in the male, with the lower part of the body of the second dorsal vertebra, and in the female with the lower part of the body of the third. The antero-posterior diameter is about two inches.

The *lower opening*, or *base*, is bounded in front by the ensiform cartilage, behind by the last dorsal vertebra, and on each side by the last rib, the Diaphragm filling in the intervening space. Its direction is obliquely downward and forward, so that the cavity of the thorax is much deeper on the posterior than on the anterior wall. It is wider transversely than from before backward. Its outer surface is convex, but it is more flattened at the centre than at the sides. Its floor is higher on the right than on the left side, corresponding in the dead body to the upper border of the fifth costal cartilage on the right side, and to the corresponding part of the sixth cartilage on the left side.

The parts which pass through the upper opening of the thorax are, from before backward in the middle line, the Sterno-hyoid and Sterno-thyroid muscles, the remains of the thymus gland, the trachea, œsophagus, thoracic duct, and the Longus colli muscles of each side; at the sides, the arteria innominata, the left common carotid and left subclavian arteries, the internal mammary and superior intercostal arteries, the right and left venæ innominatæ, and the inferior thyroid veins, the pneumogastric, sympathetic, phrenic, and cardiac nerves, the anterior branch of the first dorsal nerve, and the recurrent laryngeal nerve of the left side. The apex of each lung, covered by the pleura, also projects through this aperture a little above the margin of the first rib.

The viscera contained in the thorax are the heart, enclosed in its membranous bag, the pericardium; and the lungs, invested by the pleuræ.

THE PERICARDIUM.

The **Pericardium** is a conical membranous sac in which the heart and the commencement of the great vessels are contained. It is placed behind the sternum and the cartilages of the third, fourth, fifth, sixth, and seventh ribs of the left side, in the interval between the pleuræ.

Its *apex* is directed upward, and surrounds the great vessels about two inches above their origin from the base of the heart. Its *base* is attached to the central tendon and part of the adjoining muscular structure of the Diaphragm, extending a little farther to the left than to the right side. In *front* it is separated from the sternum by the remains of the thymus gland above and a little loose areolar tissue below, and is covered by the margins of the lungs, especially the left. *Behind*, it rests upon the bronchi, the œsophagus, and the descending aorta. *Laterally*, it is covered by the pleuræ, the phrenic nerve, with its accompanying vessels, descending between the two membranes on either side.

The pericardium is a fibro-serous membrane, and consists, therefore, of two layers, an external fibrous and an internal serous.

Fig. 602.

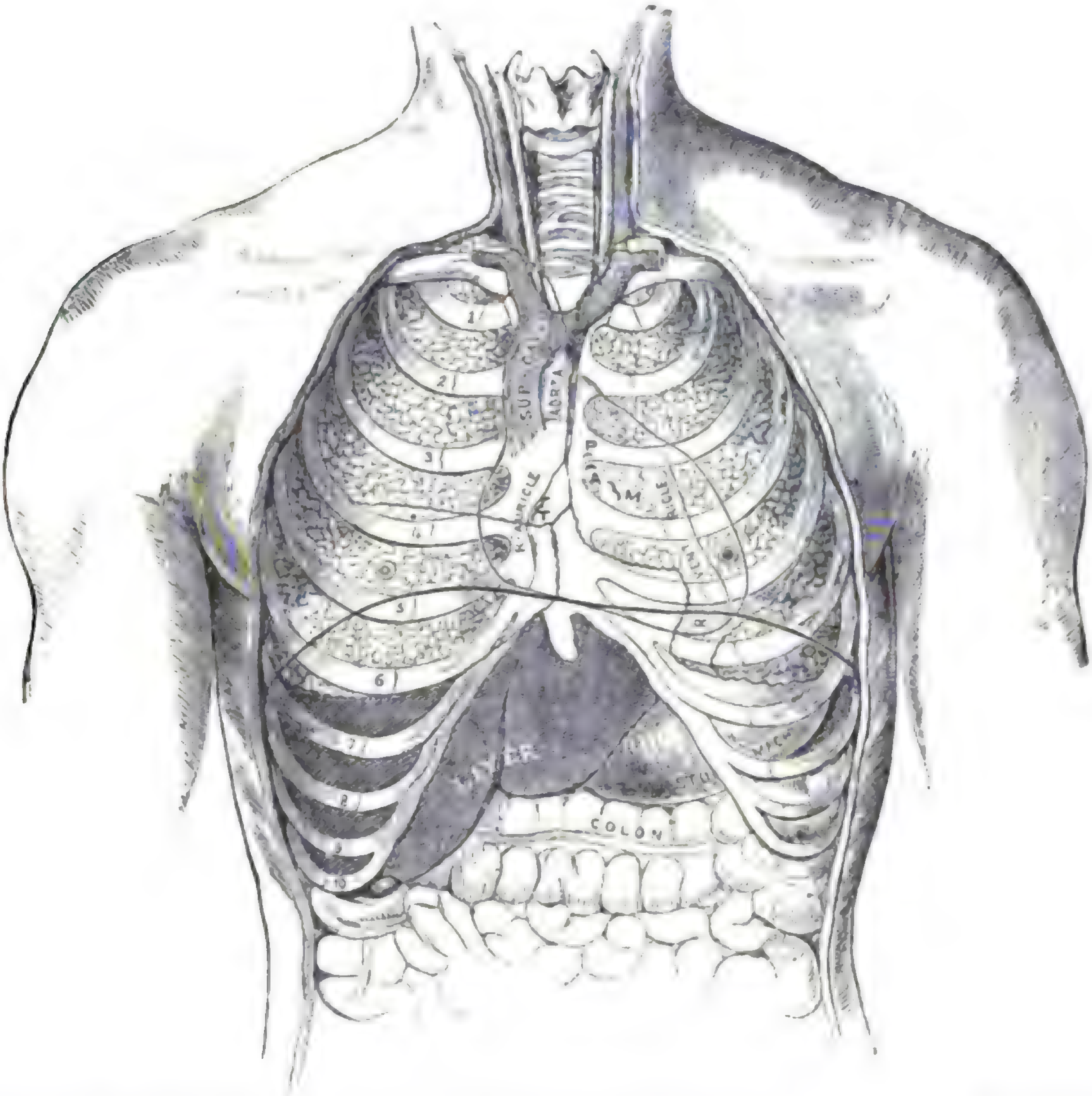

Front View of the Thorax. The ribs and sternum are represented in relation to the lungs, heart, and other internal organs: M, mitral valve; T, tricuspid valve; A, aortic semilunar valves; P, pulmonary semilunar valves.

The *fibrous layer* is a strong, dense membrane. Above, it surrounds the great vessels arising from the base of the heart, on which it is continued in the form of tubular prolongations which are gradually lost upon their external coat, the strongest being that which encloses the aorta. The pericardium may be traced over these vessels to become continuous with the deep layer of the cervical fascia. Below it is attached to the central tendon of the Diaphragm, and on the left side to its muscular fibres.

The vessels receiving fibrous prolongations from this membrane are the aorta, the superior vena cava, the right and left pulmonary arteries, and the four pulmonary veins. As the inferior vena cava enters the pericardium through the central tendon of the Diaphragm, it receives no covering from the fibrous layer.

The *serous layer* invests the heart, and is then reflected on the inner surface of the pericardium. It consists, therefore, of a visceral and parietal portion. The former invests the surface of the heart and the commencement of the great vessels to the extent of two inches from their origin; from these it is reflected upon the inner surface of the fibrous layer, lining below the upper surface of the central tendon of the Diaphragm. The serous membrane encloses the aorta and pulmonary artery in a single tube, but it only partially covers the superior and inferior vena cava and the four pulmonary veins. Its inner surface is smooth and glistening, and secretes a thin fluid which serves to facilitate the movements of the heart.

The arteries of the pericardium are derived from the internal mammary and its musculo-phrenic branch, and from the descending thoracic aorta.

[**Surgery of the Pericardium.**—In pericarditis with effusion the pericardium may be reached in the fifth intercostal space, two to two and a quarter inches to the left of the median line (J. B. Roberts).]

THE HEART.

[*Dissection.*—It is well for the student to dissect, along with the human heart, some bullocks', sheep's, and chickens' hearts. Besides opening the cavities, sections should be made in various directions to obtain a good idea of the relation of parts, especially of the ventricles and their walls.]

The **Heart** is a hollow muscular organ of a conical form placed between the lungs and enclosed in the cavity of the pericardium.

Position.—The heart is placed obliquely in the chest: the broad attached end, or base, is directed upward and backward to the right, and corresponds to the interval between the fifth and eighth dorsal vertebræ; the apex is directed forward, downward, and to the left, and corresponds to the interspace between the cartilage of the fifth and sixth ribs, three-quarters of an inch to the inner side and an inch and a half below the left nipple. The heart is placed behind the lower two-thirds of the sternum, and projects farther into the left than into the right cavity of the chest, extending from the median line about three inches in the former direction and only one and a half in the latter. Its upper border would correspond to a line drawn across the sternum on a level with the second costal cartilages, and its lower border to a line drawn obliquely, with a slight curve downward, from the articulation of the seventh right costal cartilage to the sternum, to the point above mentioned as the situation of the apex. The lungs cover a part of the heart, and during inspiration, when their borders nearly meet behind the sternum, a thin layer of lung covers the roots of all the large vessels. Hence the custom of making a patient hold his breath [in expiration] whilst examining the sounds of the heart. But a considerable portion of the heart is always uncovered by the lungs where they recede from each other below. This "area of the heart's dulness," as it is commonly called, is said by Mr. Holden[1] to be indicated roughly, but sufficiently for practical purposes, by a circle one inch in radius, the centre of which is midway between the left nipple and the end of the sternum. The anterior surface of the heart is round and convex, directed upward and forward, and formed chiefly by the right ventricle and part of the left. Its posterior surface is flattened, and rests upon the Diaphragm, and is formed chiefly by the left ventricle. The right border is long, thin, and sharp; the left border short, but thick and round.

Size.—The heart in the adult measures five inches in length, three inches and a half in breadth in the broadest part, and two inches and a half in thickness. The prevalent weight in the male varies from ten to twelve ounces, in the female from eight to ten: its proportions to the body being as 1 to 169 in males, 1 to 149 in females. The heart continues increasing in weight, and also in length, breadth, and thickness, up to an advanced period of life: this increase is more marked in men than in women.

Component Parts.—The heart is subdivided by a longitudinal muscular septum into two lateral halves, which are named respectively, from their position, right and left; and a transverse constriction divides each half of the organ into two cavities, the upper cavity on each side being called the *auricle*, the lower the *ventricle*. The right is the venous side of the heart, receiving into its auricle the dark venous blood from the entire body by the superior and inferior vena cava and coronary sinus. From the right auricle the blood passes into the right ventricle, and from the right ventricle through the pulmonary artery into the lungs. The blood, arterialized by its passage through the lungs, is returned to the left side of the heart by the pulmonary veins, which open into the left auricle; from the left auricle the blood passes into the left ventricle, and from the left ventricle is distributed by the aorta and its subdivisions through the entire body. This constitutes the circulation of the blood in the adult.

---

[1] *Landmarks, Medical and Surgical,* p. 41.

Fig. 603.

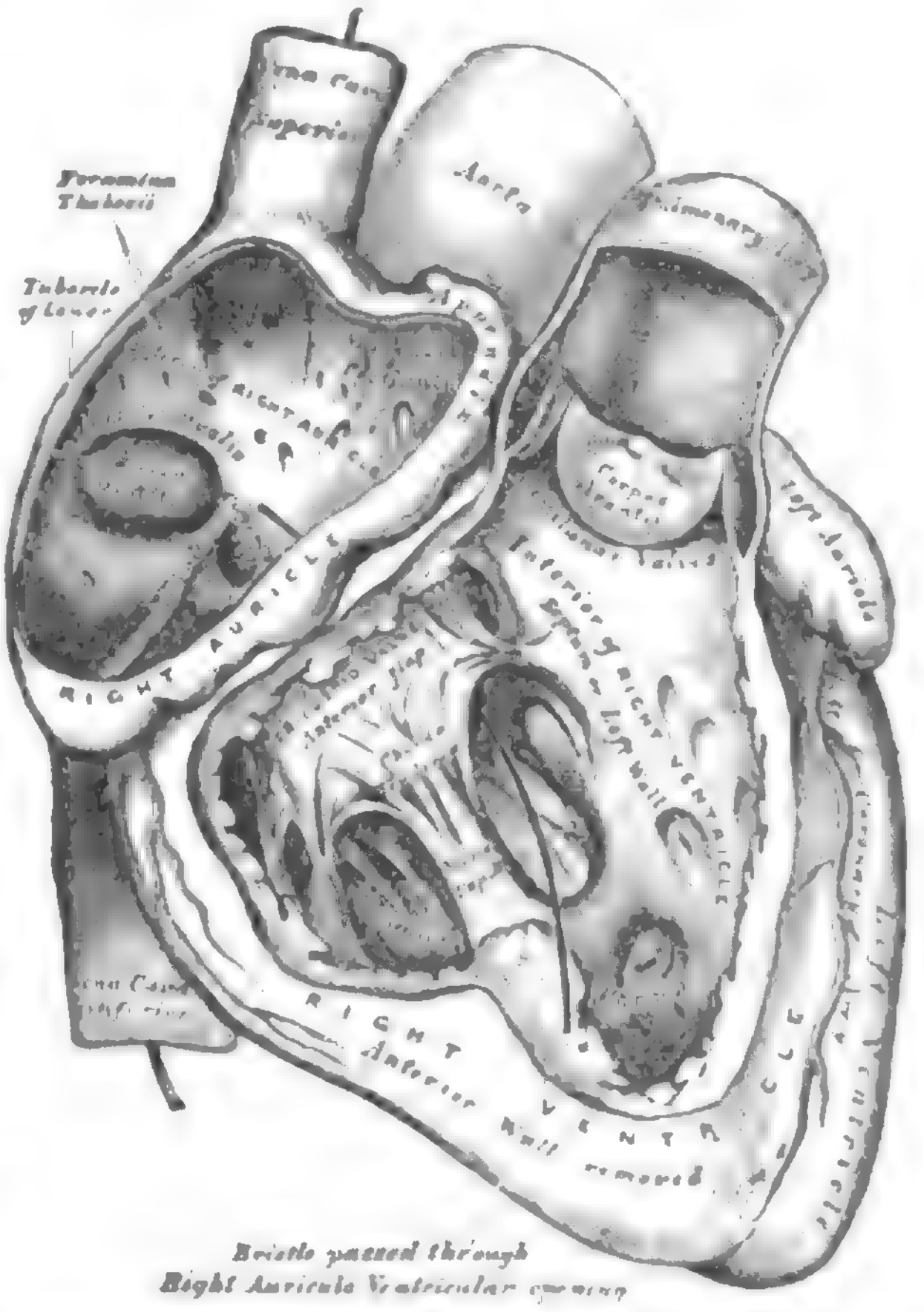

The Right Auricle and Ventricle laid open, the anterior walls of both being removed.

The division of the heart into four cavities is indicated by grooves upon its surface. The great transverse groove separating the auricles from the ventricles is called the *auriculo-ventricular* groove. It is deficient in front from being crossed by the root of the pulmonary artery, and contains the trunks of the nutrient vessels of the heart. The auricular portion occupies the base of the heart, and is subdivided into two cavities by a median septum. The two ventricles are also separated into a right and left by two longitudinal furrows, the *interventricular* grooves, which are situated one on the anterior, the other on the posterior surface: these extend from the base to the apex of the organ, the former being situated nearer to the left border of the heart, and the latter to the right. It follows, therefore, that the right ventricle forms the greater portion of the anterior surface of the heart, and the left ventricle more of its posterior surface.

Each of these cavities should now be separately examined.

The **Right Auricle** is a little larger than the left, its walls somewhat thinner, measuring about one line, and its cavity is capable of containing about two ounces. It consists of two parts—a principal cavity, or *sinus venosus*, and an *appendix auriculæ*.

The *sinus* is the large quadrangular cavity placed between the two venæ cavæ; its walls are extremely thin; it is connected below with the right ventricle, and internally with the left auricle, being free in the rest of its extent.

The *appendix auriculæ*, so called from its fancied resemblance to a dog's ear, is a small conical muscular pouch, the margins of which present a dentated edge. It projects from the sinus forward and to the left side, overlapping the root of the aorta.

To examine the interior of the auricle, an incision should be made along its right border from the entrance of the superior vena cava to that of the inferior. A second cut is to be made from the centre of this first incision to the tip of the auricular appendix, and the flaps raised.

The internal surface of the right auricle is smooth, except in the auricle and adjacent part of the anterior wall of the sinus venosus, where it is thrown into parallel ridges.

It represents the following parts for examination:

- *Openings.*
  - Superior vena cava.
  - Inferior vena cava.
  - Coronary sinus.
  - Foramina Thebesii.
  - Auriculo-ventricular.
- *Valves.*
  - Eustachian.
  - Coronary.
- Musculi pectinati.
- Tuberculum Loweri.
- *Relics of Fœtal Structure.*
  - Annulus ovalis.
  - Fossa ovalis.

The *superior vena cava* returns the blood from the upper half of the body, and opens into the upper and back part of the auricle, the direction of its orifice being downward and forward.

The *inferior vena cava*, larger than the superior, returns the blood from the lower half of the body, and opens into the lowest part of the auricle near the septum, the direction of its orifice being upward and inward. The direction of a current of blood through the superior vena cava would consequently be toward the auriculo-ventricular orifice, whilst the direction of the blood through the inferior cava would be toward the auricular septum. This is the normal direction of the two currents in fœtal life.

The *tuberculum Loweri* is a small projection on the right wall of the auricle between the two cavæ. This is most distinct in the hearts of quadrupeds; in man it is scarcely visible. It was supposed by Lower to direct the blood from the superior cava toward the auriculo-ventricular opening.

The *coronary sinus* opens into the auricle between the inferior vena cava and the auriculo-ventricular opening. It returns the blood from the substance of the heart, and is protected by a semicircular fold of the lining membrane of the auricle, the *coronary valve*. The sinus before entering the auricle is considerably dilated—nearly to the size of the end of the little finger. Its wall is partly muscular, and at its junction with the great coronary vein is somewhat constricted, and furnished with a valve consisting of two unequal segments.

The *foramina Thebesii* are numerous minute apertures, the mouths of small veins (*venæ cordis minimæ*), which open on various parts of the inner surface of the auricle. They return the blood directly from the muscular substance of the heart. Some of these foramina are minute depressions in the walls of the heart, presenting a closed extremity.

The *auriculo-ventricular opening* is the large oval aperture of communication between the auricle and the ventricle to be presently described.

The *Eustachian valve* is situated between the anterior margin of the inferior vena cava and the auriculo-ventricular orifice. It is semilunar in form, its convex margin being attached to the wall of the vein, its concave margin, which is free, terminating in two cornua, of which the left is attached to the anterior edge of the annulus ovalis, the right being lost on the wall of the auricle. The valve is formed by a duplicature of the lining membrane of the auricle containing a few muscular fibres.

In the *fœtus* this valve is of large size, and serves to direct the blood from the inferior vena cava through the foramen ovale into the left auricle.

In the *adult* it is occasionally persistent, and may assist in preventing the reflux of blood into the inferior vena cava; more commonly it is small, and its free margin presents a cribriform or filamentous appearance; occasionally it is altogether wanting.

The *coronary valve* (valve of Thebesius) is a semicircular fold of the lining membrane of the auricle protecting the orifice of the coronary sinus. It prevents the regurgitation of blood into the sinus during the contraction of the auricle. This valve is occasionally double.

The *fossa ovalis* is an oval depression corresponding to the situation of the foramen ovale in the fœtus. It is situated at the lower part of the septum auricularum, above the orifice of the inferior vena cava.

The *annulus ovalis* is the prominent oval margin of the foramen ovale. It is most distinct above and at the sides; below it is deficient. A small slit-like valvular opening is occasionally found at the upper margin of the fossa ovalis which leads upward, beneath the annulus, into the left auricle, and is the remains of the aperture between the two auricles in the fœtus.

The *musculi pectinati* are small, prominent muscular columns which run across the inner surface of the appendix auriculæ and adjoining portion of the wall of the sinus. They have received the name *pectinati* from the fancied resemblance they bear to the teeth of a comb [Latin, *pecten*].

The **Right Ventricle** is triangular in form and extends from the right auricle to near the apex of the heart. Its anterior or upper surface is rounded and convex and forms the larger part of the front of the heart. Its posterior or under surface is flattened, rests upon the Diaphragm, and forms only a small part of the back of the heart. Its inner wall is formed by the partition between the two ventricles, the *septum ventriculorum*, the surface of which is convex and bulges into the cavity of the right ventricle. Its upper and inner angle is prolonged into a conical pouch, the *infundibulum* or *conus arteriosus*, from which the pulmonary artery arises. The walls of the right ventricle are thinner than those of the left, the proportion between them being as 1 to 3. The wall is thickest at the base, and gradually becomes thinner toward the apex. The cavity, which equals that of the left ventricle, is capable of containing about three fluidounces.[1]

To examine the interior an incision should be made a little to the right of the anterior ventricular groove from the pulmonary artery to the apex of the heart, and should be carried up from thence along the right border of the ventricle as far as the auriculo-ventricular opening.

The following parts present themselves for examination:

Openings.	Auriculo-ventricular. Opening of the pulmonary artery.
Valves. . .	Tricuspid. Semilunar.

And a muscular and tendinous apparatus connected with the tricuspid valve:

Columnæ carneæ. Chordæ tendineæ.

The *auriculo-ventricular orifice* is the large oval aperture of communication between the auricle and ventricle. It is situated at the base of the ventricle near the right border of the heart, and corresponds to the centre of the sternum between the fourth costal cartilages. The opening is about an inch in diameter,[2] oval from side to side, surrounded by a fibrous ring covered by the lining membrane of the heart, and rather larger than the corresponding aperture on the left side, being sufficiently large to admit the ends of four fingers. It is guarded by the tricuspid valve.

The *opening of the pulmonary artery* is circular in form and situated at the summit of the conus arteriosus [the conical portion of the cavity of each ventricle from which the aorta and the pulmonary artery respectively arise], close to the septum ventriculorum. It is placed on the left side of the auriculo-ventricular opening, upon the anterior aspect of the heart, and corresponds to the articulation of the third costal cartilage of the left side with the sternum. Its orifice is guarded by the pulmonary semilunar valves.

The *tricuspid valve* consists of three segments of a triangular or trapezoidal

---

[1] Morrant Baker says that, "taking the means of various estimates, it may be inferred that each ventricle is able to contain four to six ounces of blood" (Kirke's *Physiology*, 10th edition, p. 156).

[2] In the *Pathological Transactions*, vol. vi. p. 119, Dr. Peacock has given some careful researches upon the weight and dimensions of the heart in health and disease. He states, as the result of his investigations, that in the healthy adult heart the right auriculo-ventricular aperture has a mean circumference of 54.4 lines, or 4$\frac{29}{50}$ inches; the left auriculo-ventricular aperture a mean circumference of 44.3 lines, or 3$\frac{11}{16}$ inches; the pulmonic orifice of 40 lines, or 3$\frac{1}{3}$ inches; and the aortic orifice of 35.5 lines, or 3$\frac{1}{24}$ inches; but the dimensions of the orifices varied greatly in different cases, the auriculo-ventricular aperture having a range of from 45 to 60 lines, and the others in the same proportion.

shape formed by a duplicature of the lining membrane of the heart, strengthened by a layer of fibrous tissue, and containing, according to Kürschner and Senac, muscular fibres. These segments are connected by their bases to the auriculo-ventricular orifice and by their sides with one another, so as to form a continuous annular membrane which is attached round the margin of the auriculo-ventricular opening, their free margins and ventricular surfaces affording attachment to a number of delicate tendinous cords, the *chordæ tendineæ*. The largest and most movable segment is placed toward the left side of the auriculo-ventricular opening, interposed between that opening and the pulmonary artery. Another segment corresponds to the front of the ventricle, and a third to its posterior wall. The central part of each segment is thick and strong; the lateral margins are thin and indented. The chordæ tendineæ are connected with the adjacent margins of the principal segments of the valve, and are further attached to each segment in the following manner: 1. Three or four reach the attached margin of each segment, where they are continuous with the auriculo-ventricular tendinous ring. 2. Others, four to six in number, are attached to the central thickened part of each segment. 3. The most numerous and finest are connected with the marginal portion of each segment.

The *columnæ carneæ* are the rounded muscular columns which project from nearly the whole of the inner surface of the ventricle, excepting near the opening of the pulmonary artery, where the wall becomes smooth. They may be classified, according to their mode of connection with the ventricle, into three sets: The first set merely form prominent ridges on the inner surface of the ventricle, being attached by their entire length on one side as well as by their extremities; the second set are attached by their two extremities, but are free in the rest of their extent; whilst the third set (*musculi papillares*), three or four in number, are attached by one extremity to the wall of the heart, the opposite extremity giving attachment to the *chordæ tendineæ*. The tricuspid valve is situated behind the middle of the sternum, about the level of the fourth costal cartilage.

Fig. 604.

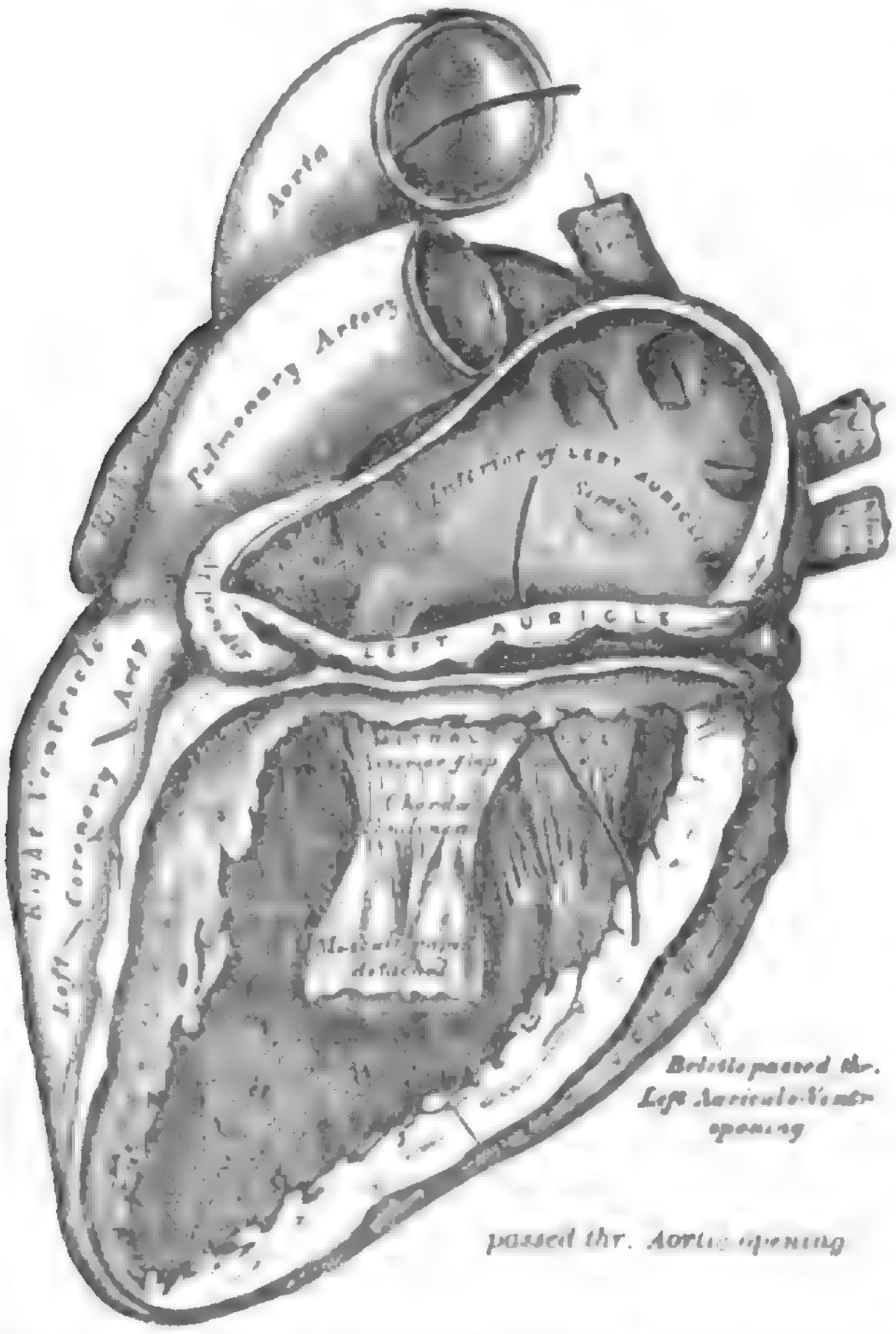

The Left Auricle and Ventricle laid open, the posterior walls of both being removed.

The *semilunar valves*, three in number,[1] guard the orifice of the pulmonary artery. They consist of three semicircular folds, two anterior (right and left) and one posterior, formed by a duplicature of the lining membrane, strengthened by fibrous tissue. They are attached by their convex margins to the wall of the artery, at its junction with the ventricle, the straight border being free and directed upward in the course of the vessel, against the sides of which the valve-flaps are pressed during the passage of the blood along the artery. The free margin of each is somewhat thicker than the rest of the valve, is strengthened by a bundle of tendinous fibres, and presents at its middle a small projecting thickened nodule, called *corpus Arantii*.[2] From this nodule tendinous fibres radiate through the valve to its attached margin, and these fibres form a constituent part of its substance throughout its whole extent, excepting two narrow lunated portions placed on either side of the nodule immediately behind the free margin; here the valve is thin and formed merely by the lining membrane. During the passage of the blood along the pulmonary artery these valves are pressed against the sides of the cylinder, and the course of the blood along the tube is uninterrupted; but during the ventricular diastole, when the current of blood along the pulmonary artery is checked and partly thrown back by its elastic walls, these valves become immediately expanded and effectually close the entrance of the tube. When the valves are closed the lunated portions of each are brought into contact with one another by their opposed surfaces, the three corpora Arantii filling up the small triangular space that would be otherwise left by the approximation of the three semilunar valves.

---

[1] The pulmonary semilunar valves have been found to be two in number, instead of three (Dr. Hand of St. Paul, Minn., in the *North-western Med. and Surg. Journ.*, July, 1873); and the same variety is more frequently noticed in the aortic semilunar valves.

[2] In former editions, as well as in other textbooks on anatomy, these little nodules have been

Between the semilunar valves and the commencement of the pulmonary artery are three pouches or dilatations, one behind each valve. These are the pulmonary sinuses (*sinuses of Valsalva*). Similar sinuses exist between the semilunar valves and the commencement of the aorta; they are larger than the pulmonary sinuses. The blood in its regurgitation toward the heart finds its way into these sinuses, and so shuts down the valve-flaps. The pulmonary valves are situated behind the junction of the left third costal cartilage with the sternum.

The **Left Auricle** is rather smaller than the right; its walls thicker, measuring about one line and a half; it consists, like the right, of two parts, a principal cavity or *sinus* and an *appendix auriculæ*.

The *sinus* is cuboidal in form, and concealed in front by the pulmonary artery and aorta; internally it is separated from the right auricle by the septum auricularum; behind it receives on each side the pulmonary veins, being free in the rest of its extent.

The *appendix auriculæ* is somewhat constricted at its junction with the auricle; it is longer, narrower, and more curved than that of the right side, and its margins more deeply indented, presenting a kind of foliated appearance. Its direction is forward and toward the right side, overlapping the root of the pulmonary artery.

In order to examine its interior a horizontal incision should be made along the attached border of the auricle to the ventricle, and from the middle of this a second incision should be carried upward.

The following parts then present themselves for examination:

The openings of the four pulmonary veins.
Auriculo-ventricular opening.
Musculi pectinati.

The *pulmonary veins*, four in number, open, two into the right and two into the left side of the auricle. The two left veins frequently terminate by a common opening. They are not provided with valves.

The *auriculo-ventricular opening* is the large oval aperture of communication between the auricle and ventricle. It is rather smaller than the corresponding opening on the opposite side. (See note 2, p. 909.)

The *musculi pectinati* are fewer in number and smaller than on the right side; they are confined to the inner surface of the appendix.

On the inner surface of the septum auricularum may be seen a lunated impression, bounded below by a crescentic ridge, the concavity of which is turned upward. The depression is just above the fossa ovalis in the right auricle.

---

described as fibro-cartilaginous in structure. At my request, Mr. Le Cronier Lancaster, demonstrator of physiology at St. George's Hospital, has investigated this subject, and reports that the "corpora Arantii" appear to consist of bundles of interlacing connective-tissue fibres with branched connective-tissue cells and some few elastic fibres. Occasionally a rounded cell, with indistinct capsule, resembling a cartilage-cell, was seen, but there were not many of them. At the free edge of the corpus the structure is denser, there being a larger proportion of fibres to cells than in the central portion. He thinks the structure of the corpus should be put down as fibrous, and not fibro-cartilaginous.

The **Left Ventricle** is longer and more conical in shape than the right ventricle. It forms a small part of the left side of the anterior surface of the heart and a considerable part of its posterior surface. It also forms the apex of the heart by its projection beyond the right ventricle. Its walls are much thicker than those of the right side, the proportion being as 3 to 1. They are also thickest in the broadest part of the ventricle, becoming gradually thinner toward the base, and also toward the apex, which is the thinnest part.

Its cavity should be opened by making an incision through its anterior wall along the left side of the ventricular septum, and carrying it round the apex and along its posterior surface to the auriculo-ventricular opening.

The following parts present themselves for examination:

Openings.	Auriculo-ventricular. Aortic.	*Valves.*	Mitral. Semilunar.
Chordæ tendineæ.		Columnæ carneæ.	

The *auriculo-ventricular opening* is placed below and to the left of the aortic orifice, in the third intercostal space to the left of the sternum. It is a little smaller than the corresponding aperture of the opposite side, and, like it, is broader in the transverse than in the antero-posterior diameter. It is surrounded by a dense fibrous ring covered by the lining membrane of the heart and guarded by the mitral valve.

The *aortic opening* is a small circular aperture in front and to the right side of the auriculo-ventricular, from which it is separated by one of the segments of the mitral valve. Its orifice is guarded by the semilunar valves. Its position corresponds to the left half of the sternum on a line with the lower border of the third costal cartilage.

The *mitral valve* is attached to the circumference of the auriculo-ventricular orifice in the same way that the tricuspid valve is on the opposite side. It is formed by a duplicature of the lining membrane, strengthened by fibrous tissue, and contains a few muscular fibres. It is larger in size, thicker, and altogether stronger than the tricuspid, and consists of two segments of unequal size. The larger segment is placed in front, between the auriculo-ventricular and aortic orifices, and is said to prevent the filling of the aorta during the distension of the ventricle. Two smaller segments are usually found at the angle of junction of the larger. The mitral valve-flaps are furnished with chordæ tendineæ, the mode of attachment of which is precisely similar to that of those on the right side, but they are thicker, stronger, and less numerous. The mitral valve lies in the third intercostal space, about an inch from the left border of the sternum.

The *semilunar valves* surround the orifice of the aorta: two are posterior (right and left) and one anterior: they are similar in structure and in their mode of attachment to those of the pulmonary artery. They are, however, larger, thicker, and stronger than those of the right side; the lunulæ are more distinct, and the corpora Arantii larger and more prominent. Between each valve and the cylinder of the aorta is a deep depression, the *sinus aortici* (sinuses of Valsalva); they are larger than those at the root of the pulmonary artery. The aortic valves lie behind the left border of the sternum, close to the lower margin of the third costal cartilage.

[For the positions of the valves, and the best places in which to auscult them, see Holden's *Landmarks*, § 43.]

The *columnæ carneæ* admit of a subdivision into three sets, like those upon the right side, but they are smaller, more numerous, and present a dense interlacement, especially at the apex and upon the posterior wall. Those attached by one extremity only, the *musculi papillares*, are two in number, being connected one to the anterior, the other to the posterior wall; they are of large size, and terminate by free rounded extremities from which the chordæ tendineæ arise.

The *endocardium* is a thin membrane which lines the internal surface of the heart; it assists in forming the valves by its reduplications, and is continuous with the lining membrane of the great blood-vessels. It is a smooth, transparent membrane, giving to the inner surface of the heart its glistening appearance. It is more opaque on the left than on the right side of the heart, thicker in the auricles than in the ventricles, and thickest in the left auricle. It is thin on the musculi pectinati and on the columnæ carneæ, but thicker on the smooth part of the auricular and ventricular walls and on the tips of the musculi papillares.

Structure.—The heart consists of muscular fibres and of fibrous rings which serve for their attachment.

The *fibrous rings* surround the auriculo-ventricular and arterial orifices: they are stronger upon the left than on the right side of the heart. The auriculo-ventricular rings serve for the attachment of the muscular fibres of the auricles and ventricles, and also for the mitral and tricuspid valves; the ring on the left side is closely connected by its right margin with the aortic arterial ring. Between these and the right auriculo-ventricular ring is a mass of fibrous tissue, and, in some of the larger animals, as the ox and elephant, a nodule of bone.

The fibrous rings surrounding the arterial orifices serve for the attachment of the great vessels and semilunar valves. Each ring receives by its ventricular margin the attachment of the muscular fibres of the ventricles; its opposite margin presents three deep semicircular notches, within which the middle coat of the artery (which presents three convex semicircular segments) is firmly fixed, the attachment of the artery to its fibrous ring being strengthened by the thin cellular coat and serous membrane externally and by the endocardium within. It is opposite the margins of these semicircular notches, in the arterial rings, that the endocardium, by its reduplication, forms the semilunar valves, the fibrous structure of the ring being continued into each of the segments of the valve at this part. The middle coat of the artery in this situation is thin, and the sides of the vessel are dilated to form the sinuses of Valsalva.

The *muscular structure* of the heart consists of bands of fibres which present an exceedingly intricate interlacement. They are of a deep-red color and marked with transverse striæ (p. 66).

The muscular fibres of the heart admit of a subdivision into two kinds—those of the auricles and those of the ventricles, which are quite independent of one another.

Fibres of the Auricles.—These are disposed in two layers—a superficial layer common to both cavities, and a deep layer proper to each. The *superficial fibres* are more distinct on the anterior surface of the auricles, across the bases of which they run in a transverse direction, forming a thin but incomplete layer. Some of these fibres pass into the septum auricularum. The *internal* or *deep fibres* proper to each auricle consist of two sets, looped and annular fibres. The *looped fibres* pass upward over each auricle, being attached by two extremities to the corresponding auriculo-ventricular rings in front and behind. The *annular fibres* surround the whole extent of the appendices auricularum, and are continued upon the walls of the venæ cavæ and coronary sinus on the right side, and upon the pulmonary veins on the left side at their connection with the heart. In the appendices they interlace with the longitudinal fibres.

The *fibres of the ventricles* are arranged in numerous layers, of which Pettigrew[1] describes seven. Other anatomists have regarded them differently, and indeed there must be some uncertainty on the subject, for the layers are not independent of each other, but their fibres are interlaced to a considerable extent. And it has been observed that as Pettigrew's observations were made chiefly on the hearts of the lower animals, they may not apply exactly to man. Yet as his description has been received by some of the best anatomists and is supported by a large series of preparations, it seems best to adopt it.

The general result of these investigations may be very briefly stated as follows: In the left ventricle the fibres of the first or most external layer are continuous with those of the seventh or most internal, those of the second with the sixth, and those of the third with the fifth, while the fourth or central layer appears to be single.

---

[1] *Phil. Trans.*, 1864.

The general direction of the fibres of the external layer is nearly vertical, but inclining somewhat from the left to right as they run downward; the direction of the fibres of the internal layer is just the reverse, nearly vertical, but running upward from left to right; those of the second layer run more obliquely downward from left to right, and those of the sixth with a corresponding obliquity in the reversed direction. The obliquity of the fibres of the third layer is greater; in fact, they approach the horizontal, as do those of the fifth in the reversed direction, while the fibres of the fourth layer run pretty nearly horizontal. The thickness of the layers increases from without inward, so that the fourth layer, which is the middle in order of sequence, lies nearer the outer than the inner surface of the ventricular wall. The fibres of the external or superficial layer arise, as a rule, from the auriculo-ventricular rings and from the fibrous rings surrounding the aorta, but a few of them are continued beneath the rings into the columnæ carneæ.[1] They curve round at the apex in a spiral, which forms the *whorl* or vortex, those from the anterior surface of the heart curving round to enter the apex posteriorly, and *vice versâ*. From the apex they are traced up into the seventh layer, which is much thicker, and from which the musculi papillares and columnæ carneæ are chiefly formed. The apex of the heart is made up exclusively of the fibres of this first layer (or first and seventh), so that when it is removed the ventricle is opened. And the successive layers terminate farther and farther from the apex—an arrangement which has led to their fibres being described as shorter; which Pettigrew doubts, attributing the shortness of the layers to the different direction of the fibres, not to any difference in length in the individual fibres. Since the deeper layers do not descend to the apex, this is the thinnest part of the ventricle, measuring only one-eighth of an inch in thickness even in the heart of an ox.

The fibres of the deeper layers are not connected with the auriculo-ventricular rings, but pass below them, each layer terminating a little below the more superficial layer which wraps round it, though the difference in this respect is not so great as in their depth toward the apex.

The fibres of the first layer pass across the septum from one ventricle to the other—an arrangement particularly well seen at the back of the heart, where there is a set of transverse fibres described by Pettigrew as the "hinge-like fibres" of the back of the heart; and the three subjacent layers also take part in the formation of both ventricles; but when the fourth layer is removed the two ventricles are entirely severed from each other posteriorly. The septum is formed of the fibres of both ventricles applied to each other.

The general arrangement of the fibres of the right ventricle is the same as that of the left, but the external fibres do not pass in to be continuous with the internal at a single point—the apex—but all along the anterior coronary groove. Its fibres are more delicate than those of the left, and it is regarded by Pettigrew as formed out of the left ventricle by a kind of reflection inward of the wall of the single cavity of which the ventricles consist at one period of fœtal life. (See p. 124.) He points out that the heart at that period may be supposed to be represented by an open tube formed of spiral fibres. If, now, a portion of this tube or cylinder were pushed down to meet the opposite wall, to which the fibres of the reflected portion adhere and with which they coalesce, there would be formed an offset from the common ventricular cavity, formed partly of common and partly of special fibres, as is the case in the heart. At this early period the outer layers are not formed and the apex is still unclosed. Their formation closes in the apex and completes the walls of the ventricles. If this is the case, the septum must be formed of two elements or sets of fibres—one proper to the original single ventricle, and therefore in after-life proper to the left ventricle; the other set formed from the reflected or reduplicated fibres which now form the right ventricle.[2] To these of course the fibres which cross over from one ventricle to the other may be added. Pettigrew regards the portion of the septum which belongs to the left ventricle as twice that which belongs to the right. (For many interesting particulars with regard to the arrangement of the fibres and the shape of the cavities the reader must be referred to the original paper.)

---

[1] "It is a great mistake to imagine that all the fibres of the ventricles arise from the auriculo-ventricular tendinous rings, the fact being that, with the exception of the fibres of the first and seventh layers, they are continuous beneath them."—Pettigrew, *op. cit.*, p. 456, *note*.

[2] If the general idea of this is not at once obvious, it will become so by taking a roll of paper,

VESSELS AND NERVES.—The *arteries* supplying the heart are the left or anterior and right or posterior coronary (p. 507).

The *veins* accompany the arteries, and terminate in the right auricle. They are the great cardiac vein, the anterior, middle, and posterior cardiac veins, and the venæ cordis minimæ (*venæ Thebesii*) (pp. 636, 637).

The *lymphatics* terminate in the thoracic and right lymphatic ducts.

The *nerves* are derived from the cardiac plexuses, which are formed partly from the cranial nerves and partly from the sympathetic. They are freely distributed both on the surface and in the substance of the heart, the separate filaments being furnished with small ganglia.[1]

PECULIARITIES IN THE VASCULAR SYSTEM OF THE FŒTUS.

The chief peculiarities in the **Heart** of the fœtus are the direct communication between the two auricles through the foramen ovale and the large size of the Eustachian valve. There are also several minor peculiarities. Thus, the position of the heart is vertical until the fourth month, when it commences to assume an oblique direction. Its size is also very considerable as compared with the body, the proportion at the second month being 1 to 50, at birth it is as 1 to 120, whilst in the adult the average is about 1 to 160. At an early period of fœtal life the auricular portion of the heart is larger than the ventricular, the right auricle being more capacious than the left; but toward birth the ventricular portion becomes the larger. The thickness of both ventricles is at first about equal, but toward birth the left becomes much the thicker of the two.

The *foramen ovale* is situated at the lower and back part of the septum auricularum, forming a communication between the auricles. It remains as a free oval opening from the time of the formation of the auricular septum (about the eighth week) until the middle period of fœtal life. About this period a fold grows up from the posterior wall of the auricle to the left of the foramen ovale, and advances over the opening, so as to form a sort of valve, which allows the blood to pass only from the right to the left auricle, and not in the opposite direction.

The *Eustachian valve* is developed from the anterior border of the inferior vena cava at its entrance into the auricle. It is directed upward on the left side of the opening of this vein, and serves to direct the blood from the inferior vena cava through the foramen ovale into the left auricle.

The peculiarities in the **Arterial System** of the fœtus are the communication between the pulmonary artery and descending part of the arch of the aorta by means of the *ductus arteriosus*, and the communication between the internal iliac arteries and the placenta by means of the *umbilical arteries*.

The *ductus arteriosus* is a short tube about half an inch in length at birth and of the diameter of a goose-quill. In the early condition it forms the continuation of the pulmonary artery, and opens into the arch of the aorta just below the origin of the left subclavian artery, and so conducts the chief part of the blood from the right ventricle into the descending aorta. When the branches of the pulmonary artery have become larger relatively to the ductus arteriosus, the latter is chiefly

---

calling one side of it the posterior and the other the anterior, and bending it at the right side of its middle till the anterior touches the posterior surface. The larger part to the left of the middle line represents the left ventricle, the smaller the right, and the double fold in the middle the septum; then if the reflected parts where they touch are gummed to each other this will represent the coalescence of the septum with the outer wall, whereby the right ventricle becomes a separate tube from the left. The lower openings of these two tubes are closed in by the growth of the external layers.

[1] For full and accurate descriptions of the nerves and ganglia of the heart the student is referred to Dr. R. Lee's papers on the subject.

connected to the left pulmonary artery, and the fibrous cord, which is all that remains of the ductus arteriosus in later life, will be found to be attached to the root of that vessel.

The *umbilical* or *hypogastric arteries* arise from the internal iliacs. Ascending along the sides of the bladder to its fundus, they pass out of the abdomen at the umbilicus, and are continued along the umbilical cord to the placenta, coiling round the umbilical vein. They return to the placenta the blood which has circulated in the system of the fœtus.

The peculiarity in the **Venous System** of the fœtus is the communication established between the placenta and the liver and portal vein through the umbilical vein, and with the inferior vena cava by the *ductus venosus*.

Fœtal Circulation.

The blood destined for the nutrition of the fœtus is carried from the placenta to the fœtus along the umbilical cord by the umbilical vein. The umbilical vein enters the abdomen at the umbilicus, and passes upward along the free margin of the suspensory ligament of the liver to the under surface of that organ, where it gives off two or three branches to the left lobe, one of which is of large size; and others to the lobus quadratus and lobulus Spigelii. At the transverse fissure it divides into two branches: of these, the larger is joined by the portal vein, and enters the right lobe; the smaller branch continues onward, under the name of the *ductus venosus*, and joins the left hepatic vein at the point of junction of that vessel with the inferior vena cava. The blood, therefore, which traverses the umbilical vein reaches the inferior vena cava in three different ways. The greater quantity circulates through the liver with the portal venous blood before entering the vena cava by the hepatic veins; some enters the liver directly, and is also returned to the inferior cava by the hepatic veins; the smaller quantity passes directly into the vena cava by the junction of the ductus venosus with the left hepatic vein.

In the *inferior cava* the blood carried by the ductus venosus and hepatic veins becomes mixed with that returning from the lower extremities and viscera of the abdomen. It enters the *right auricle*, and, guided by the Eustachian valve, passes through the foramen ovale into the *left auricle*, where it becomes mixed with a small quantity of blood returned from the lungs by the pulmonary veins. From the left auricle it passes into the *left ventricle*, and from the left ventricle into the *aorta*, by means of which it is distributed almost entirely to the head and upper extremities, a small quantity being probably carried into the descending aorta. From the head and upper extremities the blood is returned by the branches of the *superior vena cava* to the *right auricle*, where it becomes mixed with a small portion of the blood from the inferior cava. From the right auricle it descends over the Eustachian valve into the *right ventricle*, and from the right ventricle passes into the *pulmonary artery*. The lungs of the fœtus being solid and almost impervious, only a small quantity of the blood of the pulmonary artery is distributed to them by the right and left pulmonary arteries, which is returned by the pulmonary veins to the left auricle: the greater part passes through the *ductus arteriosus* into the commencement of the descending *aorta*, where it becomes mixed with a small quantity of blood transmitted by the left ventricle into the aorta. Along this vessel it descends to supply the lower extremities and viscera of the abdomen and pelvis, the chief portion being, however, conveyed by the *umbilical arteries* to the *placenta*.

From the preceding account of the circulation of the blood in the fœtus it will be seen—

1. That the placenta serves the double purpose of a respiratory and nutritive organ, receiving the venous blood from the fœtus and returning it again reoxygenated and charged with additional nutritive material.

2. That nearly the whole of the blood of the umbilical vein traverses the liver before entering the inferior cava [and the liver is the only organ in the fœtus that

receives pure arterial blood]; hence the large size of this organ, especially at an early period of fœtal life.

3. That the right auricle is the point of meeting of a double current, the blood in the inferior cava being guided by the Eustachian valve into the left auricle,

Fig. 605.

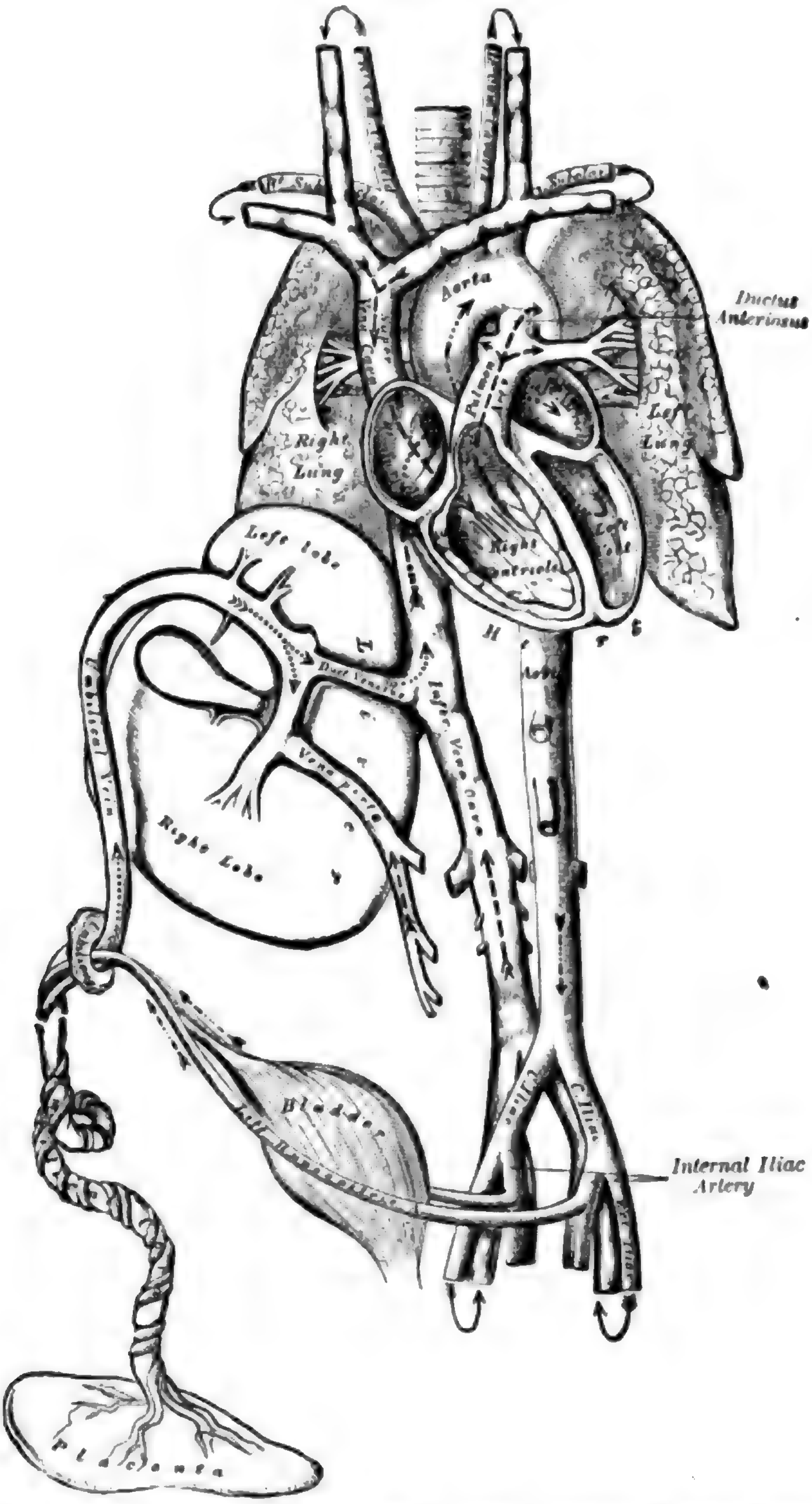
Aorta
Ductus Anteriosus
Right Lung
Left Lung
Left lobe
Right ventricle
Left Vent
Duct Venosus
Infer Vena Cava
Vena porta
Umbilical Vein
Right Lobe
Bladder
Placenta
Internal Iliac Artery

Plan of the Fœtal Circulation. In this plan the figured arrows represent the kind of blood, as well as the direction which it takes in the vessels. Thus, arterial blood is figured >>>··········>; venous blood, >>— — — —>; mixed (arterial and venous) blood, >>>·—·—·>.

whilst that in the superior cava descends into the right ventricle. At an early period of fœtal life it is highly probable that the two streams are quite distinct, for the inferior cava opens almost directly into the left auricle, and the Eustachian valve would exclude the current along the vein from entering the right ventricle. At a later period, as the separation between the two auricles becomes more distinct, it seems probable that some mixture of the two streams must take place.

4. The blood carried from the placenta to the fœtus by the umbilical vein, mixed with the blood from the inferior cava, passes almost directly to the arch of the aorta, and is distributed by the branches of that vessel to the head and upper extremities; hence the large size and perfect development of those parts at birth.

5. The blood contained in the descending aorta, chiefly derived from that which has already circulated through the head and limbs, together with a small quantity from the left ventricle, is distributed to the lower extremities; hence the small size and imperfect development of these parts at birth.

CHANGES IN THE VASCULAR SYSTEM AT BIRTH.

At birth, when respiration is established, an increased amount of blood from the pulmonary artery passes through the lungs, which now perform their office as respiratory organs, and at the same time the placental circulation is cut off. The foramen ovale becomes gradually closed in by about the tenth day after birth; the valvular fold above mentioned becomes adherent to the margins of the foramen for the greater part of its circumference, but above a slit-like opening is left between the two auricles, which sometimes remains persistent.

The *ductus arteriosus* begins to contract immediately after respiration is established, becomes completely closed from the fourth to the tenth day, and ultimately degenerates into an impervious cord which serves to connect the left pulmonary artery to the concavity of the arch of the aorta.

Of the *umbilical* or *hypogastric arteries*, the portion between the internal iliac artery and the superior vesical branch to the bladder remains pervious, though greatly shrunken in size in proportion to its lessened function: while the part between the fundus of the bladder and the umbilicus becomes obliterated between the second and fifth days after birth, and persists as a fibrous cord projecting into the peritoneal sac, so as to form the two fossæ of the peritoneum spoken of in the section on the Surgical Anatomy of Direct Inguinal Hernia.

The *umbilical vein* and *ductus venosus* become completely obliterated between the second and fifth days after birth, and ultimately dwindle to fibrous cords, the former becoming the round ligament of the liver, the latter the fibrous cord which in the adult may be traced along the fissure of the ductus venosus.

[Dr. J. Collins Warren, in a monograph of great ability entitled *The Healing of Arteries after Ligature in Man and Animals* (New York, 1886), has most carefully investigated the mode of closure of the fœtal vessels, and the student is referred to his book for fuller information.]

Organs of Voice and Respiration.

THE LARYNX.

THE **Larynx** is the organ of voice, placed at the upper part of the air-passage. It is situated between the trachea and base of the tongue, at the upper and fore part of the neck, where it forms a considerable projection in the middle line. On each side of it lie the great vessels of the neck; behind, it forms part of the boundary of the pharynx, and is covered by the mucous membrane lining that cavity.

The larynx is narrow and cylindrical below, but broad above, where it presents the form of a triangular box flattened behind and at the sides, whilst in front it is bounded by a prominent vertical ridge. It is composed of cartilages which are connected together by ligaments and moved by numerous muscles: the interior is lined by mucous membrane and supplied with vessels and nerves.

The **Cartilages** of the larynx are nine in number, three single and three pairs:

Thyroid.	Two Arytenoid.
Cricoid.	Two Cornicula Laryngis.
Epiglottis.	Two Cuneiform.

The **Thyroid** (θύρεος, a shield) is the largest cartilage of the larynx. It consists of two lateral lamellæ or alæ united at an acute angle in front, forming a vertical projection in the middle line, which is prominent above and called the *pomum Adami*. This projection is subcutaneous, more distinct in the male than in the female, and occasionally separated from the integument by a bursa mucosa.

FIG. 606.

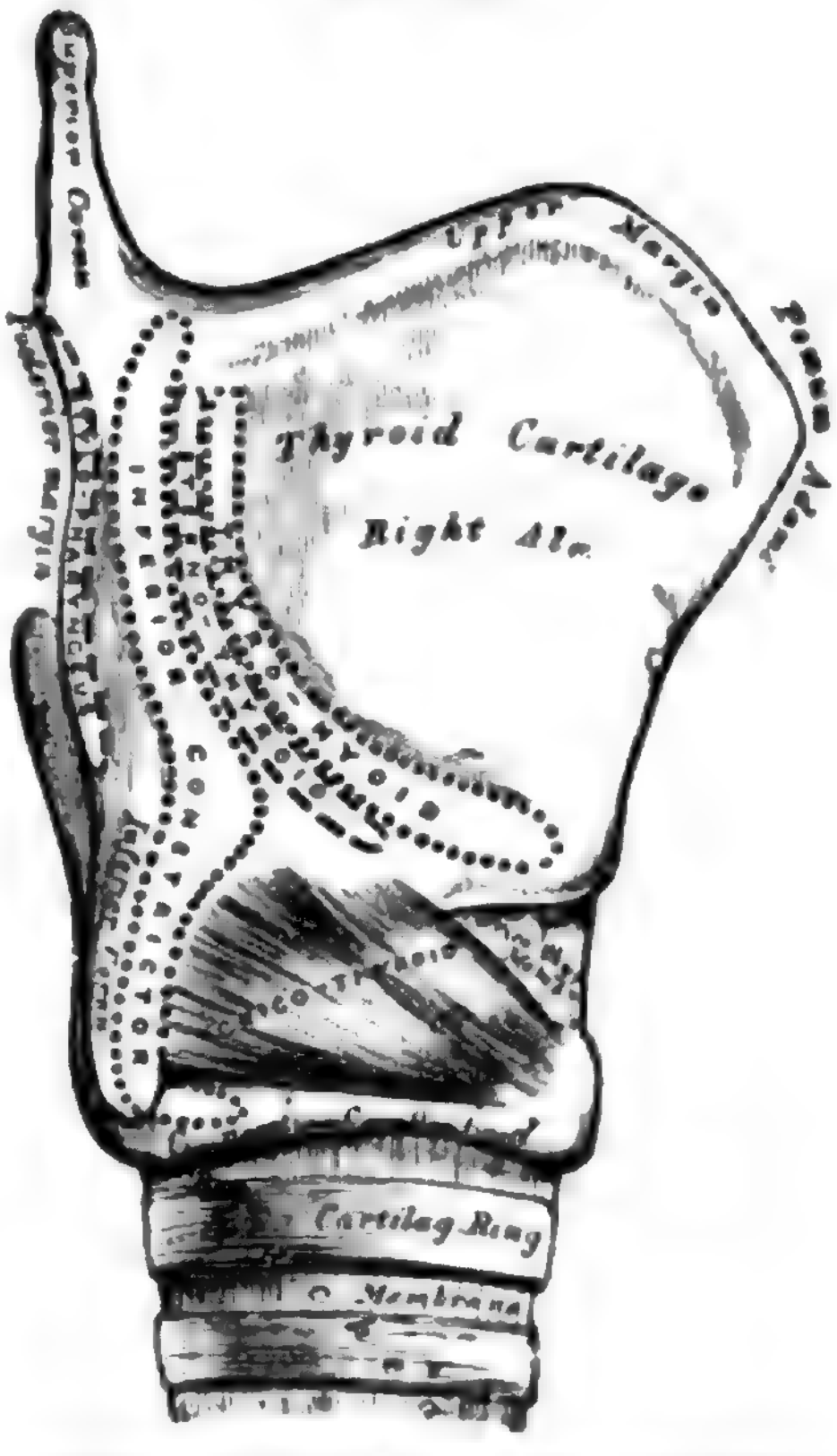

Side View of the Thyroid and Cricoid Cartilages.

Each lamella is quadrilateral in form. Its *outer surface* presents an oblique ridge, which passes downward and forward from a tubercle situated near the root of the superior cornu. This ridge gives attachment to the Sterno-thyroid and Thyro-hyoid muscles; the portion of cartilage included between it and the posterior border to part of the Inferior constrictor muscle.

The *inner surface* of each ala is smooth, concave, and covered by mucous membrane above and behind; but in front, in the receding angle formed by their junction, are attached the epiglottis, the true and false vocal chords, the Thyro-arytenoid and Thyro-epiglottidean muscles.

The *upper border* of the thyroid cartilage is deeply notched in the middle line immediately above the pomum Adami, whilst on either side it is slightly concave. This border gives attachment throughout its whole extent to the thyro-hyoid membrane.

The *lower border* is connected to the cricoid cartilage, in the median line, by the crico thyroid membrane, and on each side by the Crico-thyroid muscle.

The *posterior borders*, thick and rounded, terminate above in the *superior cornua*, and below in the *inferior cornua*. The two superior cornua are long and narrow, directed upward, backward, and inward, and terminate in a conical extremity which gives attachment to the thyro-hyoid ligament. The two inferior cornua are short and thick; they pass downward, with a slight inclination forward and inward, and present on their inner surfaces a small oval articular facet for articulation with the side of the cricoid cartilage. The posterior border receives the insertion of the Stylo-pharyngeus and Palato-pharyngeus muscles on each side.

Fig. 607.

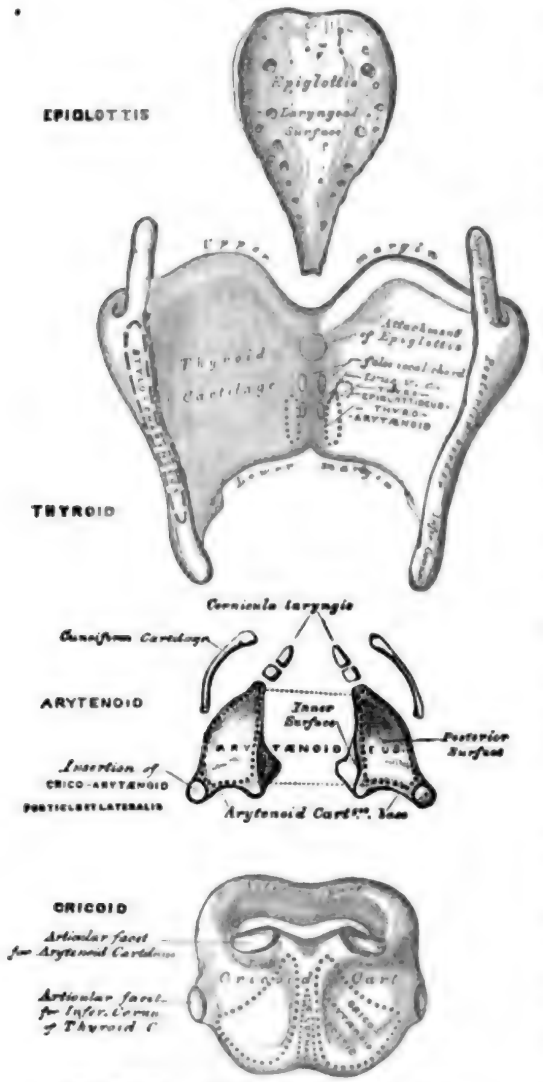
EPIGLOTTIS
Epiglottis
Laryngeal Surface
Upper margin
Attachment of Epiglottis
False vocal chord
True v. c.
THYRO-EPIGLOTTIDEUS.
THYRO-ARYTÆNOID
Thyroid Cartilage
Lower margin
THYROID
Cornicula laryngis
Cuneiform Cartilage
ARYTENOID
Inner Surface
Posterior Surface
ARYTÆNOID
Insertion of CRICO-ARYTÆNOID POSTICUS ET LATERALIS
Arytenoid Cart. Base
CRICOID
Articular facet for Arytenoid Cartilage
Articular facet for Infer. Cornu of Thyroid C.
Cricoid Cart.

The Cartilages of the Larynx, posterior view.

The **Cricoid Cartilage** is so called from its resemblance to a signet-ring (κρίκος, a ring). It is smaller but thicker and stronger than the thyroid cartilage, and forms the lower and back part of the cavity of the larynx.

Its *anterior half* is narrow, convex, affording attachment in front and at the sides to the Crico-thyroid muscles, and behind these to part of the Inferior constrictor.

Its *posterior half* is very broad, both from side to side and from above downward; it presents in the middle line a vertical ridge for the attachment of the longitudinal fibres of the œsophagus, and on either side a broad depression for the Crico-arytænoideus posticus muscle.

At the point of junction of the two halves of the cartilage on either side is a small round elevation for articulation with the inferior cornu of the thyroid cartilage.

The *lower border* of the cricoid cartilage is horizontal, and connected to the upper ring of the trachea by fibrous membrane.

Its *upper border* is directed obliquely upward and backward, owing to the great depth of its posterior surface. It gives attachment in front to the crico-thyroid membrane; at the sides to part of the same membrane and to the lateral Crico-arytenoid muscle; behind, the highest point of the upper border is surmounted on each side by a smooth oval surface for articulation with the arytenoid cartilage. Between the articular surfaces is a slight notch for the attachment of part of the Arytenoideus muscle.

The *inner surface* of the cricoid cartilage is smooth and lined by mucous membrane.

The **Arytenoid Cartilages** are so called from the resemblance they bear, when approximated, to the mouth of a pitcher (ἀρύταινα, a pitcher). They are two in number, and situated at the upper border of the cricoid cartilage at the back of the larynx. Each cartilage is pyramidal in form and presents for examination three surfaces, a base, and an apex.

The *posterior surface* is triangular, smooth, concave, and gives attachment to the Arytenoid muscle.

The *anterior surface*, somewhat convex and rough, gives attachment to the Thyro-arytenoid muscle and to the false vocal chord.

The *internal surface* is narrow, smooth, and flattened, covered by mucous membrane, and lies almost in apposition with the cartilage of the opposite side.

The *base* of each cartilage is broad, and presents a concave smooth surface for articulation with the cricoid cartilage. Of its three angles, the *external* is short, rounded, and prominent, receiving the insertion of the Posterior and Lateral crico-arytenoid muscles. The *anterior* angle, also prominent but more pointed, gives attachment to the true vocal chord.

The *apex* of each cartilage is pointed, curved backward and inward, and surmounted by a small conical-shaped, cartilaginous nodule, the *corniculum laryngis*.

The **Cornicula Laryngis** (*cartilages of Santorini*) are two small conical nodules, consisting of yellow fibro-cartilage, which articulate with the summit of the arytenoid cartilages and serve to prolong them backward and inward. To them are attached the aryteno-epiglottidean folds. They are sometimes united to the arytenoid cartilages.

The **Cuneiform Cartilages** (*cartilages of Wrisberg*) are two small, elongated, cartilaginous bodies, placed one on each side in the fold of mucous membrane which extends from the apex of the arytenoid cartilage to the side of the epiglottis (*aryteno-epiglottidean fold*): they give rise to small whitish elevations on the inner surface of the mucous membrane just in front of the arytenoid cartilages.

The **Epiglottis** is a thin lamella of fibro-cartilage, of a yellowish color, shaped like a leaf, and placed behind the tongue in front of the superior opening of the larynx. [In a fair proportion of persons the tip of the epiglottis can be seen when the tongue is well protruded.] During respiration its direction is vertically upward, its free extremity curving forward toward the base of the tongue; but when the larynx is drawn up beneath the base of the tongue during deglutition, it is carried downward and backward, so as to completely close the opening of the larynx. Its free extremity is broad and rounded; its attached end is long and narrow, and connected to the receding angle between the two alæ of the thyroid cartilage, just below the median notch, by a long, narrow, ligamentous band, the *thyro-epiglottic ligament*. It is also connected to the posterior surface of the body of the hyoid bone by an elastic ligamentous band, the *hyo-epiglottic ligament*.

Its *anterior* or *lingual surface* is curved forward toward the tongue, and covered at its upper part by mucous membrane, which is reflected on to the sides and base of the organ, forming a median and two lateral folds, the *glosso-epiglottidean ligaments*.

Its *posterior* or *laryngeal surface* is smooth, concave from side to side, convex from above downward, and covered by mucous membrane; when this is removed the surface of the cartilage is seen to be studded with a number of small mucous glands which are lodged in little pits upon its surface. To its sides the aryteno-epiglottidean folds are attached.

Structure.—The epiglottis, cuneiform cartilages, and cornicula laryngis are composed of yellow fibro-cartilage which shows little tendency to ossification; but the other cartilages resemble in structure the costal cartilages, becoming more or less ossified in old age.

Ligaments.—The ligaments of the larynx are *extrinsic*—*i. e.* those connecting the thyroid cartilage and epiglottis with the hyoid bone—and *intrinsic*—those which connect the several cartilaginous segments to each other.

The ligaments connecting the thyroid cartilage with the hyoid bone are three in number—the thyro-hyoid membrane and the two lateral thyro-hyoid ligaments. That connecting the epiglottis with the hyoid bone is the hyo-epiglottic.

The *thyro-hyoid membrane* is a broad, fibro-elastic, membranous layer attached below to the upper border of the thyroid cartilage and above to the upper border of the hyoid bone, passing behind the posterior surface and being separated from it by a synovial bursa. It is thicker in the middle line than at either side, in which situation it is pierced by the superior laryngeal vessels and nerve.

The *two lateral thyro-hyoid ligaments* are rounded elastic cords which pass between the superior cornua of the thyroid cartilage and the extremities of the greater cornua of the hyoid bone. A small cartilaginous nodule (*cartilago triticea*). sometimes bony, is frequently found in each.

The *hyo-epiglottic ligament* is an elastic fibrous band which extends from the anterior surface of the epiglottis, near its apex, to the upper border of the body of the hyoid bone.

The ligaments connecting the thyroid cartilage to the cricoid are also three in number—the crico-thyroid membrane and the capsular ligaments and synovial membranes.

The *crico-thyroid membrane* [Fig. 614, p. 928] is composed mainly of yellow elastic tissue. It is of triangular shape; thick in front, where it connects together the contiguous margins of the thyroid and cricoid cartilages; thinner at each side. where it extends from the superior border of the cricoid cartilage to the inferior margin of the true vocal chords, with which it is closely united in front.

Fig. 608.

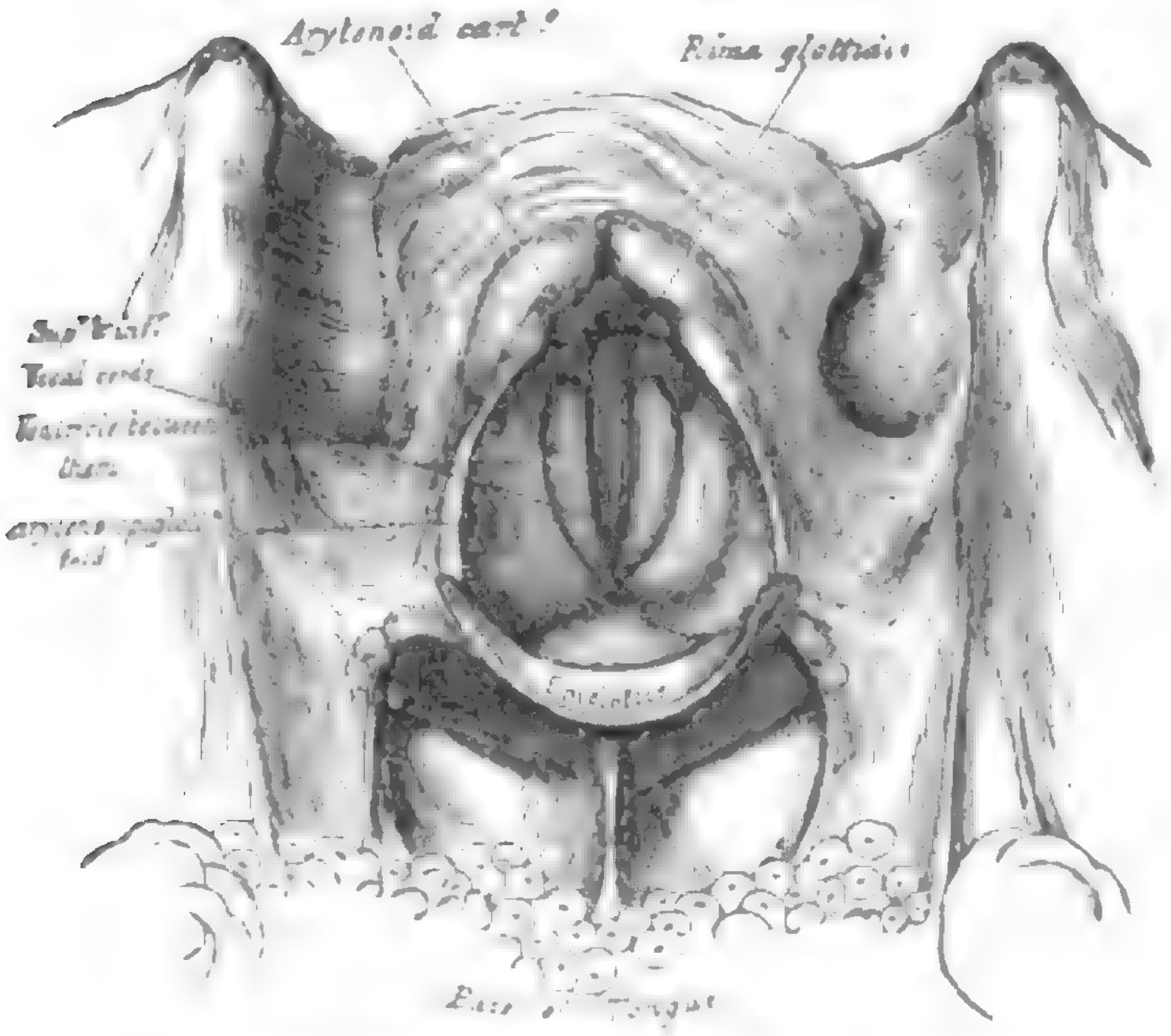

The Larynx and Adjacent Parts, seen from above.

The anterior portion of the crico-thyroid membrane is convex, concealed on each side by the Crico-thyroid muscle, subcutaneous in the middle line, and crossed horizontally by a small anastomotic arterial arch formed by the junction of the two crico-thyroid arteries. The lateral portions are lined internally by mucous membrane and covered by the lateral Crico-arytenoid and Thyro-arytenoid muscles.

[The hyoid bone, *pomum Adami*, superior and inferior borders of the thyroid cartilage, the cricoid cartilage, and the crico-thyroid membrane, are all easily felt, and are of the greatest importance in operations in this locality.]

A *capsular ligament* encloses the articulation of the inferior cornu of the thyroid with the cricoid cartilage on each side. The articulation is lined by synovial membrane.

The ligaments connecting the arytenoid cartilages to the cricoid are two thin and loose *capsular ligaments* connecting together the articulating surfaces, lined internally by synovial membrane, and strengthened behind by a strong *posterior crico-arytenoid ligament* which extends from the cricoid to the inner and back part of the base of the arytenoid cartilage.

The ligaments of the epiglottis are the thyro-epiglottic, the hyo-epiglottic (already described), and the three glosso-epiglottic folds of mucous membrane which connect the epiglottis to the sides and base of the tongue [already described above].

The *thyro-epiglottic ligament* is a long, slender, elastic cord which connects the apex of the epiglottis with the receding angle of the thyroid cartilage immediately beneath the median notch, above the attachment of the vocal chords.

Interior of the Larynx.—The *superior aperture of the larynx* (Fig. 608) is a triangular or cordiform opening, wide in front, narrow behind, and sloping obliquely downward and backward. It is bounded in front by the epiglottis; behind by the apices of the arytenoid cartilages and the cornicula laryngis; and laterally by a fold of mucous membrane enclosing ligamentous and muscular fibres stretched between the sides of the epiglottis and the apex of the arytenoid cartilages: these are the *aryteno-epiglottidean folds*, on the margins of which the cuneiform cartilages form a more or less distinct whitish prominence.

The *cavity of the larynx* extends from the aperture behind the epiglottis to the lower border of the cricoid cartilage. It is divided into two parts by the projection inward of the true vocal chords and the Thyro-arytenoid muscles; between the two chords is a long and narrow triangular fissure or chink, the *glottis*, or *rima glottidis*. The portion of the cavity of the larynx above the glottis is broad and triangular in shape, and corresponds to the interval between the alæ of the thyroid cartilage; the portion below the glottis is at first of an elliptical, and lower down of a circular form.

The *rima glottidis* is the narrow fissure or chink between the inferior or true vocal chords. It is the narrowest part of the cavity of the larynx, and corresponds to the lower level of the arytenoid cartilages. Its length in the male measures rather less than an inch, its breadth, when dilated, varying at its widest part from a third to half an inch. In the female these measurements are less by two or three lines. The form of the glottis varies [Figs. 610 and 611]. In its half-closed condition it is a narrow fissure a little enlarged and rounded behind. In quiet breathing it is widely open, somewhat triangular, the base of the triangle directed backward and corresponding to the space between the separated arytenoid cartilages. In forcible expiration it is smaller than during inspiration. When sound is produced it is more narrowed, the margins of the arytenoid cartilages being brought into contact, and the edges of the true vocal chords approximated and made parallel, the degree of approximation and tension corresponding to the height of the note produced.[1]

Fig. 609.

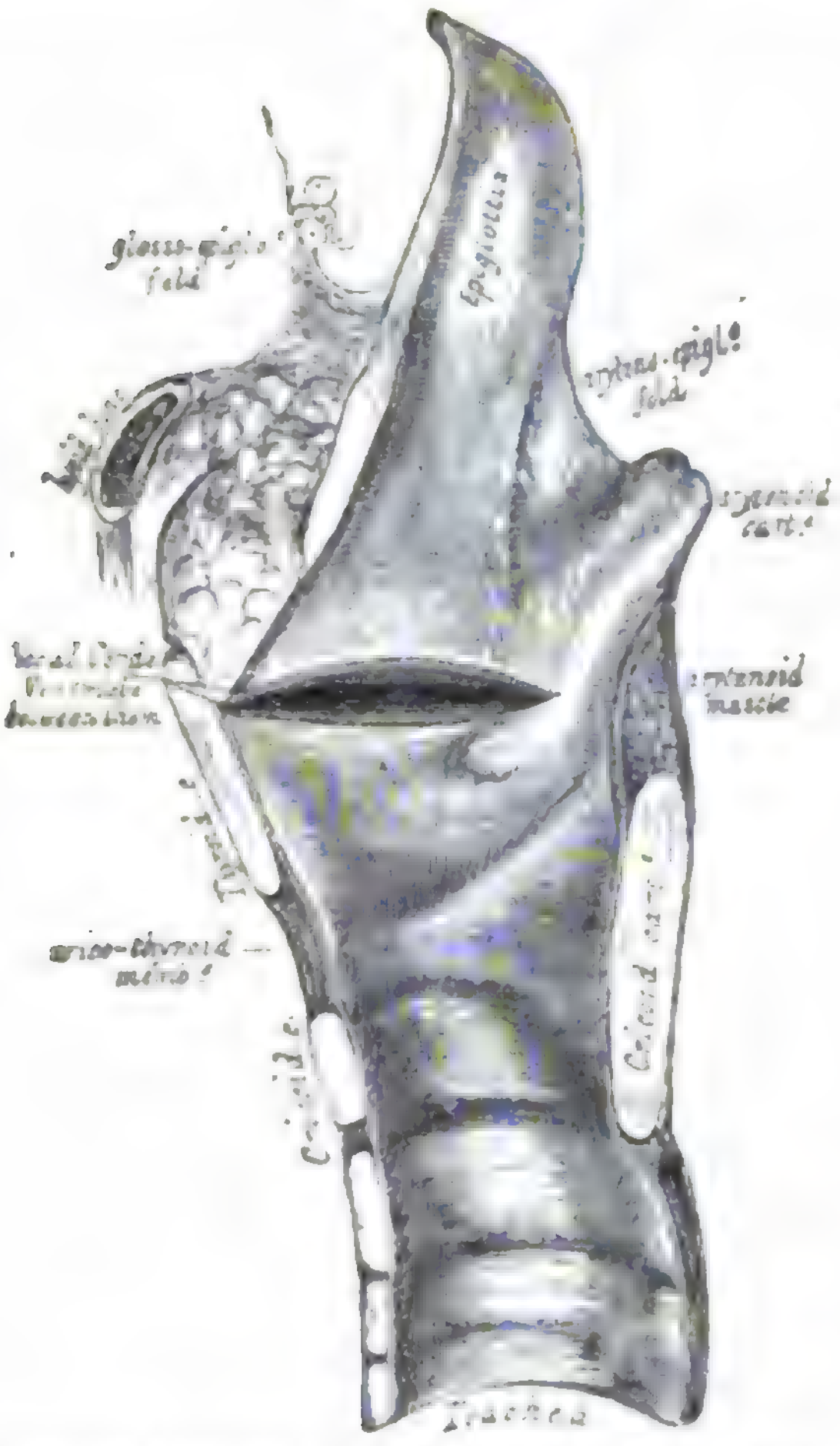

Vertical Section of the Larynx and Upper Part of the Trachea.

[Fig. 610.

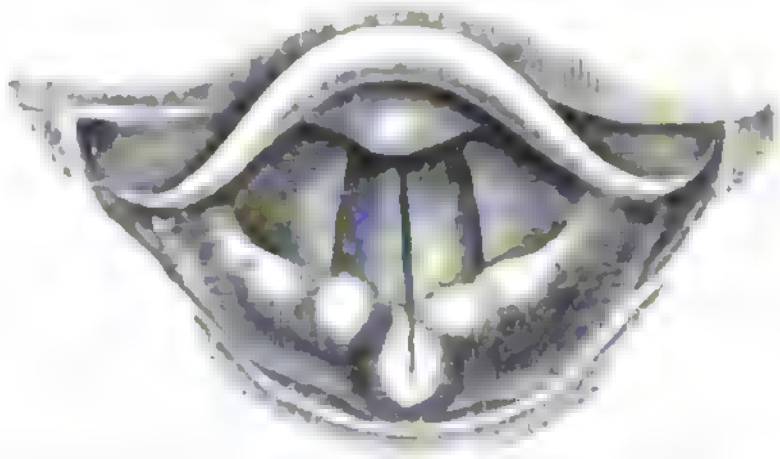

Laryngeal Image during Phonation.]

[Fig. 611.

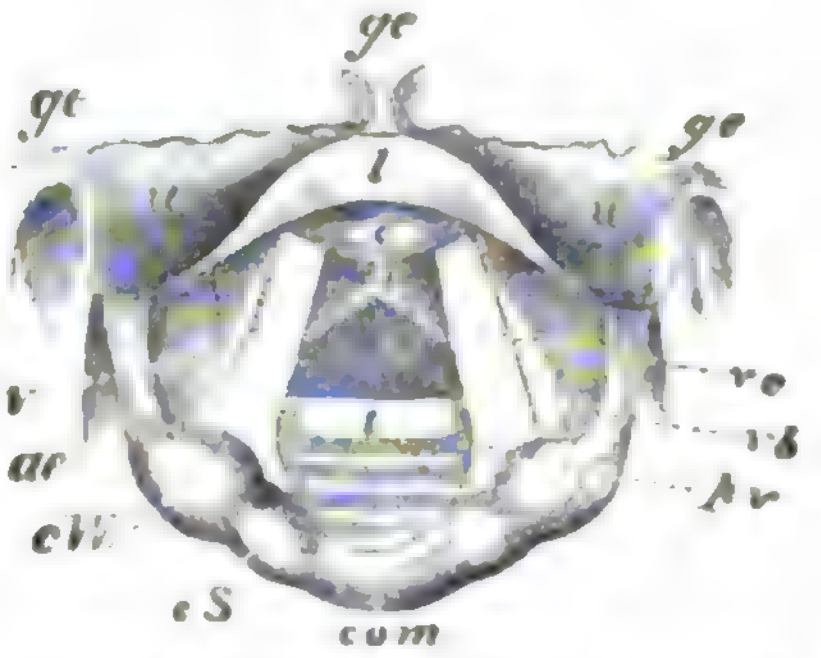

Laryngoscopic Diagram showing the Vocal Chords widely drawn apart, and the position of the various parts above and below the glottis during quiet breathing: *ge*, glosso-epiglottic fold *s*; *u*, upper surface of epiglottis; *l*, lip or arch of epiglottis; *c*, protuberance of epiglottis; *v*, ventricle of the larynx; *ae*, ary-epiglottic fold; *cW*, cartilage of Wrisberg; *cS*, cartilage of Santorini; *com*, arytenoid commissure; *vc*, vocal chord; *vb*, ventricular band; *pv*, processus vocalis; *cr*, cricoid cartilage; *t*, rings of trachea (from Mackenzie).]

The *superior* or *false vocal chords*—so called because they are not directly concerned in the production of the voice—are two folds of mucous membrane enclosing a delicate narrow fibrous band, the *superior thyro-arytenoid ligament.* This ligament consists of a thin band of elastic tissue attached in front to the angle of the thyroid cartilage below the epiglottis, and behind to the anterior surface of the arytenoid cartilage. The lower border of this ligament, enclosed in mucous membrane, forms a free crescentic margin which constitutes the upper boundary of the ventricle of the larynx.

---

[1] On the shape of the glottis in the various conditions of breathing and speaking, see *Czermak on the Laryngoscope*, translated for the New Sydenham Society.

The *inferior* or *true vocal chords*—so called from their being concerned in the production of sound—are two strong fibrous bands (*inferior thyro-arytenoid ligaments*) covered on their surface by a thin layer of mucous membrane. Each ligament consists of a band of yellow elastic tissue attached in front to the depression between the two alæ of the thyroid cartilage, and behind to the anterior angle of the base of the arytenoid. Its lower border is continuous with the thin lateral part of the crico-thyroid membrane. Its upper border forms the lower boundary of the ventricle of the larynx. Externally, the Thyro-arytenoideus muscle lies parallel with it. It is covered internally by mucous membrane, which is extremely thin and closely adherent to its surface. [The superior or false vocal chords, since they take no part in voice, are better termed the "ventricular bands," as they form the upper margin of the opening into the ventricle.]

The *ventricle of the larynx* is an oblong fossa situated between the superior and inferior vocal chords on each side and extending nearly their entire length. This fossa is bounded above by the free crescentic edge of the superior vocal chord; below by the straight margin of the true vocal chord; externally by the corresponding Thyro-arytenoideus muscle. The anterior part of the ventricle leads up by a narrow opening into a cæcal pouch of mucous membrane of variable size, called the *laryngeal pouch.*

The *sacculus laryngis*, or laryngeal pouch, is a membranous sac placed between the superior vocal chord and the inner surface of the thyroid cartilage, occasionally extending as far as its upper border; it is conical in form and curved slightly backward, like a Phrygian cap. On the surface of its mucous membrane are the openings of sixty or seventy small follicular glands which are lodged in the submucous areolar tissue. This sac is enclosed in a fibrous capsule continuous below with the superior thyro-arytenoid ligament: its laryngeal surface is covered by the Aryteno-epiglottideus inferior muscle (*Compressor sacculi laryngis*, Hilton), whilst its exterior is covered by the Thyro-arytenoideus and Thyro-epiglottideus muscles. These muscles compress the sacculus laryngis, and discharge the secretion it contains upon the chordæ vocales, the surfaces of which it is intended to lubricate.

Muscles.—The intrinsic muscles of the larynx are eight in number, five of which are the muscles of the chordæ vocales and rima glottidis; three are connected with the epiglottis.

The five muscles of the chordæ vocales and rima glottidis are the

Crico-thyroid.
Crico-arytænoideus posticus.
Crico-arytænoideus lateralis.
Arytænoideus.
Thyro-arytænoideus.

The *Crico-thyroid* is triangular in form, and situated at the fore part and side of the cricoid cartilage. It arises from the front and lateral part of the cricoid cartilage: its fibres diverge, passing obliquely upward and outward, to be inserted into the lower border of the thyroid cartilage and into the anterior border of the lower cornua.

The inner borders of these two muscles are separated in the middle line by a triangular interval occupied by the crico-thyroid membrane.

The *Crico-arytænoideus posticus* arises from the broad depression occupying each lateral half of the posterior surface of the cricoid cartilage; its fibres pass upward and outward, converging to be inserted into the outer angle of the base of the arytenoid cartilage. The upper fibres are nearly horizontal, the middle oblique, and the lower almost vertical.[1]

---

[1] Dr. Merkel of Leipsic has described a muscular slip which occasionally extends between the

The *Crico-arytænoideus lateralis* is smaller than the preceding, and of an oblong form. It arises from the upper border of the side of the cricoid cartilage, and, passing obliquely upward and backward, is inserted into the outer angle of the base of the arytenoid cartilage in front of the preceding muscle.

The *Arytænoideus* is a single muscle filling up the posterior concave surface of the arytenoid cartilages. It arises from the posterior surface and outer border of one arytenoid cartilage, and is inserted into the corresponding parts of the opposite cartilage. It consists of three planes of fibres, two oblique and one transverse. The *oblique fibres*, the most superficial, form two fasciculi which pass from the base of one cartilage to the apex of the opposite one. The *transverse fibres*, the deepest and most numerous, pass transversely across between the two cartilages; hence the Arytenoideus was formerly considered as several muscles, under the name of *transversi* and *obliqui*. A few of the oblique fibres are occasionally continued round the outer margin of the cartilage, and blend with the Thyro-arytenoid or the Arytæno-epiglottideus muscle.

Fig. 612.

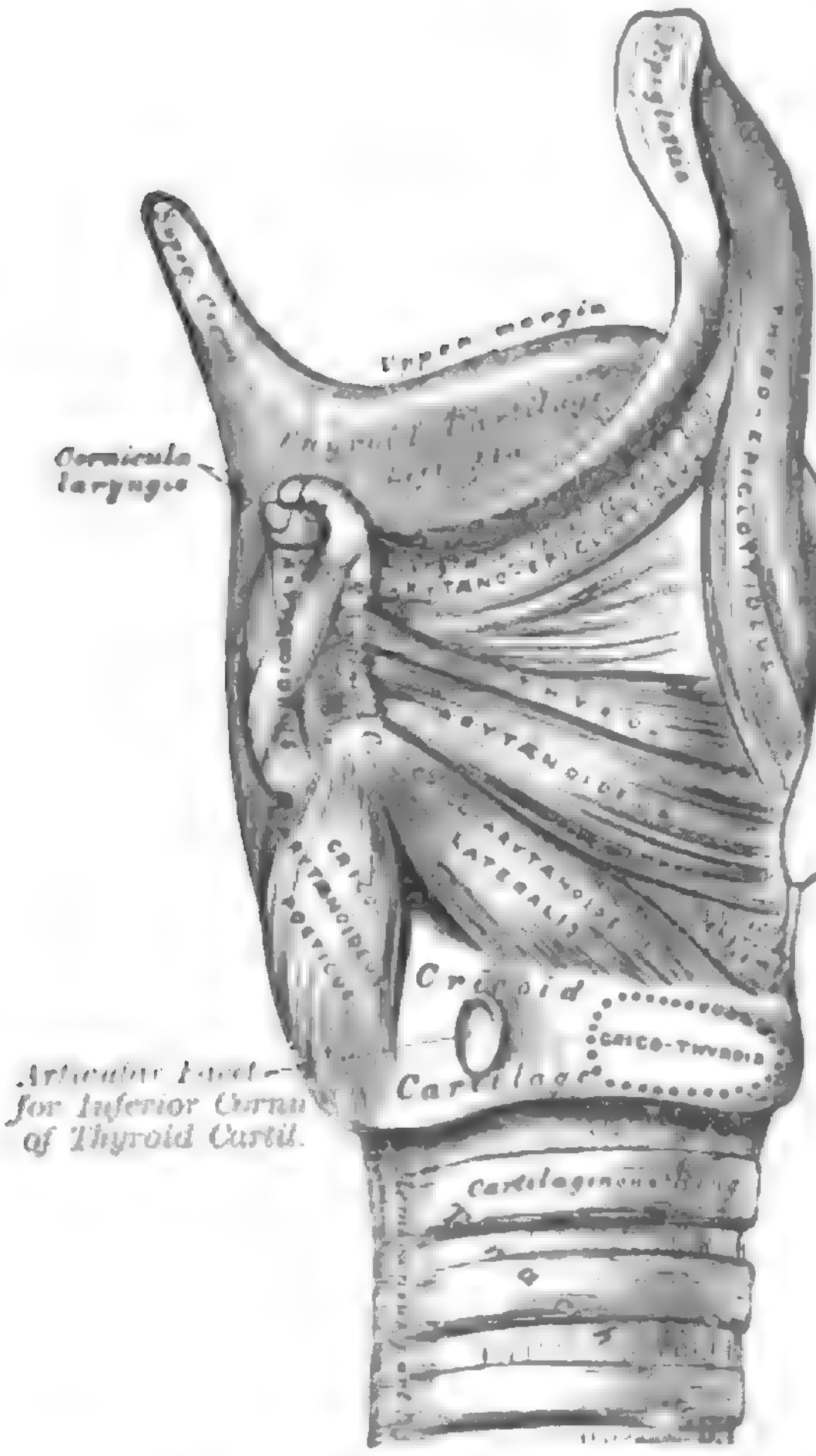
Epiglottis
Upper margin
Thyroid Cartilage
Left Ala
Cornicula laryngis
ARYTÆNO-EPIGLOTTIDEUS
THYRO-EPIGLOTTIDEUS
ARYTÆNOIDEUS
THYRO-ARYTÆNOIDEUS
CRICO-ARYTÆNOIDEUS LATERALIS
CRICO-ARYTÆNOIDEUS POSTICUS
Cricoid
Cartilage
CRICO-THYROID
Articular Facet for Inferior Cornu of Thyroid Cartil.
Cartilaginous Ring

Muscles of Larynx, side view, right ala of thyroid cartilage removed.

Fig. 613.

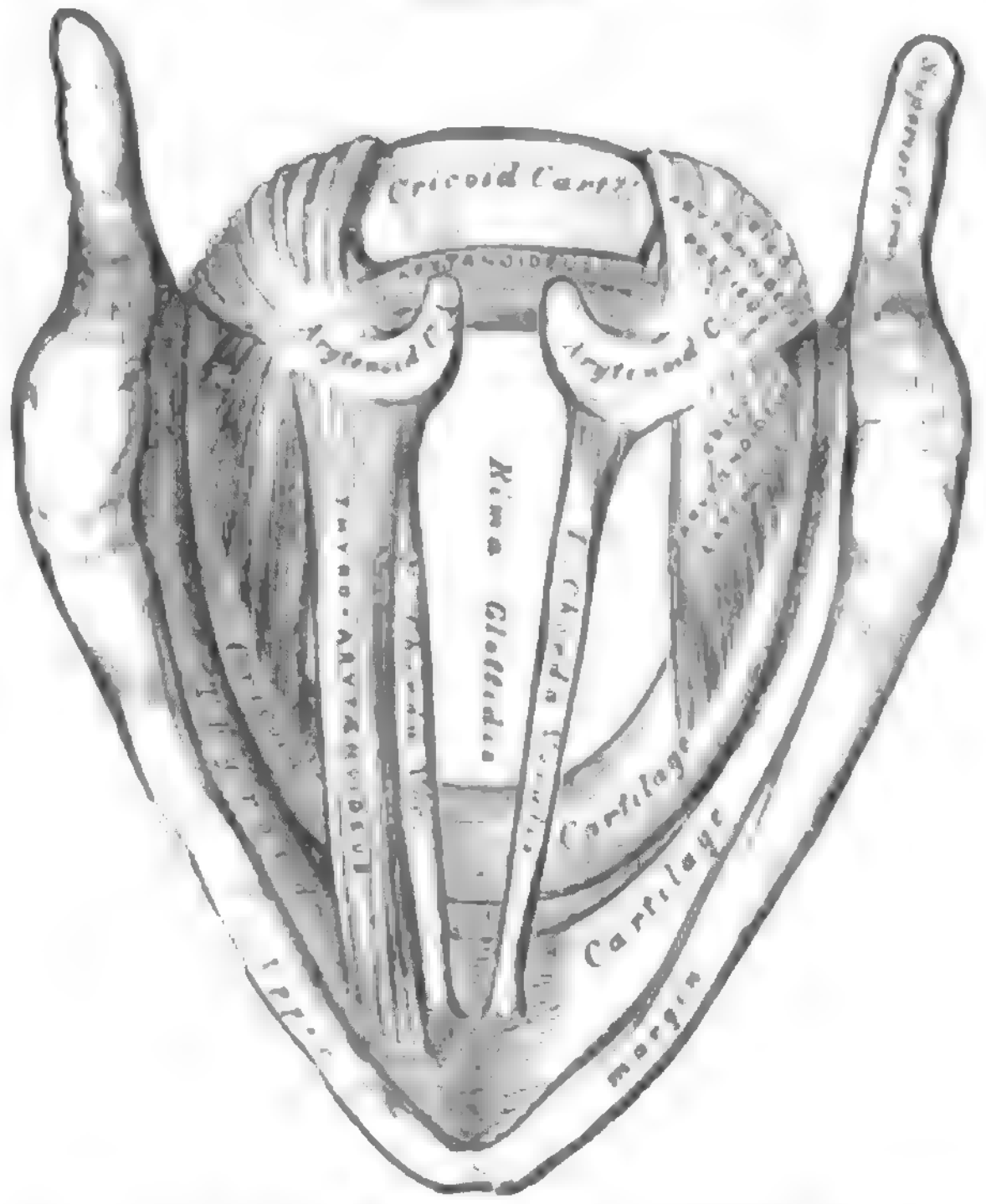
Cricoid Cartil.
ARYTÆNOIDEUS
Arytenoid C.
Arytenoid C.
Rima Glottidis
THYRO-ARYTÆNOIDEUS
Chorda Vocalis
Cartilage
Cartilage
margin

Interior of the Larynx, seen from above (enlarged).

The *Thyro-arytænoideus* is a broad, flat muscle which lies parallel with the outer side of the true vocal chord. It arises in front from the lower half of the receding angle of the thyroid cartilage and from the crico-thyroid membrane. Its fibres pass horizontally backward and outward to be inserted into the base and anterior surface of the arytenoid cartilage. This muscle consists of two fasciculi. The *inferior* or inner portion, the thicker, is inserted into the anterior angle of the base of the arytenoid cartilage and into the adjacent portion of its anterior surface; it lies parallel with the true vocal chord, to which it is adherent. The *superior* fasciculus, the thinner

---

outer border of the posterior surface of the cricoid cartilage and the posterior margin of the inferior cornu of the thyroid; this he calls the "musculus kerato-cricoideus." It is not found in every larynx, and when present exists usually only on one side but is occasionally found on both sides. Mr. Turner (*Edinburgh Medical Journal*, Feb., 1860) states that it is found in about one case in five. Its action is to fix the lower horn of the thyroid cartilage backward and downward, opposing in some measure the part of the Crico-thyroid muscle, which is connected to the anterior margin of the horn.

and outer portion, is inserted into the anterior surface and outer border of the arytenoid cartilage above the preceding fibres; it lies on the outer side of the sacculus laryngis, immediately beneath its mucous lining.

The muscles of the epiglottis are the

Thyro-epiglottideus. Arytæno-epiglottideus superior.
Arytæno-epiglottideus inferior.

The *Thyro-epiglottideus* is a delicate fasciculus which arises from the inner surface of the thyroid cartilage, just external to the origin of the Thyro-arytenoid muscle, and spreads out upon the outer surface of the sacculus laryngis: some of its fibres are lost in the aryteno-epiglottidean fold, whilst others are continued forward to the margin of the epiglottis (*Depressor epiglottidis*).

The *Arytæno-epiglottideus superior* consists of a few delicate muscular fasciculi which arise from the apex of the arytenoid cartilages, and become lost in the fold of mucous membrane extending between the arytenoid cartilage and side of the epiglottis (*aryteno-epiglottidean folds*).

The *Arytæno-epiglottideus inferior* (*Compressor sacculi laryngis*, Hilton) arises from the arytenoid cartilage, just above the attachment of the superior vocal chord: passing forward and upward, it spreads out upon the inner and upper part of the epiglottis. This muscle is separated from the preceding by an indistinct areolar interval.[1]

ACTIONS.—In considering the action of the muscles of the larynx, they may be conveniently divided into two groups—viz.: 1, those which open and close the glottis; 2, those which regulate the degree of tension of the vocal chords.

1. The muscles which open the glottis are the Crico-arytænoidei postici, and those which close it are the Arytænoideus and the Crico-arytænoidei laterales. 2. The muscles which regulate the tension of the vocal chords are the Crico-thyroidei, which make them tense and elongate them, and the Thyro-arytænoidei, which relax and shorten them. The Thyro-epiglottideus is a depressor of the epiglottis, and the Arytæno-epiglottidei constrict the superior aperture of the larynx, compress the sacculi laryngis, and empty them of their contents.

The *Crico-arytænoidei postici* separate the chordæ vocales, and consequently open the glottis, by rotating the arytenoid cartilages outward around a vertical axis passing through the crico-arytenoid joints, so that their anterior angles and the ligaments attached to them become widely separated, the vocal chords at the same time being made tense.

The *Crico-arytænoidei laterales* close the glottis by rotating the arytenoid cartilages inward, so as to approximate their anterior angles.

The *Arytænoideus muscles* approximate the arytenoid cartilages, and thus close the opening of the glottis, especially at its back part.

The *Crico-thyroid muscles* produce tension and elongation of the vocal chords. This was formerly supposed to be effected by drawing down the thyroid over the cricoid, but there seems to be good reason for believing that the thyroid cartilages are fixed by the Thyro-hyoid muscles, and that the Crico-thyroid muscles draw upward the front of the cricoid cartilage and so depress the posterior portion and with it the arytenoid cartilages, and thus elongate the vocal chords.

The *Thyro-arytænoidei muscles*, consisting of two parts having different attachments and different directions, are rather complicated as regards their action. Their main use is to draw the arytenoid cartilages forward toward the thyroid, and thus shorten and relax the vocal chords. But owing to the connection of the inner portion with the vocal chord, this part, if acting separately, is supposed to modify its elasticity and tension, and the outer portion, being inserted into the outer part of the anterior surface of the arytenoid cartilage, may rotate it inward, and thus narrow the rima glottidis by bringing the two chords together.

The *Thyro-epiglottidei* depress the epiglottis and assist in compressing the sacculi laryngis. The Arytæno-epiglottideus superior constricts the superior aperture of the larynx when it is drawn upward during deglutition and the opening closed by the epiglottis. The Arytæno-epiglottideus inferior, together with some fibres of the Thyro-arytænoidei, compress the sacculus laryngis.

---

[1] MUSCULUS TRITICEO-GLOSSUS.—Bochdalek, jun. (*Prager Vierteljahrsschrift*, 2d Part, 1866), describes a muscle hitherto entirely overlooked, except a brief statement in Henle's *Anatomy*, which arises from the nodule of cartilage (corpus triticeum) in the posterior thyro-hyoid ligament, and passes forward and upward to enter the tongue along with the Kerato-glossus muscle. He met with this muscle eight times in twenty-two subjects. It occurred in both sexes, sometimes on both sides, at others on one only.

The **Mucous Membrane** of the larynx is continuous above with that lining the mouth and pharynx, and is prolonged through the trachea and bronchi into the lungs. It lines the posterior and upper part of the anterior surface of the epiglottis, to which it is closely adherent, and forms the aryteno-epiglottidean folds which encircle the superior aperture of the larynx. It lines the whole of the cavity of the larynx, forms by its reduplication the chief part of the superior or false vocal chord, and from the ventricle is continued into the sacculus laryngis. It is then reflected over the true vocal chords, where it is thin and very intimately adherent, covers the inner surface of the crico-thyroid membrane and cricoid cartilage, and is ultimately continuous with the lining membrane of the trachea. It is covered with columnar ciliated epithelium below the superior vocal chord; but above this point the cilia are found only in front as high as the middle of the epiglottis. In the rest of its extent the epithelium is of the squamous variety.

GLANDS.—The mucous membrane of the larynx is furnished with very many muciparous glands, the orifices of which are found in nearly every part; they are very numerous upon the epiglottis, being lodged in little pits in its substance; they are also found in large numbers along the posterior margin of the arytenoid-epiglottidean fold, in front of the arytenoid cartilages, where they are termed the *arytenoid glands*. They exist also in large numbers upon the inner surface of the sacculus laryngis. None are found on the vocal chords.

VESSELS AND NERVES.—The *arteries* of the larynx are the laryngeal branches derived from the superior and inferior thyroid. The *veins* empty themselves into the superior, middle, and inferior thyroid veins. The *lymphatics* terminate in the deep cervical glands. The *nerves* are the superior laryngeal and the inferior or recurrent laryngeal branches of the pneumogastric nerves, joined by filaments from the sympathetic. The superior laryngeal nerves supply the mucous membrane of the larynx and the Crico-thyroid muscles. The inferior laryngeal nerves supply the remaining muscles. The Arytenoid muscle is supplied by both nerves.

THE TRACHEA (Fig. 614).

The **Trachea, or Windpipe,** is a cartilaginous and membranous cylindrical tube, flattened posteriorly, which extends from the lower part of the larynx, on a level with the sixth cervical vertebra, to opposite the fourth, or sometimes the fifth, dorsal, where it divides into the two bronchi, one for each lung. The trachea measures about four inches and a half in length; its diameter from side to side is from three-quarters of an inch to an inch, being always greater in the male than in the female.

RELATIONS.—The anterior surface of the trachea is convex, and covered *in the neck*, from above downward, by the isthmus of the thyroid gland, the inferior thyroid veins, the arteria thyroidea ima (when that vessel exists), the Sterno-hyoid and Sterno-thyroid muscles, the cervical fascia (in the interval between those muscles), and, more superficially, by the anastomosing branches between the anterior jugular veins; *in the thorax* it is covered from before backward by the first piece of the sternum, the remains of the thymus gland, the left innominate vein, the arch of the aorta, the innominate and left carotid arteries, and the deep cardiac plexus. It lies upon the œsophagus, which is directed to the left near the arch of the aorta; laterally, *in the neck*, it is in relation with the common carotid arteries, the lateral lobes of the thyroid gland, the inferior thyroid arteries, and recurrent laryngeal nerves; and *in the thorax* it lies in the interspace between the pleuræ, having the pneumogastric nerve on each side of it.

The **Right Bronchus**, wider, shorter, and more horizontal in direction than the left, is about an inch in length, and enters the right lung opposite the fifth dorsal vertebra. The vena azygos arches over it from behind, and the right pulmonary artery lies below, and then in front of it.

The **Left Bronchus** is smaller, more oblique, and longer than the right, being nearly two inches in length. It enters the root of the left lung opposite the sixth

FIG. 614.

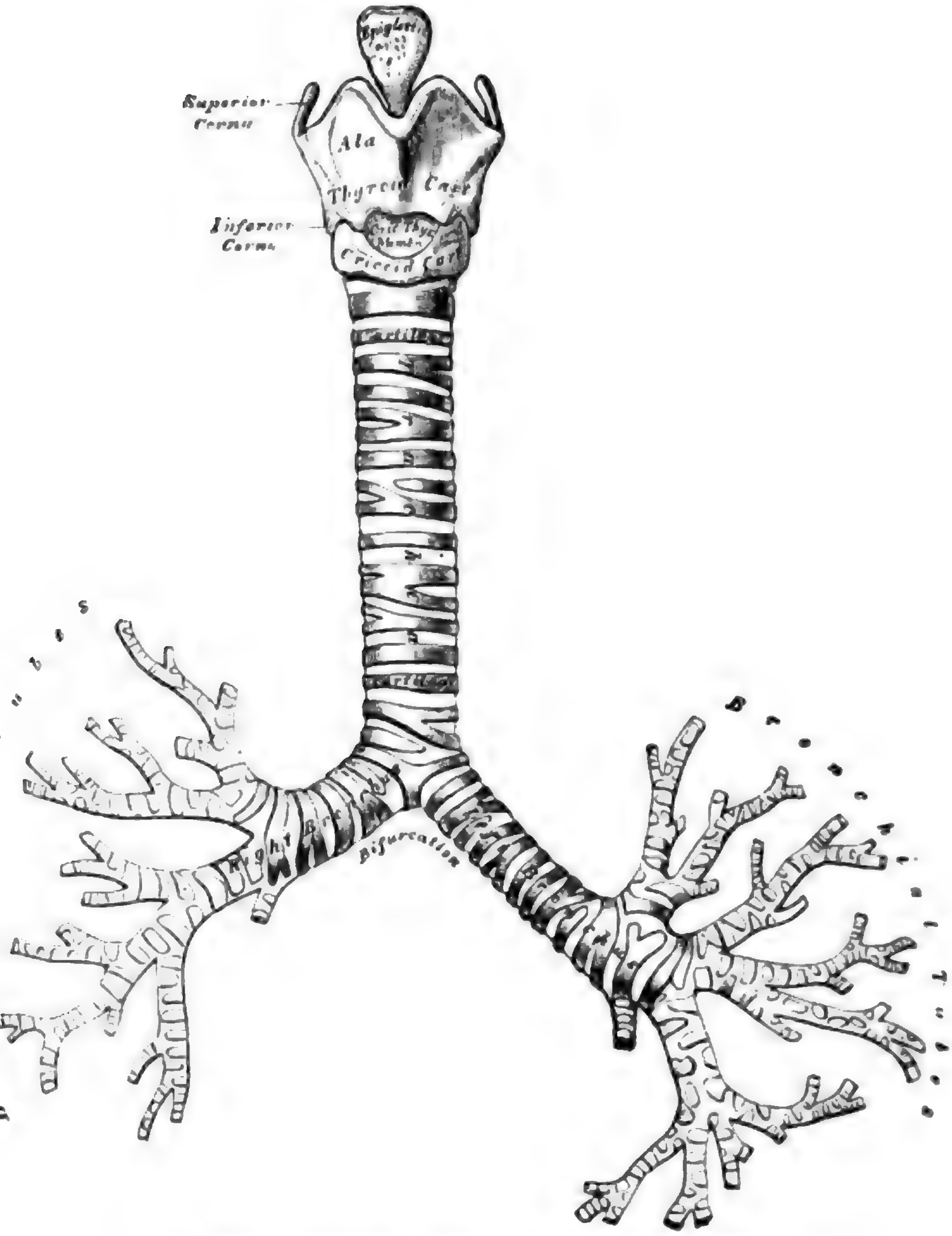
Epiglott.
Superior Cornu
Ala
Thyroid Cart.
Inferior Cornu
Crico-thyr. Memb.
Cricoid Cart.
Cartilages
Right Bronchus
Bifurcation
Bronchial Tubes
Bronchial Tubes

Front View of Cartilages of Larynx: the Trachea and Bronchi.

dorsal vertebra, about an inch lower than the right bronchus. It passes beneath the arch of the aorta, crosses, in front of the œsophagus, the thoracic duct and the descending aorta, and has the left pulmonary artery lying at first above, and then in front of it. If a transverse section is made across the trachea a short distance above its point of bifurcation, and a bird's-eye view taken of its interior (Fig. 615), the septum placed at the bottom of the trachea and separating the two bronchi will be seen to occupy the left of the median line, as was first shown by Mr. Goodall of Dublin, so that any solid body dropping into the trachea would naturally be directed toward the right bronchus; and this tendency is undoubtedly aided by the larger size of this

FIG. 615.

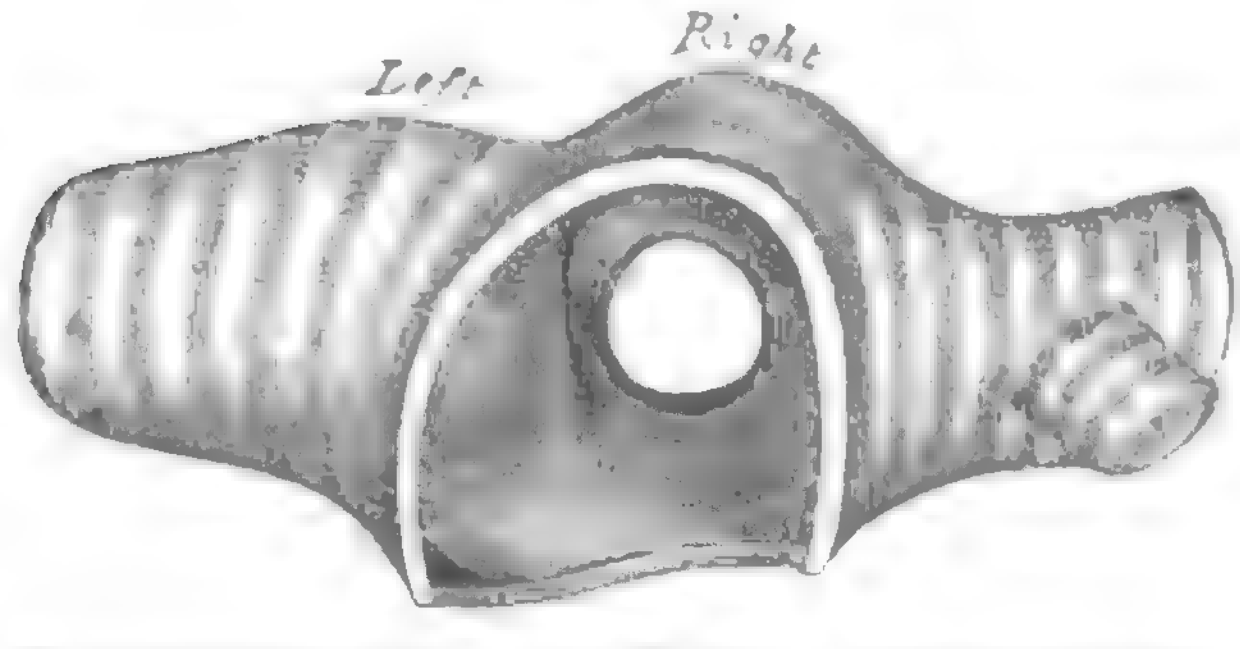

Transverse Section of the Trachea, just above its bifurcation, with a bird's-eye view of the interior.

tube as compared with its fellow. This fact serves to explain why a foreign substance in the trachea generally falls into the right bronchus.

Structure.—The trachea is composed of imperfect cartilaginous rings, fibrous membrane, muscular fibres, longitudinal yellow elastic fibres, mucous membrane, and glands.

The **Cartilages** vary from sixteen to twenty in number: each forms an imperfect ring, which surrounds about two-thirds of the cylinder of the trachea, being imperfect behind, where the tube is completed by fibrous membrane. The cartilages are placed horizontally above each other, separated by narrow membranous intervals. They measure about two lines in depth and half a line in thickness. Their outer surfaces are flattened, but internally they are convex, from being thicker in the middle than at the margins. The cartilages are enclosed in an elastic fibrous membrane, which forms a double layer, one layer, the thicker of the two, passing over the outer surface of the ring, the other over the inner surface: at the upper and lower margins of the cartilages these two layers blend together to form a single membrane, which connects the rings one with another. They are thus, as it were, imbedded in the membrane. In the space behind, between the extremities of the rings, the membrane forms a single distinct layer. The peculiar cartilages are the first and the last.

The *first cartilage* is broader than the rest, and sometimes divided at one end; it is connected by fibrous membrane with the lower border of the cricoid cartilage, with which or with the succeeding cartilage it is sometimes blended.

The *last cartilage* is thick and broad in the middle, in consequence of its lower border being prolonged into a triangular hook-shaped process which curves downward and backward between the two bronchi. It terminates on each side in an imperfect ring, which encloses the commencement of the bronchi. The cartilage above the last is somewhat broader than the rest at its centre. Two or more of the cartilages often unite partially or completely, and are sometimes bifurcated at their extremities. They are highly elastic, and seldom ossify, even in advanced life. In the right bronchus the cartilages vary in number from six to eight; in the left, from nine to twelve. They are shorter and narrower than those of the trachea.

The **Muscular Fibres** are disposed in two layers, longitudinal and transverse. The *longitudinal* fibres are the most external, and arise by minute tendons from the inner surfaces of the ends of the tracheal cartilages and from the fibrous membrane.

The *transverse fibres* (Trachealis muscle, Todd and Bowman), the most internal, form a thin layer which extends transversely between the ends of the cartilages and the intervals between them at the posterior part of the trachea. The muscular fibres are of the unstriped variety.

The **Elastic Fibres** form a complete lining to the entire cylinder of the trachea external to the mucous membrane: they are most abundant at the posterior part of the tube, between the extremities of the rings, where they are collected into distinct longitudinal bundles, and are especially numerous about the bifurcation of the trachea. They may be traced downward as a continuous membrane to the ultimate ramifications of the bronchial tubes. The fibres are contained in a loose submucous tissue together with numerous mucous glands.

The **Mucous Membrane** contains a large amount of lymphoid tissue. It presents a well-marked basement membrane, supporting a layer of columnar ciliated epithelium, between the deeper ends of which are smaller round or elongated cells. It is continuous above with that of the larynx, and below with that of the lungs.

The **Tracheal Glands** are found in great abundance at the posterior part of the trachea. They are small flattened, ovoid bodies, placed upon the outer surface of the fibrous layer, each furnished with an excretory duct, which pierces the fibrous and muscular layers and opens on the surface of the mucous membrane. Some glands of smaller size are also found at the sides of the trachea, between the layers of fibrous tissue connecting the rings, and others immediately beneath the mucous coat. The secretion from these glands serves to lubricate the inner surface of the trachea.

Vessels and Nerves.—The trachea is supplied with blood by the inferior thyroid arteries. The *veins* terminate in the thyroid venous plexus. The *nerves* are derived from the pneumogastric and its recurrent branches and from the sympathetic.

Surgical Anatomy.—The air-passages may be opened in two different situations: through the crico-thyroid membrane (*laryngotomy*), or in some part of the trachea (*tracheotomy*); and to these some surgeons have added a third method, by opening the crico-thyroid membrane and dividing the cricoid cartilage with the upper ring of the trachea (*laryngo-tracheotomy*). The student should carefully consider the relative anatomy of the air-tube in each of these situations (Fig. 616).

Fig. 616.

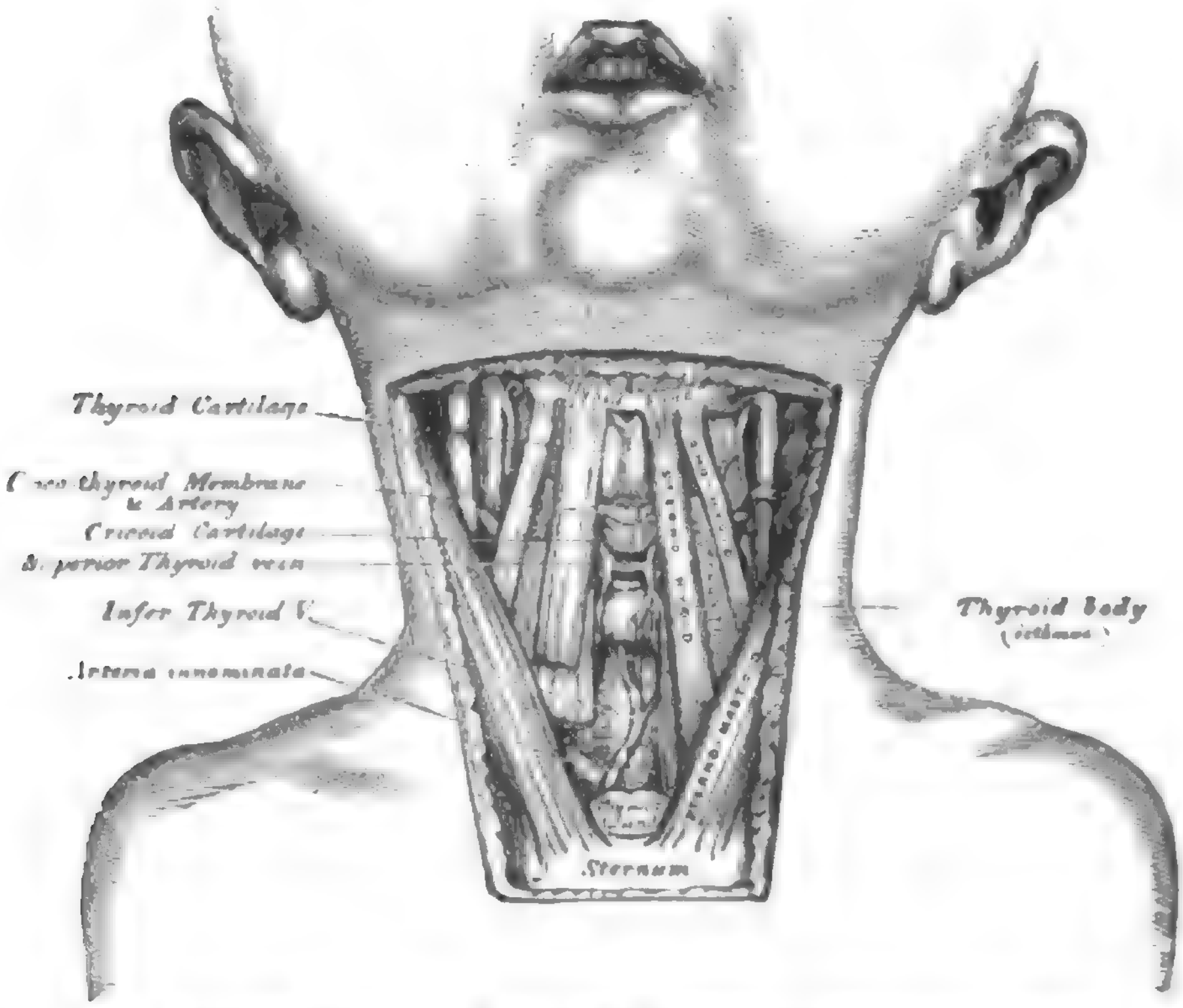

Surgical Anatomy of Laryngo-Tracheal Region, in the infant.

Laryngotomy is anatomically the most simple operation; it can most readily be performed, and should always be preferred when particular circumstances do not render the operation of tracheotomy absolutely necessary [or when instant operation is needful].

The crico-thyroid membrane is very superficial, being covered only in the middle line by the skin, superficial fascia, and the deep fascia. On each side of the middle line it is also covered by the Sterno-hyoid and Sterno-thyroid muscles, which diverge slightly from each other at their upper parts, leaving a slight interval between them. On these muscles rests the anterior jugular vein. The only vessel of any importance in connection with this operation is the crico-thyroid artery, which crosses the crico-thyroid membrane and which may be wounded, but rarely gives rise to any trouble. The operation is performed thus: The head being thrown back and steadied by an assistant, the finger is passed over the front of the neck and the crico-thyroid depression felt for. A vertical incision is then made through the skin in the middle line over this spot, and carried down through the fascia until the crico-thyroid membrane is exposed. A cross-cut is then made through the membrane close to the upper border of the cricoid cartilage, so as to avoid, if possible, the crico-thyroid artery, and a tracheotomy-tube introduced. It has been recommended, as a more rapid way of performing the operation, to make a transverse instead of a longitudinal cut through the superficial structures, and to cut at once into the air-passages. It will seen, however, that in operating in this way the anterior jugular veins would be in danger of being wounded.

Tracheotomy may be performed either above or below the isthmus of the thyroid body, or this structure may be divided and the trachea opened beneath it.

The isthmus of the thyroid gland usually crosses the second and third rings of the trachea; along its upper border is frequently to be found a large transverse communicating branch between the superior thyroid veins, and the isthmus itself is covered by a venous plexus formed between the thyroid veins of opposite sides. Theoretically, therefore, it is advisable to avoid dividing this structure in opening the trachea.

Above the isthmus the trachea is comparatively superficial, being covered by the skin, superficial fascia, deep fascia, Sterno-hyoid and thyroid muscles, and a second layer of the deep fascia, which, attached above to the lower border of the hyoid bone, descends beneath the muscles to the thyroid body, where it divides into two layers and encloses the isthmus.

Below the isthmus the trachea lies much more deeply, and is covered by the Sterno-hyoid and the Sterno-thyroid muscles and a quantity of loose areolar tissue, in which is a plexus of veins, some of them of large size, and which converge to two trunks, the inferior thyroid veins, which descend on either side of the median line on the front of the trachea to open into the innominate veins. In the infant the thymus gland ascends a variable distance along the front of the trachea, and opposite the episternal notch the windpipe is crossed by the left innominate vein. Occasionally also, in young subjects, the innominate artery crosses the tube obliquely above the level of the sternum. The arteria thyroidea ima, when that vessel exists, passes from below upward along the front of the trachea.

From these observations it must be evident that the trachea can be more readily opened above than below the isthmus of the thyroid body.

Tracheotomy above the isthmus is performed thus: The patient should, if possible, be laid on his back on a table in a good light. A pillow is to be placed under the shoulders and the head thrown back and steadied by an assistant. The surgeon, standing on the right side of his patient, makes an incision from an inch and a half to two inches in length in the median line of the neck from the top of the cricoid cartilage. The incision must be made exactly in the middle line, so as to avoid the anterior jugular veins, and after the superficial structures have been divided the interval between the Sterno-hyoid muscles must be found, the raphé divided, and the muscles drawn apart. The lower border of the cricoid cartilage must now be felt for, and the upper part of the trachea exposed from this point downward in the middle line. Bose has recommended that the layer of fascia in front of the trachea should be divided transversely at the level of the lower border of the cricoid cartilage, and, having been seized with a pair of forceps, pressed downward with the handle of the scalpel. By this means the isthmus of the thyroid gland is depressed and is saved from all danger of being wounded, and the trachea clearly exposed. The trachea is now transfixed with a sharp hook and drawn forward in order to steady it, and is then opened by inserting the knife into it and dividing the two or three upper rings of the trachea from below upward. If the trachea is to be opened below the isthmus, the incision must be made from a little below the cricoid cartilage to the top of the sternum.

In the child the trachea is smaller, more deeply placed, and more movable than in the adult. In fat or short-necked people, or in those in whom the muscles of the neck are prominently developed, the trachea is more deeply placed than in the opposite conditions.

[For a careful study of the "Anatomy of the Anterior Median Region of the Neck," with especial reference to tracheotomy in children, see Pilcher, *Brooklyn Annals of Anatomy and Surgery*, 1881.

Intubation of the Larynx.—Dr. O'Dwyer has recently reintroduced this operation as a substitute for tracheotomy, with great ingenuity and success. A tube, varying in size according to the size and age of the patient, with a flange to prevent its slipping into the trachea, is temporarily attached to a handle and introduced through the glottis into the larynx, the flange at the upper end resting on the vocal chords. The handle being now detached, the tube is left *in situ*. It is removed also by a temporary handle.]

THE PLEURÆ.

Each lung is invested upon its external surface by an exceedingly delicate serous membrane, the **Pleura,** which encloses the organ as far as its root, and is then reflected upon the inner surface of the thorax. The portion of the serous membrane investing the surface of the lung is called the *pleura pulmonalis* (visceral layer of pleura), while that which lines the inner surface of the chest is called the *pleura costalis* (parietal layer of the pleura). The interspace or cavity between these two layers is called the *cavity of the pleura.* Each pleura is therefore a shut sac, one occupying the right, the other the left half of the thorax, and they are perfectly separate, not communicating with each other. The two pleuræ do not meet in the middle line of the chest, excepting opposite the upper part of the second piece of the sternum; an interspace is thus left between them which contains all the viscera of the thorax excepting the lungs: this is the *mediastinum.*

Reflections of the Pleura (Fig. 617).—Commencing at the sternum, the pleura passes outward, covers the costal cartilages, the inner surface of the ribs and Intercostal muscles, and at the back part of the thorax passes over the thoracic ganglia and their branches, and is reflected upon the sides of the bodies of the vertebræ, where it is separated by a narrow interspace from the opposite pleura, the *posterior mediastinum.* From the vertebral column the pleura passes to the side of the pericardium, which it covers to a slight extent: it then covers the back part of the root of the lung, from the lower border of which a triangular fold descends vertically by the side of the posterior mediastinum to the Diaphragm. This fold is the broad ligament of the lung, the *ligamentum latum pulmonis*, and serves to retain the lower part of that organ in position. From the *root* the pleura may be traced over the convex surface of the lung, the summit, and base, and also over the sides of the fissures between the lobes. It covers its anterior surface and the front part of its root, and is reflected upon the side of the pericardium to the inner surface of the sternum. *Below*, it covers the upper surface of the Diaphragm; *above*, its apex projects, in the form of a cul-de-sac, through the superior opening of the thorax into the neck, extending from one to two inches above the margin of the first rib, and receives the summit of the corresponding lung; this sac is strengthened, according to Dr. Sibson, by a dome-like expansion of fascia derived from that covering the lower part of the Scaleni muscles.

FIG. 617.

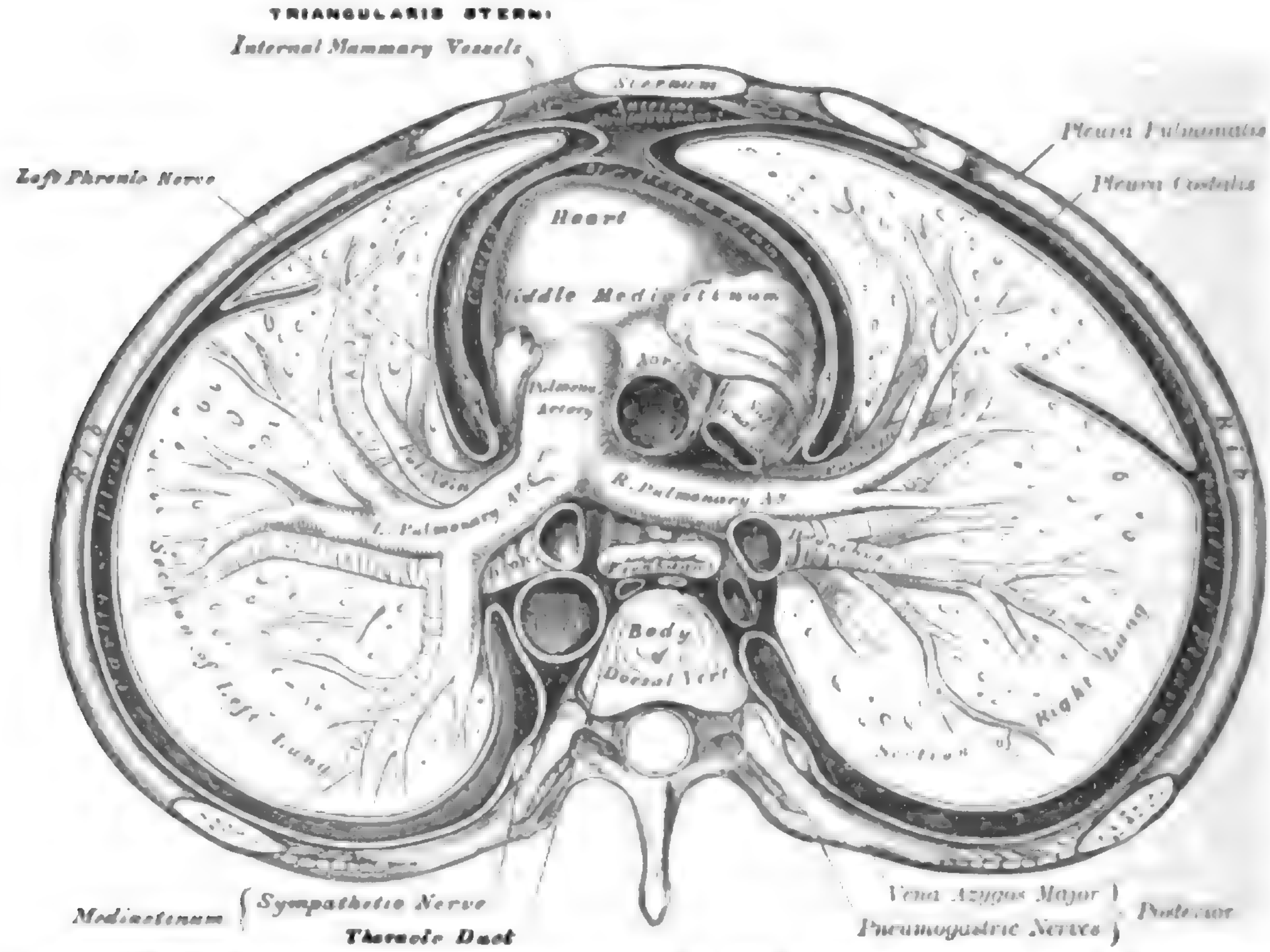
TRIANGULARIS STERNI
Internal Mammary Vessels
Sternum
Pleura Pulmonalis
Pleura Costalis
Left Phrenic Nerve
Heart
Middle Mediastinum
Aor
Pulmonary Artery
Pul. Vein
R. Pulmonary A.
L. Pulmonary A.
Rib
Pleura
Rib
Section of Left Lung
Body of Dorsal Vert
Section of Right Lung
Mediastinum
Sympathetic Nerve
Thoracic Duct
Vena Azygos Major
Pneumogastric Nerves
Posterior

A Transverse Section of the Thorax, showing the relative position of the viscera and the reflections of the pleuræ.

A little above the middle of the sternum the contiguous surfaces of the two pleuræ are sometimes in contact for a slight extent; but above and below this point the interval left between them forms the anterior mediastinum.

The inner surface of the pleura is smooth, polished, and moistened by a serous fluid; its outer surface is intimately adherent to the surface of the lung and to the pulmonary vessels as they emerge from the pericardium; it is also adherent to the upper surface of the Diaphragm: throughout the rest of its extent it is somewhat thicker, and may be separated from the adjacent parts with extreme facility.

The right pleural sac is shorter, wider, and reaches higher in the neck than the left.

VESSELS AND NERVES.—The *arteries* of the pleura are derived from the intercostal, the internal mammary, the musculo-phrenic, thymic, pericardiac, and bronchial. The *veins* correspond to the arteries. The *lymphatics* are very numerous. The *nerves* are derived from the phrenic and sympathetic (Luschka). Kölliker states that nerves accompany the ramification of the bronchial arteries in the pleura pulmonalis.

MEDIASTINUM.

The mediastinum is the space left in the median line of the chest by the non-approximation of the two pleuræ. It extends from the sternum in front to the spine behind, and contains all the viscera in the thorax excepting the lungs. The mediastinum may be divided for purposes of description into two parts: an upper portion, above the upper level of the pericardium, which is named the superior

Fig. 618.

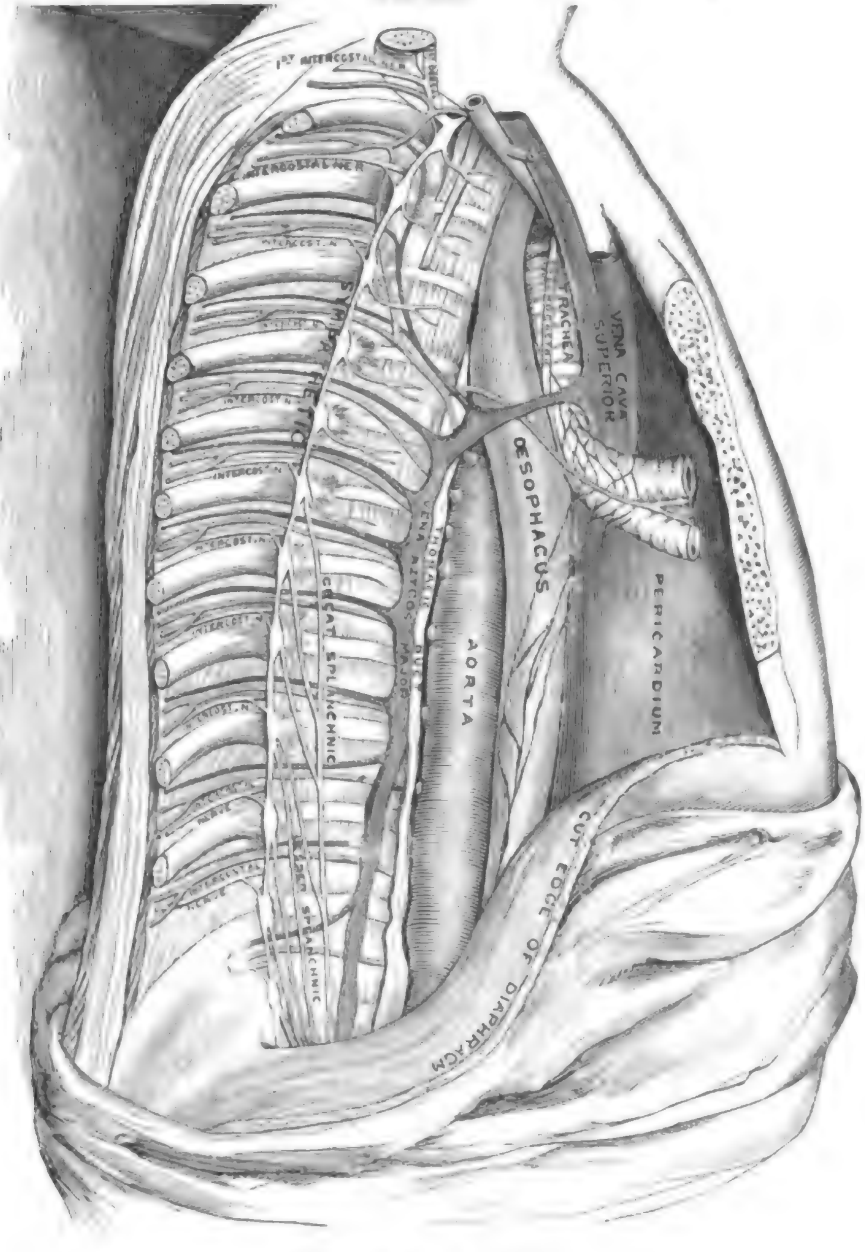
1ST INTERCOSTAL NER
INTERCOSTAL NER
INTERCOST. N
INTERCOST. N
INTERCOST. N
INTERCOST. N
INTERCOST. N
INTERCOST. N
SYMPATHETIC
TRACHEA
VENA CAVA SUPERIOR
OESOPHAGUS
VENA AZYGOS MAJOR
THORACIC DUCT
GREAT SPLANCHNIC
LESSER SPLANCHNIC
AORTA
PERICARDIUM
CUT EDGE OF DIAPHRAGM

The Posterior Mediastinum.

mediastinum (Struthers), and a lower portion, below the upper level of the pericardium. This lower portion is again subdivided into three: that part which is contained and filled by the pericardium and its contents, the *middle mediastinum;* that part which is in front of the pericardium, the *anterior mediastinum;* and that part which is behind the pericardium, the *posterior mediastinum.*

The **superior mediastinum** is that portion of the interpleural space which lies above the upper level of the pericardium between the manubrium sterni in front and the upper dorsal vertebræ behind. It is bounded below by a plane passing backward from the junction of the manubrium and gladiolus sterni to the lower part of the body of the fourth dorsal vertebra (Thane) or third dorsal vertebra (Struthers). It contains the origins of the Sterno-hyoid and Sterno-thyroid muscles and the lower ends of the Longus colli muscles; the transverse portion of the arch of the aorta; the innominate, the left carotid, and subclavian arteries; the superior vena cava and the innominate veins and the left superior intercostal vein; the pneumogastric, cardiac, phrenic, and left recurrent laryngeal nerves; the trachea, œsophagus, and thoracic duct; the remains of the thymus gland and lymphatics.

The **anterior mediastinum** is bounded in front by the sternum, on each side by the pleura, and behind by the pericardium. Owing to the oblique position of the heart toward the left side, this space is not parallel with the sternum, but directed obliquely from above downward and to the left of the median line; it is broad below, narrow above, very narrow opposite the second piece of the sternum, the contiguous surfaces of the two pleuræ being occasionally united over a small space. The anterior mediastinum contains the origins of the Triangularis sterni muscles, the internal mammary vessels of the left side, and a quantity of loose areolar tissue in which some lymphatic vessels are found ascending from the convex surface of the liver, and two or three lymphatic glands (anterior mediastinal glands).

The **middle mediastinum** is the broadest part of the interpleural space. It contains the heart enclosed in the pericardium, the ascending aorta, the superior vena cava, the bifurcation of the trachea, the pulmonary arteries and veins, and the phrenic nerves.

The **posterior mediastinum** is an irregular triangular space running parallel with the vertebral column; it is bounded in front by the pericardium and roots of the lungs, behind by the vertebral column from the lower border of the fourth dorsal vertebra downward, and on either side by the pleura. It contains the descending portion of the arch and descending thoracic aorta, the greater and lesser azygos veins, the pneumogastric and splanchnic nerves, the œsophagus, thoracic duct, and some lymphatic glands.

THE LUNGS.

The **Lungs** are the essential organs of respiration; they are two in number, placed one in each of the lateral cavities of the chest, separated from each other by the heart and other contents of the mediastinum. Each lung is conical in shape, and presents for examination an apex, a base, two borders, and two surfaces. (See Fig. 619.)

The *apex* forms a tapering cone which extends into the root of the neck about an inch to an inch and a half above the level of the first rib. [This cervical prolongation of the lung above the clavicle is often forgotten in auscultation and percussion.]

The *base* is broad, concave, and rests upon the convex surface of the Diaphragm; its circumference is thin, and fits into the space between the lower ribs and the costal attachment of the Diaphragm, extending lower down externally and behind than in front.

The *external* or *thoracic surface* is smooth, convex, of considerable extent, and corresponds to the form of the cavity of the chest, being deeper behind than in front.

The *inner surface* is concave. It presents in front a depression corresponding to the convex surface of the pericardium, and behind a deep fissure (the **hilum pulmonis**) which gives attachment to the root of the lung.

The *posterior border* is rounded and broad, and is received in the deep concavity on either side of the spinal column. It is much longer than the anterior border, and projects below between the ribs and the Diaphragm.

The *anterior border* is thin and sharp, and overlaps the front of the pericardium. The anterior border of the right lung corresponds to the median line of the chest from the junction of the first and second pieces of the sternum as low as the sixth costal cartilage. The anterior border of the left lung lies in the mid-line only as low as the fourth costal cartilage; below this it presents a V-shaped notch, in which the pericardium is exposed. The two lungs are therefore in contact in the middle line, the pleura only being interposed between the levels of the second and fourth costal cartilages.

Fig. 619.

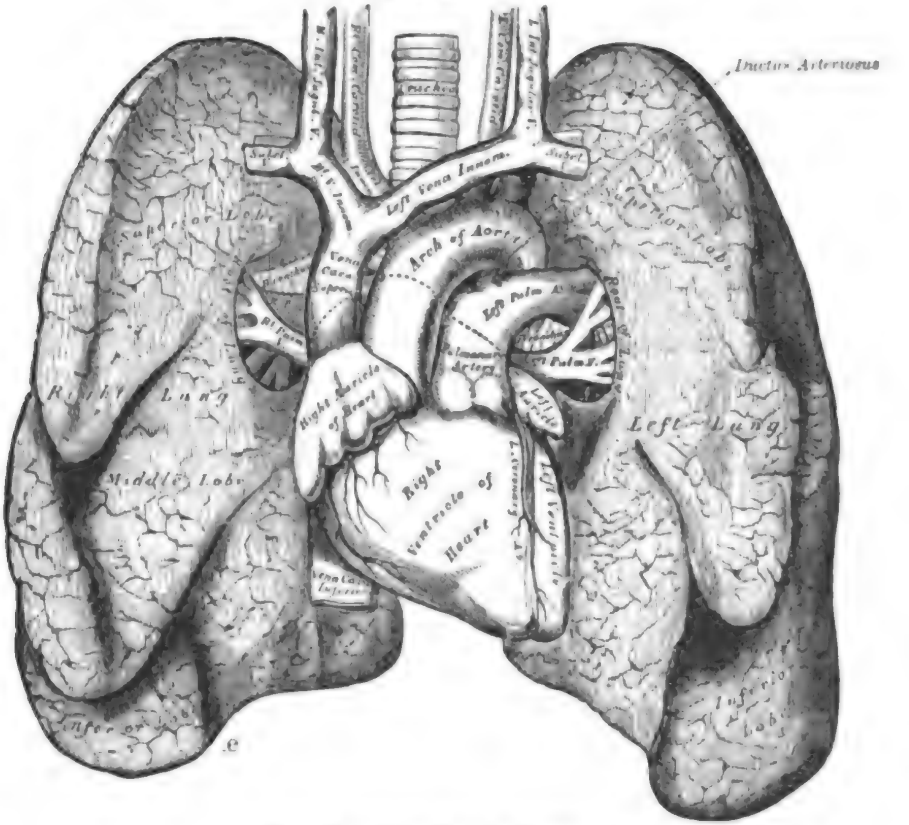
R. Int. Jugular V.
Rt. Com. Carotid
Trachea
L. Com. Carotid
L. Int. Jugular V.
Ductus Arteriosus
Subcl.
Subcl.
Rt. V. Innom.
Left Vena Innom.
Superior Lobe
Superior Lobe
Vena Cava Super.
Arch of Aorta
Bronchus
Rt. Pulm.
Left Pulm. A.
Root of Lung
Root of Lung
Bronchus
Pulmonary Artery
Lt. Pulm. V.
Right Auricle of Heart
Left Auricle
Right Lung
Left Lung
Middle Lobe
Right Ventricle of Heart
L. Coronary
Left Ventricle
Vena Cava Inferior
Inferior Lobe
Inferior Lobe
e

Front View of the Heart and Lungs.

Each lung is divided into two lobes, an upper and lower, by a long and deep fissure which extends from the upper part of the posterior border of the organ, about three inches from its apex, downward and forward to the lower part of its anterior border. This fissure penetrates nearly to the root. In the right lung the upper lobe is partially divided by a second and shorter fissure, which extends from the middle of the preceding, forward and upward, to the anterior margin of the organ, marking off a small triangular portion, the middle lobe.

The *right lung* is the larger and heavier; it is broader than the left, owing to the inclination of the heart to the left side; it is also shorter by an inch, in consequence of the Diaphragm rising higher on the right side to accommodate the liver.

A little above the middle of the inner surface of each lung, and nearer its posterior than its anterior border, is its root, by which the lung is connected to the heart and the trachea. The root is formed by the bronchial tube, the pulmonary artery, the pulmonary veins, the bronchial arteries and veins, the pulmonary plexus of nerves, lymphatics, bronchial glands, and areolar tissue,—all of which are enclosed by a reflection of the pleura. The root of the right lung lies behind the superior vena cava and ascending portion of the arch of the aorta, and below the vena azygos. That of the left lung passes beneath the arch of the aorta and in front of the descending aorta; the phrenic nerve and the anterior pulmonary plexus lie in front of each, and the pneumogastric and posterior pulmonary plexus behind each.

The chief structures composing the root of each lung are arranged in a similar manner from before backward on both sides—viz. the pulmonary veins most anterior, the pulmonary artery in the middle, and the bronchus, together with the bronchial vessels, behind.

From above downward, on the two sides, their arrangement differs, thus: on the right side their position is—bronchus, pulmonary artery, pulmonary veins; but on the left side their position is—pulmonary artery, bronchus, pulmonary veins; which is accounted for by the bronchus being placed on a lower level on the left than on the right side, in order that it may pass under the arch of the aorta.

The *weight* of both lungs together is about forty-two ounces, the right lung being two ounces heavier than the left; but much variation is met with, according to the amount of blood or serous fluid they may contain. The lungs are heavier in the male than in the female, their proportion to the body being in the former as 1 to 37; in the latter, as 1 to 43. The specific gravity of the lung-tissue varies from 0.345 to 0.746, water being 1000.

The *color* of the lungs at birth is a pinkish white; in adult life, a dark slate-color, mottled in patches; and as age advances this mottling assumes a black color. The coloring matter consists of granules of a carbonaceous substance deposited in the areolar tissue near the surface of the organ. It increases in quantity as age advances, and is more abundant in males than in females. The posterior border of the lung is usually darker than the anterior. The surface of the lung is smooth, shining, and marked out into numerous polyhedral spaces, indicating the lobules of the organ: the area of each of these spaces is crossed by numerous lighter lines.

The *substance* of the lung is of a light, porous, spongy texture; it floats in water, and crepitates when handled, owing to the presence of air in the tissue. It is also highly elastic; hence the collapsed state of these organs when they are removed from the closed cavity of the thorax.

Structure.—The lungs are composed of an external serous coat, a subserous areolar tissue, and the pulmonary substance or parenchyma.

The *serous coat* is derived from the pleura; it is thin, transparent, and invests the entire organ as far as the root.

The *subserous areolar tissue* contains a large proportion of elastic fibres; it invests the entire surface of the lung and extends inward between the lobules.

The *parenchyma* is composed of lobules, which, although closely connected together by an interlobular areolar tissue, are quite distinct from one another, and may be teased asunder without much difficulty in the fœtus. The lobules vary in size: those on the surface are large, of pyramidal form, the base turned toward the surface; those in the interior smaller and of various forms. Each lobule is composed of one of the ramifications of the bronchial tube and its terminal air-cells, and of the ramifications of the pulmonary and bronchial vessels, lymphatics, and nerves, all of these structures being connected together by areolar fibrous tissue.

The *bronchus* upon entering the substance of the lung divides and subdivides dichotomously throughout the entire organ. Sometimes three branches arise together, and occasionally small lateral branches are given off from the sides of a main trunk. Each of the smaller subdivisions of the bronchi enters a pulmonary lobule (*lobular bronchial tube*), and, again subdividing, ultimately terminates in the intercellular passages and air-cells of which the lobule is composed. Within the lungs the bronchial tubes are circular, not flattened, and their constituent elements present the following peculiarities of structure:

The *cartilages* are not imperfect rings, but consist of thin laminæ, of varied form and size, scattered irregularly along the sides of the tube, being most distinct at the points of division of the bronchi. They may be traced into tubes the diameter of which is only one-fourth of a line. Beyond this point the tubes are wholly membranous. The fibrous coat and the longitudinal elastic fibres are continued into the smallest ramifications of the bronchi. The muscular coat is disposed in the form of a continuous layer of annular fibres, which may be traced upon the smallest bronchial tubes; they consist of the unstriped variety of muscular fibre. The mucous membrane lines the bronchi and its ramifications throughout, and is covered with columnar ciliated epithelium.

According to the observations of Mr. Rainey,[1] the lobular bronchial tubes, on entering the substance of the lobules, divide and subdivide from four to nine times, according to the size of the lobule, continuing to diminish in size until they attain a diameter of $\frac{1}{50}$ to $\frac{1}{30}$ of an inch. They then become changed in structure, losing their cylindrical form, and are continued onward as irregular passages (*infundibula*, —*intercellular passages*, Rainey—*air-sacs*, Waters) through the substance of the lobule, their sides and extremities being closely covered by numerous saccular dilatations, the *air-cells*. This arrangement resembles most closely the naked-eye appearances observed in the reticulated structure of the lung of the tortoise and other Reptilia. Opinions have differed as to the existence of communications or anastomoses between the intercellular passages, or air-sacs. According to Dr. Waters,[2] these air-sacs, as he terms them, are arranged in groups or "lobulettes" of five or six, which spring from the terminal dilatation of a single bronchial tube, but have no other communication with each other or with neighboring lobulettes than that which is afforded by their common connection with the bronchial tubes.

The *air-cells*, *alveoli* (Waters), are small, polyhedral, alveolar recesses separated from each other by thin septa and communicating freely with the intercellular passages or air-sacs. They are well seen on the surface of the lung, and vary from $\frac{1}{200}$ to $\frac{1}{70}$ of an inch in diameter, being largest on the surface at the thin borders and at the apex, and smallest in the interior.

The constituent elements of the bronchial tubes at their termination in the intercellular passages become changed: their walls are now formed by an interlacing of the longitudinal elastic bundles with fibrous tissue; the muscular fibres disappear, and the mucous membrane becomes thin and delicate and lined with a layer of tessellated epithelium. The latter membrane lines the air-cells, and forms by its reduplications the septa intervening between them.

The *Pulmonary Artery* conveys the venous blood to the lungs: it divides into branches which accompany the bronchial tubes, and terminates in a dense capillary network upon the walls of the intercellular passages and air-cells. From this network the radicles of the pulmonary veins arise; coalescing into large branches, they accompany the arteries, and return the blood, purified by its passage through the capillaries, to the left auricle of the heart. In the lung the branches of the pulmonary artery are usually above and in front of a bronchial tube, the vein below.

The *Pulmonary Capillaries* form plexuses which lie immediately beneath the mucous membrane, in the walls and septa of the air-cells, and of the intercellular passages. In the septa between the air-cells the capillary network forms a single layer. The capillaries form a very minute network [Fig. 60, p. 81], the meshes of which are smaller than the vessels themselves;[3] their walls are also exceedingly thin. The vessels of

---

[1] *Medico-Chirurgical Transactions*, vol. xxviii., 1845.

[2] *The Anatomy of the Human Lung*, 1860, pp. 136–150.

[3] The meshes are only 0.002‴ to 0.008‴ in width, while the vessels are 0.003‴ to 0.005‴ (Kölliker, *Human Microscopic Anatomy*).

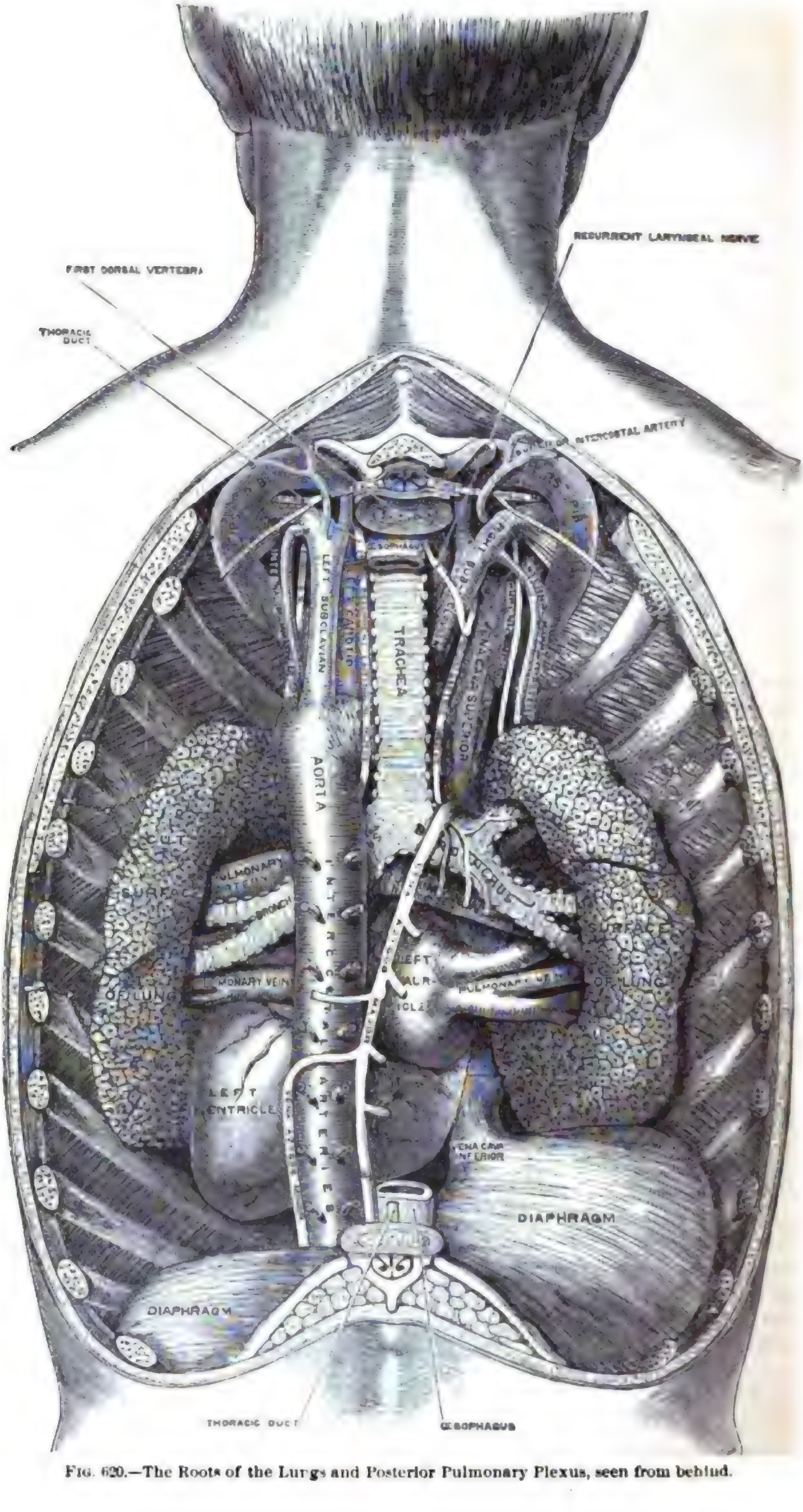
FIRST DORSAL VERTEBRA
THORACIC DUCT
RECURRENT LARYNGEAL NERVE
SUPERIOR INTERCOSTAL ARTERY
LEFT SUBCLAVIAN
L. CAROTID
OESOPHAGUS
TRACHEA
VENA CAVA SUPERIOR
AORTA
SURFACE OF LUNG
PULMONARY ARTERY
BRONCHUS
PULMONARY VEINS
INTERCOSTAL ARTERIES
BRONCHUS
SURFACE OF LUNG
LEFT AURICLE
PULMONARY VEIN
LEFT VENTRICLE
VENA CAVA INFERIOR
DIAPHRAGM
DIAPHRAGM
THORACIC DUCT
ŒSOPHAGUS

FIG. 620.—The Roots of the Lungs and Posterior Pulmonary Plexus, seen from behind.

neighboring lobules are distinct from each other, and do not anastomose; and, according to Dr. Waters, those of the separate groups of intercellular passages, or air-sacs (which groups he denominates lobulettes), are also independent; so that in the septa between two adjoining lobulettes there would be a double layer of capillaries, one layer belonging to each of the adjacent air-sacs or intercellular passages. If this is really the arrangement of the vessels, it would follow that in the septa between the air-cells (or alveoli) the blood in the capillaries would be exposed on all sides to the action of the air, since it is circulating in a single layer of vessels, which is in contact with the membrane of the air-passages on both sides, but that in the septa between the intercellular passages (or air-sacs) the blood in the double layer of capillaries will be in contact with the air on one side only.

The *Bronchial Arteries* supply blood for the nutrition of the lung: they are derived from the thoracic aorta, and, accompanying the bronchial tubes, are distributed to the bronchial glands and upon the walls of the larger bronchial tubes and pulmonary vessels, and terminate in the deep bronchial veins. Others are distributed in the interlobular areolar tissue, and terminate partly in the deep, partly in the superficial, bronchial veins. Lastly, some ramify upon the walls of the smallest bronchial tubes, communicate with the pulmonary capillary plexus, and terminate in the pulmonary veins.

The *Bronchial Vein* is formed at the root of the lung, receiving superficial and deep veins corresponding to branches of the bronchial artery. It does not, however, receive all the blood supplied by the artery, some of it passing into the pulmonary vein. It terminates on the right side in the vena azygos major, and on the left side in the superior intercostal vein.

The *Lymphatics* consist of a superficial and deep set: they terminate at the root of the lung in the bronchial glands.

NERVES.—The lungs are supplied from the anterior and posterior pulmonary plexuses, formed chiefly by branches from the sympathetic and pneumogastric. The filaments from these plexuses accompany the bronchial tubes, upon which they are lost. Small ganglia are found upon these nerves.

THYROID GLAND.

The **Thyroid Gland** bears much resemblance in structure to other glandular organs, and was formerly classified, together with the thymus, suprarenal capsules, and spleen, under the head of *ductless glands*, since it has no excretory duct. Its function is unknown, but from its situation in connection with the trachea and larynx the thyroid body is usually described with those organs, although it takes no part in the function of respiration. It is situated at the upper part of the trachea, and consists of two lateral lobes placed one on each side of that tube and connected together by a narrow transverse portion, the *isthmus*.

Its *anterior surface* is convex, and covered by the Sterno-hyoid, Sterno-thyroid, and Omo-hyoid muscles.

Its *lateral surfaces*, also convex, lie in contact with the sheath of the common carotid artery.

Its *posterior surface* is concave, and embraces the trachea and larynx. The posterior borders of the gland extend as far back as the lower part of the pharynx.

FIG. 621.

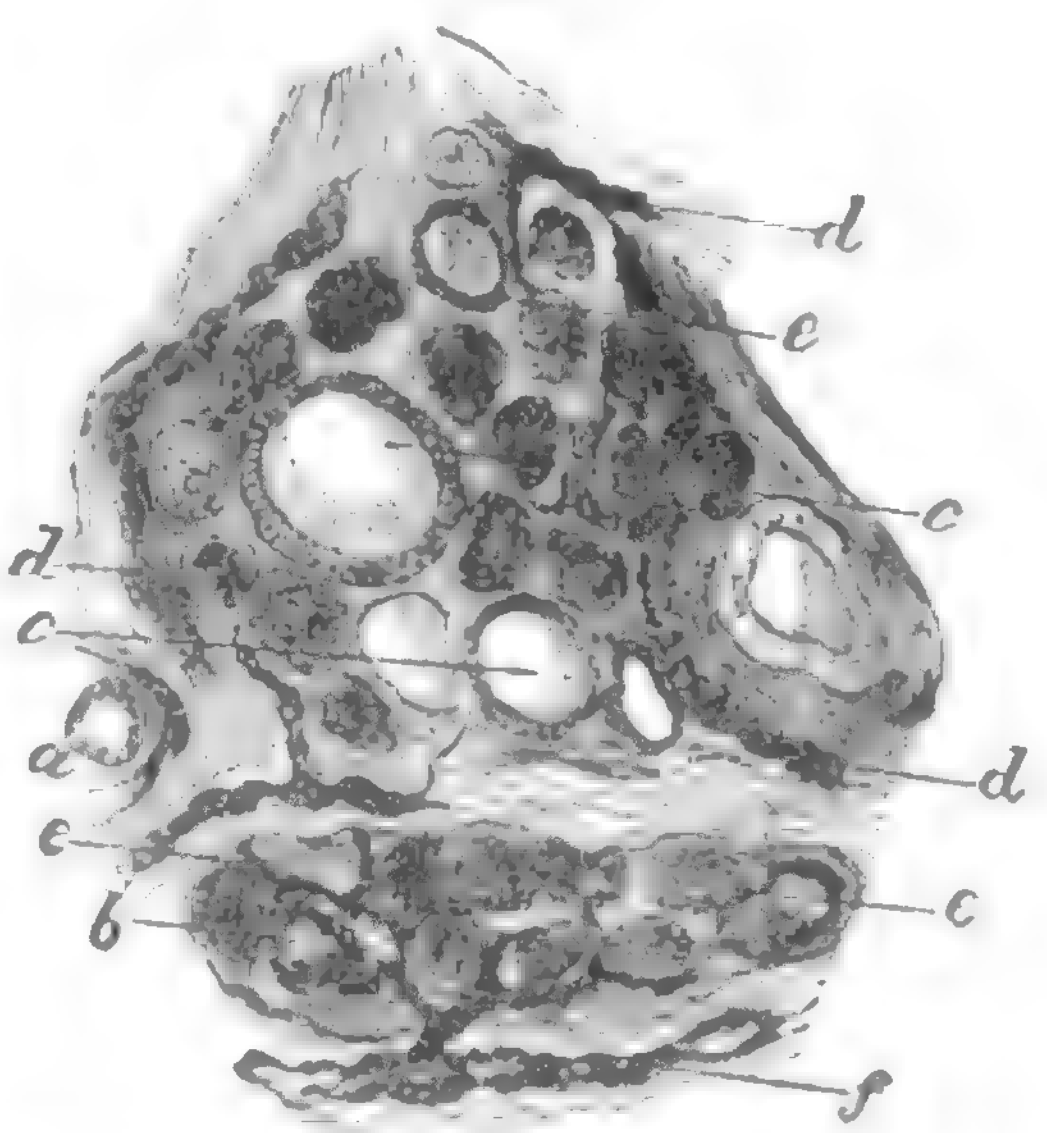

Two Lobules from the Thyroid of an Infant: *a*, small glandular vesicles with their cells; *b*, the same with incipient colloid metamorphosis, more strongly marked at *c*; *d*, coarse lymph-canals; *e*, fine radicles of the same; *f*, an efferent vessel of considerable size.

The thyroid is of a brownish-red color. Its weight varies from one to two ounces. It is larger in females than in males, and becomes slightly increased in size during menstruation [and after maternity]. It occasionally becomes enormously hypertrophied, constituting the disease called bronchocele or goitre. Each lobe is somewhat conical in shape, about two inches in length and three-quarters of an inch to an inch and a quarter in breadth, the right lobe being the larger of the two.

The *isthmus* connects the lower third of the two lateral lobes; it measures about half an inch in breadth and the same in depth, and usually covers the second and third rings of the trachea. Its situation presents, however, many variations, a point of importance in the operation of tracheotomy. Sometimes the isthmus is altogether wanting.

A third lobe, of conical shape, called the *pyramid*, occasionally arises from the upper part of the isthmus or from the adjacent portion of either lobe, but most commonly the left, and ascends as high as the hyoid bone. It is occasionally quite detached or divided into two parts, or altogether wanting.

A few muscular bands are occasionally found attached above to the body of the hyoid bone, and below to the isthmus of the gland or its pyramidal process. These form a muscle which was named by Söemmerring the *Levator glandulæ thyroideæ*.

Structure.—The thyroid body is invested by a thin capsule of connective tissue, which projects into its substance and imperfectly divides it into masses of irregular form and size. When the organ is cut into it is seen to be made up of a number of closed vesicles containing a yellow glairy fluid and separated from each other by intermediate connective tissue.

Fig. 622.

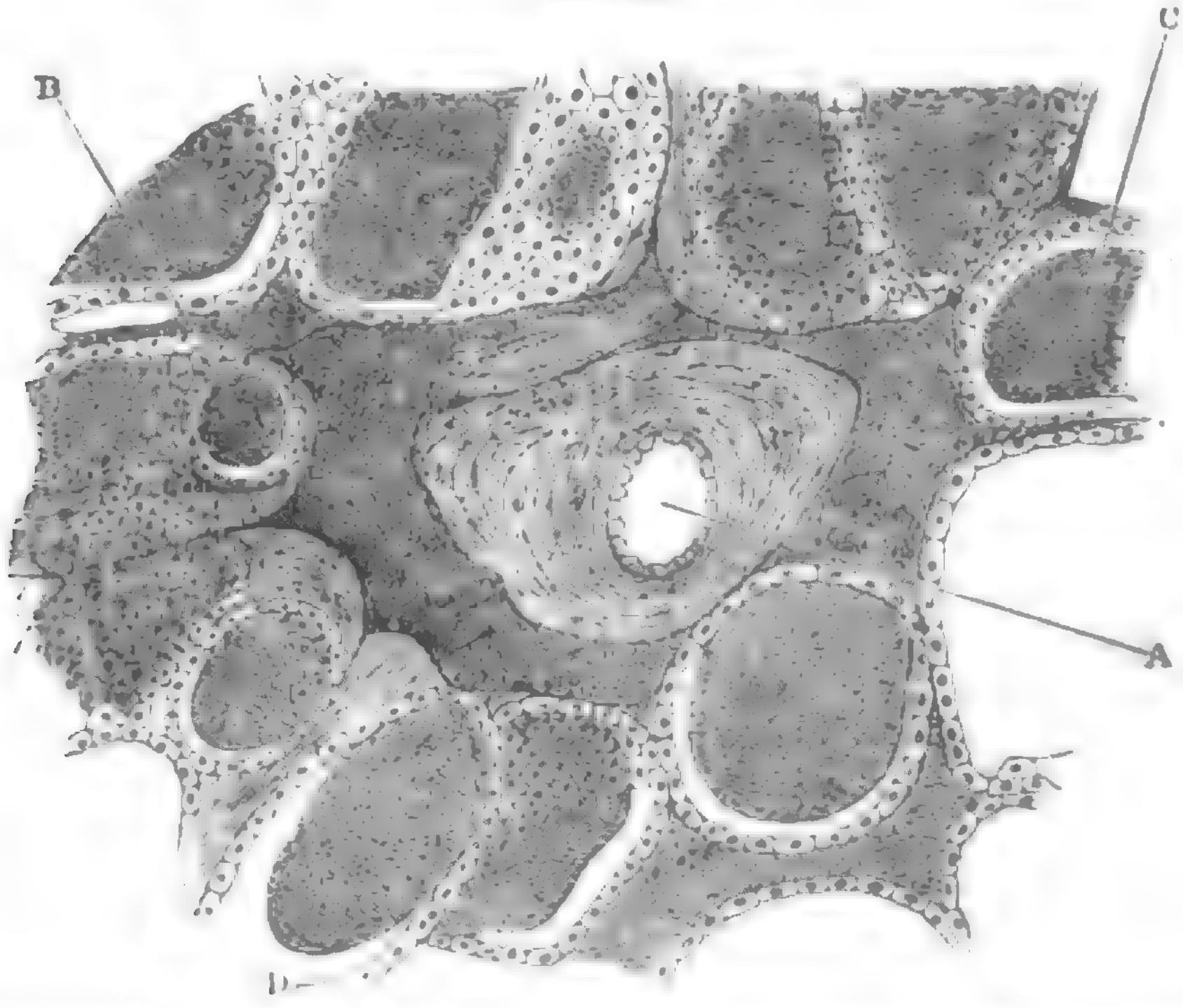

Minute Structure of Thyroid, from a transverse section of the thyroid of a dog, semi-diagrammatic (from Dr. Baber's paper, *Philosophical Transactions of the Royal Society*, vol. clxvi. pt. ii. p. 557): A, lumen of an artery, seen in transverse section; B, cross-section of a large lymphatic vessel that surrounds it, filled with a granular material; C, contents of the vesicles, which present a similar appearance to B; D, walls of gland-vesicles, the epithelial cells of which are flattened by the action of reagents.

According to Dr. Baber, who has recently published some important observations on the minute structure of the thyroid,[1] the vesicles of the thyroid of the adult animal are generally closed cavities; but in some young animals (*e. g.* young dogs) the vesicles are more or less tubular and branched. This appearance he supposes to be due to the mode of growth of the gland, and merely indicating that an increase in the number of vesicles is taking place. Each vesicle is lined by a single layer of epithelium, the cells of which, though differing somewhat in shape in different animals, have always a tendency to assume a columnar form. Between the epithelial cells exists a delicate reticulum. The vesicles are of various sizes and shapes, and contain as a normal product a viscid, homogeneous, semifluid, slightly yellowish material, which frequently contains blood, the red corpuscles of which are found in it in various stages of disintegration and decolorization, the yellow tinge being probably due to the hæmoglobin, which is thus set free from the colored corpuscles. Baber has also described in the thyroid gland of the dog large round cells ("parenchymatous cells"), each provided with a single oval-shaped nucleus, which migrate into the interior of the gland-vesicles.

---

[1] "Researches on the Minute Structure of the Thyroid Gland," *Phil. Trans.*, Part iii., 1881.

The capillary blood-vessels form a dense plexus in the connective tissue around the vesicles, between the epithelium of the vesicles and the endothelium of the lymph-spaces, which latter surround a greater or smaller part of the circumference of the vesicle. These lymph-spaces empty themselves into lymphatic vessels which run in the interlobular connective tissue, not uncommonly surrounding the arteries which they accompany, and communicate with a network in the capsule of the gland. Baber has found in the lymphatics of the thyroid a viscid material which is morphologically identical with the normal constituent of the vesicle.

From this it follows that one of the functions of the thyroid is the destruction of the colored corpuscles in the vesicles, and their removal and final discharge into the general circulation by the lymphatics.

VESSELS AND NERVES.—The *arteries* supplying the thyroid are the superior and inferior thyroid, and sometimes an additional branch (thyroidea media or ima) from the arteria innominata or the arch of the aorta, which ascends upon the front of the trachea. The arteries are remarkable for their large size and frequent anastomoses. The *veins* form a plexus on the surface of the gland and on the front of the trachea, from which arise the superior, middle, and inferior thyroid veins, the two former terminating in the internal jugular, the latter in the vena innominata. The *lymphatics* are numerous, of large size, and terminate in the thoracic and right lymphatic ducts. They are thus described by Frey: "The whole envelope of the organ is covered by knotted trunks, which take their origin from a network of very complicated canals situated in a deeper layer of the former. This latter network is formed around the secondary lobules of the gland by the reticular intercommunications of these canals (Fig. 621, *f*). From the peripheral network formed of canals burrowing through the connective tissue of the capsule lateral ramifications are given off which penetrate into the interior, and gradually enclose the primary lobes in complete rings or more or less perfect arches (*d*, *d*). From these a few fine terminal passages with blind ends (*e*) are seen sinking in between the different vesicles." The *nerves* are derived from the pneumogastric[1] and from the middle and inferior cervical ganglia of the sympathetic.

THYMUS GLAND.

The thymus gland presents much resemblance in structure to other glandular organs, and is another of the organs which used formerly to be denominated *ductless glands*.

The thymus gland is a temporary organ, attaining its full size at the end of the second year, when it ceases to grow, and gradually dwindles until at puberty it has almost disappeared. If examined when its growth is most active it will be found to consist of two lateral lobes placed in close contact along the middle line, situated partly in the superior mediastinum, partly in the neck, and extending from the fourth costal cartilage upward as high as the lower border of the thyroid gland. It is covered by the sternum and by the origins of the Sterno-hyoid and Sterno-thyroid muscles. Below it rests upon the pericardium, being separated from the arch of the aorta and great vessels by the thoracic fascia. In the neck it lies on the front and sides of the trachea, behind the Sterno-hyoid and Sterno-thyroid muscles. The two lobes generally differ in size; they are occasionally united so as to form a single mass, and sometimes separated by an intermediate lobe. The thymus is of a pinkish-gray color, soft, and lobulated on its surfaces. It is about two inches in length, one and a half in breadth below, and about three or four lines in thickness. At birth it weighs about half an ounce.

---

[1] Frey denies that the vagus supplies any of these nerves, deriving them entirely from the sympathetic.

Structure.—Each lateral lobe is composed of numerous lobules held together by delicate areolar tissue, the entire gland being enclosed in an investing capsule of a similar but denser structure. The primary lobules vary in size from a pin's head to a small pea, and are made up of a number of small nodules or follicles which are irregular in shape and are more or less fused together, especially toward the interior of the gland. According to Watney, each follicle consists of a medullary and a cortical portion, which differ in many essential particulars from each other. The *cortical* portion is mainly composed of lymphoid cells supported by a delicate reticulum. In addition to this reticulum, of which traces only are found in the medullary portion, there is also a network of finely branched cells which is continuous with a similar network in the medullary portion. This network forms an adventitia to the blood-vessels. In the *medullary* portion there are but few lymphoid cells, but there are, especially toward the centre, granular cells and concentric corpuscles. The granular cells are rounded or flask-shaped masses attached (often by fibrillated extremities) to blood-vessels and to newly-formed connective tissue. The concentric corpuscles are composed of a central mass consisting of one or more granular cells, and of a capsule which is formed of epithelioid cells which are continuous with the branched cells forming the network mentioned above.

FIG. 623.

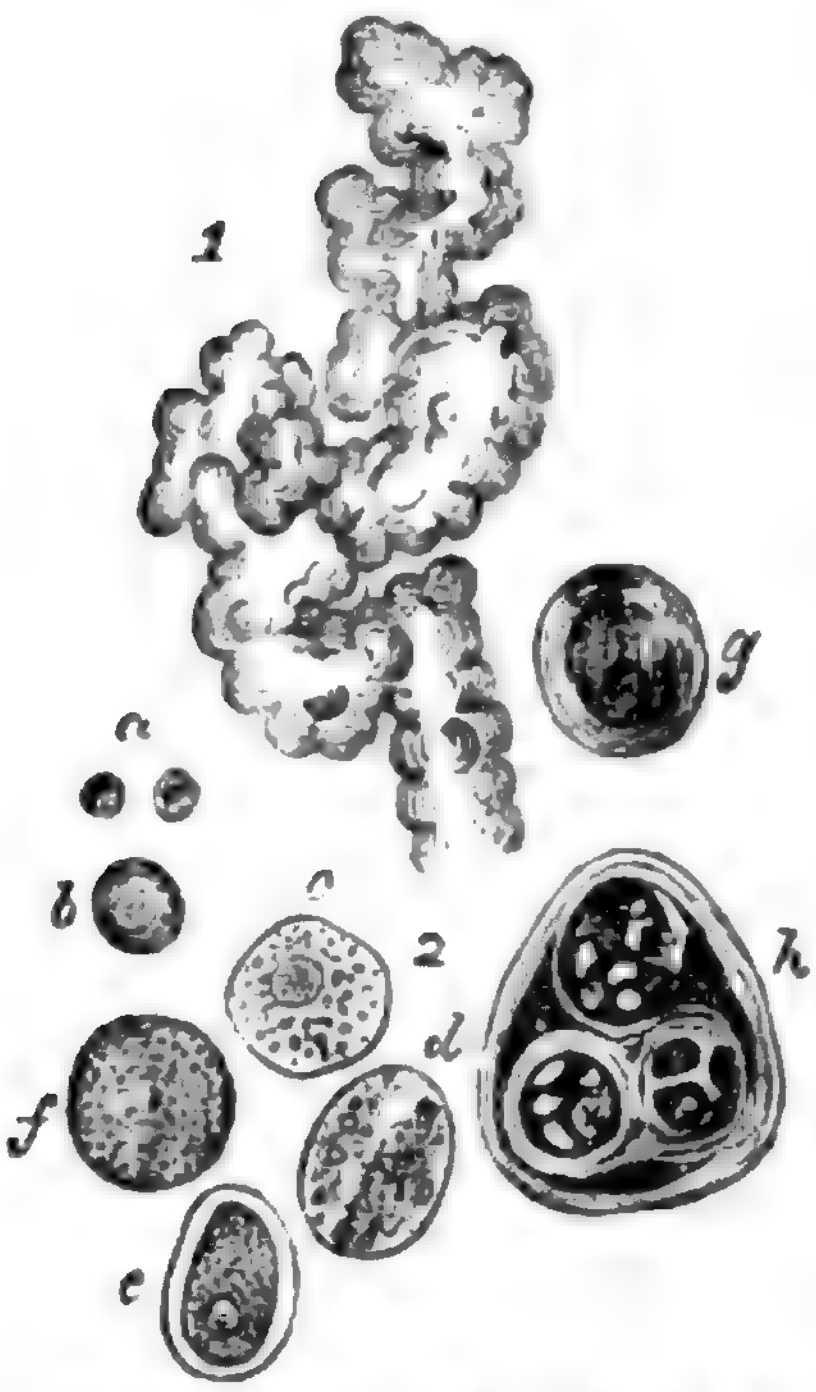

1. Upper portion of the thymus of a fœtal pig of 2′ in in length, showing the bud-like lobuli and glandular elements. 2. Cells of the thymus, mostly from a man: *a*, free nuclei; *b*, small cells; *c*, larger; *d*, larger, with oil-globules, from the ox; *e*, *f*, cells completely filled with fat, at *f*, without a nucleus; *g*, *h*, concentric bodies; *g*, an encapsulated nucleated cell; *h*, a composite structure of a similar nature.

Each follicle is surrounded by a capillary plexus, from which vessels pass into the interior, and radiate from the periphery toward the centre, and form a second zone just within the margin of the medullary portion. In the centre of the medulla there are very few vessels, and they are of minute size.

Dr. Watney has recently made the important observation that hæmoglobin is found in the thymus, either in cysts or in cells situated near to or forming part of the concentric corpuscles. This hæmoglobin varies from granules to masses exactly resembling colored blood-corpuscles, oval in the bird, reptile, and fish; circular in all mammals except in the camel. Dr. Watney has also discovered, in the lymph issuing from the thymus, similar cells to those found in the gland, and, like them, containing hæmoglobin, in the form of either granules or masses. From these facts he arrives at the physiological conclusion that the thymus is one source of the colored blood-corpuscles.

These points are illustrated in the accompanying drawing by Dr. Watney (Fig. 624), for which I have to express my thanks to him.

VESSELS AND NERVES.—The *arteries* supplying the thymus are derived from the internal mammary and from the superior and inferior thyroid. The *veins* terminate in the left vena innominata and in the thyroid veins. The *lymphatics* are of large size, arise in the substance of the gland, and are said to terminate in the internal jugular vein. Sir A. Cooper believed that these vessels carried into the blood the secretion formed in the substance of the thymus. The *nerves* are exceedingly minute; they are derived from the pneumogastric and sympathetic. Branches

Fig. 624.

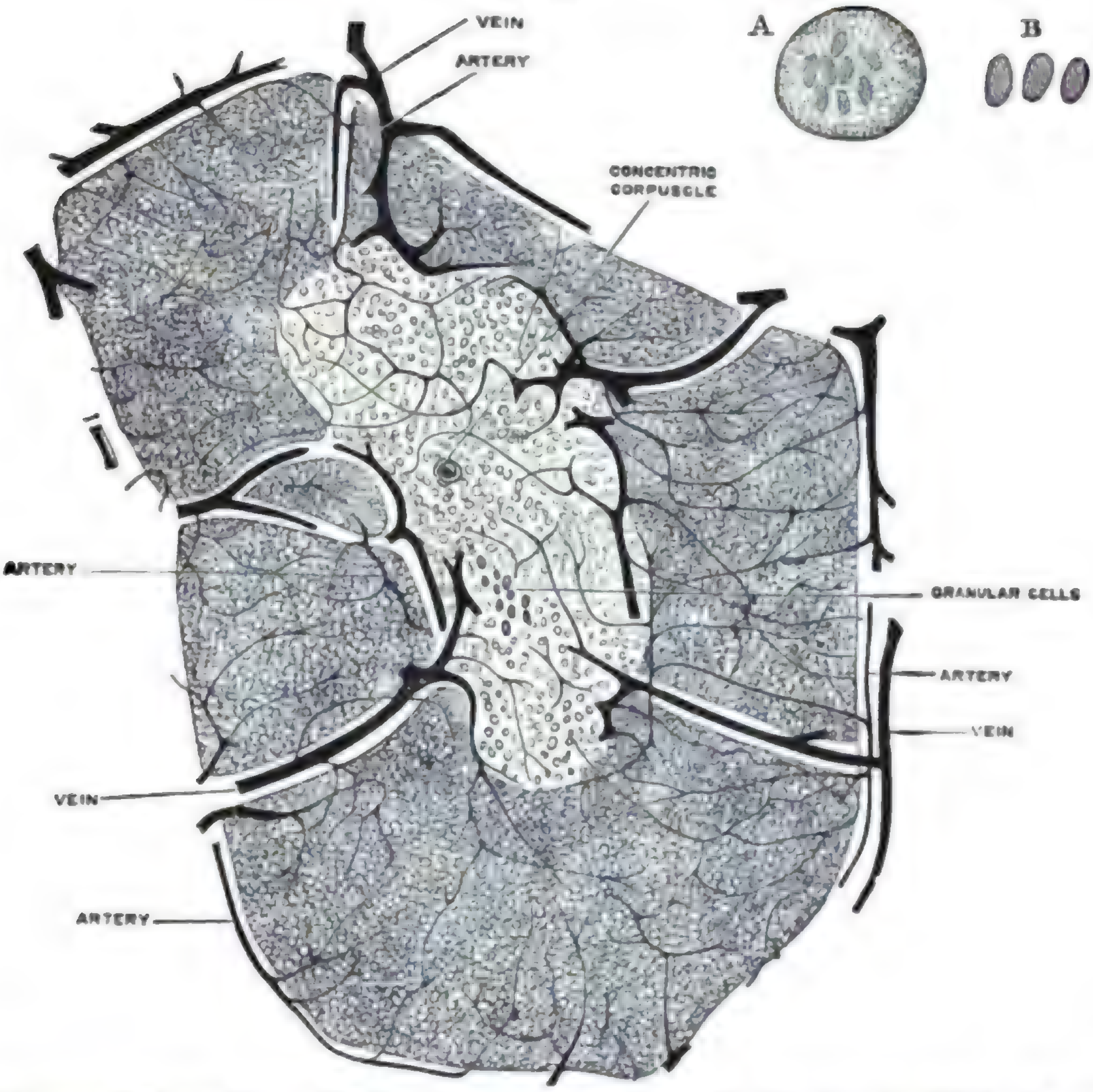
VEIN
ARTERY
A
B
CONCENTRIC CORPUSCLE
ARTERY
GRANULAR CELLS
ARTERY
VEIN
VEIN
ARTERY

Minute Structure of Thymus Gland; follicle of injected thymus from calf four days old, slightly diagrammatic (magnified about 50 diameters). The large vessels are disposed in two rings, one of which surrounds the follicle, the other lies just within the margin of the medulla: A and B, from thymus of camel, examined without addition of any reagent (magnified about 400 diameters). A, large colorless cell containing small oval masses of hæmoglobin: similar cells are found in the lymph-glands, spleen, and medulla of bone; B, colored blood-corpuscle.

from the descendens noni and phrenic reach the investing capsule, but do not penetrate into the substance of the gland.

The Urinary Organs.

THE KIDNEYS.

THE **Kidneys,** two in number, are situated in the back part of the abdomen, and are for the purpose of separating from the blood certain materials which, when dissolved in a quantity of water, also separated from the blood by the kidneys, constitute the urine. [Occasionally, there is but a single kidney.]

They are placed in the loins, one on each side of the vertebral column, behind the peritoneum, and surrounded by a mass of fat and loose areolar tissue. [Sometimes, instead of being fixed in place by this tissue, the kidney is loose, and only held by the ureter and the blood-vessels. It is then called a "floating" kidney.] Their upper extremity is on a level with the upper border of the twelfth dorsal vertebra, their lower extremity on a level with the third lumbar. The right kidney is usually on a slightly lower level than the left, probably on account of the vicinity of the liver.

The kidneys rest on the lower part of the Diaphragm and the fascia covering the Quadratus lumborum and the Psoas magnus muscles. The right one is covered in front by the right lobe of the liver, the descending portion of the duodenum, and the ascending colon; the left one has in front the fundus of the stomach, the tail of the pancreas, and the descending colon.

The kidney has a characteristic form. It is flattened on its sides, and presents at one part of its circumference a hollow. It is larger at its upper than its lower extremity. It presents for examination two surfaces, two borders, and an upper and lower extremity. Its *anterior* surface is convex, looks forward and outward, and is partially covered by peritoneum. The upper part of this surface on the right side is in contact with the under surface of the right lobe of the liver, on which it produces a slight concave impression, the *impressio renalis* (p. 892); below this the descending portion of the duodenum and the upper part of the ascending colon are connected to this surface by a quantity of loose areolar tissue. On the left side the upper part of the anterior surface of the kidney is in contact with the under surface of the stomach, and below this with the left extremity of the pancreas, whilst the lower part is connected to the descending colon by loose areolar tissue.

The *posterior surface* is flatter than the anterior, and is imbedded in areolar tissue, which separates the upper part from the Diaphragm covering the eleventh and twelfth ribs, and the lower part from the anterior lamellæ of the lumbar fascia covering the Quadratus lumborum muscle, and internally from the fascia covering the Psoas magnus muscle.

The *external* border is convex, and is directed outward and backward toward the postero-lateral wall of the abdomen. On the left side it is in contact at its upper part with the spleen.

The *internal* border is concave, and is directed forward and a little downward. It presents a deep longitudinal fissure bounded by a prominent overhanging anterior and posterior lip. This fissure is named the *hilum*, and allows of the passage of the vessels, nerves, and ureter into and out of the kidney.

The *superior extremity*, directed slightly inward as well as upward, is thick and rounded and is surmounted by the suprarenal capsule, which covers also a small portion of the anterior surface.

The *inferior extremity*, directed a little outward as well as downward, is smaller and thinner than the superior. It extends to within one or two inches of the crest of the ilium.

At the hilum of the kidney the relative position of the main structures passing into and out of the kidney is as follows: The vein is in front, the artery in the middle, and the duct or ureter behind and toward the lower part. By a knowledge of these relations the student may distinguish between the right and the left kidney. The kidney is to be laid on the table before the student on its posterior surface, with its lower extremity toward the observer; that is to say, with the ureter *behind* and *below* the other vessels; the hilum will then be directed to the side to which the kidney belongs.

Each kidney is about four inches in length, two to two and a half in breadth, and rather more than one inch in thickness. The left is somewhat longer, though narrower, than the right. The weight of the kidney in the adult male varies from 4½ oz. to 6 oz.; in the adult female, from 4 oz. to 5½ oz. The combined weight of the two kidneys in proportion to the body is about 1 in 240.

[The operations of nephrotomy (incision of the kidney) and nephrectomy (removal of the kidney) and nephro-lithotomy (removal of stone from the kidney) have recently obtained a well-recognized and very successful place in surgery. They may all be done by the lumbar incision, without involving the peritoneum, and the relation of the kidney should be observed with a view to these operations (Figs. 586 and 587, pp. 884, 885). Removal of the kidney is also done by abdominal section.]

General Structure of the Kidney.—The kidney is surrounded by a distinct investment of fibrous tissue which forms a firm, smooth covering to the organ. It closely invests it, but can be easily stripped off; in doing which, however, numerous fine processes of connective tissue and small blood-vessels are torn through. Beneath this coat a thin, wide-meshed network of unstriped muscular fibre forms an incomplete covering to the organ. When the fibrous coat is stripped off, the surface of the kidney is found to be smooth and even and of a deep-red color.

FIG. 625.

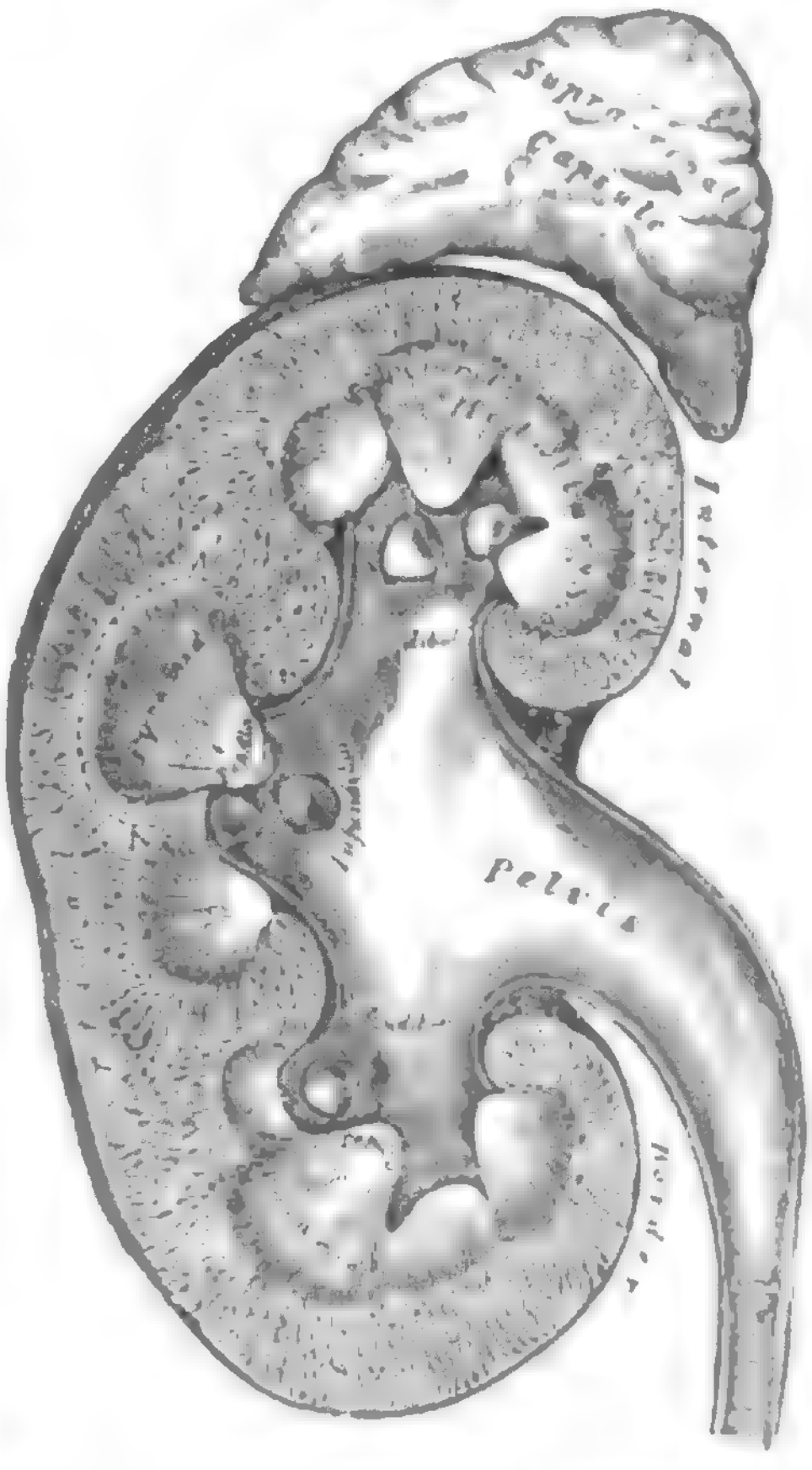

Vertical Section of Kidney.

In infants fissures extending for some depth may be seen on the surface of the organ—a remnant of the lobular construction of the gland. The kidney is dense in texture, but is easily lacerable by mechanical force. In order to obtain a knowledge of the structure of the gland a vertical section must be made from its convex to its concave border, and the loose tissue and fat removed from around the vessels and the excretory duct (Fig. 625). It will be then seen that the kidney consists of a central cavity surrounded at all parts but one by the proper kidney-substance. This central cavity is called the *sinus*, and is lined by a prolongation of the fibrous coat of the kidney, which enters through a longitudinal fissure, the *hilum* (before mentioned), which is situated at that part of the cavity which is not surrounded by kidney-structure. Through this fissure the blood-vessels of the kidney and its excretory duct pass, and therefore these structures upon entering the kidney are contained within the sinus. The excretory duct or *ureter* after entering dilates into a wide, funnel-shaped sac named the *pelvis*. This divides into two or three tubular divisions, which again divide into several short, truncated branches named *calices* or *infundibula*, all of which are contained in the central cavity of the kidney. The blood-vessels of the kidney after passing through the hilum are contained in the sinus or central cavity, lying between its lining membrane and the excretory apparatus, before entering the kidney-substance.

This central cavity, as before mentioned, is surrounded on all sides, except at the hilum, by the substance of the kidney, which is at once seen to consist of two parts—viz. of an external, granular, investing part, which is called the *cortical portion;* and of an internal part, the *medullary portion*, made up of a number of dark-colored pyramidal masses, with their bases resting on the cortical part and their apices converging toward the centre, where they form prominent papillæ which project into the interior of the calices.

The cortical substance is of a bright reddish-brown color, soft, granular, and easily lacerable. It is found everywhere immediately beneath the capsule, and is seen to extend itself in an arched form over the base of each medullary pyramid. The part separating the sides of any two pyramids through which the arteries and nerves enter and the veins and lymphatics emerge from the kidney is called a *cortical column* or *column of Bertini* (A, A′, Fig. 625), whilst that portion which stretches from one cortical column to the next, and intervenes between the base of the pyramid and the capsule (which is marked by the dotted line extending from A to A′ in Fig. 625), is called a *cortical arch*, the depth of which varies from a third to half an inch.

The *medullary substance*, as before said, is seen to consist of palish red-colored striated conical masses, the *pyramids* of Malpighi, the number of which, varying from eight to eighteen, correspond to the number of lobes of which the organ in the fœtal state is composed. The base of each pyramid is surrounded by a cortical arch and directed toward the circumference of the kidney; the sides are contiguous with the cortical columns; whilst the apex, known as the *papilla* or *mammilla* of the kidney, projects into one of the calices of the ureter.

FIG. 626.

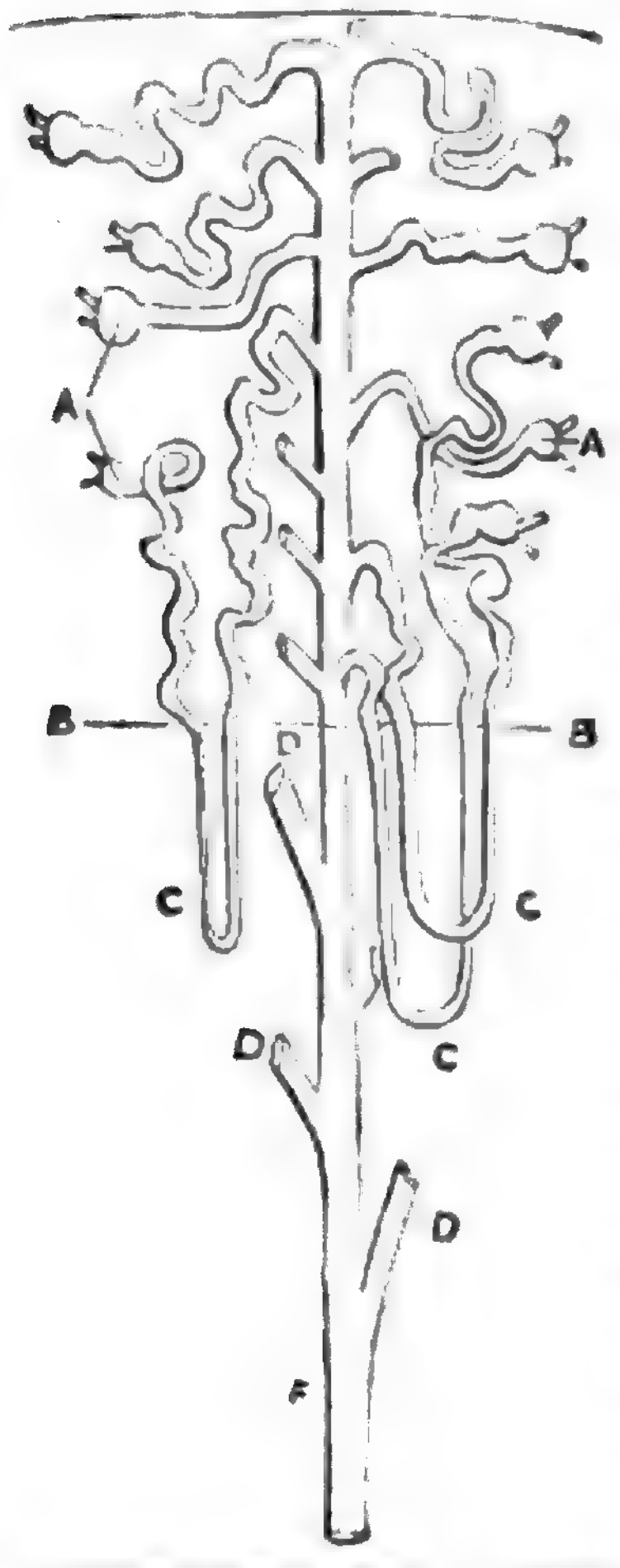

A, A, Malpighian bodies; B, B, margin of medullary structure; C, C, C, loops of Henle; D, D, D, straight tubes cut off; E, commencing straight tubes; F, termination of straight tube.

These two parts, *cortical* and *medullary*, so dissimilar in appearance, are very similar in structure, being made up of urinary tubes and blood-vessels united and bound together by a connecting matrix or stroma.

The *tubuli uriniferi*, of which the kidney is for the most part made up, commence in the cortical portion of the kidney by spherical closed sacs, called *Malpighian capsules*, and after pursuing a very circuitous course through the cortical and medullary parts of the kidney, finally terminate at the apices of the Malpighian pyramids by open mouths (Fig. 626), so that the fluid which they contain is emptied into the dilated extremity of the ureter contained in the sinus of the kidney. If the surface of one of the papillæ be examined with a lens, it will be seen to be studded over with a number of small depressions, from sixteen to twenty in number, and in a fresh kidney, upon pressure being made, fluid will be seen to exude from these depressions. They are the orifices of the tubuli uriniferi, which terminate in this situation. They commence in the cortical portion of the kidney as the *Malpighian bodies*, which are small rounded masses, varying in size, but of an average of about $\frac{1}{120}$ of an inch in diameter. They are of a deep-red color, and are found only in the cortical portion of the kidney. Each of these little bodies is composed of two parts—a central glomerulus of vessels called a *Malpighian tuft*, and a membranous envelope, the *Malpighian capsule* or *capsule of Bowman*, which latter is a small pouch-like commencement of a uriniferous tubule.

The *Malpighian tuft*, or vascular glomerulus, is a network of convoluted capillary blood-vessels held together by scanty connective tissue and grouped into from two to five lobules. This capillary network is derived from a small arterial twig, the *afferent vessel*, which pierces the wall of the capsule, generally at a point opposite that at which it is connected with the tube; and the resulting vein, the *efferent vessel*, emerges from the capsule at the same point. The afferent vessel is usually the larger of the two (Fig. 627). The *Malpighian* or *Bowman's capsule*, which surrounds the glomerulus, is formed of a hyaline membrane, supported by a small amount of connective tissue, which is continuous with the connective tissue of the tube. It is lined on its inner surface by a layer of squamous epithelial cells, which are reflected from the lining membrane on to the glomerulus at the point of entrance or exit of the afferent and efferent vessels. The whole surface of the glomerulus is covered with a continuous layer of the same cells on a delicate supporting membrane, which with the cells dip in between the lobules of the glomerulus, closely surrounding them (Fig. 628). Thus between the glomerulus and the capsule a space is left, forming a cavity lined by a continuous layer of cells which varies in size according to the state of secretion and the amount of fluid present in it. The cells, as above stated, are squamous in the adult, but in the fœtus and young subject are polyhedral or even columnar.

FIG. 627.

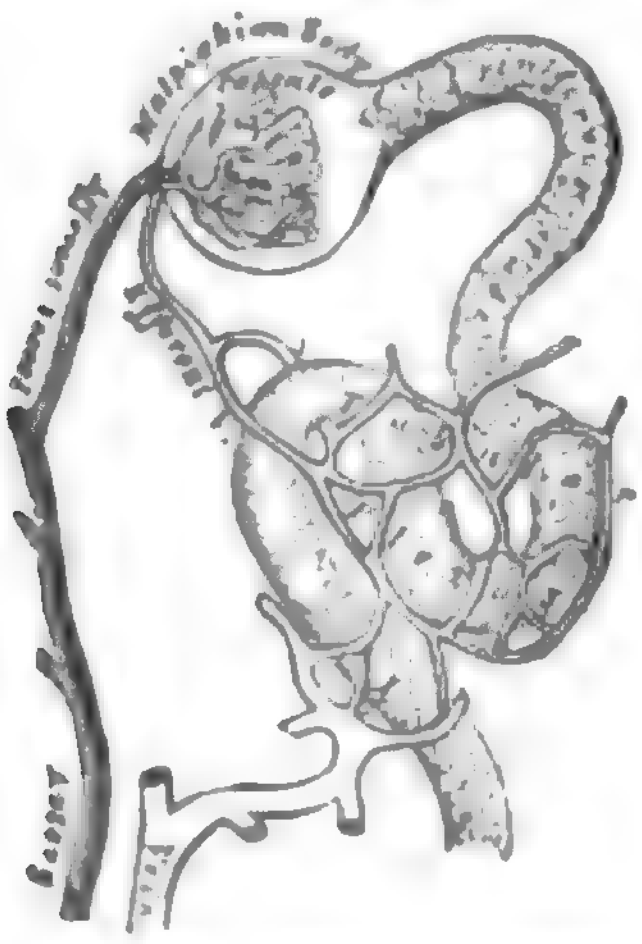

Minute Structure of Kidney.

FIG. 628.

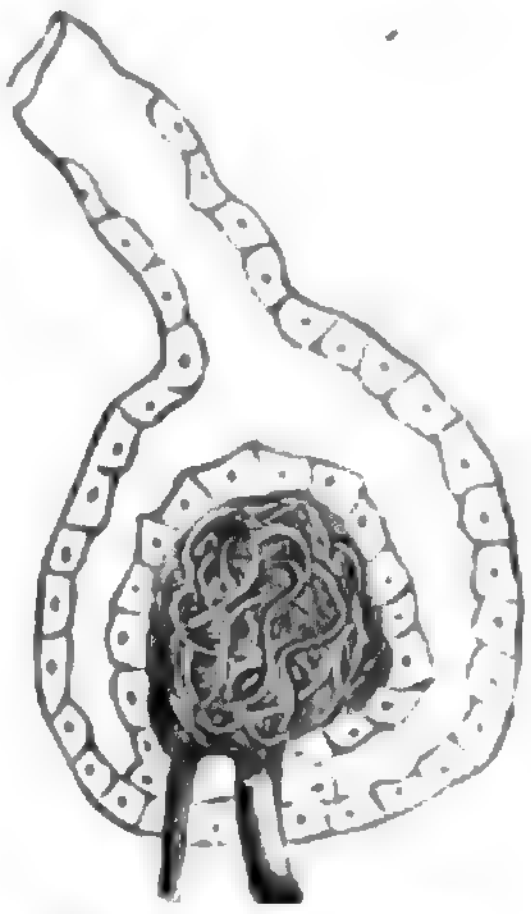

Malpighian Body.

The *tubuli uriniferi*, commencing in the Malpighian bodies, in their course present many changes in shape and direction, and are contained partly in the medullary and partly in the cortical portions of the organ. At their junction with the Malpighian capsule they present a somewhat constricted portion, which is termed the *neck*. Beyond this the tube becomes convoluted, and pursues a considerable course in the cortical structure, constituting the *proximal convoluted tube*. After a time the convolutions disappear, and the tube approaches the medullary portion of the kidney in a more or less spiral manner. This section of the tube has been called the *spiral tubule of Schachowa*. Throughout this portion of their course the tubuli uriniferi have been contained entirely in the cortical structure, and have presented a pretty uniform calibre. They now enter the medullary portion, suddenly become much smaller, quite straight in direction, and dip down for a variable depth into the pyramids, constituting the *descending limb of Henle's loop*. Bending on themselves, they form a kind of loop, *the loop of Henle*, and, reascending, they become suddenly enlarged and again spiral in direction, forming the *ascending limb of Henle's loop*, and re-enter the cortical structure. This portion of the tube does not present a uniform calibre, but becomes narrower as it ascends, and irregular in outline. As a narrow tube it enters the cortex and ascends for a short distance, when it again becomes dilated, irregular, and angular. This section is termed the *irregular tubule*; it terminates in a convoluted tube which exactly resembles the proximal convoluted tubule, and is called the *distal convoluted tubule*. This again terminates in a narrow *curved tube*, which enters the straight or collecting tube.

Each *straight* (otherwise called a *collecting* or *receiving*) *tube* commences by a small orifice on the summit of one of the papillæ, thus opening and discharging its contents into the interior of one of the calices. Traced into the substance of the pyramid, these tubes are found to run from apex to base, dividing dichotomously in their course and slightly diverging from each other. Thus dividing and subdividing, they reach the base of the pyramid, and enter the cortical structure greatly increased in number. Upon entering the cortical portion they continue a straight course for a variable distance, and are arranged in groups called *medullary rays*, several of these groups corresponding to a single pyramid. The tubes in the centre of the group are the longest, and reach almost to the surface of the kidney, while the external ones are shorter, and advance only a short distance into the cortex. In consequence of this arrangement the cortical portion presents a number of conical masses, the apices of which reach the periphery of the organ, and the bases are applied to the medullary portion. These are termed the *pyramids of Ferrein*. As they run through the cortical portion the straight tubes receive on either side the curved extremity of the convoluted tubes, which, as stated above, commence at the Malpighian capsules.

It will be seen from the above description that there is a continuous series of tubes from their commencement in the Malpighian capsules to their termination at the orifices on the apices of the pyramids of Malpighi, and that the urine, the secretion of which commences in the capsule, finds its way through these tubes into the calices of the kidney, and so into the ureter. Commencing at the capsule, the tube first presents a narrow constricted portion, the *neck*. 2. It forms a wide convoluted tube, the *proximal convoluted tube*. 3. It becomes spiral, the *spiral tubule of Schachowa*. 4. It enters the medullary structure as a narrow, straight tube, the *descending limb of Henle's loop*. 5. Forming a loop and becaming dilated, it ascends, somewhat spirally and gradually diminishing in calibre, and again enters the cortical structure, the *ascending limb of Henle's loop*. 6. It now becomes irregular and angular in outline, the *irregular tubule*. 7. It then becomes convoluted, the *distal convoluted tubule*. 8. Diminishing in size, it forms a curve, the *curved tubule*. 9. Finally, it joins a straight tube, the *straight collecting tube*, which is continued downward through the medullary substance to open at the apex of a pyramid.

Fig. 629.

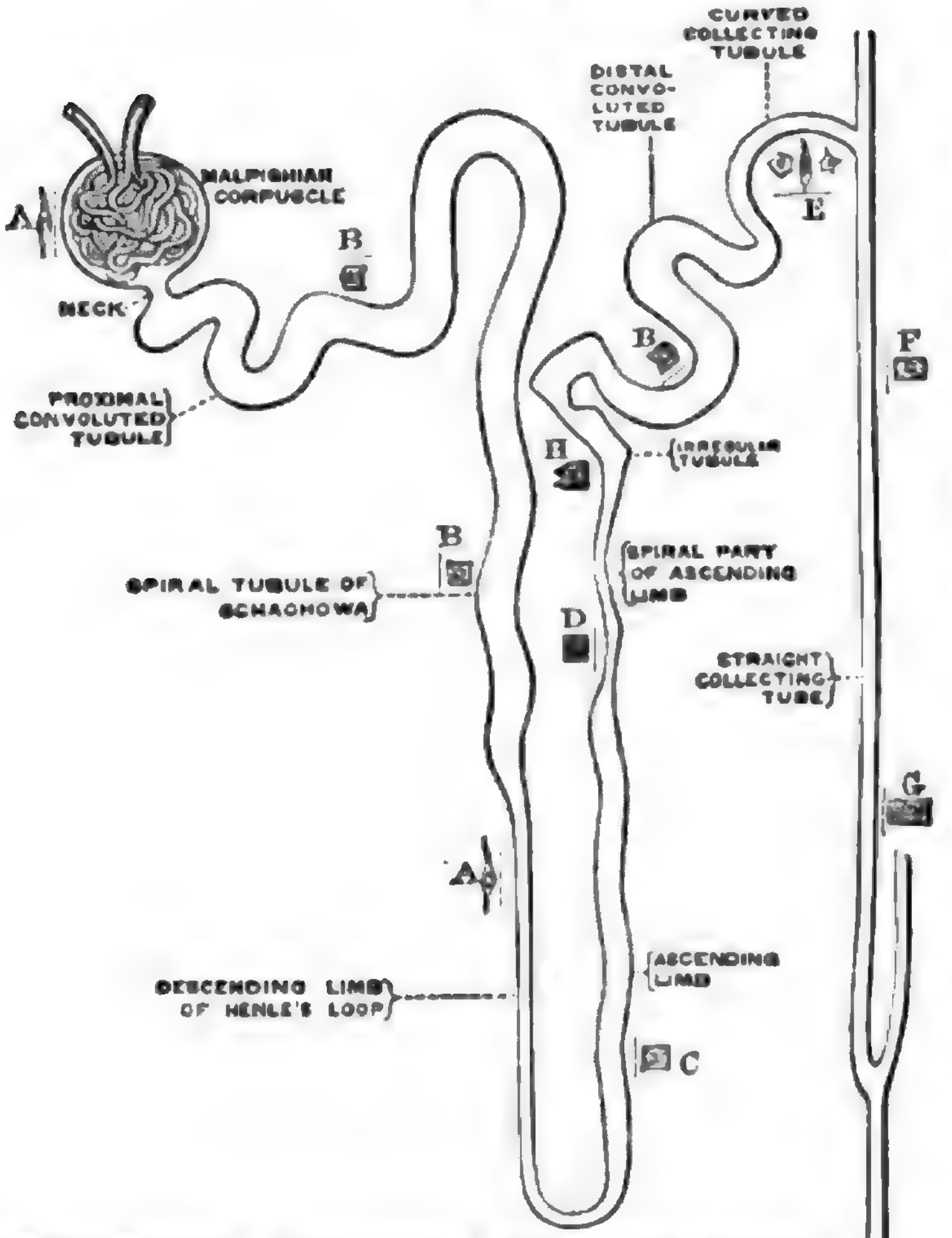

Uriniferous Tube. For the sake of clearness the epithelial cells have been represented more highly magnified than the tubes in which they are contained.

The Tubuli Uriniferi: their Structure.—The tubuli uriniferi consist of basement-membrane lined with epithelium. The epithelium varies considerably in different sections of the uriniferous tubes. In the *neck* the epithelium is continuous with that lining the Malpighian capsule, and like it consists of flattened cells with an oval nucleus (Fig. 629, A). The cells are, however, very indistinct and difficult to follow, and the tube has here the appearance of a simple basement-membrane unlined by epithelium. In the proximal convoluted tubule and the spiral tubule of Schachowa the epithelium is polyhedral in shape, the sides of the cells not being straight, but fitting into each other, and in some animals so fused together that it is impossible to make out the lines of junction. In the human kidney the cells often present an angular projection of the surface next the basement-membrane. These cells are made up of more or less rod-like fibres, which rest by one extremity on the basement-membrane, whilst the other projects toward the lumen of the tube. This gives to the cells the appearance of distinct striation (Heidenhain) (Fig. 629, B). In the descending limb of Henle's loop the epithelium resembles that found in the Malpighian capsule and the commencement of the tube, consisting of flat transparent epithelial plates with an oval nucleus (Fig. 629, A; Fig. 630). In the ascending limb, on the other hand, the cells partake more of the character of those described as existing in the proximal convoluted tubule, being polyhedral in shape and presenting the same appearance of striation. The nucleus, however, is not situated in the centre of the cell, but near the lumen (Fig. 629, C). After the ascending limb of Henle's loop becomes narrower upon entering the cortical structure, the striation appears to be confined to the outer part of the cell; at all events, it is much more distinct in this situation, the nucleus, which appears flattened and angular, being still situated near the lumen (Fig. 629, D). In the irregular tubule the cells undergo a still further change, becoming very angular and presenting thick bright rods or markings, which render the striation much more distinct than in any other section of the urinary tubules (Fig. 629, H). In the distal convoluted tubule the epithelium appears to be identical with that which has been described as existing in the proximal convoluted tubule (Fig. 629, B). In the curved tubule, just before its entrance into the straight collecting tube, the epithelium varies greatly as regards the shape of the cells, some being angular with short processes, others spindle-shaped, others polyhedral (Fig. 629, E).

FIG. 630.[1]



Longitudinal Section of Henle's Descending Limb: *a*, membrana propria; *b*, epithelium.

FIG. 631.

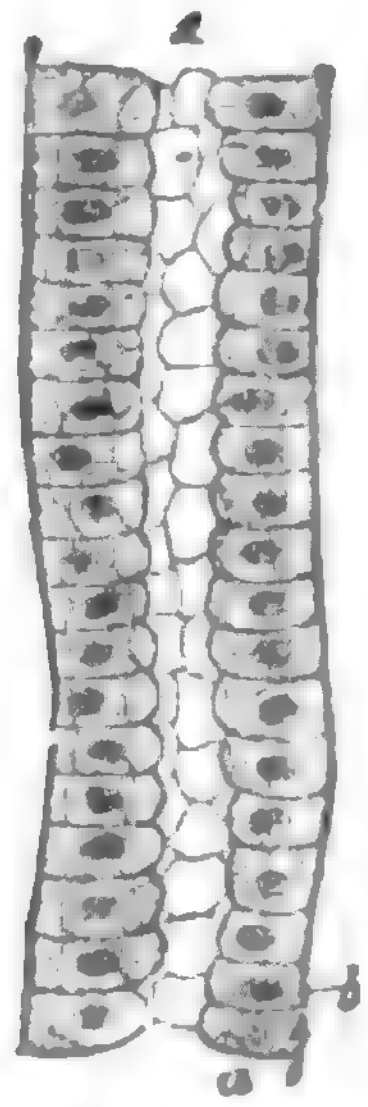

Longitudinal Section of Straight Tube: *a*, cylindrical or cubical epithelium; *b*, membrana propria.

In the straight tubes the epithelium is more or less columnar; in its papillary portion the cells are distinctly columnar and transparent (Figs. 631, 632); but as the tube approaches the cortex the cells are less uniform in shape; some are polyhedral, and others angular with short processes (Fig. 629, F and G).

The Renal Blood-vessels: their Origin, Course, and Distribution.—The kidney is plentifully supplied with blood by the renal artery, a large offset of the abdominal aorta, which enters the sinus through the hilum, dividing in its passage through the latter into four or five branches. [Quite frequently the kidney has two renal arteries, and occasionally more.] These whilst in the sinus give off a few twigs for the nutrition of the surrounding tissues, and terminate in the *arteriæ propriæ*

---

[1] From the *Handbook for the Physiological Laboratory.*

renales, which enter the kidney proper in the columns of Bertini. Two of these pass to each pyramid of Malpighi, and run along its sides for its entire length, giving off as they advance the afferent vessels of the Malpighian bodies in the columns. Having arrived at the bases of the pyramids, they make a bend in their course, so as to lie between the bases of the pyramids and the cortical arches, where they break up into two distinct sets of branches devoted to the supply of the remaining portions of the kidney.

FIG. 632.

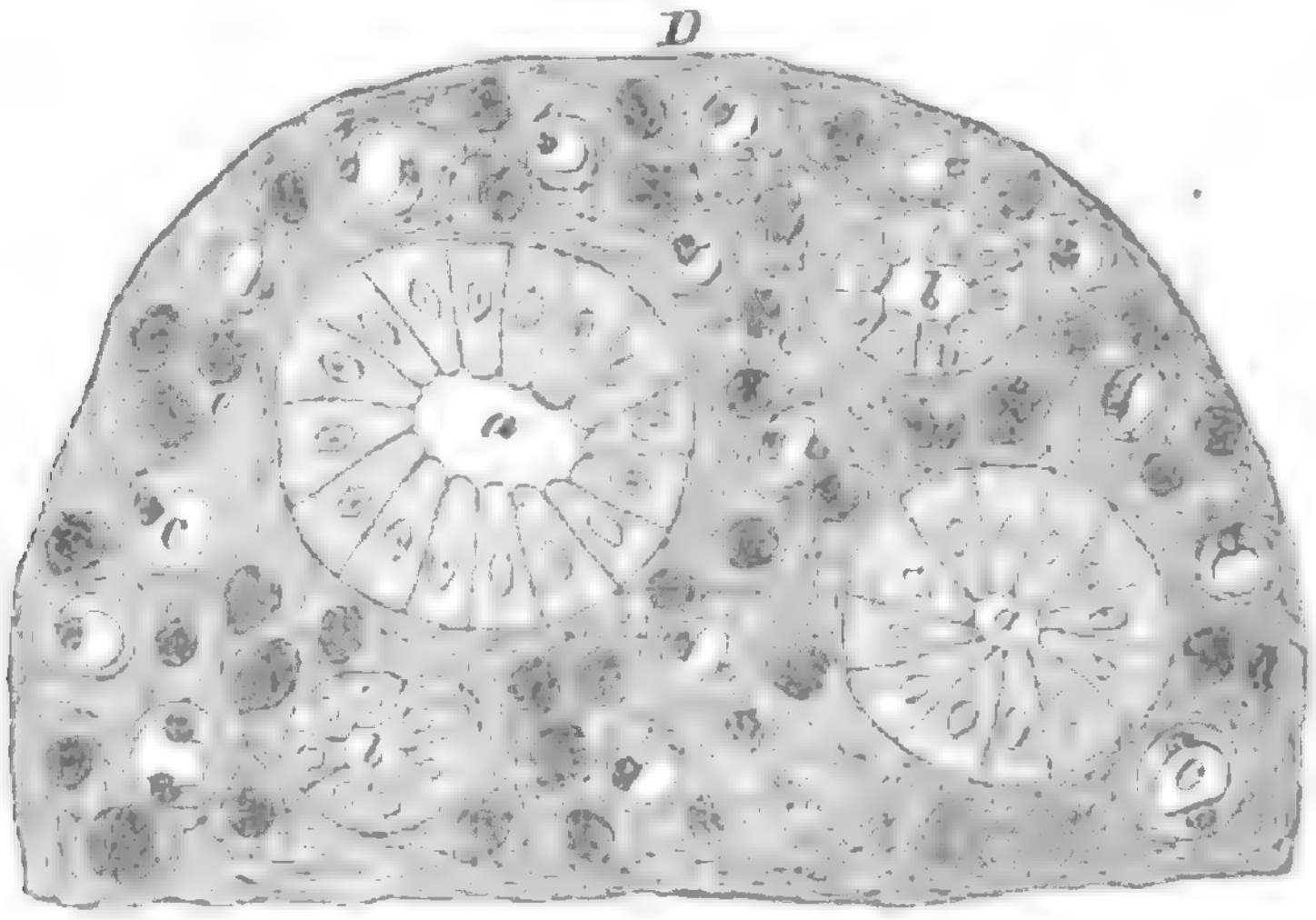

Transverse Section of Pyramidal Substance of Kidney of Pig, the blood-vessels of which are injected: *a*, large collecting tube, cut across, lined with cylindrical epithelium; *b*, branch of collecting tube, cut across, lined with epithelium with shorter cylinders; *c* and *d*, Henle's loops, cut across; *e*, blood-vessels, cut across; D, connective-tissue ground-substance.

FIG. 633.

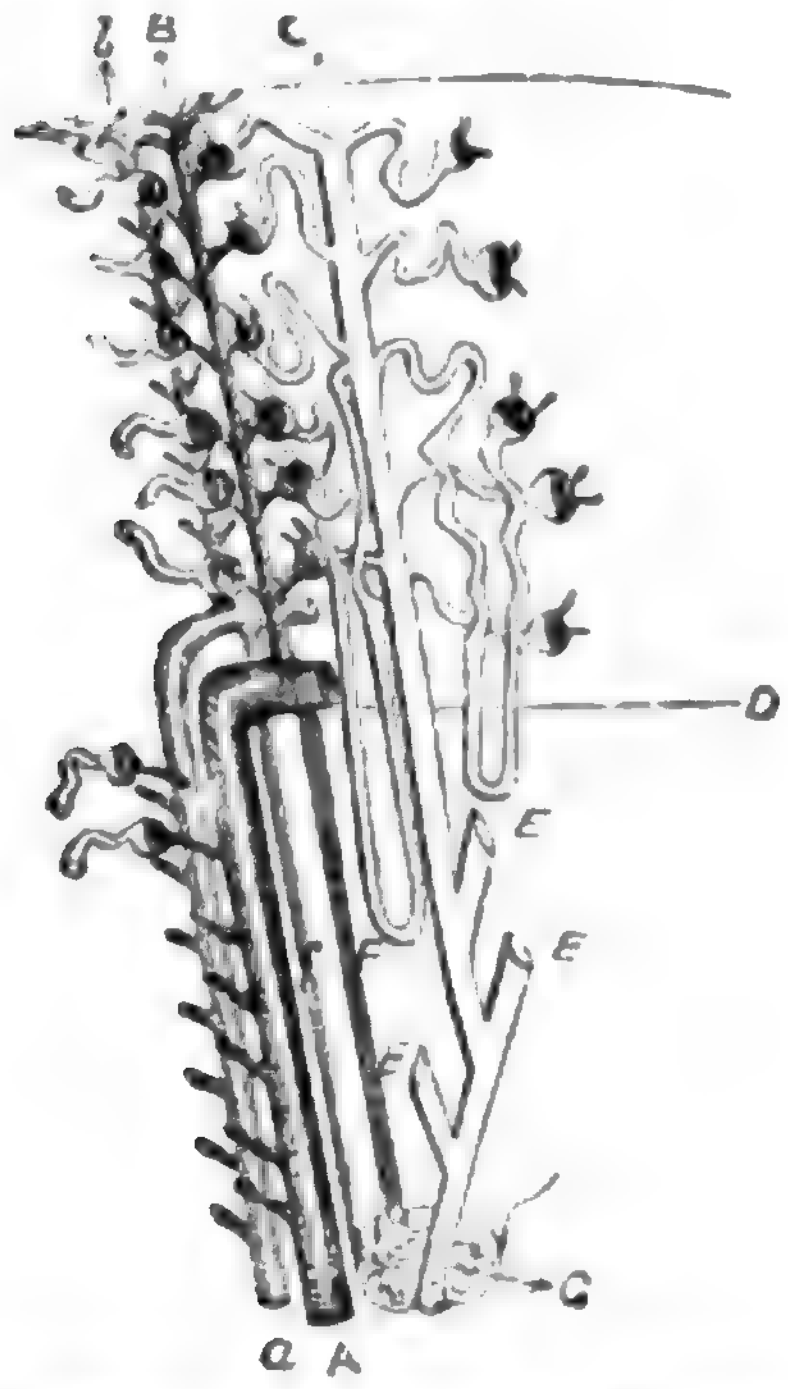

Diagrammatical Sketch of Kidney.

FIG. 634.

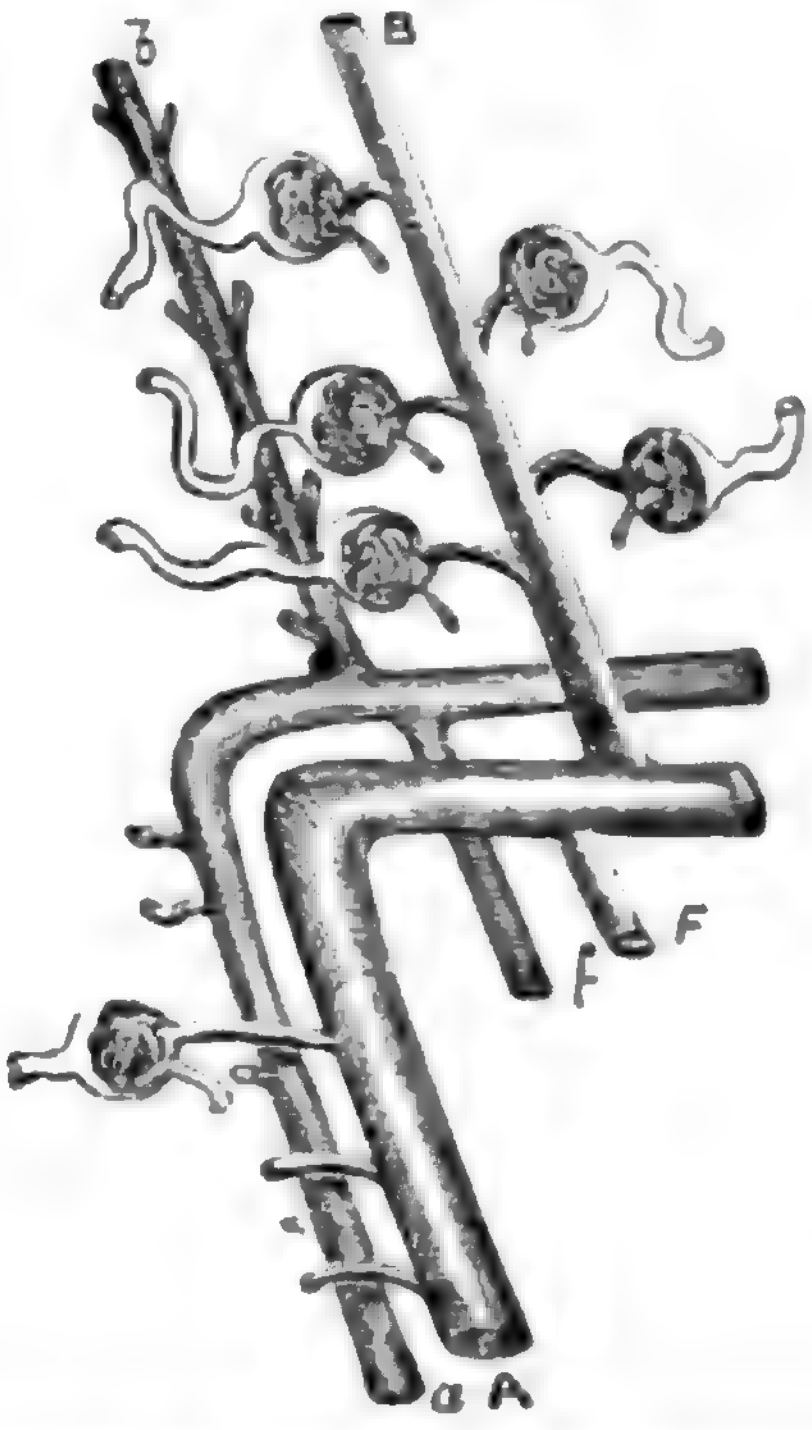

A Portion of Fig. 633, enlarged (the references are the same).

a, A, proper renal artery and vein, the former giving off the renal afferents, the latter receiving the renal efferents; *b*, B, interlobular artery and vein, the latter commencing from the stellate veins, and receiving branches from the plexus around the tubuli contorti, the former giving off renal afferents; C, straight tube, surrounded by tubuli contorti, with which it communicates, forming a pyramid of Ferrein, as more fully shown in Fig. 626; D, margin of medullary substance; E, E, E, receiving tubes, cut off; F, arteriolæ et venæ rectæ, the latter arising from (G) the plexus at the medullary apex.

The *first set, the interlobular arteries* (Figs. 633, 634, B), are given off at right angles from the side of the arteriæ propriæ renales looking toward the cortical substance, and, passing directly outward between the pyramids of Ferrein, they reach the capsule, where they terminate in the capillary network of this part. In their outward course they give off lateral branches; these are the *afferent* vessels for the Malpighian bodies (see p. 947), and, having pierced the capsule, end in the Malpighian tufts. From each tuft the corresponding renal efferent arises, which, having made its egress from the capsule near to the point where the afferent entered, anastomoses with other efferents from other tufts, and contributes to form a dense *venous plexus* around the adjacent urinary tubes (Fig. 635).

The *second set* from the arteriæ propriæ renales are for the supply of the medullary pyramids, which they enter at their bases, and, passing straight through their substance to their apices, terminate in the venous plexuses found in that situation. They are called the *arteriolæ rectæ* (Figs. 633, 634, F).

FIG. 635.

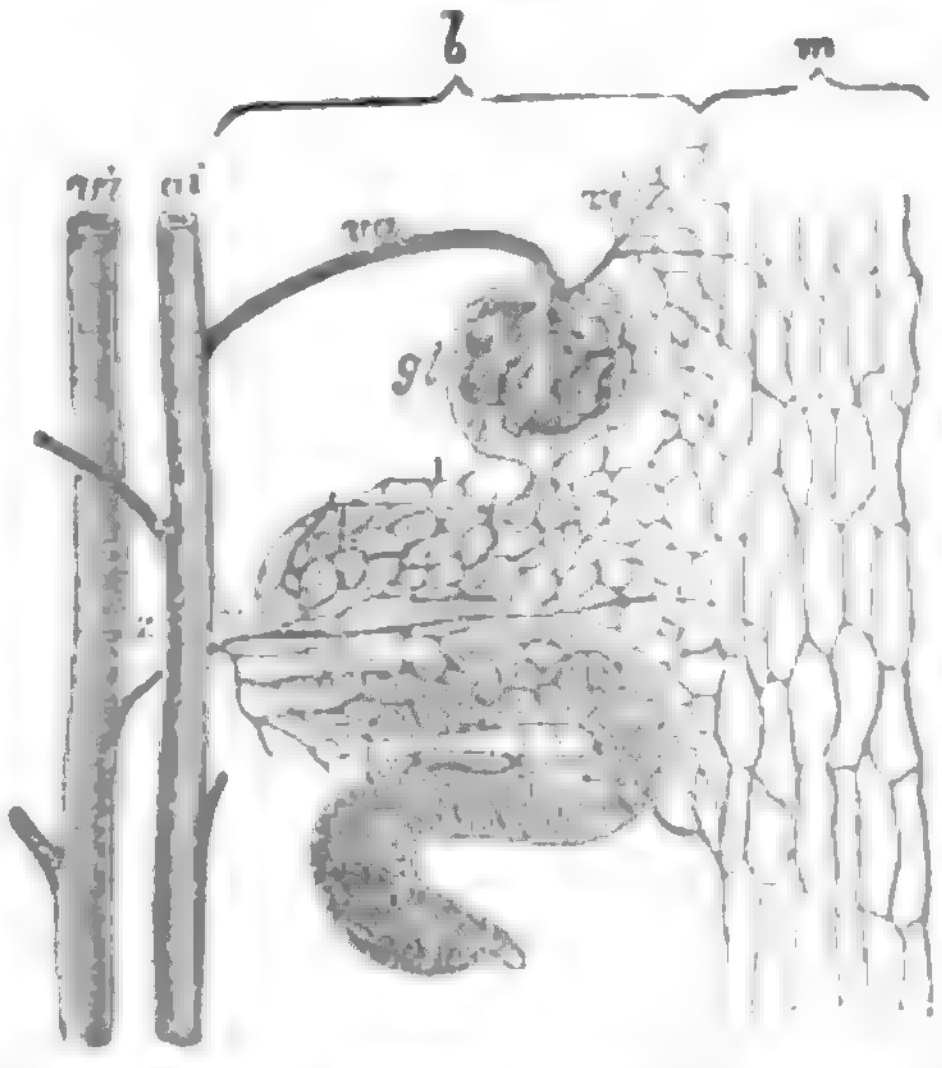

Diagrammatic Representation of the Blood-vessels in the Substance of the Cortex of the Kidney: *m*, region of the medullary ray; *b*, region of the tortuous portion of the tubules; *ai*, arteria interlobularis; *vi*, vena interlobularis; *va*, vas afferens; *gl*, glomerulus; *ve*, vas efferens; *vz*, venous twig of the interlobularis, from Ludwig, in Stricker's *Handbook*).

The *Renal Veins* arise from *three sources*: the veins beneath the capsule, the plexuses around the tubuli contorti in the cortical arches, and the plexuses situated at the apices of the pyramids of Malpighi. The veins beneath the capsule are stellate in arrangement, and are derived from the capillary network of the capsule, into which the terminal branches of the interlobular arteries break up. These join to form the *venæ interlobulares*, which pass inward *between* the pyramids of Ferrein, receive branches from the plexuses around the tubuli contorti, and, having arrived at the bases of the Malpighian pyramids, join with the venæ rectæ, next to be described (Figs. 633, 634, *b*).

The *Venæ Rectæ* are branches from the plexuses at the apices of the medullary pyramids, formed by the terminations of the arteriolæ rectæ. They pass outward in a straight course between the tubes of the medullary structure, and joining, as above stated, the venæ interlobulares, form the proper renal veins (Figs. 633, 634, *f*).

These vessels, *Venæ Propriæ Renales*, accompany the arteries of the same name running along the entire length of the sides of the pyramids, and, having received in their course the efferents from the Malpighian bodies in the cortical structure adjacent, quit the kidney proper to enter the sinus. In this cavity they inosculate with the corresponding veins from the other pyramids to form the *renal vein*, which, passing through the hilum, opens into the inferior vena cava, the left being longer than the right, from having to cross in front of the abdominal aorta.

NERVES OF THE KIDNEY.—The nerves of the kidney, although small, are about fifteen in number. They have small ganglia developed upon them, and are derived from the renal plexus, which is formed by branches from the solar plexus, the lower and outer part of the semilunar ganglion, and from the lesser and smallest splanchnic nerves. They communicate with the spermatic plexus—a circumstance which may explain the sympathy that exists between the kidney and testicle. So far as they have been traced, they seem to accompany the renal artery and its branches, but their exact mode of termination is not known.

The *lymphatics* consist of a superficial and deep set which terminate in the lumbar glands.

Connective Tissue, or Intertubular Stroma.—Although the tubules and vessels are closely packed, a certain small amount of connective tissue continuous with the capsule binds them firmly together. This tissue was first described by Goodsir, and subsequently by Bowman. Ludwig and Zawarykin have observed distinct fibres passing around the Malpighian bodies, and Henle has seen them between the straight tubes composing the medullary structure.

THE URETERS.

The **Ureters** are the two tubes which conduct the urine from the kidneys into the bladder. They commence within the sinus of the kidney by a number of short truncated branches, the *calices* or infundibula, which unite, either directly or indirectly, to form a dilated pouch, the *pelvis*, from which the ureter, after passing through the hilum of the kidney, descends to the bladder. The *calices* are cup-like tubes encircling the apices of the Malpighian pyramids; but inasmuch as one calyx may include two or even more papillæ, their number is generally less than the pyramids themselves, the former being from seven to thirteen, whilst the latter vary from eight to eighteen. These calices converge into two or three tubular divisions, which by their junction form the *pelvis*, or dilated portion of the ureter. The portion last mentioned, where the pelvis merges into the ureter proper, is found opposite the spinous process of the first lumbar vertebra, in which situation it is accessible behind the peritoneum. (See Fig. 586, p. 884.)

The *ureter proper* is a cylindrical membranous tube, from sixteen to eighteen inches in length and of the diameter of a goose-quill, extending from the pelvis of the kidney to the bladder. Its course is obliquely downward and inward through the lumbar region into the cavity of the pelvis, where it passes downward, forward, and inward across that cavity to the base of the bladder, into which it then opens by a constricted orifice, after having passed obliquely for nearly an inch between its muscular and mucous coats.

RELATIONS OF THE URETER PROPER.—In its course it rests upon the Psoas muscle, being covered by the peritoneum, and crossed obliquely, from within outward, by the spermatic vessels, the right ureter lying close to the outer side of the inferior vena cava. Opposite the first piece of the sacrum it crosses either the common or external iliac artery, lying behind the ileum on the *right* side and the sigmoid flexure of the colon on the *left*. In the pelvis it enters the posterior false ligament of the bladder, below the obliterated hypogastric artery, the vas deferens in the male passing between it and the bladder. In the female the ureter passes along the sides and cervix of the uterus and upper part of the vagina. At the base of the bladder it is situated about two inches from its fellow, lying, in the male, about an inch and a half behind the base of the prostate, at the posterior angle of the trigone.

Structure.—The *ureter* is composed of three coats—a fibrous, muscular, and mucous.

The *fibrous* coat is the same throughout the entire length of the duct, being continuous at one end with the capsule of the kidney at the floor of the sinus, whilst at the other it is lost in the fibrous structure of the bladder.

In the pelvis of the kidney the muscular coats are thick, but they become thinner and thinner in the calices, the longitudinal fibres becoming lost upon the sides of the mammillæ, whilst a few scattered fibres from the circular layer may be traced surrounding the medullary structure in the same situation. In the ureter proper the muscular fibres are very distinct, and are arranged in three layers—an external longitudinal, a middle circular, and an internal layer less distinct than the other two, but having a general longitudinal direction. According to Kölliker, this internal layer is only found in the neighborhood of the bladder.

The *mucous* coat is smooth and presents a few longitudinal folds which become effaced by distension. It is continuous with the mucous membrane of the bladder below, whilst it is prolonged over the mammillæ of the kidney above. Its epithelium is of a peculiar character, and resembles that found in the bladder. It is known by the name of "transitional" epithelium. It consists of several layers of cells, of which the innermost—that is to say, the cells in contact with the urine—are quadrilateral in shape, with a concave margin on their outer surface, into which fits the rounded end of the cells of the second layer. These, the intermediate cells, more or less resemble columnar epithelium, and are pear-shaped, with a rounded internal extremity which fits into the concavity of the cells of the first layer, and a narrow external extremity which is wedged in between the cells of the third layer. The external or third layer consists of conical or oval cells varying in number in different parts, and presenting processes which extend down into the basement membrane.

The *arteries* supplying the ureter are branches from the renal, spermatic, internal iliac, and inferior vesical.

The *nerves* are derived from the inferior mesenteric, spermatic, and hypogastric plexuses.

SUPRARENAL CAPSULES.

The suprarenal capsules were formerly classified together with the spleen, thymus, and thyroid under the head of "ductless glands," as they have no excretory duct. They are two small flattened glandular bodies, of a yellowish color, situated at the back part of the abdomen, behind the peritoneum and immediately in front of the upper part of either kidney; hence their name. The right one is somewhat triangular in shape, bearing a resemblance to a cocked hat; the left is more semilunar, and usually larger and higher than the right. They vary in size in different individuals, being sometimes so small as to be scarcely detected: their usual size is from an inch and a quarter to nearly two inches in length, rather less in width, and from two to three lines in thickness. In weight they vary from one to two drachms.

RELATIONS.—The *anterior surface* is in relation, on the right side, with the under surface of the liver, and on the left with the pancreas and spleen. The *posterior surface* rests upon the crus of the Diaphragm opposite the tenth dorsal vertebra. The *upper* thin convex border is directed upward and inward. The *lower* thick concave border rests upon the upper end of the kidney, to which it is connected by areolar tissue. The *inner border* is in relation with the great splanchnic nerves and semilunar ganglion, and lies in contact on the right side with the inferior vena cava, and on the left side with the aorta. The surface of the suprarenal gland is surrounded by areolar tissue containing much fat, and closely invested by a thin fibrous coat, which is difficult to remove on account of the numerous fibrous processes and vessels which enter the organ through the furrows on its anterior surface and base.

Structure.—On making a perpendicular section the gland is seen to consist of two substances—external or cortical, and internal or medullary. The former, which constitutes the chief part of the organ, is of a deep-yellow color, and consists chiefly of narrow columnar masses placed perpendicularly to the surface. The medullary substance is soft, pulpy, and of a dark-brown or black color, whence the name *atrabiliary capsules* formerly given to these organs. In the centre is often seen a space, not natural, but formed by the breaking down after death of the medullary substance.

The **cortical portion** owes its arrangement to the disposition of the capsule, which sends into the interior of the gland processes passing in vertically and communicating with each other by transverse bands, so as to form spaces which open into each other. These spaces are of slight depth near the surface of the organ, so that there the section somewhat resembles a net; this is termed the *zona glomerulosa*, but they become much deeper or longer farther in, so as to resemble pipes or tubes placed endwise, the *zona fasciculata*. Still deeper down, near the medullary part, the spaces become again of small extent; this is named the *zona reticularis*. These processes or trabeculæ, derived from the capsule and forming the framework of the spaces, are composed of fibrous connective tissue, with longitudinal bundles of unstriped muscular fibres. Within the interior of the spaces are contained groups of polyhedral cells, which are finely granular in appearance and contain a spherical nucleus, and not unfrequently fat-molecules. These groups of cells do not entirely fill the spaces in which they are contained, but between them and the trabeculæ of the framework is a channel which is believed to be a lymph-path or sinus, and which communicates with certain passages between the cells composing the group.

The lymph-path is supposed to open into a plexus of efferent lymphatic vessels which are contained in the capsule.

In the **medullary portion** the fibrous stroma seems to be collected together into a much closer arrangement, and forms bundles of connective tissue which are loosely applied to the large plexus of veins of which this part of the organ mainly consists. In the interstices lie a number of cells compared by Frey to those of columnar epithelium. They are coarsely granular, do not contain any fat-molecules, and some of them are branched. Luschka has affirmed that these branches are connected with the nerve-fibres of a very intricate plexus which is found in the medulla: this statement has not been verified by other observers, for the tissue of the medullary substance is less easy to make out than that of the cortical, owing to its rapid decomposition.

FIG. 636.

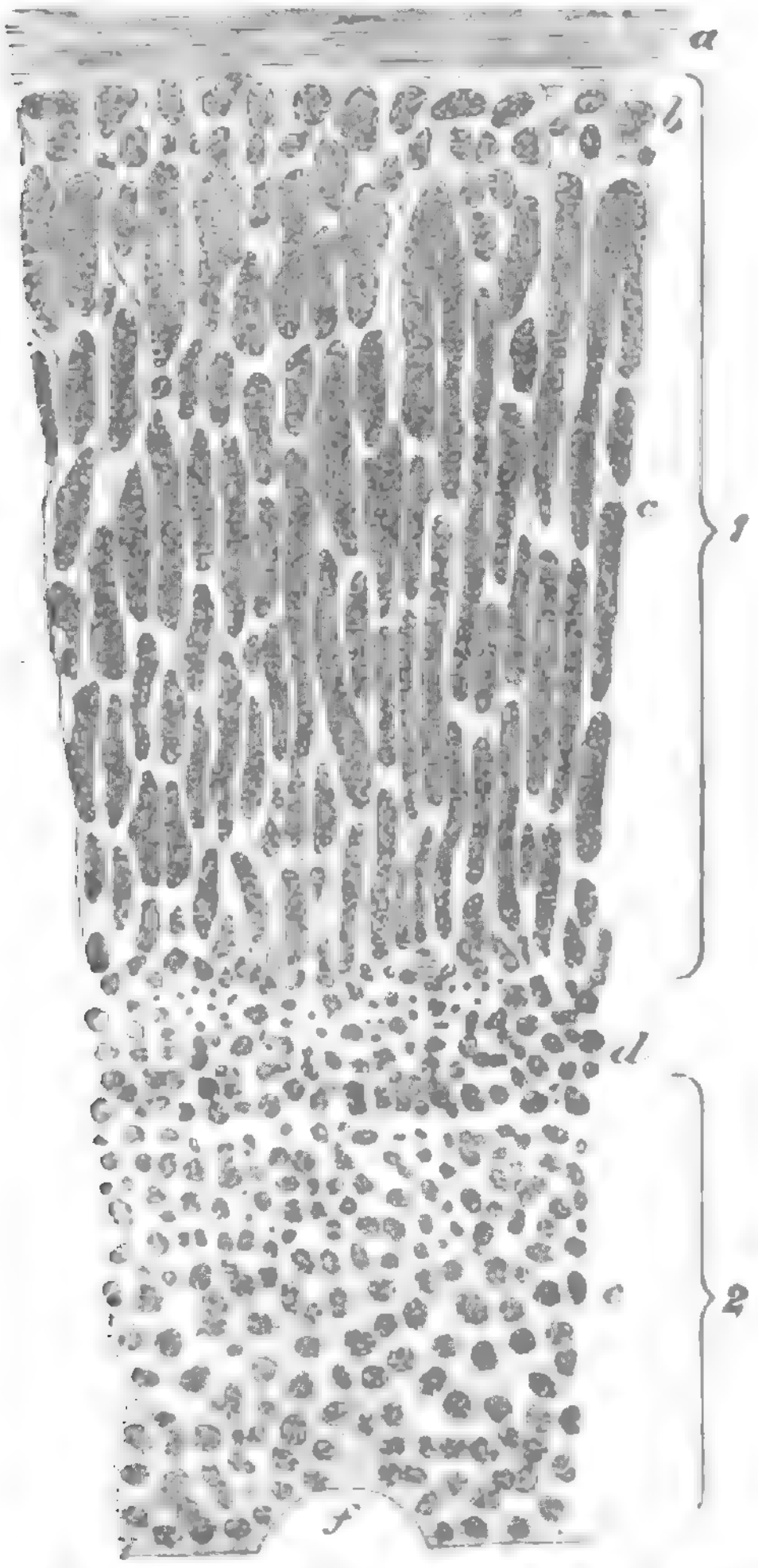

Vertical Section of the Suprarenal Capsule (from Elberth, in Stricker's *Manual*): 1, Cortical substance; 2, medullary substance; *a*, capsule; *b*, zona glomerulosa; *c*, zona fasciculata; *d*, zona reticularis; *e*, medulla; *f*, a large vein.

FIG. 637.

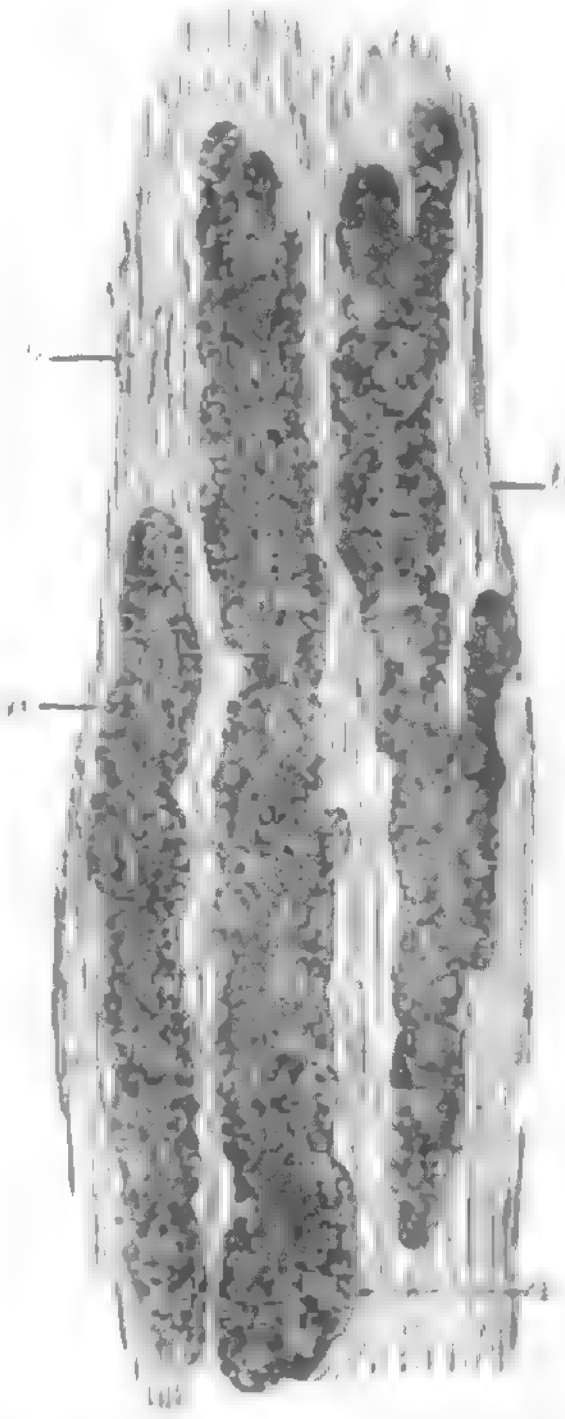

Cortical Portion of Human Suprarenal Body, under a high magnifying power: *a*, gland-cylinders; *b*, interstitial connective tissue.

FIG. 638.

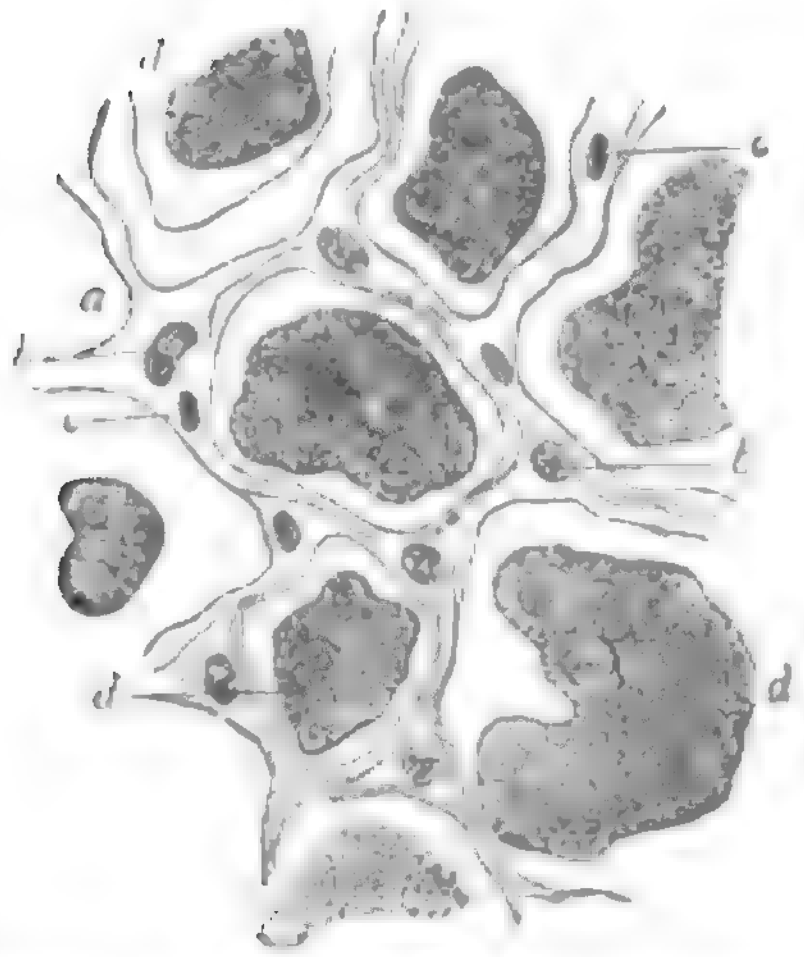

Transverse Section through the Cortical Substance of the Human Suprarenal Body: *a*, framework of connective tissue; *b*, capillaries; *c*, nuclei; *d*, gland-cells.

The numerous arteries which enter the suprarenal bodies from the sources mentioned below penetrate the cortical part of the gland, where they break up into capillaries in the fibrous septa, and these converge to the very numerous veins of the medullary portion, which are collected together into the suprarenal vein, which usually emerges as a single vessel from the centre of the gland.

The *arteries* supplying the suprarenal capsules are numerous and of large size; they are derived from the aorta, the phrenic, and the renal; they subdivide into numerous minute branches previous to entering the substance of the gland.

The *suprarenal vein* returns the blood from the medullary venous plexus, and receives several branches from the cortical substance; it opens on the right side into the inferior vena cava, on the left side into the renal vein.

The *lymphatics* terminate in the lumbar glands.

The *nerves* are exceedingly numerous: they are found chiefly, if not entirely, in the medulla, and are derived from the solar and renal plexuses, and, according to Bergmann, from the phrenic and pneumogastric nerves. They have numerous small ganglia developed upon them, from which circumstance the organ has been conjectured to have some function in connection with the sympathetic nervous system.

THE PELVIS.

The **cavity of the pelvis** is that part of the general abdominal cavity which is below the level of the linea ilio-pectinea and the promontory of the sacrum.

Boundaries.—It is bounded behind by the sacrum, the coccyx, and the great sacro-sciatic ligaments; in front and at the sides by the pubes and ischia, covered by the Obturator muscles; above it communicates with the cavity of the abdomen; and below it is limited by the triangular ligament, the Levatores ani and Coccygei muscles, and the visceral layer of the pelvic fascia, which is reflected from the wall of the pelvis on to the viscera.

Contents.—The viscera contained in this cavity are the urinary bladder, the rectum, and some of the generative organs peculiar to each sex: they are partially covered by the peritoneum, and supplied with blood-vessels, lymphatics, and nerves.

THE BLADDER.

The **Bladder** is the reservoir for the urine. It is a musculo-membranous sac situated in the pelvis, behind the pubes, and in front of the rectum in the male, the uterus and vagina intervening between it and that intestine in the female. The shape, position, and relations of the bladder are greatly influenced by age, sex, and the degree of distension of the organ. *During infancy* it is conical in shape and projects above the upper border of the pubes into the hypogastric region. *In the adult*, when quite empty and contracted, it is a small triangular sac placed deeply in the pelvis, flattened from before backward, its apex reaching as high as the upper border of the symphysis pubis. When slightly distended it has a rounded form, and is still contained within the pelvic cavity; and when greatly distended it is ovoid in shape, rising into the abdominal cavity and often extending nearly as high as the umbilicus. It is larger in its vertical diameter than from side to side, and its long axis is directed from above obliquely downward and backward, in a line directed from some point between the pubes and umbilicus (according to its distension) to the end of the coccyx. The bladder when distended is slightly curved forward toward the anterior wall of the abdomen, so as to be more convex behind than in front. In the female it is larger in the transverse than in the vertical diameter, and its capacity is said to be greater than in the male.[1] When moderately distended it measures about five inches in length and three inches across, and the ordinary amount which it contains is about a pint.

The bladder is divided into a summit, body, base, and neck.

The *summit* or apex of the bladder is rounded and directed forward and upward; it is connected to the umbilicus by a fibro-muscular cord, the *urachus*, and also by means of two rounded fibrous cords, the obliterated portions of the hypogastric arteries, which are placed one on each side of the urachus. The summit of the bladder behind the urachus is covered by peritoneum, whilst the portion in front of the urachus has no peritoneal covering, but rests against the abdominal wall.

The **Urachus** is the obliterated remains of a tubular canal which exists in the embryo, and connects the cavity of the bladder with a membranous sac placed external to the abdomen opposite the umbilicus, called the *allantois*. In the infant at birth it is occasionally found pervious, so that the urine escapes at the umbilicus, and calculi have been found in its canal.

---

[1] According to Henle, the bladder is considerably smaller in the female than in the male.

The *body* of the bladder in front is not covered by peritoneum, and is in relation with the triangular ligament, the posterior surface of the symphysis pubis, the Internal obturator muscles, and, when distended, with the abdominal parietes.

[The amount of space above the pubes uncovered by peritoneum, through which access may be had to the bladder for exploration or operation, varies very much. When the bladder is empty, there is none, as the bladder then sinks into the pelvis; when it is distended, the degree to which the peritoneum is lifted above the pubes depends on the degree of distension. This will amount to one to two inches, and if need be can be increased by stripping the peritoneum off the bladder to some extent. The bladder can also be lifted still farther and made more accessible by inserting a rubber bag into the rectum and distending it with water. Not over ten ounces should be used in the rectal bag, lest rupture take place; and for a similar reason rather less should be used in distending the bladder. The student, if possible, should distend both of these viscera experimentally both before and after opening the abdomen.]

FIG. 639.

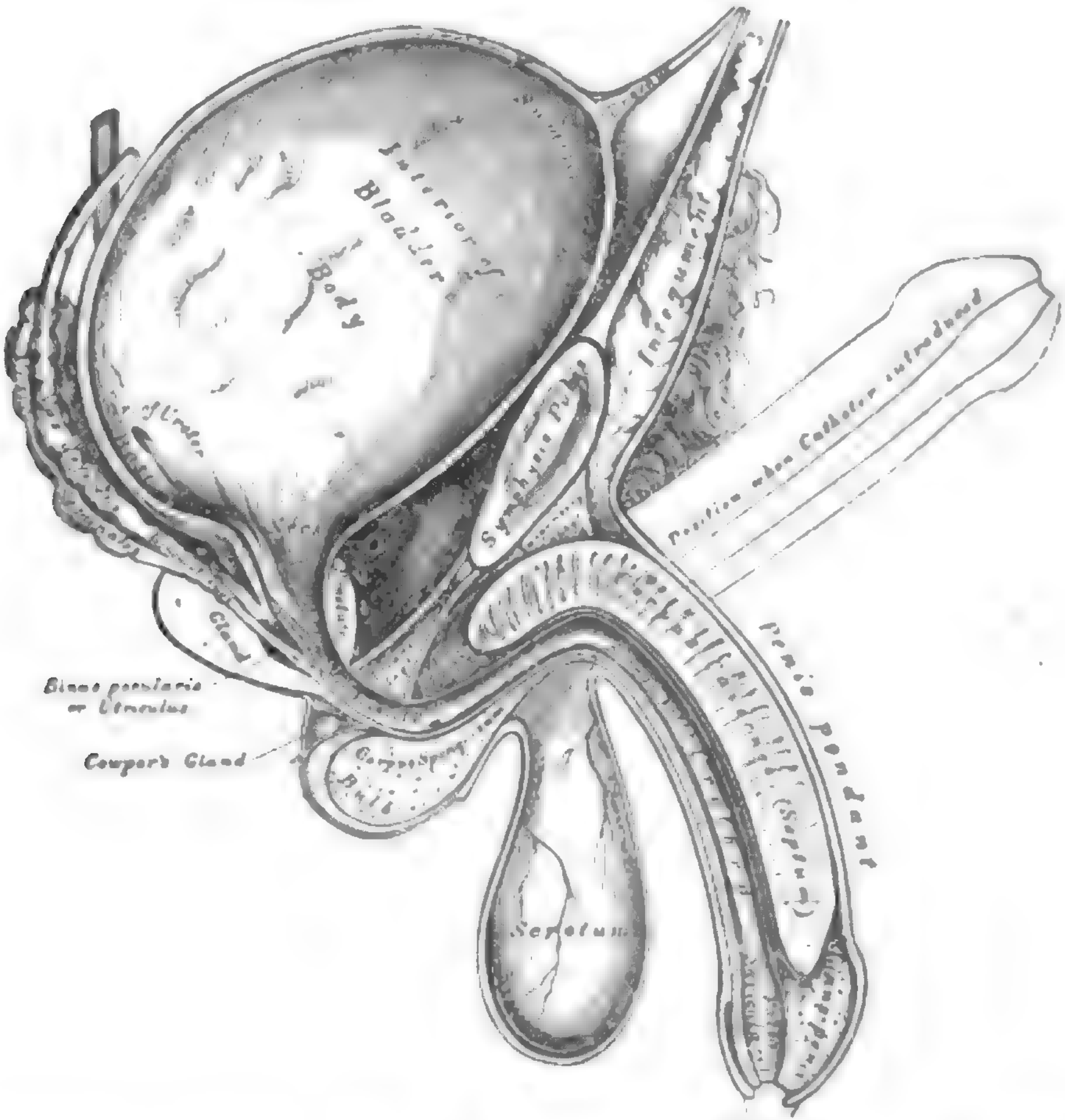

Vertical Section of Bladder, Penis, and Urethra. [Compare with Fig. 682, p. 1022.]

The posterior surface is covered by peritoneum throughout. It corresponds, in the male with the rectum; in the female with the uterus, some convolutions of the small intestine being interposed.

The side of the bladder is crossed obliquely from below, upward, and forward by the obliterated hypogastric artery: above and behind this cord the bladder is covered by peritoneum, but below and in front of it the serous covering is wanting, and it is connected to the pelvic fascia. The vas deferens passes in an arched direction from before backward along the side of the bladder, toward its base, crossing in its course the obliterated hypogastric artery and passing along the inner side of the ureter.

The *base* (*fundus*) of the bladder is directed downward and backward. It varies in extent according to the state of distension of the organ, being very broad when full, but much narrower when empty. *In the male* it rests upon the second portion of the rectum, from which it is separated by a reflection of the recto-vesical fascia. It is covered posteriorly, for a slight extent, by the peritoneum, which is reflected from it upon the rectum, forming the recto-vesical fold. The portion of the bladder in relation with the rectum corresponds to a triangular space bounded behind by the recto-vesical fold, on either side by the vesicula seminalis and vas deferens, and touching the prostate gland in front. When the bladder is very full the peritoneal fold is raised with it, and the distance between its reflection and the anus is about four inches; but this distance is much diminished when the bladder is empty and contracted. *In the female* the base of the bladder lies in contact with the lower part of the cervix uteri, is adherent to the anterior wall of the vagina, and is separated from the upper part of the anterior surface of the cervix uteri by a fold of the peritoneum.

The *neck* (*cervix*) of the bladder is the constricted portion continuous with the urethra. In the male its direction is oblique in the erect posture, and it is surrounded by the prostate gland. In the female its direction is obliquely downward and forward.

Ligaments.—The bladder is retained in its place by ligaments which are divided into true and false. The true ligaments are five in number—two anterior and two lateral, formed by the recto-vesical fascia and the urachus. The false ligaments, also five in number, are formed by folds of the peritoneum.

The *anterior ligaments* (*pubo-prostatic*) extend from the back of the pubes, one on each side of the symphysis, to the front of the neck of the bladder, over the upper surface of the prostate gland. These ligaments contain a few muscular fibres prolonged from the bladder.

The *lateral ligaments*, broader and thinner than the preceding, are attached to the lateral parts of the prostate and to the sides of the base of the bladder.

The *urachus* is the fibro-muscular cord already mentioned extending between the summit of the bladder and the umbilicus. It is broad below at its attachment to the bladder, and becomes narrower as it ascends.

The *false ligaments* of the bladder are two posterior, two lateral, and one superior.

The *two posterior* pass forward, in the male, from the sides of the rectum; in the female, from the sides of the uterus to the posterior and lateral aspect of the bladder: they form the lateral boundaries of the recto-vesical fold of the peritoneum, and contain the obliterated hypogastric arteries and the ureters, together with vessels and nerves.

The *two lateral* ligaments are reflections of the peritoneum from the iliac fossæ to the sides of the bladder.

The *superior* ligament is the prominent fold of peritoneum extending from the summit of the bladder to the umbilicus. It covers the urachus and the obliterated hypogastric arteries.

Structure.—The bladder is composed of four coats—a serous, a muscular, a submucous, and a mucous coat.

The *serous coat* is partial, and derived from the peritoneum. It invests the posterior surface from opposite the termination of the two ureters to its summit, and is reflected from this point and from the sides on to the abdominal and pelvic walls.

The *muscular coat* consists of three layers of unstriped muscular fibre: an external layer, composed of fibres having for the most part a longitudinal arrangement; a middle layer, in which the fibres are arranged more or less in a circular manner; and an internal layer, in which the fibres have a general longitudinal arrangement.

The fibres of the *external longitudinal layer* arise from the posterior surface of the body of the pubes in both sexes (*musculi pubo-vesiculis*), and in the male from the adjacent part of the prostate gland and its capsule. They pass in a more or less longitudinal manner up the anterior surface of the bladder, over its apex, and then descend along its posterior surface to its base, where they become attached to the prostate in the male and to the front of the vagina in the female. At the sides of the bladder the fibres are arranged obliquely and intersect one another. This layer has been named the *detrusor urinæ muscle.*

The *middle circular layers* are very thinly and irregularly scattered on the body of the organ, and, though to some extent placed transversely to the long axis of the bladder, are for the most part arranged obliquely. Toward the lower part of the bladder, round the cervix and commencement of the urethra, they are disposed in a thick circular layer, forming the *sphincter vesicæ*, which is continuous with the muscular fibres of the prostate gland. Pettigrew has described these two layers as forming a series of figure-of-8 spiral loops.

FIG. 640.

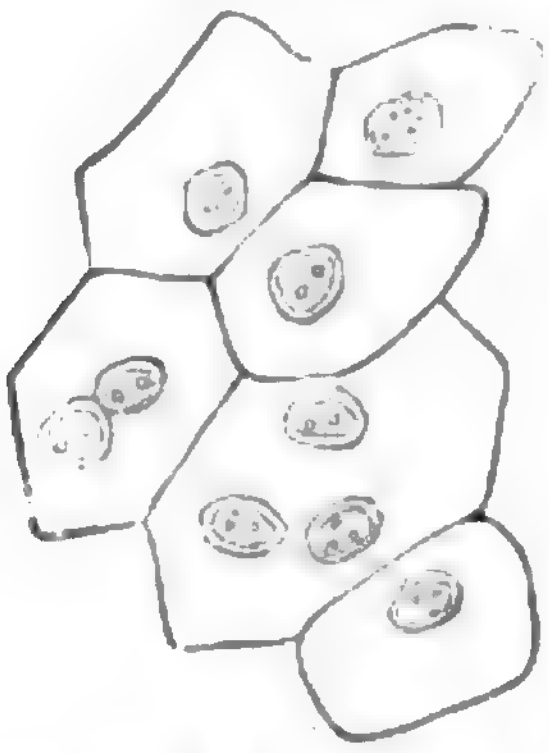

Superficial Layer of the Epithelium of the Bladder, composed of polyhedral cells of various sizes, each with one, two, or three nuclei (Klein and Noble Smith).

FIG. 641.

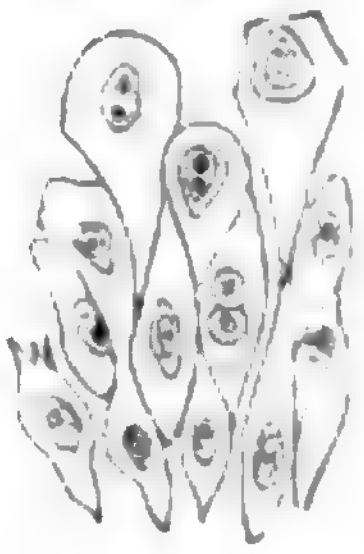

Deep Layers of Epithelium of Bladder, showing large club-shaped cells above, and smaller, more spindle-shaped cells below, each with an oval nucleus (Klein and Noble Smith).

The *internal longitudinal layer* is thin and its fasciculi have a reticular arrangement, but with a tendency to assume for the most part a longitudinal direction.

Two bands of oblique fibres, originating behind the orifices of the ureters, converge to the back part of the prostate gland, and are inserted by means of a fibrous process into the middle lobe of that organ. They are the *muscles of the ureters*, described by Sir C. Bell, who supposed that during the contraction of the bladder they served to retain the oblique direction of the ureters, and so prevent the reflux of the urine into them.

The *submucous coat* consists of a layer of areolar tissue connecting together the muscular and mucous coats, and intimately united to the latter.

The *mucous coat* is thin, smooth, and of a pale rose color. It is continuous through the ureters with the lining membrane of the uriniferous tubes, and below with that of the urethra. It is connected loosely to the muscular coat by a layer of areolar tissue, excepting at the trigone, where its adhesion is more close. It is provided with a few mucous follicles, and numerous small racemose glands, lined with columnar epithelium, exist near the neck of the organ. The epithelium covering it is of the transitional variety, consisting of a superficial layer of polyhedral, flattened cells, each with one, two, or three nuclei; beneath these a stratum of large club-shaped cells, with the narrow extremity directed downward and wedged in between smaller spindle-shaped cells, containing an oval nucleus (Figs. 640, 641).

Interior of the Bladder.—Upon the inner surface of the base of the bladder, immediately behind the urethral orifice, is a triangular, smooth surface, the apex of which is directed forward; this is the *trigonum vesicæ* or *trigone vesical.* It is paler in color than the rest of the mucous membrane, and never presents any rugæ, even in the collapsed condition of the organ, owing to its intimate adhesion to the subjacent tissue. It is bounded at each posterior angle by the orifices of the ureters, which are placed nearly two inches from each other and about an inch and a half behind the orifice of the urethra. The trigone corresponds with the interval at the base of the bladder, bounded by the prostate in front and the vesiculæ and vasa deferentia on the sides. Projecting from the lower and anterior part of the bladder into the orifice of the urethra is a slight elevation of mucous membrane called the *uvula vesicæ*. It is formed by a thickening of the prostate.

FIG. 642.

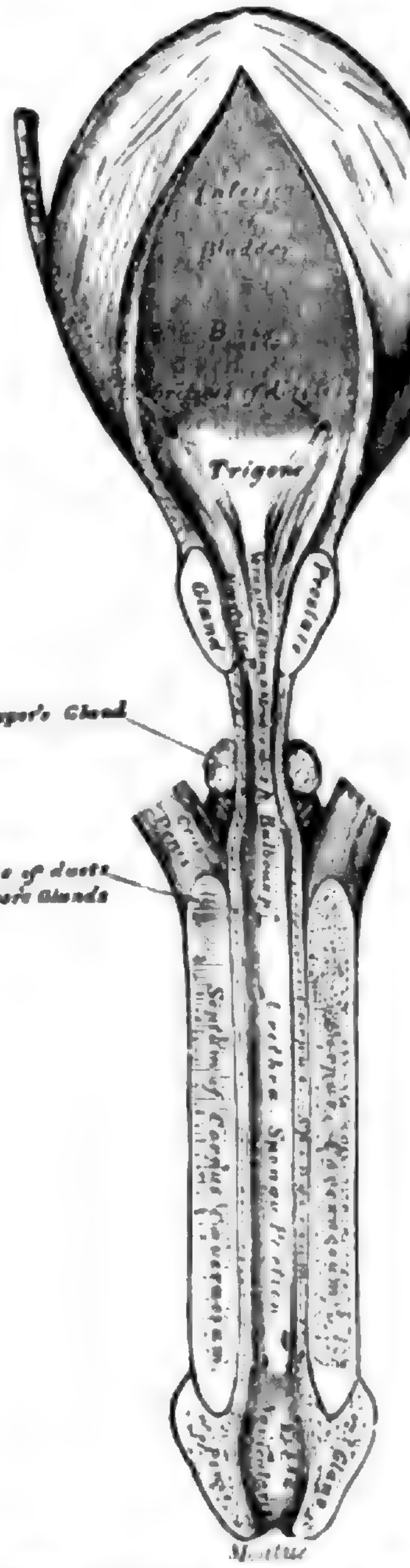

The Bladder and Urethra, laid open, seen from above.

The *arteries* supplying the bladder are the superior, middle, and inferior vesical in the male, with additional branches from the uterine and vaginal in the female. They are all derived from the anterior trunk of the internal iliac. The obturator and sciatic arteries also supply small visceral branches to the bladder.

The *veins* form a complicated plexus round the neck, sides, and base of the bladder, and terminate in the internal iliac vein.

The *lymphatics* accompany the blood-vessels, passing through the glands surrounding them.

The *nerves* are derived from the hypogastric plexus of the sympathetic and the fourth sacral nerve, the former supplying the upper part of the organ, the latter its base and neck. According to F. Darwin, the sympathetic fibres have ganglia connected with them which send branches to the vessels and muscular coat.

MALE URETHRA.

The **Urethra** extends from the neck of the bladder to the meatus urinarius. It presents a double curve in the flaccid state of the penis, but in the erect state it forms only a single curve, the concavity of which is directed upward (Fig. 639, p. 956). Its length varies from eight to nine inches, and it is divided into three portions, the prostatic, membranous, and spongy, the structure and relations of which are essentially different.

The **prostatic portion** is the widest and most dilatable part of the canal. It passes through the prostate gland from its base to its apex, lying nearer its upper than its lower surface. It is about an inch and a quarter in length; the form of the canal is spindle-shaped, being wider in the middle than at either extremity, and narrowest in front, where it joins the membranous portion. A transverse section of the canal as it lies in the prostate is horseshoe in shape, the convexity being directed upward (Fig. 644, p. 962). The canal is closed except during the passage of the urine, the upper and lower mucous surfaces being in contact.

Upon the floor of the canal is a narrow longitudinal ridge, the *verumontanum* or *caput gallinaginis*, formed by an elevation of the mucous membrane and its subjacent tissue. It is eight or nine lines in length and a line and a half in height, and contains, according to Kobelt, muscular and erectile tissues. When distended it may serve to prevent the passage of the semen backward into the bladder. On each side of the verumontanum is a slightly depressed fossa, the *prostatic sinus*, the floor of which is perforated by numerous apertures, the *orifices of the prostatic ducts*, the ducts of the middle lobe opening behind the crest. At the fore part of the verumontanum, in the middle line, is a depression, the *sinus pocularis* (*vesicula prostatica*), and upon or within its margins are the slit-like openings of the ejaculatory ducts. The sinus pocularis forms a cul-de-sac about a quarter of an inch in length which runs upward and backward in the substance of the prostate beneath the middle lobe; its prominent upper wall partly forms the verumontanum. Its walls are composed of fibrous tissue, muscular fibres, and mucous membrane, and numerous small glands open on its inner surface. It has been called by Weber, who discovered it, the *uterus masculinus*, from its homology with the female organ.

The **membranous portion** of the urethra extends between the apex of the prostate and the bulb of the corpus spongiosum. It is the narrowest part of the canal (excepting the orifice), and measures three-quarters of an inch along its upper and half an inch along its lower surface, in consequence of the bulb projecting backward beneath it below. Its upper concave surface is placed about an inch beneath the pubic arch, from which it is separated by the dorsal vessels and nerves of the penis and some muscular fibres. Its lower convex surface is separated from the rectum by a triangular space which constitutes the perineum. The membranous portion of the urethra perforates both the anterior and posterior layers of the deep perineal fascia, and receives an investment from them. As it pierces the posterior layer, the fibres around the opening are prolonged backward over the posterior part of the membranous portion of the urethra; and as it pierces the anterior layer, a similar prolongation takes place in the opposite direction, investing the anterior part of the membranous portion. It is also surrounded by the Compressor urethræ muscle.

The **spongy** [or **penile**] **portion** is the longest part of the urethra, and is contained in the corpus spongiosum. It is about six inches in length, and extends from the termination of the membranous portion to the meatus urinarius. Commencing below the symphysis pubis, it ascends for a short distance and then curves downward. It is narrow and of uniform size in the body of the penis, measuring about a quarter of an inch in diameter, being dilated behind within the bulb; and again anteriorly, within the glans penis, forming the *fossa navicularis*. A cross-section of this canal in the body of the penis has its long diameter transverse, but in the glans that diameter is directed vertically.

The *bulbous portion* is a name given in some descriptions of the urethra to the posterior part of the spongy portion contained within the bulb.

The *meatus urinarius* is the most contracted part of the urethra; it is a vertical slit about three lines in length, bounded on each side by two small labia.

[The calibre of the urethra has generally been placed much too low. In the average adult, when its walls are separated, it is $\frac{3}{8}$ of an inch in diameter (about 9 millimeters (No. 27) of the French catheter scale). It has two points of marked narrowing as to dilatability—at the meatus and the triangular ligament; and three of decided dilatation—at the fossa navicularis and the bulbous and prostatic portions.]

[Fig. 643.

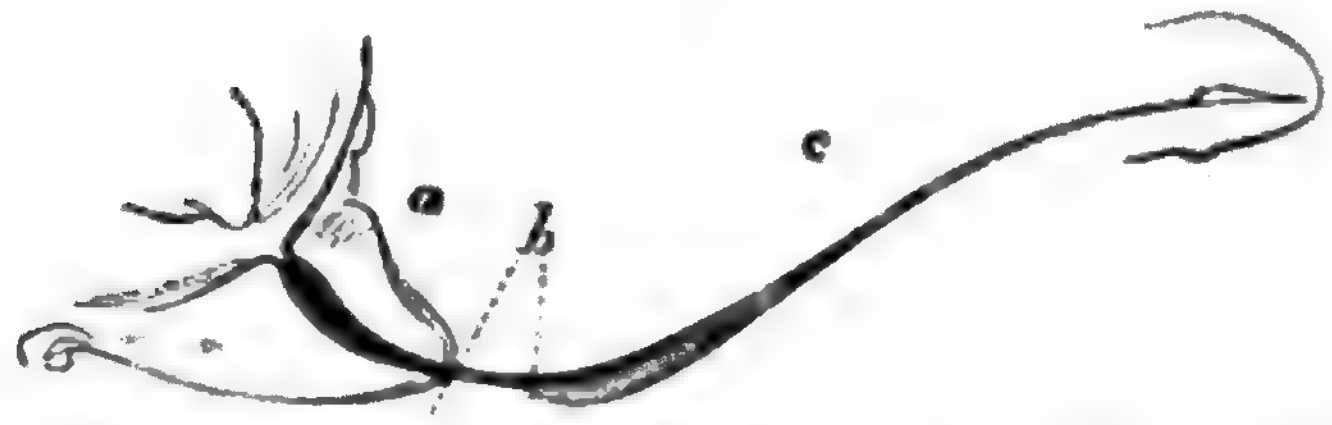

Diagram of Urethra in Natural Condition, *a*, *b*, and *c* representing the prostatic, membranous, and spongy portions respectively (Thompson).]

The inner surface of the lining membrane of the urethra, especially on the floor of the spongy portion, presents the orifices of numerous mucous glands and follicles situated in the submucous tissue, and named the *glands of Littré*. They vary in size, and their orifices are directed forward, so that they may easily intercept the point of a catheter in its passage along the canal; especially the largest one of these lacunæ, which is situated on the upper surface of the fossa navicularis, about an inch and a half from the orifice: it is called the *lacuna magna*. Into the bulbous portion are found opening the ducts of Cowper's glands.[1]

Structure.—The urethra is composed of a continuous mucous membrane supported by a submucous tissue which connects it with the various structures through which it passes.

The *mucous coat* forms part of the genito-urinary mucous membrane. It is continuous with the mucous membrane of the bladder, ureters, and kidneys, externally with the integument covering the glans penis, and is prolonged into the ducts of the glands which open into the urethra—viz. Cowper's glands, the prostate gland, and the vasa deferentia and vesiculæ seminales—through the ejaculatory ducts. In the spongy and membranous portions the mucous membrane is arranged in longitudinal folds when the organ is contracted. Small papillæ are found upon it near the orifice, and its epithelial lining is of the columnar variety, excepting near the meatus, where it is laminated.

---

[1] The student should bear in mind that though the urethra is described as a tube, it is not so in reality, but is a mere cleft; and that the canal is closed and the opposite mucous surfaces in contact except during the passage of the urine or semen.

The *submucous tissue* consists of plain muscular fibre, mixed with fibrous and elastic tissue. The muscular fibres are arranged in two layers, the inner layer being disposed longitudinally, and the outer in a circular direction. Ellis has demonstrated that the longitudinal fibres are continuous with the internal longitudinal muscular fibres of the bladder. The amount of muscular tissue differs in different parts of the canal. It is greatest in quantity in the prostatic portion, becomes diminished in amount in the membranous portion, and almost replaced by fibrous tissue in the spongy portion. In the prostatic and membranous parts of the urethra there is also a thin enveloping layer of erectile tissue.

[The cleft of the urethra (Fig. 645) is horizontal, except toward the bladder, where it is arched (Fig. 644), and toward the meatus, where it becomes vertical.]

Male Generative Organs.

PROSTATE GLAND.

THE **Prostate Gland** (πρυίστημι, to stand before) is a pale, firm, glandular body which surrounds the neck of the bladder and commencement of the urethra. It is placed in the pelvic cavity behind and below the symphysis pubis posterior to the deep perineal fascia, and upon the rectum, through which it may be distinctly felt, especially when enlarged. In shape and size it resembles a chestnut.

FIG. 644.



Transverse Section of the Prostate Gland, showing the urethra (1), arching over the eminence of the caput gallinaginis; beneath it the sinus pocularis (2) and ejaculatory ducts (3).

Its *base* is directed backward toward the neck of the bladder.

The *apex* is directed forward to the deep perineal fascia, which it touches.

Its *under surface* is smooth and rests on the rectum, to which it is connected by dense areolar fibrous tissue.

Its *upper surface* is flattened, marked by a slight longitudinal furrow, and placed about three-quarters of an inch below the pubic symphysis.

It measures about an inch and a half in its transverse diameter at the base, an inch in its antero-posterior diameter, and three-quarters of an inch in depth. Its weight is about six drachms. It is held in its position by the anterior ligaments of the bladder (*pubo-prostatic*); by the posterior layer of the deep perineal fascia, which invests the commencement of the membranous portion of the urethra and prostate gland; and by the anterior portion of the Levator ani muscle (*levator prostatæ*), which passes down on each side from the symphysis pubis and anterior ligament of the bladder to the sides of the prostate.

The prostate consists of two lateral lobes and a middle lobe.

The *two lateral lobes* are of equal size, separated behind by a deep notch, and marked by a slight furrow upon their upper and lower surfaces, which indicates the bilobed condition of the organ in some animals.

The third or *middle lobe* is a small transverse band, occasionally a rounded or triangular prominence, placed between the two lateral lobes at the under and posterior part of the organ. It lies immediately beneath the neck of the bladder, behind the commencement of the urethra, and above and between the ejaculatory ducts. Its existence is not constant, but it is occasionally found at an early period of life, as well as in adults and in old age. In advanced life this or some other portion of the prostate often becomes considerably enlarged, and projects into the bladder, so as to impede the passage of the urine. According to Dr. Messer's researches, conducted at Greenwich Hospital,[1] it would seem that such obstruction exists in 20 per cent. of all prostates over sixty years of age.

The prostate gland is perforated by the urethra and common seminal ducts. The urethra usually lies about one-third nearer its upper than its lower surface; occasionally the prostate surrounds only the lower three-fourths of this tube, and more rarely the urethra runs through the lower instead of the upper part of the gland. The ejaculatory ducts pass forward obliquely through a conical canal situated in the lower part of the prostate and open into the prostatic portion of the urethra.

Structure.—The prostate is enclosed in a thin but firm fibrous capsule distinct from that derived from the posterior layer of the deep perineal fascia, and separated from it by a plexus of veins. Its substance is of a pale reddish-gray color, very friable, but of great density. It consists of glandular substance and muscular tissue.

The muscular tissue, according to Kölliker, constitutes the proper stroma of the prostate, the connective tissue being very scanty, and simply forming thin trabeculæ between the muscular fibres in which the vessels and nerves of the gland ramify. The muscular tissue is arranged as follows: Immediately beneath the fibrous capsule is a dense layer which forms an investing sheath for the gland; secondly, around the urethra as it lies in the prostate is another dense layer of circular fibres, continuous behind with the internal layer of the muscular coat of the bladder, and in front blending with the fibres surrounding the membranous portion of the urethra. Between these two layers strong bands of muscular tissue, which decussate freely, form meshes in which the glandular structure of the organ is imbedded. In that part of the gland which is situated anterior to the urethra the muscular tissue is especially dense, and there is here little or no gland-tissue; while in that part which is behind the urethra the muscular tissue presents a wide-meshed structure, which is densest at the upper part of the gland—that is, near the bladder—becoming looser and more sponge-like toward the apex of the organ.

The *glandular substance* is composed of numerous follicular pouches opening into elongated canals, which join to form from twelve to twenty small excretory ducts. The follicles are connected together by areolar tissue, supported by prolongations from the fibrous capsule and muscular stroma and enclosed in a delicate capillary plexus. The epithelium lining both the canals and the terminal vesicles is of the columnar variety. The prostatic ducts open into the floor of the prostatic portion of the urethra.

VESSELS AND NERVES.—The *arteries* supplying the prostate are derived from the internal pudic, vesical, and hemorrhoidal. Its *veins* form a plexus around the sides and base of the gland; they receive in front the dorsal vein of the penis and terminate in the internal iliac vein. The *nerves* are derived from the hypogastric plexus.

COWPER'S GLANDS.

Cowper's Glands are two small rounded and somewhat lobulated bodies, of a yellow color, about the size of peas, placed beneath the fore part of the membranous portion of the urethra, between the two layers of the deep perineal fascia. They lie close behind the bulb, and are enclosed by the transverse fibres of the Compressor urethræ muscle. Each gland consists of several lobules, held together by a fibrous investment. Each lobule consists of a number of acini, lined by clear columnar cells, opening into one common duct, which, joining with the ducts of other lobules outside the gland, form a single excretory duct. The excretory duct of each gland, nearly an inch in length, passes obliquely forward beneath the mucous membrane, and opens by a minute orifice on the floor of the bulbous portion of the urethra. Their existence is said to be constant; they gradually diminish in size as age advances.

---

[1] *Med.-Chir. Trans.*, vol. xliii. p. 152.

THE PENIS.

The **Penis** [Figs. 639, p. 956, and 682, p. 1022] is the organ of copulation, and contains in its interior the larger portion of the urethra. It consists of a root, body, and extremity, or *glans penis*.

The *root* is broad, and firmly connected to the rami of the pubes by two strong tapering fibrous processes, the *crura*, and to the front of the symphysis pubis by a fibrous membrane, the *suspensory ligament*.

[Fig. 645.

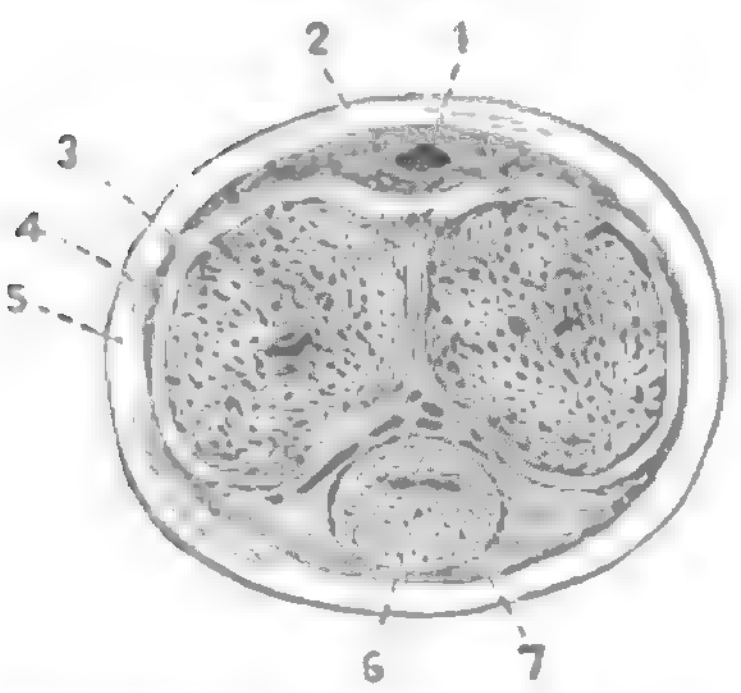

Cross-section of Penis: 1, Dorsal vein; 2, dorsal arteries; 3, corpus cavernosum; 4, tunica albuginea; 5, skin; 6, corpus spongiosum in its tunica albuginea; 7, urethra (Cruveilhier).]

The *extremity*, or *glans penis*, presents the form of an obtuse cone flattened from above downward. At its summit is a vertical fissure, the orifice of the urethra (*meatus urinarius*); at the back part of this orifice a fold of mucous membrane passes backward to the bottom of a depressed raphé, where it is continuous with the prepuce; this fold is termed the *frænum præputii*. The base of the glans forms a rounded projecting border, the *corona glandis*, and behind the corona is a deep constriction, the *cervix*. Upon both of these numerous small lenticular sebaceous glands are found, the *glandulæ Tysonii odoriferæ*. They secrete a sebaceous matter of very peculiar odor, which probably contains caseine and becomes easily decomposed.

The *body* of the penis is the part between the root and extremity. In the flaccid condition of the organ it is cylindrical, but when erect has a triangular prismatic form with rounded angles, the broadest side being turned upward and called the *dorsum*. It is covered by integument remarkable for its thinness, its dark color, its looseness of connection with the deeper parts of the organ, and its containing no adipose tissue. At the root of the penis the integument is continuous with that upon the pubes and scrotum; and at the neck of the glans it leaves the surface and becomes folded upon itself to form the *prepuce*.

The internal layer of the prepuce is attached behind to the cervix, and approaches in character to a mucous membrane; from the cervix it is reflected over the glans penis, and at the meatus urinarius is continuous with the mucous lining of the urethra.

The mucous membrane covering the glans penis contains no sebaceous glands, but projecting from its free surface are a number of small highly sensitive papillæ.

The penis is composed of a mass of erectile tissue enclosed in three cylindrical fibrous compartments. Of these, two, the *corpora cavernosa*, are placed side by side along the upper part of the organ; the third, or *corpus spongiosum*, encloses the urethra, and is placed below.

The **Corpora cavernosa** form the chief part of the body of the penis. They consist of two fibrous cylindrical tubes, placed side by side and intimately connected along the median line for their anterior three-fourths, whilst at their back part they separate from each other to form two tapering processes, named *crura*, which are connected to the rami of the pubes and ischium. Each crus commences by a blunt-pointed process in front of the tuberosity of the ischium, and near its junction with its fellow presents a slight enlargement, named by Kobelt the *bulb of the corpus cavernosum.* Just beyond this point they become constricted, and retain an equal diameter to their anterior extremity, where they form a single rounded end, which is received into a fossa in the base of the glans penis. A median groove on the upper surface lodges the dorsal vein of the penis, and the groove on the under surface receives the corpus spongiosum. The root of the penis is connected to the symphysis pubis by the suspensory ligament.

Structure.—The corpora cavernosa are surrounded by a strong fibrous envelope consisting of two sets of fibres; the one, internal, being circular in direction, and being proper to each corpus cavernosum; the other, longitudinal in direction, being common to the two corpora cavernosa and investing them in a common covering. The internal circular fibres by their junction at one part form an incomplete partition or septum between the two bodies. This fibrous investment is extremely dense, of considerable thickness, and consists of bundles of shining white fibres, with an admixture of well-developed elastic fibres, so that it is possessed of great elasticity.

The *septum* between the two corpora cavernosa forms an imperfect partition; it is thick and complete behind, but in front it is incomplete, and consists of a number of vertical bands which are arranged like the teeth of a comb, whence the name which it has received, *septum pectiniforme.* These bands extend between the dorsal and the urethral surface of the corpora cavernosa.

From the internal surface of the fibrous envelope, as well as from the sides of the septum, are given off a number of bands or cords which cross the interior of the corpora cavernosa in all directions, subdividing them into a number of separate compartments and giving the entire structure a spongy appearance. These bands and cords are called *trabeculæ,* and consist of white fibrous tissue, elastic fibres, and plain muscular fibres. In them are contained numerous arteries and nerves.

The component fibres of which the trabeculæ are composed are larger and stronger round the circumference than at the centre of the corpora cavernosa; they are also thicker behind than in front. The interspaces, on the contrary, are larger at the centre than at the circumference, their long diameter being directed transversely; they are largest anteriorly. They are occupied by venous blood, and are lined by a layer of flattened cells similar to the endothelial lining of veins.

The whole of the structure of the corpora cavernosa contained within the fibrous sheath consists, therefore, of a sponge-like tissue of areolar spaces freely communicating with each other and filled with venous blood. The spaces may therefore be regarded as large cavernous veins.

The arteries bringing the blood to these spaces are the arteries of the corpora cavernosa and branches from the dorsal artery of the penis, which perforate the fibrous capsule along the upper surface, especially near the fore part of the organ. These arteries on entering the cavernous structure divide into branches, which are supported and enclosed by the trabeculæ. Some of these terminate in a capillary network, the branches of which open directly into the cavernous spaces; others assume a tendril-like appearance, and form convoluted and somewhat dilated vessels, which were named by Müller *helicene arteries.* They project into the spaces, and from them are given off small capillary branches to supply the trabecular structure. They are bound down in the spaces by fine fibrous processes, and are more abundant in the back part of the corpora cavernosa.

The blood from the cavernous spaces is returned by a series of vessels, some of which emerge in considerable numbers from the base of the glans penis, and converge on the dorsum of the organ to form the dorsal vein; others pass out on the upper surface of the corpora cavernosa and join the dorsal vein; some emerge from the under surface of the corpora cavernosa, and, receiving branches from the corpus spongiosum, wind round the sides of the penis to terminate in the dorsal vein; but the greater number pass out at the root of the penis and join the prostatic plexus and pudendal veins (Fig. 646).

The **Corpus spongiosum** encloses the urethra, and is situated in the groove on the under surface of the corpora cavernosa. It commences posteriorly in front of the deep perineal fascia, between the diverging crura of the corpora cavernosa, where it forms a rounded enlargement, the *bulb*, and terminates anteriorly in another expansion, the *glans penis*, which overlaps the anterior rounded extremity of the corpora cavernosa. The central portion or body of the corpus spongiosum is cylindrical and tapers slightly from behind forward.

Fig. 646.

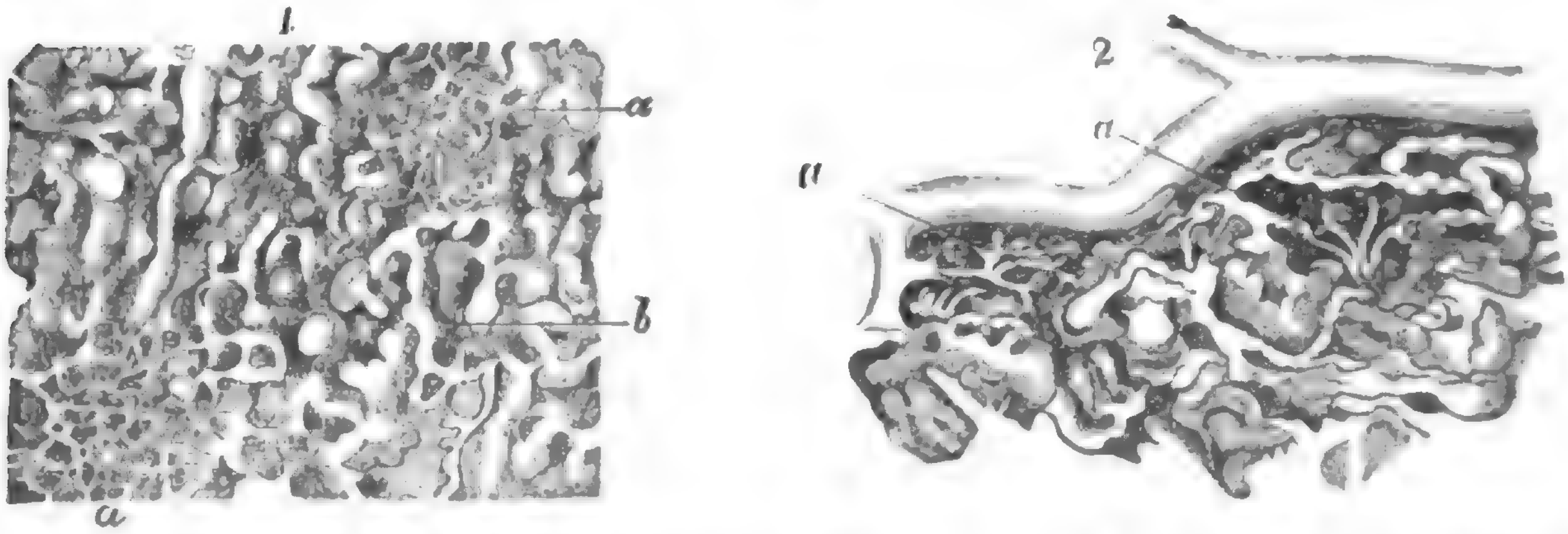

From the Peripheral Portion of the Corpus Cavernosum Penis, under a low magnifying power (copied from Langer): 1, *a*, capillary network; *b*, cavernous spaces; 2, connection of the arterial twigs (*a*) with the cavernous spaces.

The *bulb* varies in size in different subjects; it receives a fibrous investment from the anterior layer of the deep perineal fascia, and is surrounded by the Accelerator urinæ muscle. The urethra enters the bulb nearer its upper than its lower surface, being surrounded by a layer of erectile tissue, a thin prolongation of which is continued backward round the membranous and prostatic portions of the canal to the neck of the bladder, lying between the two layers of muscular tissue. The portion of the bulb below the urethra presents a partial division into two lobes, being marked externally by a linear raphé, whilst internally there projects inward for a short distance a thin fibrous septum more distinct in early life.

Structure.—The corpus spongiosum consists of a strong fibrous envelope enclosing a trabecular structure which contains in its meshes erectile tissue. The fibrous envelope is thinner, whiter in color, and more elastic than that of the corpus cavernosum. The trabeculæ are delicate, uniform in size, and the meshes between them small, their long diameter for the most part corresponding with that of the penis. A thin layer of muscular fibres, continuous behind with those of the bladder, forms part of the outer coat of the corpus spongiosum, and a second layer of muscular tissue is found immediately beneath the mucous membrane of the urethra.

The *lymphatics* of the penis consist of a superficial and deep set; the former are derived from a dense network on the skin of the glans and prepuce and from the mucous membrane of the urethra, and terminate in the inguinal glands; the latter emerge from the corpora cavernosa and corpus spongiosum, and, passing beneath the pubic arch, join the deep lymphatics of the pelvis.

The *nerves* are derived from the internal pudic nerve and the hypogastric plexus. On the glans and bulb some filaments of the cutaneous nerves have Pacinian bodies connected with them, and, according to Krause, many of them terminate in a peculiar form of end-bulb.

THE TESTES AND THEIR COVERINGS (Fig. 647).

The testes are two small glandular organs which secrete the semen; they are situated in the scrotum, being suspended by the spermatic cords. At an early period of fœtal life the testes are contained in the abdominal cavity behind the peritoneum. Before birth they descend to the inguinal canal, along which they pass with the spermatic cord, and, emerging at the external abdominal ring, they descend into the scrotum, becoming invested in their course by numerous coverings derived from the serous, muscular, and fibrous layers of the abdominal parietes, as well as by the scrotum. The coverings of the testis are the

FIG. 647.

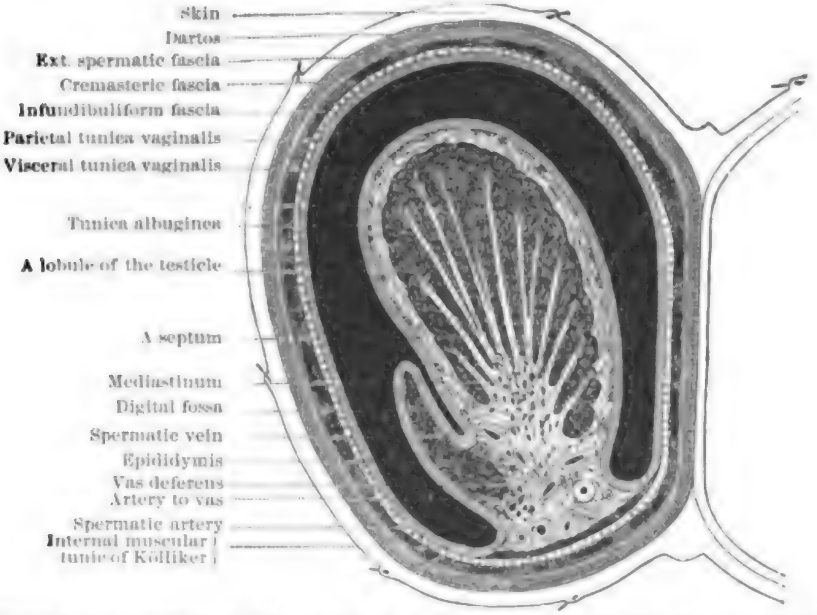
Skin
Dartos
Ext. spermatic fascia
Cremasteric fascia
Infundibuliform fascia
Parietal tunica vaginalis
Visceral tunica vaginalis
Tunica albuginea
A lobule of the testicle
A septum
Mediastinum
Digital fossa
Spermatic vein
Epididymis
Vas deferens
Artery to vas
Spermatic artery
Internal muscular tunic of Kölliker

Transverse Section through the Left Side of the Scrotum and the Left Testicle, the sac of the tunica vaginalis represented in a distended condition (Délépine).

Skin } Scrotum.
Dartos }
Intercolumnar or External spermatic fascia.
Cremasteric fascia.
Infundibuliform or Fascia propria (Internal spermatic fascia).
Tunica vaginalis.

The Scrotum is a cutaneous pouch which contains the testes and part of the spermatic cords. It is divided into two lateral halves by a median line or raphé which is continued forward to the under surface of the penis and backward along the middle line of the perineum to the anus. Of these two lateral portions, the left is longer than the right, and corresponds with the greater length of the spermatic cord on the left side. Its external aspect varies under different circumstances: thus, under the influence of warmth and in old and debilitated persons it becomes elongated and flaccid, but under the influence of cold and in the young and robust it is short, corrugated, and closely applied to the testes.

The scrotum consists of two layers, the integument and the dartos.

The **integument** is very thin, of a brownish color, and generally thrown into folds or rugæ. It is provided with sebaceous follicles, the secretion of which has a peculiar odor, and is beset with thinly-scattered, crisp hairs, the roots of which are seen through the skin.

The **dartos** is a thin layer of loose reddish tissue endowed with contractility; it forms the proper tunic of the scrotum, is continuous around the base of the scrotum with the superficial fascia of the groin, perineum, and inner side of the thighs, and sends inward a distinct septum, *septum scroti*, which divides it into two cavities for the two testes, the septum extending between the raphé and the under surface of the penis as far as its root.

The dartos is closely united to the skin externally, but connected with the subjacent parts by delicate areolar tissue, upon which it glides with the greatest facility. The dartos is very vascular, and consists of a loose areolar tissue containing unstriped muscular fibre, but no fat. Its contractility is slow and excited by cold and mechanical stimuli, but not by electricity.

The **intercolumnar fascia** is a thin membrane derived from the margin of the pillars of the external abdominal ring during the descent of the testis in the fœtus, which is prolonged downward around the surface of the cord and testis. It is separated from the dartos by loose areolar tissue, which allows of considerable movement of the latter upon it, but is intimately connected with the succeeding layers.

The **cremasteric fascia** consists of scattered bundles of muscular fibres (*Cremaster muscle*) connected together into a continuous covering by intermediate areolar tissue. The muscular fibres are derived from the lower border of the internal oblique muscle during the descent of the testis (p. 994).

The **fascia propria** is a thin membranous layer which loosely invests the surface of the cord. It is a continuation downward of the infundibuliform process of the fascia transversalis, and is also derived during the descent of the testis in the fœtus.

The **tunica vaginalis** is described with the proper covering of the testis. (A more detailed account of the other coverings of the testis will be found in the description of the Surgical Anatomy of Inguinal Hernia.)

VESSELS AND NERVES.—The *arteries* supplying the coverings of the testis are —the superficial and deep external pudic from the femoral, the superficial perineal branch of the internal pudic, and the cremasteric branch from the epigastric. The *veins* follow the course of the corresponding arteries. The *lymphatics* terminate in the inguinal glands. The *nerves* are—the ilio-inguinal branch of the lumbar plexus, the two superficial perineal branches of the internal pudic nerve, the inferior pudendal branch of the small sciatic nerve, and the genital branch of the genito-crural nerve.

The **Spermatic Cord** extends from the internal abdominal ring, where the structures of which it is composed converge, to the back part of the testicle. It is composed of arteries, veins, lymphatics, nerves, and the excretory duct of the testicle. These structures are connected together by areolar tissue, and invested by the fasciæ brought down by the testicle in its descent. In the abdominal wall the cord passes obliquely along the inguinal canal, lying at first beneath the Internal oblique and upon the fascia transversalis; but nearer the pubes it rests upon Poupart's ligament, having the aponeurosis of the External oblique in front of it and the conjoined tendon behind it. It then escapes at the external ring and descends nearly vertically into the scrotum. The left cord is rather longer than the right, consequently the left testis hangs somewhat lower than its fellow.

The *arteries of the cord* are—the spermatic, from the aorta; the artery of the vas deferens, from the superior vesical: and the cremasteric, from the deep epigastric artery.

The spermatic artery supplies the testicle. On approaching the gland it gives off some branches which supply the epididymis, and others which perforate the tunica albuginea behind and spread out on its inner surface, or pass through the fibrous septum in its interior to be distributed on the membranous septa between the lobes.

The artery of the vas deferens is a long slender vessel which accompanies the vas deferens, ramifying upon the coats of that duct and anastomosing with the spermatic artery near the testis.

The cremasteric branch from the epigastric supplies the Cremaster muscle and other coverings of the cord.

The *spermatic veins* leave the back part of the testis, and, receiving branches from the epididymis, unite to form a plexus (*pampiniform plexus*) which forms the chief mass of the cord. They pass up in front of the vas deferens, and unite to form a single trunk, which terminates on the right side in the inferior vena cava, on the left side in the left renal vein.

The *lymphatics* are of large size, accompany the blood-vessels, and terminate in the lumbar glands.

The *nerves* are the spermatic plexus from the sympathetic. This plexus is derived from the renal and aortic plexuses, joined by filaments from the hypogastric plexus which accompany the artery of the vas deferens.

TESTES.

The **Testes** are suspended in the scrotum by the spermatic cords. Each gland is of an oval form, compressed laterally and having an oblique position in the scrotum; the upper extremity being directed forward and a little outward; the lower, backward and a little inward; the anterior convex border looks forward and downward; the posterior or straight border, to which the cord is attached, backward and upward.

FIG. 648.

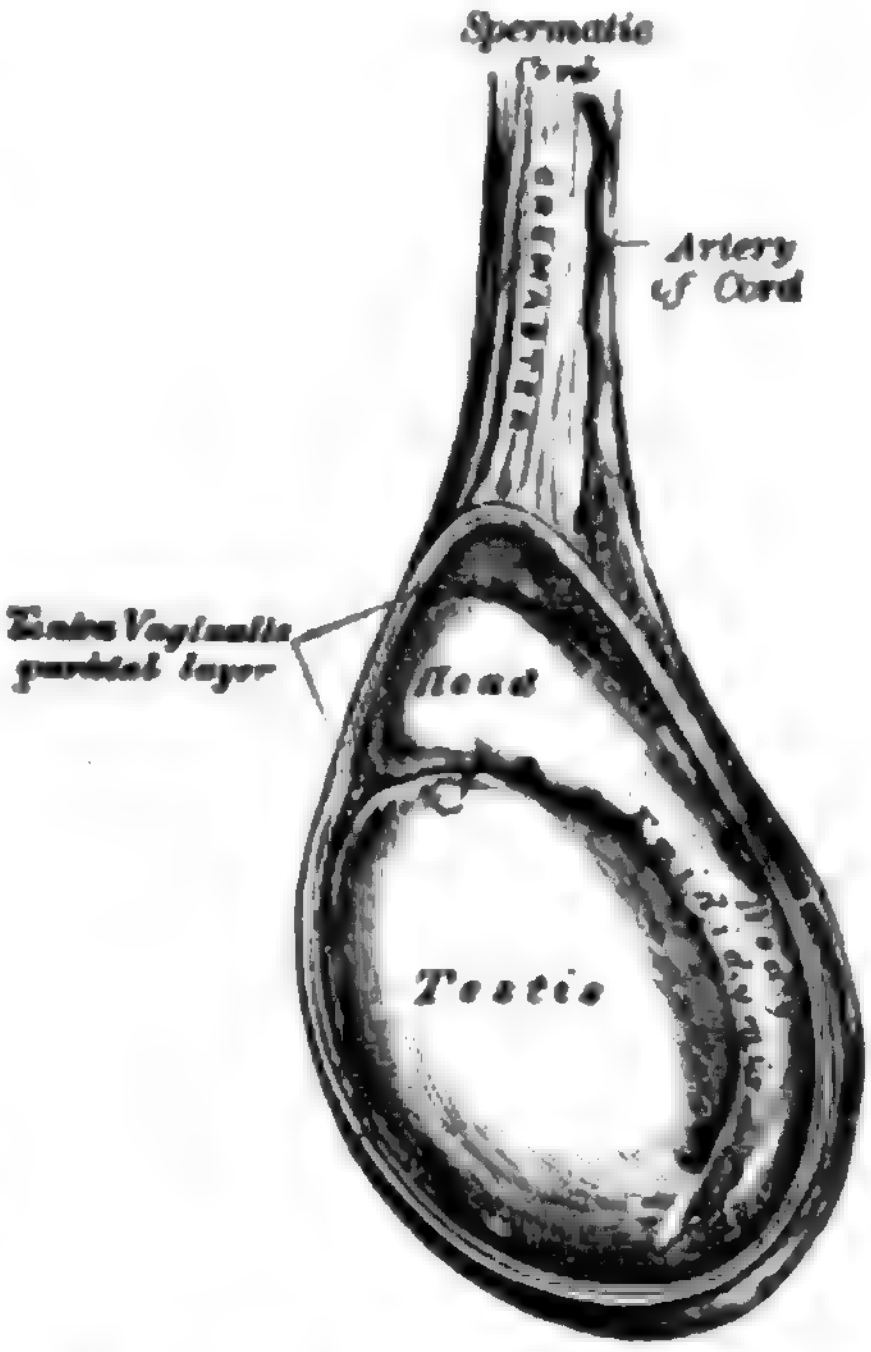

The Testis *in situ*, the tunica vaginalis having been laid open.

The anterior and lateral surfaces, as well as both extremities of the organ, are convex, free, smooth, and invested by the tunica vaginalis. The posterior border, to which the cord is attached, receives only a partial investment from that membrane. Lying upon the outer edge of this border is a long, narrow, flattened body, named, from its relation to the testis, the epididymis (δίδυμος, testis). It consists of a central portion, or *body*; an upper enlarged extremity, the *globus major*, or head; and a lower pointed extremity, the tail, or *globus minor*. The globus major is intimately connected with the upper end of the testicle by means of its efferent ducts; and the globus minor is connected with its lower end by cellular tissue and a reflection of the tunica vaginalis. The outer surface and upper and lower ends of the epididymis are free and covered by serous membrane; the body is also completely invested by it, excepting along its inner border, where it is connected to the back of the testis by a fold of the serous membrane. Attached to the upper end of the testis or to the epididymis are one or more small pedunculated bodies. One of them is pretty constantly found between the globus major of the epididymis and the testicle, and is believed to be the remains of the upper extremity of the Müllerian duct (p. 135). They are termed the hydatids of Morgagni. When the testicle is removed from the body the position of the vas deferens on the posterior and inner side of the epididymis marks the side to which the gland has belonged.

Size and Weight.—The average dimensions of this gland are from one and a half to two inches in length, one inch in breadth, and an inch and a quarter in the antero-posterior diameter; and the weight varies from six to eight drachms, the left testicle being a little the larger.

The testis is invested by three tunics—the tunica vaginalis, tunica albuginea, and tunica vasculosa.

The **Tunica Vaginalis** is the serous covering of the testis. It is a pouch of serous membrane derived from the peritoneum during the descent of the testis in the fœtus from the abdomen into the scrotum. After its descent that portion of the pouch which extends from the internal ring to near the upper part of the gland becomes obliterated, the lower portion remaining as a shut sac which invests the outer surface of the testis, and is reflected on to the internal surface of the scrotum; hence it may be described as consisting of a visceral and parietal portion.

The *visceral portion* (*tunica vaginalis propria*) covers the outer surface of the testis as well as the epididymis, connecting the latter to the testis by means of a distinct fold. From the posterior border of the gland it is reflected on to the internal surface of the scrotum.

The *parietal portion* of the serous membrane (*tunica vaginalis reflexa*) is far more extensive than the visceral portion, extending upward for some distance in front and on the inner side of the cord and reaching below the testis. The inner surface of the tunica vaginalis is free, smooth, and covered by a simple epithelial layer of flattened cells. The interval between the visceral and parietal layers of this membrane constitutes the cavity of the tunica vaginalis.

The obliterated portion of the pouch may generally be seen as a fibro-cellular thread lying in the loose areolar tissue around the spermatic cord; sometimes this may be traced as a distinct band from the upper end of the inguinal canal, where it is connected with the peritoneum, down to the tunica vaginalis; sometimes it gradually becomes lost on the spermatic cord. Occasionally no trace of it can be detected. In some cases it happens that the pouch of peritoneum does not become obliterated, but the sac of the peritoneum communicates with the tunica vaginalis. This may give rise to one of the varieties of inguinal hernia (p. 998). Or in other cases the pouch may contract, but not become entirely obliterated; it then forms a minute canal leading from the peritoneum to the tunica vaginalis.[1]

The **Tunica Albuginea** is the fibrous covering of the testis. It is a dense fibrous membrane, of a bluish-white color, composed of bundles of white fibrous tissue, which interlace in every direction. Its outer surface is covered by the tunica vaginalis, except along its posterior border, at the points of attachment of the epididymis; hence the tunica albuginea is usually considered as a fibro-serous membrane, like the pericardium. This membrane surrounds the glandular structure of the testicle, and at its posterior border is reflected into the interior of the gland, forming an incomplete vertical septum called the *mediastinum testis* (*corpus Highmorianum*).

The *mediastinum testis* extends from the upper nearly to the lower border of the gland, and is wider above than below. From the front and sides of this septum numerous slender fibrous cords and imperfect septa (*trabeculæ*) are given off, which radiate toward the surface of the organ and are attached to the inner surface of the tunica albuginea. They therefore divide the interior of the organ into a number of incomplete spaces, which are somewhat cone-shaped, being broad at their bases at the surface of the gland and becoming narrower as they converge to the mediastinum. The mediastinum supports the vessels and ducts of the testis in their passage to and from the substance of the gland.

The **Tunica Vasculosa** (*pia mater testis*) is the vascular layer of the testis, consisting of a plexus of blood-vessels held together by a delicate areolar tissue. It covers the inner surface of the tunica albuginea and the different septa in the interior of the gland, and therefore forms an internal investment to all the spaces of which the gland is composed.

Structure.—The glandular structure of the testis consists of numerous lobules (*lobuli testis*). Their number in a single testis is estimated by Berres at 250, and by Krause at 400. They differ in size according to their position, those in the middle of the gland being larger and longer. The lobules are conical in shape, the base being directed toward the circumference of the organ, the apex toward the mediastinum. Each lobule is contained in one of the intervals between the fibrous cords and vascular processes which extend between the mediastinum testis and the tunica albuginea, and consists of from one to three or more minute convoluted tubes, the *tubuli seminiferi*. The tubes may be separately unravelled by careful dissection under water, and may be seen to commence either by free cæcal ends or by anastomotic loops. The total number of tubes is considered by Munro to be about 300, and the length of each about 16 feet; by Lauth their number is estimated at 840, and their average length 2¼ feet. Their diameter varies from $\frac{1}{200}$th to $\frac{1}{150}$th of an inch. The tubuli are pale in color in early life, but in old age they acquire a deep yellow tinge from containing much fatty matter. They consist of a membrana propria, inside which are several layers of epithelial cells, the *seminal cells.* The membrana propria is a hyaline structure, consisting of several membranous layers containing oval flattened nuclei at regular intervals superimposed on one another. The seminal cells or lining epithelium differs in different tubules. In some tubes they may be seen to consist of an outer layer next the membrana propria, and two or more layers of inner cells. The former cells are more or less polyhedral in shape, uniform in size, and contain an oval or spherical nucleus; the latter cells, those comprising the inner layers, are spherical and more loosely connected together. The nucleus of most or all of them is in the process of indirect division (*karyokinesis,* p. 42), and in consequence of this numerous small spherical daughter-cells are to be seen, lying nearest to the lumen and closely connected together. These small daughter-cells are named *spermatoblasts,* and by a series of changes become converted into spermatozoa. In other tubes the gradual transition of the spermatoblasts into spermatozoa may be traced. In some tubes or parts of tubes the daughter-cells may be seen to have assumed a pear shape, with the pointed end, in which the nucleus is to be found, directed toward the inner seminal cells, while the broad part is directed into the lumen of the tube. In other parts of a tube the broad end may be seen to have become elongated into a rod-shaped body, which constitutes the middle piece of the spermatozoa, while the nucleus forms the head. Again, in other parts of the tubes these young spermatozoa may be seen collected together into fan-shaped groups, and from their distal end—that is to say, the end projecting into the lumen of the tube—a thin long filament, called the tail, is growing out. In the young subject the seminal cells present somewhat the appearance of an epithelial lining, and do not almost fill the tube, as in the adult testis.

---

[1] It is recorded that in the post-mortem examination of Sir Astley Cooper this minute canal was found on both sides of the body. Sir Astley Cooper states that when a student he suffered from inguinal hernia; probably this was of the congenital variety, and the canal found after death was the remains of the one down which the hernia travelled (*Lancet*, vol. ii., 1824, p. 116).

The tubules are enclosed in a delicate plexus of capillary vessels, and are held together by an intertubular connective tissue which presents large interstitial spaces lined by endothelium, which are believed to be the rootlets of the lymphatic vessels of the testis.

In the apices of the lobules the tubuli become less convoluted, assume a nearly straight course, and unite together to form from twenty to thirty large ducts, of about $\frac{1}{50}$th of an inch in diameter, and these, from their straight course, are called *vasa recta.*

The *vasa recta* enter the fibrous tissue of the mediastinum, and pass upward and backward, forming, in their ascent, a close network of anastomosing tubes which are merely channels in the fibrous stroma, having no proper walls; this constitutes the *rete testis.* At the upper end of the mediastinum the vessels of the rete testis terminate in from twelve to fifteen or twenty ducts, the *vasa efferentia:* they perforate the tunica albuginea and carry the seminal fluid from the testis to the epididymis. Their course is at first straight; they then become enlarged and exceedingly convoluted, and form a series of conical masses, the *coni vasculosi,* which together constitute the globus major of the epididymis. Each cone consists of a single convoluted duct from six to eight inches in length, the diameter of which gradually decreases from the testis to the epididymis. Opposite the bases of the cones the efferent vessels open at narrow intervals into a single duct, which constitutes by its complex convolutions the body and globus minor of the epididymis. When the convolutions of this tube are unravelled it measures upward of twenty feet in length, and increases in breadth and thickness as it approaches the vas deferens. The convolutions are held together by fine areolar tissue and by bands of fibrous tissue. A long narrow tube, the *vas aberrans* of Haller, is occasionally found connected with the lower part of the canal of the epididymis or with the commencement of the vas deferens. It extends up into the cord for about two or three inches, where it terminates by a blind extremity, which is occasionally bifurcated. Its length varies from an inch and a half to fourteen inches, and sometimes it becomes dilated toward its extremity: more commonly it retains the same diameter throughout. Its structure is similar to that of the vas deferens. Occasionally it is found unconnected with the epididymis.

FIG. 649.

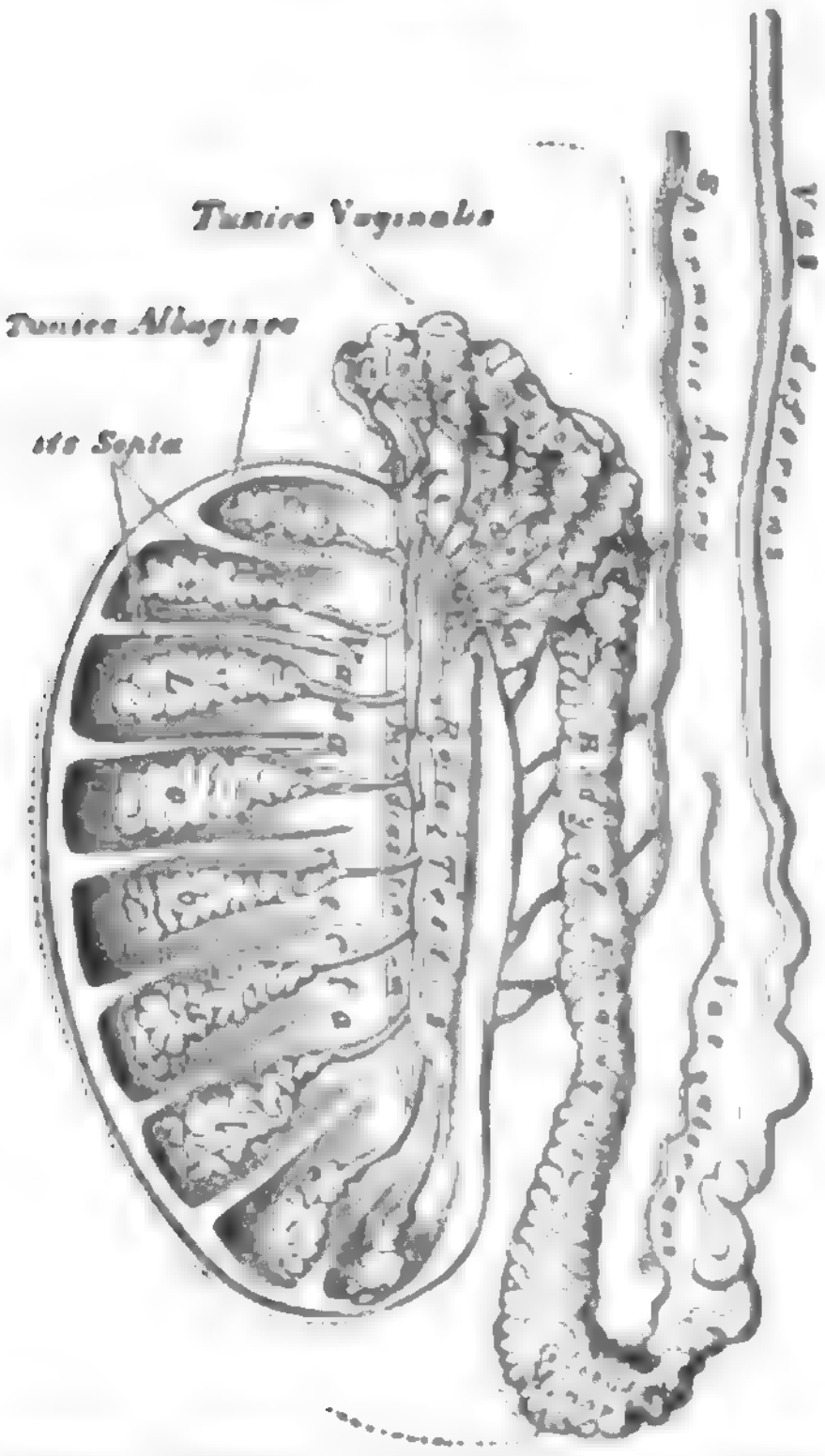

Vertical Section of the Testicle, to show the Arrangement of the Ducts.

The vasa recta are of smaller diameter than the seminal tubes, and have very thin parietes. They as well as the channels of the rete testis are lined by a single layer of flattened epithelium. The vasa efferentia and the tube of the epididymis have walls of considerable thickness, on account of the presence in them of muscular tissue, which is principally arranged in a circular manner. These tubes are lined by columnar ciliated epithelium.

The **Vas Deferens** [Figs. 639, p. 956, 649, and 682, p. 1022], the excretory duct of the testis, is the continuation of the epididymis. Commencing at the lower part of the globus minor, it ascends along the posterior and inner side of the testis and epididymis, and along the back part of the spermatic cord, through the spermatic canal, to the internal abdominal ring. From the ring it descends into the pelvis, crossing the external iliac vessels, and curves round the outer side of the deep epigastric artery: at the side of the bladder it arches backward and downward to its base, crossing over the obliterated hypogastric artery and to the inner side of the ureter. At the base of the bladder it lies between that viscus and the rectum, running along the inner border of the vesicula seminalis. In this situation it becomes enlarged and sacculated, and then, becoming narrowed at the base of the prostate, unites with the duct of the vesicula seminalis to form the ejaculatory duct. The vas deferens presents a hard and cord-like sensation to the fingers; it is about two feet in length, of cylindrical form, and about a line and a quarter in diameter. Its walls are dense, measuring one-third of a line, and its canal is extremely small, measuring about half a line.

Structure.—The vas deferens consists of three coats: 1, an external or cellular coat; 2, a muscular coat, which in the greater part of the tube consists of two layers of unstriped muscular fibre—an outer, longitudinal in direction, and an inner, circular; but in addition to these at the commencement of the vas deferens there is a third layer, consisting of longitudinal fibres placed internal to the circular stratum, between it and the mucous membrane; 3, an internal or mucous coat, which is pale and arranged in longitudinal folds; its epithelial covering is of the columnar variety.

VESICULÆ SEMINALES.

The **Seminal Vesicles** are two lobulated membranous pouches placed between the base of the bladder and the rectum, serving as reservoirs for the semen, and secreting a fluid to be added to the secretion of the testicles. Each sac is somewhat pyramidal in form, the broad end being directed backward and the narrow end forward toward the prostate. They measure about two and a half inches in length, about five lines in breadth, and two or three lines in thickness. They vary, however, in size, not only in different individuals, but also in the same individual on the two sides. Their *upper surface* is in contact with the base of the bladder, extending from near the termination of the ureters to the base of the prostate gland. Their *under surface* rests upon the rectum, from which they are separated by the recto-vesical fascia. Their *posterior extremities* diverge from each other. Their *anterior extremities* are pointed, and converge toward the base of the prostate gland, where each joins with the corresponding vas deferens to form the ejaculatory duct. Along the inner margin of each vesicula runs the enlarged and convoluted vas deferens. The inner border of the vesiculæ and the corresponding vas deferens form the lateral boundary of a triangular space limited behind by the recto-vesical peritoneal fold; the portion of the bladder included in this space rests on the rectum and corresponds with the trigonum vesicæ in its interior. [If the finger in the rectum reach beyond the prostate, the vesiculæ seminales and the trigonum may be defined by touch.]

Fig. 650.

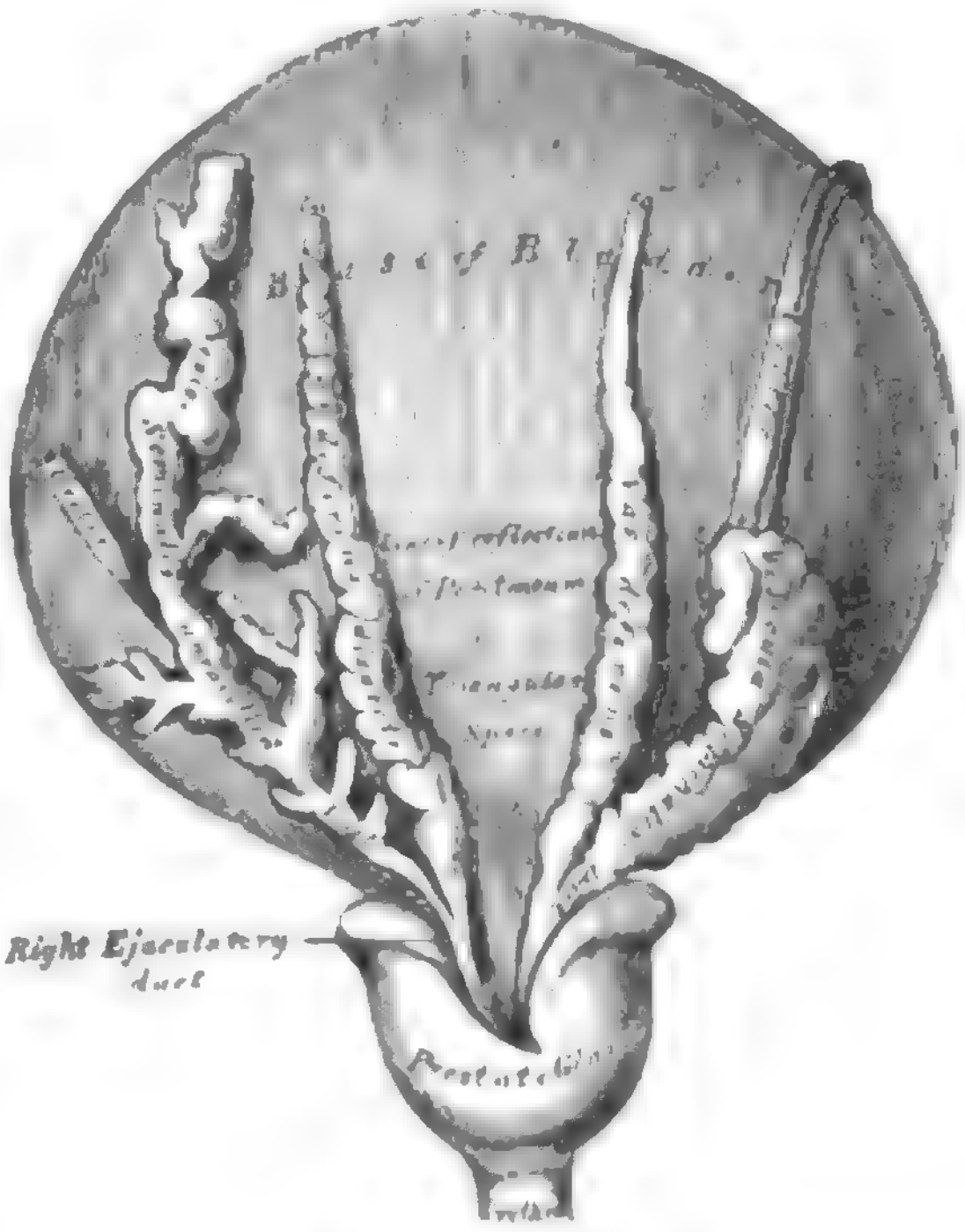

Base of the Bladder, with the Vasa Deferentia and Vesiculæ Seminales.

Each vesicula consists of a single tube coiled upon itself and giving off several irregular cæcal diverticula, the separate coils, as well as the diverticula, being connected together by fibrous tissue. When uncoiled this tube is about the diameter of a quill, and varies in length from four to six inches; it terminates posteriorly in a cul-de-sac; its anterior extremity becomes constricted into a narrow straight duct, which joins on its inner side with the corresponding vas deferens and forms the ejaculatory duct.

The **Ejaculatory Ducts,** two in number, one on each side, are formed by the junction of the duct of the vesicula seminalis with the vas deferens. Each duct is about three-quarters of an inch in length; it commences at the base of the prostate, and runs forward and upward in a canal in its substance and along the side of the sinus pocularis to terminate by a separate slit-like orifice close to or just within the margins of the sinus. The ducts diminish in size and converge toward their termination.

Structure.—The vesiculæ seminales are composed of three coats: an *external* or *fibro-cellular*, derived from the recto-vesical fascia; a *middle* or *muscular coat*, which is thinner than in the vas deferens: the muscular fibres are arranged in three layers, consisting of an inner and outer longitudinal stratum and an intermediate layer of circular fibres; and an *internal* or *mucous coat*, which is pale, of a whitish-brown color, and presents a delicate reticular structure, like that seen in the gall-bladder, but the meshes are finer. The epithelium is columnar.

The coats of the ejaculatory ducts are extremely thin; an outer fibrous layer, which is almost entirely lost after their entrance into the prostate; a layer of muscular fibres, consisting of an outer thin circular and an inner longitudinal layer; and the mucous membrane, forming the only constituents of the tubes.

VESSELS AND NERVES.—The *arteries* supplying the vesiculæ seminales are derived from the inferior vesical and middle hemorrhoidal. The *veins* and *lymphatics* accompany the arteries. The *nerves* are derived from the pelvic plexus.

The **Semen** is a thick, whitish fluid having a peculiar odor. It consists of a fluid, the *liquor seminis*, and solid particles, the *seminal granules* and *spermatozoa*.

The *liquor seminis* is transparent, colorless, and of an albuminous composition, containing particles of squamous and columnar epithelium, with oil-globules and granular matter floating in it, besides the above-mentioned solid elements.

The *seminal granules* are round, finely-granular corpuscles, measuring $\frac{1}{4000}$th of an inch in diameter.

The *spermatozoa*, or spermatic filaments, are the essential agents in producing fecundation. They consist of a flattened oval *head* (the nucleus of the original spermatoblast), of a rod-shaped *middle piece*, and [of] a long slender caudal filament or *tail.* The movements of these bodies are remarkable, and consist of a lashing or undulatory motion of the tail.

DESCENT OF THE TESTES.

The testes at an early period of fœtal life are placed at the back part of the abdominal cavity, behind the peritoneum, in front and a little below the kidneys. The anterior surface and sides are invested by peritoneum: the blood-vessels and efferent ducts are connected with their posterior surface: and attached to the lower end is a peculiar structure, the *gubernaculum testis*, which is said to assist in their descent.

The **Gubernaculum Testis** [was first described and named by John Hunter. It appears at the third month of intra-uterine life, and] attains its full development between the fifth and sixth months: it is a conical-shaped cord attached above to the lower end of the epididymis and below to the bottom of the scrotum. [Mr. C. B. Lockwood[1] states that at the sixth to the eighth month of intra-uterine life many of the lower fibres extend into Scarpa's triangle, the perineum, etc., and may thus explain the occasional presence of the testicle in these regions.] It is placed behind the peritoneum, lying upon the front of the Psoas muscle and completely filling the inguinal canal. It consists of a soft, transparent areolar tissue within, which often appears partially hollow, surrounded by a layer of striped muscular fibres, which ascends upon this body to be attached to the testis. According to Mr. Curling, the gubernaculum as well as these muscular fibres divides below into three processes: the

[Fig. 651.

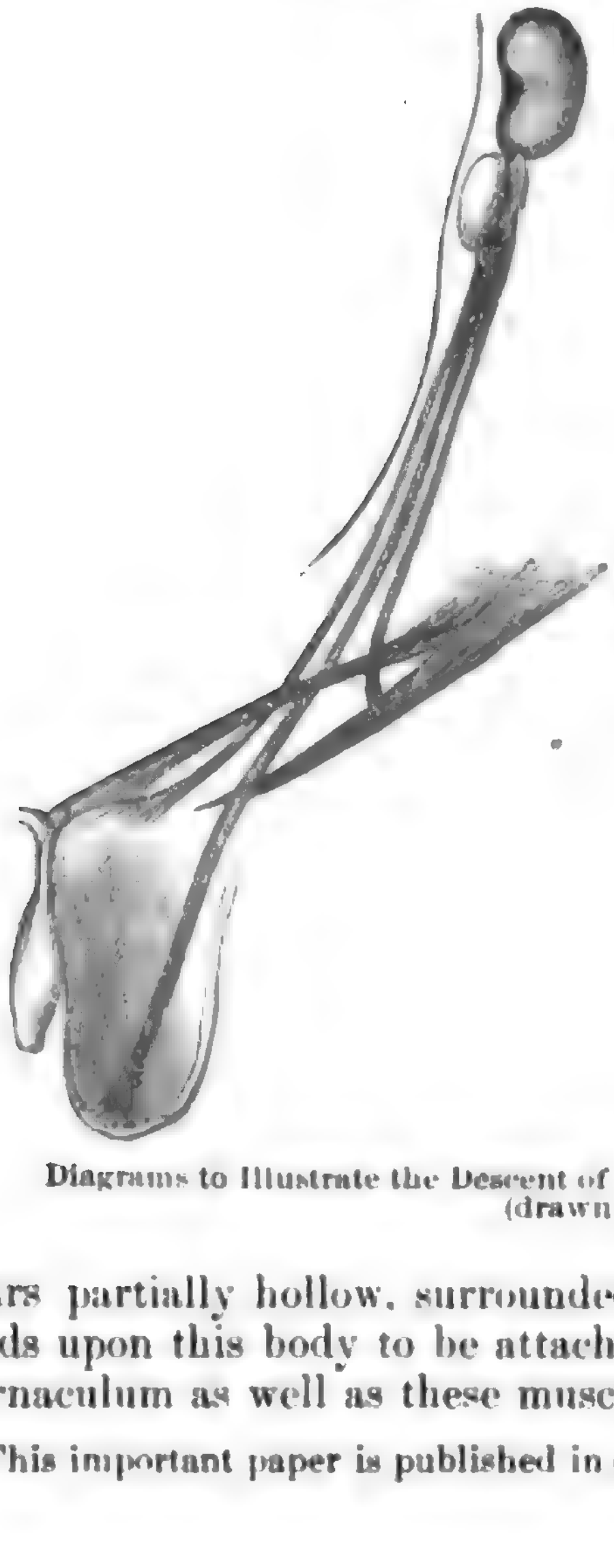

[Fig. 652.

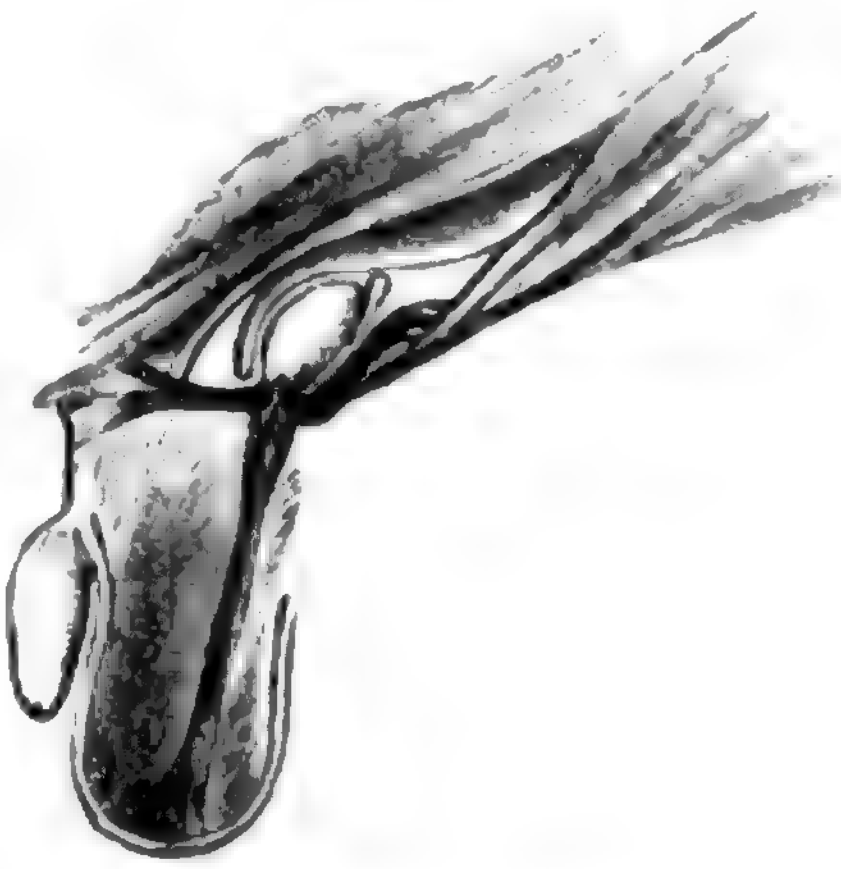

[Fig. 653.

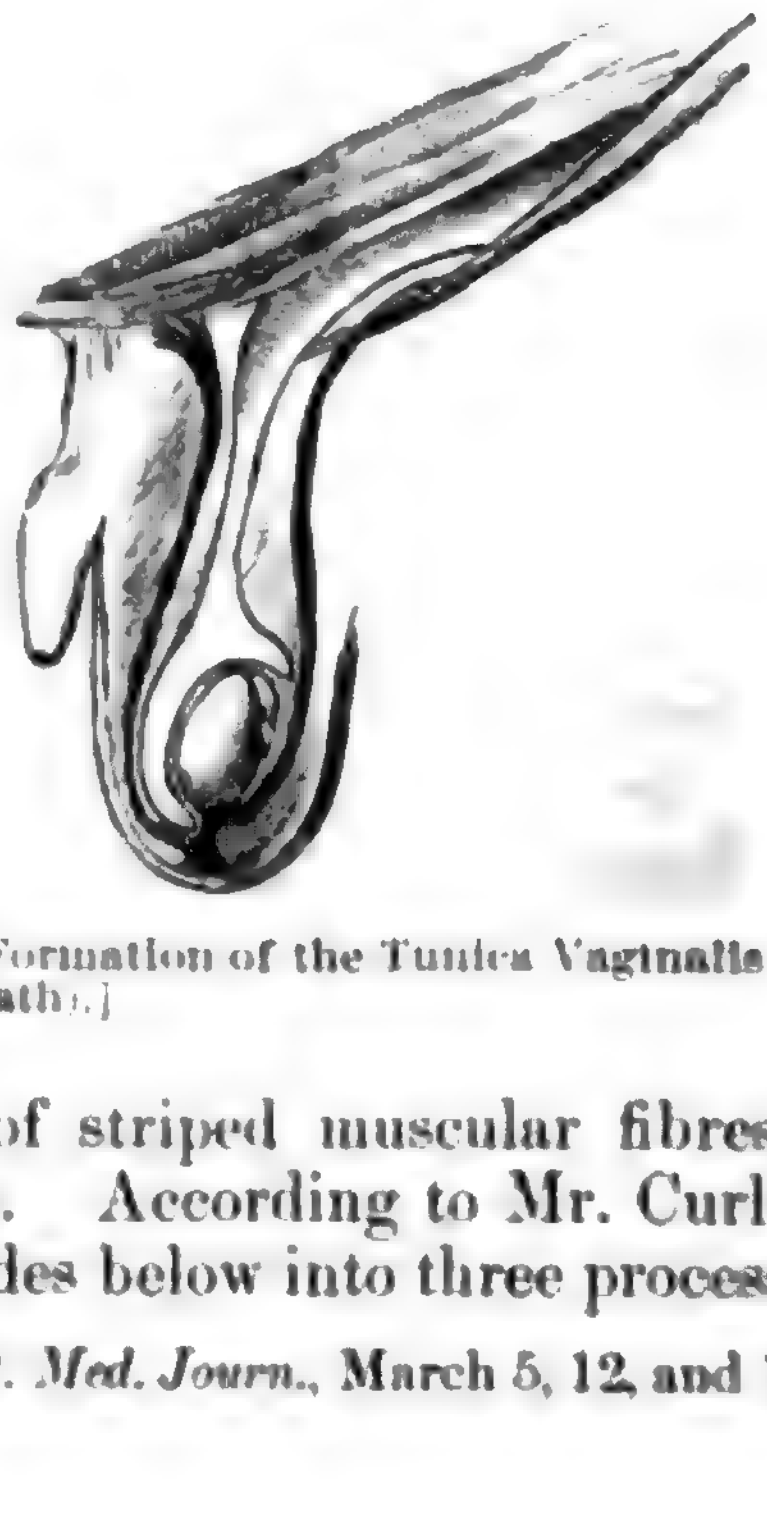

Diagrams to Illustrate the Descent of the Testis and the Formation of the Tunica Vaginalis (drawn by J. T. Gray).—(Heath.)]

---

[1] This important paper is published in outline in the *Brit. Med. Journ.*, March 5, 12, and 19, 1887.]

external and broadest process is connected with Poupart's ligament in the inguinal canal; the middle process descends along the inguinal canal to the bottom of the scrotum, where it joins the dartos; the internal one is firmly attached to the os pubis and sheath of the Rectus muscle; some fibres, moreover, are reflected from the Internal oblique on to the front of the gubernaculum. Up to the fifth month the testis is situated in the lumbar region, covered in front and at the sides by peritoneum, and supported in its position by a fold of that membrane, called the *mesorchium;* between the fifth and sixth months the testis descends to the iliac fossa, the gubernaculum at the same time becoming shortened; during the seventh month it enters the internal abdominal ring, a small pouch of peritoneum (*processus vaginalis*) preceding the testis in its course through the canal [which explains how a hydrocele may exist with an undescended testicle (Allis)]. By the end of the eighth month the testis has descended into the scrotum, carrying down with it a lengthened pouch of peritoneum, which communicates by its upper extremity with the peritoneal cavity. Just before birth the upper part of the pouch usually becomes closed, and this obliteration extends gradually downward to within a short distance of the testis. The process of peritoneum surrounding the testis, which is now entirely cut off from the peritoneal cavity, constitutes the *tunica vaginalis.*[1]

Mr. Curling believes that the descent of the testis is effected by means of the muscular fibres of the gubernaculum; those fibres which proceed from Poupart's ligament and the Obliquus internus are said to guide the organ into the inguinal canal; those attached to the pubes draw it below the external abdominal ring; and those attached to the bottom of the scrotum complete its descent.[2] During the descent of the organ these muscular fibres become gradually everted, forming a muscular layer which becomes placed external to the process of the peritoneum, surrounding the gland and spermatic cord, and constitutes the Cremaster. In the female a small cord, corresponding to the gubernaculum in the male, descends to the inguinal region, and ultimately forms the round ligament of the uterus. A pouch of peritoneum accompanies it along the inguinal canal, analogous to the processus vaginalis in the male: it is called the *canal of Nuck.*

[The **Cremaster** is wrongly described as the lower fibres of the Internal oblique, on which the testicle catches in its descent, and pulls them down. As a matter of fact, some of these looping fibres of the Cremaster extend upward along the gubernaculum while the testis is in the abdomen, and long before the testis reaches the inguinal canal other muscular fibres of the abdominal wall may be seen looping downward toward the scrotum.]

---

[1] The obliteration of the process of peritoneum which accompanies the cord, and is hence called the *funicular process,* is often incomplete. (For an account of the various conditions produced by such incomplete obliteration, which are of great importance in the pathological anatomy of inguinal hernia, the student is referred to the "Essay on Hernia," by Mr. Birkett, in *A System of Surgery,* edited by T. Holmes, vol. iv.)

[2] Cleland denies that the gubernaculum is the agent by which the change in the position of the testis is effected. (For an interesting résumé of the various views which have been held with regard to the descent of the testis, see *Mechanism of the Gubernaculum Testis,* by Cleland, Edinburgh, 1856.)

Female Organs of Generation.

THE **external Organs of Generation** in the female are the mons Veneris, the labia majora and minora, the clitoris, the meatus urinarius, and the orifice of the vagina. The term "vulva" or "pudendum," as generally applied, includes all these parts.

The **mons Veneris** is the rounded eminence in front of the pubes formed by a collection of fatty tissue beneath the integument. It surmounts the vulva and becomes covered with hair at the time of puberty.

The **Labia majora** [1] are two prominent longitudinal cutaneous folds extending downward from the mons Veneris to the anterior boundary of the perineum, and enclosing an elliptical fissure, the common urino-sexual opening. Each labium is formed externally of integument covered with hair; internally, of mucous membrane, which is continuous with the genito-urinary mucous tract; and, between the two, of a considerable quantity of areolar tissue, fat, and a tissue resembling the dartos of the scrotum, besides vessels, nerves, and glands. The labia are thicker in front than behind, and joined together at each extremity, forming the anterior and posterior commissures. The interval left between the posterior commissure and the margin of the anus is about an inch in length, and constitutes the perineum. Just within the posterior commissure is a small transverse fold, the *frænulum pudendi* or *fourchette*, which is commonly ruptured in the first parturition, and the space between it and the commissure is called the *fossa navicularis*. The labia are analogous to the scrotum in the male.

FIG. 654.

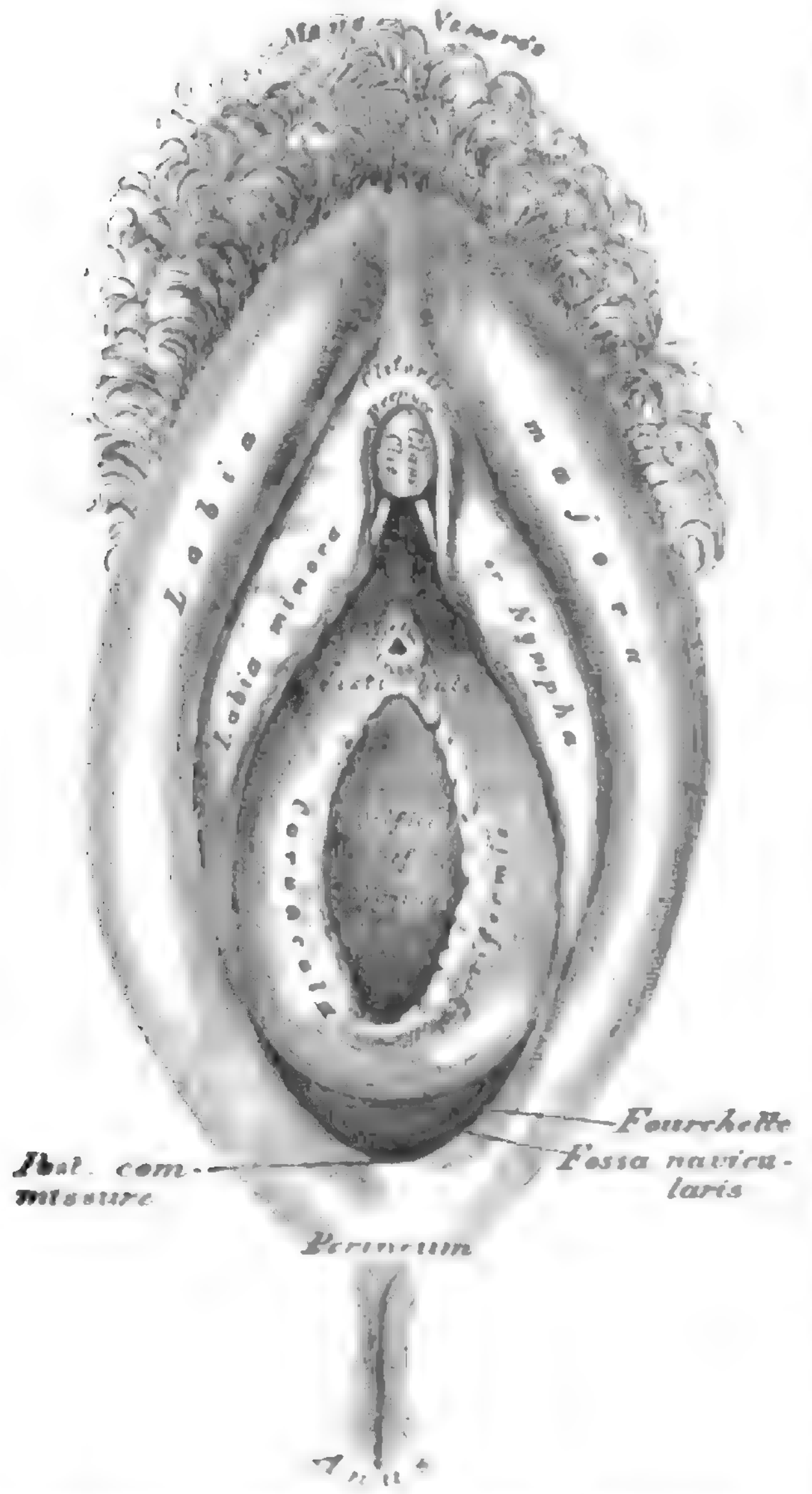

The Vulva, external Female Organs of Generation.

The **Labia minora** [1] or **Nymphæ** are two small folds of mucous membrane situated within the labia majora, extending from the clitoris obliquely downward and outward for about an inch and a half on each side of the orifice of the vagina, on the sides of which they are lost. They are continuous externally with the labia majora, internally with the inner surface of the vagina. As they converge toward the clitoris in front each labium divides into two folds, which surround the glans clitoridis, the superior folds uniting to form the præputium clitoridis, the inferior folds being attached to the glans and forming the frænum. The nymphæ are composed of mucous membrane, covered by a thin epithelial layer. They contain a plexus of vessels in their interior, and are pro-

---

[1 In the singular number "labium majus" and "minus."]

vided with numerous large mucous crypts which secrete abundance of sebaceous matter.

The **Clitoris** is an erectile structure analogous to the corpora cavernosa of the penis. [It differs from the penis in having no corpus spongiosum and no urethra.] It is situated beneath the anterior commissure, partially hidden between the anterior extremities of the labia minora. It is an elongated organ, connected to the rami of the pubes and ischia on each side by a crus; the body is short and concealed beneath the labia; the free extremity, or *glans clitoridis*, is a small rounded tubercle consisting of spongy erectile tissue and highly sensitive. The clitoris consists of two corpora cavernosa, composed of erectile tissue enclosed in a dense layer of fibrous membrane, united together along their inner surfaces by an incomplete fibrous pectiniform septum. It is provided, like the penis, with a suspensory ligament and with two small muscles, the Erectores clitoridis, which are inserted into the crura of the corpora cavernosa.

FIG. 655.

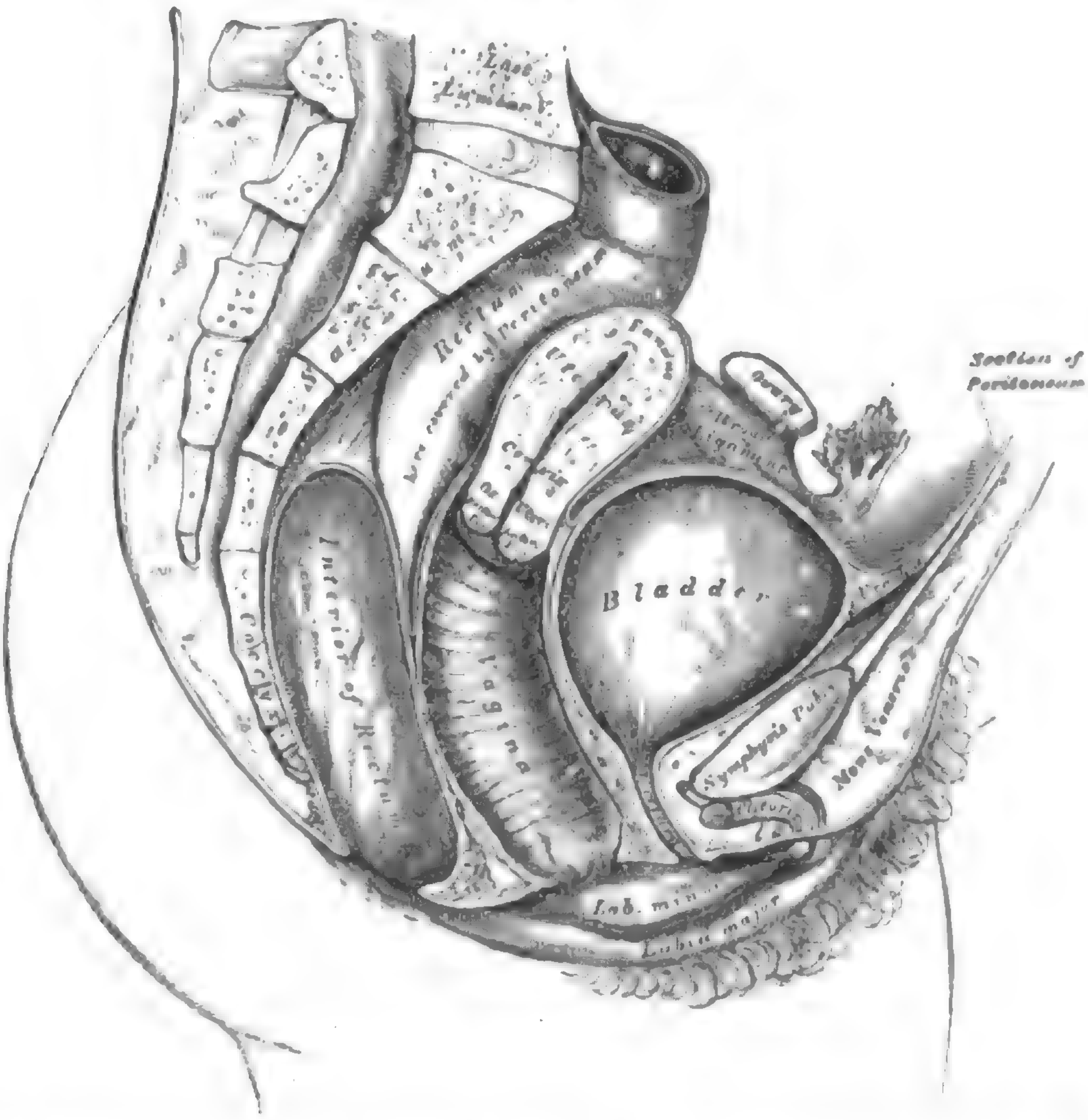
Last Lumbar V.
Rectum covered by Peritoneum
Fundus
Ovary
Section of Peritoneum
Broad Ligament
Cervix
Bladder
Interior of Rectum
Coccyx
Vagina
Symphysis Pub.
Mons Veneris
Clitoris
Lab. min.
Labia major

Section of Female Pelvis, showing position of viscera.[1] [Compare the better figure, Fig. 656, p. 978.]

Between the clitoris and the entrance of the vagina is a triangular smooth surface bounded on each side by the nymphæ; this is the vestibule.

The orifice of the urethra (**meatus urinarius**) is situated at the back part of the vestibule, about an inch below the clitoris and near the margin of the vagina, surrounded by a prominent elevation of the mucous membrane. Below the meatus urinarius is the orifice of the vagina, an elliptical aperture, more or less closed in the virgin by a membranous fold, the *hymen*.

The **Hymen** is a thin semilunar fold of mucous membrane stretched across the lower part of the orifice of the vagina, its concave margin being turned upward toward the pubes. Sometimes this membrane forms a complete septum across the orifice of the vagina—a condition known as imperforate hymen. Occasionally it forms a circular septum, perforated in the centre by a round opening; sometimes it is cribriform, or its free margin forms a membranous fringe, or it may be entirely absent. It may also persist after copulation. The hymen cannot, consequently, be considered as a test of virginity. Its rupture or the rudimentary condition of the membrane above referred to gives rise to those small rounded elevations which surround the opening of the vagina, the *carunculæ myrtiformes.*

---

[1] The student must bear in mind, that though in this diagram the vagina is represented as a widely-open tube or canal for the sake of clearness, it is not so in its normal condition, but that, as stated in the text, its walls are ordinarily in contact with each other. The same remark applies to the urethra in Fig. 639, p. 956.

[Fig. 656.

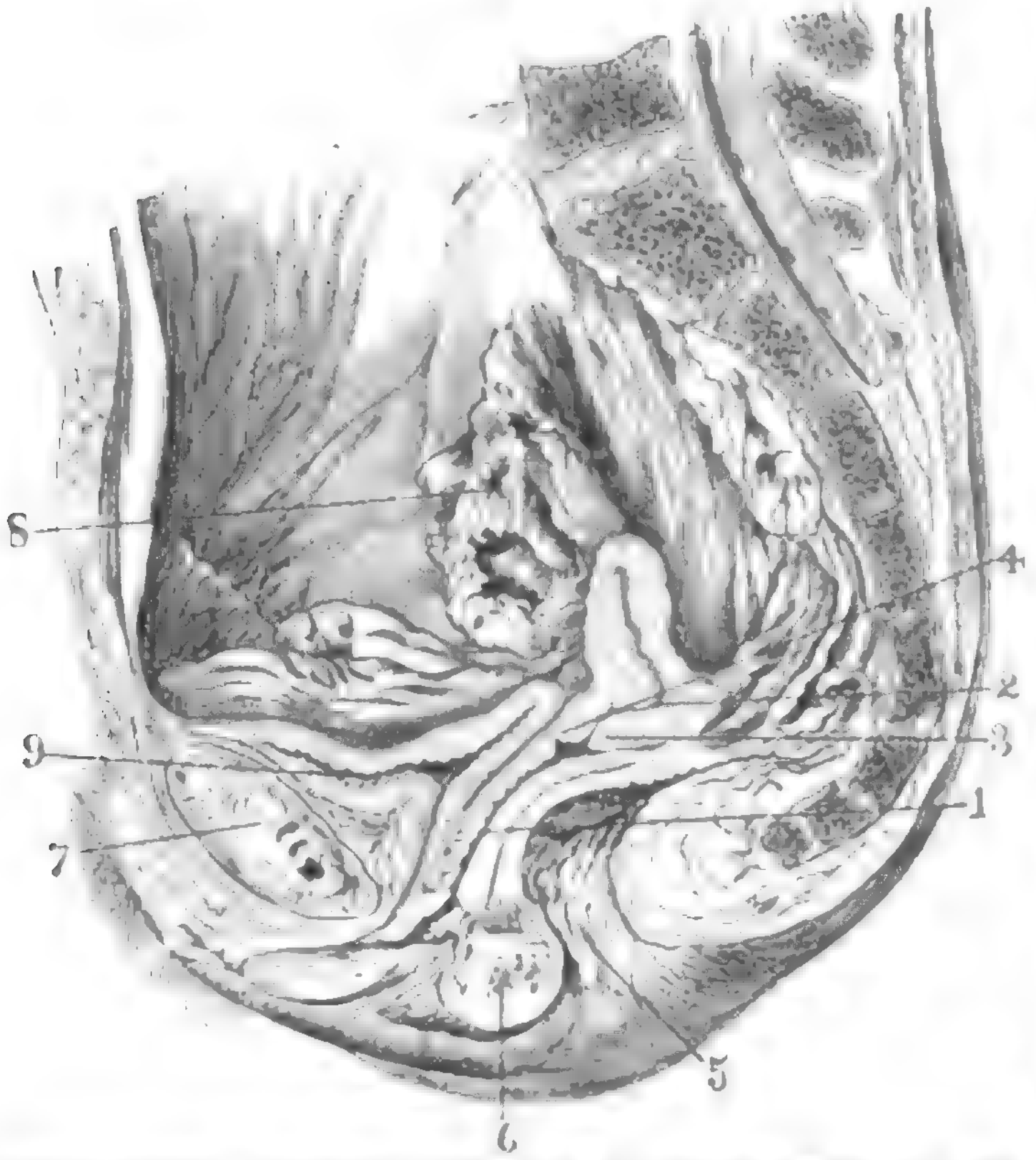

Antero-posterior (sagittal) Section of the Pelvic Organs of a Virgin: 1, vagina; 2, uterus; 3, posterior lip; 4, anterior lip; 5, anus; 6, perineum; 7, symphysis pubis; 8, fimbriated extremity of the Fallopian tube; 9, the empty bladder—note its Y shape, and also that the walls of the uterus, vagina, urethra, and bladder are in contact except when distended by their appropriate contents (D. Berry Hart).]

Glands of Bartholine.—On each side of the commencement of the vagina is a round or oblong body, of a reddish-yellow color and of the size of a horse-bean, analogous to Cowper's gland in the male. It is called the *gland of Bartholine.* Each gland opens by means of a long single duct upon the inner side of the nymphæ, external to the hymen. [Occasionally these become inflamed or obstructed and cause retention-cysts or abscesses.]

Extending from the clitoris, along either side of the vestibule and lying a little behind the nymphæ, are two large oblong masses, about an inch in length, consisting of a plexus of veins enclosed in a thin layer of fibrous membrane. These bodies are narrow in front, rounded below, and are connected with the crura of the clitoris and rami of the pubes: they are termed by Kobelt the *bulbi vestibuli,* and he considers them analogous to the bulb of the corpus spongiosum in the male. Immediately in front of these bodies is a smaller venous plexus continuous with the bulbi vestibuli behind and the glans clitoridis in front; it is called by Kobelt the *pars intermedia,* and is considered by him as analogous to that part of the body of the corpus spongiosum which immediately succeeds the bulb.

[For the anatomy of the perineum in the female, see p. 1015.]

THE BLADDER.

The **Bladder** [Figs. 656 and 657] is situated at the anterior part of the pelvis. It is in relation *in front* with the pubic bones; *behind* with the uterus, some convolutions of the small intestine being interposed; its *base* lies in contact with the neck of the uterus and with the anterior wall of the vagina. The bladder is said to be larger in the female than in the male (though this is denied by Henle), and is very broad in its transverse diameter. [Observe its Y shape when empty, and that when distended it would rise above the pubes, and the peritoneum also be lifted up above the pubes, as in Fig. 655.]

THE URETHRA.

The **Urethra** is a narrow membranous canal, about an inch and a half in length, extending from the neck of the bladder to the meatus urinarius. It is placed beneath the symphysis pubis, imbedded in the anterior wall of the vagina, and its direction is obliquely downward and forward, its course being slightly curved, the concavity directed forward and upward. Its diameter when undilated is about a quarter of an inch. The urethra perforates the triangular ligament precisely as in the male, and is surrounded by the muscular fibres of the Compressor urethræ.

Structure.—The urethra consists of three coats: muscular, erectile, and mucous. The *muscular coat* is continuous with that of the bladder; it extends the whole length of the tube and consists of a circular stratum of muscular fibres. In addition to this, between the two layers of the triangular ligament the female urethra is surrounded by the Constrictor urethræ, as in the male.

A thin layer of spongy erectile tissue, containing a plexus of large veins intermixed with bundles of unstriped muscular fibre, lies immediately beneath the mucous coat.

The *mucous coat* is pale, continuous externally with that of the vulva, and internally with that of the bladder. It is thrown into longitudinal folds, one of which, placed along the floor of the canal, resembles the verumontanum in the male urethra. It is lined by laminated epithelium, which becomes transitional near the bladder. Its external orifice is surrounded by a few mucous follicles.

The urethra, from not being surrounded by dense resisting structures, as in the male, admits of considerable dilatation, which enables the surgeon to remove with considerable facility calculi or other foreign bodies from the cavity of the bladder.

THE RECTUM.

The **Rectum** is more capacious and less curved in the female than in the male.

The *first portion* extends from the left sacro-iliac symphysis to the middle of the sacrum. Its connections are similar to those in the male.

The *second portion* extends to the tip of the coccyx. It is covered in front by the peritoneum for a short distance at its upper part: it is in relation with the posterior wall of the vagina.

The *third portion* curves backward from the vagina to the anus, leaving a space which corresponds on the surface of the body to the perineum. Its extremity is surrounded by the Sphincter muscles, and its sides are supported by the Levatores ani.

THE VAGINA.

The **Vagina** [Fig. 656] is a membranous canal extending from the vulva to the uterus. It is situated in the cavity of the pelvis, behind the bladder and in front of the rectum. Its direction is curved forward and downward, following at first the line of the axis of the cavity of the pelvis, and afterward that of the outlet. It is cylindrical in shape, flattened from before backward, and its walls are ordinarily in contact with each other. Its length is about four inches along its anterior wall, and between five and six inches along its posterior wall. It is constricted at its commencement, and becomes dilated near its uterine extremity; it surrounds the vaginal portion of the cervix uteri a short distance from the os, its attachment extending higher up on the posterior than on the anterior wall of the uterus.

RELATIONS.—Its *anterior surface* is in relation with the base of the bladder and with the urethra. Its *posterior surface* is connected to the anterior wall of the rectum for the lower three-fourths of its extent, the upper fourth being separated from that tube by the recto-uterine fold of peritoneum, which forms a cul-de-sac between the vagina and rectum. Its sides give attachment superiorly to the broad ligaments and inferiorly to the Levatores ani muscles and recto-vesical fascia.

Structure.—The vagina consists of an internal mucous lining, of a muscular coat, and of an external layer of erectile tissue.

The *mucous membrane* is continuous above with that lining the uterus, and below with the integument covering the labia majora. Its inner surface presents along the anterior and posterior walls a longitudinal ridge or raphé called the *columns of the vagina*, and numerous transverse ridges or rugæ extending outward from the raphé on either side. These rugæ are divided by furrows of variable depth, giving to the mucous membrane the appearance of being studded over with conical projections or papillæ; they are most numerous near the orifice of the vagina, especially before parturition. The epithelium covering the mucous membrane is of the squamous variety. The submucous tissue is very loose, and contains numerous large veins, which by their anastomoses form a plexus, together with smooth muscular fibres derived from the muscular coat; it is regarded by Gussenbauer as an erectile tissue.

[Fig. 657.

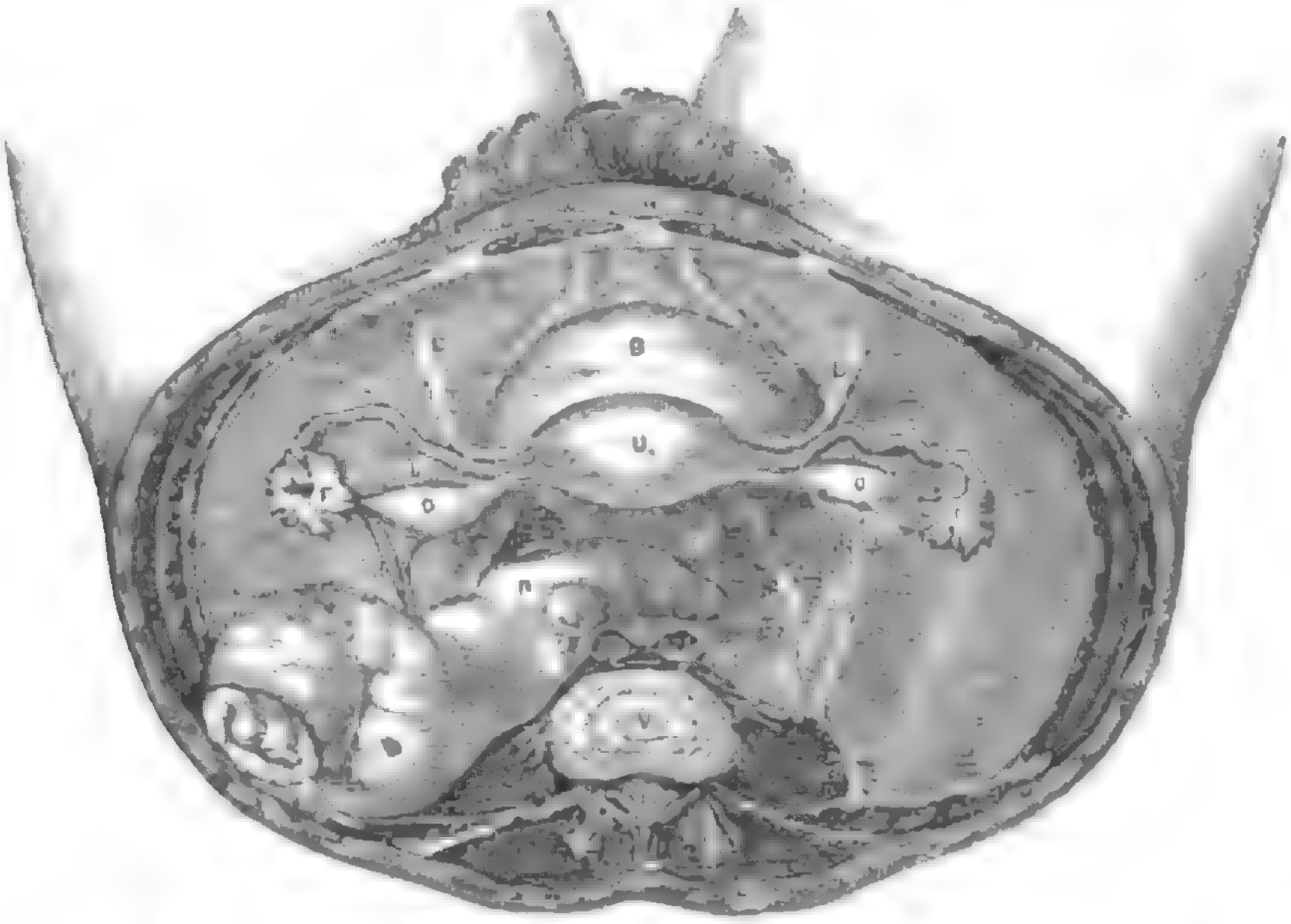

Transverse Section of the Body, showing relations of fundus uteri: M, pubes; A, A, hypogastric arteries in front of the bladder, spermatic vessels and nerves behind the ovaries; B, bladder; L, L, round ligaments; U, fundus uteri; T, T, Fallopian tubes; F, fimbriated extremity of Fallopian tubes; b, broad ligament of uterus; O, O, ovaries; R, rectum; G, right ureter; C, utero-sacral ligaments; V, last lumbar vertebra (Savage).]

The *muscular coat* consists of two layers—an external longitudinal, which is far the stronger, and an internal circular layer. The longitudinal fibres are continuous with the superficial muscular fibres of the uterus. The strongest fasciculi are those attached to the recto-vesical fascia on each side. The two layers are not distinctly separable from each other, but are connected by oblique decussating fasciculi which pass from the one layer to the other. In addition to this, the vagina at its lower end is surrounded by a band of striped muscular fibres, the *sphincter vaginæ*. (See p. 1015.)

The *erectile tissue* consists of a layer of loose connective tissue situated between the mucous membrane and the muscular coat; imbedded in it is a plexus of large veins and numerous bundles of unstriped muscular fibres derived from the circular muscular layer. The arrangement of the veins is similar to that found in other erectile tissues.

THE UTERUS.

The **Uterus** [Figs. 656 and 657] is the organ of gestation, receiving the fecundated ovum in its cavity, retaining and supporting it during the development of the fœtus, and becoming the principal agent in its expulsion at the time of parturition.

In the virgin state it is pear-shaped, flattened from before backward, and situated in the cavity of the pelvis between the bladder and the rectum; it is retained in its position by the round and broad ligaments on each side, and projects into the upper end of the vagina below. Its upper end, or base, is directed upward and forward; its lower end, or apex, downward and backward in the line of the axis of the inlet of the pelvis. It therefore forms an angle with the vagina, since the direction of the vagina corresponds to the axis of the cavity and outlet of the pelvis. The uterus measures about three inches in length, two in breadth at its upper part, and an inch in thickness, and it weighs from an ounce to an ounce and a half.

The *fundus* is the upper broad extremity of the organ: it is convex, covered by peritoneum, and placed on a line below the level of the brim of the pelvis.

The *body* gradually narrows from the fundus to the neck. Its *anterior surface* is flattened, covered by peritoneum in the upper three-fourths of its extent, and separated from the bladder by some convolutions of the small intestine: the lower fourth is connected to the bladder. Its *posterior surface* is convex, covered by peritoneum throughout, and separated from the rectum by some convolutions of the intestine. Its *lateral margins* are concave and give attachment to the Fallopian tube above, the round ligament below and in front of this, and the ligament of the ovary behind and between both of these structures.

The *cervix* is the lower rounded and constricted portion of the uterus: around its circumference is attached the upper end of the vagina, which extends upward a greater distance behind than in front.

At the vaginal extremity of the uterus is a transverse aperture, the *os uteri*, bounded by two lips, the anterior of which is thick, the posterior narrow and long.

Ligaments.—The ligaments of the uterus are eight in number: two anterior, two posterior, and two lateral formed of peritoneum, and the round ligaments (p. 988).

The *two anterior ligaments* (*vesico-uterine*) are two semilunar folds which pass between the neck of the uterus and the posterior surface of the bladder.

The *two posterior ligaments* (*recto-uterine*) pass between the sides of the uterus and rectum. The fold of peritoneum which forms these ligaments is reflected from the anterior surface of the second portion of the rectum on to the posterior surface of the upper part of the vagina, and thence passes up on to the posterior wall of the uterus. It thus forms a pouch or cul-de-sac which is termed the *recto-vaginal pouch* or *pouch of Douglas.*

The *two lateral* or *broad ligaments* pass from the sides of the uterus to the lateral walls of the pelvis, forming a septum across the pelvis which divides that cavity into two portions. In the anterior part are contained the bladder, urethra, and vagina; in the posterior part, the rectum.

The *cavity of the uterus* is small in comparison with the size of the organ: that portion of the cavity which corresponds to the body is triangular, having its base directed upward toward the fundus, and is flattened from before backward, so that its walls are closely approximated. At each superior angle is a funnel-shaped cavity which constitutes the remains of the division of the body of the uterus into two cornua, and at the bottom of each cavity is the minute orifice of the Fallopian tube. At the inferior angle of the uterine cavity is a small constricted opening, the internal orifice (*ostium internum*), which leads into the cavity of the cervix. The cavity of the cervix is somewhat fusiform, flattened from before backward, broader at the middle than at either extremity, and communicates below with the vagina. Each wall of the canal presents a longitudinal column, from which proceed a number of small oblique columns, giving the appearance of branches from the stem of a tree, and hence the name *arbor vitæ uterina* applied to it. These folds usually become very indistinct after the first labor.

Structure.—The uterus is composed of three coats—an external serous coat, a middle or muscular layer, and an internal mucous coat.

The *serous coat* is derived from the peritoneum; it invests the fundus and the whole of the posterior surface of the body of the uterus, but only the upper three-fourths of its anterior surface.

The *muscular coat* forms the chief bulk of the substance of the uterus. In the unimpregnated state it is dense, firm, of a grayish color, and cuts almost like cartilage. It is thick opposite the middle of the body and fundus, and thin at the orifices of the Fallopian tubes. It consists of bundles of unstriped muscular fibres, disposed in layers, intermixed with areolar tissue, blood-vessels, lymphatic vessels, and nerves. In the impregnated state the muscular tissue becomes more prominently developed, and is disposed in three layers—external, middle, and internal.

The external layer is placed beneath the peritoneum, disposed as a thin plane on the anterior and posterior surfaces. It consists of fibres which pass transversely across the fundus, and, converging at each superior angle of the uterus, are continued on the Fallopian tubes, the round ligament, and ligament of the ovary, some passing at each side into the broad ligament, and others running backward from the cervix into the recto-uterine ligaments.

The middle layer of fibres presents no regularity in its arrangement, being disposed longitudinally, obliquely, and transversely.

The internal or deep layer consists of circular fibres arranged in the form of two hollow cones, the apices of which surround the orifices of the Fallopian tubes, their bases intermingling with one another on the middle of the body of the uterus. At the cervix these fibres are disposed transversely, constituting the so-called internal and external sphincters of the os uteri.

The *mucous membrane* is thin, smooth, and closely adherent to the subjacent tissue. It is continuous, through the fimbriated extremity of the Fallopian tubes, with the peritoneum, and through the os uteri with the mucous membrane lining the vagina.

[Fig. 658.

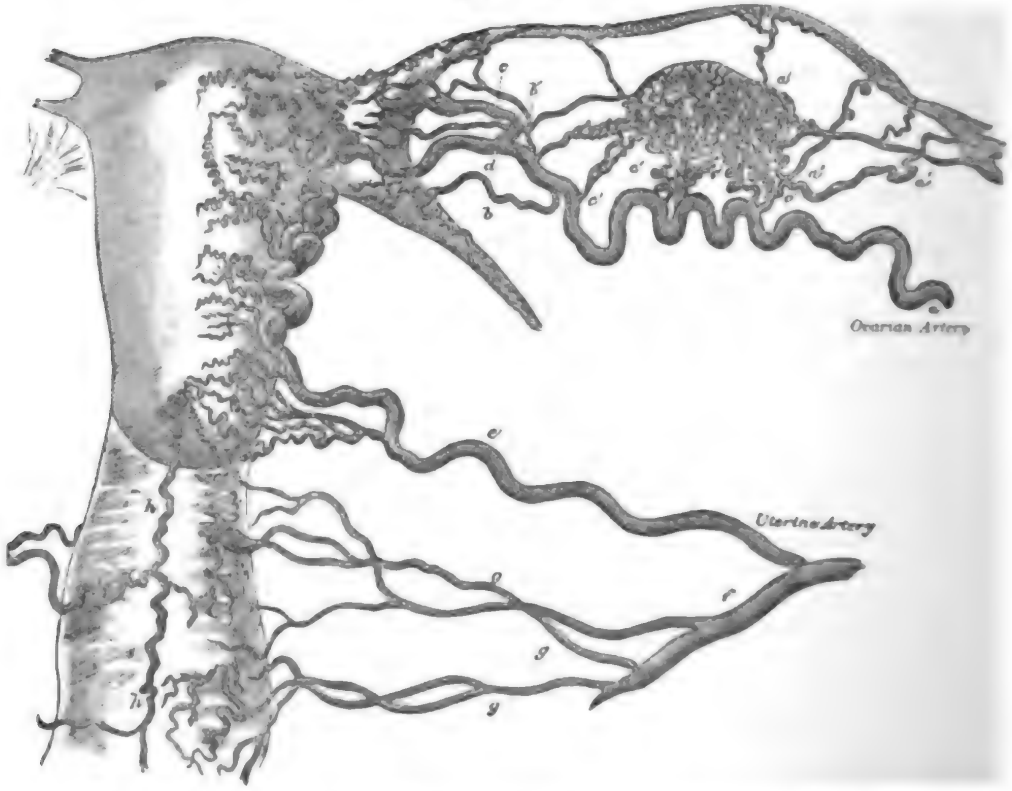

The Ovarian, Uterine, and Vaginal Arteries (Hyrtl): *a*, ovarian artery: *a'* and *b'*, branches to tube; *b*, branch to round ligament; *c*, branch to the fundus uteri; *c'*, branches to ovary; *d*, branch to the side of the uterus, anastomosing with *e*, the uterine artery, a branch of *f*, the anterior division of the internal iliac; *g*, vaginal arteries. A special branch of the uterine artery goes to the cervix, and, with its fellow of the opposite side, forms the "circular artery" at the isthmus. Note the free anastomosis and tortuousness of all these vessels, and that they all reach the uterus, ovary, and tube by the broad ligament. *h*, azygos artery of vagina (Hart and Barbour).]

In the body of the uterus it is smooth, soft, of a reddish color, lined by columnar ciliated epithelium, and presents, when viewed with a lens, the orifices of numerous tubular follicles arranged perpendicularly to the surface. They are of small size in the unimpregnated uterus, but shortly after impregnation they become enlarged, elongated, presenting a contorted or waved appearance toward their closed extremities, which occasionally dilate into two or three sacculated pouches. The circular orifices of these glands may be seen on the inner surface of the mucous membrane, many of which during the early period of pregnancy are surrounded by a whitish ring formed of epithelium which lines the follicles. In the impregnated uterus the epithelium loses its ciliated character.

In the cervix the mucous membrane between the rugæ and around the os uteri is provided with numerous mucous follicles and glands. The small, transparent, vesicular elevations so often found within the os and cervix uteri are due to closure of the mouths of these follicles and their distension with their proper secretion. They are called the *ovula of Naboth.* The mucous membrane covering the lower half of the cervix presents numerous papillæ, and the epithelium is stratified.[1]

VESSELS AND NERVES.—The *arteries* [Fig. 658] of the uterus are the uterine, from the internal iliac, and the ovarian, from the aorta. They are remarkable for their tortuous course in the substance of the organ and for their frequent anastomoses. The *veins* are of large size, and correspond with the arteries. In the impregnated uterus these vessels are termed the *uterine sinuses*, consisting of the lining membrane of the veins adhering to the walls of the canals channelled through the substance of the uterus. They terminate in the uterine plexuses. The *lymphatics* are of large size in the impregnated uterus, and terminate in the pelvic and lumbar glands. The nerves are derived from the inferior hypogastric and ovarian plexuses and from the third and fourth sacral nerves.

The form, size, and situation of the uterus vary at different periods of life and under different circumstances.

In the fœtus the uterus is contained in the abdominal cavity, projecting beyond the brim of the pelvis. The cervix is considerably larger than the body.

At puberty the uterus is pyriform in shape and weighs from eight to ten drachms. It has descended into the pelvis, the fundus being just below the level of the brim of this cavity. The arbor vitæ is distinct, and extends to the upper part of the cavity of the organ.

During menstruation the organ is enlarged and more vascular, its surfaces rounder; the os externum is rounded, its labia swollen, and the lining membrane of the body thickened, softer, and of a darker color. According to J. Williams, at each recurrence of menstruation a molecular disintegration and softening of the superficial part of the mucous membrane takes place, which leads to its complete removal. At the cessation of the menstrual flow a rapid proliferation of the cells of the deeper layers of the mucous membrane takes place, and a fresh uterine membrane is quickly formed.

During pregnancy the uterus increases so as to weigh from one pound and a half to three pounds. It becomes enormously enlarged, and projects into the hypogastric and lower part of the umbilical regions. This enlargement, which continues up to the sixth month of gestation, is partially due to increased development of pre-existing and new-formed muscular tissue. The round ligaments are enlarged, and the broad ligaments become encroached upon by the uterus making its way between their laminæ. The mucous membrane becomes more vascular, its mucous follicles and glands enlarged; the rugæ and folds in the canal of the cervix become obliterated; the blood and lymphatic vessels, as well as the nerves, according to the researches of Dr. Lee, greatly enlarged.

After parturition the uterus nearly regains its usual size, weighing from two to three ounces, but its cavity is larger than in the virgin state; the external orifice is more marked and assumes a transverse direction; its edges present a fissured surface; its vessels are tortuous, and its muscular layers are more defined.

In old age the uterus becomes atrophied and paler and denser in texture; a more distinct

---

[[1] Dr. A. W. Johnstone of Danville, Kentucky (*Brit. Gynæcol. Journ.*, ii. 292), has made some very important observations on the mucous membrane of the uterus. He calls it the "menstrual organ," and says that it is "not a mucous membrane, but belongs to the so called adenoid tissues," and that menstruation is for it exactly what the lymph-stream is to the lymph-glands or the blood-current to the spleen. Like the testicles, tonsils, Peyer's patches, the thymus gland, and many hair-follicles, its functional activity does not extend throughout life. The menstrual organ develops at puberty and declines at the menopause, its structure varying remarkably at these two periods from that of its active functional life. At each menstruation the epithelium of the body of the uterus is shed, thus preparing a nidus for the impregnated ovum, while that of the cervix and tubes is not shed, and an impregnated ovum will not therefore adhere to it. In salpingitis, etc., if the mucous membrane is lost, an impregnated ovum may adhere and produce tubal pregnancy (Tait). J. Bland Sutton's paper on "Menstruation in Monkeys" immediately precedes Dr. Johnstone's important contribution, and confirms it to a remarkable degree.]

constriction separates the body and cervix. The ostium internum, and, occasionally, the vaginal orifice, often become obliterated and its labia almost entirely disappear.

APPENDAGES OF THE UTERUS.

The appendages of the uterus are the Fallopian tubes, the ovaries and their ligaments, and the round ligaments. These structures, together with their nutrient vessels and nerves and some scattered muscular fibres, are enclosed between the two folds of peritoneum which constitute the broad ligaments; they are placed in the following order: in front is the round ligament; the Fallopian tube occupies the free margin of the broad ligament; the ovary and its ligament are behind and below the latter.

The **Fallopian Tubes,** or **Oviducts,** convey the ova from the ovaries to the cavity of the uterus. They are two in number, one on each side, situated in the free margin of the broad ligament, extending from each superior angle of the uterus to the sides of the pelvis. Each tube is about four inches in length; its canal is exceedingly minute, and commences at the superior angle of the uterus by a minute orifice, the *ostium internum*, which will hardly admit a fine bristle; it continues narrow along the inner half of the tube, and then gradually widens into a trumpet-shaped extremity which becomes contracted at its termination. This orifice is called the *ostium abdominale*, and communicates with the peritoneal cavity. Its margins are surrounded by a series of fringe-like processes, termed *fimbriæ*, and one of these processes is connected with the outer end of the ovary. To this part of the tube the name *fimbriated extremity* is applied; it is also called *morsus diaboli*, from the peculiar manner in which it embraces the surface of the ovary during sexual excitement. In connection with the fimbriæ of the Fallopian tube or with the broad ligament close to them there is frequently a small vesicle or *hydatid*, floating on a long stalk of peritoneum.

Structure.—The Fallopian tube consists of three coats—a serous, muscular, and mucous.

The *external* or *serous coat* is derived from the peritoneum.

The *middle* or *muscular coat* consists of an external longitudinal and an internal circular layer of muscular fibres continuous with those of the uterus.

The *internal* or *mucous coat* is continuous with the mucous lining of the uterus, and at the free extremity of the tube with the peritoneum. It is thrown into longitudinal folds in the outer part of the tube, which indicate its adaptation for dilatation, and is covered by a columnar ciliated epithelium. This form of epithelium is also found on the inner surface of the fimbriæ, while on the outer or serous surfaces of these processes the epithelium gradually merges into the pavement epithelium of the peritoneum.

[The Fallopian tubes of late have been shown to be the frequent seat of inflammation (salpingitis), followed by local dropsy (hydrosalpinx), or accumulations of pus (pyosalpinx), or of blood (hemato-salpinx). Laparotomy often has to be resorted to for the relief of such diseases.]

The **Ovaries** (*testes muliebres*, Galen) are analogous to the testes in the male. They are oval-shaped bodies of an elongated form, flattened from above downward, situated one on each side of the uterus in the posterior part of the broad ligament behind and below the Fallopian tubes. Each ovary is connected by its anterior margin to the broad ligaments; by its inner extremity to the uterus by a proper ligament, the ligament of the ovary; and by its outer end to the fimbriated extremity of the Fallopian tube by a short ligamentous cord. The ovaries are of a whitish color and present either a smooth or puckered uneven surface. They are each about an inch and a half in length, three-quarters of an inch in width, and about a third of an inch thick, and weigh from one to two drachms. The surfaces and posterior convex border are free, the anterior straight border being attached to the broad ligament.

Professor His has described the position of the ovary with its long diameter almost vertical and the Fallopian tube as running along its upper extremity, and then taking a sudden turn downward over the outer border of the ovary to below the level of its lower extremity. From this point the fimbriæ are directed upward, and the ovary rests upon them. From this description it would appear that the ripe ova, when liberated from the ovary, would drop at once into the tube.

[Fig. 659.

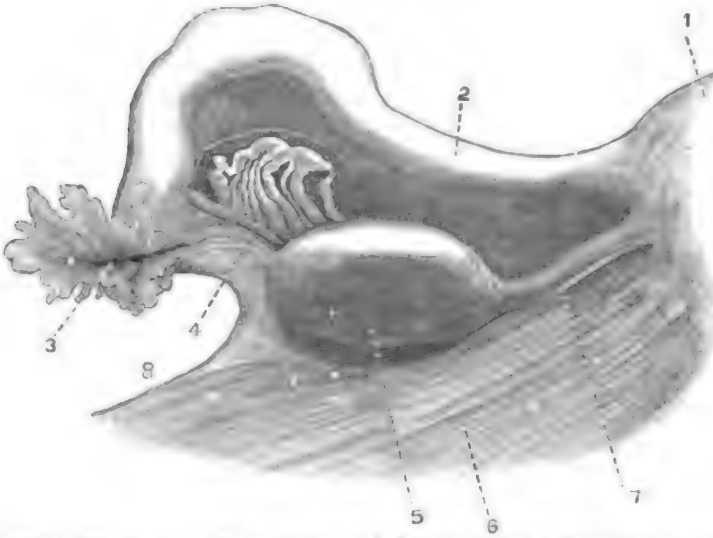

Posterior View of Uterine Appendages: 1, uterus; 2, Fallopian tube; 3, fimbriated extremity and opening of the Fallopian tube; 4, epoöphoron; 5, ovary; 6, ligament; 7, ligament of the ovary; 8, infundibulo-pelvic (broad) ligament (Henle). Compare Fig. 110, p. 136, and Fig. 657, p. 980.]

Structure.—The ovary consists of a number of Graafian vesicles imbedded in the meshes of a stroma or framework, and invested by a serous covering derived from the peritoneum.

Serous Covering.—Though the investing membrane of the ovary is derived from the peritoneum, it differs essentially from that structure, inasmuch as its epithelium consists of a single layer of columnar cells, instead of the flattened endothelial cells of other parts: this has been termed the *germinal epithelium of Waldeyer*, and gives to the surface of the ovary a dull gray aspect instead of the shining smoothness of serous membranes generally.

Fig. 660.

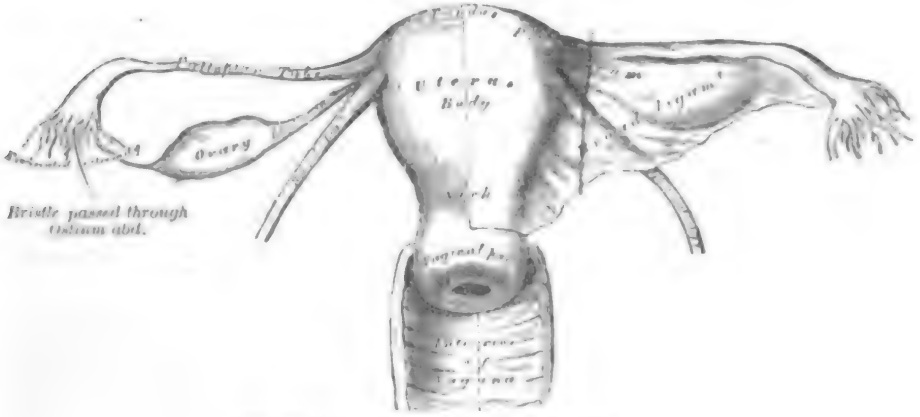

The Uterus and its Appendages, anterior view.

Stroma.—The stroma is a peculiar soft tissue abundantly supplied with blood-vessels, consisting for the most part of spindle-shaped cells, with a small amount of ordinary connective tissue. These cells have been regarded by some anatomists as unstriped muscle-cells, which, indeed, they most resemble (His); by others as connective-tissue cells (Waldeyer, Henle, and Kölliker). On the surface of the organ this tissue is much condensed, and forms a layer composed of short connective-tissue fibres, with fusiform cells between them. This was formerly regarded as a distinct fibrous covering, and was termed the *tunica albuginea*, but is nothing more than a condensed layer of the stroma of the ovary.

Graafian Vesicles.—Upon making a section of an ovary numerous round transparent vesicles of various sizes are to be seen; they are the *Graafian vesicles*, the ovisacs containing the ova. Immediately beneath the superficial covering is a layer of stroma, in which are a large number of minute vesicles of uniform size about $\frac{1}{100}$ of an inch in diameter. These are the Graafian vesicles in their earliest condition, and the layer where they are found has been termed the *cortical layer*. They are especially numerous in the ovary of the young child. After puberty and during the whole of the child-bearing period large and mature (or almost mature) Graafian vesicles are also found in the cortical layer in small numbers, and also "corpora lutea," the remains of vesicles which have burst and are undergoing atrophy and absorption. Beneath this superficial stratum other larger and more mature Graafian vesicles are found imbedded in the ovarian stroma. These increase in size as they recede from the surface toward a highly vascular stroma in the centre of the organ, termed the medullary substance (zona vasculosa, Waldeyer). This stroma forms the tissue of the hilum by which the ovary is attached and through which the blood-vessels enter; it does not contain any Graafian vesicles.

FIG. 661.

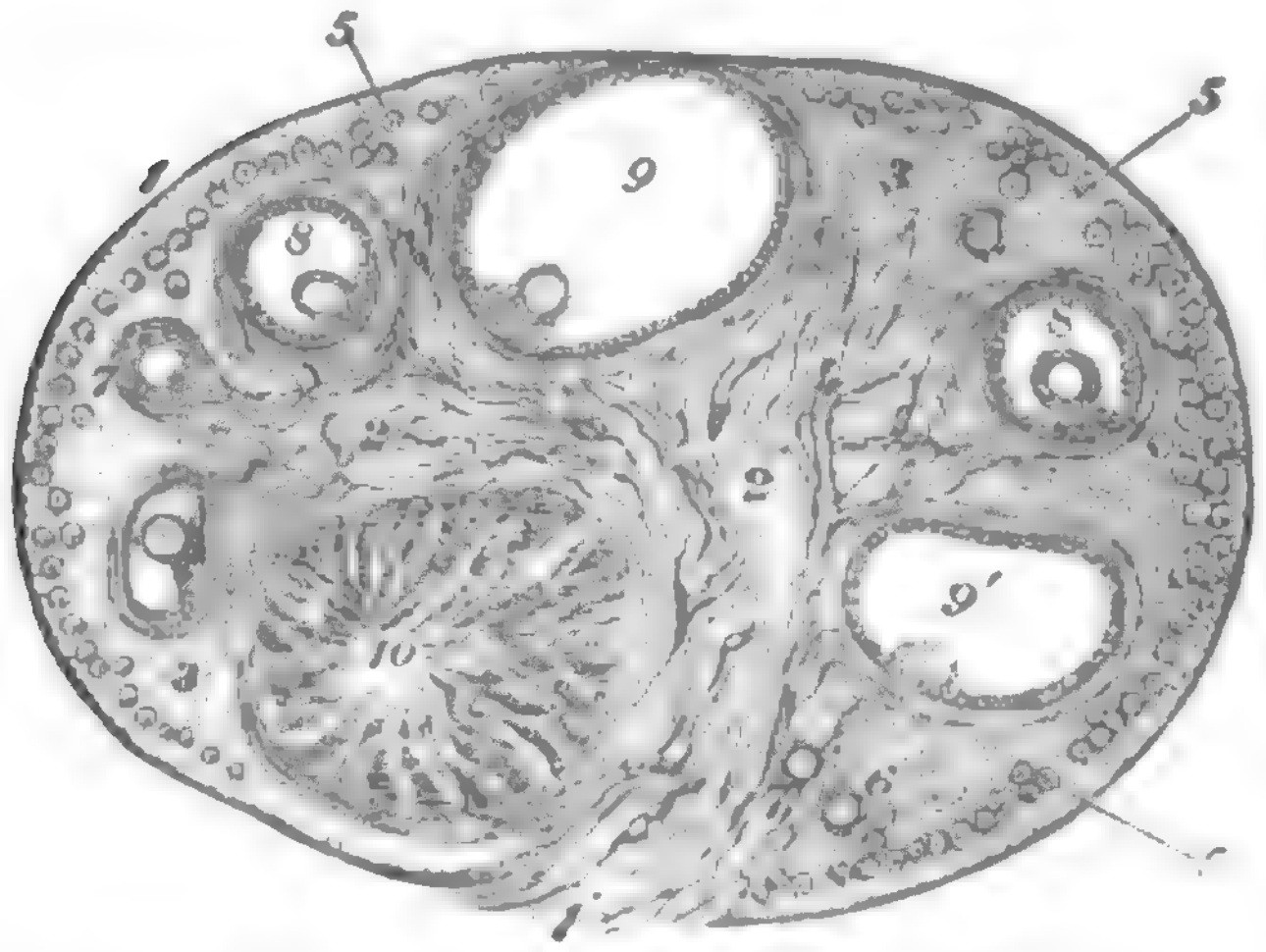

Section of the Ovary (after Schrön): 1, outer covering; 1′, attached border; 2, central stroma; 3, peripheral stroma; 4, blood-vessels; 5, Graafian follicles in their earliest stage; 6, 7, 8, more advanced follicles; 9, an almost mature follicle; 9′, follicle from which the ovum has escaped; 10, corpus luteum.

FIG. 662.

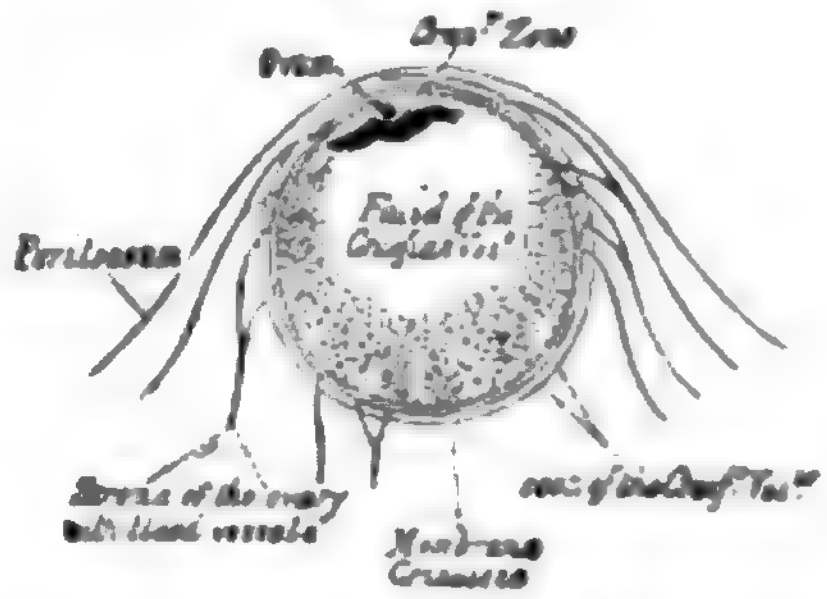

Section of the Graafian Vesicle (after Von Baer).

The *Graafian vesicles* consist of an external fibro-vascular coat connected with the surrounding stroma of the ovary by a network of blood-vessels, and an internal coat, named *ovicapsule*, which is lined by a layer of nucleated cells, called the *membrana granulosa*. The fluid contained in the interior of the vesicles is transparent and albuminous, and in it is suspended the ovum. In that part of the mature Graafian vesicle which is nearest the surface of the ovary the cells of the membrana granulosa are collected into a mass which projects into the cavity of the vesicle. This is termed the *discus proligerus*, and in this the ovum is imbedded.[1]

The ova are formed from the germ-epithelium on the surface of the ovary: the cells become enlarged and involuted, forming little depressions on the surface of the ovary. As they sink deeper into the tissue they become enclosed by the outgrowth of processes from the stroma of the ovary, and, becoming surrounded, their connection with the surface is cut off and the germ-epithelium forming the involution is contained in a cavity, the future Graafian follicle. The germ-cell or cells now form the ovum; the cell-wall forms the vitelline membrane; the nucleus, the germinal area; and a nucleolus, which soon appears, the germinal spot. A clear homogeneous protoplasm is formed within the cell, constituting the yolk, and thus the primordial ovum is developed. According to Dr. Foulis, the cells of the membrana granulosa are formed out of the nuclei of the fibro-cellular stroma of the ovary.[1]

---

[1] For a description of the ovum see p. 99.

The formation, development, and maturation of the Graafian vesicles and ova continue uninterruptedly from infancy to the end of the fruitful period of woman's life. Before puberty the ovaries are small; the Graafian vesicles contained in them are disposed in a comparatively thick layer in the cortical substance; here they present the appearance of a large number of minute closed vesicles, constituting the early condition of the Graafian vesicle; many, however, never attain full development, but shrink and disappear, their ova being incapable of impregnation. At puberty the ovaries enlarge, are more vascular, the Graafian vesicles are developed in greater abundance, and their ova are capable of fecundation.

Discharge of the Ovum.—The Graafian vesicles, after gradually approaching the surface of the ovary, burst: the ovum and fluid contents of the vesicles are liberated, and escape on the exterior of the ovary, passing thence into the Fallopian tube, the fimbriated processes of which are supposed to grasp the ovary, the aperture of the tube being applied to the part corresponding to the matured and bursting vesicle. In the human subject and most Mammalia the maturation and discharge of the ova occur at regular periods only, and are indicated in the Mammalia by the phenomena of heat or rut, and in the human female by menstruation. [See footnote p. 983.] Sexual desire is more intense in females [of the lower animals] at this period, and if the union of the sexes takes place the ovum may be fecundated.

Corpus Luteum.—Immediately after the rupture of a Graafian vesicle and the escape of its ovum the vesicle is filled with blood-tinged fluid, and in a short time the circumference of the vesicle is occupied by a firm yellow substance which is probably formed from plasma exuded from its walls. Dr. Lee believes that this yellow matter is deposited outside both the membranes of the follicle; Montgomery regards it as placed between the layers; while Kölliker considers it as a thickening of the inner layer of the outer coat of the follicle. The exudation is at first of a dark-brown or brownish-red color, but it soon becomes paler and its consistence more dense.

For every follicle in the ovary from which the ovum is discharged a corpus luteum will be found. But the characters it exhibits and the changes produced in it will be determined by the circumstance of the ovum being impregnated or not.

Although there is little doubt that corpora lutea exist in the ovaries after the escape of ova independently of coitus or impregnation, it appears that the corpus luteum of pregnancy (*true corpus luteum*) possesses characters by which it may be distinguished from one formed in a follicle from which an ovum has been discharged without subsequent impregnation (*false corpus luteum*).

The *true corpora lutea* are of large size—often as large as a mulberry—of a rounded form, and project from the surface of the ovary, the summit of the projection presenting a triangular depression or cicatrix where the peritoneum appears to have been torn. They contain a small cavity in their centre during the early period of their formation, which becomes contracted and exhibits a stellate cicatrix during the later stages of pregnancy. Their vascularity, lobulated or puckered appearance, firm consistence, and yellow color are also characteristic marks of true corpora lutea.

False corpora lutea are of small size, do not project from the surface of the ovary, are angular in form, seldom present any cicatrix, contain no cavity in their centre; the material composing them is not lobulated, its consistence is usually soft, often resembling coagulated blood; the yellow matter exists in the form of a very thin layer, or more commonly is entirely wanting. False corpora lutea most frequently result from the effusion into the cavities of the Graafian vesicles of serum or blood, which subsequently undergoes various changes and is ultimately removed. Dr. Lee states that in the false corpora lutea the yellow substance is contained within or attached to the inner surface of the Graafian vesicle, and does not surround it, as is the case in the true corpora lutea.

---

[1] *Proceedings of the Royal Society of Edinburgh*, April, 1875.

In the fœtus the ovaries, like the testes, are situated in the lumbar region, near the kidneys. They may be distinguished from those bodies at an early period by their elongated and flattened form, and by their position, which is at first oblique and then nearly transverse. They gradually descend into the pelvis.

Lying above the ovary in the broad ligament between it and the Fallopian tube is the organ of Rosenmüller, called also the parovarium or epoöphoron. This is the remnant of a fœtal structure, the development of which has been described at a former page (p. 136). [See also Fig. 659, p. 985.] In the adult it consists of a few closed convoluted tubes lined with epithelium, some of them atrophied, and one usually distinguishable from the rest by ending in a bulbous or hydatid swelling. The parovarium is connected at its uterine extremity with the remains of the Wolffian duct—the duct of Gartner.

The **Ligament of the Ovary** is a rounded cord which extends from each superior angle of the uterus to the inner extremity of the ovary; it consists of fibrous tissue and a few muscular fibres derived from the uterus.

The **Round Ligaments** are two rounded cords, between four and five inches in length, situated between the layers of the broad ligament, in front of and below the Fallopian tube. Commencing on each side at the superior angle of the uterus, this ligament passes forward and outward through the internal abdominal ring, along the inguinal canal to the labia majora, in which it becomes lost. The round ligament consists of areolar tissue, vessels, and nerves, besides a dense bundle of fibrous tissue and muscular fibres prolonged from the uterus, enclosed in a duplicature of peritoneum, which in the fœtus is prolonged in the form of a tubular process for a short distance into the inguinal canal. This process is called the *canal of Nuck*. It is generally obliterated in the adult, but sometimes remains pervious even in advanced life. It is analogous to the peritoneal pouch which accompanies the descent of the testis.

VESSELS AND NERVES.—The *arteries* of the ovaries and Fallopian tubes are the ovarian, from the aorta. They anastomose with the termination of the uterine arteries, and enter the attached border of the ovary. The *veins* follow the course of the arteries; they form a plexus near the ovary, the *pampiniform plexus*. The *nerves* are derived from the inferior hypogastric or pelvic plexus and from the ovarian plexus, the Fallopian tube receiving a branch from one of the uterine nerves.

MAMMARY GLANDS.

The **Mammæ**, or breasts, are accessory glands of the generative system, and secrete the milk. They exist in the male as well as in the female, but in the former only in the rudimentary state, unless their growth is excited by peculiar circumstances. [Very rarely in the male, but very frequently in the female, they are the seat of carcinomatous and other tumors.] In the female they are two large hemispherical eminences situated toward the lateral aspect of the pectoral region, corresponding to the intervals between the third and sixth or seventh ribs, and extending from the side of the sternum to the axilla. [Occasionally, but very rarely, supernumerary breasts exist.] Their weight and dimensions differ at different periods of life and in different individuals. Before puberty they are of small size, but enlarge as the generative organs become more completely developed. They increase during pregnancy, and especially after delivery, and become atrophied in old age. The left mamma is generally a little larger than the right. Their base is nearly circular, flattened or slightly concave, and has its long diameter directed upward and outward toward the axilla; they are separated from the Pectoral muscles by a thin layer of superficial fascia. The outer surface of the mamma is convex, and presents just below the centre a small conical prominence, the nipple (*mammilla*). The surface of the nipple is dark-colored and surrounded by an areola having a colored tint. In the virgin the areola is of a delicate rosy hue; about the second month of impregnation it enlarges and acquires a darker tinge, which increases as pregnancy advances, becoming in some cases of a dark-brown or even black color. This color diminishes as soon as lactation is over, but is never entirely lost through life. These changes in the color of the areola are of extreme importance in forming a conclusion in a case of suspected first pregnancy.

The **Nipple** is a cylindrical or conical eminence capable of undergoing a sort of erection from mechanical excitement—a change mainly due to the contraction of its muscular fibres. It is of a pink or brownish hue, its surface wrinkled and provided with papillæ, and it is perforated by numerous orifices, the apertures of the lactiferous ducts. Near the base of the nipple and upon the surface of the areola are numerous sebaceous glands, which become much enlarged during lactation, and present the appearance of small tubercles beneath the skin. These glands secrete a peculiar fatty substance which serves as a protection to the integument of the nipple in the act of sucking. The nipple consists of numerous vessels, intermixed with plain muscular fibres which are principally arranged in a circular manner around the base, some few fibres radiating from base to apex.

Structure.—The mamma consists of gland-tissue, of fibrous tissue connecting its lobes, and of fatty tissue in the intervals between the lobes. The mammary gland when freed from cellular tissue and fat is of a pale reddish color, firm in texture, circular in form, flattened from before backward, thicker in the centre than at the circumference, and presenting several inequalities on its surface, especially in front. It consists of numerous lobes, and these are composed of lobules connected together by areolar tissue, blood-vessels, and ducts. The smallest lobules consist of a cluster of rounded vesicles which open into the smallest branches of the lactiferous ducts; these ducts, uniting, form larger ducts, which terminate in a single canal, corresponding with one of the chief subdivisions of the gland. The number of excretory ducts varies from fifteen to twenty: they are termed the *tubuli lactiferi* or *galactophori*. They converge toward the areola, beneath which they form dilatations or *ampullæ*, which serve as reservoirs for the milk, and at the base of the nipple become contracted and pursue a straight course to its summit, perforating it by separate orifices considerably narrower than the ducts themselves. The ducts are composed of areolar tissue, with longitudinal and transverse elastic fibres and longitudinal muscular fibres; their mucous lining is continuous at the point of the nipple with the integument. The epithelium of the mammary gland differs according to the state of activity of the organ. In the resting gland—that is to say, in the gland of a woman who is not pregnant or suckling—the alveoli are very small and solid, being filled with a mass of granular polyhedral cells. During pregnancy the alveoli enlarge and the cells undergo rapid multiplication. At the commencement of lactation the cells in the centre of the alveolus undergo fatty degeneration, and are eliminated in the first milk as *colostrum corpuscles*. The peripheral cells of the alveolus remain, and form a single layer of granular, short, columnar cells, with a spherical nucleus, lining the limiting membrana propria. These cells during the state of activity of the gland are capable of forming in their interior oil-globules, which are then ejected into the lumen of the alveolus and constitute the milk-globules.

The *fibrous tissue* invests the entire surface of the breast, and sends down septa between its lobes, connecting them together.

The *fatty tissue* surrounds the surface of the gland, and occupies the intervals between its lobes and lobules. It usually exists in considerable abundance, and determines the form and size of the gland. There is no fat immediately beneath the areola and nipple.

VESSELS AND NERVES.—The *arteries* supplying the mammæ are derived from the thoracic branches of the axillary, the intercostals, and the internal mammary. The *veins* describe an anastomotic circle round the base of the nipple, called by Haller the *circulus venosus*. From this large branches transmit the blood to the circumference of the gland, and end in the axillary and internal mammary veins. The *lymphatics*, for the most part, run along the lower border of the Pectoralis major to the axillary glands. [These are especially important from the frequent occurrence of carcinoma in the breast.] Some few from the inner side of the breast perforate the intercostal spaces and empty themselves into the anterior mediastinal glands. The *nerves* are derived from the anterior and lateral cutaneous nerves of the thorax.

The Surgical Anatomy of Inguinal Hernia.

Dissection (Fig. 663).—For dissection of the parts concerned in inguinal hernia a male subject free from fat should always be selected. The body should be placed in the supine position, the abdomen and pelvis raised by means of blocks placed beneath them, and the lower extremities rotated outward, so as to make the parts as tense as possible. If the abdominal walls are flaccid, the cavity of the abdomen should be inflated by an aperture through the umbilicus. An incision should be made along the middle line from the umbilicus to the pubes, and continued along the front of the scrotum, and a second incision from the anterior superior spine of the ilium to just below the umbilicus. These incisions should divide the integument, and the triangular-shaped flap included between them should be reflected downward and outward, when the superficial fascia will be exposed.

The **Superficial Fascia** in this region consists of two layers, between which are found the superficial vessels and nerves and the inguinal lymphatic glands.

The *superficial layer* is thick, areolar in texture, containing adipose tissue in its meshes, the quantity of which varies in different subjects. Below, it passes over Poupart's ligament, and is continuous with the outer layer of the superficial fascia of the thigh. This fascia is continued as a tubular prolongation around the outer surface of the cord and testis. In this situation it changes its character; it becomes thin, destitute of adipose tissue, and of a pale reddish color, and assists in forming the dartos. From the scrotum it may be traced backward to be continuous with the superficial fascia of the perineum. This layer should be removed, by dividing it across in the same direction as the external incisions and reflecting it downward and outward, when the following vessels and nerves will be exposed: The superficial epigastric, superficial circumflex iliac, and superficial external pudic vessels, the terminal filaments of the hypogastric branch of the ilio-hypogastric nerve, and the upper chain of inguinal lymphatic glands.

The *superficial epigastric artery* crosses Poupart's ligament, and ascends obliquely toward the umbilicus, lying midway between the spine of the ilium and the pubes. It supplies the integument and anastomoses with the deep epigastric. This vessel is a branch of the common femoral artery, and passes through the saphenous opening of the fascia lata. Its accompanying vein empties itself into the internal saphenous after having pierced the cribriform fascia.

The *superficial circumflex iliac artery* passes outward toward the crest of the ilium, generally lying below the level of Poupart's ligament, and sending only a few branches upward to the abdomen.

The *superficial external pudic artery* passes transversely inward across the spermatic cord, and supplies the integument of the hypogastric region and of the penis and scrotum. This vessel is usually divided in the first incision made in the operation for inguinal hernia, and occasionally requires the application of a ligature.

The veins accompanying these superficial vessels are usually much larger than the arteries: they terminate in the internal saphenous vein.

Lymphatic vessels are found, taking the same course as the blood-vessels: they return the lymph from the superficial structures in the lower part of the abdomen, the scrotum, penis, mucous membrane of the urethra, perineal and gluteal regions, and terminate in a small chain of lymphatic glands, three or four in number, which lie on a level with Poupart's ligament.

NERVES.—The hypogastric branch of the ilio-hypogastric nerve perforates the aponeurosis of the external oblique above and to the outer side of the external ring, and is distributed to the integument covering the hypogastric region. The ilio-inguinal nerve may also be seen emerging at the external abdominal ring and passing down to supply the skin of the scrotum and inner side of the thigh.

The *deep layer of superficial fascia* should be divided across in the same direction as the external incisions, separated from the aponeurosis of the External oblique, to which it is connected by delicate areolar tissue, and reflected downward and outward. It is thin, aponeurotic in structure, and of considerable strength. It is intimately adherent in the middle line to the linea alba, and below to the whole length of Poupart's ligament and the upper part of the fascia lata. It forms a thin tubular prolongation round the outer surface of the cord, and is continuous with the dartos of the scrotum. From the back of the scrotum it may be traced into the perineum, where it is continuous with the deep layer of the superficial fascia in that region, which is attached behind to the triangular ligament and on each side to the ramus of the pubes and ischium. The connections of this fascia serve to explain the course taken by the urine in extravasation of that fluid from rupture of the urethra: passing forward from the perineum into the scrotum, it ascends on to the abdomen, but is prevented extending into the thighs by the attachment of the fascia to the ramus of the pubes and ischium on each side, and to Poupart's ligament in front, and is prevented from passing on to the buttock by the posterior connections of the perineal fascia.

Fig. 663.

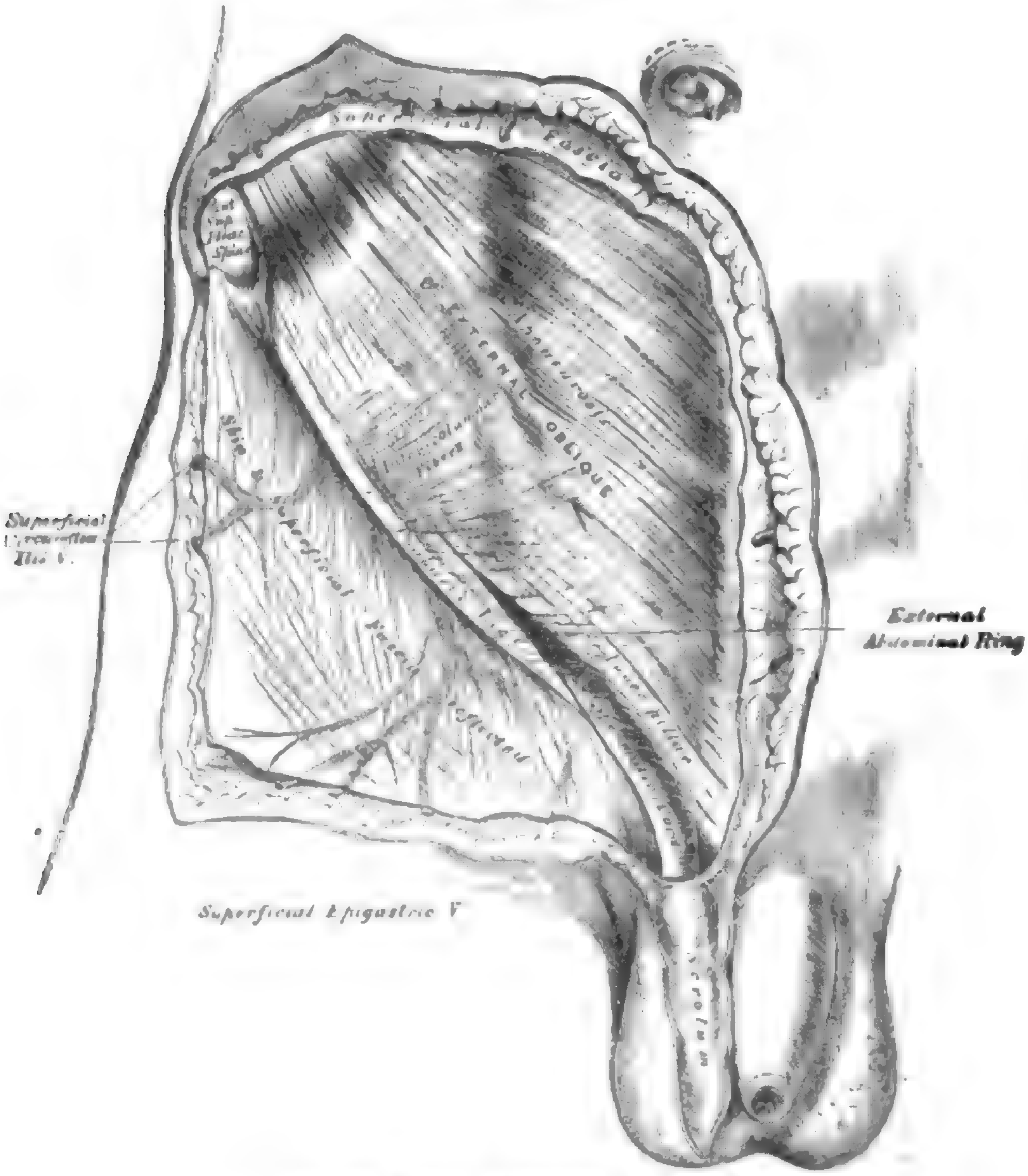
Superficial Fascia
Ant. Sup. Iliac Spine
External Oblique
Intercolumnar fibres
Superficial Circumflex Ilii V.
Superficial fascia reflected
External Abdominal Ring
Superficial Epigastric V
Scrotum

Inguinal Hernia, superficial dissection.

The **aponeurosis of the External oblique muscle** is exposed on the removal of this fascia. It is a thin, strong, membranous aponeurosis, the fibres of which are directed obliquely downward and inward. It is attached to the anterior superior spinous process of the ilium, the spine of the pubes, the linea ilio-pectinea, symphysis pubis, and linea alba. That portion of the aponeurosis which extends from the anterior superior spine of the ilium to the spine of the pubes is termed *Poupart's ligament* or the *crural arch* [Fig. 671, p. 1006]. From its attachment to the spine of the pubes a portion of the aponeurosis is reflected downward and outward to be inserted into the pectineal line: this is termed *Gimbernat's ligament.*

The External Abdominal Ring.—Just above and to the outer side of the crest of the pubes an interval is seen in the aponeurosis of the External oblique, called the *external abdominal ring.* This aperture is oblique in direction, somewhat triangular in form, and corresponds with the course of the fibres of the aponeurosis. It usually measures from base to apex about an inch, and transversely about half an inch. It is bounded below by the crest of the os pubis; above by a series of curved fibres, the *intercolumnar,* which pass across the upper angle of the ring, so as to increase its strength; and on either side by the free borders of the aponeurosis, which are called the *columns* or *pillars of the ring.*

The *external pillar,* which at the same time is inferior from the obliquity of its direction, is the stronger; it is formed by that portion of Poupart's ligament which is inserted into the spine of the pubes; it is curved round the spermatic cord so as to form a kind of groove, upon which the cord rests.

The *internal* or *superior pillar* is a broad, thin, flat band which interlaces with its fellow on the opposite side in front of the symphysis pubis, that of the right side being superficial.

The external abdominal ring gives passage to the spermatic cord in the male and round ligament in the female; it is much larger in men than in women, on account of the large size of the spermatic cord, and hence the great frequency of inguinal hernia in men. [It is called a "ring," because after a hernial protrusion occurs it really becomes circular, though not of that shape before.]

The *intercolumnar fibres* are a series of curved tendinous fibres which arch across the lower part of the aponeurosis of the External oblique. They have received their name from stretching across between the two pillars [or columns] of the external ring; they increase the strength of the membrane which bounds the upper part of this aperture, and prevent the divergence of the pillars from one another. They are thickest below, where they are connected to the outer third of Poupart's ligament, and are inserted into the linea alba, describing a curve with the convexity downward. They are much thicker and stronger at the outer angle of the external ring than internally, and are more strongly developed in the male than in the female. These fibres are continuous with a thin fascia which is closely connected to the margins of the external ring, and has received the name of the *intercolumnar* or *external spermatic fascia;* it forms a tubular prolongation around the outer surface of the cord and testis and encloses them in a distinct sheath. The sac of an inguinal hernia in passing through the external abdominal ring receives an investment from the intercolumnar fascia.

[To examine the external ring, place the finger on the middle of the scrotum and push it upward into the ring, carrying before it the pouch of scrotum so formed. This examination the student should make whenever possible, both in persons who have no hernia, to get an idea of the normal condition of the ring and cord, and in those who have a hernia, in order to recognize the changes in this condition. In the female the examination of the ring is much less satisfactory.]

The finger should be introduced a short distance into the external ring, and then, if the limb is extended and rotated outward, the aponeurosis of the External oblique, together with the iliac portion of the fascia lata, will be felt to become tense, and the external ring much contracted; if, on the contrary, the limb is flexed upon the pelvis and rotated inward, this aponeurosis will become lax, and the external ring sufficiently enlarged to admit the finger with comparative ease; hence the patient should always be put in the latter position when the taxis is applied for the reduction of an inguinal hernia, in order that the abdominal walls may be as much relaxed as possible.

The aponeurosis of the External oblique should be removed by dividing it across in the same direction as the external incisions, and reflecting it downward and outward; great care is requisite in separating it from the aponeurosis of the muscle beneath. The lower part of the Internal oblique and the Cremaster are then exposed, together with the inguinal canal, which contains the

spermatic cord (Fig. 664). The mode of insertion of Poupart's and Gimbernat's ligaments into the pubes should also be examined.

Poupart's ligament, or the femoral arch, extends from the anterior superior spine of the ilium to the spine of the pubes. It is also attached to the pectineal line to the extent of about an inch, forming Gimbernat's ligament. Its general direction is curved toward the thigh, where it is continuous with the fascia lata. Its outer half is rounded, oblique in its direction, and continuous with the iliac fascia. Its inner half gradually widens at its attachment to the pubes, is more horizontal in direction, and lies beneath the spermatic cord. [In every case of hernia or other disease in this region the only safe way to determine its real situation is to *fix* the bony attachments of the two ends of Poupart's ligament by *touch*. Its line should then be marked by an aniline ("indelible") pencil. The eye is very apt to be deceived by the furrow of the groin caused by flexure at the hip-joint. This furrow is a little below Poupart's ligament, and is apt to mislead us as to whether a hernia is femoral or inguinal. Once that the line of Poupart's ligament is *accurately* fixed, as above, a hernia that emerges above that line must be inguinal, and one below it must be femoral.]

Fig. 664.

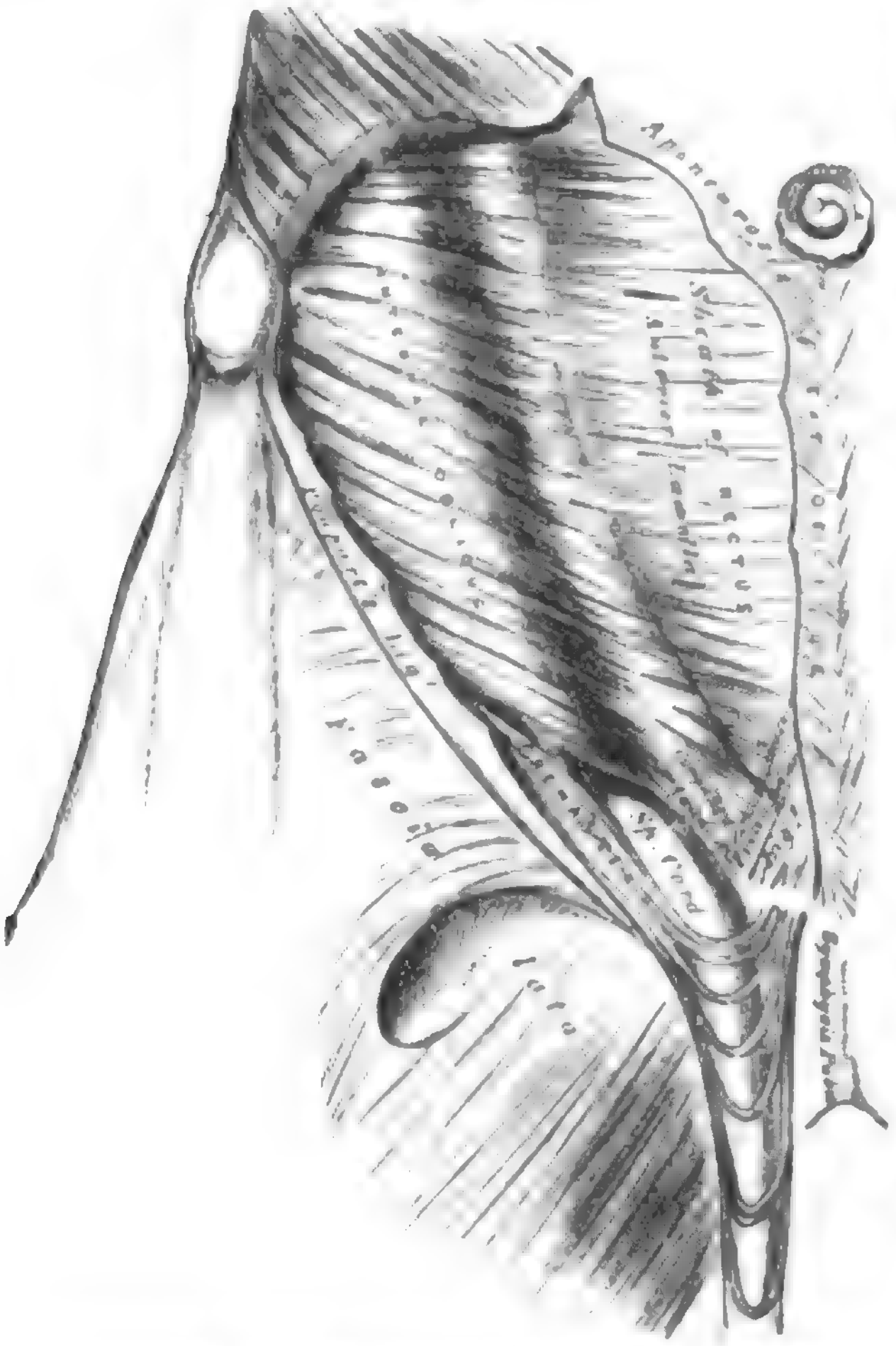

Inguinal Hernia, showing the Internal Oblique, Cremaster, and Spermatic Canal.

Gimbernat's ligament [Figs. 671 and 672, p. 1006] is that portion of the aponeurosis of the External oblique which is inserted into the pectineal line; it is thin, membranous in structure, triangular in shape, the base directed outward, the apex corresponding to the spine of the pubes. Its anterior margin is continuous with Poupart's ligament, and its posterior margin attached to the pectineal line.

The **triangular ligament** is a band of tendinous fibres, of a triangular shape, which is attached by its apex to the reflected portion of Poupart's ligament along the pectineal line. It passes inward beneath the spermatic cord, and expands into a somewhat fan-shaped fascia, lying behind the inner pillar of the external abdominal ring and in front of the conjoined tendon, and interlaces with the ligament of the other side at the linea alba.

The **Internal oblique muscle** has been described (p. 414). The part which is now exposed is partly muscular and partly tendinous in structure. Those fibres which arise from the outer half of Poupart's ligament are thin, pale in color, curve downward, and terminate in an aponeurosis which passes in front of the Rectus and Pyramidalis muscles, to be inserted into the crest of the os pubis and pectineal line to the extent of half an inch, in common with that of the Transversalis muscle, forming by their junction the "conjoined tendon." This tendon is placed behind Gimbernat's ligament and the external abdominal ring, being separated from them by the triangular ligament, and serves to strengthen what would otherwise be a very weak point in the abdominal wall. When a direct inguinal hernia passes through the external ring the conjoined tendon usually forms one of its coverings.

The **Cremaster** is a thin muscular layer composed of a number of fasciculi which arise from the middle of Poupart's ligament at the inner side of the Internal oblique, being connected with that muscle and also occasionally with the Transversalis. It passes along the outer side of the spermatic cord, descends with it through the external ring upon the front and sides of the cord, and forms a series of loops which differ in thickness and length in different subjects. Those at the upper part of the cord are exceedingly short, but they become in succession longer and longer, the longest reaching down as low as the testicle, where a few are inserted into the tunica vaginalis. These loops are united together by areolar tissue, and form a thin covering over the cord, the *fascia cremasterica*. The fibres ascend along the inner side of the cord, and are inserted by a small pointed tendon into the crest of the os pubis and front of the sheath of the Rectus muscle. It is supplied by the genital branch of the genito-crural nerve. [Part of this muscle is unstriped muscular fibre, but part consists of striped voluntary fibres. Many persons can voluntarily contract the muscle and elevate the testicle almost to the external ring. It responds also to mechanical irritation of the skin of the upper and inner thigh by drawing the finger or a pencil, etc. quickly across it, thus forming the "Cremaster reflex," analogous to the patellar and other similar reflexes. (See also p. 746.)]

It will be observed that the origin and insertion of the Cremaster are precisely similar to those of the lower fibres of the Internal oblique. This fact affords an easy explanation of the manner in which the testicle and cord are invested by this muscle. At an early period of fœtal life the testis is placed at the lower and back part of the abdominal cavity, but during its descent toward the scrotum, which takes place before birth, it passes beneath the arched border of the Internal oblique. In its passage beneath this muscle some fibres are derived from its lower part, which accompany the testicle and cord into the scrotum. [See p. 975 for the correct view of the Cremaster in relation to the descent of the testicle.]

It occasionally happens that the loops of the Cremaster surround the cord, some lying behind as well as in front. It is probable that under these circumstances the testis in its descent passed through instead of beneath the fibres of the Internal oblique.

In the descent of an oblique inguinal hernia, which takes the same course as the spermatic cord, the Cremaster muscle forms one of its coverings. This muscle becomes largely developed in case of hydrocele and large old scrotal herniæ. No such muscle exists in the female, but an analogous structure is developed in those cases where an oblique inguinal hernia descends beneath the margin of the Internal oblique.

The Internal oblique should be detached from Poupart's ligament, separated from the Transversalis to the same extent as in the previous incisions, and reflected inward on to the sheath of the Rectus (Fig. 665). The circumflex iliac vessels, which lie between these two muscles, form a valuable guide to their separation.

The **Transversalis muscle** has been previously described (p. 415). Its lower portion is partly fleshy and partly tendinous in structure; this portion arises from the outer third of Poupart's ligament, and, arching downward and inward over the cord, terminates in an aponeurosis which is inserted into

FIG. 665.

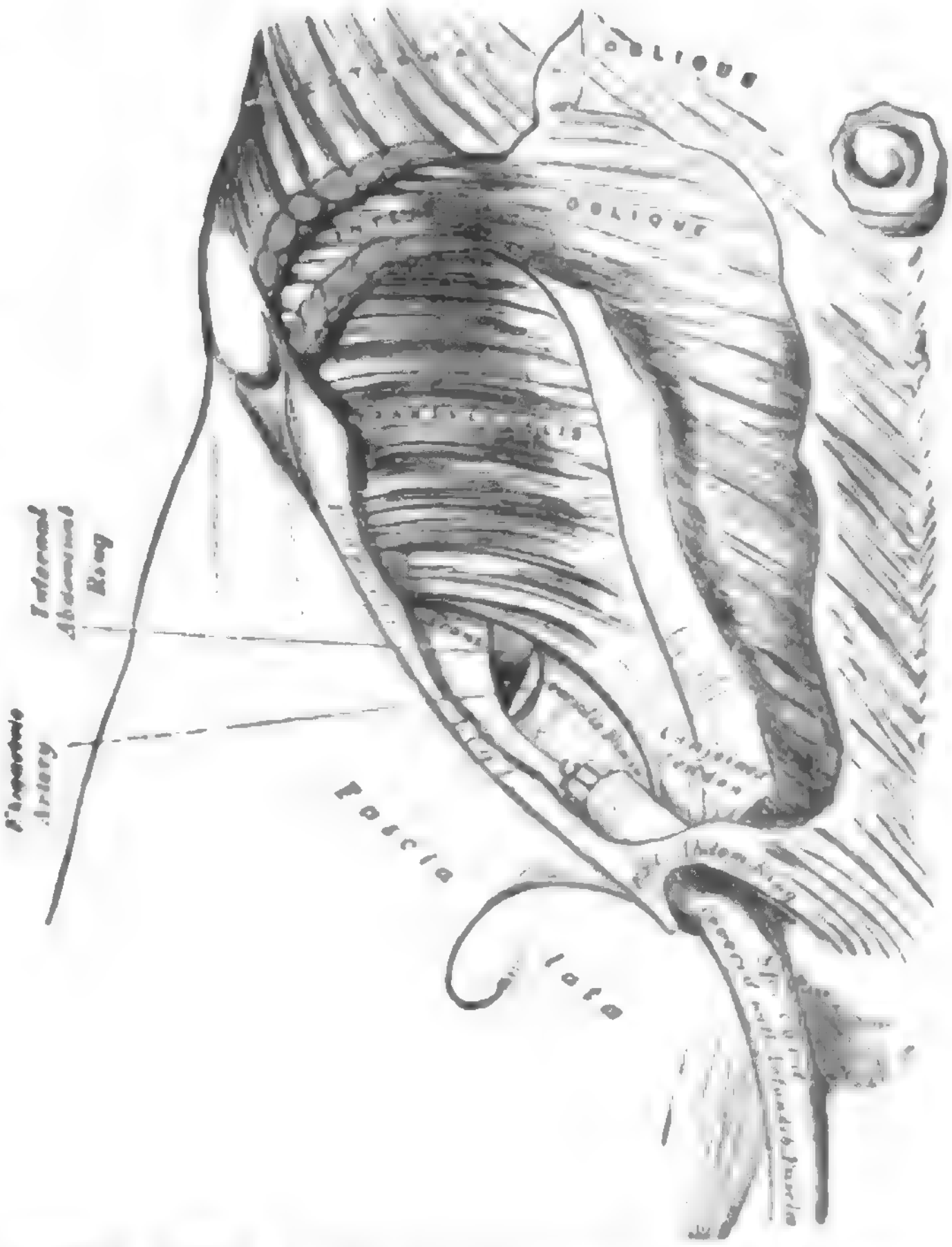

Inguinal Hernia, showing the Transversalis Muscle, the Transversalis Fascia, and the Internal Abdominal Ring.

the linea alba, the crest of the pubes, and the pectineal line to the extent of an inch, forming, together with the Internal oblique, the conjoined tendon. Between the lower border of this muscle and Poupart's ligament a space is left in which is seen the fascia transversalis.

The **Inguinal** or **Spermatic Canal** contains the spermatic cord in the male and the round ligament in the female. It is an oblique canal about an inch and a half in length, directed downward and inward, and placed parallel with and a little above Poupart's ligament. It commences above at the internal abdominal ring, which is the point where the cord enters the spermatic canal, and terminates below at the external ring. It is bounded *in front* by the integument and superficial fascia, by the aponeurosis of the External oblique throughout its whole length, and by the Internal oblique for its outer third; *behind*, by the triangular ligament, the conjoined tendon of the Internal oblique and Transversalis, transversalis fascia, and the subperitoneal fat and peritoneum; *above*, by the arched fibres of the Internal oblique and Transversalis; *below*, by the union of the fascia transversalis with Poupart's ligament. That form of protrusion in which the intestine follows the course of the spermatic cord along the spermatic canal is called *oblique inguinal hernia*.

The **Fascia Transversalis** is a thin aponeurotic membrane which lies between the inner surface of the Transversalis muscle and the peritoneum. It forms part of the general layer of fascia which lines the interior of the abdominal and pelvic cavities, and is directly continuous with the iliac and pelvic fasciæ.

In the inguinal region the transversalis fascia is thick and dense in structure, and joined by fibres from the aponeurosis of the Transversalis, but it becomes thin and cellular as it ascends to the Diaphragm. Below, it has the following attachments: External to the femoral vessels it is connected to the posterior margin of Poupart's ligament, and is there continuous with the iliac fascia; internal to the vessels it is thin, and attached to the pubes and pectineal line behind the conjoined tendon, with which it is united; and, corresponding to the points where the femoral vessels pass into the thigh, this fascia descends in front of them, forming the anterior wall of the femoral sheath.

The **Internal Abdominal Ring** is situated in the transversalis fascia, midway between the anterior superior spine of the ilium and the symphysis pubis, and about half an inch above Poupart's ligament. It is of an oval form, the extremities of the oval directed upward and downward, varies in size in different subjects, and is much larger in the male than in the female. It is bounded above and externally by the arched fibres of the Transversalis muscle, below and internally by the epigastric vessels. It transmits the spermatic cord in the male and the round ligament in the female, and from its circumference a thin, funnel-shaped membrane, *the infundibuliform fascia*, is continued round the cord and testis, enclosing them in a distinct pouch. When the sac of an oblique inguinal hernia passes through the internal ring, the infundibuliform process of the transversalis fascia forms one of its coverings.

Between the fascia transversalis and the peritoneum is a quantity of loose areolar tissue. In some subjects it is of considerable thickness and loaded with adipose tissue. Opposite the internal ring it is continued round the surface of the cord, forming a loose sheath for it.

The *epigastric artery* bears a very important relation to the internal abdominal ring. This vessel lies between the transversalis fascia and peritoneum, and passes obliquely upward and inward from its origin from the external iliac to the margin of the sheath of the Rectus muscle. In this course it lies along the lower and inner margin of the internal ring and beneath the commencement of the spermatic cord, the vas deferens curving round it as it passes from the ring into the pelvis.

The **Peritoneum**, corresponding to the inner surface of the internal ring, presents a well-marked depression, the depth of which varies in different subjects. A thin fibrous band is continued from it along the front of the cord for a variable distance, and becomes ultimately lost. This is the remains of the pouch of peritoneum which in the fœtus accompanies the cord and testis into the scrotum, the obliteration of which commences soon after birth. In some cases the fibrous band can only be traced a short distance, but occasionally it may be followed as a fine cord as far as the upper end of the tunica vaginalis. Sometimes the tube of peritoneum is only closed at intervals and presents a sacculated appearance, or a single pouch may extend along the whole length of the cord, which may be closed above, or the pouch may be directly continuous with the peritoneum by an opening at its upper part.

[General Remarks upon Hernia.]

[Herniæ in different parts of the body (with the exception of ventral and diaphragmatic herniæ) are rendered possible by the necessity for openings in the abdominal walls, generally for the passage of certain structures out of or into the abdominal cavity—*e. g.* the spermatic cord, the femoral, umbilical, and other vessels. Internal to all such openings is the peritoneum (Fig. 666, 1), and externally are the superficial fascia and skin (Fig. 666, 5 and 6). We have then three coverings—viz. peritoneum, superficial fascia, and skin, common to all the usual varieties of hernia; and, as every hernia has six coverings, there remain but three coverings peculiar to each individual kind of hernia.

In the passage of the structures above referred to through the abdominal wall there must be a *canal*, with an *internal* opening (Fig. 666, 2) and an *external* opening (Fig. 666, 4). Each of these openings in the normal condition is *closed* by a fascia or other tissue. These two fasciæ, therefore, being pushed before a hernia, will form two of the peculiar coverings of each hernia. The third peculiar covering is found always *in* the *canal* (Fig. 666, 3). The following figure and table will be found very useful in remembering these various openings and coverings:

[Fig. 666.

Diagram of the Coverings of Herniæ.

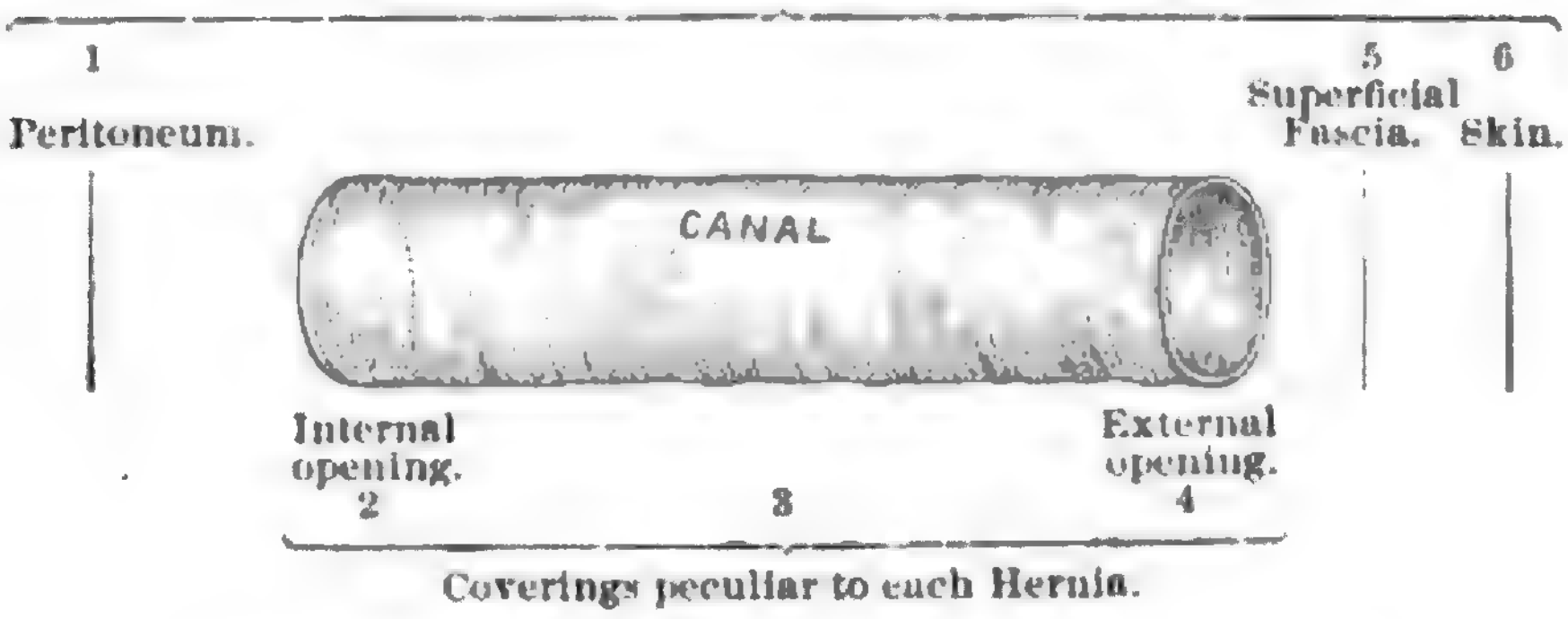

Table of the Peculiar Coverings of Herniæ.

Variety of Hernia.	2. Internal Opening.	3. Canal.	4. External Opening.
1. Oblique Inguinal	Internal abdominal ring closed by the *Infundibular fascia.*	Inguinal canal. *Cremaster muscle.*	External abdominal ring closed by the *Intercolumnar fascia.*
2. Direct Inguinal	Abnormal opening closed by the *Transversalis fascia.*	Abnormal canal. *Conjoined tendon.*	External abdominal ring closed by the *Intercolumnar fascia.*
3. Femoral	Femoral ring closed by the *Septum crurale* (or *femorale*).	Femoral. *Femoral sheath or fascia propria.*	Saphenous opening closed by the *Cribriform fascia.*]

INGUINAL HERNIA.

Inguinal Hernia is that form of protrusion which makes its way through the abdomen in the inguinal region.

There are two principal varieties of inguinal hernia—external or oblique, and internal or direct.

External or *oblique inguinal hernia*, the more frequent of the two, takes the same oblique course as the spermatic cord. It is called *external*, from the neck of the sac being on the outer or iliac side of the epigastric artery.

Internal or *direct inguinal hernia* does not follow the same course as the cord, but protrudes through the abdominal wall on the inner or pubic side of the epigastric artery.

Oblique Inguinal Hernia.

In **oblique inguinal hernia** the intestine escapes from the abdominal cavity at the internal ring, pushing before it a pouch of peritoneum which forms the hernial sac (Fig. 667, A). As it enters the inguinal canal it receives an investment from the subserous areolar tissue, and is enclosed in the infundibuliform process of the transversalis fascia. In passing along the inguinal canal it displaces upward the arched fibres of the Transversalis and Internal oblique muscles, and is surrounded by the fibres of the Cremaster. It then passes along the front of the cord, and escapes from the inguinal canal at the external ring, receiving investments from the intercolumnar fascia and also the superficial fascia and the integument. Lastly, it may descend into the scrotum.

Fig. 667.

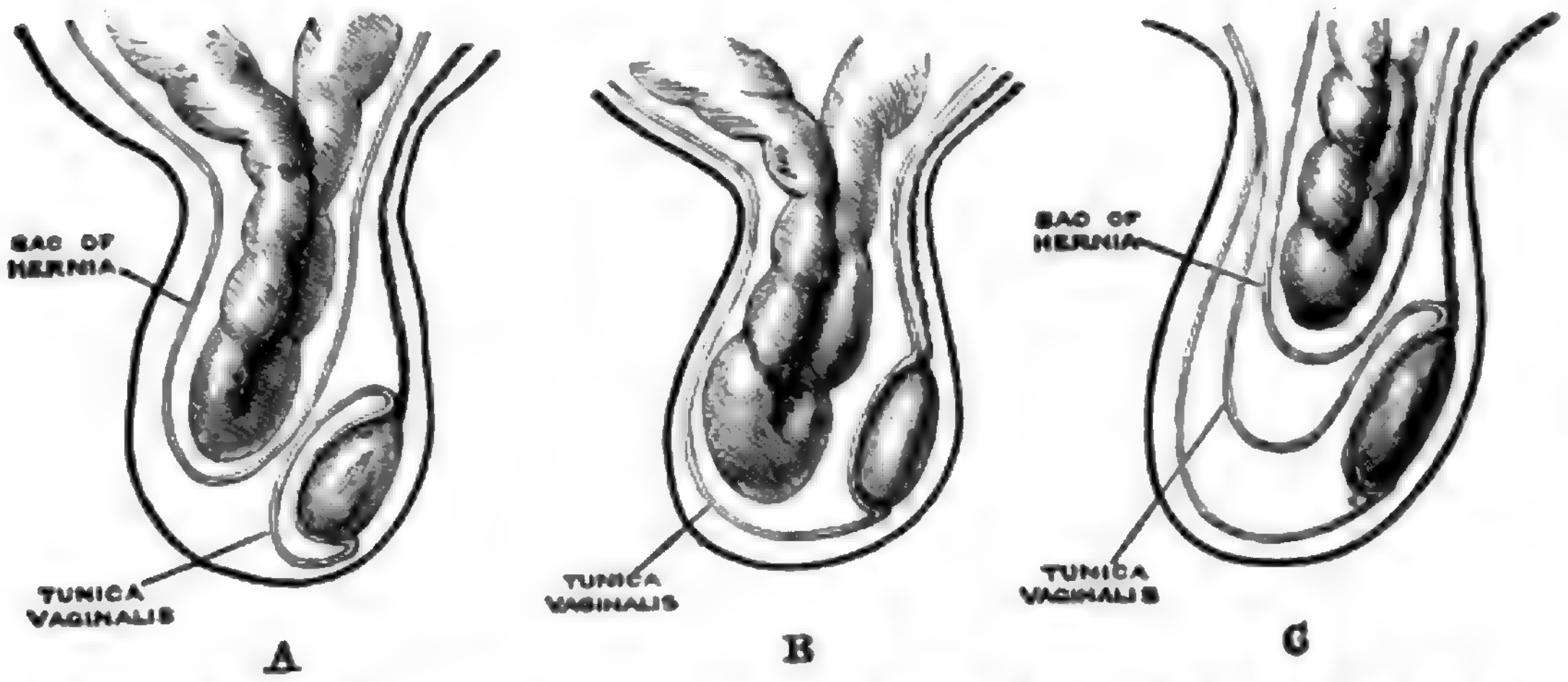

Varieties of Oblique Inguinal Hernia: A, common scrotal hernia, showing the relation of the sac to the tunica vaginalis. B, congenital hernia, the sac being continuous with the tunica vaginalis. C, infantile hernia, showing the relation of the sac to the tunica vaginalis, the latter being prolonged in front of the sac.

The coverings of this form of hernia, after it has passed through the external ring, are, from without inward, the integument, superficial fascia, intercolumnar fascia, Cremaster muscle, infundibuliform fascia, subserous areolar tissue, and peritoneum.

This form of hernia lies in front of the vessels of the spermatic cord, and seldom extends below the testis, on account of the intimate adhesion of the coverings of the cord to the tunica vaginalis.

The *seat of stricture* in oblique inguinal hernia is either at the external ring in the inguinal canal, caused by the fibres of the Internal oblique or Transversalis, or at the internal ring, most frequently in the latter situation. If it is situated at the external ring, the division of a few fibres at one point of its circumference is all that is necessary for the replacement of the hernia. If in the inguinal canal or at the internal ring, it may be necessary to divide the aponeurosis of the External oblique so as to lay open the inguinal canal. In dividing the stricture the direction of the incision should be upward.

When the intestine passes along the inguinal canal, and, escaping from the external ring, passes into the scrotum, it is called *complete oblique inguinal* or *scrotal hernia*. If the intestine does not escape from the external ring, but is retained in the inguinal canal, it is called *incomplete inguinal hernia* or *bubonocele*. In each of these cases the coverings which invest it will depend upon the extent to which it descends in the inguinal canal.

There are two other varieties of oblique inguinal hernia—the congenital and infantile.

Congenital hernia (Fig. 667, B) is liable to occur in those cases where the pouch of peritoneum which accompanies the cord and testis in its descent in the fœtus remains unclosed and communicates directly with the peritoneum. The intestine descends along this pouch into the cavity of the tunica vaginalis and lies in contact with the testis. This form of hernia has no proper sac, being contained within the tunica vaginalis.

In *infantile hernia* (encysted) (Fig. 667, C) the pouch of peritoneum forming the tunica vaginalis becomes obliterated at its upper part, generally at or near the external abdominal ring; below this the pouch does not become closed, but forms a large cavity in which the testicle is contained. The hernial sac descends along the inguinal canal, and enters the scrotum behind the tunica vaginalis. As it descends it becomes more or less completely invested by the posterior layer of the tunica vaginalis, from which it is separated by a little loose areolar tissue; so that in operating upon this variety of hernia three layers of peritoneum would require division, the first and second being the layers of the tunica vaginalis, the third the anterior layer of the hernial sac.

DIRECT INGUINAL HERNIA.

In direct inguinal hernia the protrusion makes its way through some part of the abdominal wall internal to the epigastric artery, and passes directly through the abdominal parietes and external ring. At the lower part of the abdominal wall is a triangular space (*Hesselbach's triangle*) bounded externally by the deep epigastric artery, internally by the margin of the Rectus muscle, below by Poupart's ligament [Fig. 672, p. 1006]. The conjoined tendon is stretched across the inner two-thirds of this space, the remaining portion of the space being filled in by the transversalis fascia.

In some cases the hernial protrusion escapes from the abdomen on the outer side of the conjoined tendon, pushing before it the peritoneum, the subserous areolar tissue, and the transversalis fascia. It then enters the inguinal canal, passing along nearly its whole length, and finally emerges from the external ring, receiving an investment from the intercolumnar fascia. The coverings of this form of hernia are precisely similar to those investing the oblique form.[1]

In other cases the intestine is either forced through the fibres of the conjoined tendon, or the tendon is gradually distended in front of it so as to form a complete investment for it. The intestine then enters the lower end of the inguinal canal, escapes at the external ring lying on the inner side of the cord, and receives additional coverings from the superficial fascia and the integument. This form of hernia has the same coverings as the oblique variety, excepting that the conjoined tendon is substituted for the Cremaster, and the infundibuliform fascia is replaced by a part of the general fascia transversalis.

The *seat of stricture* in both varieties of direct hernia is most frequently at the neck of the sac or at the external ring. In that form of hernia which perforates the conjoined tendon it not unfrequently occurs at the edges of the fissure through which the gut passes. In dividing the stricture the incision should in all cases be directed upward.[1]

---

[1] The difference between the position of the neck of the sac in these two forms of direct inguinal hernia has been referred, with some probability, to a difference in the relative positions of the obliterated hypogastric artery and the epigastric artery. The projection of the hypogastric artery toward the cavity of the abdomen produces two fossæ in the peritoneum. When the course of the obliterated hypogastric artery corresponds pretty nearly with that of the epigastric—which is regarded as the normal arrangement—the bottom of the external fossa of the peritoneum corresponds to the position of the internal abdominal ring, and a hernia which distends and pushes out the peritoneum lining this fossa is an oblique hernia. When, on the other hand, the obliterated hypogastric artery lies considerably to the inner side of the epigastric, it divides the triangle of Hesselbach into two parts. In that case a hernia may distend and push out the peritoneum forming the bottom of the fossa bounded externally by the epigastric artery and internally by the obliterated hypogastric artery, and by so doing will protrude the tissues which form the abdominal wall between the internal ring and the conjoined tendon. It will be a direct hernia, since the neck of the sac lies internal to the epigastric artery; but its coverings, as stated in the text, will be identical with those of the oblique form, with the insignificant difference that the covering from the transversalis fascia is taken from another portion of that fascia, and not from its infundibuliform process.

If the hernial protrusion passes into the inguinal canal, but does not escape from the external abdominal ring, it forms what is called *incomplete direct hernia.* This form of hernia is usually of small size, and in corpulent persons very difficult of detection.

Direct inguinal hernia is of much less frequent occurrence than the oblique, their comparative frequency being, according to Cloquet, as one to five. It occurs far more frequently in men than in women, on account of the larger size of the external ring in the former sex. It differs from the oblique in its smaller size and globular form, dependent most probably on the resistance offered to its progress by the transversalis fascia and conjoined tendon. It differs also in its position, being placed over the pubes and not in the course of the inguinal canal. The epigastric artery runs on the outer or iliac side of the neck of the sac, and the spermatic cord along its external and posterior side, not directly behind it, as in oblique inguinal hernia.

SURGICAL ANATOMY OF FEMORAL HERNIA.

The dissection of the parts comprised in the anatomy of femoral hernia should be performed, if possible, upon a female subject free from fat. The subject should lie upon its back; a block is first placed under the pelvis, the thigh everted, and the knee slightly bent, and retained in this position. An incision should then be made from the anterior superior spinous process of the ilium along Poupart's ligament to the symphysis pubis; a second incision should be carried transversely across the thigh about six inches beneath the preceding; and these are to be connected together by a vertical one carried along the inner side of the thigh. These several incisions should divide merely the integument; this is to be reflected outward, when the superficial fascia will be exposed.

[Consult General Remarks upon Hernia, and Fig. 666, p. 997.]

The **superficial fascia** at the upper part of the thigh consists of two layers, between which are found the cutaneous vessels and nerves and numerous lymphatic glands.

The *superficial layer* is a thick and dense fibro-cellular membrane, in the meshes of which is found a considerable amount of adipose tissue, varying in quantity in different subjects; this layer may be traced upward over Poupart's ligament to be continuous with the superficial fascia of the abdomen; whilst below and on the inner and outer sides of the limb it is continuous with the superficial fascia covering the rest of the thigh.

This layer should be detached by dividing it across in the same direction as the external incisions; its removal will be facilitated by commencing at the lower and inner angle of the space, detaching it at first from the front of the internal saphenous vein, and dissecting it off from the anterior surface of that vessel and its branches; it should then be reflected outward in the same manner as the integument. The cutaneous vessels and nerves and superficial inguinal glands are then exposed, lying upon the deep layer of the superficial fascia. These are the internal saphenous vein and the superficial epigastric, superficial circumflex iliac, and superficial external pudic vessels, as well as numerous lymphatics ascending with the saphenous vein to the saphenous glands.

The *internal saphenous vein* is a vessel of considerable size which ascends obliquely upward along the inner side of the thigh. It passes through the saphenous opening in the fascia lata to terminate in the femoral vein. This vessel is accompanied by numerous lymphatics, which return the lymph from the dorsum of the foot and inner side of the leg and thigh: they terminate in the glands which surround the saphenous opening. Diverging from the same point are the superficial epigastric vessels, which run across Poupart's ligament obliquely upward and inward to the lower part of the abdomen; the superficial circumflex iliac vessels, which pass obliquely outward along Poupart's ligament to the crest of the ilium; and the superficial external pudic vessels, which pass inward to the perineum and scrotum. These vessels supply the subcutaneous areolar tissue and the integument, and are accompanied by numerous lymphatic vessels which return the lymph from the same parts to the inguinal glands.

---

[1] In all cases of inguinal hernia, whether oblique or direct, it is proper to divide the stricture directly upward; the reason of this is obvious, for by cutting in this direction the incision is made parallel to the epigastric artery—either external to it in the oblique variety, or internal to it in the direct form of hernia—and thus all chance of wounding the vessel is avoided. If the incision was made outward, the artery might be divided if the hernia was direct, and if made inward it would stand an equal chance of injury if the case was one of oblique inguinal hernia.

The *superficial lymphatic glands* are arranged in two groups, one of which is disposed above and parallel with Poupart's ligament, and the other below the ligament surrounding the termination of the saphenous vein, and following (occasionally) the course of that vessel a short distance along the thigh. The upper chain receives the lymphatic vessels from the genital organs, lower part of the abdomen, perineum, and buttock; the lower chain receives the lymphatic vessels from the lower extremity.

The *nerves* supplying the integument of the region are derived from the ilio-inguinal, the genito-crural, and anterior crural. The ilio-inguinal nerve may be found on the inner side of the internal saphenous vein, the terminal branch of the genito-crural nerve outside the vein, and the middle and external cutaneous nerves more external.

The *deep layer* of superficial fascia should be divided in the same direction as the external incisions, and separated from the fascia lata; this is easily effected to the inner side of the saphenous vein, when it forms a distinct though very thin membrane. External to the vein it can scarcely be separated as a continuous layer. It is placed beneath the subcutaneous vessels and nerves and upon the surface of the fascia lata. It is intimately adherent above to the lower margin of Poupart's ligament, and about one inch below this ligament covers the saphenous opening in the fascia lata, is closely united to its circumference, and is connected to the sheath of the femoral vessels corresponding to its under surface. The portion of fascia covering this aperture is perforated by the internal saphenous vein, and by numerous blood- and lymphatic vessels; hence it has been termed the *cribriform fascia*, the openings of these vessels having been likened to the holes in a sieve. The cribriform fascia adheres closely both to the superficial fascia and the fascia lata, so that it is described by some anatomists as a part of the fascia lata, but is usually considered (as in this work) as belonging to the superficial fascia. It is not till the cribriform fascia has been cleared away that the saphenous opening is seen, so that this opening does not in ordinary cases exist naturally, but is the result of dissection. Mr. Callender, however, speaks of cases in which, probably as the result of pressure from enlarged inguinal glands, the fascia has become atrophied and a saphenous opening exists independent of dissection.[1] A femoral hernia in passing through the saphenous opening receives the cribriform fascia as one of its coverings.

The deep layer of superficial fascia, together with the cribriform fascia, having been removed, the fascia lata is exposed.

The **Fascia Lata**, already described (p. 465), is a dense fibrous aponeurosis which forms a uniform investment for the whole of this region of the limb. At the upper and inner part of the thigh a large oval-shaped aperture is observed in it, which transmits the internal saphenous vein and other smaller vessels and is called the *saphenous opening*. In order the more correctly to consider the mode of formation of this aperture, the fascia lata in this part of the thigh is described as consisting of two portions, an iliac portion and a pubic portion.

The *iliac portion* of the fascia lata is situated on the outer side of the saphenous opening, covering the outer surface of the Sartorius, the Rectus, the Psoas, and the Iliacus muscles. It is attached externally to the crest of the ilium, and its anterior superior spine to the whole length of Poupart's ligament as far internally as the spine of the pubes, and to the pectineal line in conjunction with Gimbernat's ligament, where it becomes continuous with the pubic portion. From the spine of the pubes it is reflected downward and outward, forming an arched margin, the outer boundary (*superior cornu*) of the saphenous opening. This is sometimes called the *falciform process* of the fascia lata (femoral ligament of Hey); it overlies and is adherent to the sheath of the femoral vessels beneath; to its edge is attached the cribriform fascia, and it is continuous below with the pubic portion of the fascia lata by a well-defined curved margin.[1]

---

[1] *Anatomy of Femoral Rupture*, note on p. 18.

The *pubic portion* of the fascia lata is situated at the inner side of the saphenous opening: at the lower margin of this aperture it is continuous with the iliac portion: traced upward, it covers the surface of the Pectineus, Adductor longus, and Gracilis muscles; and, passing behind the sheath of the femoral vessels, to which it is closely united, is continuous with the sheath of the Psoas and Iliacus muscles, and is finally lost in the fibrous capsule of the hip-joint. This fascia is attached above to the pectineal line and internally to the margin of the pubic arch. It may be observed from this description that the iliac portion of the fascia lata passes in

FIG. 668.

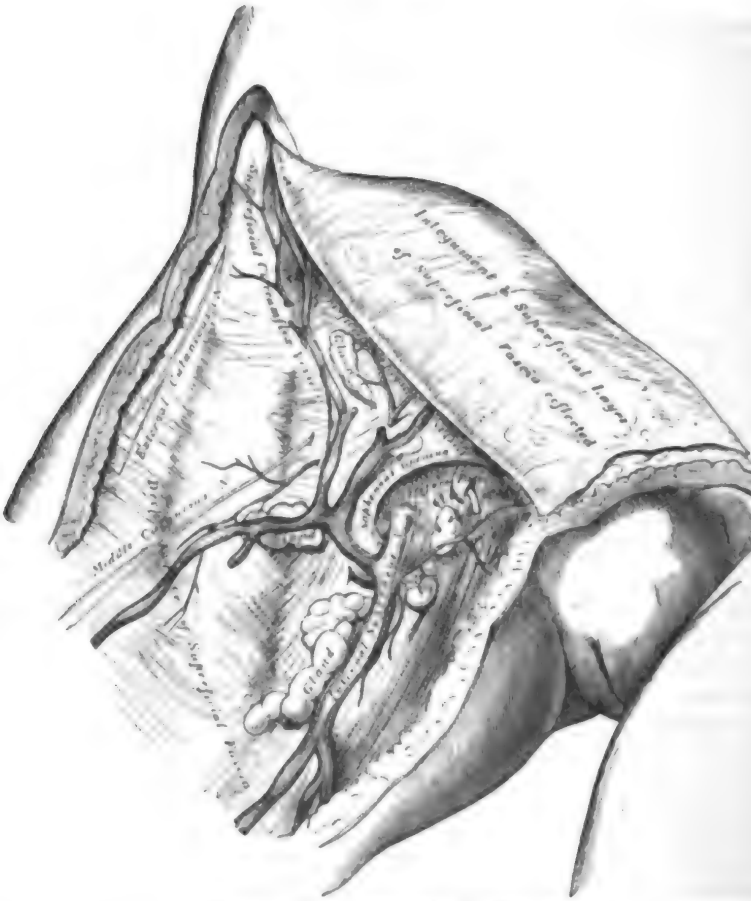

Femoral Hernia, superficial dissection.

---

[1] Mr. Gay (on *Femoral Rupture*, p. 13) describes the iliac portion of the fascia lata as advancing to the saphenous opening, then becoming abruptly reflected on itself, so as to form two layers, the inner or lower of which is continuous with the thin fascia repeatedly alluded to by Sir A. Cooper as spread out beneath it and in front of the sheath of the vessels. This deep layer of the iliac fascia is traversed by a band of ligamentous fibres lying immediately behind the crural [femoral] arch, and named the deep crural [or femoral] arch, which Mr. Gay identifies with Hey's ligament.

front of the femoral vessels, the pubic portion behind them; an apparent aperture consequently exists between the two, through which the internal saphenous joins the femoral vein.

The **Saphenous Opening** is an oval-shaped aperture measuring about an inch and a half in length and half an inch in width. It is situated at the upper and inner part of the thigh, below Poupart's ligament, toward the inner side, and is directed obliquely downward and outward. [It is the external end of the femoral canal, and so is analogous to the "external ring" in inguinal hernia, the femoral ring being analogous to the "internal ring."]

Fig. 669.

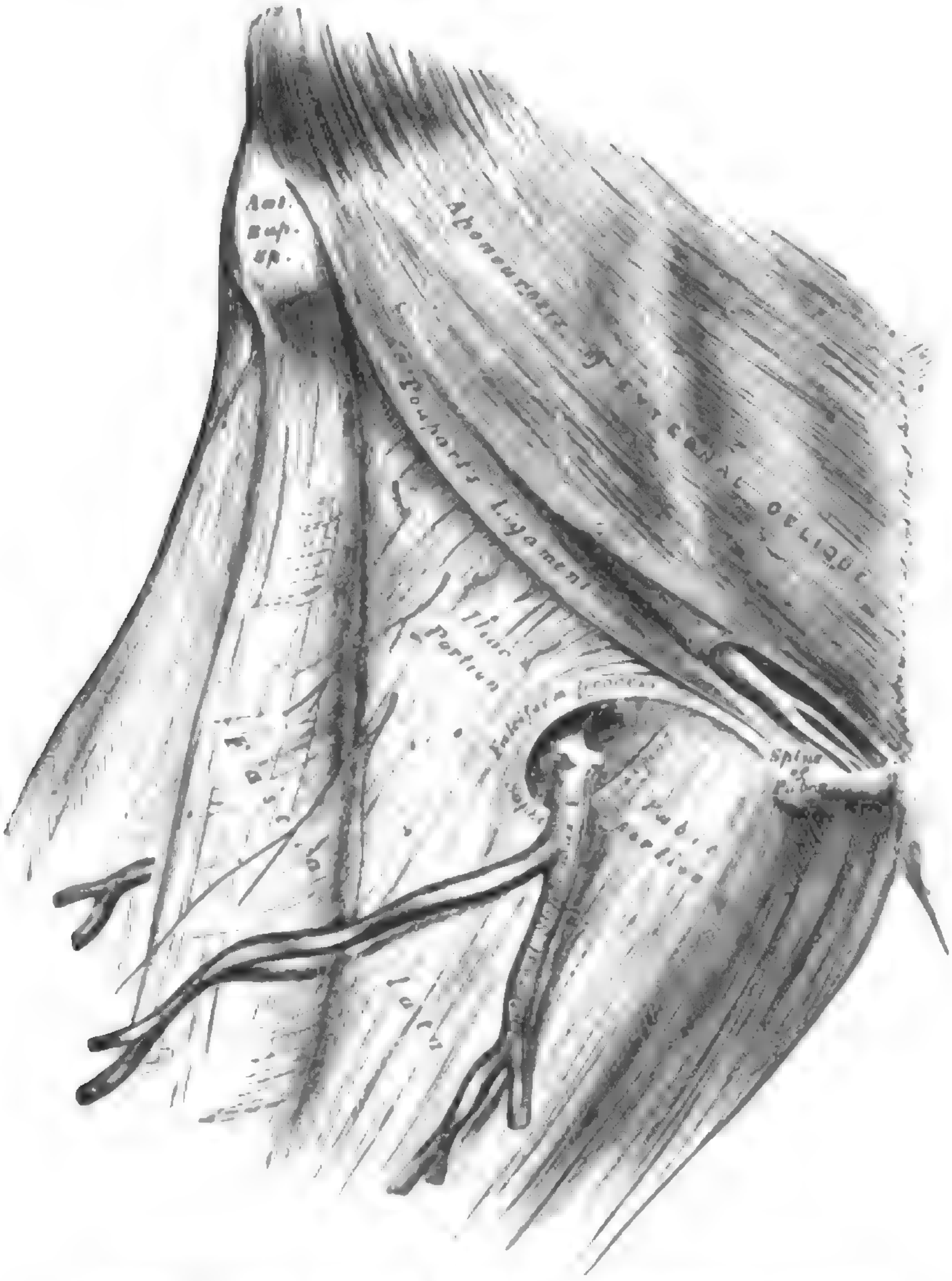
Ant. Sup. Sp.
Aponeurosis of External Oblique
Poupart's Ligament
Iliac Portion
Falciform process
Spine of Pubes
Pubic portion
Fascia Lata

Femoral Hernia, showing fascia lata and saphenous opening.

Its *outer margin* is of a semilunar form, thin, strong, sharply defined, and lies on a plane considerably anterior to the inner margin. If this edge is traced upward, it will be seen to form a curved elongated process or cornu (the superior cornu), or *falciform process of Burns*, which ascends in front of the femoral vessels, and, curving inward, is attached to Poupart's ligament and to the spine of the pubes and pectineal line, where it is continuous with the pubic portion.[1] If traced downward, it is found continuous with another curved margin, the concavity of which is directed upward and inward: this is the inferior cornu of the saphenous opening, and is blended with the pubic portion of the fascia lata covering the Pectineus muscle.

---

[1] It is difficult to perceive in the recognized description of these ligaments (Hey's and Burns's) any difference between the two, nor is it clear what structure Mr. Hey really intended to describe. Mr. Gay (on *Femoral Rupture*, p. 16) gives very cogent reasons for thinking that the "deep crural arch" was the structure which Hey had in view. The most recent writer on femoral hernia speaks thus while treating of these parts: "The whole upper edge of the iliac fascia lata is commonly called the 'falciform process,' whilst its deeper fibres receive the name of 'Burns's ligament.' Hey's femoral ligament would appear to consist of distinct fibres connected with the inner fold of the iliac fascia, which extend immediately beneath the tendon of the external oblique to the subperitoneal fascia" (Callender, *On the Anatomy of the Parts concerned in Femoral Rupture*, p. 19, note). This description of Hey's ligament accords closely with that of the deep femoral arch, for the subperito-

The *inner boundary* of the opening is on a plane *posterior* to the outer margin and behind the level of the femoral vessels; it is much less prominent and defined than the outer, from being stretched over the subjacent Pectineus muscle. It is through the saphenous opening that a femoral hernia passes after descending along the femoral canal.

If the finger be introduced into the saphenous opening while the limb is moved in different directions, the aperture will be found to be greatly constricted on extending the limb or rotating it outward, and to be relaxed on flexing the limb and inverting it: hence the necessity for placing the limb in the latter position in employing the taxis for the reduction of a femoral hernia.

The iliac portion of the fascia lata, but not its falciform process, should now be removed by detaching it from the lower margin of Poupart's ligament, carefully dissecting it from the subjacent structures, and turning it inward, when the sheath of the femoral vessels is exposed descending beneath Poupart's ligament (Fig. 670).

Poupart's Ligament, or the **Femoral Arch** [see remarks on this ligament on p. 994. The adjective "crural" in relation to the anatomy of femoral hernia is being less and less used in this country: "femoral" is happily replacing it. I have therefore substituted it in this American edition in most places. The student, however, must remember the use of "crural," or he will misunderstand much of the literature of femoral hernia], is the lower border of the aponeurosis of the External oblique muscle, which stretches across from the anterior superior spine of the ilium to the spine of the os pubis and pectineal line: the portion corresponding to the latter insertion is called *Gimbernat's ligament*. The direction of Poupart's ligament is curved downward toward the thigh, its outer half being oblique, its inner half nearly horizontal. Nearly the whole of the space included between the femoral arch and innominate bone is filled in by the parts which descend from the abdomen into the thigh. The outer half of the space is occupied by the Iliacus and Psoas muscles, together with the external cutaneous and anterior crural nerves. The pubic half of the space is occupied by the femoral vessels included in their sheath, a small oval-shaped interval existing between the femoral vein and the inner wall of the sheath, which is occupied merely by a little loose areolar tissue, and occasionally by a small lymphatic gland: this is the femoral ring, through which the gut descends in femoral hernia.

Gimbernat's Ligament (Figs. 671 and 672) is that part of the aponeurosis of the External oblique muscle which is reflected downward and outward [from Poupart's ligament] to be inserted into the pectineal line of the os pubis. It is about an inch in length, larger in the male than in the female, almost horizontal in direction in the erect posture, and of a triangular form, the base directed outward. Its *base* or outer margin is concave, thin, and sharp, lies in contact with the femoral sheath, and is blended with the pubic portion of the fascia lata. Its *apex* corresponds to the spine of the pubes. Its *posterior margin* is attached to the pectineal line. Its *anterior margin* is continuous with Poupart's ligament.

Femoral Sheath.—If Poupart's ligament be divided, the femoral sheath may be demonstrated as a continuation downward of the fasciæ that line the abdomen, the transversalis fascia passing down in front of the femoral vessels and the iliac fascia descending behind them: these fasciæ are directly continuous on the iliac side of the femoral artery, but a small space exists between the femoral vein and the point where they are continuous on the pubic side of that vessel, which constitutes the femoral or crural canal. The femoral sheath is closely adherent to the contained

---

neal fascia is Mr. Callender's name for the fascia transversalis. Mr. Callender goes on to say: "The upper border of this (saphenous) opening thus receives, by an unfortunate complication, the name of 'falciform process' 'femoral ligament,' 'Burns's or Hey's ligament.' The various divisions of the iliac fascia lata depend in great measure upon the skill of the dissector, and are, in my opinion, artificial."

vessels about an inch below the saphenous opening, becoming blended with the areolar sheath of the vessels, but opposite Poupart's ligament it is much larger than is required to contain them; hence the funnel-shaped form which it presents. The outer border of the sheath is perforated by the genito-crural nerve. Its inner border is pierced by the internal saphenous vein and numerous lymphatic vessels. In front it is covered by the iliac portion of the fascia lata, and behind it is the pubic portion of the same fascia.

Deep Femoral Arch.—Passing across the front of the femoral sheath, and closely connected with it, is a thickened band of fibres, called the *deep femoral arch.* It is apparently a thickening of the fascia transversalis, joining externally to the centre of Poupart's ligament, and arching across the front of the femoral sheath to be inserted by a broad attachment into the pectineal line behind the conjoined tendon. In some subjects this structure is not very prominently marked, and not unfrequently it is altogether wanting.

Fig. 670.

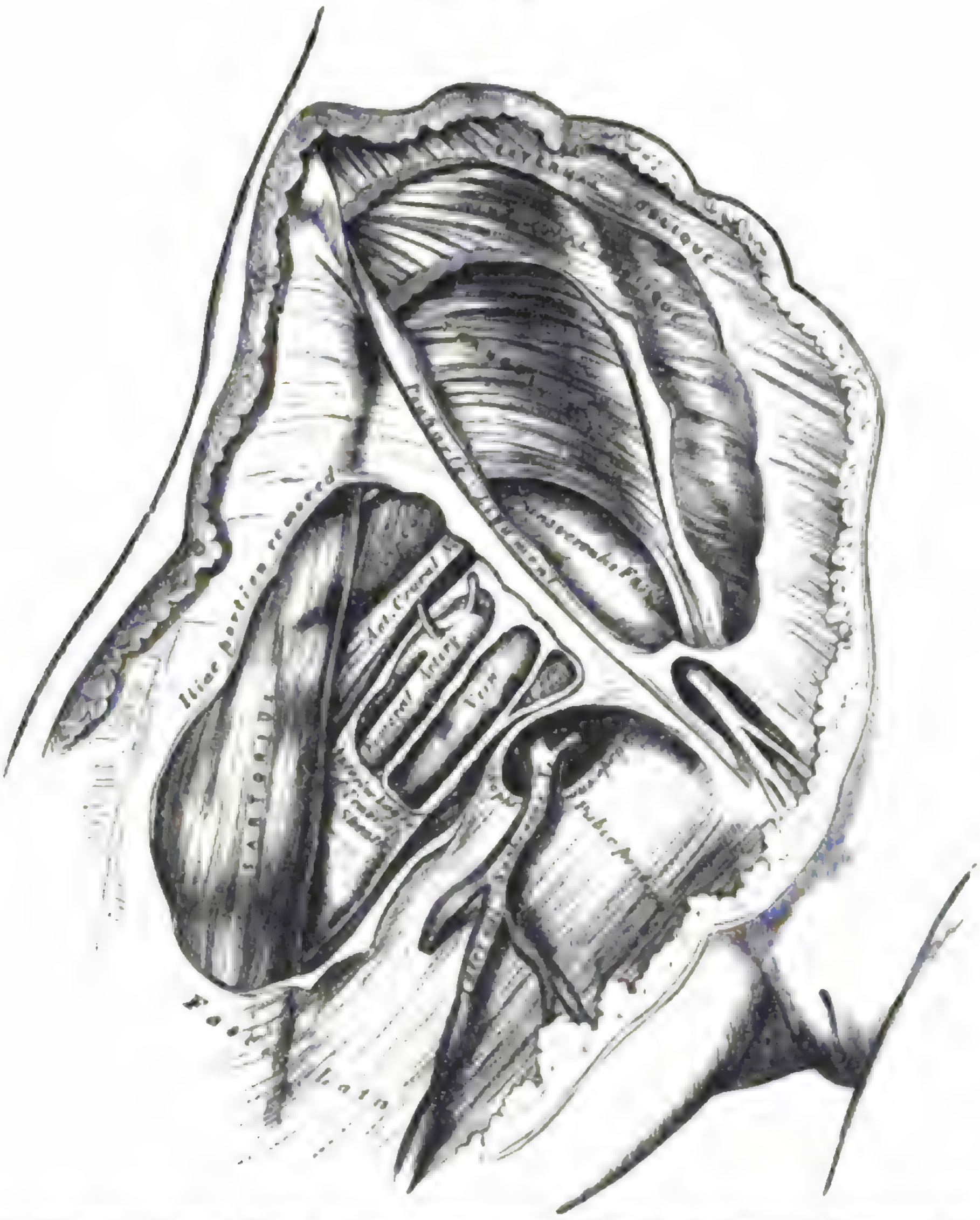

Femoral Hernia, Iliac Portion of Fascia Lata removed and Sheath of Femoral Vessels and Femoral Canal exposed.

If the anterior wall of the sheath is removed, the femoral artery and vein are seen lying side by side, a thin septum separating the two vessels, while another septum may be seen lying just internal to the vein and cutting off a small space between the vein and the inner wall of the sheath. The septa are stretched between the anterior and posterior walls of the sheath, so that each vessel is enclosed in a separate compartment. The interval left between the vein and the inner wall of the sheath is not filled up by any structure, excepting a little loose areolar tissue, a few lymphatic vessels, and occasionally a lymphatic gland: this is the femoral or crural canal, through which the intestine descends in femoral hernia.

Fig. 671.

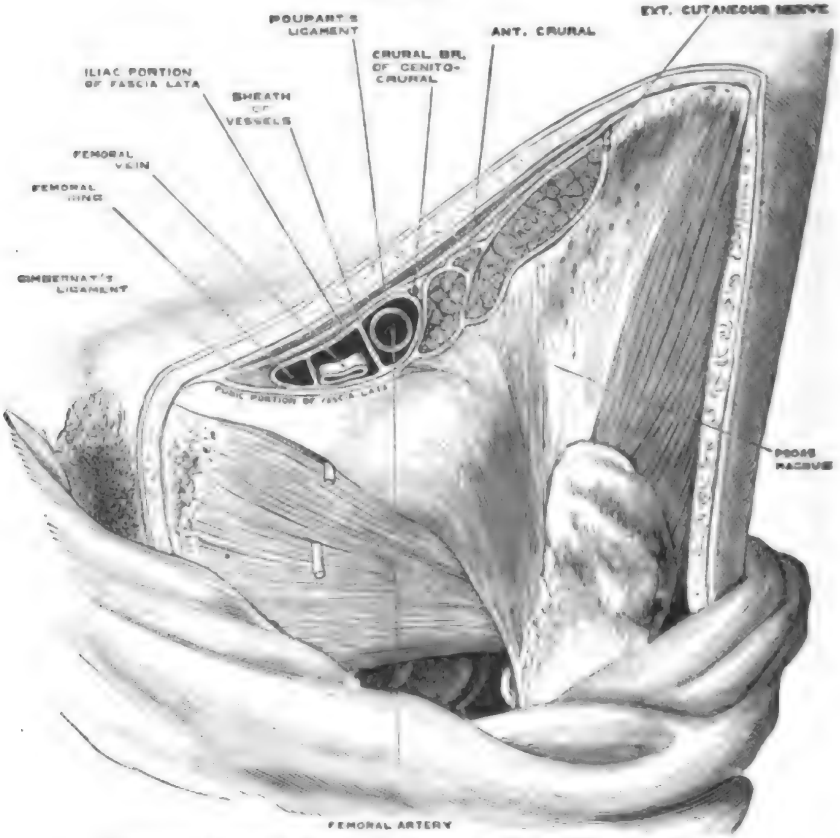
POUPART'S LIGAMENT
EXT. CUTANEOUS NERVE
ANT. CRURAL
CRURAL BR. OF GENITO-CRURAL
ILIAC PORTION OF FASCIA LATA
SHEATH OF VESSELS
FEMORAL VEIN
FEMORAL RING
GIMBERNAT'S LIGAMENT
PUBIC PORTION OF FASCIA LATA
PSOAS MAGNUS
FEMORAL ARTERY

Structures which pass beneath the Femoral Arch [viewed from in front].

The **Femoral Canal** is the narrow interval between the femoral vein and the inner wall of the femoral sheath. It exists as a distinct canal only when the sheath has been separated from the vein by dissection or by the pressure of a hernia or

Fig. 672.

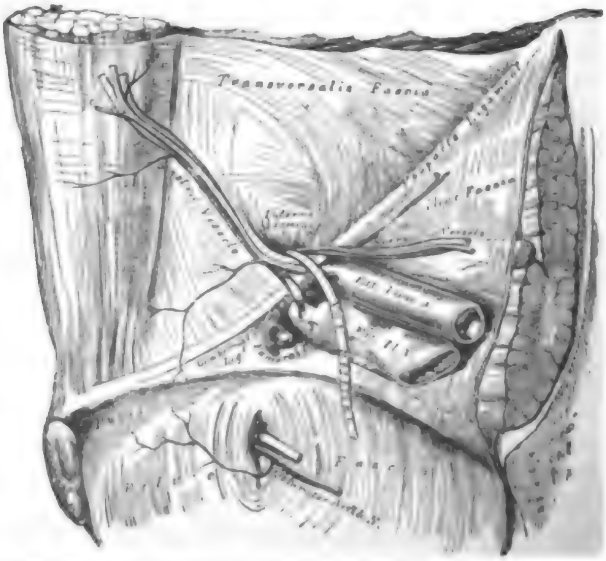
Transversalis Fascia
Iliac Fascia

Hernia, the relations of the Femoral and Internal Abdominal Rings, seen from within the abdomen, right side.

tumor. Its length is from a quarter to half an inch, and it extends from Gimbernat's ligament to the upper part of the saphenous opening.

Its *anterior wall* is very narrow, and formed by a continuation downward of the fascia transversalis under Poupart's ligament, covered by the falciform process of the fascia lata.

Its *posterior wall* is formed by a continuation downward of the iliac fascia, covering the pubic portion of the fascia lata.

Its *outer wall* is formed by the fibrous septum separating it from the inner side of the femoral vein.

Its *inner wall* is formed by the junction of the processes of the transversalis and iliac fasciæ (which form the inner side of the femoral sheath) and lies in contact at its commencement with the outer edge of Gimbernat's ligament.

This canal has two orifices—an upper one, the *femoral* or *crural ring*, closed by the septum crurale [or femorale]; and a lower one, the *saphenous opening*, closed by the cribriform fascia.

The **Femoral** (or **Crural**) **Ring** (Figs. 671 and 672) is the upper opening of the femoral canal and leads into the cavity of the abdomen.[1] It is bounded in front by Poupart's ligament and the deep femoral arch; behind by the pubes, covered by the Pectineus muscle and the pubic portion of the fascia lata; internally by the base of Gimbernat's ligament, the conjoined tendon, the transversalis fascia, and the deep femoral arch; externally by the fibrous septum lying on the inner side of the femoral vein. The femoral ring is of an oval form; its long diameter, directed transversely, measures about half an inch, and it is larger in the female than in the male [on account of the greater width of the female pelvis]; which is one of the reasons of the greater frequency of femoral hernia in the former sex.

Position of Parts around the Ring.—The spermatic cord in the male and the round ligament in the female lie immediately above the anterior margin of the femoral ring, and may be divided in an operation for femoral hernia if the incision for the relief of the stricture is not of limited extent. In the female this is of little importance, but in the male the spermatic artery and vas deferens may be divided.

The *femoral vein* lies on the outer side of the ring.

The *epigastric artery* in its passage inward from the external iliac artery to the umbilicus passes across the upper and outer angle of the femoral ring, and is consequently in danger of being wounded if the stricture is divided in a direction upward and outward.

The *communicating branch* between the epigastric and obturator lies in front of the ring.

The circumference of the ring is thus seen to be bounded by vessels in every part, excepting internally and behind. It is in the former position that the stricture is divided in cases of strangulated femoral hernia.

The *obturator artery*, when it arises by a common trunk with the epigastric—which occurs once in every three subjects and a half—bears a very important relation to the femoral ring. In some cases it descends on the inner side of the external iliac vein to the obturator foramen, and will consequently lie on the outer side of the femoral ring, where there is no danger of its being wounded in the operation for dividing the stricture in femoral hernia. (See Fig. 401, A, p. 587.) Occasionally, however, the obturator artery curves along the free margin of Gimbernat's ligament in its passage to the obturator foramen; it would consequently skirt along the greater part of the circumference of the femoral canal, and could hardly avoid being wounded in the operation. (See Fig. 401, B, p. 587.) [To avoid this accident the edge of the knife should be dulled, and the edge of Gimbernat's ligament only nicked and then torn.]

Septum Crurale [or Femorale].—The femoral ring is closed by a layer of condensed areolar tissue, called by J. Cloquet the *septum crurale.* This serves as a barrier to the protrusion of a hernia through this part. Its upper surface is slightly concave and supports a small lymphatic gland, by which it is separated from the subserous areolar tissue and peritoneum. Its under surface is turned toward the femoral canal. The septum crurale is perforated by numerous apertures for the passage of lymphatic vessels connecting the deep inguinal glands with those surrounding the external iliac artery.

---

[1] This ring, like the femoral canal, is a morbid or an artificial product. "Each femoral hernia makes for itself (for neither outlet exists in the natural anatomy of the region) a crural canal and a crural (femoral) ring" (Callender, *op. cit.*, p. 40).

The size of the femoral canal, the degree of tension of its orifices, and consequently the degree of constriction of a hernia, vary according to the position of the limb. If the leg and thigh are extended, abducted, or everted, the femoral canal and its orifices are rendered tense from the traction on these parts by Poupart's ligament and the fascia lata, as may be ascertained by passing the finger along the canal. If, on the contrary, the thigh is flexed upon the pelvis, and at the same time adducted and rotated inward, the femoral canal and its orifices become considerably relaxed; for this reason the limb should always be placed in the latter position when the application of the taxis is made in attempting the reduction of a femoral hernia.

The septum crurale is separated from the peritoneum by a quantity of loose subserous areolar tissue. In some subjects this tissue contains a considerable amount of adipose substance, which, when protruded forward in front of the sac of a femoral hernia, may be mistaken for a portion of omentum.

Descent of the Hernia.—From the preceding description it follows that the femoral ring must be a weak point in the abdominal wall: hence it is that when violent or long-continued pressure is made upon the abdominal viscera a portion of intestine may be forced into it, constituting a femoral hernia; and the changes in the tissues of the abdomen which are produced by pregnancy, together with the larger size of this aperture in the female, serve to explain the frequency of this form of hernia in women.

When a portion of the intestine is forced through the femoral ring, it carries before it a pouch of peritoneum, which forms what is called the *hernial sac;* it receives an investment from the subserous areolar tissue and from the septum crurale, and descends vertically along the femoral canal in the inner compartment of the sheath of the femoral vessels as far as the saphenous opening; at this point it changes its course, being prevented from extending farther down the sheath on account of the narrowing of the sheath and its close contact with the vessels, and also from the close attachment of the superficial fascia and femoral sheath to the lower part of the circumference of the saphenous opening; the tumor is consequently directed forward, pushing before it the cribriform fascia, and then curves upward on to the falciform process of the fascia lata and lower part of the tendon of the External oblique, being covered by the superficial fascia and integument. While the hernia is contained in the femoral canal it is usually of small size, owing to the resisting nature of the surrounding parts; but when it has escaped from the saphenous opening into the loose areolar tissue of the groin it becomes considerably enlarged. The direction taken by a femoral hernia in its descent is at first downward, then forward and upward; this should be borne in mind, as in the application of the taxis for the reduction of a femoral hernia pressure should be directed in the reverse order.

Coverings of the Hernia.—The coverings of a femoral hernia from within outward are peritoneum, subserous areolar tissue, the septum crurale [femorale], femoral sheath, cribriform fascia, superficial fascia, and integument.[1]

Varieties of Femoral Hernia.—If the intestine descends along the femoral canal only as far as the saphenous opening, and does not escape from this aperture, it is called *incomplete femoral hernia.* The small size of the protrusion in this form of hernia, on account of the firm and resisting nature of the canal in which it is contained, renders it an exceedingly dangerous variety of the disease, from the extreme difficulty of detecting the existence of the swelling, especially in corpulent subjects. The coverings of an incomplete femoral hernia would be, from without inward, integument, superficial fascia, falciform process of fascia lata, femoral sheath, septum crurale [femorale], subserous areolar tissue, and peritoneum. When, however, the hernial tumor protrudes through the saphenous opening and directs itself forward and upward, it forms a *complete femoral hernia.* Occasionally the hernial sac descends on the iliac side of the femoral vessels or in front of these vessels, or even sometimes behind them.

---

[1] Sir A. Cooper has described an investment for femoral hernia under the name of "fascia propria," lying immediately external to the peritoneal sac, but frequently separated from it by more or less adipose tissue. Surgically, it is important to remember the existence (at any rate, the occasional existence) of this layer, on account of the ease with which an inexperienced operator may mistake the fascia for the peritoneal sac, and the contained fat for omentum. Anatomically, this fascia appears identical with what is called in the text "subserous areolar tissue," the areolar tissue being thickened and caused to assume a membranous appearance by the pressure of the hernia.

The *seat of stricture* of a femoral hernia varies: it may be in the peritoneum at the neck of the hernial sac; in the greater number of cases it would appear to be at the point of junction of the falciform process of the fascia lata with the lunated edge of Gimbernat's ligament, or at the margin of the saphenous opening in the thigh. The stricture should in every case be divided in a direction upward and inward, and the extent necessary in the majority of cases is about two or three lines. By these means all vessels or other structures of importance in relation with the neck of the hernial sac will be avoided.

Digitized

Surgical Anatomy of the Perineum and Ischio-rectal Region.

Dissection.—The student should select a well-developed muscular [male] subject free from fat, and the dissection should be commenced early, in order that the parts may be examined in as recent a state as possible. A staff having been introduced into the bladder, and the subject placed in the position shown in Fig. 673, the scrotum should be raised upward and retained in that position, and the rectum moderately distended with tow [the anus being closed by stitches].

The space which is now exposed corresponds to the inferior aperture or outlet of the pelvis. Its deep boundaries are, in front, the pubic arch and subpubic ligament; behind, the tip of the coccyx; and on each side, the ramus of the pubes and ischium, the tuberosity of the ischium, and great sacro-sciatic ligament. The space included by these boundaries is somewhat lozenge-shaped, and is limited on the surface of the body by the scrotum in front, by the buttocks behind, and on each side by the inner side of the thighs. It measures, from before backward, about three and a quarter inches, and about three and a half in the broadest part of its transverse diameter, between the ischial tuberosities. A line drawn transversely between the anterior part of the tuberosity of the ischium on each side in front of the anus divides this space into two portions. The anterior portion contains the penis and urethra, and is called the *perineum*. The posterior portion contains the termination of the rectum, and is called the *ischio-rectal region*.

FIG. 673.

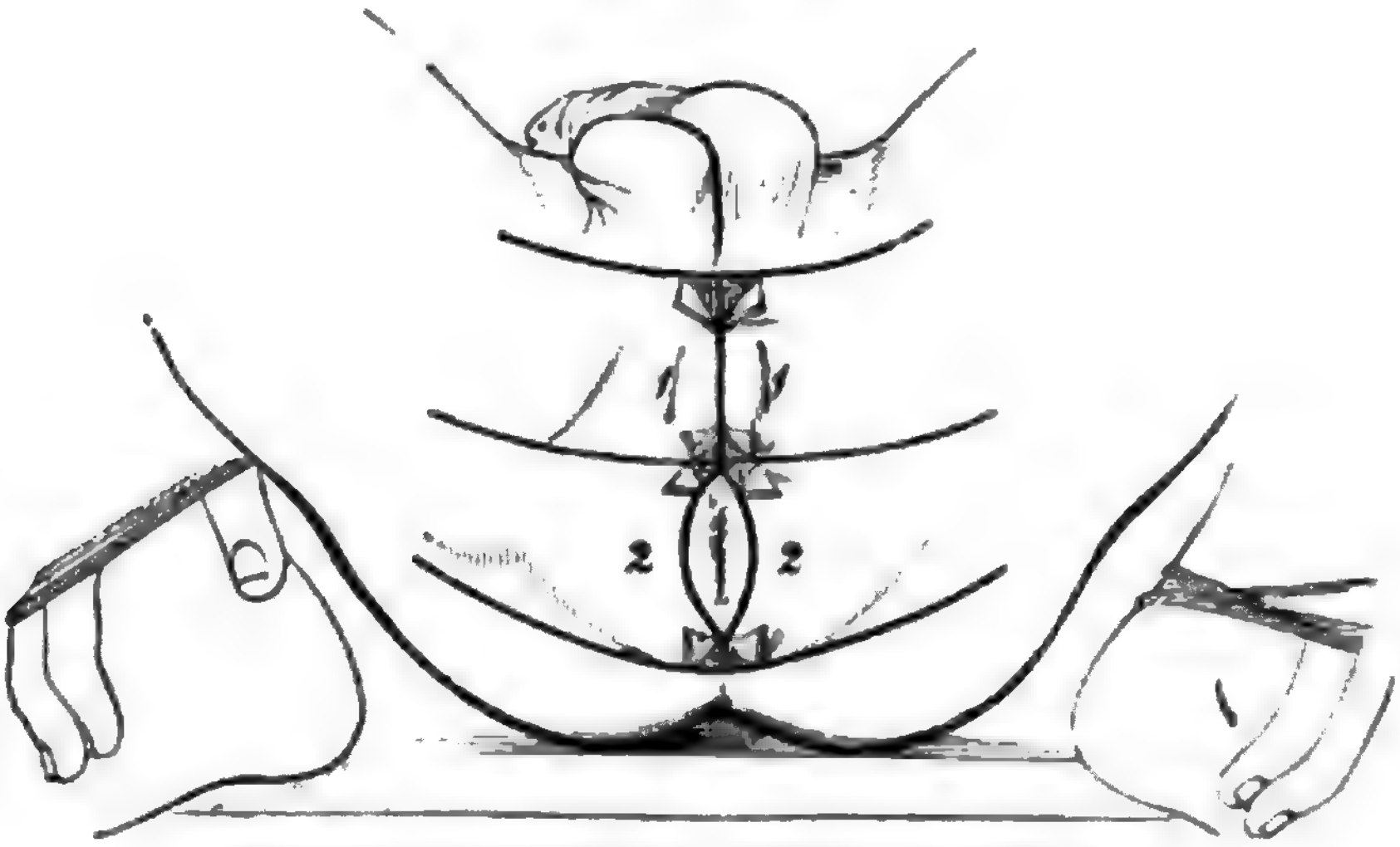

Dissection of Perineum and Ischio-rectal Region.

ISCHIO-RECTAL REGION.

The ischio-rectal region corresponds to the portion of the outlet of the pelvis situated immediately behind the perineum: it contains the termination of the rectum. A deep fossa filled with fat is seen on either side of the intestine between it and the tuberosity of the ischium: this is called the *ischio-rectal fossa*.

The **ischio-rectal region** presents in the middle line the aperture of the *anus*; around this orifice the integument is thrown into numerous folds, which are obliterated on distension of the intestine. The integument is of a dark color, continuous with the mucous membrane of the rectum, and provided with numerous follicles, which occasionally inflame and suppurate and may be mistaken for fistulæ. The veins around the margin of the anus are occasionally much dilated, forming a number of hard pendent masses of a dark bluish color, covered partly by mucous membrane and partly by the integument. These tumors constitute the disease called *external piles*.

Dissection.—Make an incision through the integument along the median line, from the base of the scrotum to the anterior extremity of the anus; carry it round the margins of this aperture to its posterior extremity, and continue it backward about an inch behind the tip of the coccyx. A transverse incision should now be carried across the base of the scrotum at the anterior extremity of the preceding; a second, carried in the same direction, should be made in front of the anus; and a third at the posterior extremity of the gut. These incisions should be sufficiently extensive to enable the dissector to raise the integument from the inner side of the thighs. The flaps of skin corresponding to the ischio-rectal region (Figs. 673–680) should now be removed. In dissecting the integument from this region great care is required, otherwise the Corrugator cutis ani and External sphincter will be removed, as they are intimately adherent to the skin.

The **superficial fascia** is exposed on the removal of the skin: it is very thick, areolar in texture, and contains much fat in its meshes. In it are found ramifying two or three cutaneous branches of the small sciatic nerve; these turn round the inferior border of the Gluteus maximus and are distributed to the integument in this region.

Corrugator Cutis Ani.—Around the anus is a thin stratum of involuntary muscle which radiates from the interior of the anus, where it commences in the submucous tissue, to the skin outside, where it blends with the subcutaneous tissue. By its contraction it raises the skin into ridges radiating from the margin of the anus.

The **External Sphincter** is a thin flat plane of muscular fibres, elliptical in shape, and intimately adherent to the integument surrounding the margin of the anus. It measures about three or four inches in length from its anterior to its posterior extremity, being about an inch in breadth opposite the anus. It arises from the tip of the coccyx by a narrow tendinous band, and from the superficial fascia in front of that bone, and is inserted into the tendinous centre of the perineum, joining with the Transversus perinæi, the Levator ani, and the Accelerator urinæ. Like other sphincter muscles, it consists of two planes of muscular fibres, which surround the margin of the anus and join in a commissure before and behind.

RELATIONS.—By its *superficial surface* with the integument; by its *deep surface* it is in contact with the internal Sphincter, and is separated from the Levator ani by loose areolar tissue.

The **Sphincter ani** is a voluntary muscle supplied by the hemorrhoidal branch of the fourth sacral nerve. This muscle is divided in the operation for fistula in ano, and also in some cases of fissure of the rectum, especially if attended with much pain or spasm. The object of its division is to keep the parts at rest and in contact during the healing process.

The **Internal Sphincter** is a muscular ring about an inch in breadth which surrounds the lower extremity of the rectum, its inferior border being contiguous to, but quite separate from, the External sphincter. This muscle is about two lines in thickness, and is formed by an aggregation of the involuntary circular fibres of the intestine. It is paler in color and less coarse in texture than the External sphincter.

The **Ischio-rectal Fossa** is situated between the end of the rectum and the tuberosity of the ischium on each side. It is triangular in shape; its base, directed to the surface of the body, is formed by the integument of the ischiorectal region; its *apex*, directed upward, corresponds to the point of division of the obturator fascia and the thin membrane given off from it which covers the outer surface of the Levator ani (anal fascia). Its dimensions are about an inch in breadth at the base and about two inches in depth, being deeper behind than in front. It is bounded *internally* by the Sphincter ani, Levator ani, and Coccygeus muscles; *externally* by the tuberosity of the ischium and the obturator fascia, which covers the inner surface of the Obturator internus muscle; *in front* it is limited by the line of junction of the superficial and deep perineal fasciæ; and *behind*, by the margin of the Gluteus maximus and the great sacro-sciatic ligament. This space is filled with a large mass of adipose tissue, which explains the frequency with which abscesses in the neighborhood of the rectum burrow to a considerable depth.

If the subject has been injected, on placing the finger on the outer wall of this fossa the internal pudic artery and its accompanying veins and nerve will be felt about an inch and a half above the margin of the ischiatic tuberosity, but approaching nearer the surface as they pass forward along the inner margin of the pubic arch. These structures are enclosed in a sheath formed by the obturator fascia, the pudic nerve lying below the artery (Fig. 402, p. 588). Crossing the space transversely about its centre are the inferior hemorrhoidal vessels and nerves, branches of the internal pudic; they are distributed to the integument of the anus and to the muscles of the lower end of the rectum. These vessels are occasionally of large size, and may give rise to troublesome hemorrhage when divided in the operation of lithotomy or of fistula in ano. At the back part of this space may be seen a branch of the fourth sacral nerve, and at the fore part of the space a cutaneous branch of the perineal nerve.

PERINEUM.

The perineal space is of a triangular form; its deep boundaries are limited laterally by the rami of the pubes and ischia, meeting in front at the pubic arch; behind by an imaginary transverse line extending between the tuberosities of the ischia. The lateral boundaries are, in the adult, from three inches to three inches

FIG. 674.

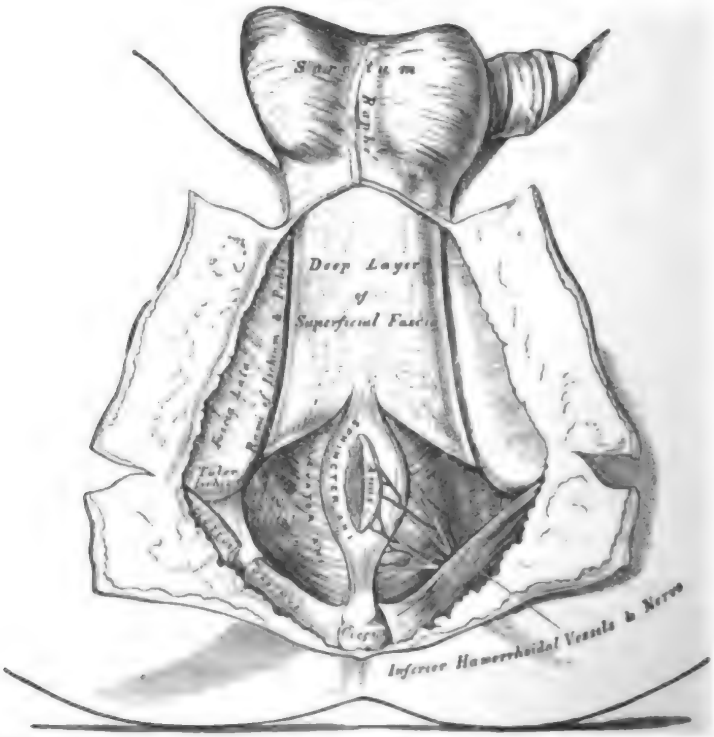

The Perineum, the Integument and Superficial Layer of Superficial Fascia reflected.

and a half in length, and the base from two to three inches and a half in breadth, the average extent of the space being two inches and three-quarters. The variations in the diameter of this space are of extreme interest in connection with the operation of lithotomy and the extraction of a stone from the cavity of the bladder.

In those cases where the tuberosities of the ischia are near together it would be necessary to make the incisions in the lateral operation of lithotomy less oblique than if the tuberosities were widely separated, and the perineal space, consequently, wider. The perineum is subdivided by the median raphé into two equal parts. Of these, the left is the one in which the operation of lateral lithotomy is performed.

In the middle line the perineum is convex and corresponds to the bulb of the urethra. The skin covering it is of a dark color, thin, freely movable upon the subjacent parts, and covered with sharp crisp hairs, which should be removed before the dissection of the part is commenced. In front of the anus a prominent line commences, the raphé, continuous in front with the raphé of the scrotum. The flaps of integument corresponding to this space having been removed in the manner shown in Fig. 675, the superficial fascia is exposed.

FIG. 675.

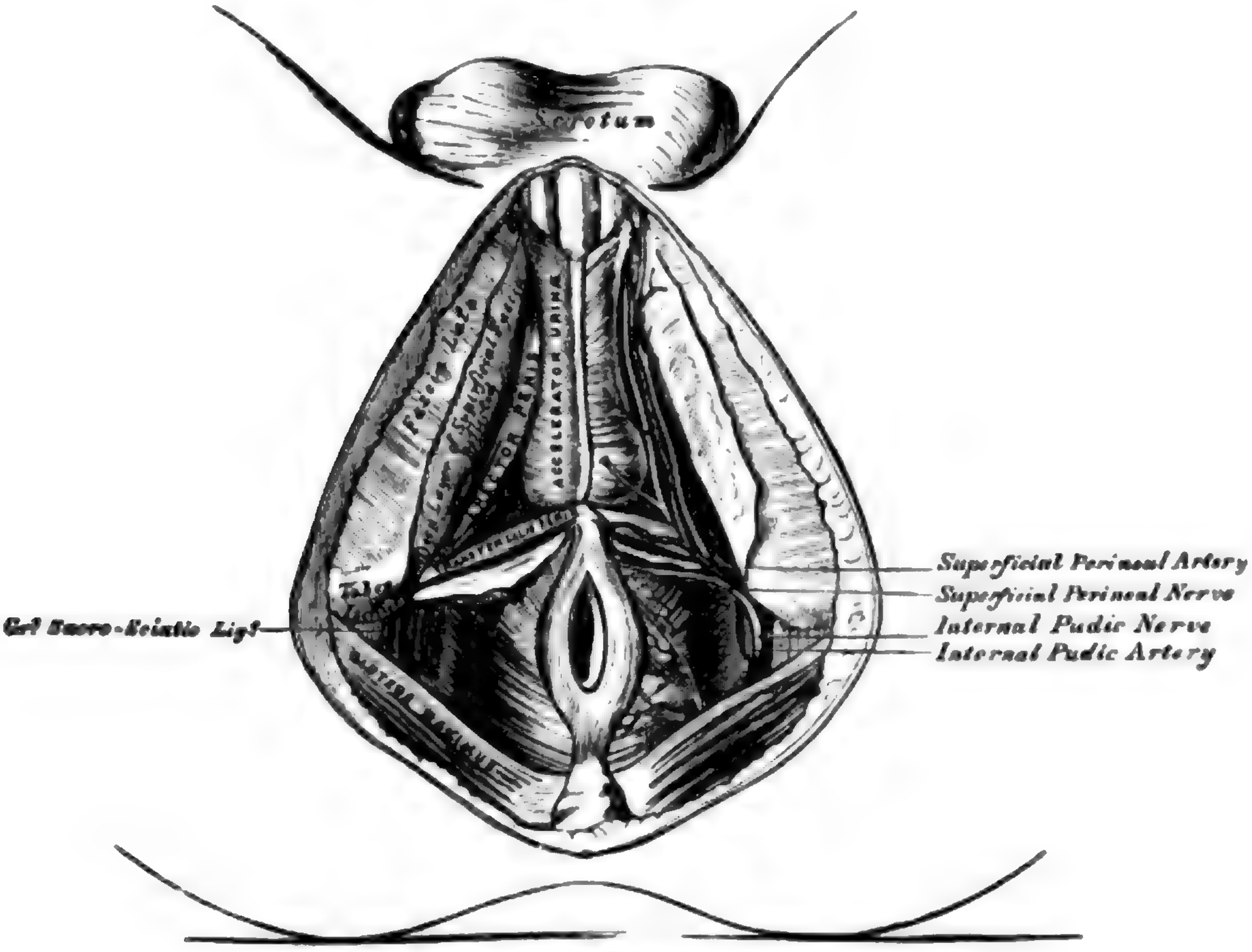

The Superficial Muscles and Vessels of the Perineum.

The **superficial fascia** consists of two layers, superficial and deep, as in other regions of the body.

The *superficial layer* is thick, loose, areolar in texture, and contains much adipose tissue in its meshes, the amount of which varies in different subjects. In front it is continuous with the dartos of the scrotum; behind it is continuous with the subcutaneous areolar tissue surrounding the anus; and on either side with the same fascia on the inner side of the thighs. This layer should be carefully removed after it has been examined, when the deep layer will be exposed.

The *deep layer of superficial fascia* (superficial perineal fascia) is thin, aponeurotic in structure, and of considerable strength, serving to bind down the muscles of the root of the penis. It is continuous in front with the dartos of the scrotum; on either side it is firmly attached to the margins of the rami of the pubes and ischium, external to the crus penis and as far back as the tuberosity of the ischium; posteriorly it curves down behind the Transversus perinæi muscles to join the lower margin of the deep perineal fascia. This fascia not only covers the muscles in this region, but sends down a vertical septum from its under surface which separates the back part of the subjacent space into two, being incomplete in front.

In rupture of the anterior portion of the urethra accompanied by extravasation of urine the fluid makes its way forward, beneath this fascia, into the areolar tissue of the scrotum, penis, and anterior and lateral portions of the abdomen; it rarely extends into the areolar tissue on the inner side of the thighs or backward around the anus. This limitation of the extravasated fluid to the parts above named is easy of explanation when the attachments of the deep layer of the superficial fascia are considered. When this fascia is removed the muscles connected with the penis and urethra will be exposed; these are, in the middle line, the Accelerator urinæ, on each side the Erector penis, and behind the Transversus perinæi.

The **Accelerator urinæ** (*Ejaculator seminis* or *bulbo-cavernosus*) is placed in the middle line of the perineum, immediately in front of the anus. It consists of two symmetrical halves united along the median line by a tendinous raphé. It arises from the central tendon of the perineum and from the median raphé in front. From this point its fibres diverge like the plumes of a pen; the most posterior form a thin layer which is lost on the anterior surface of the triangular ligament; the middle fibres encircle the bulb and adjacent parts of the corpus spongiosum, and join with the fibres of the opposite side, on the upper part of the corpus spongiosum, in a strong aponeurosis; the anterior fibres, the longest and most distinct, spread out over the sides of the corpus cavernosum, to be inserted partly into that body anterior to the Erector penis, occasionally extending to the os pubis, partly terminating in a tendinous expansion which covers the dorsal vessels of the penis. The latter fibres are best seen by dividing the muscle longitudinally and dissecting it outward from the surface of the urethra.

ACTION.—This muscle serves to empty the canal of the urethra after the bladder has expelled its contents; during the greater part of the act of micturition its fibres are relaxed, and it only comes into action at the end of the process. The middle fibres are supposed by Krause to assist in the erection of the corpus spongiosum by compressing the erectile tissue of the bulb. The anterior fibres, according to Tyrrel, also contribute to the erection of the penis, as they are inserted into and continuous with the fascia of the penis, compressing the dorsal vein during the contraction of the muscle.

The **Erector Penis** covers the unattached part of the crus penis. It is an elongated muscle, broader in the middle than at either extremity, and situated on either side of the lateral boundary of the perineum. It arises by tendinous and fleshy fibres from the inner surface of the tuberosity of the ischium, behind the crus penis, from the surface of the crus and from the adjacent portion of the ramus of the pubes. From these points fleshy fibres succeed, ending in an aponeurosis which is inserted into the sides and under surface of the crus penis. This muscle compresses the crus penis and retards the return of the blood through the veins, and thus serves to maintain the organ erect.

The **Transversus Perinæi** is a narrow muscular slip which passes more or less transversely across the back part of the perineal space. It arises by a small tendon from the inner and fore side of the tuberosity of the ischium, and, passing obliquely forward and inward, is inserted into the central tendinous point of the perineum, joining in this situation with the muscle of the opposite side, the Sphincter ani behind, and the Accelerator urinæ in front.

Between the muscles just examined a triangular space exists, bounded internally by the Accelerator urinæ, externally by the Erector penis, and behind by the Transversus perinæi. The floor of this space is formed by the triangular ligament of the urethra (deep perineal fascia), and running from behind forward in it are the superficial perineal vessels and nerves, the transverse perineal artery coursing along the posterior boundary of the space on the Transversus perinæi muscle.

In the lateral operation of lithotomy the knife is carried obliquely across the back part of this space downward and outward into the ischio-rectal fossa, dividing the Transversus perinæi muscle and artery, the posterior fibres of the Accelerator urinæ, the superficial perineal vessels and nerve, and more posteriorly the inferior hemorrhoidal vessels.

The superficial and transverse perineal arteries are described at p. 589, and the superficial perineal and inferior pudendal nerves at pp. 778 and 780.

The muscles of the perineum in the female are the—

Superficial Muscles. { Sphincter vaginæ (Bulbo-cavernosus). Sphincter ani.
Erector clitoridis. Levator ani.
Transversus perinæi. Coccygeus.

[*Deep Muscles.* . . . { Deep Transversus perinæi.
Constrictor vaginæ.
Depressor urethræ (Jarjavay's muscle).]

The **Sphincter Vaginæ** or **Bulbo-cavernosus** is placed on each side of the orifice of the vagina, and is analogous to the Accelerator urinæ in the male. It is attached posteriorly to the central tendon of the perineum, where it blends with the Sphincter ani. Its fibres pass forward on each side of the vagina to be inserted into the corpora cavernosa of the clitoris, a fasciculus crossing over the body of the organ so as to compress the dorsal vein.

The **Erector Clitoridis** resembles the Erector penis in the male, but is smaller than it, arising from the tuberosity of the ischium and being inserted on each side of the crus.

The **Transversus Perinæi** is inserted into the side of the Sphincter vaginæ, and the Levator ani into the side of the vagina and rectum. The other muscles are precisely similar to those in the male.

[The **Deep Transversus Perinæi** arises from the ramus of the ischium, and passes to the central point of the perineum.

[Fig. 676.

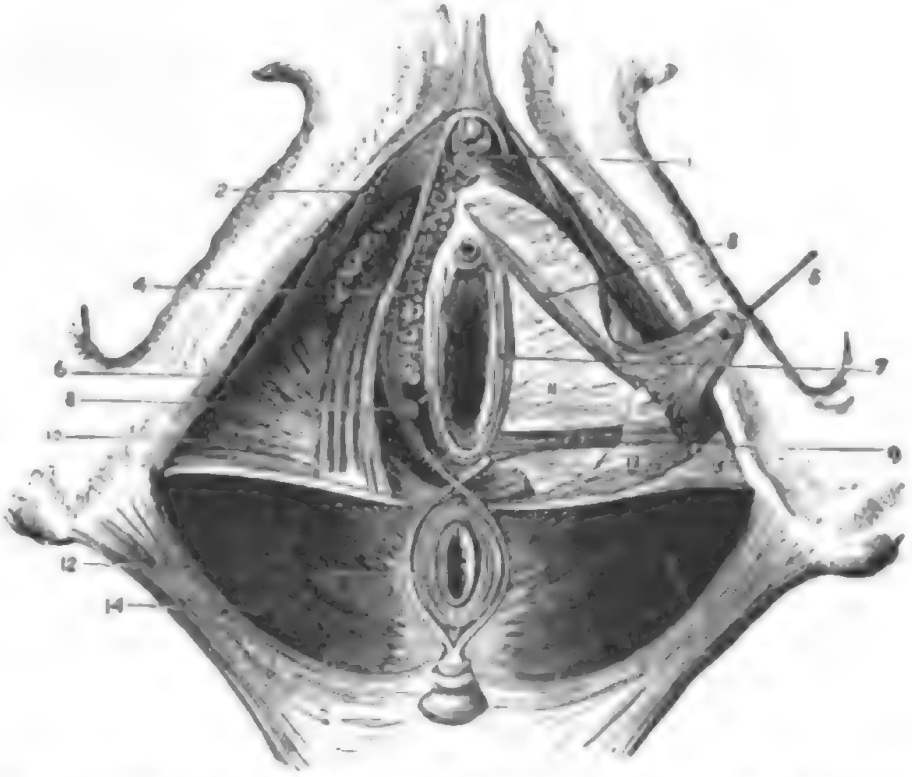

The Muscles of the Female Perineum, superficial on right, and deep on left side: 1, clitoris; 2, Erector clitoridis; 3, Jarjavay's muscle (Depressor urethræ); 4, bulb of vagina; 5, Transversus perinæi (reflected); 6, Bulbo-cavernosus (Sphincter vaginæ); 7, Constrictor vaginæ; 8, gland of Bartholin; 9, Deep Transversus perinæi; 10, Superficial Transversus perinæi; 11, posterior layer of triangular ligament; 12, Sphincter ani; 13, triangular ligament; 14, Levator ani; 15, Ischio-perineal ligament (Savage and Luschka).]

The **Constrictor Vaginæ** consists of a few fibres which arise from the central tendon of the perineum and encircle the vaginal opening. It is joined by

The **Depressor Urethræ** (Jarjavay's muscle), which arises from the ramus of the ischium close to the deep Transverse muscle, and sometimes united with it. It runs upward and inward to join the fibres of the Constrictor, and also to join its fellow-muscle over the urethra.

The student will have great difficulty in dissecting these deep muscles, even in favorable subjects and when dissected early. But every student should dissect carefully the perineum in the female, as well as the male, in order at least to get a correct general idea of its anatomy.]

The Accelerator urinæ and Erector penis muscles should now be removed, when the deep perineal fascia will be exposed, stretching across the front part of the outlet of the pelvis. The urethra is seen perforating its centre just behind the bulb, and on either side is the crus penis, connecting the corpus cavernosum with the ramus of the ischium and pubes.

The **deep perineal fascia** (*triangular ligament* [Figs. 679, 681, 682]) is a dense membranous lamina which closes the front part of the outlet of the pelvis. It is triangular in shape, about an inch and a half in depth, attached above, by its apex, to the under surface of the symphysis pubis and subpubic ligament, and on each side to the rami of the ischium and pubes beneath the crura penis. Its inferior margin, or base, is directed toward the rectum and connected to the central tendinous point of the perineum. It is continuous with the deep layer of the superficial fascia behind the Transversus perinæi muscle, and with a thin fascia which covers the cutaneous surface of the Levator ani muscle (anal fascia).

[FIG. 677.

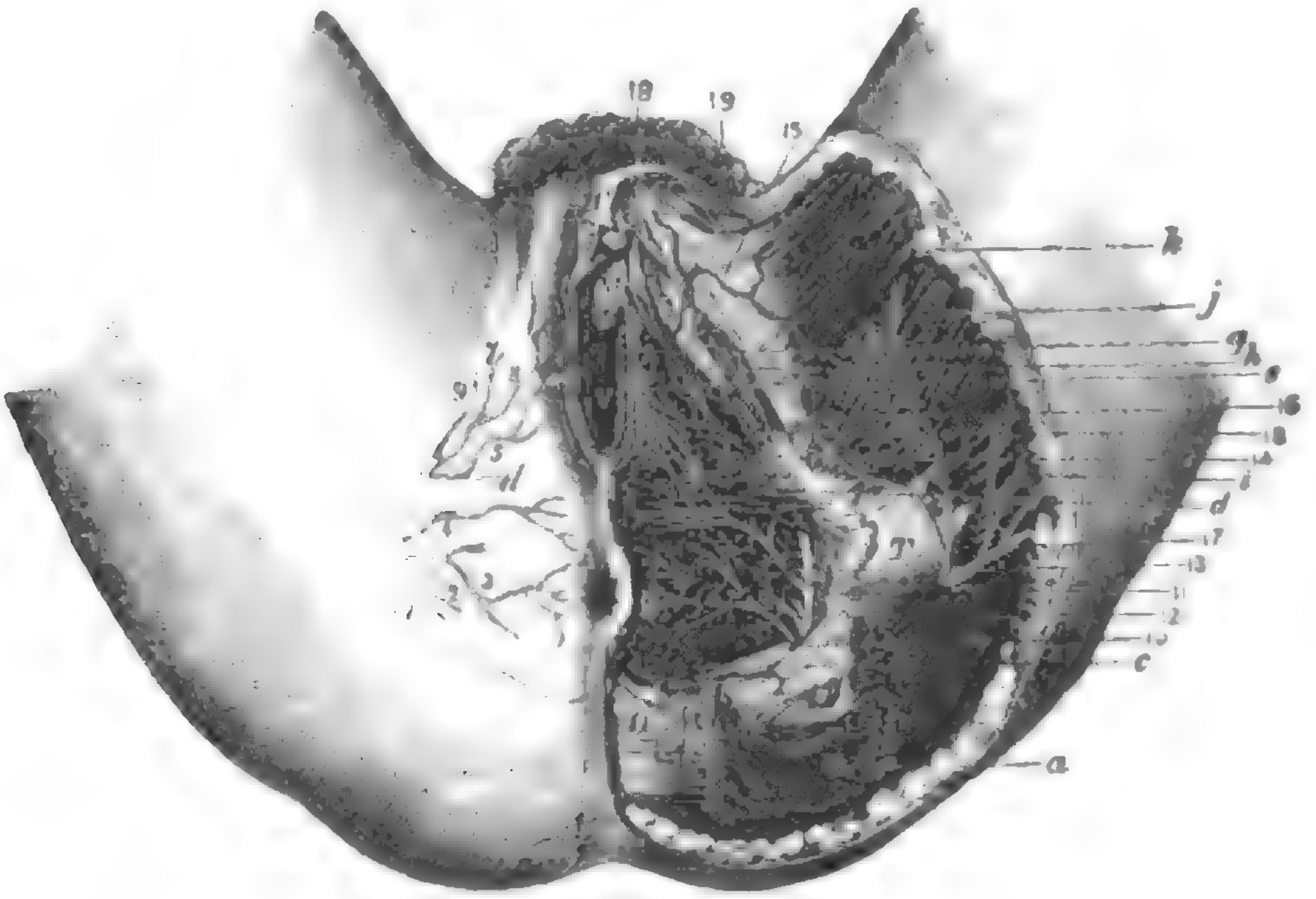

The Female Perineum.

1, Pudic artery.
2, Branch to Levator ani.
3, Inferior hemorrhoidal artery.
4, Transverse artery.
5, Great labial (superficial perineal) artery.
7, Dorsal artery of clitoris.
8, Artery of bulb.
9, Artery to crus clitoridis.
10, Inferior hemorrhoidal nerve.
11, Pudic nerve.
12, Muscular branch.
13, Internal superficial perineal nerve.
14, External superficial perineal nerve.
15, Its junction with—
16, Inferior pudendal nerve.
17, Small sciatic nerve.
18, 18, Dorsal nerve of clitoris.
19, Ilio-inguinal nerve.
A, Anus.
C, Clitoris.
M, Meatus urinarius.
L, Great sacro-sciatic ligament.
V, Vagina.
O, Coccyx.
T, Tuberosity of ischium.
a, Gluteus maximus.
c, Levator ani.
d, Superficial transverse muscle.
e, Compressor bulbi.
g, Erector clitoridis.
h, Triangular ligament (cut).
i, Biceps and Semitendinosus.
j, Adductor magnus.
k, Gracilis (Dr. Savage's *Illustrations*).]

The triangular ligament in the female is not so strong as in the male. It is attached to the pubic arch, its apex being connected with the symphysis pubis. It is divided in the middle line by the aperture of the vagina, with the external coat of which it becomes blended, and in front of this is perforated by the urethra. Its posterior border is continuous, as in the male, with the deep layer of the superficial fascia around the Transversus perinæi muscle.

The deep perineal fascia is perforated by the urethra about an inch below the symphysis pubis. The aperture is circular in form and about three or four lines in diameter. Above this is the aperture for the dorsal vein of the penis, and outside the latter the pudic nerve and artery pierce it.

The deep perineal fascia consists of two layers, anterior and posterior; these are separated above, but united below.

The *anterior layer* is continued forward around the anterior part of the membranous portion of the urethra, becoming lost upon the bulb.

The *posterior layer* is derived from the obturator fascia;[1] it is continued backward around the posterior part of the membranous portion of the urethra and the outer surface of the prostate gland.

---

[1] "On the Anatomy of the Posterior Layer of the Triangular Ligament," see a paper by Mr. Carrington, in *Guy's Hospital Reports*.

If the anterior layer of this fascia is detached on either side, the following parts are seen between it and the posterior layer: The subpubic ligament above, close to the pubes, the dorsal vein of the penis, the membranous portion of the urethra, and the Compressor urethræ muscle; Cowper's glands and their ducts; the pudic vessels and dorsal nerve of the penis; the artery and nerve of the bulb; and a plexus of veins.

The **Compressor Urethræ** (*Constrictor urethræ* [Guthrie's muscle, Fig. 678, 8, 9]) surrounds the whole length of the membranous portion of the urethra, and is contained between the two layers of the deep perineal fascia. It arises by aponeurotic fibres from the upper part of the ramus of the pubes on each side to the extent of half or three-quarters of an inch: each segment of the muscle passes inward and divides into two fasciculi, which surround the urethra from the prostate gland behind to the bulbous portion of the urethra in front, and unite at the upper and lower surfaces of this tube with the muscle of the opposite side by means of a tendinous raphé. [The perpendicular portion, generally called Wilson's muscle (Fig. 678, 10), is now usually discarded by anatomists.]

[Fig. 678.

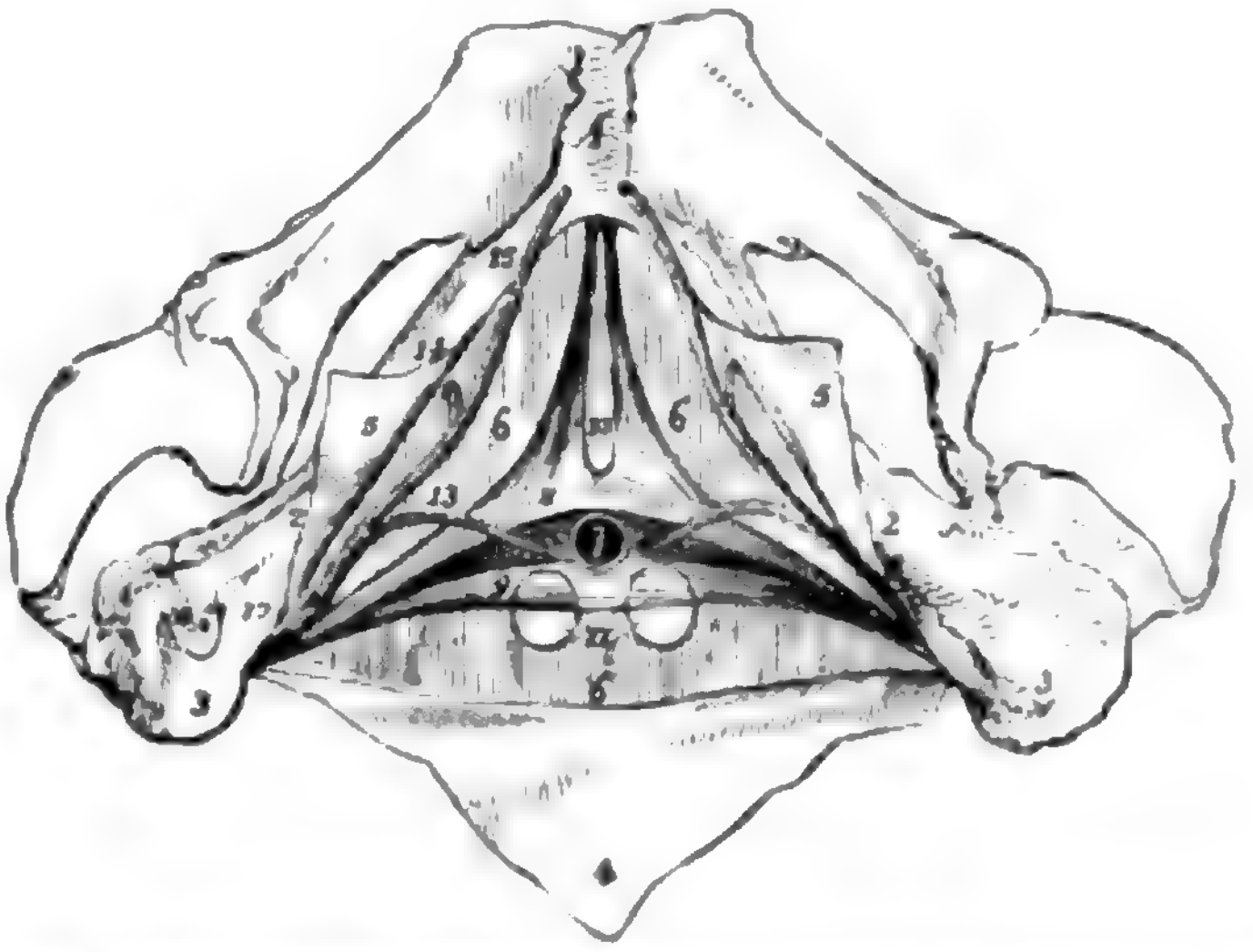

The Structures contained between the two Layers of the Deep Perineal Fascia: 1, the symphysis pubis; 2, 2, the ramus of the pubes and ischium; 3, 3, the tuberosities of the ischia; 4, a triangular portion of the superficial fascia turned down and shown to be continuous with the deep fascia (6); 5, 5, two portions of the superficial perineal fascia, showing its connection to the ramus of the pubes and ischium; 6, 6, the posterior layer of the deep perineal fascia, the anterior layer having been removed; 7, the membranous portion of the urethra cut across; 8, the superior fasciculus of the Compressor urethræ muscle of one side; 9, the inferior fasciculus of the Compressor urethræ. The two fasciculi (8 and 9) constitute Guthrie's muscle of one side; 10, the pubic portions of the Compressor urethræ, Wilson's muscles; 11, Cowper's glands, partly embraced by the lower fasciculus of the Compressor urethræ muscle; 12, the internal pudic artery, passing posteriorly to the crus of the Compressor urethræ; 13, the artery of the bulb; 14, the artery of the corpus cavernosum; 15, the arteria dorsalis penis (Wilson).]

Circular muscular fibres surround the membranous portion of the urethra from the bulb in front to the prostate gland behind; they are placed immediately beneath the transverse fibres already described, and are continuous with the muscular fibres of the bladder. These fibres are involuntary.

Cowper's Glands are situated immediately below the membranous portion of the urethra, close behind the bulb and below the artery of the bulb.

The *Pudic Vessels and Dorsal Nerve of the Penis* are placed along the inner margin of the pubic arch (pp. 588 and 778).

The *Artery of the Bulb* passes transversely inward from the internal pudic along the base of the triangular ligament, between the two layers of fascia, accompanied by a branch of the pudic nerve (p. 589).

If the posterior layer of the deep perineal fascia is removed and the crus penis of one side detached from the bone, the under or perineal surface of the Levator ani is brought fully into view. This muscle, with the triangular ligament in front and the Coccygeus and Pyriformis behind, closes in the outlet of the pelvis.

The **Levator ani** is a broad thin muscle situated on each side of the pelvis. It is attached to the inner surface of the sides of the true pelvis, and, descending, unites with its fellow of the opposite side to form the floor of the pelvic cavity. It supports the viscera in this cavity and surrounds the various structures which pass through it. It arises in front from the posterior surface of the body and ramus of the pubes on the outer side of the symphysis; posteriorly from the inner surface of the spine of the ischium; and between these two points from the angle of division between the obturator and recto-vesical layers of the pelvic fascia at their under part [Fig. 681, p. 1020]: the fibres pass downward to the middle line of the floor of the pelvis, and are inserted, the most posterior fibres into the sides of the apex of the coccyx; those placed more anteriorly unite with the muscle of the opposite side in a median fibrous raphé which extends between the coccyx and the margin of the anus. The middle fibres, which form the larger portion of the muscle, are inserted into the side of the rectum, blending with the fibres of the Sphincter muscles; lastly, the anterior fibres, the longest, descend upon the side of the prostate gland to unite beneath it with the muscle of the opposite side, blending with the fibres of the External sphincter and Transversus perinæi muscles at the tendinous centre of the perineum.

The anterior portion is occasionally separated from the rest of the muscle by areolar tissue. From this circumstance, as well as from its peculiar relation with the prostate gland, descending by its side and surrounding it as in a sling, it has been described by Santorini and others as a distinct muscle under the name of the *Levator prostatæ*. In the female the anterior fibres of the Levator ani descend upon the sides of the vagina.

FIG. 679.

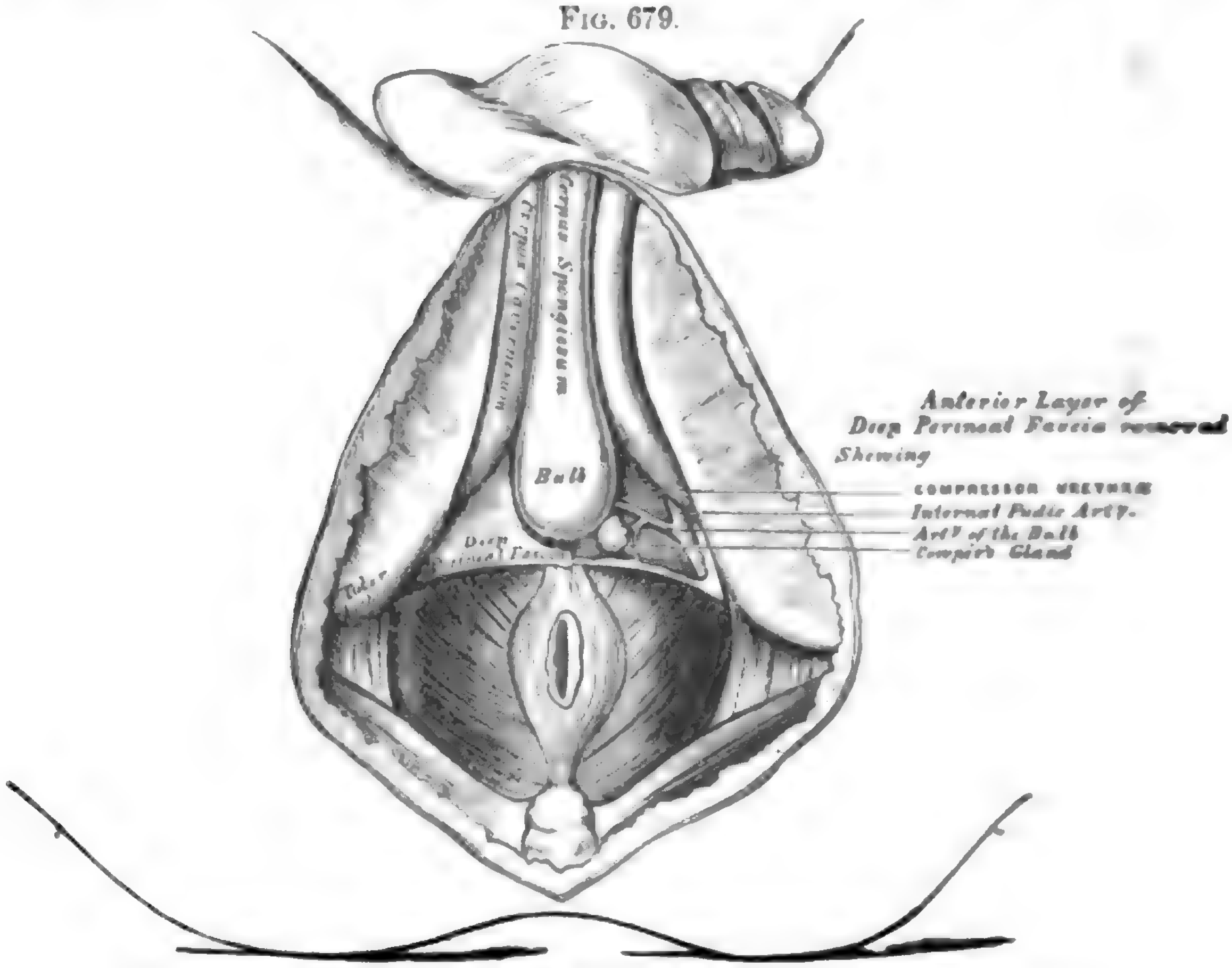

Deep Perineal Fascia; on the left side the anterior layer has been removed.

RELATIONS [Fig. 681].—By its *inner* or *pelvic surface* with the recto-vesical fascia, which separates it from the viscera of the pelvis and from the peritoneum. By its *outer* or *perineal surface* it forms the inner boundary of the ischio-rectal fossa, and is covered by a quantity of fat and by a thin layer of fascia (anal fascia) continued from the obturator fascia. Its *posterior border* is continuous with the Coccygeus muscle. Its *anterior border* is separated from the muscle of the opposite side by a triangular space through which the urethra, and in the female the vagina, passes from the pelvis.

ACTIONS.—This muscle supports the lower end of the rectum and vagina, and also the bladder, during the efforts of expulsion. It elevates and inverts the lower end of the rectum, after it has been protruded and everted during the expulsion of the feces. It is also a muscle of forced expiration.

The **Coccygeus** is situated behind and parallel with the preceding. It is a triangular plane of muscular and tendinous fibres, arising by its apex from the spine of the ischium and lesser sacro-sciatic ligament, and inserted by its base into the margin of the coccyx and into the side of the lower piece of the sacrum. This muscle is continuous with the posterior border of the Levator ani and closes in the back part of the outlet of the pelvis.

Relations.—By its *inner* or *pelvic surface* with the rectum; by its *external surface* with the lesser sacro-sciatic ligament; by its *posterior border* with the Pyriformis.

Action.—The Coccygei muscles raise and support the coccyx after it has been pressed backward during defecation or parturition.

Position of the Viscera at the Outlet of the Pelvis.—Divide the central tendinous point of the perineum, separate the rectum from its connections by dividing the fibres of the Levator ani, which descend upon the sides of the prostate gland, and draw the gut backward toward the coccyx, when the under surface of the prostate gland, the neck and base of the bladder, the vesiculæ seminales, and vasa deferentia will be exposed.

The **Prostate Gland** is placed immediately in front of the neck of the bladder around the prostatic portion of the urethra, its base being turned backward and its under surface toward the rectum. It is retained in its position by the Levator prostatæ and by the pubo-prostatic ligaments, and is invested by a dense fibrous covering continued from the posterior layer of the deep perineal fascia. The longest diameters of this gland are in the antero-posterior direction and transversely at its base; and hence the greatest extent of incision that can be made in it without dividing its substance completely across is obliquely outward and backward. This is the direction in which the incision is made through it in the operation of [lateral] lithotomy, the extent of which should seldom exceed an inch in length. The relations of the prostate to the rectum should be noticed: by means of the finger introduced into the gut the surgeon detects enlargement or other disease of this organ; he is enabled also by the same means to direct the point of a catheter when its introduction is attended with much difficulty either from injury or disease of the membranous or prostatic portions of the urethra.

Fig. 680.

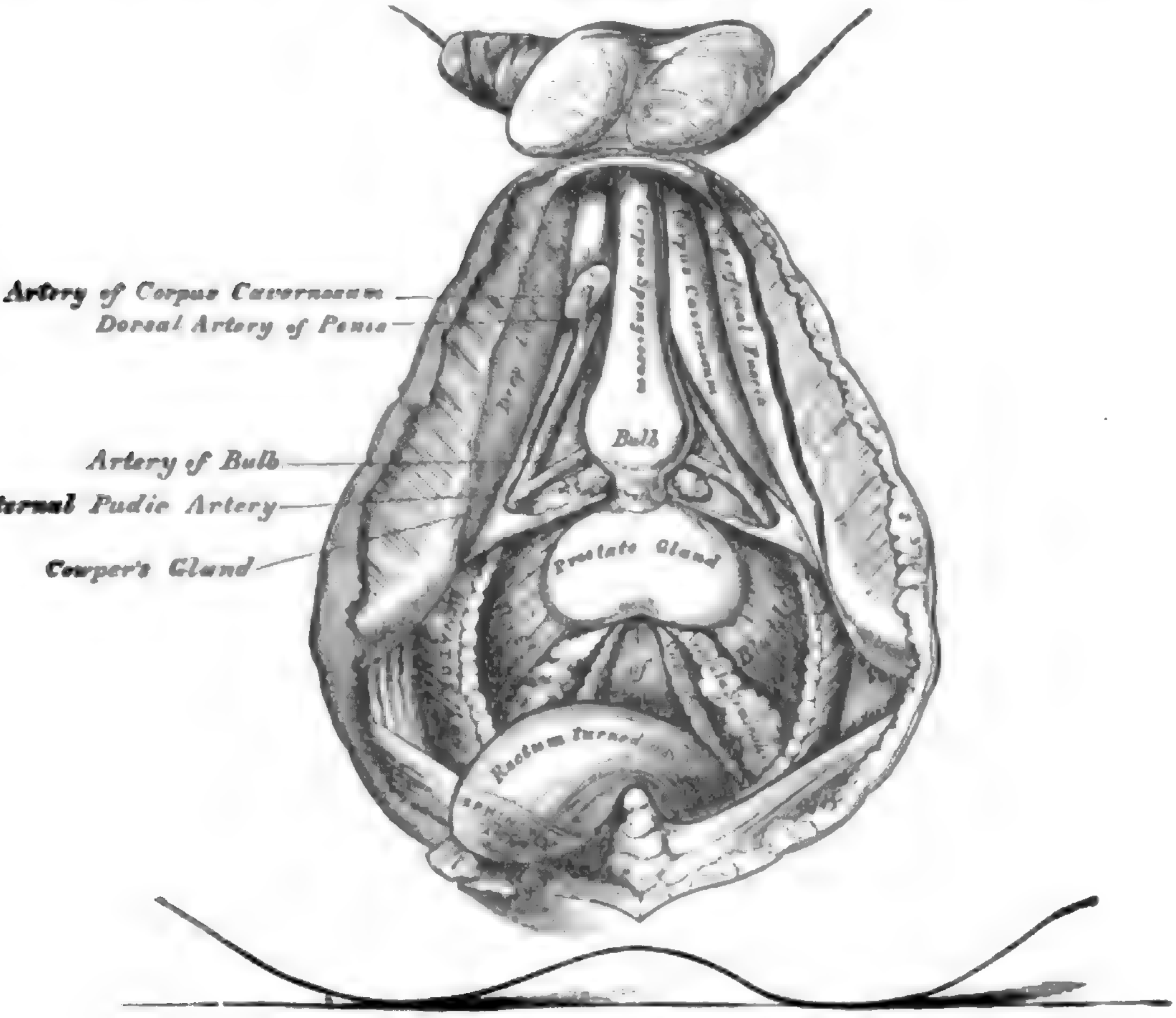

A View of the Position of the Viscera at the Outlet of the Pelvis.

Behind the prostate is the posterior surface of the neck and base of the bladder: a small triangular portion of this organ is seen, bounded in front by the prostate gland, behind by the recto-vesical fold of the peritoneum, on each side by the vesiculæ seminales and vasa deferentia, and separated from direct contact with the rectum by the recto-vesical fascia. The relation of this portion of the bladder to the rectum is of extreme interest to the surgeon. In cases of retention of urine this portion of the organ is found projecting into the rectum between three and four inches from the margin of the anus, and may be easily perforated during life without injury to any important parts; this portion of the bladder is consequently frequently selected for the performance of the operation of tapping the bladder. If the finger be introduced into the bowel, the surgeon may in some cases learn the position as well as the size and weight of a calculus in the bladder; and in the operation for its removal, if, as is not unfrequently the case, it should be lodged behind an enlarged prostate, it may be displaced from its position by pressing upward the base of the bladder from the rectum.

Parts Concerned in the Operation of Lithotomy.—The triangular ligament must be replaced and the rectum drawn forward so as to occupy its normal position.

FIG. 681.

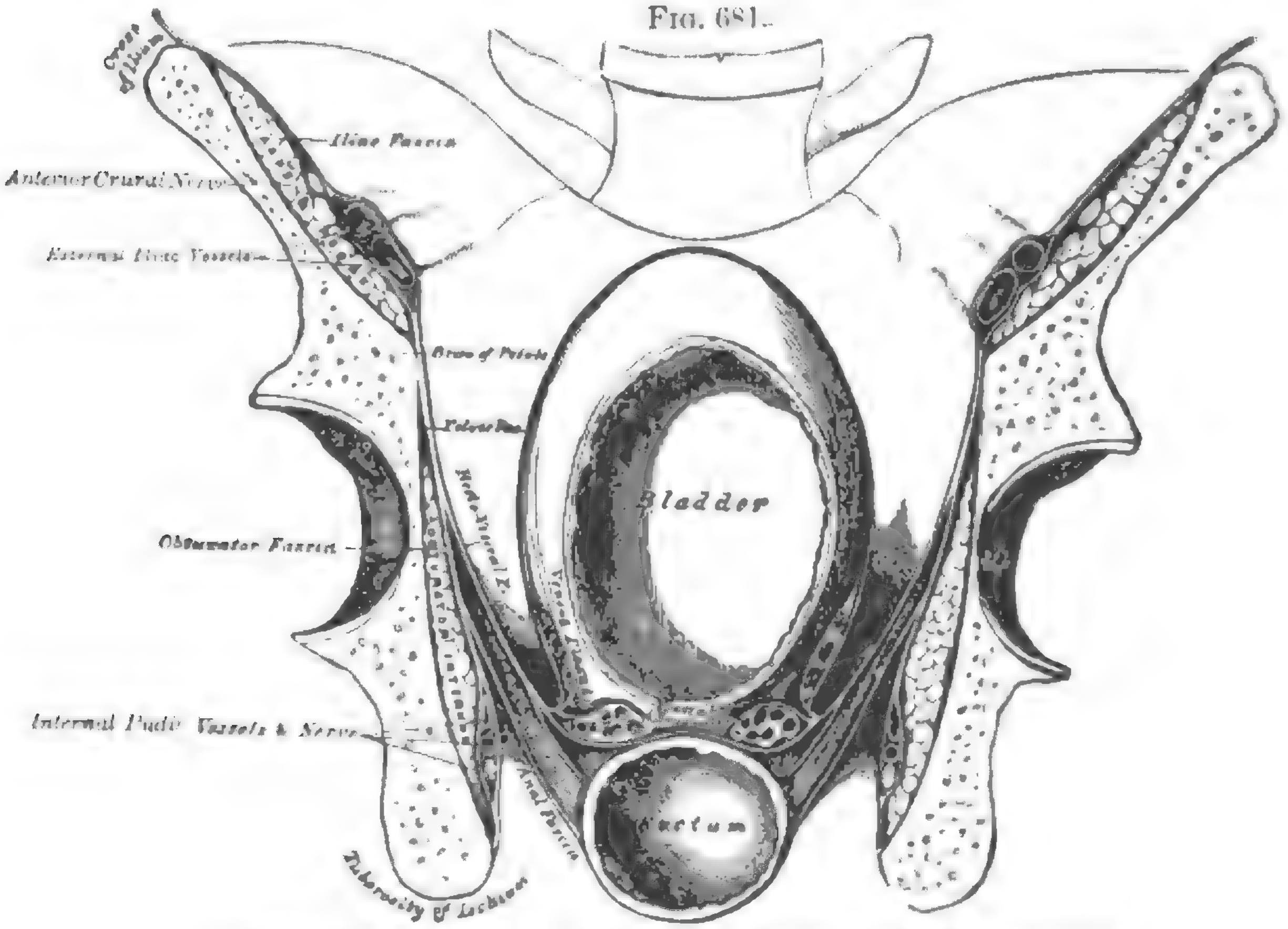

A Transverse Section of the Pelvis, showing the pelvic fascia from behind.

The student should then consider the position of the various parts in reference to the lateral operation of lithotomy. This operation is performed on the left side of the perineum, as it is most convenient for the right hand of the operator. A staff having been introduced into the bladder, the first incision is commenced midway between the anus and the back of the scrotum (*i. e.* in an ordinary adult perineum about an inch and a half in front of the anus), a little on the left side of the raphé, and carried obliquely backward and outward to midway between the anus and tuberosity of the ischium. The incision divides the integument and superficial fascia, the inferior hemorrhoidal vessels and nerves, and the superficial and transverse perineal vessels; if the forefinger of the left hand is thrust upward and forward into the wound, pressing at the same time the rectum inward and backward, the staff may be felt in the membranous portion of the urethra. The finger is fixed upon the staff, and the structures covering it are divided with the point of the knife, which must be directed along the groove toward the bladder, the edge of the knife being turned outward and backward, dividing in its course the membranous portion of the urethra and part of the left lobe of the prostate gland to the extent of about an inch. The knife is then withdrawn and the forefinger of the left hand passed along the staff into the bladder: the staff having been withdrawn and the position of the stone ascertained, the forceps is introduced over the finger into the bladder. If the stone is very large, the opposite side of the prostate may be notched before the forceps are introduced: the finger is now withdrawn, and the blades of the forceps opened and made to grasp the stone, which must be extracted by slow and cautious undulating movements.

Parts Divided in the Operation.—The various structures divided in this operation are as follows: The integument, superficial fascia, inferior hemorrhoidal vessels and nerves, the posterior fibres of the Accelerator urinæ, the Transversus perinæi muscle and artery (and, probably, the superficial perineal vessels and nerve), the deep perineal fascia, the anterior fibres of the Levator ani, part of the Compressor urethræ, the membranous and prostatic portions of the urethra, and part of the prostate gland.

Parts to be Avoided in the Operation.—In making the necessary incisions in the perineum for the extraction of a calculus the following parts should be avoided: The primary incision should not be made too near the middle line, for fear of wounding the bulb of the corpus spongiosum or the rectum; nor too far externally, otherwise the pudic artery may be implicated as it ascends along the inner border of the pubic arch. If the incisions are carried too far forward, the artery of the bulb may be divided; if carried too far backward, the entire breadth of the prostate and neck of the bladder may be cut through, which allows the urine to become infiltrated behind the pelvic fascia into the loose areolar tissue between the bladder and rectum, instead of escaping externally; diffuse inflammation is consequently set up, and peritonitis, from the close proximity of the recto-vesical peritoneal fold, is the consequence. If, on the contrary, the prostate is divided in front of the base of the gland, the urine makes its way externally, and there is less danger of infiltration taking place.

During the operation it is of great importance that the finger should be passed into the bladder *before* the staff is removed; if this is neglected and if the incision made through the prostate and neck of the bladder is too small, great difficulty may be experienced in introducing the finger afterward; and in the child, where the connections of the bladder to the surrounding parts are very loose, the force made in the attempt is sufficient to displace the bladder up into the abdomen out of the reach of the operator. Such a proceeding has not unfrequently occurred, producing the most embarrassing results and total failure of the operation.

It is necessary to bear in mind that the arteries in the perineum occasionally take an abnormal course. Thus the artery of the bulb, when it arises, as sometimes happens, from the pudic opposite the tuber ischii, is liable to be wounded in the operation for lithotomy in its passage forward to the bulb. The accessory pudic may be divided near the posterior border of the prostate gland if this is completely cut across, and the prostatic veins, especially in people advanced in life, are of large size, and give rise, when divided, to troublesome hemorrhage.

PELVIC FASCIA.

The **Pelvic Fascia** (Fig. 682) is a thin membrane which lines the whole of the cavity of the pelvis and is continuous with the transversalis and iliac fasciæ. It is attached to the brim of the pelvis for a short distance at the side of the cavity, and to the inner surface of the bone round the attachment of the Obturator internus. At the posterior border of this muscle it is continued backward as a very thin membrane in front of the Pyriformis muscle and sacral nerves, behind the branches of the internal iliac artery and vein (which perforate it), to the front of the sacrum. In front it follows the attachment of the Obturator internus to the bone, arches beneath the obturator vessels, completing the orifice of the obturator canal, and at the front of the pelvis is attached to the lower part of the symphysis pubis. At the level of a line extending from the lower part of the symphysis pubis to the spine of the ischium is a thickened whitish band; this marks the attachment of the Levator ani muscle to the pelvic fascia, and corresponds to its point of division into two layers, the obturator and recto-vesical.

The **obturator fascia** descends and covers the Obturator internus muscle. It is a direct continuation of the pelvic fascia below the white line above mentioned, and is attached to the pubic arch and to the margin of the great sacro-sciatic ligament. From its attachment to the pubes a process is given off which is continuous with a similar process from the opposite side, so as to close the front part of the outlet of the pelvis, forming the posterior layer of the triangular ligament. This fascia forms a canal for the pudic vessels and nerve in their passage forward to the perineum, and is continuous with a thin membrane which covers the perineal aspect of the Levator ani muscle, called the *ischio-rectal* (*anal*) *fascia*.

FIG. 682.

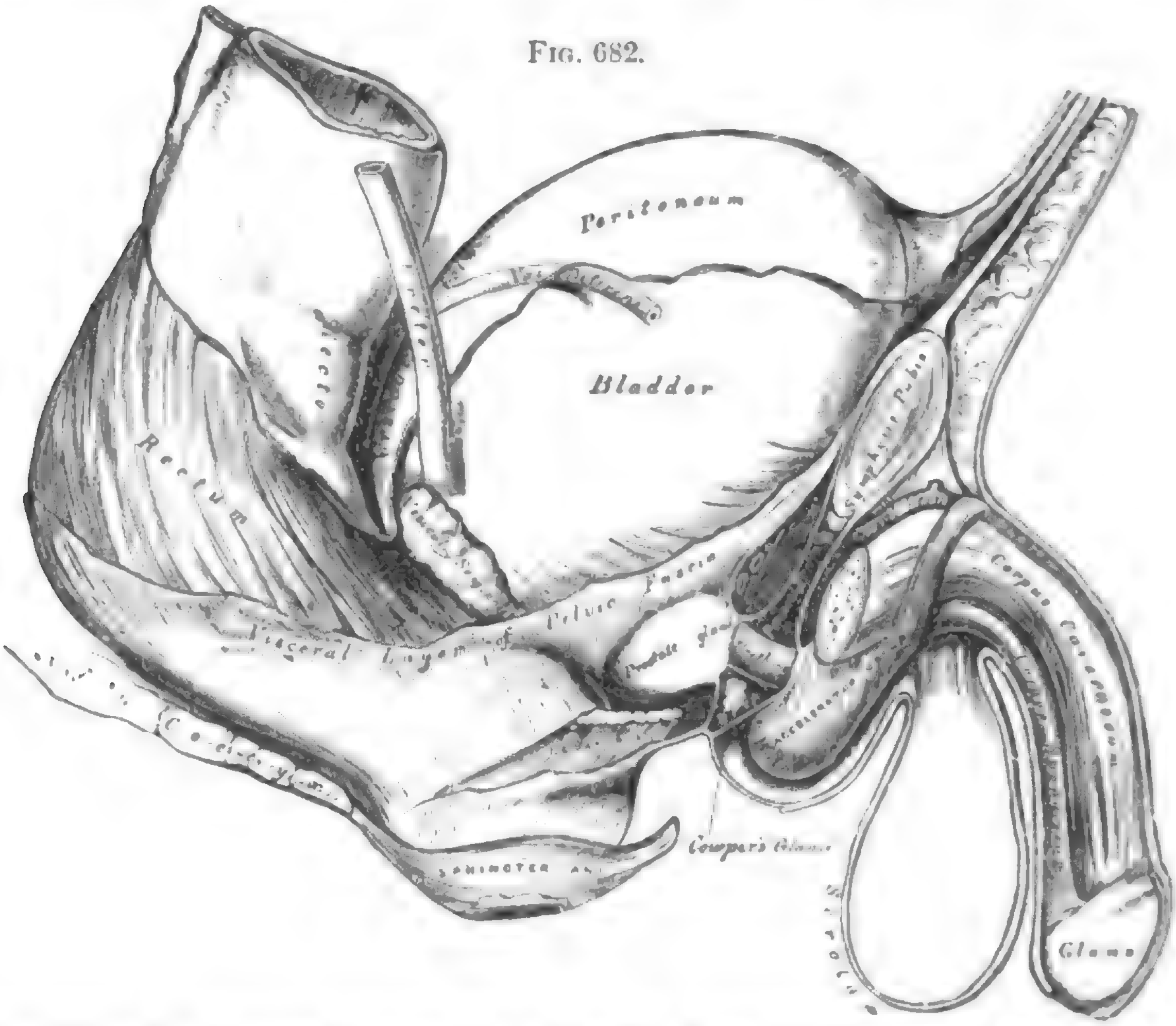

Side View of the Pelvic Viscera of the Male Subject, showing the pelvic and perineal fasciæ. [Compare with Fig. 639, p. 956.]

The **recto-vesical fascia** (*visceral layer of the pelvic fascia*) descends into the pelvis upon the upper surface of the Levator ani muscle, and invests the prostate, bladder, and rectum. From the inner surface of the symphysis pubis a short rounded band is continued to the upper surface of the prostate and neck of the bladder, forming the pubo-prostatic or anterior true ligaments of the bladder. At the side this fascia is connected to the side of the prostate, enclosing this gland and the vesico-prostatic plexus of veins, and is continued upward on the surface of the bladder, forming the lateral true ligaments of the organ. Another prolongation invests the vesiculæ seminales and passes across between the bladder and rectum, being continuous with the same fascia of the opposite side. Another thin prolongation is reflected round the surface of the lower end of the rectum. The Levator ani muscle arises from the point of division of the pelvic fascia, the visceral layer of the fascia descending upon and being intimately adherent to the upper surface of the muscle, while the under surface of the muscle is covered by a thin layer derived from the obturator fascia, called the ischio-rectal or anal fascia. In the female the vagina perforates the recto-vesical fascia and receives a prolongation from it.

LANDMARKS,

MEDICAL AND SURGICAL.

BY

LUTHER HOLDEN,

EX-PRESIDENT, MEMBER OF COUNCIL, AND MEMBER OF THE COURT OF EXAMINERS OF THE ROYAL COLLEGE OF SURGEONS OF ENGLAND; CONSULTING SURGEON TO SAINT BARTHOLOMEW'S AND THE FOUNDLING HOSPITALS;

ASSISTED BY

JAMES SHUTER, M.A. CAMB., F.R.C.S.,

ASSISTANT SURGEON TO THE ROYAL FREE HOSPITAL; LATE DEMONSTRATOR OF PHYSIOLOGY, AND LATE ASSISTANT DEMONSTRATOR OF ANATOMY, AT SAINT BARTHOLOMEW'S HOSPITAL.

FROM THE THIRD ENGLISH EDITION, WITH ADDITIONS,

BY

WILLIAM W. KEEN, M.D.,

PROFESSOR OF SURGERY IN THE WOMAN'S MEDICAL COLLEGE OF PENNSYLVANIA; PROFESSOR OF ARTISTIC ANATOMY IN THE PENNSYLVANIA ACADEMY OF THE FINE ARTS; FORMERLY LECTURER ON ANATOMY IN THE PHILADELPHIA SCHOOL OF ANATOMY; SURGEON TO ST. MARY'S HOSPITAL; FELLOW OF THE COLLEGE OF PHYSICIANS OF PHILADELPHIA, ETC.

1887.

"*Chirurgus mente prius et oculis agat quam manu armata.*"

LANDMARKS,

MEDICAL AND SURGICAL.

[See on p. 33 of *Gray's Anatomy* (edition of 1887) the introductory paper, by W. W. Keen, M. D., the American editor, "*On the Systematic Use of the Living Model in Teaching Anatomy.*"]

1. In clinical teaching we often have occasion to point out, on the surface of the living body, what may be called "medical and surgical landmarks.". By "landmarks" we mean surface-marks, such as lines, eminences, depressions, which are guides to, or indications of, deeper-seated parts. This practice is not only most useful, but absolutely necessary, because many even advanced students of anatomy are not so ready as they ought to be in their recognition of parts when covered by skin. Students who may be familiar enough with bones, muscles, blood-vessels, or viscera in the dissected subject are often sadly at fault when they come to put this knowledge into practice in the living.

For instance, ask a student to put his finger on the exact place where he would feel for the head of the radius, the coracoid process of the scapula, the tubercle of the scaphoid bone in the foot; ask him to compress effectually one of the main arteries, to chalk the line of its course; to map on the chest the position of the heart and the several valves at its base; to trace along the walls of the chest the outline of the lungs and pleura; to point out the bony prominences about the joints, and their relative position in the different motions of the joints; test him about the muscles and tendons which can be seen or felt as they stand out in relief or remain in repose; let him introduce his finger into the several orifices of the body and say what parts are accessible to the touch,—questions such as these even a good anatomist, unaccustomed to deal with the living subject, might possibly find himself at a loss to answer.

2. **Object in View.**—Our main object, therefore, is to induce in students the habit of looking at the living body with anatomical eyes, and with eyes, too, at their fingers' ends. The value of this habit cannot be too highly estimated. Is it not of the utmost importance to an operating surgeon that he should have in his mind's eye the various structures of the body as they lie grouped, connected, and working together? Should he not try at least to see them with the same clearness and accuracy as if they were perfectly transparent?

Moreover, the habit of examining the living body with "anatomical eyes" and "surgical fingers" teaches the eye and the hand to act together, and trains that delicate sense of touch which every surgeon should possess.

This habit is within easy reach of any one who has carefully dissected for himself and learned what to feel for. Plates will not give him this knowledge. Let a student examine his own body with a skeleton before him. Better still that two should work thus together, each serving as a model to the other.

Teachers of anatomy should follow the example of Sir C. Bell, who was in the habit of introducing, from time to time, a powerful muscular fellow to his class, "in order to show how much of the structure of the body, such as the articulations and the muscles, might be learned without actual dissection."[1]

At the same time, it is only fair to say that "landmarks" cannot always be defined with precision. A considerable latitude must be allowed for natural variations in different persons. In some their anatomy stands out beautifully clear; in others it is masked by obesity. Selecting, therefore, for study a moderately lean person, let us begin with the head.

---

[1] Some pertinent remarks on this subject have been made by Mr. C. Heath in a pamphlet *On Anatomy in Relation to Physic.*

THE HEAD.

3. **Scalp: its Density.**—The great toughness of the scalp, more especially at the back of the head, is owing to its intimate connection with the cranial aponeurosis, the scalp-vessels and hair-bulbs intervening. This density often obscures the diagnosis of tumors on the cranium. A tumor growing upon the head may be either above or below the aponeurosis of the scalp. If below, it will have a firm resisting feel, being bound down by the aponeurosis. Nevertheless, its firmness and resistance may depend not simply on its confinement beneath the aponeurosis, but on its having its origin [from the skull or] within the skull. Look with suspicion, then, on every tumor on the head that will not readily permit you to move it about, so as to be sure of its connections prior to an attempt at extirpation.

The scalp moves freely over the pericranium, to which it is very loosely connected by areolar tissue. When suppuration takes place in this tissue, free incisions through the dense scalp must be made to let the pus out.

4. **Arteries of Scalp.**—The supraorbital artery can be felt beating just above the supraorbital notch, and traced for some way up to the forehead; the temporal (anterior branch) ascends tortuously about one inch and a quarter behind the external angular process of the frontal bone; the occipital can be felt near the middle of a line drawn from the occipital protuberance to the mastoid process; the posterior auricular, near the apex of the mastoid process. All these arteries can be effectually compressed against the subjacent bone.

5. **Skull-cap.**—The skull-cap is rarely quite symmetrical. This want of symmetry is often obvious. It may occur in men highly gifted, as in the celebrated French anatomist Bichat. As to shape and relative dimensions, no two heads are exactly alike, any more than are two faces. It is beside my present purpose to go into the question of craniology, more than to say that, although the cranium does not exactly follow the brain in all its eminences and depressions so as to be like a cast of its surface, yet it certainly indicates the dimensions of the great cerebral masses. The prominence of the frontal and parietal "eminences" and of the occipital region may be taken as a general indication of the development of the corresponding lobes of the brain. To ascertain the relative proportions of these three regions, let a thread be passed from one meatus auditorius to the other, across the frontal, parietal, and occipital eminences respectively.

[**Anterior Fontanelle.**—At the junction of the sagittal and the coronal sutures in the new-born child is the anterior fontanelle, caused by the as yet incomplete ossification of the frontal and the parietal bones. It closes at about twelve to eighteen months of age. Its condition, as to whether it is a hollow or a hill, is important, for it shows the wasting of the fluids of the body, as in the summer diarrhœas of children, or the redundancy of fluid within the skull, as in hydrocephalus. The pulse of a sleeping child can often be counted at the fontanelle by the eye alone. In the adult the *bregma*, or point of junction of the sagittal and coronal sutures, is situated, as I have determined on 185 skulls, .375 of an inch in front of the line joining the two external auditory meatuses. In 16 of these skulls it was on the line, and in 7 behind it.]

Frontal Sinuses.—The frontal sinuses formed by the separation of the two tables of the skull vary much in size in different persons and at different periods of life. This fact has an important bearing on wounds in the forehead and on trephining in this situation. These "bumps" do not exist in children, because the tables of the skull do not begin to separate before puberty. From an examination of many skulls in the Hunterian Museum, I find that the absence of the "bumps," even in middle age, does not necessarily imply the absence of the sinuses, since they may be formed by a retrocession of the inner wall of the skull. In old persons, as a rule, when the sinuses enlarge it is by the encroachment of the inner table on the brain-case. The inner wall of the skull here follows the shrinking brain. It is therefore important to bear in mind that an adult, and more especially an elderly person, may have a large frontal sinus without any external indication of it.

Neither does a very prominent bump necessarily imply the existence of a large sinus or indeed of even a small one. The "bump" may be a mere heaping up of bone, a degradation, as in some Australian skulls.

Mastoid Process.—The mastoid process, which can be felt behind the ear, contains air-cells, to which the above observations may also be applied. ["Mastoid disease," or suppuration in these cells, which, like the frontal sinuses, are lined by mucous membrane, causes pain, tenderness, and swelling over the process, and almost always demands early trephining to evacuate the pus.]

Occipital Protuberance.—The occipital protuberance and the superior curved line can be distinctly felt at the back of the head. The protuberance is always the thickest part of the skull-cap, and more prominent in some than in others.

The **posterior inferior angle of the parietal bone,** grooved by the lateral sinus, is on a level with the zygoma, and a trifle more than one inch behind the front border of the mastoid process.

Lines of Cerebral Sinuses.—A line drawn over the head from the root of the nose to the occipital protuberance corresponds with the superior longitudinal sinus. [As the left hemisphere is the larger of the two, the sinus lies mostly to the *right* of the middle line, the right border of the sinus being indicated by a line at the extremity of the dentations of the sagittal suture.] Another line drawn from the occipital protuberance to the front border of the mastoid process corresponds with a part of the lateral sinus.

Middle Meningeal Artery.—The trunk of the middle meningeal artery runs along the front lower corner of the parietal bone, about one inch and a half behind and half an inch above the external angular process of the frontal [or one inch and a half above the zygoma: this is a more definite measuring-point vertically].

A straight line drawn from the front of one mastoid process to the other would pass through the middle of the condyles of the occiput, showing how nearly the skull is balanced on the top of the spine in the erect posture.

6. **Thickness of Skull-cap.**—The average thickness of the cap of an adult skull is about $\frac{1}{5}$ of an inch. The thickest part is at the occipital protuberance, where it is often $\frac{3}{4}$ of an inch or more, even in an otherwise thin skull. The thinnest part is at the temple, where it may be almost as thin as parchment. Every one in the habit of making post-mortem examinations knows how much the skull-cap differs in thickness in different persons and in different parts of same skull. In old persons it is often in some parts not thicker than a shilling, owing to absorption of the diploë. Another point of interest is that the inner plane of the cap is not always parallel with the outer. Hence, in applying the trephine this is not a bad rule: "Think that you are operating on the thinnest skull ever seen, and thinner in one half of the circle than the other."

7. **Levels of the Brain.**—The level of the anterior lobes in front corresponds with a straight line drawn across the forehead just above the eyebrows. The lower level of the anterior and middle lobes of the cerebrum corresponds with a line drawn from the external angular process of the frontal bone to the upper part of the meatus auditorius. Another line drawn from the meatus to the occipital protuberance corresponds with the lower level of the posterior lobe. The lower level of the cerebellum cannot be defined by external examination. It depends upon the extent to which the occipital fossæ bulge into the nape of the neck; and this bulge varies in different skulls.

[**Ear.**—The axis of the auditory canal is not directly transverse, but inward and forward, toward the opposite temple—a fact of importance in the use of instruments or of injections into the ear. The canal should always be inspected with care for abscesses, foreign bodies, or impacted wax, and, in cases of possible fracture at the base of the skull, for the escape of cerebro-spinal fluid. About one inch from the external meatus the canal is closed by the *membrana tympani.* This can be seen best through a speculum by reflected light from a hand or forehead mirror, but not uncommonly it can be seen without the speculum. To examine the auditory canal or the membrana tympani the auricle must be pulled gently, but decidedly, upward and backward.]

[**Cerebral Localization and Topography.**—(See Gray's *Anatomy*, p. 681).]

THE FACE.

8. The approaches to the organs of the senses, their ever-varying expression, their numerous muscles, and their rich profusion of vessels and nerves, give the face great anatomical importance, which has a most valuable bearing, not only on the practice of surgery, but on the physiognomy of health and in the diagnosis of disease.

9. **Foramina for Branches of Fifth Nerve.**—As a surgeon may be called upon to divide any one of the three chief branches of the fifth nerve upon the face, he looks with interest to the precise situations where they leave their bony foramina with their corresponding arteries. The supraorbital notch or foramen can be felt about the junc-

tion of the inner with the middle third of the supraorbital margin. From this point a perpendicular line drawn with a slight inclination outward, so as to cross the interval between the two bicuspid teeth in both jaws, passes over the infraorbital and the mental foramina. The direction of these two lower foramina looks toward the angle of the nose. [The canal in the lower jaw for the inferior dental nerve, it must be remembered, in persons who have lost the alveolar process by absorption, lies by so much nearer the upper margin of the jaw. A trephine must, therefore, in such persons be applied well above the middle of the bone, or the canal may be missed entirely.]

10. **Pulley for Superior Oblique Muscle.**—By pressing the thumb beneath the internal angular process of the frontal bone the cartilaginous pulley for the tendon of the Superior oblique muscle can be distinctly felt. We should be careful not to interfere with this pulley in any operation about the orbit.

11. **Lower Jaw.**—The working of the condyle of the jaw vertically and from side to side can be distinctly felt [and seen] in front of the ear. When the mouth is opened wide the condyle advances out of the glenoid cavity on to the eminentia articularis, and returns into its socket when the mouth is shut. The muscle which causes this advance is the External pterygoid, and it gives the jaw a greater freedom of grinding motion.

The posterior margin of the ramus of the lower jaw corresponds with a line drawn from the condyle to the angle. In opening abscesses in the parotid region the knife should not be introduced behind this line, for fear of wounding the external carotid artery. Punctures to any depth may be safely made in front of it. They are often necessary where inflammation of the parotid gland ensues after eruptive fevers and runs on to suppuration. The swelling, tension, and pain are most distressing. Owing to the fibrous framework of the gland the matter is not circumscribed, but diffused. One puncture is not enough. Three or more may be requisite. The blade of the knife should be held horizontally, so as to be less likely to injure the branches of the facial nerve. [These incisions are better made in the direction of radii from a point just below the ear.] We are not to be disappointed if no matter flows. The punctures give relief, and matter will probably exude the next day.

[**Zygoma.**—In front of the ear lies the zygoma, one of the most marked and important landmarks to the touch, and in lean persons to the eye.

Seventh Nerve.—This nerve, after emerging from the stylo-mastoid foramen, passes into the parotid gland and is distributed to the facial muscles, its branches running toward the temple, the eye, the cheek, and the jaw. It can always readily be galvanized in facial palsy, etc. by placing one pole below the lobule of the ear and the other at the desired points of the face.]

12. **Parotid Duct.**—A line drawn from the bottom of the lobe of the ear to midway between the nose and the mouth gives the course of the parotid duct. Opposite the second upper molar the duct opens by a papilla into the mouth [which can be readily seen]. The branch of the facial nerve which supplies the Buccinator runs with the duct.

13. **Temporal and Facial Arteries.**—The pulsation of the trunk of the temporal artery can be felt between the root of the zygoma and the ear. This should be well known to and used by chloroformists. It is also a convenient pulse to feel in a sleeping patient. The facial artery can be distinctly felt as it passes over the body of the jaw at the anterior edge of the Masseter; again near the corner of the mouth close to the mucous membrane; and lastly by the side of the ala nasi up to the inner side of the tendo oculi. By holding the lips between the finger and thumb the coronary arteries are felt under the mucous membrane [and can be compressed here either by the finger and thumb or by a spring clip in hare-lip and other similar operations]. The facial vein does not accompany the tortuous artery, but runs a straight course from the inner angle of the eye to the front border of the Masseter, just behind the artery.

14. **Eyelids and Eyes.**—The opening between the eyelids varies in size in different persons; hence more of the eyeball is seen in some than in others, and the eye appears larger. Although human eyes do vary a little in size, yet the actual difference is by no means so great as is generally supposed. The size of the fissure has much to do with the apparent size of the eye. Contrast the narrow fissure of the Chinese and Mongolian races and the apparent smallness of their eyes with those of Europeans. As a rule, the external angle of the lid is higher than the internal. When not exaggerated it gives the face an arch and pleasing expression.

Evert the lids to see the Meibomian glands; observe their perpendicular arrangement in the substance of the tarsal cartilages. [Eversion of the upper lid is best done while the patient is looking down, by placing a pencil on the lid, next seizing the eyelashes, and then pushing the pencil gently downward, while by the lashes the free border of the lid is lifted over it. In case of a suspected foreign body, if it be not found on the lid, it must be remembered that it may easily be in the cornea and have been overlooked on the dark iris or pupil as a background. Oblique light will best reveal it if there.]

The free borders of the lids are not bevelled, as described by J. L. Petit and most anatomists, "so as to form with the globe of the closed eye a triangular canal for the flow of the tears." On the contrary, it is easily seen that the lid-margins, when closed, come into accurate contact. The plane is not exactly horizontal, but slightly inclined upward.

Every time the eye is shut the ball turns upward and inward, so that the cornea is completely covered by the upper lid. This may be well seen by raising the lid of a sleeping infant; also in cases of low fever when the lid is not completely closed. The upturning of the eye obviously clears the cornea and protects it from the light.

A careful examination of the motion of the lower lid in the act of shutting the eye proves that it is a double motion. The lid is not only slightly raised, but drawn inward about $\frac{1}{12}$ of an inch. This second movement sweeps any particles of dust as well as moisture toward the inner canthus.

15. **Puncta Lachrymalia.**—The puncta lachrymalia are distinctly visible [as two little black dots] at the inner angles of the lids. The lower punctum is larger and a little more external than the upper, so that they are not exactly opposite. The direction, too, of the puncta deserves notice. Their open mouths look a little backward, ready to imbibe the tears. When their proper bearing is lost, as in facial paralysis or by a cicatrix near the lid, the tears overflow the cheek. The length of the lachrymal canals is from three to four lines. The lower is a little shorter and wider than the upper. As each makes a little angle in its course about a line from its orifice, the lid should be drawn outward to straighten the canal when we introduce a probe.

16. **Lachrymal Sac.**—To find the lachrymal sac, draw outward the eyelids to tighten the tendo oculi, which crosses the sac a little above its middle. A knife introduced just below the tendon close to the edge of the orbit would enter the sac. The angular artery and vein would be on the inner side of the incision. A probe directed in a line with the inner edge of the orbit—*i. e.* downward, outward, and backward—would pass down the nasal duct and appear in the inferior meatus of the nose.

The tendo oculi serves many purposes besides giving attachment to the cartilages and muscles of the lids. One purpose is said to be to pump the tears into the lachrymal sac. Place a finger on the tendon and feel that it tightens every time the lids are closed. The tendon, being intimately connected to the sac, draws, as it tightens, the sac-wall outward and forward, and in this way it may pump along the lachrymal canals any fluid collected at the angle of the eye. [This is by the action of the Tensor tarsi (Horner's) muscle.]

17. **Nasal Duct.**—The nasal duct is from six to eight lines long, and narrowest in the middle of its course. Its termination in the inferior meatus lies under the inferior spongy bone, about a quarter of an inch behind the bony edge of the nostril. The appearance of the orifice in the dry bone conveys no idea of its size and shape in life, for it is diminished by a valve-like fold of mucous membrane, so that it becomes in most cases a mere slit, not exceeding a line in diameter.

The facility with which instruments can be introduced into the nasal opening of the duct depends upon its position as well as its size. This position varies in different instances. Sometimes it opens directly into the roof of the inferior meatus, in which case the hole is large and round, so that tears readily run into the nose. In other instances the opening is situated on the outer wall of the meatus, and is then always such a narrow fissure as to be hardly discernible. The practical conclusion, then, is, that a probe can be easily introduced when the opening is in the roof of the meatus, but not without difficulty and laceration of the mucous membrane when on the outer wall. This difficulty, indeed, may be increased by the narrowness of the meatus, arising from an unusual curvature of the spongy bone.

18. **Nose and Nasal Cavities.**—The line where the cartilages of the nose are attached to the nasal and superior maxillary bones can be traced with precision. The close connection of the skin to the cartilages admits of no stretching; hence the acute pain felt in erysipelas and boils on the nose. The external aperture of the nose is always placed a little lower than the floor of the nostril, so that the nose must be pulled up before we can inspect its cavities.

Looking into the nostrils, we find that the left is, in the majority of cases, narrower than the right, owing to an inclination of the septum toward the left. A communication sometimes exists between them through a hole in the septum, as in the case of the celebrated anatomist Hildebrandt. By stretching open the anterior nares we can get a view of the end of the inferior spongy bone. The middle spongy bone cannot be seen: its attachment to the ethmoid is high up, nearly opposite the tendo oculi. [With the head thrown well back this middle turbinated bone can be seen. It is important not to mistake these spongy bones for polypi.] The cavities are so much narrowed transversely by the spongy bones that in the extraction of polypi it is better to dilate the blades of the forceps perpendicularly and near the septum.

[**Lips.**—The color of the vermilion border the doctor ought always, and even unconsciously, to notice as a means of judging of the condition of the circulation and the character of the blood.]

19. **Mouth.**—What can be seen and felt through the mouth? The upper surface of the tongue, "*speculum primarum viarum*," is a study in itself. We notice on its under surface a median furrow, on each side of which stands out the ranine vein, lying upon the prominent fibres of the lingualis. In the middle line of the floor of the mouth is the frænum linguæ, with the orifice of the duct of the submaxillary gland on each side of it. The gland itself can be detected immediately beneath the mucous membrane by feeling farther back near the angle of the jaw, at the same time pressing the gland upward from below.

The long ridge of mucous membrane on each side of the floor contains the sublingual glands.

We can feel the attachment of the Genio-hyo-glossi behind the symphysis of the jaw. The division of this attachment would enable a surgeon to draw the tongue more freely out of the mouth in any attempt to remove carcinoma extending far back into its root.

There is great difference in the shape of the hard palate: this difference depends upon the depth of the alveolar processes. In some it forms a broad arch; in others it is narrow and rises almost to a point like a Gothic arch, and materially impairs the tone of the voice. [The line of junction of the hard and soft palates is perceptible to the eye by a difference in color of the two surfaces, and also to the touch.]

[**Teeth.**—In young children the question of the impending eruption of any tooth should always be settled by inspection and touch. The secondary incisor teeth should be examined if any possibility of syphilis exist. Before giving any anæsthetic artificial teeth should invariably be removed.]

Throat.—To examine the throat well, the nose should be held so as to compel breathing through the mouth. Thus the soft palate will be raised, the palatine arches widened, and the tonsils and the back of the pharynx fairly exposed. Pressing the tongue downward, provided it be done very gently, is also of advantage. Rude treatment the tongue at once resists. The forefinger can be passed into the throat, beyond the epiglottis, as low as the bottom of the cricoid cartilage, and thus search the pharynx down to the top of the œsophagus and the hyoid space (on each side), where foreign bodies are so apt to lodge. [A forefinger of ordinary length can scarcely reach beyond the epiglottis.] The greater cornu of the hyoid bone can be felt as a distinct projection on either side. In introducing a tube into the œsophagus the finger should keep the instrument well against the back of the pharynx, so as to prevent its slipping into the larynx.

Pass the finger between the teeth and the cheek and feel the anterior border of the coronoid process of the jaw. On the inner side of this process, between it and the tuberosity of the upper jaw, is a recess where a deeply-seated temporal abscess might burst or might be opened. Behind the last molar on the inner side of the upper jaw we can distinctly feel the hamular process of the sphenoid bone; also the lower part of the pterygoid fossa and the internal pterygoid plate. Behind and on the outer side of the last molar can be felt part of the back of the antrum and of the lower part of the external pterygoid plate.

On the roof of the mouth we can feel the pulsation of the posterior palatine artery. Hemorrhage from this vessel can be arrested by plugging the orifice of the canal, which lies (not far from the surface) on the inner side of the last molar, about one-third of an inch in front of the hamular process.

When the mouth is wide open the pterygo-maxillary ligament forms a prominent fold readily seen and felt beneath the mucous membrane behind the last molar teeth. A little below the attachment of this ligament to the lower jaw we can easily feel the gustatory nerve, as it runs close to the bone below the last molar tooth. The exact position of the nerve can be ascertained in one's own person by the acute pain on pressure. A division of the nerve, easily effected by a small incision, gives much temporary relief in cases of advanced carcinoma of the tongue.

To feed a patient in spasmodic closure of the jaw it is well to know that there is behind the last molar teeth a space sufficient for the passage of a small tube into the mouth.

Antrum.—Lift up the upper lip and examine the front wall of the antrum. The proper place in which to tap it is above the second bicuspid tooth, about one inch above the margin of the gum. [Percussion of the antrum will often give valuable information.]

20. **Posterior Nares.**—A surgeon's finger should be familiar with the feel of the posterior nares and of all that is within reach behind the soft palate. This is important in relation to the attachment of polypi, to plugging the nostrils, and to the proper size of the plug. In the examination of this part of the back of the throat it is necessary to throw the head well back, because in this position nearly all the pharynx in front of the basilar process comes down below the level of the hard palate, and can be seen as well as felt. But when the skull is horizontal—*i. e.* at a right angle with the spine—the hard palate is on a level with the margin of the foramen magnum, and the parts covering the basilar process are concealed from view.

The head then being well back, introduce the forefinger behind the soft palate and turn it up toward the base of the skull. You feel the strong grip of the superior constrictor. Hooking the finger well forward, you can feel the contour of the posterior nares. Their size depends upon the anterior, but rarely exceeds a small inch in the vertical diameter and a small half-inch in the transverse. The plug for the posterior nares should not be larger than this. Their plane is not perpendicular, but slopes a little forward. You can feel the septum formed by the vomer, and also the posterior end of the inferior spongy bone in each nostril.

21. **Tonsils.**—Before taking leave of the throat look well at the position of the tonsils between the anterior and posterior half-arches of the palate. In a healthy state they should not project beyond the level of these arches. In all operations upon the tonsils we should remember the close proximity of the external carotid artery to their outer side. Nothing intervenes but the pharyngeal aponeurosis and the superior constrictor of the pharynx. Hence the rule in operating on the tonsils, always to keep the point of the knife inward.

In troublesome hemorrhage from the tonsils after an incision or removal, it is well to know that they are accessible to pressure, if necessary, by means of a padded stick or even a finger.

22. **Features.**—A word or two on the lines of the face as indicative of expression. Every one pays unconscious homage to the study of physiognomy when, scanning the features of a stranger, he draws conclusions concerning his intelligence, disposition, and character. Without discussing how much physiognomy is really worth, there can be no doubt that it is a mistake to place it in the same category as phrenology, since the latter lacks that sound base of physiology which no one can deny to the former.

A person fond of observing cannot fail to have arrived at the conclusion that a man's daily calling moulds his features. Place a soldier, a sailor, a compositor, and a clergyman side by side, and who will not immediately detect a marked difference in their physiognomies?

The muscles of the features are generally described as arising from the bony fabric of the face, and as inserted into the nose, the corners of the mouth, and the lips. But this description gives a very inadequate idea of their true insertion. They drop fibres into the skin all along their course, so that there is hardly a point of the face which has not its little fibre to move it. The habitual recurrence of good or evil thoughts, the indulgence in particular modes of life, call into play corresponding sets of muscles, which, by producing folds and wrinkles, give a permanent cast to the features and speak a language which all can understand, and which rarely misleads. Schiller puts this well when he says that "it is an admirable proof of Infinite Wisdom that what is noble and benevolent beautifies the human countenance; what is base and hateful imprints upon it a revolting expression."

THE NECK.

[**Skin.**—In no part of the body can the differing thickness of the skin be more readily perceived than by pinching up a fold at the front, side, and back of the neck.]

23. **Subcutaneous Veins.**—Notice first the direction of the subcutaneous veins. The chief subcutaneous vein is the external jugular. Its course corresponds with a line drawn from the angle of the jaw to the middle of the clavicle, where it joins the subclavian. It is made more prominent by putting the Sterno-mastoid into action or by gentle pressure on the lower end of the vein. It is exceptionally joined by a branch which runs over the clavicle and is termed "jugulo-cephalic." The anterior jugular generally runs along the front border of the Sterno-mastoid. [The condition of these veins should be examined in all diseases causing respiratory disturbance, especially dyspnœa. In case of tricuspid regurgitation there will be a venous pulse seen. The stethoscope may also reveal a venous hum or musical note over these veins in anæmia.]

24. **Parts in Central Line: Os Hyoides.**—Immediately below and nearly on a level with the lower jaw we feel the body of the os hyoides, and can trace backward on each side the whole length of the cornua. They might easily be broken by the grasp of a garrotter. Below the body of the os hyoides is the gap above the thyroid cartilage. This gap corresponds with the anterior thyro-hyoid ligament and the apex of the epiglottis; so that in cases of cut-throat in this situation nearly the whole of the epiglottis lies above the wound.

Thyroid Cartilage.—The projection and depth of the notch in the thyroid cartilage, or "pomum Adami," varies in different persons. Between the notch and the hyoid bone there is a large bursa, which facilitates the play of the cartilage beneath the bone in deglutition. The notch does not appear till puberty, and is throughout life much less distinct in the female than the male. The finger can trace the upper borders and cornua of the thyroid cartilage: its lower cornua can be felt by the side of the cricoid.

On each side of the thyroid cartilage we can recognize the lateral lobes of the thyroid gland. On the upper and front part of the gland we can distinctly feel the pulsation of the superior thyroid artery. This pulsation, coupled with the fact that the gland rises and falls with the larynx in deglutition, gives the best means of distinguishing a bronchocele from other tumors resembling it.

Below the angle of the thyroid cartilage we feel the interval between it and the cricoid, which is occupied by the crico-thyroid membrane. In laryngotomy we cut through this membrane transversely close to the upper edge of the cricoid cartilage, in order that the incision may be as far as possible from the attachment of the vocal chords.

25. **Cricoid Cartilage.**—The projection of the cricoid cartilage is a point of great interest to the surgeon, because it is his chief guide in opening the air-passages, and can always be felt even in infants, however young or fat. It corresponds to the interval between the fifth and sixth cervical vertebræ. The commencement of the œsophagus lies behind it: here, therefore, a foreign substance too large to be swallowed would probably lodge, and might be felt externally.

Again, a transverse line drawn from the cricoid cartilage horizontally across the neck would pass over the spot where the omo-hyoid crosses the common carotid. Just above this spot is the most convenient place for tying the artery.

26. Those who have not directed their attention to the subject are hardly aware what a little distance there is between the cricoid cartilage and the upper part of the sternum. In a person of the average height, sitting with the neck in an easy position, the distance is barely one inch and a half. When the neck is well stretched about three-quarters of an inch more is gained. Thus we have (generally) not more than seven or eight rings of the trachea above the sternum. None of these rings can be felt externally. The second, third, and fourth are covered by the isthmus of the thyroid gland. The trachea, it should be remembered, recedes from the surface more and more as it descends, so that just above the sternum in a short, fat-necked adult the front of the trachea would be quite one inch and a half from the skin.

27. **Trachea.**—In the dead subject nothing is more easy than to open the trachea: in the living this operation may be attended with the greatest difficulties. In urgent dyspnœa you must expect to find the patient with his head bent forward and the chin dropped, so as to relax as much as possible the parts. On raising his head a paroxysm of dyspnœa is almost sure to come on, threatening instant suffocation. The Elevator and Depressor muscles draw the trachea and larynx up and down with a rapidity and a force which may bring the cricoid cartilage within half an inch of the sternum. The great thyroid veins which descend in front of the trachea are sure to be distended.

There may be a middle thyroid artery. In children the lobes of the thymus may extend up in front of the trachea, and the left vena innominata may cross it unusually high. Thus the air-tube may be covered by important parts which ought not to be cut. Considering all these possible complications, the least difficult and the best mode of proceeding is to open the trachea just below the cricoid cartilage, and, if more room be requisite, to pull down the isthmus of the thyroid gland, or in children to divide the cricoid itself. It is important that all the incisions be made strictly in the middle line, the "line of safety."

28. **Sterno-mastoid Muscle.**—The Sterno-mastoid muscle is the great surgical landmark of the neck. It stands out in bold relief when the head is turned toward the opposite shoulder [and the attempt to do so is resisted]. Its inner border overlaps the common carotid, which can be easily compressed for a short time against the spine about the level of the cricoid cartilage. The artery extends (generally) as high as the upper border of the thyroid cartilage, and corresponds with a line drawn from the sterno-clavicular joint to midway between the angle of the jaw and the mastoid process.

Between the sternal origins of the Sterno-mastoid is the fossa above the sternum, more or less perceptible in different necks. As it heaves and sinks alternately, especially in distressed breathing, it was called by the old anatomists "fonticulus gutturis." In beautiful necks, as seen in the "Venus," it is filled up by fat.

Notice the interval between the sternal and clavicular origins of the Sterno-mastoid. A knife introduced a very little way into this interval would wound, slanting inward, the common carotid—slanting outward, the internal jugular vein. These facts are of importance in performing the subcutaneous section of the tendon of this muscle.

29. **Sterno-clavicular Joint.**—Many important parts lie behind the sterno-clavicular joint. There is the commencement of the vena innominata; behind this comes the common carotid on the left side, and the division of the arteria innominata on the right. Deeper still, the apex of the lung rises into the neck.

In a child the arteria innominata often lies in front of the trachea and divides a little higher than the joint—a point to be remembered in tracheotomy (27).

30. **Apex of the Lung in the Neck.**—The extent to which the apex of the lung rises into the neck is greater than is generally supposed. Many observations in reference to this point lead to the conclusion that the lung rises behind the Sterno-mastoid, on an average, one inch and a half above the clavicle; in persons with long necks as much as two inches. The apex of the lung and pleura is covered by the clavicular origin of the Sterno-mastoid, the Sterno-thyroid, and a part of the Scalenus anticus. It is also crossed by the subclavian vessels in the first part of their course. As this cervical portion of lung is peculiarly liable to tubercular disease, it should always be carefully examined. Its condition may be ascertained by percussion near the sternal end of the clavicle.

31. **Supraclavicular Fossa.**—The hollow above the clavicle, between the Sterno-mastoid and the Trapezius, is very manifest in emaciation and old age. [Shrugging the shoulders makes it exceedingly pronounced.] Notice the termination here of the external jugular vein. In some necks only a small depression is visible, particularly when the Trapezius has a broad insertion into the clavicle and comes well forward, so that its front border gives a graceful contour to the base of the neck.

32. **Subclavian Artery.**—In the supraclavicular fossa, near the outer border of the Sterno-mastoid and about one inch above the clavicle, we feel the pulsation of the subclavian artery. Here the artery lies upon the first rib, and can be effectually compressed. A little pressure is sufficient. But the pressure must be made in the right direction, or the artery will be pressed off the rib instead of against it. The plane of the rib is such that the pressure, to be effectual, must be made in a direction downward and a little inward. It is best to stand behind the shoulder and make the pressure with one thumb.

It is worth remembering that the outer border of the Sterno-mastoid corresponds pretty nearly with the outer edge of the Scalenus anticus, which is the surgical guide to the subclavian artery.

[**Phrenic Nerve.**—As the phrenic nerve passes over the Scalenus anticus, it can now be readily located. If it is to be galvanized, one pole of the battery should be placed in this fossa and the other over the Diaphragm.]

By pressing deeply at the upper part of the supraclavicular fossa, the transverse process of the seventh cervical vertebra can be distinctly felt.

In long and thin necks a thin cord is perceptible running nearly parallel with and just above the clavicle. It is the posterior belly of the Omo-hyoideus. See it rising and falling in breathing, and making tense during inspiration that part of the cervical fascia which lies over the cervical portion of the lung. Thus it may be said to be in all respects a muscle of inspiration, co-operating with the Sterno-mastoid and Scaleni. In the language of transcendental anatomy, we may say that the central tendon of the Omo-hyoid represents a rudimentary cervical rib. Its posterior belly is analogous to a serration of the Serratus magnus, its anterior belly to a Sterno-hyoid.

THE CHEST.

33. As a rule, the right half of the chest is slightly larger than the left. Of 92 persons of the male sex and good constitutions, 72 had the right side the larger, 11 the left; 10 had both sides equal. The maximum of difference in favor of the right was one inch and a quarter. The measurements were made on a plane with the nipple.

34. **Peculiarities in the Female.**—The chest of the female differs from that of the male in the following points: Its general capacity is less; the sternum is shorter, the upper opening is larger in proportion to the lower; the upper ribs are more movable, and therefore permit a greater enlargement of the chest at its upper part in adaptation to the requirements of pregnancy.

35. The top of the sternum is on a level with the second dorsal vertebra, and the available space between the top of the sternum and the spine is hardly more than two inches.[1]

36. **Parts behind First Bone of Sternum.**—There is little or no lung behind the first bone of the sternum, the space being occupied by the trachea and large vessels, as follows:

The left vena innominata crosses the sternum just below the upper border. Next come the great primary branches of the arch of the aorta. Deeper still is the trachea dividing into its two bronchi opposite the junction of the first and second bones of the sternum. Deepest of all is the œsophagus.

About one inch from the upper border of the sternum is the highest part of the aorta, which lies on the bifurcation of the trachea.

37. The course of the arteria innominata corresponds with a line drawn from the middle of the junction of the first with the second bone of the sternum to the right sterno-clavicular joint. When the artery rises higher than usual into the neck its pulsation can be felt in the fossa above the sternum.

38. **Rules for Counting the Ribs.**—In fat persons it is often difficult to count the ribs; hence the following rules may be useful:

a. The finger passed down from the top of the sternum soon comes to a transverse projection, slight but always to be felt [and generally seen], at the junction of the first with the second bone of the sternum. This corresponds with the level of the cartilage of the second rib.

b. The nipple of the male is placed, in the great majority of cases, between the fourth and the fifth ribs, about three-quarters of an inch external to their cartilages.

c. The lower external border of the Pectoralis major corresponds with the direction of the fifth rib.

d. A line drawn horizontally from the nipple round the chest cuts the sixth intercostal space midway between the sternum and the spine. This is a useful rule in tapping the chest.

e. When the arm is raised the highest visible digitation of the Serratus magnus corresponds with the sixth rib. The digitations below this correspond respectively with the seventh and eighth ribs.

f. The scapula lies on the ribs from the second to the seventh, inclusive.

g. The eleventh and twelfth ribs can be felt even in corpulent persons outside the Erector spinæ, sloping downward.

h. One should remember the fact that the sternal end of each rib lies on a lower level than its corresponding vertebra. For instance, a line drawn horizontally backward from the middle of the third costal cartilage at its junction with the sternum to the spine would touch the body, not of the third dorsal vertebra, but of the sixth. Again, the end of the sternum would be on about the level of the tenth dorsal vertebra. Much latitude must be allowed here for variation in the length of the sternum, especially in women.

---

[1] In several adult normal skeletons measured in the Hunterian Museum the average diameters of the upper opening of the chest were—antero-posterior, about 2¼ inches; transverse, about 4½ inches. In the skeleton of O'Brien, the Irish giant, the antero-posterior diameter measures 4 inches, the transverse 6¼.

39. **Interval below Clavicle.**—Immediately below the clavicle we recognize the triangular interval between the Pectoralis major and the Deltoid. This space varies in different cases, depending on the distance between the muscles. It is important as a guide to the coracoid process and the axillary artery. In a case of injury to the shoulder, to ascertain whether the coracoid process is broken, carry the arm outward to put the Deltoid and Pectoral muscles on the stretch and make manifest the space between their opposite borders. Pressing the thumb into the space, we can feel the inner side of the coracoid process, the apex being under the fibres of the Deltoid; thus it is easy to ascertain whether it be broken. Moreover, this space corresponds with the line of the axillary artery; here its pulsation can be distinctly felt, and here it can be compressed (but not easily or for long) against the second rib.

40. **Internal Mammary Artery.**—The line of the internal mammary artery runs perpendicularly behind the cartilages of the ribs, about half an inch from the sternum. The perforating branch through the second intercostal space is generally the largest.

41. **Outline of Heart on Chest-wall.**—To have a general idea of the form and position of the heart map its outline on the wall of the chest [by an aniline pencil], as follows:

a. To define the base draw a transverse line across the sternum corresponding with the upper borders of the third costal cartilages: continue the line half an inch to the right of the sternum and one inch to the left.

b. To find the apex mark a point about two inches below the left nipple and one inch to its sternal side. This point will be between the fifth and sixth ribs [and can generally be determined by feeling the apex beat].

c. To find the lower border (which lies on the central tendon of the Diaphragm) draw a line, slightly curved downward, from the apex across the bottom of the sternum (not the ensiform cartilage) as far as its right edge.

FIG. 683.

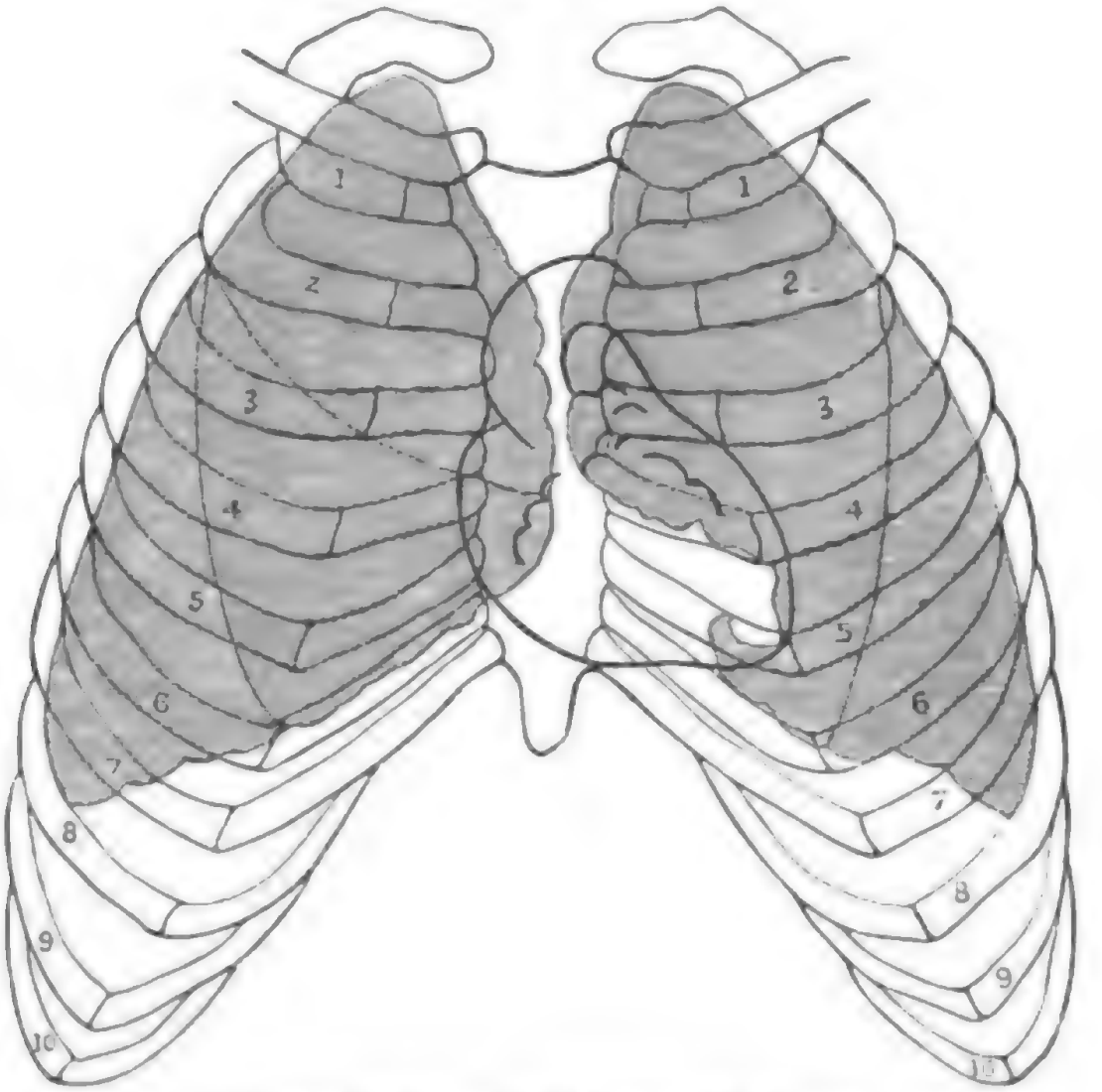

Outline of the Heart, its Valves, and the Lungs.

d. To define the right border (formed by the right auricle) continue the last line upward with an outward curve, so as to join the right end of the base.

e. To define the left border (formed by the left ventricle) draw a line curving to the left, but not including the nipple, from the left end of the base to the apex.

Such an outline (seen in the cut above with angles rounded off) shows that the apex of the heart points downward and toward the left, the base a little upward and toward the right; that the greater part of it lies in the left half of the chest; and that the only part which lies to the right of the sternum is the right auricle. A needle introduced in the third, the fourth, or the fifth right intercostal space close to the sternum would penetrate the lung and the right auricle.

A needle passed through the second intercostal space close to the right side of the sternum would, after passing through the lung, enter the pericardium and the most prominent part of the bulge of the aorta.

A needle passed through the first intercostal space close to the right side of the sternum would pass through the lung and enter the superior vena cava above the pericardium.

42. The best definition of that part of the præcordial region which is less resonant on percussion was given by Dr. Latham years ago in his *Clinical Lectures:* "Make a circle of two inches in diameter round a point midway between the nipple and the end of the sternum. This circle will define sufficiently for all practical purposes that part of the heart which lies immediately behind the wall of the chest and is not covered by lung or pleura."

Apex of the Heart.—The apex of the heart pulsates between the fifth and sixth ribs, two inches below the nipple and one inch to its sternal side. The place and extent, however, of the heart's impulse vary a little with the position of the body. Of this any one may convince himself by leaning forward, backward, on this side, and on that, feeling at the same time the heart. Inspiration and expiration also alter the position of the heart. In a deep inspiration it may descend half an inch and can be felt beating at the pit of the stomach.

43. **Valves of the Heart.**—The aortic valves lie behind the third intercostal space, close to the left side of the sternum.

The pulmonary valves lie in front of the aortic, behind the junction of the third costal cartilage on the left side with the sternum.

The tricuspid valves lie behind the middle of the sternum, about the level of the fourth costal cartilage.

The mitral valves (the deepest of all) lie behind the third intercostal space, about one inch to the left of the sternum.

Thus these valves are so situated that the mouth of an ordinary-sized stethoscope will cover a portion of them all, if placed over the sternal end of the third intercostal space on the left side. All are covered by a thin layer of lung; therefore we hear their action better when the breathing is for a moment suspended [in expiration].

[**Where to Auscult the Valves of the Heart.**—The valves being so close together, it is evident that to discriminate the sound of one from that of the others we must be able to auscult them separately; and accordingly we follow the diverging course of the blood-currents they transmit. Hence,

The aortic valve is best auscuited over the second intercostal space at the right border of the sternum; it can also be heard over the aorta in the back from the third to the ninth dorsal spines, especially if there be any murmur;

The pulmonary valve, over the second space at the left border of the sternum;

The tricuspid valve, over the middle of the sternum above the ensiform cartilage; and

The mitral valve, over the apex of the heart.]

44. **Outline of the Lungs.**—Now let us trace on the chest the outline of the lungs with as much precision as their expansion and contraction in breathing permit. (See Fig. 683.)

45. The apex of each lung rises into the neck behind the sternal end of the clavicle and Sterno-mastoid muscle as much as an inch and a half; in females rather higher than in males (30). From the sternal ends of the clavicles the lungs converge, so that their thin edges almost meet in the mesial line on a level with the second costal cartilage. Thus there is little or no lung behind the first bone of the sternum. From the level of the second costal cartilage to the level of the fourth the margins of the lungs run parallel or nearly so close behind the middle of the sternum; consequently their thin edges overlap the great vessels and valves at the base of the heart.

Below the level of the fourth costal cartilage the margins of the lungs diverge, but not in an equal degree. The margin of the right corresponds with the direction of the cartilage of the sixth rib: the margin of the left, being notched for the heart, runs behind the cartilage of the fourth. A line drawn perpendicularly from the nipple would find the lung margin about the lowest part of the sixth rib. Laterally—*i. e.* in the axillary line—the lung margin comes down as low as the eighth rib: posteriorly—*i. e.* in the dorsal or scapular line—it descends as low as the tenth.

It should be remembered that in a deep inspiration the lung margins descend about one inch and a half.

In children the lungs are separated in front by the thymus gland. Allowance should be made for this. About the approach of puberty the thymus disappears.

46. **Anterior Mediastinum.**—The direction of the anterior mediastinum is not straight down the middle of the sternum, but slants a little to the left, owing to the position of the heart. The right pleural sac generally encroaches a little upon the left, behind the middle of the sternum. A needle introduced through the middle of the sternum opposite the third or the fourth rib would go through the right pleura.

47. **Reflection of Pleura.**—The reflection of the pleura from the wall of the chest on to the Diaphragm corresponds with a sloping line drawn from the bottom of the sternum over the cartilages of the ribs down to the lower border of the last rib.

Since the pleura lines the inside of the last rib, a musket-ball or other foreign body loose in the pleural sac and rolling on the Diaphragm might fall to the lowest part of the sac, which would be between the eleventh and twelfth ribs. The ball might be extracted here. The chest might also be tapped here, but not with a trocar, since a trocar would penetrate both layers of pleura and go through the Diaphragm into the abdomen.

The operation should be done cautiously, by an incision beginning about two inches from the spine on the outer border of the Erector spinæ, on a level between the spines of the eleventh and twelfth dorsal vertebræ. The intercostal artery will not be injured if the opening be made below the middle of the space, which is very wide.[1]

THE BACK.

48. **Median Furrow.**—In a muscular man a furrow caused by the prominence of the Erector spinæ on each side runs down the middle of the back. The lower end of the furrow corresponds with the interval between the spine of the last lumbar and that of the first sacral vertebra. [It must be observed that in the skeleton and the body furrows and prominences, hills and hollows, are, as a general rule, reversed. Bony projections in the skeleton, as a rule, are for muscular origins. As at a little distance from the origin the muscular bellies swell out, such prominences lie at the bottom of depressions. But when long sickness wastes the soft parts the form of the skeleton reappears, and such bony prominences then become the favorite seats of bed-sores.]

49. **Spines of the Vertebræ.**—A little friction with the fingers down the backbone will cause the spines of the vertebræ to be tipped with red, so that they can be easily counted and any deviation from the straight line detected. Still, it is worth remembering that the spine of the third dorsal is on a level with the commencement of the spine of the scapula; that the spine of the seventh dorsal is on a level with the inferior angle of the scapula; that the spine of the last dorsal is on a level with the head of the last rib.

Division of the Trachea.—The division of the trachea is opposite the spine of the third, in some cases the fourth, dorsal vertebra. In front this division is on the level of the junction of the first with the second bone of the sternum.

The root of the spine of the scapula is marked by a slight dimple in the skin. This is on a level with the third intercostal space. A stethoscope placed on the inner side of the dimple would cover the bronchus, more especially the right, since it is nearer to the chest-wall.

Make a man lean forward, with his arms folded across the chest; this will make prominent the spines of the vertebræ. The lower border of the Trapezius will guide you to the spine of the twelfth dorsal vertebra.

---

[1] Special experiments upon this subject were made many years ago by the late Professor Quekett in the work-rooms of the College of Surgeons.

50. The place where the **Kidney** is most accessible to pressure is below the last rib on the outer edge of the Erector spinæ.

51. The highest part of the **Ilium** is about the level of the fourth lumbar spine. The best incision for opening the descending colon is in a slightly sloping line beginning at the outer edge of the Erector spinæ, midway between the crest of the ilium and the last rib, and continued across the flank for three inches or more, according to the amount of subcutaneous fat. [This ilio-costal space varies very much in its vertical measurement. I have seen it only a finger's breadth, and again a whole hand's breadth. The line of the colon passes through it vertically about half an inch behind the middle of the crest of the ilium (Heath).]

52. In the pit of the neck we can feel the Trapezius and the ligamentum nuchæ. By pressing deeply we detect the forked prominent spine of the second cervical vertebra.

53. The spines of the third, fourth, and fifth cervical vertebræ recede from the surface to permit free extension of the neck, and cannot often be felt. But the spines of the sixth and seventh (v. prominens) [and first dorsal] stand out well.

54. Notice that most of the spines of the dorsal vertebræ, owing to their obliquity, do not tally with the heads of their corresponding ribs. Thus, the spine of the second dorsal corresponds with the head of the third rib, the spine of the third dorsal with the head of the fourth rib, and so on till we come to the eleventh and twelfth dorsal vertebræ, which do tally with their corresponding ribs. All this, however, is best seen in the skeleton.

55. The spines of the vertebræ may be useful as landmarks indicative of the levels of important organs. I have therefore arranged them in a tabular form, thus:

Tabular Plan of Parts opposite the Spines of the Vertebræ.

CERVICAL.	5th.	Cricoid cartilage. Œsophagus begins.
	7th.	Apex of lung: higher in the female than in the male (30).
DORSAL.	1st.	
	2d.	
	3d.	Aorta reaches spine. Apex of lower lobe of lung. Angle of bifurcation of trachea (49).
	4th.	Aortic arch ends. Upper level of heart.
	5th.	
	6th.	
	7th.	
	8th.	Lower level of heart. Central tendon of Diaphragm.
	9th.	Œsophagus and vena cava through Diaphragm. Upper edge of spleen.
	10th.	Lower edge of lung. Liver comes to surface posteriorly. Cardiac orifice of stomach.
	11th.	Lower border of spleen. Renal capsule.
	12th.	Lowest part of pleura. Aorta through Diaphragm. Pylorus.
LUMBAR.	1st.	Renal arteries. Pelvis of kidney (83).
	2d.	Termination of spinal cord. Pancreas. Duodenum just below. Receptaculum chyli.
	3d.	Umbilicus. Lower border of kidney.
	4th.	Division of aorta (65). Highest part of ilium.
	5th.	

56. **Origins of the Spinal Nerves.**—It is useful to know opposite what vertebræ the spinal nerves in the different regions arise from the spinal cord. They arise as follows:

The origins of the eight cervical nerves correspond to the interval between the occiput and the sixth cervical spine.

The origins of the first six dorsal nerves correspond to the interval between the sixth cervical and the fourth dorsal spines.

The origins of the six lower dorsal nerves correspond to the interval between the fourth and the eleventh dorsal spines.

The origins of the five lumbar nerves correspond to the interval between the eleventh and twelfth dorsal spines.

The origins of the five sacral nerves correspond to the spines of the last dorsal and the first lumbar vertebræ.

[Fig. 684.

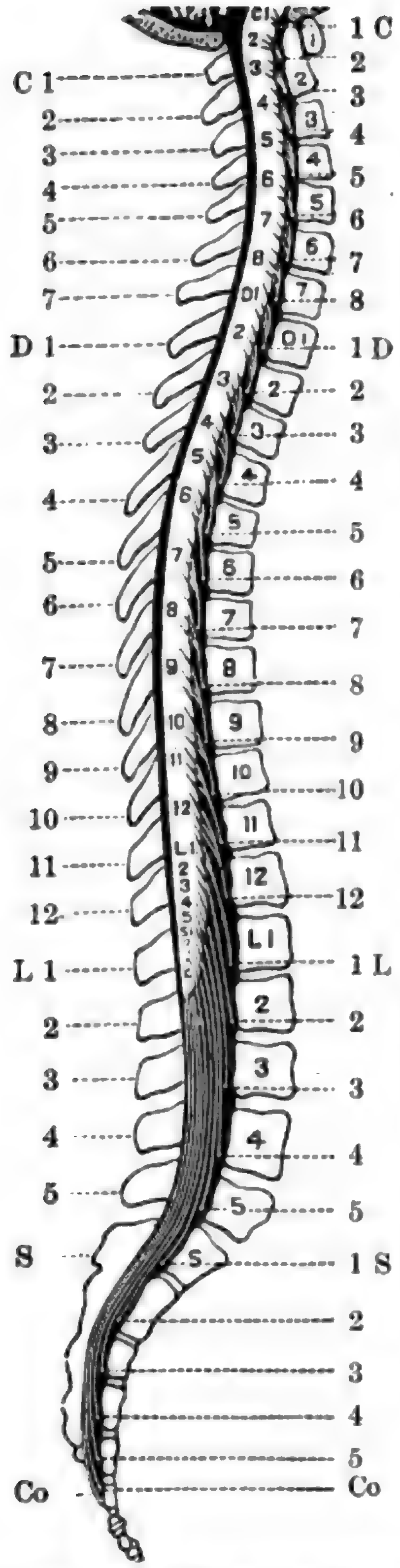

MOTOR.	SENSORY.	REFLEX.
St. Mastoid. Trapezius.	Neck and Scalp.	
Diaphragm.	Neck and Shoulder.	
Serratus. Shoulder. mus. Arm. mus. Hand. mus. (ulnar lowest.)	Shoulder. Arm. Hand.	Scapular.
Intercostal muscles.	Front of Thorax. Ensiform area.	Epigastric.
Abdominal muscles.	Abdomen (Umbilicus 10th). Buttock, upper part.	Abdominal.
Flexors, hip.	Groin and Scrotum (front).	Cremasteric.
Extensors, knee.	Thigh outer side. Thigh front. Thigh inner side.	*Knee-jerk.*
Adductors. hip. Abductors. hip. Extensors (?) hip.	Leg, inner side.	Gluteal.
Flexors, knee (?) Muscles of leg moving foot.	Buttock, lower part. Back of Thigh. Leg and Foot except inner part.	*Foot-clonus.* Plantar.
Perineal and Anal muscles.	Perineum and Anus.	
	Skin from Coccyx to Anus.	

Diagram and Table showing the Approximate Relation to the Spinal Nerves of the Various Motor, Sensory, and Reflex Functions of the Spinal Cord (*from anatomical and pathological data*). (From Gowers.)

57. Movements of the Spine.—The movements of which the spine is capable are threefold: 1, flexion and extension; 2, lateral inclination; 3, torsion. Flexion and extension are freest between the third and sixth cervical vertebræ, between the eleventh dorsal and the second lumbar, and between the last lumbar and the sacrum. This is well marked in severe cases of opisthotonos, where the body is supported on the back of the head and heels.[1]

Still better may it be observed when a mountebank bends backward and touches the ground with his head.

The lateral movement is freest in the neck and the loins.

The movement of torsion or rotation round its own axis may be proved by the following experiment: Seated upright, with the back and shoulders well applied against the back of a chair, we can turn the head and neck as far as 70°. Leaning forward, so as to let the dorsal and lumbar vertebræ come into play, we can turn 30° more.

---

[1] See a beautiful illustration of this in Sir C. Bell's *Anatomy of Expression*, p. 160.

[The atlo-axoid movement amounts to 25° to each side, the remaining cervical vertebræ give 45° more, making 70° in the neck; the dorso-lumbar movement is about 30°, to which the hips add from 65° to 80°, or a total rotation of 165° to 180°. For purposes of observation we gain, in addition to this, about 70° more for the eyeball, so that, posteriorly as well as anteriorly, the field of vision right and left overlaps very largely.]

FIG. 685.

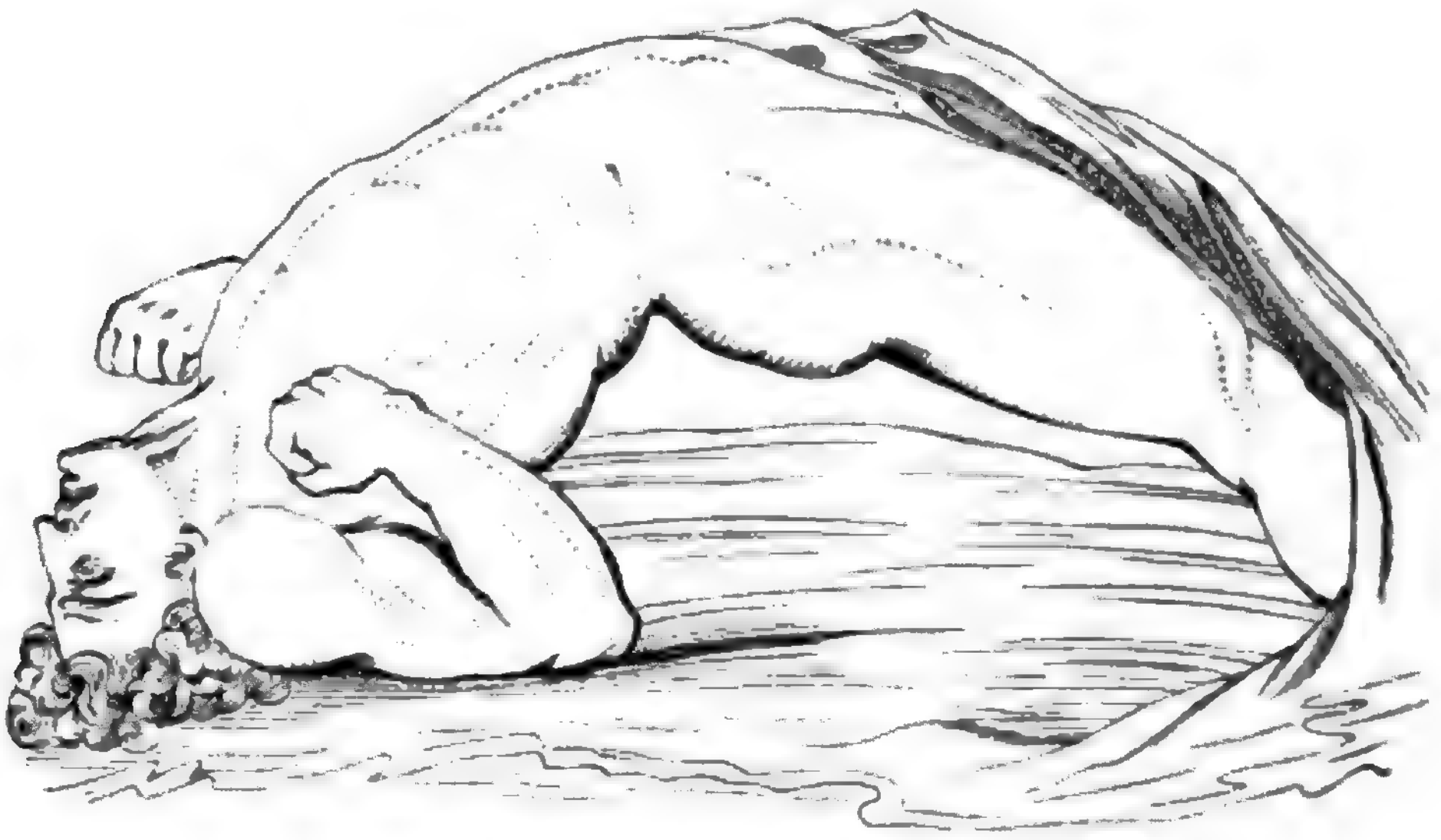

Opisthotonos (after Bell).

58. **Position and Motions of Scapula.**—There are a few points worthy of observation about the scapula. It covers the ribs from the second to the seventh inclusive. We can feel its superior angle covered by the trapezius. The inferior angle is covered by the Latissimus dorsi, which keeps it well applied against the ribs in the strong and athletic; but in weak and consumptive persons the lower angles of the scapulæ project like wings—hence the term "scapulæ alatæ."

A line drawn horizontally from the spine of the sixth dorsal vertebra over the inferior angle of the scapula gives the upper border of the Latissimus dorsi. Another line drawn from the root of the spine of the scapula to the spine of the last dorsal vertebra gives the lower border of the Trapezius, which stands a little in relief.

59. The sliding movement of the scapula on the chest can be properly understood only on the living subject. It can move not only upward and downward, as in shrugging the shoulders—backward and forward, as in throwing back the shoulders—but it has a rotatory movement round a movable centre. This rotation is seen while the arm is being raised from the horizontal to the vertical position, and is effected by the co-operation of the Trapezius with the Serratus magnus. The glenoid cavity is thus made to look upward, the inferior angle slides forward, and is well held under the Latissimus dorsi.

60. For the medical examination of the back the patient should sit with the arms hanging between his thighs, to lower the scapulæ as much as possible. In this position the spine of the scapula corresponds (nearly) with the fissure between the upper and lower lobes of the lung, the apex of the lower lobe being about the level of the third rib.

[Usually I prefer to have the arms folded across the chest—obviously the better position for women—and it uncovers the back rather better.

The remarkable mobility of the scapula is best seen by contrasting this position with the place of the scapula when the shoulders are thrown well back. In this last position the lower angles of the scapulæ will be two or three inches apart, while in the former this interval measures from twelve to sixteen inches. Moreover, so soon as the arm is lifted from the trunk at an angle of 30° or 40°, and long before it reaches the horizontal line, the scapula begins to move. This mobility of the scapula explains readily the great range of movement, and therefore the usefulness of the arm, in cases of ankylosis of the shoulder-joint.]

THE ABDOMEN.

The student is assumed to be familiar with the conventional lines dividing the abdomen into regions.

61. **Abdominal Lines.**—The linea alba, or central line of the abdomen, marks the union of the aponeuroses of the abdominal muscles. It runs from the apex of the ensiform cartilage to the symphysis pubis. As this line is the thinnest and least vascular part of the abdominal wall, we make our incision along it in ovariotomy [Cæsarean section, and most other operations on the abdominal and pelvic viscera] and in the high operation of lithotomy; in it we tap the abdomen in ascites and the distended bladder in retention of urine.

The so-called "linea semilunaris," at the outer border of the sheath of the rectus, corresponds with a line drawn slightly curved (with the concavity toward the linea alba) from the lowest part of the seventh rib to the spine of the pubes. This line would be in an adult about three inches from the umbilicus, but in an abdomen distended by dropsy or other cause the distance is increased in proportion. [These lines of adhesion in the abdominal wall limit extravasations, emphysema, etc. between their layers.]

It is important to know the position of the lineæ transversæ, or tendinous intersections across the rectus abdominis. There are rarely any below the umbilicus, and generally three above it. The first is about the level of the umbilicus. The second is about four inches higher; that is, about the level of the lowest part of the tenth rib. These are the principal lines, and they divide the upper part of each rectus into two nearly quadrilateral portions, an upper and a lower; of these, those on the right side are a trifle larger than on the left. We see these muscular squares pretty plainly in some athletic subjects. Much more frequently we see them, too much exaggerated, on canvas and in marble. Artists are apt to exaggerate them and make the front of the belly too much like a chess-board. It is lucky for them that all the world does not see with anatomical eyes.

A familiarity with the shape and position of these divisions of the rectus is of importance, lest we should, in ignorance, make a mistake in our diagnosis. A spasmodic contraction of one of these divisions, particularly the upper, or a collection of matter within its sheath, has been frequently mistaken for deep-seated abdominal disease.

In the erect position the anterior superior spines of the ilia are a little below the level of the promontory of the sacrum. The bifurcation of the aorta is on about the level of the highest part of the crest of the ilium.

62. **Umbilicus.**—The umbilicus is not midway between the ensiform cartilage and the pubes, but rather nearer to the pubes. In all cases it is situated above the centre of a man's height. It is a vulgar error to say that when a man lies with legs and arms outstretched and a circle is drawn round him, the umbilicus lies in the centre of it. This central point is in most persons just above the pubes.

[From the vertex to the umbilicus, the whole height being taken as the unit of measurement, is .550 at birth—*i. e.* the mid-point is above the navel. At two years it is at the navel, and gradually falls as the legs grow longer, until at thirty the mid-point is just below the pubes in men (half an inch) and just above it in women. Moreover, while at three to five years of age the whole height is equal to the distance between the outstretched finger-tips, before that age it is somewhat greater, and in adult life is much less.]

In very corpulent persons two deep transverse furrows run across the abdomen. One runs across the navel and completely conceals it. The other is lower down, just above the fat of the pubes. In tapping the bladder above the pubes in such a case the trocar should be introduced where this line intersects the linea alba.

Although the position of the umbilicus varies a little in different persons as the abdomen is unusually protuberant or the reverse, still, as a general rule, it is placed about the level of the body of the third lumbar vertebra. Now, since the aorta divides a little below the middle of the fourth lumbar, it follows that the best place to apply pressure on this great vessel is one inch below the umbilicus and slightly to the left of it (65). That the aorta can, under favorable circumstances, be compressed under chloroform sufficiently to cure an aneurism below it is proved by recorded cases, and by none more effectually than by a case related in the second volume of the *Reports of St. Bartholomew's Hospital.* It may be asked, Why not apply pressure on the aorta above the umbilicus? The answer is, that the aorta above the umbilicus is farther from the surface, and is, moreover, covered by important structures upon which pressure would be dangerous.

[The umbilicus is a point of fusion of all the tissues of the abdominal wall. Hence, it becomes a most valuable guide as to the depth of our position when cutting through the abdominal wall to attack tumors, etc. in the abdominal cavity. Attempt to sweep the finger under the umbilicus: if through the abdominal wall and upon the tumor, the finger will meet with no obstacle other than adhesions, which can be destroyed; if, on the contrary, still in the thickness of the abdominal wall (and it is not always easy to distinguish this in any other way), the finger will be absolutely arrested at the navel, and no force will carry it farther.

The umbilicus being the remains of an opening into the belly, when stretched by ascites, as the fluid can insinuate itself everywhere, it usually bulges out considerably; but in tumors this cannot be the case.

Again, it affords passage to the contents of the belly not uncommonly, and so we have umbilical herniæ; and sometimes ovarian fluids, pus in peritonitis, and entozoa escape here.

It is also an important point for measurements, sometimes used in fractures and dislocations of the hip and femur and in fractures of the anterior superior spines, and always in measuring the size of tumors from it to the ensiform, the pubes, and the two iliac spines.

The umbilicus is always much deeper and wider in women than in men.]

63. **Parts behind the Linea Alba.**—Let us next consider what viscera lie immediately behind the linea alba. For two or three fingers' breadth below the ensiform cartilage there is the left lobe of the liver, which here crosses the middle line. Below the edge of the liver comes the stomach, more or less in contact with the linea alba according to its degree of distension. In extreme distension the stomach pushes everything out of the way, and occupies all the room between the liver and the umbilicus. When empty and contracted it retreats behind the liver and lies flat in front of the pancreas at the back of the abdomen, thus giving rise to the hollow termed the "pit of the stomach." But as the stomach distends it makes a considerable fulness where there was a pit. The middle of the transverse colon lies above the umbilicus, occupying space (vertically two or three inches) according to its distension. Behind and below the umbilicus, supposing the bladder contracted, are the small intestines, covered by the great omentum.

64. **Peritoneum.**—The peritoneum is in contact with the linea alba all the way down to the pubes when the bladder is empty. But when the bladder distends it raises the peritoneum from the middle line above the pubes, so that with a bladder distended halfway up to the umbilicus there is a space of nearly two inches above the symphysis where the bladder may be tapped without risk of injury to the peritoneum. For the same reason we have space sufficient for the successful performance of the high operation for stone. This fact in anatomy must have been well understood by Jean de Dot, the smith at Amsterdam, who in the seventeenth century cut himself in the linea alba above the pubes and took out of his bladder a stone as large as a hen's egg. The stone, the knife, and the portrait of the operator may be seen to this day in the museum at Leyden.

65. **Division of the Aorta.**—The aorta generally divides at a point one inch and a half below the umbilicus. A more reliable guide to this division than the umbilicus is a point (a very little to the left) of the middle line about the level of the highest part of the crest of the ilium. A line drawn with a slight curve outward from this point to the groin, where the pulsation of the common femoral can be distinctly felt (rather nearer to the pubes than the ilium), gives the direction of the common iliac and external iliac arteries. About the first two inches of this line belong to the common iliac, the remainder to the external. Slight pressure readily detects the pulsation of the external iliac above Poupart's ligament.

As a rule, the length of the common iliac is about two inches, but it should be remembered there are frequent deviations. It may be between three-quarters of an inch and three inches and a half long. These varieties may arise either from a high division of the aorta or a low division of the common iliac, or both. It is impossible to ascertain during life what is its length in a given instance, for there is no necessary relation between its length and the height of the stature. It is often short in tall men, and *vice versâ*. Anatomists generally describe the right as a trifle longer than the left, but their average length is pretty nearly the same.

66. Mr. Abernethy, who in the year 1796 first put a ligature round the external iliac, made his incision in the line of the artery. But the easiest and safest way to reach the vessel is by an incision (recommended in the first instance by Sir Astley Cooper, and now generally adopted) beginning just on the inner side of the artery, a little above Poupart's

ligament, and continued upward and outward a little beyond the spine of the ilium. The same incision extended farther in the same direction would reach the common iliac.

67. **Bony Prominences.**—The anterior superior spine of the ilium, the spine of the pubes, and the line of Poupart's ligament are landmarks with which every surgeon should be thoroughly familiar.

68. **Spine of the Ilium.**—The spine of the ilium is the spot from which we measure the length of the lower extremity. It is a valuable landmark in determining the nature of injuries to the pelvis and the hip. The thumb easily feels the spine, even in fat persons. Its position with regard to the trochanter major should be carefully examined. The best way to do this is to place the thumbs firmly on the opposite spines and to grasp the trochanters with the fingers. Any abnormal position on one side is thus easily ascertained with the sound side as a guide.

[In all such measurements it is of the utmost importance that a line joining the two spines should be at right angles to the axis of the body, or the measurements cannot fail to be inaccurate. The spines also are so open to error as points of measurement (for we scarcely ever can get precisely corresponding points on the two sides) that I have long since adopted the following method: See that the body is straight and the pelvis (*i. e.* the line between the two spines) at right angles to it. Let an assistant hold the head immovably in the middle line. Let the patient seize the tape-line with his teeth. Measure one side, say to the inner malleolus. Then measure the other side—never by keeping the measure of the first side and simply passing across to the other leg, but by an independent measurement. The last precaution eliminates our preconceptions. The chief source of error here—which exists in all methods of measurement—is the position of the pelvis. The advantage is in one and the same starting-point, and that in the median line.

It must not be forgotten, however, that there is not infrequently a normal difference in the length of the two legs.]

69. **Spine of the Pubes.**—The spine of the pubes is the best guide to the external abdominal ring, which cannot easily be felt by placing the finger directly over it, since it is generally covered by fat. To feel it distinctly we should push up the skin of the scrotum and get beneath the subcutaneous fat. If there be any difficulty in finding it, abduct the thigh, and the tense tendon of the adductor longus will lead up to it.

The position of the spine of the pubes is appealed to as a means of diagnosis in doubt between inguinal and femoral hernia. The spine lies on the outer side of the neck of an inguinal hernia, on the inner side of the neck of a femoral.

The spine of the pubes is nearly on the same horizontal line as the upper part of the trochanter major. In this line about one full inch external to the spine is the femoral ring. Here is the seat of stricture in a femoral hernia.

70. **Poupart's Ligament, or Crural Arch.**—The line of Poupart's ligament (crural arch) is in most persons indicated by a slight crescent-like furrow along the skin. It corresponds with a line drawn, not straight, but with a gentle curve downward, from the spine of the ilium to the spine of the pubes. With the help of the preceding landmarks it is easy to find the exact position of the external and internal abdominal rings and the direction of the inguinal canal.

[In hernia it is always treacherous to trust the eye. We must define exactly the iliac and pubic spines by the fingers, and draw the line of Poupart's ligament between them by an aniline pencil. It lies at the uppermost border of the "groin," or groove between the abdomen and the thigh; and unless we so define its two ends we are very apt to get it, and especially the inner and most important end, too low, and so mistake the variety of hernia we have to deal with.

Moreover, an examination of the external abdominal ring will disclose its condition and show whether the hernia is or is not inguinal. Unfortunately, in women, in whom femoral hernia is most frequent, this examination is least satisfactory. The exact location of the line of Poupart's ligament is, therefore, in women doubly important.]

71. **Abdominal Rings.**—The external abdominal ring is situated immediately above the spine of the pubes. It is an oval opening with the long axis directed obliquely downward and inward. Though its size varies a little in different persons, yet as a rule it will admit the end of the little finger, so that we can tell by examination whether it be free or otherwise. To ascertain this, the best way is to push up the thin skin of the scrotum before the finger; then, by tracking the spermatic cord, the finger readily glides over the crest of the pubes and feels the sharp margins of the ring.

The position of the internal ring is about midway between the spine of the ilium and the symphysis of the pubes, and about two-thirds of an inch above Poupart's ligament.

72. **Inguinal Canal.**—The position of the external and internal abdominal rings being ascertained, it is plain that the direction of the inguinal canal must be obliquely downward and inward, and that its length in a well-formed adult male is from one and a half to two inches, according as we include the openings or not. In very young children the canal is much shorter and less oblique, the inner ring being behind the outer. With the growth of the pelvis in its transverse direction the anterior spines of the ilia become farther apart, and thus draw the internal ring more and more away from (*i. e.* to the outer side of) the external.

73. **Spermatic Cord.**—The spermatic cord can be felt as it emerges through the external ring, and its course can be tracked into the scrotum. The vas deferens can be distinctly felt at the back of the cord and separated from its other component parts.

74. **Epigastric Artery.**—The direction of the deep epigastric artery corresponds with a line drawn from the inner border of the internal ring up the middle of the Rectus muscle toward the chest. [It lies to the inside of oblique, and to the outside of direct, inguinal hernia.]

In thin persons the absorbent glands which lie along Poupart's ligament can be distinctly felt. They are usually oval, with their long axes parallel to the line of the ligament. [See § 97.]

75. **Abdominal Viscera.**—Now let us see how far we can make out externally the position and size of the abdominal viscera.

To make this examination with anything like success it is desirable to relax the abdominal muscles. The man should be on his back, the head, shoulders, and thorax being well raised, to relax the Recti muscles, and the thighs bent on the abdomen, to relax the several fasciæ attached to the crural arch. To induce complete relaxation where a very careful examination is desired [ether or] chloroform should be given.

In manipulating the abdomen we should not use the tips of the fingers. This is sure to excite the contraction of the muscles. The flat hand should be gently pressed upon it, and with an undulating movement.

76. It is well to bear in mind that the central tendon of the Diaphragm is about the level of the lower end of the sternum at its junction with the seventh costal cartilage; that the right half of the Diaphragm rises to about the level of the fifth rib—that is, about an inch below the nipple; that the left half does not rise quite so high. In tranquil breathing the Diaphragm descends about half an inch.

The position of the abdominal viscera varies, to a certain extent, in different persons. In some of them, especially the stomach, their position varies in the same person at different times.

Let us take first the largest of the abdominal viscera—the liver.

77. **Liver.**—The liver lies under the right hypochondrium, and passes across the middle line over the stomach into the left hypochondrium, generally speaking as far as the left mammary line. The extent to which it can be felt below the edges of the ribs depends upon whether it is enlarged or not, as well as upon its texture, and also upon the amount of flatus in the stomach and intestines. As a rule, in health its lower thin border projects about half an inch below the costal cartilages, and can be felt moving up and down with the action of the Diaphragm, but it requires an educated hand to feel it; an uneducated hand would miss it altogether. That part of it, however, which crosses the middle line below the ensiform cartilage is much more accessible to the feel; here it lies immediately behind the linea alba and in front of the stomach, nearly halfway down to the umbilicus. Here, therefore, is the best place to feel whether the liver be enlarged or pushed down lower than it ought to be. If it be much enlarged and much lower, even the most untutored hand could detect its edge.

Even if the edge of the liver be felt very much lower than its normal below the ribs, it does not necessarily follow that the liver is enlarged, since it may be pressed down by other causes—for instance, the habit of wearing tight stays.

To what height does the liver ascend? This can only be ascertained by careful percussion of the chest-wall. The highest part of its convexity on the right side is about one inch below the nipple, or nearly on a level with the external and inferior angle of the pectoralis major. Posteriorly, the liver comes to the surface below the base of the right lung, above the level of the tenth dorsal spine.

Roughly speaking, the upper border of the liver corresponds with the level of the tendinous centre of the Diaphragm; that is, the level of the lower end of the sternum.

Thus, a needle thrust into the right side, between the sixth and seventh ribs, would traverse the lung and then go through the Diaphragm into the liver.

78. **Gall-bladder.**—The gall-bladder, or rather the fundus of it, is situated just below the edge of the liver, about the ninth costal cartilage, outside the edge of the right Rectus muscle, but [unless distended] cannot be felt.

79. **Stomach.**—The stomach varies in size more than any [other] organ in the body. When empty and contracted (63) it lies at the back of the abdomen, overlapped by the left lobe of the liver, and in front of the pancreas. When very full, it turns on its axis and swells up toward the front, coming close behind the wall of the abdomen, occupying most of the left hypochondrium and epigastrium, displacing the other contiguous organs, pushing in every direction, and often interfering with the action of the heart and left lung. Hence the palpitation and distressing heart symptoms in indigestion and flatulence.

The cardiac orifice of the stomach lies to the left of the middle line, just below the level of the junction of the seventh costal cartilage with the sternum.

80. **Pylorus.**—The pylorus lies under the liver, on the right side, near the end of the cartilage of the eighth rib, but it cannot be felt, unless occasionally when enlarged and hardened by disease.

81. **Spleen.**—The spleen, if it be healthy, cannot be felt, so completely is it sheltered by the ribs. It lies on the left side, connected to the great end of the stomach, beneath the ninth, tenth, and eleventh ribs, between the axillary lines—lines drawn vertically downward from the anterior and posterior margins of the axilla. Its upper edge is on a level with the spine of the ninth dorsal vertebra, its lower with the spine of the eleventh.

Its position and size, therefore, in health can only be ascertained, and not very accurately, by the extent of dulness on percussion. The greatest amount of dulness would be over the tenth and eleventh ribs; above this the thin edge of the lung would intervene between the spleen and the abdominal wall. If, therefore, the spleen can be distinctly felt below the ribs, it must be enlarged. In proportion to its enlargement, so can its lower rounded border be detected below the tenth and eleventh ribs, especially when forced downward by a deep inspiration.[1]

82. **Pancreas.**—The pancreas lies transversely behind the stomach, and crosses the aorta and the spine about the junction of the first and second lumbar vertebræ. The proper place to feel for it, therefore, would be in the linea alba, about two or three inches above the umbilicus. Is it perceptible to the touch? Only under very deep pressure and very favorable circumstances, such as an emaciated and empty abdomen. It is worth remembering that it may be felt under such conditions. The pancreas of normal size, in thin persons, has been mistaken for disease—disease of the transverse arch of the colon or aneurism of the abdominal aorta.

83. **Kidney.**—The kidney lies at the back of the abdomen, on the Quadratus lumborum and Psoas muscles, opposite the two lower dorsal and two upper lumbar spines. The right, owing to the size of the liver, is a trifle—say, three-quarters of an inch—lower than the left. The pelvis of the kidney is on about the level of the spine of the first lumbar vertebræ: the upper border is on about the level of the space between the eleventh and twelfth dorsal spines; the lower border comes as low as the third lumbar spine. During a deep inspiration both kidneys are depressed by the Diaphragm nearly half an inch.

Can we feel the normal kidney? The only place where it is accessible to pressure is just below the last rib, on the outer edge of the Erector spinæ. I say accessible to pressure, for I have never succeeded in satisfying myself that I have distinctly felt its rounded lower border in the living subject, nor even in the dead, with the advantage of flaccid abdominal walls and the opportunity of making hard pressure with both hands placed simultaneously, one in front of the abdomen, the other on the back. For these reasons, although we can easily ascertain its degree of tenderness, we cannot actually feel it unless it be considerably enlarged.

We must be on our guard not to mistake for the kidney an enlarged liver or spleen or an accumulation of feces in the lumbar part of the colon. [As Sir William Jenner has pointed out, the anterior border of the spleen is sharp and may be notched, in both of which respects it differs from the kidney, even when enlarged.]

84. **Large Intestine.**—Let us now trace the large intestine and see where it is

---

[1] See some good observations on the position of the enlarged spleen, by Sir W. Jenner, *Brit. Med. Journ.*, Jan. 16, 1869.

accessible to pressure. The cæcum or caput coli and the ilio-cæcal valve lie in the right iliac fossa [or more frequently in the upper pelvis, much nearer the middle line than generally supposed[1]]. The ascending colon runs up the right lumbar region over the right kidney. [For its line, see § 51.] The transverse colon crosses the abdomen two or three inches above the umbilicus. The descending colon lies in the left lumbar region in front of the left kidney. The sigmoid flexure occupies the left iliac fossa.

Throughout this tortuous course, except at the hepatic and splenic flexures, the colon is accessible to pressure, and we could, under favorable circumstances, detect hardened feces in it. In a case which occurred in St. Bartholomew's Hospital a collection of feces in the transverse colon formed a distinct tumor in the abdomen. All the symptoms yielded to large and repeated injections of olive oil. In another case an accumulation of fecal matter in the sigmoid flexure during life was mistaken for a malignant disease.

85. **Colotomy.**—The operation of opening the colon (colotomy) may be done in the right or left loin below the kidney, in that part of the colon not covered by peritoneum.

The landmarks of the operation are: (1) the last rib, of which feel the sloping edge; (2) the crest of the ilium; (3) the outer border of the Erector spinæ. The incision should be about three inches long, midway between the rib and the ilium. It should begin at the outer border of the Erector spinæ, and should slope downward and outward in the direction of the rib. The edge of the Quadratus lumborum, which is the guide to the colon, is about one inch external to the edge of the Erector spinæ, or three full inches from the lumbar spines. The line of the gut is vertical, and runs for a good two inches between the lower border of the kidney and the iliac crest on the left side; rather less on the right.

Small Intestines.—All the room below the umbilicus is occupied by the small intestines. The coils of the jejunum lie nearer to the umbilicus (one reason of the great fatality of umbilical herniæ). Those of the ilium are lower down. [As the patches of Peyer involved in typhoid fever lie chiefly near the lower end of the ilium, which terminates at the ilio-cæcal valve, this will account for the tenderness found here.

It must be remembered that in ascites, while the fluid will gravitate to the lowest point in the abdominal cavity, the intestines, being filled with air and tethered to the spine by the mesentery, will float on top. Hence the value of "postural diagnosis"—*i. e.* percussion in different postures, on the right side, the left side, the back, etc. In any solid or encysted tumor this cannot hold good.]

On the right side, a little below the ninth rib, the colon lies close to the gall-bladder, and is, after death, sometimes tinged with bile. Posteriorly, this part of the colon is in contact with the kidney and duodenum.

86. **Bladder.**—When the bladder distends it gradually rises out of the pelvis into the abdomen, pushes the small intestines out of the way [lifts the peritoneum off from its anterior wall], and forms a swelling above the pubes, reaching in some instances up to the navel. The outline of this swelling is perceptible to the hand as well as to percussion. More than this, fluctuation can be felt through the distended bladder by tapping on it in front with the fingers of one hand, while the forefinger of the other passed up the rectum feels the bottom of the trigone.

THE PERINEUM.

The body is supposed to be placed in the usual position for lithotomy.

87. **Bony Framework.**—We can readily feel the osseous and ligamentous boundaries of the perineum—namely, the rami of the pubes and ischia, the tuberosities of the ischia, the great sacro-ischiatic ligaments, and the apex of the coccyx. This framework forms a lozenge-shaped space. If we draw an imaginary line across it from the front of one tuber ischii to the other, we divide this space into an anterior and a posterior triangle. The anterior is nearly equilateral, and in a well-formed pelvis its sides are from three to three and a half inches long. It is called the urethral triangle. The posterior, containing the greater part of the anus and the ischio-rectal fossa on each side, is called the anal triangle.

88. **Raphé.**—A slight central ridge of skin, called the "raphé," runs from the anus up the perineum, scrotum, and penis. This raphé, or middle line of the perineum, is the

---

[1] See Mr. Treves's valuable monograph on *The Anatomy of the Intestinal Canal and Peritoneum in Man.*

"line of safety" in making incisions to let out matter or effused urine or to divide a stricture.

89. **Central Point of the Perineum.**—It is very important to know that a point of the raphé about midway between the scrotum (where it joins the perineum) and the centre of the anus corresponds with the so-called "central tendon," where the perineal muscles meet. The bulb of the urethra lies above this point, and never, at any age, comes lower down. The artery of the bulb, too, never runs below this level. Therefore the incision in lithotomy should never commence above it. A knife introduced at this point and pushed backward with a very slight inclination upward would enter the membranous part of the urethra just in front of the prostate gland; pushed still farther, it would enter the neck of the bladder. This point, then, is a very good landmark to the urethra in lithotomy, or, indeed, in any operations on the perineum.

The incision in the lateral operation of lithotomy, beginning below the point indicated, should be carried downward and outward between the anus and the tuberosity of the ischium, a little nearer to the tuberosity than the anus [because the rectum is wider than the anus]. The lower end of the incision should reach a point just below the [level of the] anus.

90. **Triangular Ligament.**—In a thin perineum we can feel the lower border of the deep perineal fascia, or the so-called "triangular ligament," of the urethra. The urethra passes through it about one inch below the lower part of the symphysis pubis and about three-quarters of an inch higher than the central tendon of the perineum. It is important to bear in mind these landmarks in introducing a catheter. If the catheter be depressed too soon, its passage will be resisted by the triangular ligament; if too late, it will be likely to make a false passage by running through the bulb.

91. **Anus.**—One of the most important landmarks which guide a surgeon in his operation about the anus is a white line[1] at the junction of the skin and mucous membrane. It is easily recognized and is of especial interest, because it marks with great precision the linear interval between the External and Internal sphincter muscles. From this line the Internal sphincter extends upward, beneath the mucous membrane, for about an inch, becoming gradually more and more attenuated.

The wrinkled appearance of the anus is caused by the contraction of the External sphincter. At the bottom of these cutaneous folds, especially toward the coccyx, we look for "fissure of the anus."

92. **Landmarks in the Rectum.**—Many valuable landmarks may be felt by introducing the finger into the rectum, with a catheter at the same time in the urethra. The principal of these landmarks are the following:

a. The finger can feel the extent and powerful grasp of the Internal sphincter for about one inch up the bowel (91).

b. **Urethra.**—Through the front wall of the bowel it can most distinctly feel the track of the membranous part of the urethra, exactly in the middle line. This is very important, because you can ascertain with precision whether the catheter has deviated from the proper track.

c. **Prostate Gland.**—About an inch and a half or two inches from the anus the finger comes upon the prostate gland. The gland lies in close contact with the bowel, and can be detected by its shape and hard feel. The finger, moved from side to side, can examine the size of its lateral lobes, their consistence and sensibility.

d. The finger, introduced still farther, can reach beyond the prostate as far as the apex of the trigone of the bladder. More than this, it can feel the angle between the ductus communes ejaculatorii, which forms the apex of the trigone. This is the precise spot where the distended bladder should be punctured through the rectum. The more distended the bladder, the easier can this spot be felt. Fluctuation is at once detected by a gentle tap on the bladder above the pubes (86). The trocar must be thrust in the direction of the axis of the distended bladder; that is, roughly speaking, in a line drawn from the anus through the pelvis to the umbilicus.

e. The fold of peritoneum called the recto-vesical pouch is about four inches from the anus, therefore it is not within reach of the finger, and we run no risk of wounding it in tapping the bladder if the trocar be introduced near the angle of the trigone. [J. B. Roberts has measured the distance of the recto-vesical (or recto-vaginal) pouch from the anus, both *in situ* and after removal from the body. The distance was one and a quarter to two inches *in situ*, and from three and a half to four and a quarter inches after removal.]

f. The finger can feel one of the ridges or folds of mucous membrane which are situated at the lower part of the rectum. This fold projects from the side, and sometimes from the upper part of the rectum, near the prostate. When thickened or ulcerated this fold occasions great pain in defecation, and great relief is afforded by its division.

---

[1] *Lectures on Rest and Pain*, by John Hilton, F. R. S., London, 1863, p. 280.

g. Lastly, the finger can examine the condition of the spaces filled with fat on either side of the rectum, called the ischio-rectal fossæ, with a view to ascertain the existence of deep-seated collections of matter or the internal communications of fistulæ.

[It is often important to instruct mothers and nurses as to the difference in the **Direction of the Anus and that of the Rectum,** in order that they may introduce the nozzle of an enema syringe without pain. The rectum, after following the curve of the sacrum and coccyx, suddenly bends backward and terminates in the anus. The axis of the anal opening is in the direction of the navel for about an inch, and when the finger, the syringe-nozzle, or other instrument has been introduced thus far, it may then be swept around so as to point to the small of the back and be pushed in as far as necessary.

It is useful to remember that in women the posterior wall of the vagina can be everted from the rectum, and, *vice versâ,* the rectum from the vagina, and so be carefully examined without a speculum.]

Introduction of Catheters.—In the introduction of catheters the following are good rules: Keep the point of the instrument well applied against the upper surface of the urethra; depress the handle at the right moment (90); keep the umbilicus in view; in cases of difficulty feel the urethra through the rectum, to ascertain whether the instrument be in the right direction. Attention to these rules diminishes the risk of making a false passage, an injury which under great delicacy in manipulation ought never to happen.

Urethra in the Child.—In children the membranous part of the urethra is, relatively speaking, very long, owing to the smallness of the prostate. It is also more sharply curved, because the bladder in children is more in the abdomen than in the pelvis. It is, moreover, composed of thin and delicate walls. The greatest gentleness, therefore, should be used in passing a catheter, else the instrument is likely to pass through the coats and make a false passage. Hence the advantage of being able to ascertain through the rectum whether the instrument be in the right track and moving freely in the bladder, which can also be easily felt in children.

THE THIGH.

93. **Poupart's Ligament, or Crural Arch.**—Mark the anterior superior spine of the ilium, the spine of the pubes, and define the line of Poupart's ligament, which extends between them. This line is one of our guides in the diagnosis of inguinal and femoral herniæ. If the bulk of the tumor be above the line, the hernia is probably inguinal; if below it, femoral. The line is not a straight one drawn from the spine of the ilium to the spine of the pubes, but slightly curved, with the convexity downward, owing to its close connection with the fascia lata of the thigh. In many persons it can be distinctly felt; in nearly all its precise course is indicated by a slight furrow in the skin.

For the points about the spine of the pubes refer to paragraph 69.

94. **Furrow at the Bend of the Thigh.**—When the thigh is even slightly bent there appears a second furrow in the skin below that at the crural arch. This second furrow begins at the angle between the scrotum and the thigh, passes outward, and is gradually lost between the top of the trochanter and the anterior superior spine of the ilium. It runs right across the front of the capsule of the hip-joint. For this reason it is a valuable landmark in amputation at the hip-joint. The point of the knife should be introduced externally where the furrow begins, should run precisely along the line of it, and come out where it ends, so that the capsule of the joint may be opened with the first thrust. In suspected disease of the hip, pressure made in this line, just below the spine of the ilium, will tell us if the joint be tender. Effusion into the joint obliterates all trace of the furrow and makes a fulness when contrasted with the opposite groin.

95. **Saphenous Opening.**—In most persons there is a natural depression over the saphenous opening in the fascia lata, where the saphena vein joins the femoral. The position of this opening is just below the inner third of Poupart's ligament and about an inch and a half external to the spine of the pubes. This is the place where the swelling of a femoral hernia first appears; therefore it ought to be carefully examined in cases of doubt.

96. **Femoral Ring.**—The position of the femoral ring, through which the hernia

escapes from the abdomen, is, on a deeper plane, about half an inch higher than the saphenous opening and immediately under Poupart's ligament. As the plane of the ring is vertical in the supine position of the body, the way in which we should try to reduce a femoral hernia is by pressure, applied first in a downward direction, afterward in an upward. The intestine protruded has to pass back under a sharp edge of fascia—namely, the upper horn of the saphenous opening (known as Hey's ligament) [or the falciform process]. At the same time we bend the thigh, to relax the fascia as much as possible.

A good way to find the seat of the femoral ring with precision is the following: Feel for the pulsation of the femoral artery on the pubes; allow half an inch (on the inner side) for the femoral vein; then comes the femoral ring.

In performing the operation for the relief of the stricture in femoral hernia the incision through the skin should be about an inch and a half external to the spine of the pubes. Its direction should be vertical and its middle should be just over the femoral ring.

97. Lymphatic Glands in the Groin.—The cluster of inguinal and femoral [*i. e.* saphenous] lymphatic glands can sometimes be felt in thin persons. The inguinal lie for the most part along the line of Poupart's ligament: they receive the absorbents from the wall of the abdomen, the urethra, the penis, the scrotum, anus [perineum, and gluteal region]. The femoral [or saphenous] glands lie chiefly over the saphenous opening and along the outer side of the saphena vein: they receive the absorbents of the lower extremity; they receive some also from the scrotum, of which we have practical evidence in cases of chimney-sweepers' cancer. [It is extremely important to differentiate these two sets of glands—the inguinal and the saphenous—as the enlargement of one set or the other often throws great light on the seat and character of any lesion producing this enlargement.]

98. Trochanter Major.—The trochanter major is a most valuable landmark, to which we are continually appealing in injuries and diseases of the lower extremity. There is a natural depression over the hip (in fat persons) [and thin too], where it lies very near the surface, and can be plainly felt, especially when the thigh is rotated. Nothing intervenes between the bone and the skin except the strong fascia of the Gluteus maximus and the great bursa underneath it.

The top of the trochanter lies pretty nearly on a level with the spine of the pubes, and is about three-fourths of an inch lower than the top of the head of the femur. A careful examination of the bearing of the great trochanter to the other bony prominences of the pelvis, and a comparison of its relative position with that of the opposite side, are the best guides in the diagnosis of injuries about the hip and the position of the head of the femur.

99. Nélaton's Line.—"If in the normal state you examine the relations of the great trochanter to the other bony prominences of the pelvis, you will find that the top of the trochanter corresponds to a line drawn from the anterior superior spine of the ilium to the most prominent part of the tuberosity of the ischium. This line also runs through the centre of the acetabulum. The extent of displacement in dislocation or fracture is marked by the projection of the trochanter behind and above this line."[1]

"Nélaton's line," as it is termed, theoretically holds good. But in stout persons it is not always easy to feel these bony points so as to draw the line with precision. A surgeon must, after all, in many cases trust to measurement by his eyes and his flat hands—his best guides. Thus, let the thumbs be placed firmly on the spines of the ilia, while the fingers grasp the trochanters on each side. Having the sound side as a standard of comparison, the hand will easily detect any displacement on the injured side. Hippocrates bids us compare the sound parts with the parts affected (in fractures) and observe the inequalities.

The top of the great trochanter is the guide in an operation recently introduced by Mr. Adams—namely, the "subcutaneous section of the neck of the femur." "The puncture should be made one inch above and nearly one inch in front of the top of the trochanter. The neck of the bone is to be sawn through at right angles to its axis, the saw working parallel to Poupart's ligament and about one inch below it." [Gant's operation is a similar subcutaneous section of the shaft of the femur just below the lesser trochanter.]

Spine of the Ilium.—The anterior superior spine of the ilium is the point from which we measure the length of the lower limb. [See § 68.] By looking at the spines of opposite sides we can detect any slant in the pelvis. [Their position should be carefully marked by an aniline pencil.] By pressure on both spines simultaneously [or, better still, by grasping this portion of the ilium] we examine if there be a fracture of the pelvis or disease at the sacro-iliac joint.

---

[1] Nélaton, *Pathologie chirurgicale*, t. iv. p. 441, 1848.

100. "In reducing a dislocation of the hip by manipulation it is important to bear in mind that in every position the head of the femur faces nearly in the direction of the inner aspect of its internal condyle."[1]

101. **Compression of Femoral Artery.**—About a point midway between the spine of the ilium and the symphysis pubis the femoral artery can be felt beating and effectually compressed against the pubes. How should the pressure be applied when the patient lies on the back? In accordance with the slope of the bone; that is, with a slight inclination upward. A want of attention to this point is the reason why so many fail when they undertake to command the circulation through the femoral artery in an amputation or to cure an aneurism by digital compression. [I think the chief reason of failure in attempting compression of the femoral is that pressure is made two or three inches below Poupart's ligament, instead of *immediately* below it. In the former position thick muscles form the floor against which it is ineffectually compressed; in the latter it is directly on the edge of the pelvis or the head of the femur.]

If the Italian tourniquet be used, we should be careful to adjust the counterpad well under the tuberosity of the ischium. If digital pressure be used, it is easy to command the femoral by slight pressure of the thumb, provided the fingers have a firm hold on the great trochanter.

102. **Sartorius.**—The Sartorius is the great fleshy landmark of the thigh, as the Biceps is of the arm and the Sterno-cleido-mastoideus of the neck. Its direction and borders may easily be traced by asking the patient to raise his leg, a movement which puts the muscle in action. The same action defines the boundaries of the triangle (of Scarpa) formed by Poupart's ligament, the Adductor longus, and Sartorius.

Line of Femoral Artery.—To define the course of the femoral artery draw a line from midway between the anterior superior spine of the ilium and the symphysis pubis to the (spur-like) tubercle for the Adductor magnus on the inner side of the knee. The femoral artery lies under the upper two-thirds of this line.

The Sartorius begins to cross the artery, as a rule, from three to four inches below Poupart's ligament. The point at which the profunda artery arises is about one and a half or two inches below the ligament. Therefore the incision for tying the femoral in Scarpa's triangle should commence about a hand's breadth below Poupart's ligament [unless this is actually *measured*, we are very apt to get the incision too low down], and be continued for three inches in the line of the artery.

To command the femoral in Scarpa's triangle the pad of the tourniquet should be placed at the apex, and the direction of the pressure should be, not backward, but outward, so that the artery may be compressed against the femur.

In the middle third of the thigh the femoral artery lies in Hunter's canal, overlapped by the Sartorius. About the commencement of the lower third the artery leaves the canal through the oval opening in the Adductor magnus, and under the name of popliteal enters the popliteal space. The line for finding the artery in Hunter's canal has been already traced (102). The incision to reach the artery in this part of its course would fall in with the outer border of the Sartorius.

To command the femoral artery in Hunter's canal the pressure should be directed outwardly, so as to press the vessel against the bone.

THE BUTTOCKS.

103. **Buttocks: Bony Landmarks.**—The bony landmarks of the buttocks which can be distinctly felt are: 1, the posterior superior spines of the ilia; 2, the spines of the sacral vertebræ; 3, the two tubercles of the last sacral vertebra; 4, the apex of the coccyx in the deep groove leading to the anus; 5, the tuberosities of the ischia on each side of the anus.

The posterior spines of the ilia are about the level of the second sacral spine, and correspond with the middle of the sacro-iliac symphysis [and are marked by a graceful dimple].

The third sacral spine marks the lowest level to which the membranes of the cord and the cerebro-spinal fluid descend in the spinal canal.

The tuberosities of the ischia, in the erect position, are covered by the Gluteus maximus. In the sitting position they support the weight of the body, and are only covered by a thick pad of coarse fat. Between this pad and the bones there is a bursa which becomes occasionally enlarged and inflamed in coachmen.

---

[1] Bigelow, *Mechanism of Dislocation and Fracture of the Hip*, Philadelphia, 1869.

The prominence of the nates is one of the characteristics of man in connection with his erect attitude. "Les fesses n'appartiennent qu'à l'espèce humaine." They are formed of an accumulation of fat over the great muscle of the buttock (Gluteus maximus). From their appearance we may gather some indication of the state of the constitution. They are firm and globose in the vigorous, loose and flaccid in the infirm. Wasting and flattening of one, compared with the other, is an early symptom of disease in the hip.

104. **Fold of the Buttock.**—The deep furrow, termed "the fold of the buttock" [or gluteo-femoral crease], which separates the nates from the back of the thigh corresponds with the lower border of the Gluteus maximus. Its altered direction in disease of the hip is very characteristic. This is the best place to feel for the great ischiatic nerve. We find it by pressing deeply between the trochanter and the tuber ischii, rather nearer to the latter. When we sit upright the nerve is not liable to pressure, but it becomes numbed when we sit long sideways.

105. **Gluteal Artery.**—To find at what point the gluteal artery comes out of the pelvis, draw a line from the posterior superior spine of the ilium to the top of the trochanter major, rotated inward. The junction of the inner with the middle third of this line lies over the artery as it emerges from the upper border of the great ischiatic notch.

The point of exit of the ischiatic artery from the pelvis is about half an inch lower than that of the gluteal.

106. **Pudic Artery.**—The pudic artery crosses the spine of the ischium. To find it, draw a line from the outer side of the tuber ischii to the posterior superior spine of the ilium. The junction of the lower with the middle third gives the position of the artery. The ischiatic artery lies close to it, but nearer the middle line.

Looking at the course of these arteries, it appears that when we sit on hard seats the pressure is sustained by the bones; when we recline on soft seats the pressure is sustained more by the soft parts and reaches the arteries; hence the tendency of modern modes of reposing to drive the blood into the interior of the pelvis and favor the production of piles and uterine disorders. A celebrated French accoucheur used to say that the fashion of high waists, tight lacing, and easy-chairs brought him many thousands a year.

THE KNEE.

107. **Bony Points.**—The patella, the tuberosities of the two condyles, the tubercle of the tibia for the attachment of the ligamentum patellæ, another (the lateral) tubercle on the outer side of the head of the tibia, and the head of the fibula are the chief bony landmarks of the knee.

Observe that the head of the fibula lies at the outer and back part of the tibia, and that it is pretty nearly on a level with the tubercle for the attachment of the ligamentum patellæ.

We can also feel the adductor tubercle or spur-like projection of bone above the internal condyle which gives attachment to the tendon of the Adductor magnus. This spur-like projection corresponds with the level of the epiphysis of the lower end of the femur, and also with the level of the highest part of the trochlea for the patella—facts worth notice in performing excision of the knee. [The importance of preserving intact this inferior epiphysial cartilage of the femur is best understood when it is remembered that, due to its late ossification, this is the seat of the greatest growth in the entire body. While the whole body from birth to adult life grows (in the male) 3.37 times, and the whole leg 4.49 times, the lower femur grows 7.30 times.]

"In reducing a dislocation of the hip it is important to bear in mind that the inner aspect of the internal condyle in every position of the limb faces nearly in the direction of the head of the femur" (100).

The tubercle on the outer side of the head of the tibia gives attachment to the broad and strong aponeurosis (tendon of the Tensor fasciæ), which, acting like a brace for the support of the pelvis, is well seen in emaciated persons down the outer side of the thigh. [In fracture of the neck of the femur, therefore, instead of being tense, the fascia will yield to pressure, especially just above the knee and the great trochanter. The patient should be standing (Allis).] This tubercle indicates the level to which the condyles of the femur descend, and the lower level of the synovial membrane.

The patella in extension of the knee is nearly all above the condyles; in flexion it lies in the intercondyloid fossa (more on the external condyle), and thus protects the joint in kneeling. Its inner border is thicker and more prominent than the outer, which slopes down toward its condyle.

108. **Ligamentum Patellæ.**—The line of the ligamentum patellæ is vertical. Hence any deviation from this line one way or the other indicates more or less dislocation of the tibia. There is a pellet of fat under the ligament which answers a "packing" purpose—sinking in when the knee is bent, rising when the knee is extended, and bulging on either side of the tendon almost enough to give the feel of fluctuation.

In a well-formed leg the ligamentum patellæ, the tubercle of the tibia, and the middle of the ankle should be in the same straight line—a useful point in the adjustment of fractures.

Behind the upper half of the ligamentum patellæ is the synovial membrane of the knee-joint; behind the lower half is a synovial bursa and a pad of fat. It is well to remember this in cases of injury to the ligamentum patellæ.

109. **Prepatellar Bursa.**—The patellar or housemaid's bursa is situated not only over the patella, but over the upper part of the ligament. This is plain enough when the bursa becomes enlarged. There is another subcutaneous bursa over the insertion of the ligament into the tubercle of the tibia. This is quite independent of the deep bursa between the tendon and the bone [the "subpatellar" bursa].

110. **Synovial Membrane of Knee.**—The synovial membrane of the knee when the joint is extended rises like a cul-de-sac above the upper border of the patella about two inches. It ascends, too, a little higher under the vastus internus than the vastus externus—a fact very manifest when the joint is distended. When the knee is bent this cul-de-sac is drawn down; hence the rule of bending the knee in operations near the lower end of the femur.

The lower level of the synovial membrane of the knee is just above the level of the upper part of the head of the fibula. The tibio-fibular synovial membrane is, with rare exceptions, independent of that of the knee.

[It is surprising to note what a large part of the surface of the joint, and especially on the femur, is exposed to examination by the touch with the knee in flexion. The condition of the synovial membrane and the cartilage, therefore, can be ascertained. The trochlear groove is especially well defined.]

111. **Popliteal Tendons.**—The tendons forming the boundaries of the popliteal space can be distinctly felt when the muscles which bend the knee are acting. On the outer side we have the biceps running down to the head of the fibula. On the inner side we feel three tendons, disposed as follows: Nearest to the middle of the popliteal space is the Semitendinosus [slender], very salient, and traceable high up the thigh; next comes the thick round tendon of the Semimembranosus; still more internally is the Gracilis. The Sartorius, which forms a graceful muscular prominence on the inner side of the knee, does not become tendinous until it gets below it.

[A very interesting experiment may be tried on the "ligamentous action" (as Prof. Cleland calls it) of these muscles. Standing with the back fixed against a wall to steady especially the pelvis, the knee can be made almost to touch the belly. But note that the knee is flexed. Repeat the experiment, the knee being kept rigid, and when the heel has been but slightly raised a sharp pain in the ham follows any effort to carry it higher. Flexion of the rigid leg from the vertical line to a right angle increases the distance from the tuber ischii to the tuberosities of the tibia by some six or eight centimeters—an amount of stretching these muscles cannot undergo. Hence the compulsory flexion of the knee in flexion of the hip.

The same thing is seen in the wrist. Flex the wrist with the fingers extended, and again with the fingers in a "fist." The first movement can be carried to 90°, the second only to 30°, or in some up to 60°. Making a fist had already stretched the flexors, and they can be stretched but little farther. Many surgeons make errors in the leg, but especially in the forearm and hand, and inflict injury as well as needless pain, by forgetting these facts while making passive movement.

It must be noted, however, that in children there is less danger of this over-stretching, for from childhood to old age there is a progressive invasion of the extensible belly by the inextensible tendon in the muscles generally. Hence the ease with which children, even when seated, can lift the heel (without moving the pelvis) and make the hips the point of an acute angle.]

112. **Popliteal Bursa.**—The precise position of this bursa in the popliteal space,

which sometimes enlarges to the size of a hen's egg, is between the tendon of the inner head of the Gastrocnemius and the tendon of the Semimembranosus, just where they rub one against the other. The bursa is from one and a half to two inches long. When enlarged it makes a swelling on the inner side of the popliteal space which bulges and becomes tense when the knee is extended, and *vice versâ*. I examined one hundred and fifty bodies with a view to ascertain how often this bursa communicates with the synovial membrane of the knee. There was a communication about once in five instances. This should make us cautious in interfering too roughly with the bursa when enlarged.

113. **Popliteal Artery.**—The popliteal artery can be felt beating, and can be compressed against the back of the femur, close to which it lies. But pressure sufficient to stop the blood should be firm, and should be made against the bone nearer to the inner than the outer hamstrings. The line of the artery corresponds with the middle of the ham. It lies under cover of the fleshy belly of the Semimembranosus, and the outer border of this muscle is the guide to it. An incision down the middle of the ham would fall in with the vessel just above the condyles.

114. **Peroneal Nerve.**—The peroneal nerve runs parallel with and close to the inner border of the tendon of the Biceps. It can be felt in thin persons. There is a risk of dividing it in tenotomy of the Biceps, unless the knife be carefully introduced [flatwise between the two and the cut made] from within outward. Below the knee the nerve can be felt close to the fibula just below the head, and when pressed upon in this situation causes a sensation to run down its branches to the foot.

THE LEG AND ANKLE.

115. **Bony Points.**—The tubercle of the tibia (for the attachment of the ligamentum patellæ), the sharp front edge called the shin, and the broad flat [internal] subcutaneous surface of the bone can be felt all the way down. The inner edge can be felt too, but not so plainly. The lower third is the narrowest part of the bone and the most frequent seat of fracture.

The head of the fibula is a good landmark on the outer side of the leg, about one inch below the top of the tibia and nearly on a level with the tubercle. Observe that it is placed well back, and that it forms no part of the knee-joint and takes no share in supporting the weight.

The shaft of the fibula arches backward, the reverse of the shaft of the tibia. The fact of the bones not being on the same plane should be remembered in flap amputations. The shaft of the fibula is so buried amongst the muscles that the only part to be distinctly felt is the lower fourth. Here there is a flat triangular subcutaneous surface between the Peroneus tertius in front and the two Peronei (longus and brevis) behind. Here is the most frequent seat of fracture.

116. **Malleoli.**—The shape and relative position of the malleoli should be carefully studied as the great landmarks of the ankle. The inner malleolus does not descend so low as the outer, and advances more to the front: at the same time, owing to its greater antero-posterior depth, it is on the same plane as the outer behind. The lower border of the inner malleolus is somewhat rounded, and the slight notch in it for the attachment of the lateral ligament can be felt. The outer malleolus descends lower than the inner, thus effectually locking the joint on the outer side. Its shape is not unlike the head of a serpent. Viewed in profile, it lies just in the middle of the joint.

In Syme's amputation of the foot at the ankle the line of the incision should run from the apex of the outer malleolus, under the sole, to the centre of the inner.

In a well-formed leg the inner edge of the patella, the inner ankle, and the inner side of the great toe should be in the same vertical plane. Look to these landmarks in adjusting a fracture or dislocation, keeping at the same time an eye upon the conformation of the opposite limb.

[In consequence of violence, usually a sprain, a sliver of the internal surface of the thick malleoli may be broken off, seriously implicating the joint, but yet not perceptible by mobility, crepitus, or otherwise from the exterior. Mr. Callender has happily named such "sprain-fractures."

Into the intermalleolar space the astragalus is tightly wedged or mortised, and we have here, as I pointed out some years ago, a valuable means of diagnosis in case of Pott's fracture of the fibula three or four inches above the external malleolus. In such a fracture this intermalleolar space is widened. If now the leg be seized by one hand above the ankle and the foot by the other, with the palm under the sole, the thumb and fingers will have the astragalus in their grasp. The astragalus can then be pushed sidewise against the outer malleolus, and then shoved suddenly toward the firm inner malleolus, against which it will come with an easily-perceived impact if there be fracture. If none exist, the astragalus will have no lateral play. Motion at the medio-tarsal joints must not be mistaken for this tibio-tarsal movement.]

There are several strong tendons to be seen and felt about the ankle.

117. **Tendo Achillis.**—Behind is the tendo Achillis. It forms a high relief, with a shallow gutter on each side of it. The narrowest part of the tendon, where it should be divided in tenotomy, is about the level of the inner ankle; below this it expands again to be attached to the lower and back part of the os calcis. Seen in profile, the tendon is not straight, but slightly concave, being drawn in by an aponeurosis which forms a sort of girdle around it. This girdle proceeds from the posterior ligament of the ankle: and, though most of its fibres encircle the tendon, some of them adhere to and draw in its sides. All this disappears when the tendon is laid bare by dissection. [Between the tendo Achillis and the calcis is a synovial bursa.]

118. **Tendons Behind the Inner Ankle.**—Above and behind the malleolus internus we can feel the broad flat tendon of the Tibialis posticus, and upon it that of the Flexor longus digitorum. The tendon of the Tibialis posticus lies nearest to the bone, and comes well up in relief in adduction of the foot. It lies close to, and parallel with, the inner edge of the tibia, so that this edge is the best guide to it. Therefore in tenotomy the knife should be introduced first perpendicularly between the tendon and the bone, and then turned at right angles to cut the tendon. The tendon has a separate sheath and synovial membrane, which commences about one inch and a half above the apex of the malleolus, and is continued to its insertion into the tubercle of the scaphoid bone. The proper place, then, for division of the tendon is about two inches above the end of the malleolus.

In a young and fat child, where the inner edge of the tibia cannot be distinctly felt, the best guide to the tendon is a point midway between the front and the back of the ankle. An incision in front of this point might injure the internal saphena vein; behind this point, the posterior tibial artery.

119. **Tendons Behind the Outer Ankle.**—Behind the malleolus externus we feel the two peroneal (long and short) tendons. They lie close to the edge of the fibula, the short one nearer to the bone. In dividing these tendons the knife should be introduced perpendicularly to the surface and about two inches above the apex of the ankle, so as to be above the synovial sheaths of the tendons.

Tendons in Front of the Ankle.—Over the front of the ankle, when the muscles are in action, we can see and feel, beginning on the inner side, the tendons of the Tibialis anticus, the Extensor longus pollicis, the Extensor longus digitorum, and the Peroneus tertius. They start up like cords when the foot is raised [especially when the action is resisted], and are kept in their proper relative position by strong pulleys formed by the anterior annular ligament. Of these pulleys, the strongest is that of the Extensor communis digitorum. When the ankle is sprained the pain and swelling arise from a stretching of these pulleys and effusion into their synovial sheaths. A laceration of one of the pulleys and escape of the tendon is extremely rare.

The place for the division of the tendon of the Tibialis anticus, so as to divide it below its synovial sheath, is about one inch before its insertion into the cuneiform bone. The knife should be introduced on the outer side, so as to avoid the dorsal artery of the foot.

[Most of these tendons can be best seen by standing a model on one foot—*i. e.* in unstable equilibrium.]

Now trace the lines of the arteries and the landmarks near which they divide.

120. **Popliteal Artery.**—About one inch and a quarter below the head of the fibula—or, say, one inch below the tubercle of the tibia—the popliteal artery divides into the anterior and posterior tibial. The peroneal comes off from the posterior tibial about three inches below the head of the fibula.

Consequently, we may lay down, as a general rule, that in amputations one inch below the head of the fibula only one main artery, the popliteal, is divided; in amputations two inches below the head of the fibula two main arteries, the anterior and posterior tibial, are divided; in amputations three inches below the head three main arteries, the two tibials and the peroneal, are divided.

121. **Anterior Tibial Artery.**—The anterior tibial artery comes in front of the

interosseous membrane one inch and a quarter below the head of the fibula, and here lies close to this bone. Its subsequent course is defined by a line drawn from the front of the head of the fibula to the middle of the front of the ankle. This line corresponds pretty nearly with the outer border of the Tibialis anticus all the way down. If this muscle be put in action, its outer border (the intermuscular line) is plainly seen, and the incision for the ligature of the artery in any part of its course may be defined with the greatest precision. The artery can be felt beating, and can be compressed where it crosses the front of the tibia and ankle.

122. **Posterior Tibial Artery.**—The posterior tibial commences about one inch and a quarter below the head of the fibula. Its subsequent course corresponds with a line drawn from the middle of the upper part of the calf to the hollow behind the inner ankle, where it can be felt beating distinctly about half an inch behind the edge of the tibia. A vertical incision down the middle of the calf would reach the artery under cover of the Gastrocnemius and Soleus. A vertical incision along the middle third of the leg, about half an inch from the inner edge of the tibia, would enable the operator to reach the artery sideways, by detaching from the bone the tibial origin of the Soleus.

[The posterior tibial artery, behind the malleolus, lies midway between the tendo Achillis, or the heel, and the malleolus. It is the middle of five structures: in front of it are (1) the Tibialis posticus tendon, (2) the Flexor longus digitorum tendon; behind it are (4) the posterior tibial nerve and (5) the Flexor longus pollicis tendon. It is important to observe that, as Wyeth has shown, it bifurcates into the two plantar arteries at a line drawn from the point of the malleolus to the middle of the heel.]

123. **Saphena Veins.**—The subcutaneous veins on the dorsum of the foot form an arch convex toward the toes (as on the back of the hand), from which issue the two main subcutaneous trunks of the lower limb, the internal and external saphena veins. The internal vein can be always plainly seen over the front of the inner ankle. Its farther course up the inner side of the leg, knee, and thigh to its termination in the femoral is not in all persons manifest.

[It lies about half an inch behind the internal border of the tibia, skirts the knee postero-internally, and, passing up the inside of the thigh, empties at the saphenous opening into the femoral. A thrombus not uncommonly may form in it or in the femoral, or may extend from it into the femoral. The careful investigation of both veins then becomes very important, and is not generally difficult, especially if we remember the course of the saphena and the relation of the femoral to its artery.]

The external saphena vein runs behind the outer ankle and up the middle of the calf to empty itself (generally) into the popliteal vein.

THE FOOT.

What are the bony landmarks which guide us in the surgery of the foot?

124. **Points of Bone.**—Along the inner side of the foot, beginning from behind, we can feel—1, the tuberosity of the os calcis; 2, the projection of the internal malleolus; 3, the projection of the os calcis, termed "sustentaculum tali," about one full inch below the malleolus; 4, about one inch in front of the malleolus internus and a little lower is the tubercle of the scaphoid bone, the gap between it and the sustentaculum tali being filled by the calcaneo-scaphoid ligament and the tendon of the Tibialis posticus, in which there is often a sesamoid bone; 5, the internal cuneiform bone; 6. the projection of the first metatarsal bone; 7, the sesamoid bones of the great toe. [On a line nearly midway from the scaphoid to the inner malleolus the head of the astragalus can be felt. In front, with the foot in extension, we can feel also the upper and lateral articular surfaces of the astragalus, and especially the ridges between them.]

Along the outer side of the foot we can feel—1, the external tuberosity of the os calcis; 2, the external malleolus; 3, the peroneal tubercle of the os calcis, one inch below the malleolus, with the long peroneal tendon below it and the short one above it; 4, the projection of the base of the fifth metatarsal bone.

125. **Lines of Joints.**—In fat persons the following rules for finding the joints may be of service as regards the surgery of the foot:

The level of the ankle-joint lies about half an inch above the end of the inner malleolus. This is worth remembering in performing "Syme's amputation."

The tubercle of the scaphoid bone is the best guide to the astragalo-scaphoid joint, which lies immediately behind it, and the plane of this joint is in the same line as that of the calcaneo-cuboid. Thus, a line drawn transversely over the dorsum of the foot, behind the tubercle of the scaphoid, would strike both the joints opened in "Chopart's operation."

Place your thumb on the tubercle of the scaphoid, and measure about one inch and a half in front: here you find the joint between the internal cuneiform bone and the metatarsal bone of the great toe. This point is useful in "Lisfranc's operation," which consists in the removal of the metatarsal bones.

The line of the calcaneo-cuboid joint lies midway between the external malleolus and the (tarsal) end of the metatarsal bone of the little toe.

The projection of the fifth metatarsal bone is the guide to the joint between it and the cuboid.

Notice that the line of the joints between the metatarsal bones and the first phalanges lies a full inch farther back than the interdigital folds of the skin. This is a point to be remembered in amputating the toes.

126. **Dorsal Artery.**—The line of the dorsal artery of the foot is from the middle of the ankle to the interval between the first and second metatarsal bones. The artery can be felt beating over the bones along the outer side of the Extensor longus pollicis, which is the best guide to it.

127. **Bursa.**—The synovial sheath of the Extensor longus pollicis extends from the front of the ankle over the instep (apex of the internal cuneiform bone) as far as the metatarsal bone of the great toe. There is generally a bursa over the instep above, or it may be below, the tendon.

There is often a large irregular bursa between the tendons of the Extensor longus digitorum and the projecting end of the astragalus, over which the tendons play. There is much friction here. It is well to be aware that this bursa sometimes communicates with the joint of the head of the astragalus.

128. **Plantar Arteries.**—The course of the external plantar artery corresponds with a line drawn from the hollow behind the inner ankle obliquely across the sole nearly to the base of the fifth metatarsal bone; from thence the artery turns transversely across the foot, lying (deeply) near the bases of the metatarsal bones, till it inosculates with the dorsal artery of the foot in the first interosseous space.

The course of the internal plantar corresponds with a line drawn from the inner side of the os calcis to the middle of the great toe.

129. **Plantar Fascia.**—To divide the plantar fascia subcutaneously, the best place is about one inch in front of its attachment to the os calcis. This is the narrowest part of it. The knife should be introduced on the inner side, and the incision will be behind the plantar artery.

The subcutaneous section of the tendon of the Abductor pollicis should be made about one inch before its insertion.

[It is evidently the opinion of shoemakers that the axis of the sole of the foot ought to be a median straight line, and the two borders symmetrically curved toward it. If a foot they have not unduly distorted be observed carefully, it will be seen (B. Lee) that the axis is curved; that on the inner border of the foot, the heel and the front part of the foot are in nearly a straight line, while the outer border is a curved line. If Nature were followed, natural-shaped feet would be the result and the miseries of corns and bunions be unknown.]

THE ARM.

130. **Clavicle.**—The line of the clavicle and the projection of the joint at either end can always be felt, even in the fattest persons. Its direction is not perfectly horizontal, but slightly inclined downward when the arm hangs quietly by the side. When the body lies flat on the back, the shoulder not only falls back, but rises a little, the weight of the limb being taken off. Hence the modern practice of treating fractures of the clavicle (in the early stage) by the supine position.

On the front surface of the clavicle, not far from its acromial end, there is in many persons of mature age a spine-like projection of bone. So far as I know, it has not been described. A gentleman, himself a surgeon, showed me an instance in his own person. He suspected it was an exostosis.

As a rule, the acromio-clavicular joint forms an even plane. But there is sometimes a knob of bone at the acromial end of the clavicle, or it may be only a thickening of the fibro-cartilage sometimes existing in the joint. In either case this relief might be mistaken for a dislocation or even for a fracture. A reference to the other shoulder might settle the question.

[Being subcutaneous throughout, the clavicle can readily be seized and examined for fracture, syphilitic nodes, etc. If before a glass the arm be swung round, raised and lowered, the shoulder be shrugged, etc., we shall appreciate the fact that this is the only bony connection the arm has with the body, and to what a very large extent it is movable, the sterno-clavicular joint being the pivot, not only for motion of the clavicle, but of the entire arm.]

131. **Bony Points of the Shoulder.**—We can distinctly feel the spine of the scapula and the acromion, more especially at the angle where they join behind the shoulder. This angle is the best place from which to measure in taking the comparative length of the arms.

In some shoulders, though very rarely, there is an abnormal symphysis between the spine of the scapula and the acromion. There may indeed be two symphyses and two acromial bones, the acromion having two centres of ossification. These normal symphyses might be mistaken for fractures until we have examined the opposite shoulder, which is sure to present a similar conformation.[1] [In dislocation of the shoulder the acromion process projects abnormally, with a hollow below it, due to absence of the head of the humerus from its proper place.]

Tuberosities.—Projecting beyond the acromion (the arm hanging by the side) we can feel, through the fibres of the deltoid, the upper part of the humerus. It distinctly moves under the hand when the arm is rotated. It is not the head of the bone which is felt, but the tuberosities, the greater externally, the lesser in front. These tuberosities form the convexity of the shoulder. When the arm is raised this convexity disappears; there is a slight depression in its place. The head of the bone can be felt by pressing the fingers high up in the axilla.

The absence of this prominence formed by the upper part of the humerus under the Deltoid, and the presence of a prominence low in the hollow of the axilla, or in front below the coracoid process, or behind on the back of the scapula, bespeak dislocation of the head of the bone.

In examining obscure injuries about the shoulders it is worth remembering that in the normal relation of the bones and in every position the great tuberosity faces in the direction of the external condyle. The head of the bone faces very much in the direction of the internal condyle.

It is worth remembering, also, that the upper epiphysis of the humerus includes the tuberosities, and that it does not unite by bone to the shaft till about the twentieth year.

By making deep pressure in front of the shoulder when the arm is pendent and supine, we can feel the bicipital groove [between the two tuberosities]. It looks directly forward, and runs in a line drawn vertically downward through the middle of the Biceps to its tendon at the elbow. We should be aware of this, lest it be mistaken for a fracture.

132. **Coraco-acromial Ligament.**—Under the anterior fibres of the Deltoid we can distinctly feel the position and extent of the coraco-acromial ligament. A knife passed vertically through the middle of it goes at once into the shoulder-joint and strikes the bicipital groove with the tendon—a point to be remembered in excision.

In persons of an athletic build the triangular form and beautiful structure of the Deltoid become conspicuous when the muscle is in action. The depression on the outer side of the arm, indicating its insertion, is the place selected for issues or setons.

The arm being held up by an assistant, the anterior and posterior borders of the relaxed Deltoid admit of being raised, so that in amputation at the shoulder the knife can be introduced beneath the muscle to make the flap.

133. **Axilla.**—[To show its borders best, let the model place his elbow on your shoulder and press down upon it, when the muscles will be brought into strong relief.] The anterior border of the axilla, formed by the Pectoralis major, follows the line of the fifth rib. In counting the ribs or in tapping the chest it is worth remembering that the highest visible digitation of the Serratus magnus is attached to the sixth rib. The angle of the digitation is directed forward, and corresponds to the upper edge of the rib. The second visible digitation corresponds to the seventh rib; the interval between these digi-

---

[1] See Pruge on "Ossa Acromialia" (*Zeitschrift für rationelle Medizin*), 3, Reihe, Bd. vii., 1859.

tations, therefore, corresponds to the sixth intercostal space—a convenient place for tapping the chest (38).

In the normal state no glands can be felt in the axilla. [But in feeling to see if they are enlarged, remember that they lie next the chest, at the inner, and not the outer, wall of the axilla—a position which facilitates also their removal.]

134. **Axillary Artery.**—When the arm is raised to a right angle with the body, and the head of the humerus thereby depressed, the axillary artery is plainly felt beating, and can be perfectly compressed on the inner side of the Coraco-brachialis. This muscle stands out in relief along the humeral side of the axilla, and is the best guide to the artery. A line drawn along its inner border—that is, down the middle [or rather at the junction of the middle and anterior thirds] of the axilla—corresponds with the course of the artery.

The depth and form of the axilla alter in different positions of the arm. In the arm raised and abducted the axilla becomes nearly flat; hence this position is always adopted in operations.

In opening abscesses in the axilla the incision should be made midway between the borders, and the point of the knife introduced from above downward.

135. **Brachial Artery.**—When the arm is extended and supinated a line drawn from the deepest part of the middle of the axilla [or rather at the junction of the middle and anterior thirds] down the inner side of the Biceps to the middle of the bend of the elbow corresponds with the course of the brachial artery. The artery can be felt and compressed all the way down, but nowhere so effectually as midway, where it lies on the tendon of the Coraco-brachialis close to the inner side of the humerus. The only direction to apply the pressure effectually is outward and a little backward, else the artery will slip off the bone. [A high bifurcation very often occurs, and will probably be perceptible on careful examination.

The median nerve lies to the outside of the artery above, crosses it, usually in front at the middle, and lies to the inside below. It can usually be felt and very easily differentiated from the artery.]

The musculo-spiral nerve and superior profunda artery wind round the back of the humerus about its middle, and come to the front of the external condyloid ridge [in the groove between the Supinator longus and the Brachialis anticus, where it is accessible to the battery and in operations]. Thus for full three inches above the condyles there is nothing to interfere with operations on the back of the bone, which is here broad and flat.

136. **Bend of Elbow.**—At the bend of the elbow the tendon of the Biceps can be plainly felt, as well as the pulsation of the brachial artery close to its inner side, before dividing into the radial and ulnar. [If the arm be strongly fixed at a right angle—by attempting to lift a heavy table, for instance—the bicipital fascia can be outlined by the finger, and in many persons by the eye.]

Cutaneous Veins.—The bend of the elbow in young children and in persons with fat and round arms presents a semicircular fold of which the curve embraces the lower part of the Biceps; but in muscular persons we see the distinct boundaries of the triangular space formed by the Pronator teres on the inner side and the Supinator longus on the outer. Here can be traced, standing out in strong relief under the thin white skin, the superficial veins, which, in days gone by, when bloodletting was the fashion, were of such great importance. Their arrangement, although subject to variety, is very much like the branches of the letter M, the middle of the M being at the middle of the elbow. Of these branches, the median basilic, which runs over the tendon of the Biceps, is the largest and most conspicuous, and is generally selected for venesection; it crosses the course of the brachial artery, nothing intervening but the semilunar aponeurosis from the tendon of the Biceps.

137. **Landmarks of Elbow.**—It is of great importance to be familiar with the relative positions of the various bony prominences about the elbow. We can always feel the internal and external condyles. The internal is the more prominent of the two, and a trifle higher.

Olecranon.—We can always feel the olecranon. This is somewhat nearer to the inner than to the outer condyle. [On strong flexion the groove in the humerus for the olecranon can be readily felt, and even seen.] Between the olecranon and the internal condyle is a deep depression in which lies the ulnar nerve (vulgarly called the "funny [or "crazy"] bone").

On the outer side of the olecranon, just below the external condyle, is a pit in the skin constant even in fat persons (when the elbow is extended). This pit is considered one of the beauties of the elbow in a graceful arm; it is seen in a child as a pretty little dimple. [The dimple disappears on semiflexion.] To the surgeon it is most interesting, as in this valley behind the Supinator longus and the radial Extensors of the wrist he can distinctly feel the head of the radius rolling in pronation and supination of the forearm. It is therefore one of the most important landmarks of the elbow, since it enables us to say whether the head of the radius is in its right place, and whether it rotates with the shaft.

Can the tubercle of the radius be felt? Yes, but only on the back of the forearm in extreme pronation. Its projection is then distinctly perceptible just below the head of the bone.

Relations of the Olecranon and Condyles.—To examine the relative positions of the olecranon and condyles in the different motions of the elbow-joint, place the thumb on one condyle, the tip of the middle finger on the other, and the tip of the forefinger on the olecranon. In extension the highest point of the olecranon is never above the line of the condyles; indeed, it is just in this line. With the elbow at right angles the point of the olecranon is vertically below the line of the condyles. In extreme flexion the point of the olecranon lies in front of the line of the condyles.

All these relative positions would be altered in the dislocation of the ulna, but not (necessarily) in a fracture of the lower end of the humerus.

Sometimes, though rarely, we meet with a hook-like projection of bone above the internal condyle. It is called a "supracondyloid" process; it can be felt through the skin, with its concavity downward, and is a rudiment of the bony canal which in many Mammalia transmits the median nerve and ulnar artery. A third origin of the Pronator teres is always attached to it; this origin covers the brachial artery.[1]

Bursæ.—The subcutaneous bursa over the olecranon, if distended, would be as large as a walnut. A second bursa sometimes exists a little lower down upon the ulna. There is also a small subcutaneous bursa over each of the condyles.

The vertical extent of the elbow-joint is limited above by a line drawn from one condyle to the other; below by a line corresponding to the lowest part of the head of the radius.

138. **Interosseous Arteries.**—About one inch below the head of the radius the ulnar artery gives off the common interosseous, and this divides about half an inch lower into the anterior and posterior interosseous. Thus, in amputating the forearm, say two inches below the head of the radius, four arteries at least would require ligature.

By flexion of the elbow to the utmost the circulation through the brachial artery can be arrested, but the position is painful and can be tolerated only for a short time.

Lymphatic Gland.—There is a small lymphatic gland just above the inner condyle in front of the intermuscular septum. It is the first to take alarm in poisoned wounds [chancres, etc.] of the hand.

THE FOREARM AND WRIST.

139. **Ulna.**—The edge of the ulna is subcutaneous, and can be felt from the olecranon to the styloid process (in supination). Any irregularity could be easily detected. The styloid process of the ulna does not descend so low as the styloid process of the radius, or it would impede the free adduction of the hand. Its apex is on a level with the radio-carpal joint. The head of the ulna is plainly felt and seen projecting at the back of the wrist, especially in pronation of the forearm. It then lies between the tendons of the Extensor carpi ulnaris and Extensor minimi digiti. There is often a subcutaneous bursa over it. [In supination it is the styloid process, and not the head of the ulna, which is felt posteriorly.]

140. **Radius.**—The upper half of the shaft of the radius [but not the head] is so covered by muscles that we cannot feel it; the lower half is more accessible to the touch, especially just above and just below the part where it is crossed by the Extensors of the thumb. Its styloid process is readily felt, and made all the more manifest by being covered by the first two Extensor tendons of the thumb. It descends lower and lies more to the front than the corresponding process of the ulna. The relative positions of

---

[1] See on this subject a monograph, "Canalis Supracondyloideus Humeri," by W. Grüber, Petersburg, 1856.

these styloid processes can be best examined by placing the thumb on one and the forefinger on the other.

Feel for the little bony pulley on the back of the radius near the wrist which keeps in place the third Extensor tendon of the thumb. This and the bone just above it is the place which we examine for a suspected fracture (termed Colles's) near the lower end of the radius.

141. **Carpus.**—Below the styloid process of the radius, just on the inner side of the Extensors of the thumb, we feel the tubercle of the scaphoid bone. Between the styloid process and the tubercle is the level of the radio-carpal joint. A little lower we feel the trapezium.

Just below the ulna on the palm of the hand we feel the pisiform bone, and on the inner side of this the cuneiform.

There are several transverse furrows on the palmar aspect of the wrist. The lowest of these, which is slightly convex downward, corresponds with the upper edge of the anterior annular ligament and the intercarpal joint. The line of the radio-carpal joint, as already stated, is on a level with the apex of the styloid process of the ulna.

In forcible [and resisted] flexion of the wrist the tendon of the Flexor carpi radialis and that of the Palmaris longus come up in relief. On the outer side of the first-named tendon we feel the pulse, the radial artery here lying close to the radius.

The tendon of the Palmaris longus runs near the middle of the wrist, and close to its inner border runs the median nerve. In letting out deep-seated matter near the wrist the incision should be made close to and parallel with the inner edge of the radial Flexor tendon, so as to avoid injury to the median nerve. [The median nerve in the forearm lies under the Flexor sublimis digitorum, in a line drawn from the bend of the elbow just inside the artery to a point between the tendons of the Palmaris longus and the Flexor carpi radialis. It is here not only amenable to operations, but often is cut in accidents.]

We can feel the tendon of the Flexor carpi ulnaris for some distance above the wrist. It overlies the ulnar artery and somewhat masks its pulsation.

142. **Pulse.**—The "pulse at the wrist" is felt just outside the tendon of the Flexor carpi radialis. In feeling the pulse it should be remembered that in some cases the superficialis volæ arises higher and is larger than usual. In such cases it runs by the side of the radial artery, and gives additional volume to the pulse. The old writers call it "pulsus duplex." When in doubt, therefore, it is well to feel the pulse in each wrist.

143. **Great Carpal Bursa.**—The great synovial sheath under the annular ligament common to the Flexor tendons of the fingers and the long Flexor of the thumb extends upward about an inch and a half above the edge of the ligament, and downward as low as the middle of the palm. This general synovial sheath communicates with the special sheaths of the thumb and the little finger; not with that of the index, middle, and ring fingers. [Hence felons on the thumb and little finger are much more dangerous (and fortunately much more rare) than on the other fingers, since the pus may invade the main synovial sheath of the Flexors.]

144. **"Tabatière anatomique."**—On the outer side of the wrist we can distinctly see and feel, when in action, the three Extensor tendons of the thumb. Between the second and third there is deep depression at the root of the thumb which the French humorously call the "tabatière anatomique." In this depression we can make out—1, the relief of the superficial radial vein; 2, the radial artery in its passage to the back of the hand; 3, the upper end of the metacarpal bone of the thumb.

145. **Tendons on the Back of the Wrist.**—The relative positions of the several Extensor tendons of the wrist and fingers as they play in their grooves over the back of the radius and ulna can all be distinctly traced when the several muscles are put in action. The length of their synovial sheaths should be remembered. They vary from one inch and a half to two inches and a half. The longest of all are those of the Extensors of the thumb. When these sheaths are inflamed and swollen, the motion of the tendons becomes painful and gives rise to a feeling of crepitus, called "tenalgia crepitans" by some writers. It is said to be met with sometimes in pianists. [On the overstretching of these muscles, see § 111.]

146. **Lines of Arteries.**—The course of the radial artery corresponds with a line drawn from the outer border of the tendon of the Biceps at the bend of the elbow down the front of the forearm to the front of the styloid process of the radius. In the upper third of its course the artery is overlapped by the Supinator longus. To make allow-

ance for this, the incision for the ligature of the artery in this situation should be made, not precisely in the line of its course, but rather nearer the middle of the forearm.

The line of the ulnar artery runs from the middle of the bend of the elbow (slightly curving inward) to the outer side of the pisiform bone. The radial and ulnar arteries can, in most cases, be effectually commanded by pressure well applied at the wrist in wounds of the palmar arch.

Before we make incisions along the forearm it is always desirable to ascertain whether the ulnar artery, which usually runs under the superficial muscles, may not run abnormally over them; in which case its pulsations can be felt all down the forearm.

THE HAND.

147. It is beside the purpose here to examine the question whether the hand can tell more than the arm, the leg, or any other part of the body about the physical constitution of its owner, and to what use it has been put. Those who are interested in this subject should read a very elaborate treatise by Carus[1] *On the Reason and Meaning of the Different Forms of the Hand.* Still less would I indulge curiosity by inquiring whether the professors of chiromancy, relying on the text "erit signum in manu tua et quasi monumentum ante oculos tuos," can advance any reasonable pretensions for their assertion that they can read in the furrows of the palm the future destiny of its master.

148. **Furrow in Palm.**—The only furrow in the palm useful as a surgical landmark is that which runs transversely across its lower third [from the ulnar border to the interspace between the fore and middle fingers], and is well seen when the fingers are slightly bent. This transverse furrow corresponds pretty nearly with the metacarpal joints of the [middle, ring, and little] fingers, with the upper limit of the synovial sheaths of the Flexor tendons of the four fingers (that of the little finger excepted (143)); also with the splitting of the palmar fascia into its four slips. The transverse metacarpal ligament lies in the same line with it. Again, a little below this furrow the digital arteries bifurcate to run along the opposite sides of the fingers. [The furrow which starts between the thumb and forefinger on the radial border of the hand, and runs toward the ulnar border, marks the level of the metacarpal joint of the forefinger. The third marked crease is caused by flexion of the thumb; the other two, by flexion of the fingers.]

149. **Interdigital Folds.**—By pressure upon the interdigital folds of skin we can feel the transverse ligament of the fingers, which prevents their too wide separation. The skin of these folds is much thinner on the dorsal than the palmar aspect; hence deep-seated abscesses in the palm very frequently burst on the back of the hand.

150. **Digital Furrows.**—Concerning the transverse furrows on the palmar surface of the fingers, notice that the first furrows, close to the palm, do not correspond with the metacarpal joints. The second and third furrows do correspond with their respective joints.

The slight depression observable between the ball of the thumb and that of the little finger corresponds with the middle of the anterior annular ligament.

151. **Palmar Arterial Arches.**—In opening abscesses in the palm it is important to bear in mind the position of the large arterial arches which lie beneath the palmar fascia. The line of the superficial palmar arch crosses the palm about the junction of the upper with the lower two-thirds—that is, in the line of the [web of the] thumb separated widely from the fingers. From this the digital arteries run straight between the shafts of the metacarpal bones toward the clefts of the fingers. Incisions, therefore, to let out pus beneath the palmar fascia may safely be made in the lower two-thirds of the palm, provided they run in the direction of the middle line of the fingers. The deep palmar arch lies half an inch nearer the wrist than the superficial.

152. **Digital Arteries.**—As the digital arteries run along the sides of the fingers, the incision to open a thecal abscess should be made strictly in the middle line. It should be made not over, but between, the joints, since the sheath is strongest and thickest over the shafts of the phalanges, and therefore more likely to produce strangulation of the enclosed tendons.

153. **Metacarpal Joint of Thumb.**—The joint of the metacarpal bone of the thumb with the trapezium can be distinctly felt by tracing the dorsal surface of the bone upward till we come to the prominence which indicates the joint at the bottom of the "tabatière anatomique" (140). Supposing, however, there be much swelling, the

---

[1] *Ueber Grund und Bedeutung der verschiedenen Formen der Hand*, Stuttgart, 1846.

knife introduced at the angle between the first and second metacarpal bones readily finds the joint if the blade be directed outward.

154. **Sesamoid Bones.**—The sesamoid bones of the thumb can be distinctly felt. Just above them—that is, nearer to the wrist—lies the joint between the metacarpal bone and the first phalanx. We should remember the position of these bones in amputation at this joint. *Mutatis mutandis*, the same observations apply to the sesamoid bones of the great toe.

The Extensor tendon of the last joint of the thumb crosses the apex of the first interosseous space. Under the tendon and in the angle between the bones we feel the radial artery just before it sinks into the palm.

155. **Subcutaneous Veins.**—The veins on the back of the hand, and their arrangement in the form of arches which receive the digital veins, are sufficiently obvious. The number and arrangement of the arches may vary, but in all hands it is interesting to notice that the veins from the fingers run up between the knuckles and out of harm's way.

156. **Interosseous Arteries.**—Since the dorsal interosseous arteries, like the palmar, run along the interosseous spaces, incisions to let out pus should always be made along the lines of the metacarpal bones.

157. **Digital Bursæ.**—Small subcutaneous bursæ are sometimes developed over the knuckles and the backs of the joints of the fingers. They often become enlarged and unseemly in persons of a rheumatic or gouty tendency.

158. **Knuckles and Digital Joints.**—The three rows of projections called "the knuckles" are formed by the proximal bones of the several joints: thus the first row is formed by the ends of the metacarpals; the second, by the ends of the first phalanges, and so forth. In amputations of the fingers it is well to remember that in all cases the line of the joints is a little in advance of the knuckles; that is, nearer the end of the fingers.

Long and graceful fingers, coupled with thickness and breadth of the sentient pulp at their ends and too great arching of the nails, have been regarded, ever since the days of Hippocrates, as not unlikely indications of a tendency to pulmonary disease.

[Staining the **nails** (*e. g.* by nitric acid) affords a means of determining the fact and the rate of their growth, and therefore of the nutritive processes in the corresponding arm or leg.]

PALPATION BY THE RECTUM.

The following report is from Mr. Walsham of St. Bartholomew's Hospital, who, having a small hand (somewhat less than seven and a half inches round), has had opportunities of introducing it up the rectum in the living subject for the purpose of diagnosis:

"It is possible to introduce the hand (if small) into the rectum, in many cases into the sigmoid flexure, and in rare instances into the descending colon.

"Once beyond the sphincter, the hand enters a capacious sac, and the following important parts can be felt through its walls:

"Through the anterior wall the hand first recognizes the prostate, which feels like a moderately large chestnut. Immediately behind the prostate the vesiculæ seminales may be distinguished as two softish masses situated one on either side of the middle line. Internal to them the whipcord-like feel of the vasa deferentia can be readily traced over the bladder to the sides of the pelvis.

"The bladder is easily recognized, when moderately distended, as a soft fluctuating tumor behind the prostate; when empty it cannot be distinguished from the intestines, which then descend between the rectum and the pubes. The arch of the pubes can be well defined when the bladder is empty.

"Through the posterior wall of the bowel the coccyx and sacrum can be felt, the curve of the sacrum being readily followed by the hand.

"The projecting spine of the ischium on each side of the pelvis is a valuable landmark. From this point the outlines of the greater and lesser sacro-ischiatic foramina can be traced by the fingers, and any new growth encroaching on the pelvic cavity through these apertures could be easily detected.

"If the hand be now pushed farther up the gut, the promontory of the sacrum is reached; the pulsation of the iliac vessels becomes manifest, and the course of the external iliac can be traced along the brim of the pelvis to the crural arch, the loose attachments of the rectum permitting very free movement in this direction. The internal iliac artery can also be followed to the upper part of the great sacro-ischiatic foramen.

"By semi-rotatory movement and alternately flexing and extending the fingers the hand can gradually be insinuated into the commencement of the sigmoid flexure. In the sigmoid flexure the fingers can explore the whole of the lower part of the abdomen, the loose attachment of this portion of the gut permitting the hand to travel freely over the iliac and hypogastric regions.

"The parts that can here be felt are the bifurcation of the aorta, the division of the common iliac arteries, the iliac fossa, and the crest of the ilium.

"In the female the uterus in the middle line and the ovaries on either side can be readily distinguished.

"In the introduction of the hand into the rectum in a patient under chloroform the dilatation of the Sphincter ani should be very gradual: first two fingers, then four, and finally the thumb, should be passed. It is necessary to use considerable force, and unless care be taken not only the integumentary edge of the anus, but the Sphincter itself, may be lacerated. The introduction is facilitated by the application of the other hand upon the abdomen.

"When the dilatation has been gradual and the hand not too large, no incontinence of feces and no very considerable amount of pain have resulted.

"We have been informed on reliable authority that permanent incontinence of feces has occasionally followed these examinations."

Lastly, we think it right to insist upon the important fact that in some subjects even a small hand cannot be passed up the rectum beyond the reflection of the peritoneum over the second part of the gut. In such instances the peritoneum offers a resistance like a tight garter, and prevents the farther advance of the hand without great risk of laceration of the parts.[1]

EXAMINATION PER VAGINAM.

For this report I am indebted to Dr. Godson of St. Bartholomew's Hospital:

"The finger introduced into the vagina comes upon the carunculæ myrtiformes, which are vascular membranous processes independent of the hymen, variable in number, size, and form. It also feels the transverse ridges known as 'rugæ.'

"Along the anterior wall of the vagina the finger readily detects the track of the urethra, which feels like a prominent cord and forms an excellent guide to the orifice of the meatus urinarius in passing a catheter. The orifice is indicated by a slight semicircular prominence situated about one-third of an inch above the orifice of the vagina. Behind the urethra the finger comes upon the posterior wall of the bladder. But the bladder is not perceptible, as such, to the touch unless distended. With a catheter previously introduced it is much more readily explored.

"The septum between the vagina and the rectum is so thin that, should the rectum contain fecal matter, its presence becomes at once apparent to the finger.

"The cervix uteri is felt protruding from the roof of the vagina in a direction downward and backward—that is, in a line from the umbilicus to the coccyx. The os uteri is felt, small and round, in the centre of the cervix. The posterior lip feels a little lower than the anterior. The cul-de-sac formed by the vagina in front and behind the cervix should be perfectly elastic to the touch, and not communicate the sensation of a resisting body. Any resistance here bespeaks an abnormal condition.

"The bony landmarks within reach of a finger, or perhaps two, in a woman who has not borne a child are the symphysis pubis, the rami of the pubes, and ischia. The coccyx and part of the hollow of the sacrum may also be felt, but not without exerting much pressure on the posterior wall of the vagina, which gives considerable pain. If the promontory of the sacrum can be felt, it is a sign that the conjugate diameter of the pelvis is abnormal.

"The finger in the rectum can detect almost everything which has been mentioned in connection with the vagina. The shape and direction of the cervix uteri are almost as perceptible, and the posterior wall of the uterus can be examined. The peritoneal fold termed recto-vaginal (Douglas's space) can also be well explored, and anything abnormal detected in this direction—a point of great importance in the diagnosis of diseases and displacements of the uterus.

---

[1] For further information on this subject see a paper by Mr. Walsham in *St. Bartholomew's Hospital Reports*, vol. xii.

"The ovary in its normal state and position cannot be detected by the touch, even with the hand firmly pressed on the hypogastrium. If a movable body be felt through the vaginal roof on one side of the cervix, if this body be exquisitely tender and recede at once from the finger, it is an ovary in a state of prolapse.

"The fundus of a healthy unimpregnated uterus never rises above the level of the brim of the pelvis, and cannot therefore be felt by pressing the hand on the hypogastrium.

"The direction of the uterus is subject to changes which cannot be looked upon as abnormal. The fundus may be thrown backward by a distended bladder or forward by a distended rectum. The axis of its cavity is not a straight, but a curved line, and uterine sounds should be shaped to suit it."

INDEX.

A.

Abdomen, 858
  apertures found in, 859
  boundaries of, 858
  landmarks of, 1041
  lymphatics of, 646
  muscles of, 411
  regions of, 859
  viscera of, 860, 1044
Abdominal aorta, 571
    branches of, 574
    surgical anatomy of, 573
  lines, 1041
  muscles, 411
  ring, external, 413
    internal, 996
  viscera, position of, 860
Abducens nerve, 731
Abductor indicis muscle, 456
  minimi digiti muscle, hand, 455
      foot, 490
  pollicis muscle, hand, 452
      foot, 489
Aberrant duct of testis, 971
Absorbent glands, 638
Absorbents, 638
Accelerator urinæ muscle, 1014
Accessorii orbicularis oris, 377
Accessorius ad sacro-lumbalem muscle, 406
  pedis, 491
Accessory obturator nerve, 773
  palatine canals, 193
  pudic artery, 588
Acervulus cerebri, 702
Acetabulum, 265
Acromial end of clavicle, fracture of, 458
  nerves, 751
  region, muscles of, 432
  thoracic artery, 556
Acromio-clavicular joint, 324
Acromion process, 235
    fracture of, 458
Actions of muscles. See each group of muscles.
Adductor brevis muscle, 471
  longus muscle, 470
  magnus muscle, 471
  pollicis muscle, hand, 454
      foot, 492
Adenoid connective tissue, 48
Adipose tissue, 49
Afferent vessels of kidney, 947
Air-cells, 938
Air-sacs of lung, 938
Alæ of vomer, 197
Alar ligaments, 310
    of knee, 351
  thoracic artery, 556
Alimentary canal, 839
    development of, 130
    subdivisions of, 839
Allantois, 111, 955
Alveolar artery, 524
  process, 189, 199
Alveoli of lower jaw, 199
  of upper jaw, 189
    formation of, 849
  of stomach, 872
Amnion, 109
Amniotic cavity, 110
Amphiarthrosis, 298
Ampullæ of semicircular canals, 833
  of tubuli lactiferi, 909
Amygdalæ, 851
  of cerebellum, 710
Anal fascia, 1022
Anastomosis of arteries, 501
Anastomotica magna of brachial, 561
    of femoral, 599
Anatomical neck of humerus, 238
      fracture of, 458
  [position of hand, 250]
Anconeus muscle, 447
Andersch, ganglion of, 737
[Aneurismal thrill, how to produce, 596]
Aneurisms of abdominal aorta, 573
  of arch of aorta, 506
  of thoracic aorta, 570
[Angle at knee and elbow, 242]
  of jaw, 201
  of pubes, 265
  of rib, 225
  sacro-vertebral, 153
Angular artery, 518
  convolution, 676
  movement, 300
  process, external, 168
    internal, 168
  vein, 614
Animal constituent of bone, 58
Ankle-joint, 354
  relations of tendons and vessels to, 356
Annular ligament of radius and ulna, 333
    of wrist, anterior, 449
      posterior, 450
    of ankle, anterior, 487
      external, 488
      internal, 488
    of stapes, 830
Annulus ovalis, 909
Anterior annular ligament, wrist, 449
      ankle, 487
Anterior chamber of eye, 816
  crural nerve, 773
  dental canal, 187
  ethmoidal cells, 182
  fontanelle, 184
  fossa of skull, 206
  nasal spine, 190
  palatine canal, 189, 208
    fossa, 189, 208
  radicular zone, 658
  region of skull, 213
  triangle of neck, 525
Antihelix, 823
  fossa of, 823
Antitragicus muscle, 824
Antitragus, 823
Antrum of Highmore, 187
  [percussion of, 188, 189]
  landmarks of, 1031
Anus, 1010
  development of, 132
  landmarks of, 1047
  muscles of, 1011
Aorta, 502
  abdominal, 571
  branches of, 574
  development of, 127
  division of, 1042
  landmarks of, 1042
  surgical anatomy of, 506
  arch of, 503
    ascending part of, 504
    branches of, 507
    descending part of, 505
    peculiarities of, 506
      of branches of, 507
    sinuses of, 504
    surgical anatomy of, 506
    transverse portion of, 504
  descending, 569
  thoracic, 569
    branches of, 570
    surgical anatomy of, 570
Aortic opening of diaphragm, 424
    of heart, 912
  plexus, 796
  semilunar valves, 912
  sinuses, 913
Apertura scalæ vestibuli cochleæ, 832
Aponeurosis, 364
  of deltoid, 432
  of external oblique in inguinal region, 992
  infraspinous, 434
  of occipito-frontalis, 367
  subscapular, 433
  suprahyoid, 388
  of soft palate, 851
  supraspinous, 433
Apophysis, 142

- Apparatus ligamentosus colli, 309
- Appendages of eye, 819
  - of skin, 92
  - of uterus, 984
- Appendices epiploicæ, 869
- Appendix of right auricle, 907
  - of left auricle, 911
  - vermiformis, 882
    - [surgical anatomy of, 882]
- Aqua labyrinthi, 837
- Aquæductus cochleæ, 174, 834
  - vestibuli, 174, 832
  - Fallopii, 174, 827
  - Sylvii, 701
- Aqueous humor, 816
- Arachnoid of brain, 663
  - of cord, 653
- Arantii corpora, 911, 912
- Arantius, ventricle of, 667
- Arbor vitæ uterina, 981
    - of cerebellum, 711
- Arch of aorta, 503
    - peculiarities of, 506
    - branches of, 507
    - surgical anatomy, 506
  - of pubes, 269
  - of a vertebra, 143
  - supraorbital, 167
  - crural or femoral, 1004
  - palmar superficial, 566
  - deep, 563
  - plantar, 610
  - zygomatic, 212
- Arches, pharyngeal, 117
  - aortic, fœtal, 127
- Arciform fibres of medulla oblongata, 668
- Arcuate fibres of cerebrum, 707
    - of cerebellum, 711
- Area, germinal, 102
- Areola of breast, 988
- Areolar tissue, 46
- Arm, back of, muscles of, 438
  - front of, muscles of, 435
  - arteries of, 541
  - bones of, 237
  - fascia of, 435
  - landmarks of, 1054
  - lymphatic glands of, 643
  - lymphatics of, 643
  - superficial fascia of, 431
  - nerves of, 755
  - veins of, 623
- Arnold's nerve, 739
    - canal for, 174
  - ganglion, 729
- Arteria centralis retinæ, 532
- Arteriæ propriæ renales, 949
  - receptaculi, 530
- Arteries, development of, 126
- Arteries, general anatomy of, 78
  - anastomoses of, 501
  - capillary, 81
  - distribution of, 501
  - mode of division, 501
  - mode of origin of branches, 501
  - nerves of, 81
  - sheath of, 80
  - structure of, 78
  - subdivision of, 501
  - systemic, 501
  - vessels of, 80
- Arteries or artery, accessory pudic, 588
- Arteries or artery—
  - acromial thoracic, 556
  - alar thoracic, 556
  - alveolar, 524
  - anastomotica magna of brachial, 561
      - of femoral, 599
  - angular, 518
  - [anterior and internal frontal, 537]
    - cerebral, 533
    - [cerebral, 534, 537] .
    - choroid, 534
    - ciliary, 532
    - communicating, 534
    - intercostal, 552
    - spinal, 549
  - aorta, 502
    - abdominal, 571
    - arch of, 503
    - ascending part, 504
    - descending part, 505
    - transverse portion, 504
    - thoracic, 569
  - articular, knee, 602
  - ascending cervical, 550
    - pharyngeal, 520
  - auditory, 549, 838
  - auricular anterior, 521
    - posterior, 520
  - axillary, 554
    - landmarks of, 1055
  - azygos of knee, 602
  - basilar, 549
  - brachial, 558
  - bronchial, 570, 939
  - buccal, 524
    - of bulb, 589
  - calcanean, internal, 609
  - carotid, common, 509
    - external, 512
    - internal, 528
  - carpal ulnar, 569
    - of cavernous body, 589
    - radial, 564
  - centralis retinæ, 532
  - cerebellar, 549
  - cerebral, 534, 549
    - ascending cervical, 550
    - superficial, 551
    - princeps, 519
    - profunda, 553
  - choroid anterior, 534
    - posterior, 549
  - ciliary, 532
  - circle of Willis, 550
  - [circular, of uterus, 982]
  - circumflex, of arm, 557
    - of thigh, 598
    - iliac, 593
    - superficial, 597
  - cochlear, 838
  - coccygeal, 590
  - colica dextra, 579
    - media, 579
    - sinistra, 579
  - cœliac axis, 574
  - comes nervi ischiadici, 590
    - phrenici, 552
  - common carotid, 509
    - [femoral, 594]
    - iliac, 582
  - communicating, anterior cerebri, 534
    - posterior cerebri, 534
- Arteries or artery—
  - communicating branch of ulnar, 569
  - coronary of heart, 507
    - of lip, 518
  - [cortical, 539]
    - [system of, in brain, 534, 537]
  - cremasteric, 593
  - crico-thyroid, 515
  - cystic, 576
  - deep branch of ulnar, 569
    - cervical, 552
    - [femoral, 594]
    - palmar arch, 562
    - temporal, 524
  - deferent, 586
  - dental inferior, 523
    - superior, 524
  - descending aorta, 569
    - palatine, 524
  - digital plantar, 610
    - of ulnar, 569
  - dorsal, of penis, 589
    - of scapula, 557
  - dorsalis hallucis, 606
    - indicis, 564
    - linguæ, 515
    - pedis, 605
    - pollicis, 564
  - epigastric, 593
    - landmarks of, 1054
    - superior, 552
    - superficial, 597
  - ethmoidal, 532
  - external carotid, 512
    - plantar, 610
    - iliac, 591
  - facial, 516
    - landmarks of, 1058
  - femoral, 594
    - compression of, 1048
      - landmarks of, 1049
    - deep, 598
  - frontal, 532
    - landmarks of, 1058
  - [ganglionic system of, in brain, 536]
  - gastric, 574, 577
  - gastro-duodenalis, 575
  - gastro-epiploica dextra, 576
    - sinistra, 577
  - gluteal, 591
    - inferior, 590
      - landmarks of, 1051
  - helicine, 965
  - hemorrhoidal inferior, 589
    - middle, 586
    - superior, 579
  - hepatic, 574
  - hyoid branch of lingual, 515
    - of superior thyroid, 514
  - hypogastric in fœtus, 584, 916
  - ileo-colic, 579
  - iliac, common, 582
    - external, 591
    - internal, 584
  - ilio-lumbar, 591
  - inferior cerebellar, 549
    - dental, 523
    - labial, 518
    - laryngeal, 550
    - mesenteric, 579
    - profunda, 561
    - pyloric, 575
    - thyroid, 550

Arteries or artery—
- infraorbital, 524
- innominate, 508
- intercostal, 571
  - anterior, 552
  - superior, 552
- internal auditory, 838
  - carotid, 528
  - iliac, 584
  - mammary, 551
  - maxillary, 522
  - plantar, 610
- interosseous ulnar, 568
  - landmarks of, 1059
  - of foot, 607
    - landmarks of, 1059
  - of hand, 565, 568
- intestini tenuis, 577
- labial inferior, 518
- lachrymal, 531
- laryngeal superior, 515
  - inferior, 550
- lateral sacral, 591
  - spinal, 547
- lateralis nasi, 518
- [lenticulo-striate, 536]
- lingual, 515
- long ciliary, 532
  - thoracic, 556
- lumbar, 581
- malleolar, 605
- mammary internal, 551
  - landmarks of, 1035
- masseteric, 524
- maxillary internal, 521
- median, of forearm, 568
  - of spinal cord, 549
- mediastinal, 552
  - posterior, 571
- [medullary, 539]
- meningeal anterior, 530
  - middle, 523
    - landmarks of, 1027
  - small, 523
    - from occipital, 519
    - from pharyngeal, 520
    - from vertebral, 548
- mesenteric inferior, 579
  - superior, 577
- metacarpal, 564
- metatarsal, 606
- [middle and internal frontal, 537]
  - [cerebral, 534, 537]
  - sacral, 582
- musculo-phrenic, 552
- mylo-hyoid, 523
- nasal, 525
  - of ophthalmic, 532
  - of septum, 518
- nutrient of humerus, 561
  - femur, 599
  - fibula, 609
  - radius, 568
  - tibia, 609
  - ulna, 567
- obturator, 587
- occipital, 519
- œsophageal, 571
- [of brain, 534]
- [of Broca's convolution, 538, 540]
- [of cerebral hemorrhage, 536]
- [of the ascending frontal convolution, 538]

Arteries or artery—
- [of the ascending parietal convolution, 538]
- [of the medulla oblongata, 548]
- [of the spinal cord, 547]
- ophthalmic, 530
- orbital, 524
- ovarian, 581
- palatine, ascending, 517
  - descending, 524
  - posterior, 524
  - of pharyngeal, 520
  - palmar arch, superficial, 566
    - deep, 563
- palmar interossei, 565
- palpebral, 532
- pancreatic, 577
- pancreatico-duodenalis, 576
  - inferior, 577
- perforating, of hand, 565
  - of thigh, 599
  - of foot, 610
  - of intercostal, 552
- plantar, 609
- pericardiac, 552, 570
- perineal, superficial, 589
  - transverse, 589
- peroneal, 608
  - anterior, 609
- pharyngea ascendens, 520
- phrenic, 581
- pollicis, 564
- popliteal, 599
  - landmarks of, 1053
- posterior auricular, 520
  - [cerebral, 538, 549]
  - communicating, 534
  - meningeal, from vertebral, 548
  - palatine, 524
- princeps cervicis, 519
- profunda of arm, inferior, 561
  - superior, 561
  - cervicis, 552
  - femoris, 598
- pterygoid, 524
- pterygo-palatine, 524
- pudic, deep external, 598
  - landmarks of, 1051
  - superficial external, 598
    - internal, 588
- pulmonary, 502, 938
- pyloric inferior, 575
  - of hepatic, 575
- radial, 562
  - landmarks of, 1060
- radialis indicis, 564
- ranine, 516
- recurrent interosseous, 568
  - radial, 564
  - ulnar, anterior, 567
    - posterior, 567
  - tibial, 605
- renal, 580
- sacral lateral, 591
  - middle, 582
- scapular, posterior, 551
- sciatic, 590
- short ciliary, 532
- sigmoid, 579
- spermatic, 581, 968
- spheno-palatine, 525
- spinal, anterior, 549
  - lateral, 549
  - posterior, 549

Arteries or artery—
- spinal, median, 549
- splenic, 576
- sterno-mastoid, 519
- stylo-mastoid, 520
- subclavian, 542
  - landmarks of, 1033
- sublingual, 515
- submaxillary, 518
- submental, 518
- subscapular, 556
- superficial cervical, 551
  - circumflex iliac, 593
  - [femoral, 594]
  - perineal, 589
  - palmar arch, 566
- superficialis volæ, 564
- superior cerebellar, 549
  - epigastric, 552
  - hemorrhoidal, 580
  - intercostal, 552
  - laryngeal, 515
  - mesenteric, 577
  - profunda, 561
  - thoracic, 556
  - thyroid, 514
- supraorbital, 531
- suprarenal, 580
- suprascapular, 550
- sural, 602
- [Sylvian, 534, 537]
- tarsal, 606
- temporal, 521
  - anterior, 521
  - deep, 524
  - middle, 521
  - posterior, 521
- [terminal, 535, 539]
- thoracic, acromial, 556
  - alar, 556
  - aorta, 569
  - long, 556
  - superior, 556
- thyroid axis, 550
- thyroid inferior, 550
  - superior, 514
- thyroidea ima, 508, 941
- tibial anterior, 603
  - landmarks of, 1054
  - posterior, 607
    - landmarks of, 1055
  - recurrent, 605
- tonsillar, 518
  - transverse facial, 521
- transversalis colli, 551
- tympanic, from internal carotid, 530
  - from internal maxillary, 523
- ulnar, 566
  - landmarks of, 1061
  - recurrent anterior, 567
  - posterior, 567
  - umbilical in fœtus, 586, 916
  - uterine, 586
- [uncinate, 539]
- vaginal, 586
- vasa aberrantia of arm, 560
  - brevia, 577
  - intestini tenuis, 577
- vertebral, 546
- vesical inferior, 586
  - middle, 586
  - superior, 586
    - vestibular, 838
- Vidian, 524

Arteriolæ rectæ, 950
Arthrodia, 298
Articular arteries (knee), from popliteal, 603
  cartilage, 141
  lamella of bone, 296
  processes of vertebræ, 143
Articulations in general, 296
    different kinds of, 297
  acromio-clavicular, 324
  ankle, 354
  astragalo-calcanean, 358
  astragalo-scaphoid, 360
  atlo-axoid, 306
  calcaneo-astragaloid, 358
  calcaneo-cuboid, 359
  calcaneo-scaphoid, 359
  carpo-metacarpal, 338
  carpal, 336
  classification of, 297
  coccygeal, 321
  chondro-sternal, 315
  costo-transverse, 315
  costo-vertebral, 313
  elbow, 329
  femoro-tibial, 347
  hip, 342
  immovable, 297
  knee, 346
  metacarpal, 340
  metacarpo-phalangeal, 340
  metatarso-phalangeal, 361
  metatarsal, 361
  mixed, 298
  movable, 298
  movements of, 300
  occipito-atloid, 309
  occipito-axoid, 309
  pelvis, 320
  pelvis with spine, 318
  phalanges, 341
  pubic, 321
  radio-carpal, 335
  radio-ulnar, inferior, 333
    middle, 333
    superior, 333
  sacro-coccygeal, 320
  sacro-iliac, 319
  sacro-sciatic, 320
  sacro-vertebral, 318
  scapulo-clavicular, 324
  scapulo-humeral, 326
  shoulder, 326
  sterno-clavicular, 322
    landmarks of, 1034
    of sternum, 317
  tarso-metatarsal, 360
  tarsal, 357
  temporo-maxillary, 310
  tibio-fibular, inferior, 354
    middle, 353
    superior, 353
    of tympanic bones, 829
  vertebral column, 301
  wrist, 335
Arytæno-epiglottideus, superior, 926
  inferior, 926
Arytæno-epiglottidean folds, 923
Arytenoid cartilages, 920
  glands, 927
  muscle, 925
Ascending colon, 883
  palatine artery, 517
  pharyngeal artery, 520
[Asterion, 685]
Astragalus, 288
  development of, 293
Atlas, 144
  development of, 151
Atlo-axoid articulation, 306
Atrabiliary capsules, 952
Attollens aurem muscle, 369
Attrahens aurem muscle, 369
Auditory artery, 838
    veins, 838
  canal, 825
  meatus, external, 173
    internal, 174
  nerve, 736, 838
  process, 173
  vesicle, 122
Auricle of ear, 823
  cartilage of, 823
  ligaments of, 823
  of heart, left, 911
  appendix of, 907, 911
  sinus of, 911
  right, 907
    openings in, 908
    valves in, 908
  sinus of, 907
  septum of, 906, 912
Auricular artery, posterior, 520
    anterior, 521
  fissure, 174, 210
  lymphatic glands, 640
  nerve of vagus, 740
  posterior from facial, 735
  surface of sacrum, 154
  veins, anterior, 612
    posterior, 613
Auricularis anterior muscle, 369
  posterior, 369
  superior, 369
  magnus nerve, 750
Auriculo-temporal nerve, 728
Auriculo-ventricular groove of heart, 907
  opening, left, 912
    right, 909
Axes of the pelvis, 270
Axilla, 553
  dissection of, 426
  landmarks of, 1057
Axillary artery, 554
  landmarks of, 1058
  peculiarities, 555
  surgical anatomy of, 555
  branches of, 556
  lymphatic glands, 643
  space, 553
  vein, 625
Axis, or second vertebra, 145
  development of, 152
  cerebro-spinal, 652
  cœliac, 574
  thyroid, 550
Axis-cylinder of nerve-tubes, 70
Azygos artery, articular, 602
  veins, 627
  uvulæ muscle, 395

B.

Bacillary layer of retina, 815
Back, furrows of, 1037
  muscles of, first layer, 399
    second layer, 403
    third layer, 404
Back—
  muscles of fourth layer, 405
    fifth layer, 409
Ball-and-socket joint. See *Enarthrodia.*
Bartholine, duct of, 854
  glands of, 978
Base of brain, 687
  of skull, 205
    external surface, 208
    internal surface, 205
Basement membranes, 49
Basilar artery, 547
  membrane of cochlea, 835
  process, 162
  suture, 203
Basilic vein, 624
  median, 624
Basio-glossus muscle, 390, 391
[Basion, 685]
Basis vertebrarum venæ, 629
Bauhin, valve of, 882
Beak of corpus callosum, 692
Beaunis et Bouchard, Table of Development of Fœtus from, 139
[Bed-sores and sacral canal, 154]
Bend of elbow, 559
Biceps muscle of arm, 436
  of thigh, 477
[Bichat, fissure of, 675, 697]
Bicipital groove, 238
  tuberosity, 248
Bicuspid teeth, 841
Biliary ducts, 895, 896
  structure of, 897
Biventer cervicis muscle, 408
Bladder, 955
  ligaments of, 957
  trigone of, 958
  vessels and nerves of, 959
  female, 978
Blastodermic membrane, 102
Blood, general anatomy of:
  circulation of, in adult, 907
    in fœtus, 915
  crystals, 39
  gases of, 39
  globules, 36
  [third corpuscle of, 38]
[Blood-plaques, 38]
[Blood-vessels of the medulla oblongata, 548]
  [of the spinal cord, 547]
Bochdalek, ganglion of, 725
  on musculus triticeo-glossus, 926, *note*
Body of a tooth, 841
  of a vertebra, 143
Bone, general anatomy of, 54
  animal constituent of, 58
  apophysis of, 142
  articular lamella of, 296
  canaliculi of, 56
  cancellous tissue of, 54
  cells, 58
  chemical analysis of, 58
  compact tissue of, 54
  diploë of, 141
  development of, 59
  earthy constituent of, 58
  eminences and depressions of, 142
  epiphysis of, 142
  growth of, 62

Bone—
  Haversian canals of, 56
    systems of, 56
  inorganic constituent of, 59
  lacunæ of, 57
  lamellæ of, 57
  lymphatics of, 55
  marrow of, 54
  medullary canal of, 54, 141
  membrane of, 54
  microscopic appearances, 55
  nerves of, 55
  organic constituent of, 58
  ossification of, 59
  ossific centres, number of, 63
  periosteum of, 54
  spongy tissue of, 141
  vessels of, 55
Bones, forms of—viz. long, short, flat, mixed, irregular, 141
  number of, in the body, 141
Bones or bone, descriptive anatomy of, 141
  astragalus, 288
  atlas, 144
  axis, 145
  calcaneum, 284
  carpal, 250
  clavicle, 229
  coccyx, 157
  cranial, 160
  cuboid, 287
  cuneiform of carpus, 252
    of tarsus, 289, 290
  ear, 828
  ethmoid, 181
  facial, 185
  femur, 270
  fibula, 281
  frontal, 166
  hand, 250
  humerus, 237
  hyoid, 219
  ilium, 261
  incus, 829
  inferior maxillary, 197
    turbinated, 196
  innominate, 260
  ischium, 263
  lachrymal, 191
  lesser lachrymal, 191
  lingual, 219
  magnum, 254
  malar, 192
  malleus, 829
  maxillary, inferior, 197
    superior, 186
  metacarpal, 255
  metatarsal, 291
  nasal, 185
  occipital, 160
  orbicular, 830
  palate, 193
  parietal, 164
  patella, 277
  pelvic, 267
  phalanges of foot, 292
    of hand, 257
  pisiform, 252
  pubic, 264
  radius, 248
  ribs, 224
  sacrum, 152
  scaphoid of carpus, 250
    of tarsus, 289
Bones or bone—
  scapula, 233
  semilunar, 252
  sesamoid, 294
  sphenoid, 176
  sphenoidal, spongy, 180
  stapes, 830
  sternum, 222
  superior maxillary, 186
  tarsal, 284
  temporal, 170
  tibia, 278
  trapezium, 252
  trapezoid, 254
  triquetral, 184
  turbinate, inferior, 196
    middle, 182
    superior, 183
  tympanic, 175
  ulna, 243
  unciform, 255
  vertebra prominens, 147
  vertebræ, cervical, 143
    dorsal, 147
    lumbar, 149
  vomer, 197
  Wormian, 184
Bone, articular lamella of, 296
Bowman's capsule, 946
Brachia of optic lobes, 702
Brachial artery, 558
    branches of, 561
    peculiarities of, 559
    surgical anatomy of, 560
  lymphatic glands, 643
  plexus, 752
  region, posterior, muscles of, 446, 447
    anterior, 440, 443
  veins, 625
Brachialis anticus muscle, 437
Brain, base of, 687
  [blood-vessels of, 534]
  convolutions of, 672
  development of, 118
  dura mater of, 661
  general anatomy of, 72
  interior of, 690
  landmarks of, 1037
  lobes of, 687
  membranes and dissection, 661
  subdivision into parts, 664
  [topography of, 681]
  upper surface of, 672
  weight of, 665
[Brain-centres for motion, 681]
Breasts, 988
[Bregma, 685]
Brim of pelvis, 268
Broad ligaments of uterus, 981
    formation of, 864
[Broca's convolution, 676]
Bronchi, right and left, 927
  septum of, 928
    in lung, 936
Bronchial arteries, 571, 939
  lymphatic glands, 650
  septum, 928
  tubes. See *Bronchi.*
  veins, 628, 939
Brunner's glands, 879
Bubonocele, 998
Buccal arteries, 524
  cavity, development of, 131
  glands, 840
Buccal lymphatic glands, 640
  nerve of facial, 736
    of inferior maxillary, 728
  veins, 614
Buccinator muscle, 377
Bulb, artery of, 589
  of corpus cavernosum, 965
  of corpus spongiosum, 966
  olfactory, 688, 716
Bulbi vestibuli, 978
Bulbous portion of the urethra, 960
Bulbs of the fornix, 689
Burdach's column, 658
Burns, ligament of, 1003, *note*
[Bursa of heel, 357]
  [prepatellar, 350]
  [subpatellar, 350]
Bursæ mucosæ, 297
Bursæ of shoulder, 327, 328
  carpal, 1060
  digital, 1062
  of ham, 601
  of olecranon, 1058
  of wrist, 1060
  plantar, 1056
  popliteal, 1052
  prepatellar, 1052
Bursal synovial membranes, 297
Buttocks, folds of, 1050
  landmarks of, 1051

C.

Cæcum, 882
  [surgical anatomy of, 882]
Calamus scriptorius, 713
Calcanean arteries, internal, 609
Calcaneo-astragaloid ligaments, 358
Calcaneo-cuboid ligaments, 359
Calcaneo-scaphoid ligaments, 359
Calcaneum, 284
Calcarine fissure, 678
Calices of kidney, 945
Callender, Mr., researches on femoral hernia, 1003
Calloso-marginal fissure, 678
Camper's ligament. See *Triangular Ligament of Urethra.*
Canals or canal, accessory palatine, 193
  alimentary, 839
  anterior dental, 187
    palatine, 189
    for Arnold's nerve, 174
  auditory, 825
  carotid, 173, 174
  central, of modiolus, 833
    for chorda tympani, 171, 826
    of cochlea, 833
  crural, 1006
  dental posterior, 187
  ethmoidal, 169
  femoral, 1006
  Haversian, of bone, 56
  of Huguier, 171
  incisive, 208
  inferior dental, 199
  infraorbital, 186
  inguinal, 996
    landmarks of, 1044
  for Jacobson's (tympanic) nerve, 174

Canals or canal—
  lachrymal, 822
  naso-palatine, 189
  of Nuck, 975, 988
  of Petit, 818
  palatine, anterior, 189
    posterior, 187
  pterygo-palatine, 178
  sacral, 155
  of Schlemm, 811
  spermatic, 996
  of spinal cord, 120
  spiral, of cochlea, 833
  of Stilling, 817
  of modiolus, 833
  semicircular, 832
  for tensor tympani, 175, 809
  temporo-malar, 193
  vertebral, 160
  Vidian, 180
  of Wirsung, 898
Canaliculi of bone, 58
  of eyelids, 822
Canalis centralis modioli, 833
  reuniens, 837
  spiralis modioli, 834
Cancellous tissue of bone, 54, 141
Canine eminence, 186
  fossa, 186
  teeth, 841
Canthi of eyelids, 814
Capillaries, 81
Capitellum of humerus, 241
Capsular ligament of hip, 342
    of knee, 348
    of shoulder, 326
    of thumb, 338
    of vertebræ, 304
Capsule, external, of brain, 694
  internal, of brain, 693
  in fœtus, 122
  of Glisson, 892
  of kidney, 945
  of lens, 817
  of Tenon, 805
Capsules, suprarenal, 953
Caput cornu posterioris, 658
  gallinaginis, 959
Cardiac lymphatics, 650
  nerves, 789, 790
    from pneumogastric, 741
  plexus of nerves, deep, 792
      superficial, 793
  veins, 636
Cardinal veins, fœtal, 128
Carotid artery, common, 509
      branches of (occasional), 511
      peculiarities of, 511
      surgical anatomy of, 511
    external, 512
      branches of, 514
      surgical anatomy of, 515
    internal, 528
      branches of, 530
      peculiarities of, 530
      surgical anatomy, 530
  branch of Vidian, 727
  canal, 174
  ganglion, 789
  groove, 177
  plexus, 789
  triangle, inferior, 526
    superior, 526
Carpal arteries, from radial, 564
    from ulnar, 569
  ligaments, 336
Carpo-metacarpal articulations, 338
Carpus, 250
  development of, 259
  articulations of, 336
Cartilage, general anatomy of, 50
  articular, 51
  cellular, 50
  fibrous, 53
  hyaline, 51
  intercellular substance of, 51
  reticular, 53
  temporary, 52
    descriptive anatomy of:
  arytenoid, 920
  of auricle, 823
  of bronchi, 937
  costal, 52, 228
  cricoid, 920
  cuneiform, 921
  of ear, 823, 825, 829
  ensiform, 222
  of epiglottis, 921
  of larynx, 919
  of the nose, 802
  of the pinna, 823
  of Santorini, 921
  semilunar of knee, 349
  of septum of nose, 803
  tarsal, 820
  thyroid, 919
  of trachea, 929
  of Wrisberg, 921
  xiphoid, 222
Cartilago triticea, 922
Caruncula lachrymalis, 821
  mammillaris, 716
Carunculæ myrtiformes, 978
Cauda equina, 775
Cava, inferior, 633
    peculiarities, 633
  superior, 627
Cavernous body, artery of, 589
  groove, 177
  nerves of penis, 797
  plexus, 789
  sinus, 621
    nerves in, 732
Cavity, cotyloid, 265
  glenoid, 236
  of pelvis, 268
  sigmoid, 245
Cells, 40
  of bone, 58
  ethmoidal, 182
  mastoid, 172
Cellular tissue, lymphoid, 48
    mucoid, 48
    retiform, 48
Cement of teeth, 845
    formation of, 848
Central canal of cord, 656
  gray nucleus, 659
  lobe of cerebrum, 677
Centres of ossification, 63
Centrum ovale, majus, 691
    minus, 690
Cephalic vein, 624
    median, 624
Cerebellar arteries, anterior, 549
    superior, 549
Cerebellar arteries—
    inferior, 549
  column, 658
  veins, 619
Cerebelli incisura, anterior, 709
    posterior, 709
Cerebellum, 708
  corpus dentatum of, 710
  hemispheres of, 709
  laminæ of, 711
  lobes of, 710
  lobulus centralis of, 709
  median lobe of, 709
  peduncles of, 711
  structure of, 710
  under surface of, 709
  upper surface of, 708
  the valley of, 709
  ventricle of, 712
  weight of, 708
Cerebral arteries, 534
    anterior, 534
    middle, 534
    posterior, 549
  convolutions, 672
  [localization and topography, 681]
  lymphatics, 641
  veins, 618
  ventricles, 690
Cerebro-spinal axis, 653
  fluid, 664
  nerves, 69
Cerebrum, 664, 672
  base of, 687
  commissures of, 707
  convolutions of, 672
  crura of, 690
  fibres of, 706
  fissures of, 675
  general arrangement of its parts, 690
  gray matter of, 72, 703
  hemispheres of, 672
  interior of, 690
  labia of, 691
  lobes of, 687
  peduncles of, 689
  structure of, 703
  sulci, 673
  under surface, 687
  upper surface, 672
  ventricles of, 692, 700
Ceruminous glands, 826
Cervical artery, ascending, 550
    superficial, 551
  princeps, 519
  profunda, 552
Cervical fascia, 382, 383
  ganglion, inferior, 791
    middle, 790
    superior, 786
  lymphatic glands, deep, 642
      superficial, 642
  nerves, 746
    anterior divisions of, 749
    posterior divisions of 747
    roots of, 642
  plexus, 749
    deep branches of, 751
    posterior, 747
    superficial branches of, 750
  veins, ascending, 617
    deep, 617
  vertebræ, 143

Cervicalis ascendens muscle, 406
Cervico-facial nerve, 736
Cervix cornu posterioris, 659
  uteri, 983
Chambers of the eye, 816
Check ligaments, 310
Cheek, muscles of, 377
Cheeks, structure of, 840
Chest, landmarks of, 1034
  muscles of front, 427
    of side, 430
Chiasma, or optic commissure, 717
Chondro-glossus muscle, 390, 391
Chondro-sternal ligaments, 315
Chondro-xiphoid ligament, 317
Chorda dorsalis, 106, 114
  tympani nerve, 734, 831
Chordæ tendineæ, of right ventricle, 910
    of left ventricle, 912
    vocales, 923, 924
    Willisii, 619
Chorion, 110
Choroidal fissure, 121
Choroid arteries, anterior, 533
    posterior, 549
  coat of eye, 809
  plexus of lateral ventricle, 694
    of fourth ventricle, 714
    of third ventricle, 699
  veins of brain, 619
Chyle, 40
Chyli receptaculum, 638
Cilia, or eyelashes, 821
Ciliary arteries, 532, 819
  ganglion, 723
  ligament, 812
  muscle, 812
  nerves, long, 722
    short, 722
  processes of eye, 810
Circle of Willis, 550
Circular sinus, 621
Circulation of blood in adult, 907
    in fœtus, 915
Circumduction, 300
Circumferential fibro-cartilage, 53
Circumflex artery of arm, anterior, 557
      posterior, 557
    of thigh, external, 598
      internal, 599
  iliac artery, 593
      superficial, 598
    vein, 631
      superficial, 630
    nerve, 756
Circumflexus palati muscle, 394
Claustrum, 694
Clavicle, 229
  development of, 232
  fracture of, 457
  landmarks of, 1056
  [relation of, to arm and trunk, 229]
Clavicular nerves, 751
Cleft palate, 397
Clinoid processes, anterior, 179
    middle, 176
    posterior, 177
Clitoris, 977
  frænum of, 976
  lymphatics of, 648
Clitoris—
  muscles of, 976, 1015
  prepuce of, 976
Clivus Blumenbachii, 177
Cloaca, 137
Coccygeal artery, 590
  gland, 582
  nerves, 775
Coccygeus muscle, 1018
Coccyx, 157
  development of, 158
Cochlea, 833
  aqueduct of, 174
  arteries of, 838
  central axis of, 833
  cupola of, 833
  denticulate lamina of, 835
  infundibulum of, 833
  lamina spiralis of, 834
  nerves of, 838
  scalæ of, 834
  spiral canal of, 833
  veins of, 838
Cochlear artery, 838
  nerve, 838
Cochleariform process, 175, 828
Cochlearis muscle, 835
Cœliac axis, 574
  plexus, 794
Colica dextra artery, 579
  media, 579
  sinistra, 579
Collateral circulation. See *Surgical Anatomy of each Artery.*
  fibres of cerebrum, 707
  fissure, 679
Collecting tubes of kidney, 948
Colles's fracture, 461
Colon, 883
Colostrum corpuscles, 989
Colotomy, landmarks for, 1046
Columella cochleæ, 833
Columnæ carneæ of left ventricle, 912
    of right ventricle, 910
  papillares, 910, 913
Columna nasi, 802
Column of Goll, 658
  posterior vesicular, of spinal cord, 660
Columns of abdominal ring, 993
  of medulla oblongata, 667
  of spinal cord, 655
  of vagina, 980
Comes nervi ischiadici artery, 590
  phrenici artery, 551
Commissura, simplex, of cerebellum, 709
  brevis, of cerebellum, 710
Commissures of flocculus, 710
  optic, 717
  of brain, anterior, 701
    middle or soft, 701
    posterior, 701
  of spinal cord, gray, 656
      white, 656
Common ligaments of vertebræ, 302, 303
Communicans noni nerve, 752
  peronei, 782
Communicating artery of brain, anterior, 534
      posterior, 534
    from dorsalis pedis, 606
Communicating artery from ulnar, 569
Compact tissue of bone, 54, 141
Complexus muscle, 408
Compressor narium minor, 374
  nasi, 374
  sacculi laryngis, 926
  urethræ, 1017
Conarium, 702
Concentric corpuscles of thymus, 942
Conception, where effected, 101
Concha, 823
Condyles of bones. See *Bones.*
Condyloid foramina, 162
  fossæ, 162
  process, 200
  veins, posterior, 617, 620
Congenital fissures in cranium, 184
  hernia, 999
Conglobate glands, 638
Coni vasculosi, 971
Conjoined tendon of internal oblique and transversalis, 414, 994
Conjunctiva, 821
Connecting fibro-cartilages, 53
Connective tissue, 45
    development of, 48
Conoid ligament, 324
Constrictor inferior muscle, 392
    medius, 393
    superior, 393
  isthmi faucium, 396
  urethræ, 1017
Contractile-fibre cells, 67
Conus arteriosus, 909
[Convolution, Broca's, 676]
  of corpus callosum, 679
Convolutions of cerebrum, structure of, 703
Coraco-acromial ligament, 326
Coraco-brachialis muscle, 436
Coraco-clavicular ligament, 324
Coraco-humeral ligament, 327
Coracoid ligament, 326
  process, 236
    fracture of, 458
Cord, spermatic, 968
  umbilical, 113
  [ventricle of, 656, 661, 667]
Cordiform tendon of diaphragm, 424
Corium of skin, 90
  of tongue, 799
Cornea, 807
Corneal corpuscles, 808
  spaces, 808
Cornicula laryngis, 921
Cornu Ammonis, 696
Cornua of the coccyx, 157
  of hyoid bone, 219
  of the sacrum, 154
  of thyroid cartilage, 920
Corona glandis, 964
  radiata, 706
Coronal suture, 203
Coronaria ventriculi artery, 574
Coronary arteries of lip, 518
    of heart, 507
    peculiarities, 508
  ligament of liver, 890
  ligaments of knee, 350
  plexus, anterior, 793

Coronary plexus—
  posterior, 793
  sinus, 636
    opening of, 908
  valve, 908
Coronoid depression, 241
  process of jaw, 200
    of ulna, 243
      fracture of, 459
Corpora albicantia, 689
  Arantii, 911, 912
  mammillaria, 689
  cavernosa penis, 964
    crura of, 964
  cavernosa clitoridis, 977
  geniculata, 700, 706
  olivaria, 666
  pyramidalia, 666
  quadrigemina, 702
  restiformia, 666
  striata, 693
Corpus callosum, 691, 707
    convolution of, 679
    genu of, 691
    peduncles of, 692
    ventricle of, 691
  dentatum of cerebellum, 710
    of olivary body, 667
  fimbriatum, 695
  Highmorianum, 970
  luteum, 987
  spongiosum, 966
Corpus cavernosum, artery of, 589
  dentatum, 667
Corpuscles, blood-, 36
    development of, 125
  Malpighian, of kidney, 946
    of spleen, 902
Corrugator supercilii muscle, 370
Cortex of cerebrum, 703
  of cerebellum, 711
Corti, membrane of, 835
  organ of, 835
  rods of, 836
[Cortical arterial system of brain, 534, 537]
  arches, 946
  columns, 946
  substance of brain, 703
    of kidney, 946
    of suprarenal capsules, 953
    of teeth, 845
Costal cartilages, 52, 228
  connection with ribs, 317
Costo-chondral articulation, 317
Costo-clavicular ligament, 323
Costo-colic ligament, 869
Costo-coracoid fascia, 429
Costo-transverse articulations, 314
Costo-vertebral articulations, 312
Costal-vertebral ligaments, 313
Chondro-xiphoid ligaments, 317
Cotunnius, nerve of, 726
Cotyloid cavity, 265
  ligament, 344
  notch, 265
Coverings of direct inguinal hernia, 999
  of femoral hernia, 1011
  of oblique, 998
  of testis, 969
Cowper's glands, 963, 1017
Cranial bones, 160
    articulations of, 2[illegible]3
  fossæ, 205
Cranial nerves, 715
    first pair, 716
    second, 717
    third, 718
    fourth, 719
    fifth, 719
    sixth, 731
    seventh, 732
    eighth, 736
    ninth, 736
    tenth, 738
    eleventh, 741
    twelfth, 742
    development of, 120
  sutures, 202
Cranium, 160
  congenital fissures in, 184
  development of, 183
  lymphatics of, 641
Cremaster muscle, 994
    formation of, 995
Cremasteric artery, 593
  fascia, 995
Crescents of Gianuzzi, 855
Crest, frontal, 168
  of ilium, 261
  lachrymal, 191
  nasal, 185
  occipital, 160
    internal, 163
  turbinated, of palate, 194
    of the superior maxillary, 187
    of pubes, 265
    of tibia, 280
Cribriform fascia, 1001
  plate of ethmoid, 181
Crico-arytænoideus lateralis muscle, 925
  posticus muscle, 924
Crico-thyroid artery, 515
  membrane, 922
  muscle, 924
Cricoid cartilage, 920
    landmarks of, 1032
Crista galli, 181, 206
  pubis, 265
  vestibuli, 832
Crochet of uncinate gyrus, 680, 708
Cross pyramidal fasciculus, 658
Crown of a tooth, 841
Crucial anastomosis, 599
  ligaments of knee, 349
Crura cerebri, 689
  cerebelli, 710
  of clitoris, 977
  of corpora cavernosa, 964
  of diaphragm, 424
  of fornix, 699
Crural arch, 993, 1004
    deep, 1005
  canal, 1006
  nerve, anterior, 773
  ring, 1007
  sheath, 1005
  septum, 1008
Crureus muscle, 468
Crus penis, 964
Crusta petrosa of teeth, 845
    of crus cerebri, 690, 707
Crypts of Lieberkühn, 879
Crystalline lens, 817
Crystals, blood-, 39
Cuboid bone, 287
Cuneate lobe, 680
  fasciculus, 658
Cuneiform bone, hand, 252
    foot, external, 290
      internal, 289
      middle, 290
  cartilages, 921
Cupola of cochlea, 833
Curling, Mr., on the descent of the testes, 974
Curvatures of the spine, 159
Cuspidate teeth, 841
Cutaneous branches of accessory obturator, 773
    of anterior tibial nerve, 782
    of cervical plexus, 750
    of circumflex, 756
    of dorsal nerve of penis, 77
    of dorsal nerves, 764
    of external popliteal, 782
      internal, 780
    of inferior hemorrhoidal nerve, 778
    of ilio-hypogastric, 770
    of ilio-inguinal, 770
    of intercostal nerves, 766
    of lesser sciatic nerve, 779
    of lumbar nerves, 767
    of median, 759
    of musculo-spiral, 762
    of ulnar nerve, 761
    of arm, musculo-cutaneous, 756
      internal, 756
      lesser internal, 757
    of buttock and thigh, 779
    of inguinal region, 1001
    of ischio-rectal region, 1011
      from obturator, 771
    of thigh, external, 770
      internal, 774
      middle, 773
    of patella, 774
    of perineal nerve, 779
      plantar nerve, 781
    of posterior tibial, 781
    of radial, 763
    of sacral nerves, 775
    of ulnar, 761
Cuticle of skin, 89
Cuticula dentis, 847
Cutis vera, 90
Cuvier, ducts of, 129
Cystic artery, 676
  duct, 896
    valve of, 896
  plexus of nerves, 794
  veins, 636

D.

Dartos, 967
Decussation of optic nerves, 717
  of pyramids, 666
Decidua, 111
  serotina, 112
  reflexa, 112
  vera, 112
Deciduous teeth, 840
Deep crural arch, 1005
  palmar arch, 563
  perineal fascia, 1015
Deferent artery, 586
Deglutition, actions of, 394, 395
Deltoid aponeurosis, 432

Deltoid muscle, 432
Demilunes of Heidenhain, 855
Demours, membrane of, 807
Dens sapientiæ, 843
Dental artery, inferior, 523
    posterior, 524
  canal, anterior, 187
    inferior, 199
    posterior, 187
  groove, 846, 848
  nerves, anterior, 725
    inferior, 729
    middle, 725
    posterior, 724
  ridges, 846
  sacs, 848
  tubuli, 844
  vein, inferior, 614
Dentate fissure, 679
Denticulate lamina of cochlea, 834
Dentinal sac, 847
Dentine, 844
  formation of, 847
Depressions of Pacchionian bodies, 165
Depressor alæ nasi, 374
  anguli oris, 376
  epiglottidis, 926
  labii inferioris, 396
Derma, or true skin, 90
Descemet, membrane of, 807
Descendens noni nerve, 743
Descending aorta, 569
  colon, 883
Descent of testicle, 974
Development of atlas, 151
  axis, 152
  alimentary canal and its appendages, 130
  arteries, 126
  bone, 59
  carpus, 259
  clavicle, 232
  coccyx, 158
  cranium, 115, 183
  ear, 122
  ethmoid, 183
  eye, 121
  face, 115
  femur, 276
  fibula, 283
  foot, 294
  frontal bone, 169
  genital organs, 135
  hand, 259
  heart, 124
  humerus, 241
  hyoid bone, 220
  inferior turbinated bone, 196
  lachrymal bone, 192
  lens, 121
  lower jaw, 201
  lumbar vertebræ, 152
  malar bone, 193
  mammæ, 123
  metacarpus, 259
  metatarsus, 294
  muscles, 124
  nasal bone, 185
  nervous centres, 118
  nose, 117
  occipital bone, 164
  os innominatum, 266
Development of—
  palate, 117
  palate bone, 195
  parietal bone, 166
  patella, 278
  permanent teeth, 848
  phalanges of hand, 259
    of foot, 294
  radius, 249
  ribs, 228
  sacrum, 156
  scapula, 236
  seventh cervical, 152
  skin, 123
  sphenoid, 180
  spine, 114
  sternum, 223
  superior maxillary bone, 190
  tarsus, 294
  temporary teeth, 846
  temporal bone, 175
  tibia, 281
  ulna, 247
  veins, 128
  vertebræ, 150
  vomer, 197
  Wormian, 184
Development of Organs, Chronological Table of, 139
Diameters of pelvis, 268
Diaphragm, 422
  development of, 132
  lymphatics of, 650
Diaphysis, 63, [141]
Diarthrosis, 298
  rotatoria, 300
Digastric muscle, 388
  fossa, 172
  lobe of cerebellum, 710
  nerve, from facial, 734
Digestion, organs of, 839
Digital arteries from ulnar, 569
    from plantar, 610
  cavity of lateral ventricle, 692
  fossa, 271
  nerves, from median, 759
    from radial, 763
    from ulnar, 762
    of foot, 782
Dilatator naris, anterior, 374
  posterior, 374
Diploë, 142
  veins of, 617
Direct inguinal hernia, 999
  course of, 999
  coverings of, 999
  incomplete, 1000
  pyramidal fasciculus, 658
Discus proligerus, 986
Disks, blood, 36
  development of, 125
Dissection of abdominal muscles, 412
  arch of aorta, 501
  arm, 435
  auricular region, 369
  axilla, 426
  back, 399
  epicranial region, 366
  eye, 808
  femoral hernia, 1000
  face, 369
  foot, 488
  forearm, 439
  gluteal region, 472
Dissection of—
  hand, 449
  heart, left auricle, 911
    left ventricle, 912
    right auricle, 907
    right ventricle, 909
  hernia, femoral, 1000
    inguinal, 991
  iliac region, 462
  inferior maxillary region, 376
  infrahyoid region, 386
  inguinal hernia, 991
  intermaxillary region, 377
  ischio-rectal region, 1010
  leg, 479
  lingual region, 390
  neck, 382
  orbit, 371
  palatal region, 394
  palm of hand, 449
  palpebral region, 369
  pancreas, 897
  pectoral region, 426
  perineum, 1010, 1016
  pharynx, 392
  pterygoid muscles, 380
  radial region, 444
  scalp, 366
  sole of foot, 488
  spinal cord and membranes, 652
  suprahyoid region, 388
  temporal muscle, 379
  thigh, front of, 465
    back of, 477
    inner side of, 470
Dorsal artery of penis, 589
  nerve of penis, 779
  nerves, 764
    peculiar, 767
  vein of penis, 632
  vertebræ, 147
    peculiar, 149
Dorsales pollicis arteries, 564
Dorsalis hallucis artery, 606
  indicis, 564
  linguæ, 515
  pedis, 605
    branches of, 606
    peculiarities of, 606
    surgical anatomy of, 606
  scapulæ, 556
Dorsi-lumbar nerve, 767
Dorsi-spinal veins, 628
Dorsum of scapula, 233
  ephippii or sellæ, 176
Douglas, pouch of, 981
  semilunar fold of, 418
Ducts or duct, of Bartholine, 854
  biliary, 896
  of Cowper's glands, 964
  of Cuvier, 129
  cystic, 896
  ejaculatory, 973
  of Gartner, 136
  galactophorous, 989
  hepatic, 895, 896
  of kidney, 951
  lactiferous, 989
  of liver, 895
  lymphatic, right, 640
  nasal, 822
    landmarks of, 1029
  of pancreas, 898
  parotid, 853

Ducts or duct of—
Rivini, 854
seminal, 971
Stenson's, 853
thoracic, 639
Wharton's, 853
Ductless glands:
spleen, 899
suprarenal capsule, 953
thyroid, 939
thymus, 941
Ductus arteriosus, 915
how obliterated in fœtus, 918
communis choledochus, 896
pancreaticus minor, 898
Rivini, 854
venosus, 916
how obliterated, 918
Duodenal glands, 879
Duodenum, 874
vessels and nerves of, 876
Dura mater of brain, 661
arteries of, 662
nerves of, 662
processes of, 662
veins of, 662
of cord, 652
peculiarities of, 652

E.

Ear, 823
arteries of, 826, 831, 838
[artistic value of, 825]
auditory canal, 825
cochlea, 835
internal, or labyrinth, 832
membranous labyrinth, 837
muscles of auricle, 824
of tympanum, 830
ossicula of, 829
pinna or auricle of, 823
semicircular canals, 832
tympanum, 826
vestibule, 832
Earthy constituents of bone, 59
Eighth nerve, 736
Ejaculatory ducts, 973
Elastic lamina of cornea, 808
[Elbow, angle at, 242]
anastomoses around, 562
bend of, 559
joint, 329
landmarks of, 1058
vessels and nerves of, 331
[Election, triangle of, 526]
[Electrical points for muscles, 496]
Eleventh nerve, 741
Embryo, first rudiments of, 103
Eminence of aquæductus Fallopii, 827
canine, 186
frontal, 167
ilio-pectineal, 265
nasal, 169
parietal, 164
Eminences and depressions of bones, 142
Eminentia articularis, 171
collateralis, 693
Enamel epithelium, 846, 847
of teeth, 845
formation of, 846
germ, 846
Enamel—
organ, neck of, 846
rods, 845
Enarthrosis, 299
[End-arteries, 535]
End-bulbs of Krause, 75
End plates, motorial, of Kühne, 75
Endocardium, 912
Endolymph, 838
Endothelium, 41
Ensiform appendix, 222
Epencephalon, 119
Ependyma, 692
Epiblast, 102
Epidermis, structure of, 89
development of, 123
Epididymis, 972
development of, 135
Epigastric artery, deep, 593
peculiarities, 593
relation to femoral ring, 1007
with internal ring, 996
superficial, 597
superior, 552
plexus, 793
region, 860
vein, 631
superficial, 630
Epiglottic glands, 927
Epiglottis, 921
Epiphyses, 63, 142
[Epiphysis, 141]
cerebri, 702
Epipteric bone, 184
Epithelium, ciliated, 43
columnar, 43
pavement, 42
spheroidal or glandular, 43. See *Various Organs.*
[Epoöphoron, 136, 985]
Erectile tissue, its structure, 965
of clitoris, 977
of penis, 965
Erector clitoridis, 977, 1015
penis, 1014
spinæ, 406
Eruption of the teeth, 849
Ethmo-sphenoidal suture, 206
Ethmoid bone, 181
articulations of, 183
cribriform plate of, 181
development of, 183
lateral masses of, 182
os planum of, 182
perpendicular plate of, 181
unciform process of, 182
Ethmoidal artery, 532
canal, anterior, 169
posterior, 169
cells, 182
crest, 177
notch, 169, 182
process of inferior turbinated, 196
spine, 176
Ethmoido-frontal suture, 206
Eustachian tube, 175, 828
valve, 908
in fœtal heart, 915
Examination per vaginam, 1063
Expiration, muscles of, 421
[Expression, muscles of, 365]
Extensor coccygis, 410
Extensor brevis digitorum muscle, 489
carpi radialis brevior, 445
longior, 405
carpi ulnaris, 446
communis digitorum (hand), 446
indicis, 448
longus digitorum (foot), 480
minimi digiti, 446
ossis metacarpi pollicis, 447
primi internodii pollicis, 447
proprius pollicis, 480
secundi internodii pollicis, 448
External abdominal ring, 413, 997
annular ligament, 488
capsule, 694
inguinal hernia, 999
orbital foramina, 178
pterygoid plate, 179
spermatic fascia, 414, 993
sphincter, 1014
Eye, 805
appendages of, 819
chambers of, 816
ciliary ligament, 812
muscle, 812
processes of, 810
humors of, 816
aqueous, 816
crystalline lens, 817
vitreous, 817
landmarks of, 1028
membrana pupillaris, 812
choroid, 809
conjunctiva, 821
cornea, 807
hyaloid membrane, 817
iris, 810
Jacob's, 815
retina, 812
sclerotic, 806
pupil of, 810
tunics of, 806
uvea of, 811
vessels of globe of, 819
elastic lamina of cornea, 808
Eyeball, muscles of, 371
nerves of, 819
vessels of, 819
Eyebrows, 819
Eyelashes, 821
Eyelids, 819
cartilages of, 820
Meibomian glands of, 820
muscles of, 370
tarsal ligament of, 820
Eye-teeth, 841

F.

Face, arteries of, 516
bones of, 160, 185
lymphatics of, 641
muscles of, 370
nerves of, 735
veins of, 613
Facial artery, 516
surgical anatomy of, 519
transverse, 521
bones, 185
nerve, 732
vein, 613

Falciform process of fascia lata, 1002
  ligament of liver, 889
Fallopian tubes, 984
    development of, 135 ,
    fimbriated extremity of, 984
    lymphatics of, 648
    nerves of, 988
    structure of, 985
    vessels of, 988
False corpora lutea, 987
  ligaments of bladder, 957
  pelvis, 268
  ribs, 221
Falx cerebelli, 663
  cerebri, 662
Fangs of teeth, 841
Fascia, anal, 1022
Fasciæ, general description of, 364
  of arm, 435
  of cranial region, 366
  cervical, deep, 383
    superficial, 382
  costo-coracoid, 429
  cremasteric, 995
  cribriform, 1001
  deep, 365
  dentata, 697
  dorsal, of foot, 489
  fibro-areolar, its structure, 364
  iliac, 462
  infundibuliform, 996
  intercolumnar, 414, 993
  intercostal, 420
  intermuscular, of arm, 436
    of foot, 488
  ischio-rectal, 1022
  lata, 465, 1001
    falciform process of, 1002
    iliac portion, 466, 1001
    pubic portion, 466, 1002
  of leg, 479
    deep transverse, 484
  lumborum, 416
  obturator, 1022
  of mamma, 426
  of neck, 382
  palmar, 450
  pelvic, 1021
  perineal, deep, 1015
    superficial, 1013
  plantar, 489
    of foot, 488
    of forearm, 439
    of hand, 450
  propria of spermatic cord, 968
    of femoral hernia, 1009
  recto-vesical, 1022
  spermatic, 414, 993
  superficial, 364
    of inguinal region, 991
    of ischio-rectal region, 1010
    of thigh, 465
  temporal, 379
    of thigh, deep, 465
    superficial, 465
    of thorax, 419, 426
  transversalis, 996
  visceral layer of pelvic, 1022
Fasciculi teretes, 667, 713
Fasciculus of Türck, 658
  unciformis, 688
Fat, 50
Fauces, isthmus of, 851
Features as landmarks, 1031
Fecundation of ovum, 101
Female organs of generation:
    bulbi vestibuli, 978
    carunculæ myrtiformes, 978
    clitoris, 977
    development of, 135
    fossa navicularis, 976
    frænulum pudendi, 976
    glands of Bartholine, 978
    hymen, 977
    labia majora, 976
      minora, 976
    nymphæ, 976
    præputium clitoridis, 976
    uterus, 980
    vagina, 979
    vestibule, 977
Femoral artery, 594
      branches of, 597
      peculiarities of, 596
      surgical anatomy of, 596
    deep, 598
  canal, 1006
    variation in size of, according to position of limb, 1008
  hernia, complete, 1009
    coverings of, 1008
    descent of, 1008
    dissection of, 1001
      incomplete, 1009
    seat of stricture, 1009
    surgical anatomy of, 1000
  ligament (Hey's) 1002
  position of surrounding parts, 1007
  region, muscles of anterior, 465
    internal, 470
    posterior, 477
  ring, 1007
  sheath, 1004
  vein, 631
    relation of femoral ring, 1007
Femur, 270
  articulations of, 276
  attachment of muscles to, 276
      below trochanters, 494
  condyles of, 274
  development of, 276
  fracture of, above condyles, 495
  head of, 271
  neck of, 271
    fracture of, 494
  structure of, 275
  trochanters of, 271
Fenestra ovalis, 826
  rotunda, 827, 834
Fenestrated membrane of Henle, 79
Ferrein, pyramids of, 948
Fibræ arciformes, 666, 667
    transversæ, 713
Fibre-cells, contractile, 67
[Fibres of Gerdy, 451]
  of Müller, 815
  of muscle, 362
  of nerves, 69
Fibro-cartilage, 52
  interarticular, 52
    connecting, circumferential, and stratiform, 53
Fibro-cartilages, acromio-clavicular, 324
Fibro-cartilages—
  intercoccygean, 321
  intervertebral, 303
    of knee, 350
    of lower jaw, 311
  pubic, 321
  radio-ulnar, 334
  sacro-coccygean, 321
  sterno-clavicular, 323
Fibrous cartilage, 52
  nervous matter, 69
  rings of heart, 913
  tissue, white, 45
    yellow, 46
Fibro-serous membranes, 95
Fibula, 281
  articulations of, 283
  attachment of muscles to, 283
  development of, 283
  fracture of, with dislocation of the tibia, 495
  landmarks of, 1053
Fibular region, muscles of, 486
Fifth nerve, 719
  ventricle of brain, 697
Fillet, 667
Filum terminale of cord, 654
Fimbriæ of Fallopian tube, 984
First nerve, 716
Fissure, auricular, 175
  for gall-bladder, 891
  for vena cava, 891
  Glaserian, 171, 826
  horizontal, of cerebellum, 710
    of ductus venosus, 891
  longitudinal, of cerebrum, 672, 687
    of liver, 891
  [of Bichat, 675, 697]
  of cerebrum, 697
  of liver, 891
  of lung, 935
  of medulla oblongata, 665
  [of Rolando, 675, 685]
  of spinal cord, 655
  [of Sylvius, 675, 686]
  [parieto-occipital, 676, 687]
  portal, 891
  pterygo-maxillary, 212
  spheno-maxillary, 212
  sphenoidal, 178
  Sylvian, 675, 688
  transverse, of liver, 891
  umbilical, 891
Fissures, congenital, in cranium, 184
  calcarine, 678
  collateral, 679
  calloso-marginal, 678
  dentate, 679
  intraparietal, 676
  parallel, 677
  parieto-occipital, 678
  precentral, 676
  Rolando, 675
  Sylvius, 675, 688
Flat bones, 141
Flexor accessorius muscle, 491
  brevis digitorum, 490
  brevis minimi digiti (hand), 455
      (foot), 492
  brevis pollicis (hand), 454
      (foot), 492
  carpi radialis, 440

d by Google

Flexor carpi ulnaris, 441
  digitorum sublimis, 441
  digitorum profundus, 442
  longus digitorum, 485
  longus pollicis (hand), 442
    (foot), 484
  ossis metacarpi pollicis, 453
Floating ribs, 225
Flocculus, 710
Fœtus, circulation in, 916
  Eustachian valve in, 915
  foramen ovale in, 126, 915
  liver of, distribution of its vessels, 916
  ovaries in, 135
  vascular system in, peculiarities, 915
Folds, aryteno-epiglottidean, 923
  genital, 138
  recto-uterine, 981
  recto-vesical, 957
  vesico-uterine, 981
Follicle of hair, 93
  of intestine, 879
Follicles, sebaceous, 94
Fontana, spaces of, 811
Fontanelles, 163, 184
Foot, arteries of, 605, 608
  bones of, 284
  development of, 294
  dorsum, muscles of, 489
  fascia of, 489
  ligaments of, 487
  sole of, muscles of, 489
    fascia of, 488
  nerves of, 781
  veins of, 630
[Foot-sole, imprint of, 294]
Foramen cæcum of frontal bone, 168, 206
    of medulla oblongata, 665
    of tongue, 799
  carotid, 174
  condyloid, 162
  dental inferior, 199
  ethmoidal, 206
  incisive, 208
  infraorbital, 186
  intervertebral, 159
  jugular, 207
  lacerum anterius, 179, 206
  magnum, 161
  mastoid, 171
  medium, 207
  mental, 198
  obturator, 266
  of Majendie, 653
  of Monro, 694, 702
  of sphenoid, 179, 206
  of Winslow, 866
  optic, 176, 206
  ovale of heart, 915
  palatine, anterior, 190, 207
    posterior, 194, 208
  parietal, 164
  posterius, 207
  pterygo-palatine, 178
  rotundum, 178, 207
  sacro-sciatic, 263, 320
    of Scarpa, 190, 208
    of Sömmerring, 813
  spheno-palatine, 195, 217
  [spinal, 144]
  spinosum, 178, 207
Foramen of Stenson, 190, 208
  sternal, 222
  stylo-mastoid, 174
  supraorbital, 167
  thyroid, 266
  vertebral, 144
  Vesalii, 178, 207
Foramina, sacral, 153
    of diaphragm, 424
  external orbital, 178
    of face, landmarks of, 1027
  malar, 192
  olfactory, 181
  Thebesii, 637, 908
Forearm, arteries of, 561
  bones of, 242
  fascia of, 439
  landmarks of, 1060
  lymphatics of, 644
  muscles of, 439
  nerves of, 759
  veins of, 624
[Forehead, wrinkles of, 368, 371]
Form of bones, 141
Fornix, 698
  bulbs of, 689
  conjunctivæ, 821
  crura of, 699
Fossa of antihelix, 823
  canine, 186
  condyloid, 162
  cystis felleæ, 891
  digastric, 172
  digital, 271
  glenoid, 171
  of helix, 823
  iliac, 261
  incisive, 186, 198
  infra- and supraspinous, 233
  innominata, 823
  ischio-rectal, 1010
  jugular, 175
  lachrymal, 169
  myrtiform, 186
  navicularis of urethra, 960
  of vulva, 976
  occipital, 162
  olfactory of fœtus, 123
  ovalis, 908
  palatine, anterior, 189
  pituitary, 176
  pterygoid, of sphenoid, 179
    of lower jaw, 199
  scaphoid, 179
  scaphoidea, 823
  sigmoidea, 172
  spheno-maxillary, 212
  of skull, anterior, 206
    middle, 206
    posterior, 207
  sublingual, 199
  submaxillary, 199
  subscapular, 233
  temporal, 211
  trochanteric, 271
  zygomatic, 212
Fossæ, nasal, 215, 803
  of skull, 206
Fourchette, 976
Fourth nerve, 719
  ventricle, 712
Fovea, anterior of fourth ventricle, 713
  centralis retinæ, 813
Fovea hemispherica, 832
  posterior of fourth ventricle, 713
  semi-elliptica, 832
Fracture of acromion process, 457
  centre of clavicle, 457
    acromial end of, 458
  coracoid process, 458
  coronoid process of ulna, 459
  femur above condyles, 495
    below trochanters, 494
  fibula, with dislocation of tibia, 495
  humerus, anatomical neck, 458
    shaft of, 458
    surgical neck, 458
  neck of femur, 494
  olecranon process, 459
  patella, 495
  Pott's, 495
  radius, 460
    lower end of, 461
    neck of, 459
    shaft of, 460
    and ulna, 460
  sternal end of clavicle, 458
  tibia, shaft of, 495
  ulna, shaft of, 460
Fræna of ileo-cæcal valve, 883
Frænulum pudendi, 976
    of Vieussens' valve, 703
Frænum clitoridis, 977
  labii superioris et inferioris, 839
  linguæ, 799
  præputii, 964
Frontal artery, 532
  bone, 166
    articulations of, 170
    attachment of muscles to, 170
    development of, 169
    structure of, 169
  crest, 168
  eminence, 167
  lobe, 676
  nerve, 721
  process of malar, 192
  sinuses, 169
    landmarks of, 1026
  suture, 166, 170, 203
  vein, 613
Fronto-malar suture, 215
Fronto-nasal process, 117
Fronto-sphenoidal suture, 206, 215
Fundamental fasciculus, 658
Fundus of bladder, 957
  of uterus, 981
Funiculi graciles, 666
    of nerve, 73
Funiculus of Rolando, 668
Furrow, auriculo-ventricular, 907
  digital, 1061
  genital, 138
  interventricular, 907
Furrowed band of cerebellum, 710

G.

Galactophorous ducts, 989
Galen, veins of, 618, 699
Gall-bladder, 895

Gall-bladder—
fissure for, 891
structure of, 896
[surgery of, 896]
valve of, 896
Ganglion corpuscles, 78
Ganglion or ganglia, general anatomy of, 77
of Andersch, 737
Arnold's, 729
cardiac, 793
carotid, 789
cephalic, 723
cervical, inferior, 791
middle, 790
superior, 787
ciliary, 723
on circumflex nerve, 756
diaphragmatic, 794
on facial nerve, 733
of fifth nerve, 722
Gasserian, 720
of glosso-pharyngeal, 737
impar, 783, 792
intercarotid, 790
on posterior interosseous nerve, 764
jugular, 737
lenticular, 723
lingual, 790
lumbar, 792
Meckel's, 725
mesenteric, 796
ophthalmic, 722
otic, 729
petrous, 757
pharyngeal, 790
of pneumogastric, 739
of portio dura, 733
of Ribes, 784
of root of vagus, 739
sacral, 792
semilunar, of abdomen, 793
spheno-palatine, 724
of spinal nerves, 745
spirale, 835
submaxillary, 730
suprarenal, 794
of sympathetic nerve, 784
temporal, 790
thoracic, 791
thyroid, 790
of trunk of vagus, 739
of Wrisberg, 793
[Ganglionic arterial system of brain, 536]
branch of nasal nerve, 722
Gartner, duct of, 136
Gases of the blood, 39
Gasserian ganglion, 720
depression for, 174
Gastric arteries (vasa brevia), 577
artery, 574
follicles, 872
nerves from vagus, 741
plexus, 795
vein, 635
Gastro-colic omentum, 867
Gastro-duodenal artery, 575
plexus, 795
Gastro-epiploica dextra artery, 576
sinistra, 577
Gastro-epiploic plexus, 795
Gastro-epiploic veins, 635
Gastro-hepatic omentum, 867
Gastro-phrenic ligament, 870
Gastro-splenic omentum, 867
Gastrocnemius muscle, 482
Gelatinous connective tissue, 48
nerve-fibres, 71
Gemellus inferior muscle, 476
superior, 476
Generative organs, development of, 135
female, 976
male, 962
Genial tubercles, 199
Genio-hyo-glossus muscle, 390
Genio-hyoid muscle, 389
Genital cord, 134
folds, 138
furrow, 138
tubercle, 138
Genito-crural nerve, 770
Genu of the corpus callosum, 691
[Gerdy, fibres of, 451]
Gerlach's nerve network, 659
Germinal area, 102
disk, 102
spot, 100
vesicle, 100
Gimbernat's ligament, 413, 1004
Ginglymus, 299
Giraldès, organ of, 135
[Girdle, pelvic, 259]
[shoulder, 259]
[Glabella, 684]
of frontal bone, 168
Gladiolus, 222
Glands, ductless, 899
spleen, 899
suprarenal, 953
thymus, 941
thyroid, 939
Glands, lymphatics, 87
Gland or glands, secreting, 97
accessory of parotid, 853
arytenoid, 927
of Bartholine, 978
of biliary ducts, 897
Brunner's, 879
buccal, 840
ceruminous, 826
coccygeal, 582
Cowper's, 963, 1017
duodenal, 879
epiglottic, 927
gastric, 872
of Havers, 297
labial, 839
lachrymal, 821
of larynx, 927
lingual, 800
of Littré, 960
of Luschka, 582
mammary, 988
Meibomian, 820
molar, 840
mucilaginous, of Havers, 297
odoriferæ, 964
œsophageal, 858
of Pacchioni, 619, 662
palatine, 851, 856
parotid, 852
peptic, 872
Peyer's, 880
pharyngeal, 857
Gland or glands—
pineal, 702
pituitary, 689
prostate, 962
salivary, 852
sebaceous, 94
solitary, 880
sublingual, 854
submaxillary, 853
sudoriferous, 94
suprarenal, 953
thymus, 941
thyroid, 939
tracheal, 929
of Tyson, 964
uterine, 983
of vulva, 978
Glandulæ odoriferæ, 964
Pacchioni, 619, 662
Glans penis, 964
clitoridis, 977
Glaserian fissure, 171, 826
Glenoid cavity, 236
fossa, 171
ligament of shoulder, 327
of phalanges, 341
Gliding movement, 300
Glisson's capsule, 867, 892
Globules, blood-, 36
development of, 125
Globus major of epididymus, 971
minor, 971
Glosso-epiglottidean ligaments, 921
Glosso-pharyngeal nerve, 736
Glottis, 923
rima of, 923
Gluteal artery, 591
inferior, 590
lymphatic glands, 645
nerve, inferior, 780
superior, 778
region, lymphatics of, 646
muscles of, 472
veins, 632
aponeurosis, 465
Gluteus maximus muscle, 473
medius, 474
minimus, 474
Gomphosis, 298
[Gonion, 685]
Graafian vesicles, 986
membrana granulosa of, 986
ovicapsule of, 986
structure of, 986
Gracilis muscle, 470
Gray nervous substance, 68
matter of cerebellum, 711
of cerebrum, 703
of fourth ventricle, 714
of medulla oblongata, 669
of spinal cord, 658
Great omentum, 867
sciatic nerve, 780
Greater wings of sphenoid, 178
Groin, 991
cutaneous vessels and nerves of, 991
landmarks of, 1049
superficial fascia of, 991
surgical anatomy of, 991
Groove, auriculo-ventricular, 907
bicipital, 238
cavernous, 177
primitive dental, 846

Groove—
  infraorbital, 187
  lachrymal, 187
  mylo-hyoid, 199
  nasal, 185
  occipital, 172
  optic, 176
  subclavian, 226
Grooves in the radius, 249
  ventricular, 907
Growth of bones, 62
Gubernaculum testis, 974
Gums, 840
Gustatory nerve, 729
Gyri operti, 678, 688
Gyrus fornicatus, 679

H.

Hæmatoidin crystals, 39
Hæmin crystals, 39
Hæmoglobin crystals, 39
Hair-cells of internal ear, 836
Hairs, 92
  follicles, 93
  root-sheath, 92
  shaft, 93
  structure of, 93
Ham, region of the, 600
Hamstring tendons, surgical anatomy of, 479
Hamular process of sphenoid, 179
    of humerus, 240, *note*
    of lachrymal, 191
Hand, arteries of, 566
  bones of, 250
  fascia of, 449
  landmarks of, 1061
  ligaments of, 336
  muscles of, 449
  nerves of, from median, 759
    from radial, 763
    from ulnar, 761
  veins of, 623
Hard palate, 850
Harmonia, 298
Hasner, valve of, 822
Havers, glands of, 297
Haversian canals of bone, 56
Head, lymphatics of, 640
  muscles of, 365
  veins of, 612
Heart, 906
  annular fibres of auricles, 913
  arteries of, 507, 915
  circular fibres of, 913
  development of, 124
  endocardium, 912
  fibres of the auricles, 913
    of the ventricles, 913
  fibrous rings of, 913
  fœtal relics in, 909
  infundibulum of, 909
  landmarks of, 1035
  left auricle, 911
    ventricle, 912
  looped fibres of auricles, 913
  lymphatics of, 650, 915
  muscular fibres of, 66
    structure of, 913
  nerves of, 740, 792, 915
  outline of, on chest-wall, 1035
  position of, 906
  right auricle, 907
Heart—
  right ventricle, 909
  septum ventriculorum, 909
  size and weight, 906
  spiral fibres of, 914
  structure of, 913
  subdivision into cavities, 907
  valves of, landmarks, 1036
  veins of, 636
  vortex of, 914
Heidenhain, demilunes of, 855
Helicine arteries, 965
Helicis major muscle, 824
  minor, 824
Helicotrema of cochlea, 833
Helix, 823
  fossa of, 823
  muscles of, 824
  process of, 823
Hemorrhoidal artery, inferior, 589
    middle, 586
    superior, 579
  nerve, inferior, 778
  plexus of nerves, 796
  veins, inferior, 632
    middle, 632
    superior, 634
  venous plexus, 632, 634
Henle, looped tubes of, 947
Hepatic artery, 574, 894
  cells, 893
  duct, 896
  plexus, 794
  veins, 634, 892, 894
Hernia, congenital, 999
  descent of, 1008
  direct inguinal, 999
    dissection of, 1000
  femoral, coverings of, 1008
  [general remarks on, 997]
  infantile, 999
  inguinal, 991
    dissection of, 991
  oblique inguinal, 998
  scrotal, 998
Hesselbach's triangle, 999
Hey's ligament, 1002
Hiatus Fallopii, 174
Highmore, antrum of, 187
Hilton's muscle, 926
Hilum of kidney, 944
  of spleen, 899
Hinge joint, 299
Hip-joint, 342
  muscles of, 472
    in relation with, 345
Hippocampus major, 696
  minor, 693
Horizontal plate of ethmoid, 181
    of palate, 193
[Horner's muscle, 371, 822]
Horny band of Tarinus, 694
Huguier, canal of, 171
Humerus, 237
  anatomical neck, fracture of, 458
  articulations of, 242
  attachment of muscles to, 242
  development of, 241
  head of, 237
  landmarks of, 1057
  neck of, 238
  nutrient artery of, 561
  shaft, fracture of, 458
Humerus—
  [surgical head, 237]
  surgical neck, fracture of, 458
  tuberosities of, greater and lesser, 238
Humors of the eye, 816
Hyaline cartilage, 51
Hyaloid membrane of eye, 815
Hydatid of Morgagni, 136
Hymen, 977
Hyo-epiglottic ligament, 922
Hyo-glossal membrane, 801
Hyo-glossus muscle, 390
Hyoid artery of superior thyroid, 514
  bone, 219
    attachment of muscles to, 220
    cornua of, 219
    development of, 220
    landmarks of, 1032
  branch of lingual artery, 515
  region, muscles of, infra-, 386
    supra-, 388
Hypoblast, 102
Hypochondriac regions, 860
Hypogastric arteries in fœtus, 584, 916
    how obliterated, 918
  plexus, 796
    inferior, 796
  region, 860
Hypoglossal nerve, 742
Hypophysis cerebri, 689
  of pituitary body, 119

I.

Ileo-cæcal or ileo-colic valve, 882
Ileo-colic artery, 579
Ileum, 876
Iliac arteries, common, 582
      peculiarities, 583
      surgical anatomy of, 583
    external, 591
      surgical anatomy of, 592
    internal, 584
      at birth, 584
      peculiarity in the fœtus, 584
      surgical anatomy of, 585
  fascia, 462
    portion of fascia lata, 466
  fossa, 261
    lymphatic glands, 648
  region, muscles of, 462
  veins, common, 632
      peculiarities of, 632
    external, 631
    internal, 631
Iliacus muscle, 464
Ilio-costalis muscle, 406
Ilio-femoral ligament, 343
Ilio-hypogastric nerve, 769
Ilio-inguinal nerve, 770
Ilio-lumbar artery, 591
  ligament, 318
  vein, 632
Ilio-pectineal eminence, 265
Ilio-tibial band, 467
Ilium, 261
  crest of, 261
  dorsum of, 261
  landmarks of, 1043
  spines, 261

Ilium—
  venter of, 261
Impressio colica, 892
  renalis, 892
Incisive canal, 208
  foramina, 208
  fossa, 186, 198
Incisor teeth, 841
Incisura intertragica, 823
  cerebelli, 709
  Santorini, 825
Incus, 829
  development of, 123
  ligament of, 830
    suspensory, 830
Infantile hernia, 999
Inferior dental artery, 523
  dental canal, 199
  [frontal sulcus, 676, 686]
  maxillary bone, 197
    landmarks of, 1028
  meatus of nose, 218
  occipital fossa, 163
  profunda artery, 561
  turbinated bones, 196
    articulations of, 196
    development of, 196
    ethmoidal process of, 196
    lachrymal process of, 196
    maxillary process of, 196
  vena cava, 633
Inferior-posterior lobe of cerebellum, 710
Infracostal muscles, 420
Inframaxillary nerves from facial, 736
Infraorbital artery, 524
  canal, 187
  foramen, 186
  groove, 187
  plexus of nerves, 724
    branches of facial, 735
Infraspinatus muscle, 434
Infraspinous fascia, 433
Infratrochlear nerve, 722
Infundibula of kidney, 945
Infundibuliform fascia, 996
Infundibulum of brain, 689
  of cochlea, 833
  of ethmoid, 183
  of heart, 909
Ingrassias, processes of, 179
Inguinal canal, 996
  glands, deep, 645
    superficial, 644, 1001
  hernia, 997
    dissection of, 991
  region, 860
[Inion, 684]
Inlet of pelvis, 268
Innominate artery, 508
    peculiarities of, 508
    surgical anatomy of, 509
  bone, 260
    articulations of, 267
    attachment of muscles to, 267
    development of, 266
  veins, 625
    peculiarities of, 626
Inorganic constituents of bone, 58
Inspiration, muscles of, 421
[Insula, 677]
Interarticular fibro-cartilage, 52
Interarticular fibro-cartilage—
    of scapulo-clavicular joint, 325
    of jaw, 311
    of knee, 350
    of radio-ulnar joint, 333
    of sterno-clavicular joint, 323
  ligament of ribs, 314
Intercarotid ganglion, 790
Intercellular substance of cartilage, 51
Interchondral ligaments, 317
Interclavicular ligament, 323
Intercolumnar fascia, 414, 993
Intercondyloid notch, 274
Intercostal arteries, 571
    anterior, 571
    superior, 552
  fasciæ, 420
  lymphatics, 650
  lymphatic glands, 649
  muscles, 420
  nerves, 766
  spaces, 220
  veins, superior, 627
Intercosto-humeral nerves, 758, 766
Interglobular spaces, 845
Interlobular arteries of kidney, 950
  biliary plexus, 894
Intermaxillary suture, 213
Intermembranous ossification, 63
Internal abdominal ring, 996
  annular ligament, 488
  capsule, 693
  carotid artery, 528
  cutaneous nerve, 756
  inguinal hernia, 997
  mammary artery, 551
  maxillary artery, 571
    branches of, 522
  mammary vein, 626
  oblique muscle, 414
  occipital crest, 163
  pterygoid plate, 179
  sphincter, 1011
Internasal suture, 213
Interossei muscles, dorsal of hand, 456
    of foot, 493
  palmar, 457
  plantar, 493
Interosseous artery of forearm, 567
    of foot, 606
  fibro-cartilages, 298
  membrane of forearm, 333
    of leg, 353
  nerve, anterior, 759
    posterior, 764
  veins of forearm, 624
Interpeduncular space of brain, 689
Interspinales muscles, 410
Interspinous ligaments, 304
Intertransversales muscles, 410
Intertransverse ligaments, 304
Intertubular stroma of kidney, 951
Intervertebral notches, 143
  foramen, 160
  substance, 303
Intestine, development of, 130
Intestine—
  [growth of, 881]
  large, coats of, 886
    landmarks of, 1045
  lymphatics of, 649
  small, 874
    coats of, 876
      landmarks of, 1046
Intracartilaginous ossification, 59
Intralobular veins, 894
Intraparietal fissure, 676
  [sulcus, 676, 686]
[Intubation of the larynx, 931]
Intumescentia gangliformis, 733
Involuntary muscle, 67
Iris, 810
Irregular bones, 142
Ischiatic lymphatic glands, 645
Ischio-rectal fascia, 1022
  fossa, 1011
  position of vessels and nerves in, 1012
  region, surgical anatomy of, 1011
Ischium, 263
  body of, 263
  ramus of, 264
  spine of, 263
  tuberosity of, 264
Island of Reil, 677
Isthmus of the fauces, 851
  of thyroid gland, 940
Iter ad infundibulum, 702
  a tertio ad quartum ventriculum, 701
  chordæ posterius, 826
Ivory of tooth, 844

J.

Jacob's membrane, 815
Jacobson's nerve, 738, 831
  canal for, 174
Jaw, lower, 197
  articulations of, 202
  attachment of muscles to, 202
  changes produced in, by age, 200
  condyle of, 200
  development of, 200
  ligaments of, 311
  oblique line of, 199
  pterygoid fossa of, 200
  rami of, 199
  sigmoid notch of, 200
  symphysis of, 197
  upper. See *Maxillary Bone.*
Jejunum, 876
Joint. See *Articulations.*
Jugular foramen, 207
  fossa, 175
  ganglion, 737
  process, 161
  surface, 174
  vein, anterior, 615
    external, 615
    internal, 616
      sinus or gulf of, 616
    posterior, external, 615

K.

Kerato-glossus muscle, 390
Kerkring, valves of, 877
Kidney, 944

d by Goo

Kidney—
  calices of, 945
  cortical substance of, 946
  development of, 133
  ducts of, 952
  hilum of, 944
  infundibula of, 945
  landmarks of, 1045
  lymphatics of, 648, 951
  Malpighian bodies of, 946
  mammillæ of, 946
  medullary substance, 946
  nerves of, 951
  papillæ of, 946
  pelvis of, 945
  pyramids of Ferrein, 948
  renal artery, 949
  sinus of, 945
  [surgery of, 945]
  tubuli uriniferi, 946
  veins of, 634, 951
  weight and dimensions, 945
[Knee, angle at, 242]
Knee-joint, 346
  landmarks of, 1051
Knuckles, landmarks of, 1062
Krause's membrane, 65
  end-bulbs of, 75
Kuhne, his views on the terminations of motor nerves, 77
Kürschner, on structure of heart's valves, 910

L.

Labia cerebri, 691
  pudendi majora, 976
    minora, 976
    lymphatics of, 648
Labial artery, 518
  glands, 839
  veins, superior, 614
    inferior, 614
Labium tympanicum, 835
  vestibulare, 835
Labyrinth, 832
  arteries of, 838
  fibro-serous membrane of, 837
Lachrymal apparatus, 821
  artery, 531
  bone, 191
    articulations of, 192
    attachment of muscles to, 192
    development of, 192
  canals, 822
  caruncula, 821
  crest, 191
  fossa, 169
  gland, 821
  groove, 187
  nerve, 721
  papilla, 819, 822
  process of inferior turbinated bone, 196
  puncta, 822
  sac, 822
  tubercle, 189
Lacteals, 638, 649, 878
Lactiferous ducts, 989
Lacuna magna, 960
Lacunæ of bone, 57
Lacus lachrymalis, 819
[Lambda, 684]
Lambdoid suture, 203
Lamella, horizontal, of ethmoid, 181
  perpendicular, of ethmoid, 181
  of bone, articular, 296
Lamellæ of bone, 57
Lamina cinerea, 687
  cribrosa, 174
    of sclerotic, 806
  fusca, 806
  spiralis ossea of cochlea, 834
    membranacea, 835, *note*
  suprachoroidea, 809
  of cornea, elastic, 806
  of the vertebræ, 143
    cerebellum, 711
Laminæ dorsales, 103
Laminated tubercle of cerebellum, 710
Lancisi, nerves of, 692
Landmarks, medical and surgical, 1025
  abdomen, 1041
    bony prominences of, 1043
    lines of, 1041
    manipulation of, 1044
    rings of, 1043
    viscera of, 1044
  ankle, 1053
  anterior tibial artery, 1054
  anterior fontanelle, 1026
  antrum, 1031
  anus, 1047
  aorta, division of, 1042
  arm, 1056
    cutaneous veins of, 1058
  axilla, 1057
  axillary artery, 1058
  back, 1037
    furrows of, 1037
  bladder, 1046
  brachial artery, 1058
  brain, levels of, 1027
  bursa, carpal, 1060
    digital, 1062
    of elbow, 1059
    of foot, 1053
    of patella, 1052
  buttocks, 1050
  carpus, 1060
  catheter, introduction of, 1048
  chest, 1034
    in the female, 1034
  clavicle, 1056
    below, 1035
  colotomy, 1046
  condyles of humerus, 1059
  coraco-acromial ligament, 1057
  cricoid cartilage, 1032
  crural arch, 1043
  cutaneous veins of arm, 1058
  diaphragm, 1044
  digital arteries, 1061
    furrows, 1061
    joints, 1062
  dorsal artery of foot, 1056
    ear, 1027
  elbow, 1058
    cutaneous veins of, 1058
  epigastric artery, 1044
  eyelids, 1028
  eyes, 1028
  face, 1027
  facial artery, 1028
  features, 1031
  femoral artery, 1050
Landmarks—
  femoral artery, compression of, 1050
    ring, 1048
  fibula, 1053
  fingers, 1062
  foot, 1055
    arteries of, 1056
    bones of, 1055
    bursa of, 1056
    joints of, 1055
  foramina for fifth nerve, 1027
  forearm, 1059
  gall-bladder, 1045
  gluteal artery, 1051
  groin, 1049
  hand, 1061
  head, 1026
  heart, 1035
    apex of, 1036
    auscultation of, 1036
    outlines of, 1035
    valves of, 1036
  Hunter's canal, 1050
  hyoid bone, 1032
  ilium, prominences of, 1043
  inguinal canal, 1044
    glands, 1049
  interdigital folds, 1061
  internal mammary artery, 1035
  interosseous arteries of arm, 1059
    of hand, 1062
  intestines, large, 1045
    small, 1046
  kidney, 1045
  knee, 1051
    bony prominences of, 1051
    synovial membrane of, 1052
  knuckles, 1062
  lachrymal sac, 1029
  leg, 1053
  ligamentum patellæ, 1052
  linea alba, 1042
  lineæ semilunares, 1041
  lips, 1030
  liver, 1044
  lower jaw, 1028
  lung, 1036
    apex of, 1033
    outlines of, 1036
  malleoli, 1053
  mastoid process, 1026
  mediastinum, anterior, 1037
  metacarpal joints, 1061
  middle meningeal artery, 1027
  mouth, 1030
  nares, 1031
  nasal cavities and duct, 1029
  neck, 1031
    veins of, 1032
  Nélaton's line, 1049
  nose, 1029
  occipital protuberance, 1027
  olecranon, 1058
  [on the skull, 684]
  palm of hand, 1061
  palmar arches, 1061
  palpation by rectum, 1062
  pancreas, 1045
  parotid duct, 1028
  patella, 1051
  patellar bursa, 1052
  perineum, 1046

Landmarks—
  perineum, bony framework of, 1046
    raphé of, 1046
  peritoneum, 1042
  peroneal nerve, 1053
  phrenic nerve, 1053
  pit of the stomach, 1041
  plantar arteries, 1056
    fascia, 1056
  pleura, reflections of, 1037
  pomum Adami, 1032
  popliteal artery, 1054
    bursa, 1052
    tendons, 1052
  posterior tibial artery, 1055
  Poupart's ligament, 1043
  prostate gland, 1047
  pubes, bony prominences, 1043
  pudic artery, 1051
  pulley for superior oblique, 1028
  pulse at wrist, 1060
  puncta lachrymalia, 1029
  pylorus, 1045
  radial artery, 1060
  radius, 1059
  raphé of perineum, 1046
  rectum, 1047
    palpation by, 1062
  ribs, rules for counting, 1034
  saphena veins, 1055
  saphenous opening, 1048
  sartorious, 1050
  scalp, 1026
    arteries of, 1026
    density of, 1026
  scapula, 1040
  sesamoid bones, 1062
  seventh nerve, 1028
  shoulder, 1057
  sinuses, cerebral, 1027
    frontal, 1026
  skull-cap, 1026
    thickness of, 1027
  spermatic cord, 1044
  spinal nerves, 1038
  spine, movements of, 1039
    of ilium, 1043
    of pubes, 1043
  spines of vertebræ, 1038
  spleen, 1045
  sterno-clavicular joint, 1033
  sterno-mastoid muscle, 1033
  sternum, 1034
  stomach, 1045
  subclavian artery, 1033
  subcutaneous veins of hand, 1062
    of neck, 1032
  supraclavicular fossa, 1033
  supracondyloid processes, 1058
  tabatière anatomique, 1060
  teeth, 1030
  temporal artery, 1028
  tendo Achillis, 1054
  tendons of ankle, 1054
    of wrist, 1060
  thigh, 1048
    bend of, 1048
  throat, 1030
  thumb, 1061
  thyroid cartilage, 1032
  tibia, 1051
  tonsils, 1031

Landmarks—
  trachea, 1032
    division of, 1037
  triangular ligament, 1047
  trigonum vesicæ, 1047
  trochanters, 1049
  tuberosities of arm, 1057
  ulna, 1059
  ulnar artery, 1061
  umbilicus, 1041
  urethra, 1047
    in child, 1048
  vagina, examinations of, 1063
  vertebræ, spines of, 1037
    tabular plan of, 1039
  viscera, abdominal, 1044
  wrist, 1059
  zygoma, 1028
Large intestine, 881
    areolar coat, 887
    cæcum, 882
    colon, 883
    ilio-cæcal valve, 882
    mucous coat, 887
    muscular coat, 887
    rectum, 886
    serous coat of, 887
Laryngeal artery, inferior, 550
    superior, 515
  nerve, external, 740
    internal, 740
    recurrent, 740
    superior, 740
      from sympathetic, 789
  pouch, 924
  veins, 627
Laryngo-tracheotomy, 930
Laryngotomy, 930
Larynx, 919
  actions of muscles of, 926
  arteries of, 927
  cartilages of, 919
  cavity of, 923
  glands of, 927
  glottis, 923
  interior of, 922
  [intubation of, 931]
  ligaments of, 922
  lymphatics of, 927
  mucous membrane of, 927
  muscles of, 924
  nerves of, 927
  rima glottidis, 923
  superior aperture of, 922
  veins of, 927
  ventricle of, 924
  vocal chords of, false, 923
      true, 924
Lateral ginglymus, 300
  ligaments of liver, 890
  masses of ethmoid, 182
  region of skull, 211
  sinus of brain, 620
  tract of medulla oblongata, 666, 669
Lateralis nasi artery, 518
Latissimus dorsi muscle, 401
Lee, Dr., researches on sympathetic nerve, 797, *note*
Leg, arteries of, 602, 603
  bones of, 276
  fascia of, 479
    deep transverse, 484
  ligaments of, 342
  lymphatics of, 645

Leg—
  muscles of, 479
    back of, 481
    front of, 480
  nerves of, 782
  veins of, 630
Lens, 817
  changes produced in, by age, 818
  development of, 122
  suspensory ligament of, 818
Lenticular ganglion, 723
Lesser lachrymal bone, 191
  omentum, 867
  sciatic nerve, 779
  wings of sphenoid, 179
Levator anguli oris, 375
    scapulæ, 403
  ani, 1017
  glandulæ thyroideæ, 940
  labii inferioris, 376
    superioris alæque nasi, 374
    superioris, 375
  menti, 376
  palati, 394
  palpebræ, 371
  prostatæ, 1018
Levatores costarum, 422
Lieberkühn, crypts of, 879
Ligament, structure of, 296
  acromio-clavicular, superior, 324
    inferior, 324
  alar of knee, 351
  of ankle, anterior, 354
    lateral, 355
  annular of radius, 333
    of wrist, anterior, 336
      posterior, 336
    of ankle, 354
      external, 356
      internal, 355
    of stapes, 831
  anterior, of knee, 347
  arcuate, 422
  aryteno-epiglottic, 922
  astragalo-scaphoid, 360
  atlo-axoid, anterior, 306
    posterior, 307
  of bladder, false, 957
    true, 957
  broad, of liver, 889
  calcaneo-astragaloid, external, 358
    interosseous, 358
    posterior, 358
  calcaneo-cuboid, internal, 359
    long, 359
    short, 359
    superior, 359
  calcaneo-scaphoid, inferior, 359
    superior, 359
  capsular. See *Individual Joints.*
  carpo-metacarpal, dorsal, 339
    interosseous, 339
    palmar, 339
  of carpus, 336
  central, of spinal cord, 654
  check, 310
  chondro-sternal, anterior, 315
    posterior, 315
  ciliary of eye, 812
  common vertebral, anterior, 302

Ligament—
  common vertebral, posterior, 303
  conoid, 324
  coraco-acromial, 326
  coraco-clavicular, 324
  coraco-humeral, 327
  coracoid, 324
  coronary of liver, 890
  costo-clavicular, 322
  costo-transverse, 315
  costo-vertebral, or stellate, 313
  cotyloid, 345
  crico-arytenoid, 922
  crico-thyroid, 922
  crucial, of knee, 349
  cruciform, 308
  deltoid, 355
  dorsal. See *Individual Joints.*
      of elbow, 330
    anterior, 330
    external lateral, 330
    internal lateral, 330
    posterior, 330
  falciform of liver, 889
  femoral (Hey's), 1002
  gastro-phrenic, 870
  Gimbernat's, 413, 994, 1004
  glenoid, 327
  glosso-epiglottidean, 921
  of hip, 342
  hyo-epiglottic, 922
  ilio-femoral, 343
  ilio-lumbar, 318
  of incus, 830
  interarticular of ribs, 314
  interclavicular, 323
  interchondral, 317
  interosseous. See *Individual Joints.*
  interspinous, 304
  intertransverse, 304
  intervertebral, 303
  of jaw, 311
  of knee, 347
  of larynx, 921
  lateral See *Individual Joints.*
  longitudinal of liver, 889
  long plantar, 358
  lumbo-iliac, 318
  lumbo-sacral, 318
  of malleus, 830
  metacarpo-phalangeal, 340
  metacarpal, 340
  metatarsal, 361
  metatarso-phalangeal, 361
  mucosum of knee, 351
  nuchæ, 401
  oblique, 333
  obturator, 475
  occipito-atloid, anterior, 309
    lateral, 309
    posterior, 309
  occipito-axoid, 309
  odontoid, 310
  orbicular, 333
  of ossicula, 830
  of ovary, 988
  palpebral or tarsal, 820
  of patella, 347
  of pelvis, 319
  of the phalanges, hand, 341
      foot, 361
  of the pinna, 823
  plantar, 359

Ligament—
  posterior of knee, or posticum Winslowii, 347
  Poupart's, 412, 994, 1004
  pterygo-maxillary, 378
  pubic, anterior, 321
    posterior, 321
    superior, 321
  pubo-prostatic, 957
  radio-carpal, 336
  radio-ulnar joint, inferior, 333
      middle, 333
      superior, 333
  recto-uterine, 981
  rhomboid, 323
  round, of uterus, 988
    of liver, 889
    of radius and ulna, 332
    of hip, 342
  sacro-coccygeal, anterior, 321
    posterior, 321
  sacro-iliac, anterior, 319
    oblique, 320
    posterior, 319
  sacro-sciatic, greater, 320
      lesser, 320
  sacro-vertebral, 318
  of scapula, 326
  scapulo-clavicular, 324
  of shoulder, 326
  stellate, 313
  sterno-clavicular, anterior, 332
    posterior, 323
  of sternum, 314
  stylo-maxillary, 311
  subpubic, 321
  supraspinous, 304
  suspensory of incus, 830
    of lens, 818
    of liver, 889
    of malleus, 830
    of mamma, 427
    of penis, 964
    of spleen, 899
  sutural, 296
  tarsal of eyelids, 820
  tarso-metatarsal, 360
  of tarsus, 358
  teres of hip, 344
  thyro-arytenoid, inferior, 924
    superior, 924
  of thumb, 338
  tibio-tarsal, 354
  thyro-epiglottic, 922
  thyro-hyoid, 922
  tibio-fibula, 356
  transverse of atlas, 307
    of hip, 342
    of knee, 347
    of scapula, 326
  trapezoid, 324
  triangular of urethra, 994
  of tympanic bones, 830
  of uterus, 981
  of vertebræ, 302
  vesico-uterine, 981
  of Winslow, 347
  of wrist, anterior, 336
    lateral external, 336
    lateral internal, 336
    posterior, 336
  of Zinn, 372
Ligamenta alaria, 351
  subflava, 304
  suspensoria of mamma, 427

Ligamentum arcuatum externum, 423
    internum, 423
  denticulatum, 654
  latum pulmonis, 932
  mucosum, 351
  nuchæ, 401
  patellæ, 347
  pectinatum iridis, 811
  posticum Winslowii, 347
  spirale, 835
  teres, 344
Ligature of arteries. See each *Artery.*
Limbus laminæ spiralis, 835
  luteus, 813
[**Line, Nélaton's**, 272]
    landmarks of, 1049
Linea alba, 418
    landmarks of, 1042
  aspera, 273
  ilio-pectinea, 264
  quadrati, 273
  splendens, 654
Lineæ semilunares, 419
    landmarks of, 1041
  transversæ of abdomen, 419
    landmarks of, 1042
  transversæ of fourth ventricle, 713
Lingual artery, 515
    surgical anatomy of, 516
  bone, 219
  ganglion, 790
  nerve, 729
  veins, 616
Lingualis muscle, 390
Linguetta laminosa, 703
Lingula of sphenoid, 177
Lips, 839
  arteries of, 517, 518
Liquor Cotunnii, 837
  Scarpæ, 838
  sanguinis, 38
  seminis, 974
Lithotomy, parts concerned in operation of, 1020
    avoided in operation, 1021
    divided, 1021
Littré, glands of, 960
Liver, 889
  changes of position in, 889
  development of, 132
  distribution of vessels to in fœtus, 916
  ducts of, 896
  fibrous coat of, 892
  fissures of, 891
  [floating, 889]
  hepatic artery, 574, 894
    cells, 893
    duct, 896
    veins, 634, 894
      landmarks of, 1044
  ligaments of, 889
  coronary, 890
  lateral, 890
  longitudinal, 889
  round, 891
  lobes of, 891
  lobules of, 892
  lymphatics of, 648
  nerves of, 795
  portal vein, 894
  situation, size, and weight, 889

Liver—
  structure of, 892
  its surfaces and borders, 889
  vessels of, 894
  [wandering, 889]
Lobe, central, 677
  cuneate, 680
  frontal, 676
  marginal, 679
  occipital, 677
  orbital, 676
  parietal, 676
  quadrate, 680
  temporo-sphenoidal, 677, 679
  uncinate, 680
Lobes of cerebrum, 672
  of cerebellum, 708
  of kidney, 945
  of liver, 891
  of lung, 935
  of prostate, 963
  of testis, 970
  of thyroid, 939
  of thymus, 941
Lobule of the ear, 823
  [paracentral, 680]
Lobules of liver, 893
  of kidney, 945
  of lung, 936
Lobulettes of lung, 937
Lobuli testes, 970
Lobulus centralis of cerebellum, 709
   Spigelii, 892
Lobus caudatus, 892
  quadratus, 892
Locus ceruleus, 713
  niger, 690
  perforatus anticus, 688
  posticus, 689
Long bones, 141
  saphenous nerve, 774
Longissimus dorsi muscle, 406
Longitudinal fissure, of brain, 672, 687
   of liver, 891
  ligament of liver, 889
  sinus of brain, superior, 619
   inferior, 620
Longus colli muscle, 398
Looped tubes of Henle, 947
Lower extremity, arteries of, 593, 594
   bones of, 259
   fascia of, 461
   lymphatics of, 644
   ligaments of, 341
   muscles of, 461
   nerves of, 770
   veins of, 630
Lower, tubercle of, 908
Lumbar arteries, 581
  fascia, 416
  ganglia, 792
  glands, 646
  nerves, 767
  plexus of nerves, 768
  region, 860
  vein, ascending, 633
  veins, 633
  vertebræ, 149
   development of, 152
Lumbo iliac ligament, 318
Lumbo-sacral ligament, 318
   nerve, 768
Lumbricales muscles, hand, 455
   foot, 491
Lungs, 934
  air-cells of, 937
  air-sacs, 939
  apex of, landmarks of, 1033
  bronchial arteries, 939
   veins, 939
  capillaries of, 937
  development, 132
  in fœtus, 916
  landmarks of, 1036
  lobes and fissures of, 935
  lobules of, 936
  lobulettes, 937
  lymphatics of, 650, 939
  nerves of, 939
  pulmonary artery, 937
   veins, 937
  root of, 936
  structure of, 936
  weight, color, etc., 936
Lunulæ of nails, 92
Luschka's gland, 582
Lymph, 39
Lymphatic duct, right, 640
Lymphatic glands, general anatomy of, 87
  descriptive anatomy, anterior mediastinal, 650
   auricular posterior, 640
   axillary, 643
   brachial, 643
   bronchial, 650
   buccal, 641
   cervical, deep, 642
    superficial, 642
   in front of elbow, 643
   gluteal, 645
  of head, 640
  iliac, external, 646
   internal, 646
  inguinal, deep, 645
   superficial, 644
  intercostal, 649
  internal mammary, 650
  ischiatic, 645
  of large intestine, 649
  of lower extremity, 644
  lumbar, 646
  of neck, 642
  occipital, 640
  parotid, 640
  of pelvis, 646
  popliteal, 645
  radial, 643, 644
  sacral, 646
  of small intestines, 649
  of spleen, 649
  of stomach, 649
  submaxillary, 640
  of thorax, 650
  tibial anterior, 645
  ulnar, 643, 644
  of upper extremity, 643
  zygomatic, 640
Lymphatics, general anatomy of, 84
  origin of, 86
  plexus of, 86
  subdivision into deep and superficial, 638
  valves of, 85
  vessels, 84
  where found, 87
Lymphatics—
   descriptive anatomy:
  abdomen, 646
  arm, 643
  bladder, 648
  bone, 55
  broad ligaments, 648
  cardiac, 650
  cerebral, 641
  cervical, superficial and deep, 642
  chest, 650
  of clitoris, 648
  of cranium, 641
  diaphragm, 650
  face, superficial, 641
   deep, 641
  Fallopian tubes, 648
  gluteal region, 646
  head, superficial, 640
  heart, 650
  intercostal, 649
  internal mammary, 650
  intestines, 649
  kidneys, 648
  labia, 648
  lacteals, 649
  large intestine, 649
  leg, 644
  liver, 648
  lower extremity, 644
  lung, 650
  lymphatic duct, 640
  meningeal, 641
  mouth, 641
  neck, 642
  nose, 641
  nymphæ, 648
  œsophagus, 651
  ovaries, 648
  pancreas, 649
  pelvis, 646
  penis, 647
  perineum, 647
  pharynx, 642
  pia mater, 641
  prostate, 648
  rectum, 648
  scrotum, 647
  small intestine, 649
  spleen, 649
  stomach, 649
  testicle, 648
  thoracic duct, 639
  thorax, 649
  thymic, 651
  thyroid, 651
  upper extremity, 643
   deep, 644
   superficial, 644
  uterus, 648
  vagina, 648
Lymphoid connective tissue, 48
   of tongue, 801
   of tonsil, 857
Lyra of fornix, 699

M.

Macula cribrosa, 832
  germinativa, 99
  lutea, 816
Magnum of carpus, 254
Majendie, foramen of, 653
Malar bone, 192

Malar bone—
articulations of, 193
attachment of muscles to, 193
development of, 193
frontal process of, 192
maxillary process of, 192
orbital process of, 192
zygomatic process of, 193
canals, 193
nerves, from facial, 735
process of superior maxillary, 189
Male urethra, 959
Malleolar arteries, external and internal, 605
Malleolus, external, 282
internal, 281
Malleus, 829
development of, 123
suspensory ligament of, 830
Malpighi, pyramids of, 946
Malpighian bodies of kidney, 946
tufts, 946
capsules, 946
corpuscles of spleen, 902
Mamma, areola of, 988
lobules of, 989
nerves of, 989
nipple or mammilla of, 988
vessels of, 989
Mammæ, development of, 123
Mammary artery, internal, 551
glands, 988
lymphatic glands, 650
veins, internal, 626
Mammilla of breast, 988
of kidney, 946
Manubrium of sternum, 222
of malleus, 829
Marginal lobe, 679
Marrow of bone, 54
Marshall, vestigial fold of, 626
Masseter muscle, 378
Masseteric arteries, 524
nerve, 727
veins, 614
[Mastication, muscles of, 365]
Masto-occipital suture, 203
Masto-parietal suture, 203
[Mastoid cells, 172, 827]
openings of, 827
[disease, 172, 827]
foramen, 171
portion of temporal bone, 171
process, 171
vein, 620
Matrix of nail, 92
Maxillary arch, fetal, 117
artery, internal, 521
bone, inferior, 197
superior, 186
development of, 190
nerve, inferior, 727
superior, 723
process of inferior turbinated, 196
malar bone, 193
sinus, 187
tuberosity, 187
vein, internal, 614
Meatus auditorius externus, 173
internus, 174
of nose, inferior, 218, 804
Meatus—
of nose, middle, 218, 804
superior, 217, 804
urinarius, male, 964
female, 977
Meatuses of the nose, 217, 804
Meckel's cartilage, 118
ganglion, 725
Median artery of forearm, 568
of spinal cord, 549
nerve, 759
vein, 624
Mediastinal arteries, from internal mammary, 552
posterior, from aorta, 571
lymphatic glands, 650
Mediastinum, anterior, 934
middle, 934
landmarks of, 1037
posterior, 934
superior, 934
testis, 970
Medulla oblongata, 665
anterior pyramids of, 666
back of, 667
fissures of, 666
lateral tract, 666, 667
olivary body, 666, 667
posterior pyramids, 666
restiform bodies, 666, 668
septum of, 668
structure of, 667
spinalis, 654
Medullary canal of bone, 62, 141
membrane of bone, 54
plates, 103
sheath of nerve-fibres, 70
substance of brain, 72
of kidney, 946
of suprarenal capsules, 954
velum, posterior, of cerebellum, 710
Medullated nerve-fibres, 69
Medullo-spinal veins, 629
Meibomian glands, 820
Membrana basilaris, 835
fusca, 806
of Graafian vesicle, 986
limitans of retina, 813
nictitans, 821
pupillaris, 812
sacciformis, 339
tectoria, 835
tympani, 829
secundaria, 834
Membrane of aqueous chamber, 808
arachnoid, spinal, 653
cerebral, 663
choroid, 809
of Corti, 835
costo-coracoid, 429
crico-thyroid, 922
of Descemet, 807
fenestrated, 79
hyaloid, 817
Jacob's, 815
limiting, 813
pituitary, 803
pupillary, 812
of Reissner, 835
Schneiderian, 803
thyro-hyoid, 921
Membranes of spinal cord, 652
of brain, 661
Membranous labyrinth, 837
portion of urethra, 960
semicircular canals, 837
Meningeal artery, from ascending pharyngeal, 520
anterior, from internal carotid, 530
lymphatics, 641
middle, from internal maxillary, 523
from occipital, 520
posterior, from vertebral, 548
small, from internal maxillary, 523
veins, 616, 662
Meninges. See *Membranes.*
Menisci, 52
[Menstrual organ, 983]
Mental eminence, 213
foramen, 198, 213
process, 198
Mesencephalon, 119
Mesenteric artery, inferior, 579
superior, 577
glands, 649
plexus of nerves, inferior, 796
superior, 796
vein, inferior, 634
superior, 634
Mesenteries, 867
Mesoblast, 102
Mesocæcum, 868
Mésocéphale, 669
Mesocolon, ascending, 868
descending, 868
transverse, 869
Mesonephros, 133
Mesorchium, 135
Mesorectum, 869
Mesovarium, 135
Metacarpal artery, 564
articulations, 340
Metacarpo phalangeal articulations, 340
Metacarpus, 255
common characters of, 255
development of, 259
peculiar bones of, 256
Metanephros, 133
Metatarsal articulations, 361
artery, 606
bones, 291
Metatarso-phalangeal articulations, 391
Metatarsus, 261
development of, 294
Metencephalon, 119
Middle clinoid processes, 176
ear, or tympanum, 826
fossa of skull, 206
meatus, 218, 804
Mid-frontal process (fœtal), 117
Milk teeth, 843
Mitral valve, 912
Mixed bones, 142
lateral column, 658
[Model, use of the living, 33]
Modiolus of cochlea, 833
Molar glands, 840
teeth, 841
teeth, peculiar, 842
Monro, foramen of, 699, 702
Mons Veneris, 976
Monticulus cerebelli, 709
Morgagni, hydatid of, 127

Morgagni—
sinus of, 393
Morsus diaboli, 984
Motor oculi nerve, 718
Mouth, 839
landmarks of, 1030
mucous membrane of, 839
muscles of, 375
Movement admitted in joints, 300
Mucilaginous glands, 297
Mucoid cellular tissue, 48
Mucous glands of tongue, 800
membrane, 96
Müller, duct of, 133
fibres of, 816
Multicuspidati teeth, 841
Multifidus spinæ muscle, 409
Muscle, general anatomy of, 64
of animal life, 64
arrangement of fibres of, 64
bipenniform, 362
blood-vessels of, 67
derivation of names, 363
development of, 124
fasciculi of, 64
fibrils of, 65
form of, 362
involuntary, 67
lymphatics of, 67
meaning of the terms "origin" and "insertion," 363
mode of connection of, with bone, cartilage, skin, etc., 364
nerves of, 67, 76
of organic life, 76
penniform, 362
radiated, 362
sarcous elements of, 65
sheath of, 64
size of, 362
striped, 64
structure of, 64
tendons of, 364
unstriped, 67
voluntary, 64
Muscles or muscle, descriptive anatomy: of abdomen, 412
abductor minimi digiti (hand), 455
(foot), 490
indicis, 456
pollicis (hand), 452
(foot), 489
accelerator urinæ, 1013
accessorii orbicularis oris, 377
accessorius pedis, 491
ad sacro-lumbalem, 406
adductor brevis, 471
longus, 470
magnus, 471
pollicis (hand), 454
(foot), 492
anconeus, 447
antitragicus, 854
arytæno-epiglottideus, inferior, 926
superior, 926
arytænoideus, 924
attollens aurem, 369
attrahens aurem, 369
azygos uvulæ, 395
basio-glossus, 390
biceps (arm), 436
(thigh), 477

Muscles or muscle—
biventer cervicis, 408
brachialis anticus, 437
buccinator, 377
[bulbo-cavernosus, 1014, 1015]
cervicalis ascendens, 406
chondro-glossus, 391
ciliary of eye, 812
circumflexus palati, 394
coccygeus, 1018
cochlearis, 835
complexus, 408
compressor narium minor, 374
nasi, 374
sacculi laryngis, 926
urethræ, 1017
constrictor isthmi faucium, 396
pharyngis inferior, 392
medius, 393
superior, 393
urethræ, 1017
[vaginæ, 1015]
coraco-brachialis, 436
corrugator supercilii, 370
cutis ani, 1011
of cranial region, 366
[cremaster, 975, 994]
crico-arytænoideus lateralis, 925
posticus, 924
crico-thyroid, 924
crureus, 468
[deep transversus perinæi, 1015]
deltoid, 432
depressor anguli oris, 376
alæ nasi, 374
epiglottidis, 926
labii inferioris, 376
[urethræ, 1015]
diaphragm, 422
digastric, 388
dilatator naris, anterior, 374
posterior, 374
[electrical points for, 496]
erector clitoridis, 1015
penis, 1014
spinæ, 406
[of expression, 365]
of external ear, 369
external sphincter, 1011
extensor brevis digitorum, 489
carpi radialis brevior, 444
longior, 444
ulnaris, 446
coccygis, 410
digitorum communis, 446
indicis, 448
longus digitorum, 480
minimi digiti, 446
ossis metacarpi pollicis, 447
primi internodii pollicis, 447
proprius pollicis, 480
secundi internodii pollicis, 448
of face, 369
[peculiarities of, 365]
femoral region, anterior, 465
internal, 470
posterior, 477
fibular region, 486
flexor accessorius, 491
brevis minimi digiti (hand), 455
(foot), 492

Muscles or muscle—
flexor brevis digitorum, 490
pollicis (hand), 454
(foot), 492
carpi radialis, 440
ulnaris, 441
digitorum sublimis, 441
longus digitorum, 485
pollicis (hand), 442
(foot), 484
ossis metacarpi pollicis, 453
profundus digitorum, 442
gastrocnemius, 482
gemellus superior, 476
inferior, 476
genio-hyo-glossus, 390
genio-hyoid, 389
gluteus maximus, 473
medius, 474
minimus, 474
gracilis, 470
of hand, 452
of head and face, 365
helicis, major, 824
minor, 824
Hilton's, 926
[Horner's, 371, 822]
[how to ascertain action of, 363]
of hip, 472
hyo-glossus, 390
iliac region, 462
iliacus, 464
ilio-costalis, 406
infracostal, 420
infraspinatus, 434
intercostal, 420
internal sphincter, 1011
interossei of foot, 493
of hand, 455
interspinales, 410
intertransversales, 410
[Jarjavay's, 1015]
kerato-glossus, 390
labial, 375
of larynx, 924
latissimus dorsi, 401
of leg, 479
levator anguli oris, 375
ani, 1017
glandulæ thyroideæ, 940
labii inferioris, 376
superioris, 374
superioris alæque nasi, 374
menti, 376
palati, 394
palpebræ, 371
prostatæ, 1018
scapulæ, 403
[uvulæ, 395]
levatores costarum, 421
[ligamentous action of, 301]
lingualis, 391
longissimus dorsi, 406
longus colli, 398
lumbricales (hand), 455
(foot), 491
masseter, 378
[of mastication, 365]
multifidus spinæ, 409
musculus accessorius ad sacro-lumbalem, 406
mylo-hyoid, 389
naso-labialis, 377
of neck, 381

Muscles or muscle—
  obliquus auris, 824
    abdominus externus, 412
      internus, 414
    capitis superior, 411
      inferior, 410
  obturator, externus, 476
    internus, 475
  occipito-frontalis, 366
  oculi, inferior, 373
    superior, 373
  omo-hyoid, 387
  opponens minimi digiti, 455
    pollicis, 453
  orbicularis oris, 377
    palpebrarum, 370
  of orbit, 371
  palate, 394
  palato-glossus, 396
  palato-pharyngeus, 396
  palmaris brevis, 454
    longus, 441
  pectineus, 470
  pectoralis, major, 427
    minor, 429
  of perineum, male, 1014
    female, 1015
  peroneus brevis, 486
    longus, 486
    tertius, 481
  of pharynx, 392
  plantaris, 483
  platysma myoides, 382
  popliteus, 484
  pronator quadratus, 443
    radii teres, 440
  psoas magnus, 463
    parvus, 464
  pterygoid, internal, 381
    external, 380
  pyramidalis abdominis, 418
    nasi, 374
  pyriformis, 475
  quadratus femoris, 476
    lumborum, 418
    menti, 376
  quadriceps extensor cruris, 467
  rectus abdominus, 417
    capitis anticus major, 397
        minor, 397
    externus, inferior, and internus, 372
    femoris, 467
    lateralis, 398
    oculi, superior, 371
    posticus major, 410
      minor, 410
  retrahens aurem, 369
  rhomboideus major, 403
    minor, 403
  risorius, 378
  rotatores spinæ, 409
  sacro-lumbalis, 406
  sartorius, 467
    landmarks of, 1050
  scalenus anticus, 398
    medius, 398
    posticus, 398
  semimembranosus, 478
  semispinalis dorsi, 409
    colli, 409
  semitendinosus, 478
  serratus magnus, 430
    posticus, superior, 404
      inferior, 404

Muscles or muscle—
  sole of foot, 489
    first layer, 489
    second layer, 491
    third layer, 492
    fourth layer, 493
  soleus, 483
  sphincter, external, 1011
    internal, 1011
    vaginæ, 1015
  spinalis dorsi, 408
    colli, 408
  splenius, 405
    capitis, 405
    colli, 405
  stapedius, 831
  sterno-cleido-mastoid, 385
    landmarks of, 1033
  sterno-hyoid, 386
  sterno-thyroid, 386
  [structure of, 363]
  stylo-glossus, 392
  stylo-hyoid, 388
  stylo-pharyngeus, 394
  subanconeus, 438
  subclavius, 429
  subcrureus, 469
  subscapularis, 433
  supinator brevis, 447
    longus, 444
  supraspinales, 410
  supraspinatus, 433
  temporal, 379
  tensor-palati, 394
  tarsi, 371
  tympani, 830
    vaginæ femoris, 466
  teres major, 435
    minor, 434
  thyro-arytænoideus, 925
  thyro-epiglottideus, 926
  thyro-hyoid, 387
  tibialis anticus, 479
    posticus, 485
  of tongue, 389
  trachelo-mastoid, 408
  tragicus, 824
  transversalis abdominis, 415
    colli, 406
  transversus auriculæ, 824
    pedis, 492
    perinæi, 1014
      (female), 1015
  trapezius, 400
  triangularis sterni, 420
  triceps, extensor cubiti, 438
    extensor cruris, 468
    femoralis, 469
  of tympanum, 830
  of ureters, 957
  of urethra, 1014
  vastus externus, 468
    internus and crureus, 468
  zygomaticus major, 375
    minor, 375
Muscular fibres of heart, 66
[Muscularis mucosæ, 67, 877]
Musculi papillares, left ventricle, 912
    right, 910
  pectinati in left auricle, 911
    in right, 909
Musculo-cutaneous nerve of arm, 756
    from peroneal, 783
Musculo-spiral nerve, 762
Musculo-phrenic artery, 552
Musculus accessorius ad sacrolumbalem, 406
  suspensorius duodeni, 876, *note*
Mylo-hyoid artery, 523
  groove, 199
  muscle, 389
  nerve, 729
  ridge, 199
Myrtiform fossa, 186

N.

Nails, 92
Nares, anterior, 215
    posterior, 856
  landmarks of, 1031
  septum of, 217, 803
Nasal angle, 185
  artery, of internal maxillary, 524
    of ophthalmic, 531
    of septum, 518
  bones, 185
    articulations of, 186
    development of, 185
  cartilages, 802
  crest, 185
  duct, 822
  eminence, 168, 213
  fossæ, 215, 803
    arteries of, 804
    landmarks of, 1029
    mucous membrane of, 804
    nerves of, 805
    veins of, 805
  groove, 185
  nerve, 721
  nerves from Meckel's ganglion, 726
  notch, 168
  process, 189
  spine, 168
    anterior, 190
    posterior, 193
  venous arch, 613
[Nasion, 684]
Nasmyth's membrane, 847
Naso-maxillary suture, 213
Naso-palatine nerve, 726
Nates of brain, 702
[Necessity, triangle of, 525]
Neck, glands of, 642
  landmarks of, 1031
  lymphatics of, 642
  muscles of, 381
  triangle of, anterior, 525
    posterior, 527
  veins of, 615
    landmarks of, 1032
[Nélaton's line, 272]
    landmarks of, 1049
Nerve-corpuscles, 69
Nerves, general anatomy of, 72
  cerebro-spinal, 73
  funiculi of, 73
  neurilemma of, 73
  origin of, 74
  plexus of, 73
  sheath of, 73
  spinal roots of, 744
  subdivision of, 72
  termination of, 74
  vessels of, 73

Nerves—
  of special sense, 716
Nerves or nerve, descriptive anatomy of: abducens, 731
 accessory obturator, 773
 acromiales, 751
 anterior crural, 773
 auditory, 736
  auricular, posterior, 735
   of vagus, 740
  auricularis magnus, 750
  of auriculo-temporal, 728
  of second cervical, 747
  of small occipital, 750
 of brachial plexus, 752
 buccal, 728
  of facial, 736
 cardiac, 790
   inferior, 791
   middle, 790
   superior, 790
  plexus, deep, 792
   superficial, 793
  of pneumogastric, 739
 cavernous, of penis, 797
 cervical anterior, 749
  posterior, 747
  superficial, 750
 cervico-facial, 736
 chorda tympani, 734, 831
 ciliary, long, 722
  short, 722
 circumflex, 756
 claviculares, 751
 coccygeal, 776
 cochlear, 838
 communicans noni, 752
  peronei, 782
 of Cotunnius, 726
 cranial, 715
 crural anterior, 773
 cutaneous. See that heading.
 deep palmar, 762
  temporal, 728
 dental anterior, 725
  inferior, 729
  posterior, 724
 descendens noni, 743
 digastric, from facial, 735
 digital (foot), 782, 783
 dorsal (hand), 764
  peculiar, 767
  of penis, 778
  spinal, 764
 dorsi-lumbar, 767
 of dura mater, 662
 eighth pair, 736
 eleventh pair, 741
 of eyeball, 717
 facial, 732
 fifth, 719
 fourth, 719
 frontal, 721
 ganglionic branch of nasal, 722
 gastric branches of vagus, 795
 genito-crural, 770
 glosso-pharyngeal, 736
 gluteal, inferior, 780
  superior, 778
 great petrosal, 727
 great splanchnic, 791
 gustatory, 729
 hemorrhoidal, inferior, 796

Nerves or nerve—
  of heart. See *Cardiac.*
 hepatic, 791
 hypoglossal, 742
 ilio-hypogastric, 769
 ilio-inguinal, 770
 incisor, 729
 inferior maxillary, 727
 inframaxillary, of facial, 736
 infraorbital of facial, 735
 infra trochlear, 722
 intercostal, 766
 intercosto-humeral, 766
 interosseous, anterior, 759
  posterior, 764
 ischiadic, great, 780
  small, 779
 Jacobson's, 738
 labial, 725
 of labyrinth, 838
 lachrymal, 721
 of Lancisi, 692
 large cavernous, 797
 laryngeal, external, 740
  internal, 740
  recurrent, 740
  superior, 740
 lesser splanchnic, 791
 lingual of fifth, 729
  of glosso-pharyngeal, 738
 long ciliary, 722
  saphenous, 774
  thoracic, 754
 lumbar, 767
 lumbo-sacral, 768
 malar branch of orbital nerve, 723
  of facial, 735
 masseteric, 727
 maxillary, inferior, 727
  superior, 723
 median, 759
 mental, 729
 middle cardiac, 790
 motor of the eye, common, 718
  external, 730
 musculo-cutaneous of arm, 756
  leg, 783
 musculo-spiral, 763
 mylo-hyoid, 729
 nasal, ophthalmic, 721
  from Meckel's ganglion, 727
  from Vidian, 727
 naso-palatine, 726
 ninth, 736
 obturator, 770
 occipital, great, 747
  small, 750
  of facial, 735
  of third cervical, 747
 œsophageal, 741
 olfactory, 716
 ophthalmic, 720
 optic, 717
 orbital nerves, their relation, 731
  in cavernous sinus, 732
  in orbit, 732
  in sphenoidal fissure, 732
 orbital of superior maxillary, 723
 palatine, anterior or large, 725
  external, 726
  posterior or small, 726

Nerves or nerve—
 palmar, cutaneous, of median, 759
  ulnar, 761
 palpebral, 725
 par vagum, 738
 pathetic, 719
 perforans Casserii, 756
 perineal, 778
  superficial, 780
 peroneal, 782
  landmarks of, 1053
 petrosal, superficial, external or large, 727, 733
  small, 733
 pharyngeal, of pneumogastric, 740
  of glosso-pharyngeal, 738
  of sympathetic, 790
  of Meckel's ganglion, 727
  of external laryngeal, 740
 phrenic, 752
 plantar, cutaneous, 781
  external, 782
  internal, 781
 pneumogastric, 738
 popliteal, external, 782
  internal, 780
 portia inter duram et mollem, 733
 portio dura, 732
  mollis, 736
 posterior auricular, 735
 pterygoid, 728
 pterygo-palatine, 727
 pudendal, inferior, 780
 pudic, 778
 pulmonary, from vagus, 741
 radial, 763
 recurrent laryngeal, 740
 recurrent to tentorium, 719
 renal splanchnic, 719
 respiratory, external, 754
  internal, 752
 sacral, 775
  plexus, 777
 saphenous, long or internal, 774
  short or external, 781
 sciatic, great, 780
  small, 779
 short ciliary, 723
 sixth, 731
 small cavernous, 797
 spheno-palatine, 726
 spinal, 744
  accessory, 741
 splanchnic, great, 791
  small, 791
  smallest, 791
 sternales, 751
 stylo-hyoid of facial, 735
 subclavian, 754
 suboccipital, 747
  posterior branch of, 748
 subscapular, 755
 superficialis colli, 750
 superior cardiac, 790
  maxillary, 723
 supraclavicular, 751
 supramaxillary of facial, 736
 supraorbital, 721
 suprascapular, 755
 supratrochlear, 721
 sympathetic, 784

Nerves or nerve—
  temporal, deep, 728
    of facial, 735
  of auriculo-temporal, 728
  temporo-facial, 735
  temporo-malar, 723
  tenth, 738
  third, or motor oculi, 718
  [thirteenth cranial, 735]
  thoracic posterior, 754
    anterior, 755
  thyro-hyoid, 743
  tibial, anterior, 782
    posterior, 781
  of tongue, 801
  tonsillar, 738
  trifacial or trigeminus, 719
  trochlear, 719
  twelfth, 742
  tympanic, of glosso-pharyngeal, 737, 831
    of facial, 734
  ulnar, 761
  uterine, 797
  vaginal, 797
  vagus, 738
  vestibular, 838
  Vidian, 727
  of Wrisberg, 757
Nervous substance, chemical analysis, 71
    gelatinous, 68
    gray, 68
    white, 69
  layer of retina, 814
Nervous system, general anatomy of, 68
  fibrous nervous matter, 69
    ganglia, 77
  gelatinous fibres, 68
  gray or cineritious substance, 68
  sympathetic, 71
    composition of, 71
  vesicular nervous matter, 68
  white or medullary substance, 69
Nervus cardiacus magnus, 790
    minor, 791
  superficialis cordis, 790
Neurilemma, 73
  of cord, 654
Neural crest, 120
Neuroglia, 72
  of cord, 656
Nidus hirundinis, of cerebellum, 710
Ninth nerve, 936
Nipple, 988
  landmarks of, 1034
Nodes of Ranvier, 70
Nodule of cerebellum, 710
Noduli Arantii, 910, 912
Non-medullated nerve-fibres, 71
Nose, 801
  arteries of, 803
  bones of, 185
  cartilages of, 802
  cartilage of septum of, 803
  development of, 123
  fossæ of, 215, 803
  landmarks of, 1029
  mucous membrane of, 803
  muscles of, 374
  nerves of, 803
Nose—
  veins of, 803
Nostrils, landmarks of, 1029
Notch, cotyloid, 265
  ethmoidal, 169, 181
  intercondyloid, 274
  nasal, 168
  pterygoid, 179
  sacro-sciatic, greater, 263
    lesser, 263
  sigmoid, 200
  spheno-palatine, 195
  supraorbital, 167
  suprascapular, 235
Notochord, 106, 114
Nucleus amygdalæ, 694
  caudatus, 693
  lenticularis, 693
Nuck, canal of, 975, 988
Nutrient artery of bone, 55
Nymphæ, 976
  lymphatics of, 648

O.

[Obelion, 685]
Oblique inguinal hernia, 998
    coverings of, 998
  ligament, 333
  line of the clavicle, 230
    of lower jaw, 199
    of radius, 248
Obliquus auris muscle, 824
  externus abdominis, 412
    internus, 414
  inferior capitis, 410
    superior, 411
  inferior oculi, 373
    superior, 372
Obturator artery, 587
    peculiarities of, 587
    relation of, to femoral ring, 1007
  externus muscle, 476
    internus, 475
  fascia, 1022
  foramen, 266
  ligament or membrane, 475
  nerve, 770
    accessory, 773
  veins, 632
Occipital artery, 519
  bone, 160
    articulations of, 164
    attachment of muscles to, 164
    development of, 164
  crests, 160, 163
    protuberances, 160, 163
  fossæ, 162
  lobe, 677
  lymphatic glands, 640
    groove, 172
  sinus, 620
  triangle, 527
  vein, 615
Occipitalis major nerve, 747
  minor, 750
Occipito-atloid articulation, 309
Occipito-axoid articulation, 309
Occipito-frontalis muscle, 366
Occiput, arteries of, 519
Ocular cleft, 121
  cup, 121
  vesicle, primitive, 121
    secondary, 121
Odontoblasts, 848
Odontoid ligaments, 310
    tubercle for, 161
  process of axis, 146
Œsophageal arteries, 571
  branches of vagus nerve, 741
  glands, 856
  opening of, diaphragm, 424
  plexus, 741
Œsophagus, 857
  lymphatics of, 651
  structure of, 857
  surgical anatomy of, 857
Olecranon process, 243
    fracture of, 459
    landmarks of, 1058
Olfactory bulb, 716
  cells, 804
  foramina, 181
  fossæ (fœtal), 123
  nerve, 716
Olivary bodies of medulla oblongata, 666, 667
  fasciculus, 667
  process, 176
Omenta, 867
Omentum, gastro-colic, 867
  gastro-hepatic, 867
  gastro-splenic, 867
  great, 867
  lesser, 867
Omo-hyoid muscle, 387
Omphalo-mesenteric arteries, fœtal, 125
  duct, 108
  veins, 125
Opening of aorta in left ventricle, 912
  aortic, in diaphragm, 424
  caval, in diaphragm, 424
  of coronary sinus, 908
  of inferior cava, 908
  left auriculo-ventricular, 911
  œsophageal in diaphragm, 424
  of pulmonary artery, 909
    veins, 911
  right auriculo-ventricular, 909
  saphenous, 466, 1003
    landmarks of, 1048
  of superior cava, 908
Operation for club-foot, 487
  of laryngotomy, 930
  of laryngo-tracheotomy, 930
  of lithotomy, 1020
  of œsophagotomy, 858
  of staphylorraphy, 396
  for strabismus, 374
  tracheotomy, 930
  for wry-neck, 386
  ligature of arteries. See Surgical Anatomy of each.
[Ophryon, 684]
Ophthalmic artery, 530
  ganglion, 722
  nerve, 720
  vein, 621
Opponens minimi digiti muscle, 455
  pollicis muscle, 453
Optic commissure, 717
  foramen, 176, 206
  groove, 176
  lobes, 703
  nerve, 717
    inter-retinal fibres, 717

Optic thalami, 699
  tract, 717
Ora serrata, 813
Orbicular bone, 830
  ligament, 333
Orbicularis ciliaris, 371
  latus, 371
  oris muscle, 377
  palpebrarum, 370
Orbit, 214
  arteries of, 531
  muscles of, 371
  relation of nerves in, 732
Orbital artery, 524
  foramina, 179
  lobe, 676
  nerve, 723
  process of malar, 192
    of palate, 195
Organic constituent of bone, 59
Orifice, œsophageal of stomach, 869
  pyloric of stomach, 871
Os calcis, 284
    development of, 294
  hyoides, 219
  innominatum, 260
    development of, 266
  magnum of carpus, 254
  orbiculare, 830
  planum, 182
  unguis, 191
Os uteri, 981
Ossa triquetra, 184
Ossicula auditûs, 829
  ligaments of, 830
Ossification, period of, 63
  intracartilaginous, 59
  intramembranous, 63
  of bone, 59
  of spine, progress in, 152
Osteoblasts, 60
Osteoclasts, 62
Osteo-dentine, 846
Osteology, 141
Ostium abdominale of Fallopian tube, 991
  internum or uterinum, 984
  uteri internum, 981
Otic ganglion, 729
Otoliths, 838
Outlet of pelvis, 269
Ovarian arteries, 581
  plexus of nerves, 794
  veins, 634
Ovary, 984
  corpus luteum of, 987
  development of, 135
  Graafian vesicles of, 986
  ligament of, 988
  lymphatics of, 648
  nerves of, 989
  ovicapsule of, 986
  shape, position, and dimensions, 985
  stroma of, 984
  tunica albuginea of, 986
  vessels of, 989
Ovicapsule of Graafian vesicle, 986
Oviducts, 984
Ovisacs of ovary, 986
Ovula of Naboth, 983
Ovum, 99
  discharge of, 987
Ovum—
  discus proligerus of, 99
  fecundation of, 101
  germinal spot of, 100
  vesicle of, 100
  vitelline membrane of, 99
  yolk of, 100
  zona pellucida of, 99

P.

Pacchionian depressions, 165
  glands, 619, 662
Pacinian corpuscles, 75
Pad of corpus callosum, 692
Palatal glands, 850
Palate, arches of, 851
    development of, 117
  bone, 193
    articulations of, 196
    attachment of muscles to, 196
    development of, 195
    horizontal plate of, 193
    orbital process of, 195
    process of superior maxillary, 187
    sphenoidal process of, 195
    turbinated crest of, 194
    vertical plate of, 194
  hard, 850
  muscles of, 394
  soft, 850
Palatine artery, ascending, 517
    descending or posterior, 524
  canal, anterior, 189
    accessory, 193
    posterior, 193
  fossa, anterior, 189
  nerves, 726
  process of superior maxillary, 189
  veins, inferior, 614
Palato-glossus muscle, 392, 396
Palato-pharyngeus, 396
[Palm, lines in, 340]
Palmar arch, deep, 562
    superficial, 566
  cutaneous nerve, 759
  fascia, 450
  interossei arteries, 565
  nerve, deep, of ulnar, 762
    superficial, 762
  veins, 623
Palmaris brevis muscle, 454
  longus muscle, 441
Palm of hand, landmarks of, 1061
Palpebræ, 819
Palpebral arteries, 532
  cartilages, 819
  fissures, 819
  folds of conjunctiva, 821
  ligaments, 820
  muscles, 370
  veins, inferior, 614
    superior, 614
Pampiniform plexus of veins, 633, 968, 988
Pancreas, 897
  development of, 132
  landmarks of, 1045
  lymphatics of, 649
  structure of, 898
  [surgery of, 899]
Pancreas—
  vessels and nerves of, 899
Pancreatic arteries, 577
  duct, 898
  plexus of nerves, 794
  veins, 635
Pancreatica magna artery, 577
Pancreatico-duodenal artery, 577
    inferior, 577
  plexus of nerves, 794
  vein, 635
Papilla lachrymalis, 819, 822
  spiralis, 836
Papillæ of tooth, 846
  conicæ vel filiformes, 800
  conjunctival, 822
  fungiformes (mediæ), 799
  of kidney, 946
  maximæ (circumvallatæ), 799
  of skin, 91
  of tongue, 799
Papillary layer of skin, 91
[Paracentral lobule, 680]
Par vagum, 738
Parallel fissure, 677
Parietal bones, 164
    articulations of, 166
    attachment of muscles to, 166
    development of, 166
  eminence, 164
  foramen, 164
  lobe, 676
Parieto-occipital fissure, [676], 678, [687]
Parotid duct, 853
    landmarks of, 1028
  gland, 852
    accessory portion of, 853
    nerves of, 853
    vessels of, 853
  lymphatic glands, 640
  veins, 614
Parovarium, 136, 988
Patella, 277
  articulations of, 278
  attachment of muscles to, 278
  development of, 278
  fracture of, 495
  landmarks of, 1052
Pecquet, reservoir of, 639
Pectineus muscle, 470
Pectiniforme septum, 965
Pectoral region, dissection of, 427
Pectoralis major, 427
  minor, 429
Peculiar dorsal vertebræ, 149
Pedicles of a vertebra, 143
Peduncles of cerebellum, 711
  of cerebrum, 690, 706
  of corpus callosum, 692
  of pineal gland, 702
Pelvic fascia, 1021
    parietal or obturator layer, 1022
    visceral layer, 1022
  plexus, 796
Pelvis, 267, 955
  arteries of, 584
  articulations of, 319
  axes of, 269
  boundaries of, 268
  brim of, 268
  cavity of, 268
  diameters of, 269

Pelvis—
  false, 268
  inlet of, 268
  ligaments of, 319
  lymphatics of, 646
  male and female, differences of, 270
  outlet of, 269
  position of, 269
  position of viscera at outlet of, 1019
  true, 268
Pelvis of kidney, 945
  [to show rocking of, 352]
Penis, 964
  arteries of, 965
  body of, 964
  corpora cavernosa, 964
  corpus spongiosum, 966
  development of, 138
  dorsal artery of, 589
    nerve of, 778
    vein of, 632
  lymphatics of, 647, 966
  muscles of, 1014
  nerves of, 966
  prepuce of, 964
  root of, 964
  suspensory ligament, 964
Penniform muscle, 362
Perforans Casserii nerve, 756
Perforated space, anterior, 688
    posterior, 689
Perforating arteries, of hand, 565
    from mammary artery, 552
    plantar, 610
    profunda, 599
Pericardiac arteries, 552, 570
Pericardium, relations of, 904
  fibrous layer of, 905
  serous layer of, 905
  structure of, 905
  [surgery of, 906]
  vessels of, 906
  vestigial fold of, 626
Perilymph, 837
Perineal artery, superficial, 589
    transverse, 589
  fascia, deep, 1015
    superficial, 1013
  nerve, 778
    superficial, 778
Perineum, 1012
  abnormal course of arteries in, 1021
  deep boundaries of, 1012
  development of, 138
  landmarks of, 1046
  lymphatics of, 647
  muscles of, 1014
  surgical anatomy of, 1013
Perineurium, 73
Periosteum, 54
  of teeth, 841
[Peritoneum of fœtus, 863]
  greater cavity of, 862
  landmarks of, 1042
  lesser cavity of, 861, 865
  ligaments of, 867
  mesenteries of, 867
  omenta of, 867
  reflections traced, 863
Permanent cartilage, 50
  teeth, 841
Peroneal artery, 608
Peroneal artery—
  anterior, 609
  peculiarities of, 609
  nerve, 782
  veins, 631
Peroneus brevis muscle, 486
  longus, 486
  tertius, 481
Perpendicular plate of ethmoid, 181
Pes accessorius, 696
  hippocampi, 696
Petit, canal of, 818
Petro-occipital suture, 203
Petro-sphenoidal suture, 203
Petrosal nerve, superficial or large, from Vidian, 727
    external, 733
    small, 733
  sinus inferior, 622
    superior, 622
Petrous ganglion, 737
  portion of temporal bone, 173
Peyer's glands, 880
Phalanges, hand, 257
    articulations of, 258, 341
    development of, 259
  foot, 292
    articulations of, 293, 361
    development of, 294
[Phalangette, 258]
[Phalangine, 258]
[Phalanx, 258]
Pharyngeal aponeurosis, 856
  arches, 116
  artery, ascending, 520
  clefts, 116
  ganglion, 790
  glands, 856
  nerve, from external laryngeal, 740
    from glosso-pharyngeal, 738
    from Meckel's ganglion, 727
    from sympathetic, 789
    from vagus, 740
  plexus of nerves, 740, 789
  spine, 162
  tonsil, 857
  vein, 616
Pharynx, 856
  aponeurosis of, 856
  arteries of, 520
  development of, 130
  mucous membrane of, 856
  muscles of, 393
Phleboliths, 632
Phrenic arteries, 581
  nerve, 752
  plexus of nerves, 794
  veins, 634
Pia mater, of brain, 664
  of cord, 654
  testis, 970
Pigment, 50
  of iris, 811
  of skin, 90
Pigmentary layer of retina, 815
Pillars of external abdominal ring, 414, 993
  of diaphragm, 424
  of fauces, 851
  of fornix, 699
Pineal gland, 702
  penduncles of, 702
Pinna of ear, 823
Pinna of ear—
    ligaments of, 823
    muscles of, 824
    nerves of, 824
    vessels of, 824
Pisiform bone, 252
Pit of stomach, landmarks of, 1041
Pituitary body, 689
    development of, 119
  fossa, 176
  membrane, 803
Placenta, 113
Placental sinus, 113
  circulation, 126
Plantar artery, external, 610
    internal, 610
  cutaneous nerve, 781
  fascia, 488
  ligaments, 359
  nerve, external, 782
    internal, 781
  veins, external, 631
    internal, 631
Plantaris muscle, 483
Plasma, 38
Platysma myoides, 382
Pleura, 931
  cavity of, 931
  costalis, 931
  pulmonalis, 931
  reflections of, traced, 931
  vessels and nerves of, 932
Plexus of nerves, 73
  aortic, 796
  brachial, 752
  cardiac, deep, 792
    superficial, 793
  carotid, 789
    external, 789
  cavernous, 789
  cervical, 749
    posterior, 747
  cœliac, 794
  colic, left, 796
    middle, 796
    right, 796
  coronary, anterior, 793
    posterior, 793
  cystic, 794
  diaphragmatic, 794
  epigastric or solar, 793
  facial, 790
  gastric, 794
  gastro-duodenal, 794
  gastro-epiploic, 794
    left, 794
  great cardiac, 792
  hemorrhoidal superior, 796
    inferior, 796
  hepatic, 795
  hypogastric, 796
    inferior, 796
  ileo-colic, 796
  infraorbital, 725
  lumbar, 768
  meningeal, 790
  mesenteric, inferior, 796
    superior, 796
  œsophageal, 741
  ophthalmic, 789
  ovarian, 794
  pancreatic, 794
  pancreatico-duodenal, 794
  patellæ, 774

Plexus—
  pharyngea., 740, 790
  phrenic, 794
  prostatic, 796
  pulmonary, anterior, 741
    posterior, 741
  pyloric, 794
  renal, 794
  sacral, 777
  sigmoid, 796
  solar, 793
  spermatic, 794
  splenic, 794
  superficial cardiac, 793
  suprarenal, 794
  tonsillar, 738
  tympanic, 737
  vaginal, 797
  vertebral, 791
  vesical, 796
Plexus of veins. See *Veins.*
Plica semilunaris, 821
Pneumogastric lobule of cerebellum, 710
  nerve, 738
Polar globules of Robin, 100
Pomum Adami, 919
    landmarks of, 1032
Pons hepatis, 891
  Tarini, 689
  Varolii, 669
Popliteal artery, 599
  branches of, 602
  lymphatic glands, 645
  nerve, external, 782
    internal, 780
  peculiarities of, 601
  space, 600
  surgical anatomy of, 601
  vein, 631
Popliteus muscle, 484
Pores of the skin, 94
Portal canals, 892
  fissure, 891
  vein, 636, 892, 894
Portio dura of seventh nerve, 732
  inter duram et mollem, 733
  mollis, 736
Porus opticus of sclerotic, 806
Posterior. See *under each separate head.*
Posterior glenoid process, 171
  vesicular column, 660
Post-oral arches (fœtal), 117
Pott's fracture, 495
Pouch of Douglas, 981
Pouches, laryngeal, 924
Poupart's ligament, 412, 993, 1003
    landmarks of, 1043
Præputium clitoridis, 976
Prævertebral fascia, 385
Precentral fissure, 676
  [sulcus, 676, 686]
Prepuce, 964
Primitive trace, 102
  otic vesicle, 122
  sheath of nerve-fibre, 70
Princeps cervicis artery, 519
  pollicis artery, 564
Processes or process, acromion, 235
  alveolar, 189
  angular, external, 168

Processes or process—
  angular, internal, 168
  auditory, 173
  basilar, 162
  ciliary, 810
  clinoid, anterior, 179
    middle, 176
    posterior, 177
  cochleariform, 175, 828
  condyloid of lower jaw, 200
  coracoid, 236
  coronoid of lower jaw, 200
    of ulna, 243
  ethmoidal of inferior turbinated, 196
  frontal of malar, 192
  hamular of lachrymal, 191
    of sphenoid, 179
  of helix, 823
  of Ingrassias, 179
  jugular, 161
  lachrymal of inferior turbinated bone, 196
  malar, 189
  of malar bone, 193
  mastoid, 171
    landmarks of, 1027
  maxillary of inferior turbinated, 196
  mental, 198
  nasal, 189
  odontoid of axis, 146
  olecranon, 243
  olivary, 176
  orbital of malar, 192
  of palate, 195
  palatine of superior maxillary, 189
  post-glenoid, 171
  pterygoid of palate bone, 194
    of sphenoid, 180
  sphenoidal of palate, 195
  spinous of tibia, 174
    of ilium, 263
    of sphenoid, 178
  styloid of temporal, 174
    of ulna, 247
    of radius, 249
  unciform, 255
    of ethmoid, 182
  vaginal of sphenoid, 178
    of temporal, 174
  vermiform of cerebellum, 710
  zygomatic, 193
Processus ad medullam, 711
  ad pontem, 711
  brevis of malleus, 829
  clavatus, 667
  cochleariformis, 175, 828
  e cerebello ad testes, 711
  gracilis of malleus, 829
Profunda cervicis artery, 552
  femoris artery, 588
  inferior artery of arm, 561
    superior, 561
  vein, 631
Promontory of tympanum, 827
  of sacrum, 153
Pronator quadratus muscle, 443
  radii teres muscle, 440
Pronephros, 133
Pronucleus, female, 100
  male, 101
Prosencephalon, 119
Prostate gland, 962

Prostate gland—
    landmarks of, 1047
    levator muscle of, 963, 1018
    lobes of, 963
    lymphatics of, 648
    surgical anatomy of, 1019
    vessels and nerves of, 963
Prostatic plexus of nerves, 796
    of veins, 632
  portion of urethra, 959
  sinus, 959
Protoplasm, 41
Protovertebræ, 106
Protovertebral somites, 106
Protuberance, occipital, external, 160
    internal, 163
    landmarks of, 1027
Psoas magnus muscle, 463
  parvus, 464
[Pterion, 684]
Pterygo-maxillary fissure, 212
  ligament, 378
Pterygo-palatine artery, 524
  canal, 178
  nerve, 727
Pterygoid arteries, 524
  fossa of sphenoid, 179
    of lower jaw, 200
  muscles, 380
  nerve, 728
  notch, 179
  plexus of veins, 614
  process of palate bone, 194
  processes of sphenoid, 179
  ridge, 178
Pubes, 264
  angle of, 265
  crest of, 265
  landmarks of, 1043
  spine of, 264
  symphysis of, 265, 321
Pubic arch, 269
    articulations of, 321
    portion of fascia lata, 466
Pubo-prostatic ligaments, 957
Pudendum, 976
Pudic artery in male, 588
      peculiarities of, 588
    accessory, 587
    deep external, 598
    in female, 589
    superficial external, 598
  nerve, 778
  vein, external, 630
    internal, 632
Pulmonary artery, 502, 937
    opening of, in right ventricle, 909
  capillaries, 937
  nerves from vagus, 741
  sinuses, 911
  veins, 611, 612, 937
    openings of, left auricle, 911
Pulp-cavity of tooth, 843
  of teeth, development of, 848
Pulp of spleen, 900
Pulse at wrist, landmarks of, 1060
Puncta vasculosa, 690
  lachrymalia, 822
    landmarks of, 1029
Pupil of eye, 810
  membrane of, 812
Purkinje, axis-cylinder of, 70

d by Go

Pyloric artery, 575
inferior, 576
plexus, 794
Pylorus, 871
landmarks of, 1045
Pyramid in vestibule, 832
of cerebellum, 710
of thyroid gland, 940
of tympanum, 827
Pyramidalis muscle, 418
nasi, 374
Pyramids, anterior, 666
decussation of, 666
of Ferrein, 948
of Malpighi, 946
of the spine, 158
posterior, 666
Pyriformis muscle, 475

Q.

Quadrate lobe, 680
Quadratus femoris muscle, 476
lumborum, 418
menti, 376
Quadriceps extensor cruris muscle, 467
Quadrigeminal bodies, 702

R.

Racemose glands, 97
Radial artery, 562
branches of, 563
peculiarities of, 563
surgical anatomy of, 563
lymphatic glands, 643
nerve, 793
recurrent artery, 564
region, muscles of, 444
vein, 623
Radialis indicis artery, 564
Radio-carpal articulation, 335
Radio-ulnar articulations, inferior, 333
middle, 333
superior, 333
Radius, 248
and ulna, fracture of, 460
articulations of, 250
development of, 249
fracture of, 460
grooves in lower end of, 249
landmarks of, 1059
muscles attached to, 250
oblique line of, 248
sigmoid cavity of, 249
tuberosity of, 248
Rami of the lower jaw, 199
Ramus of ischium, 264
descending, 265
horizontal of pubes, 265
of pubes, 265
Ranine artery, 516
vein, 614, 616
Ranvier, nodes of, 70
Raphé of corpus callosum, 692
of palate, 850
of perineum, 1013
landmarks of, 1046
of tongue, 799
Receiving-tubes of kidney, 948
Receptaculi arteriæ, 530
Receptaculum chyli, 639
Recessus labyrinthi, 122
Recto-uterine ligaments, 981
Recto-vesical fascia, 1022
fold, peritoneal, 957
Rectum, 886
development of, 130
relations of, male, 886
female, 886, 979
folds of, 887
landmarks of, 1047
lymphatics of, 648
palpation by, 1062
Rectus abdominis, 417
capitis anticus major, 397
minor, 397
femoris muscle, 467
lateralis, 398
oculi, internus, superior, inferior, and externus, 272
posticus major, 410
minor, 410
Recurrent artery, interosseous, 568
radial, 564
tibial, 605
ulnar, anterior, 567
posterior, 567
laryngeal nerve, 740
nerves to tentorium, 719
Region, abdominal, 411
acromial, muscles of, 432
auricular, 369
back, muscles of, 399
brachial, anterior, 442
posterior, 446
cervical superficial, muscles of, 382
diaphragmatic, 422
epicranial, muscles of, 366
epigastric, 860
femoral, muscles of, anterior, 465
internal, 470
posterior, 477
fibular, 486
foot, dorsum of, 489
sole of, 489
gluteal, muscles of, 472
groin, 991
of hand, muscles of, 462
humeral, anterior, 435
posterior, 438
hypochondriac, 860
hypogastric, 860
iliac, muscles of, 462
infrahyoid, 386
inguinal, 991
intermaxillary, muscles of, 377
ischio-rectal, 1010
laryngo-tracheal, surgical anatomy of, 930
lingual, muscles of, 389
lumbar, 860
maxillary, muscles of, inferior, 376
superior, 375
nasal, muscles of, 374
orbital, muscles of, 371
palatal, muscles of, 394
palpebral, 369
perineum, 1012
pharyngeal, muscles of, 392
popliteal, 599
pterygo-maxillary, muscles of, 380
radial, muscles of, 444
Region—
scapular, muscles of, anterior, 433
posterior, 433
Scarpa's triangle, 594
suprahyoid, muscles of, 388
temporo-maxillary, muscles of, 378
thoracic, 419
anterior, 427
lateral, 430
tibio-fibular, anterior, 479
posterior, 481
umbilical, 860
vertebral, muscles of, anterior, 397
lateral, 398
Regions of abdomen, 859
Reil, island of, 677
Renal afferent vessels, 947, 951
artery, 580, 949
efferent vessels, 947, 951
plexus, 794
veins, 634, 951
Respiration, organs of, 919
muscles of, 421
Respiratory nerves of Bell, external, 754
internal, 752
Restiform bodies of medulla oblongata, 666, 668
Rete mucosum of skin, 89
Malpighii, 90
testis, 971
Reticular cartilage, 53
layer of skin, 91
lamina of Kölliker, 836
Retiform connective tissue, 48
Retina, 812
arteria centralis of, 532, 816
fovea centralis of, 813
limbus luteus of, 813
membrana limitans of, 813
layers of, 813
structure of, 813
Retinacula of ileo-cæcal valve, 883
Retrahens aurem muscle, 369
Rhomboid impression, 231
ligament, 323
Rhomboidal sinus, 118
Rhomboideus, major, 403
minor, 403
Ribs, 224
angle of, 226
articulations of, 312
attachment of muscles to, 228
development of, 228
false, 224
floating, 225
head of, 225
landmarks of, 1034
ligaments of, 313
neck of, 225
peculiar, 226
true, 224
tuberosity of, 225
vertebral, 225
vertebro-chondral, 225
vertebro-sternal, 224
Ridge, internal occipital, 162
mylo-hyoidean, 199
pterygoid, 178
superciliary, 167
temporal, 170, 211

d by Google

Rima glottidis, 923
Ring, abdominal, external, 413, 993
internal, 996
landmarks of, 1043
femoral or crural, 1006
landmarks of, 1048
fibrous, of heart, 913
Risorius muscle, 378
Rivini, ducts of, 854
Rods of Corti, 836
Rolando, tubercle of, 669
[fissure of, 675, 685]
Root of lung, 936
Roots of spinal nerves, 744
of teeth, 841
of zygomatic process, 171
Rosenmüller, organ of, 135
accessory gland of, 822
Rostrum of sphenoid bone, 178
of corpus callosum, 692
Rotation, 300
Rotatores spinæ muscles, 409
Round ligaments of uterus, 988
relations of, to femoral ring, 1007
of liver, 891
Rugæ of stomach, 872
of vagina, 980
Rupture of urethra, course taken by urine in, 1013

S.

Sac, lachrymal, 822
landmarks of, 1029
of omentum, 863
Saccular secretory glands, 97
Saccule of vestibule, 837
Sacculus laryngis, 924
Sacra-media artery, 582
Sacral arteries, lateral, 591
canal, 155
cornua, 154
foramina, 153
ganglia, 792
groove, 154
lymphatic glands, 646
nerves, 777
plexus, 777
vein, lateral, 632
middle, 632
Sacro-coccygeal ligaments, 320
Sacro-iliac articulation, 319
Sacro-lumbalis muscle, 406
Sacro-sciatic foramen, greater, 263, 320
lesser 263, 320
ligaments, 319, 320
notch, greater, 263
lesser, 263
Sacro-vertebral angle, 153
ligament, 318
Sacrum, 152
ala of, 155
articulations of, 157
attachment of muscles to, 157
development of, 156
peculiarities of, 156
structure of, 155
Sacs, dental, 847
Sagittal suture, 203
Salivary glands, 852
structure of, 854
Salpingo-pharyngeus, 396
Santorini, cartilages of, 921
Saphenous nerve, long or internal, 774
short, 781
opening, 466, 1003
vein, external or short, 631
internal or long, 630, 1000
Sarcolemma, 64
Sarcous elements of muscle, 65
Sartorius muscle, 467
Scala tympani of cochlea, 834
media, 834
vestibuli of cochlea, 834
Scalæ of cochlea, 834
Scalenus anticus, 398
medius, 398
posticus, 398
Scalp, arteries of, 1026
density of, 1026
Scaphoid bone, hand, 250
foot, 289
fossa of sphenoid, 179
Scapula, 233
articulations of, 237
attachment of muscles to, 237
development of, 236
dorsum of, 233
glenoid cavity of, 236
head of, 236
landmarks of, 1040
ligaments of, 326
[mobility of, 329]
muscles of, 433
spine of, 233
venter of, 233
Scapular artery, posterior, 551
region, muscles of, anterior, 433
posterior, 433
veins, 625
Scapulo-clavicular articulation, 324
Scarfskin, 89
Scarpa, foramina of, 190, 208
Scarpa's triangle, 594
Schachowa, spiral tubes of, 947
Schindylesis, 298
Schneiderian membrane, 803
Schultze, cells of, 717, 804
Schwann, white substance of, 70
Sciatic artery, 590
nerve, greater, 780
lesser, 778
veins, 632
Sclerotic, 806
Scrotal hernia, 998
Scrotum, 967
dartos of, 967
development of, 138
lymphatics of, 647
nerves of, 969
septum of, 968
vessels of, 968
Sebaceous glands, 94
Second nerve, 717
Secreting glands, 97
Sella Turcica, 176, 206
Semen, 973
liquor seminis of, 973
seminal granules of, 973
spermatozoa of, 973
Semicircular canals, 832
Semilunar bone, 252
cartilages of knee, 349
fold of Douglas, 418
fascia, 436
Semilunar ganglion of fifth nerve, 720
of abdomen, 793
valves, aortic, 912
pulmonic, 910
Semimembranosus muscle, 458
Seminal granules, 973
cells, 971
tubes, 970
vesicles, 972
Semispinalis muscle, 409
Semitendinosus muscle, 478
Senac, on structure of heart's valves, 910
Senses, organs of the, 798
Septum auricularum, 911
cartilage of, 803
crurale, 1008
lucidum, 697
of medulla oblongata, 668
of nose, 217
pectiniforme, 965
of pons Varolii, 672
scroti, 967
subarachnoid, 653
of tongue, 801
ventriculorum, 914
Septum between bronchi, 928
Serous glands of tongue, 800
Serous membranes, 95
Serratus magnus, 430
posticus, inferior, 404
superior, 404
Serum, 39
Sesamoid bones, 294
cartilages, 803
Seventh nerve, 732
Shaft of a bone, its structure, 141
Sheath of arteries, 80
of muscles, 64
of nerves, 73
of rectus muscle, 417
femoral or crural, 1004
Short bones, 141
Shoulder, muscles of, 429
joint, 326
landmarks of, 1057
vessels and nerves of, 328
Sigmoid artery, 579
cavity, greater and lesser, of ulna, 245
of radius, 249
flexure of colon, 885
mesocolon, 869
notch of lower jaw, 200
Sinus circularis iridis, 811
of jugular vein, 616
of kidney, 946
pocularis, 959
prostaticus, 135, 959
Sinuses, cranial, 167, 612, 619
cavernous, 621
circular, 621
of coronary vein, 637, 908
ethmoidal, 183
frontal, 168
landmarks of, 1026
of heart, of right auricle, 907
of left, 911
landmarks of cerebral, 1027
lateral, 620
longitudinal inferior, 620
superior, 619
of nose, 167
occipital, 621

Sinuses—
  maxillary, 187
  petrosal, inferior, 622
    superior, 622
  pulmonary, 911
  sphenoidal, 177
  straight, 620
  transverse, 622
  of Valsalva, aortic, 912
Sixth nerve, 731
Skeleton, 141
  number of its pieces, 141
Skin, general anatomy of, 89
  appendages of, 92
  areolæ of, 91
  corium of, 90
  cuticle of, 89
  derma, or true skin, 90
  development of, 123
  epidermis of, 89
  furrows of, 91
  hairs, 92
  muscular fibres of, 94
  nails, 92
  nerves of, 92
  papillary layer of, 91
  rete mucosum of, 89
  sebaceous glands of, 94
  sudoriferous or sweat-glands of, 94
  tactile corpuscles of, 75
  vessels of, 91
Skull, 160, 204
  anterior region, 213
  base of, external surface, 208
    internal surface, 205
  fossa of, anterior, 206
    middle, 206
    posterior, 207
  [landmarks on, 684]
  lateral region of, 211
  tables of, 141
  vertex of, 204
  vitreous table of, 142
Skull-cap, thickness of, 1027
Slender lobe of cerebellum, 710
Small intestine, cellular coat of, 877
  mucous coat of, 877
  muscular coat of, 876
  serous coat of, 876
  simple follicles, 879
  valvulæ conniventes, 877
  villi of, 877
Small intestines, 874
  duodenum, 874
  ileum, 876
  jejunum, 876
Socia parotidis, 853
Soft palate, 850
  aponeurosis of, 851
  arches or pillars of, 851
  muscles of, 394
  structure of, 851
Solar plexus, 793
[Sole of foot, imprint of, 294]
    muscles of, first layer, 489
      second layer, 491
      third layer, 492
Soleus muscle, 482
Solitary glands, 880
Somatopleure, 106
Sömmerring, yellow spot of, 813
Space, anterior perforated, 688
  axillary, 553
Space—
  intercostal, 225
  popliteal, 600
  posterior perforated, 689
Spaces of Fontana, 811
Spermatic artery, 581, 968
    veins of, 968
  canal, 996
  cord, 968
    arteries of, 968
    landmarks of, 1044
  course of, 968
  fascia, external, 414, 993
  lymphatics of, 969
  nerves of, 969
  plexus of nerves, 794
    of veins, 633
  relation to femoral ring, 1007
    of, in inguinal canal, 968, 996
  veins, 633, 968
Spermatoblasts, 971
Spermatozoa, 973
Spheno-maxillary fissure, 212
  fossa, 212
Spheno-palatine artery, 525
  foramen, 195
  ganglion, 725
  nerves, 724
  notch, 195
Spheno-parietal suture, 203
Sphenoid bone, 176
  articulations of, 181
  attachment of muscles to, 181
  body of, 176
  development of, 180
  greater wings of, 178
  lesser wings of, 179
  pterygoid processes of, 179
  rostrum of, 178
  spinous processes of, 178
  vaginal processes of, 178
Sphenoidal fissure, 179
  nerves in, 732
  process of palate, 195
  sinuses, 177
  turbinated bones, 180
Sphincter muscle of bladder, 958
  of rectum, external, 1011
    internal, 1011
  of vagina, 1015
Spinal arteries, anterior, 549
      lateral, 547
      median, 549
      posterior, 549
    canal, 160
Spinal cord, 654
    arachnoid of, 653
    arrangement of gray and white matter in, 656
    central canal of, 661
    central ligament of, 654
    columns of, 655
    development of, 113
    dura mater of, 652
    fissures of, 655
    fœtal, peculiarity of, 654
    gray commissure of, 655
    internal structure of, 656
    ligamentum denticulatum of, 654
    membranes of, 652
    neuroglia of, 656
    pia mater of, 654
    sections of, 655
Spinal cord—
    white commissure of, 656
      matter of, 657
Spinal accessory nerve, 741
Spinal nerves, 744
    arrangement into groups, 744
    branches of, anterior, 745
      posterior, 745
    development of, 120
      landmarks of, 1038
    ganglia of, 745
    origin of, in cord, 660
      of roots, anterior, 744
        posterior, 744
Spinal veins, 628
    longitudinal anterior, 629
      posterior, 629
Spinalis colli muscle, 408
  dorsi, 408
Spine, 142
  articulations of, 301
  development of, 113
  general description of, 158
  landmarks of, 1043
  ossification of, 150
Spines of bones, ethmoidal, 176
    of ischium, 263
  nasal, 168
    anterior, 190
    posterior, 193
  pharyngeal, 162
  of pubes, 264
  of scapula, 233
Spinous process of ilium, 261
      landmarks of, 1043, 1049
    of sphenoid, 178
    of tibia, 278
    of vertebræ, 143
      landmarks of, 1038
Spiral canal of cochlea, 833
Splanchnic nerve, greater, 791
    lesser, 791
    smallest or renal, 791
Splanchnopleure, 106
Spleen, 899
  artery of, 901
  capillaries of, 902
  fibro-elastic coat of, 900
  landmarks of, 1045
  lymphatics of, 649, 903
  Malpighian corpuscles of, 902
  nerves of, 903
  proper substance of, 900
  relations of, 899
  serous coat of, 900
  size and weight, 899
  structure of, 900
  trabeculæ of, 900
  veins of, 903
Splenic artery, 576
    distribution of, 902
  corpuscles, 902
  plexus, 793
  vein, 635
Splenium of corpus callosum, 692
Splenius muscle, 405
Spongy portion of urethra [illegible]
  tissue of bone, 141
Squamo-parietal suture, 20
Squamo-sphenoidal suture, 203
Squamous portion of temporal bone, 170
Stapedius muscle, 831

Stapes, 830
  annular ligament of, 830
  development of, 123
Stellate ligament, 313
  plexus of kidney, 951
Stenson, foramina of, 190, 208
Stenson's duct, 853
[Stephanion, 684]
Sternal end of clavicle, fracture of, 457
  foramen, 224
  ligaments, 317
  nerves, 751
Sterno-clavicular articulation, 322
Sterno-hyoid muscle, 386
Sterno-mastoid muscle, 385
  artery, 519
Sterno-thyroid muscle, 386
Sternum, 220
  articulations of, 224
  attachment of muscles to, 224
  development of, 223
  landmarks of, 1031
  ligaments of, 317
Stomach, 869
  alteration in position of, 870
  alveoli of, 872
  areolar coat of, 872
  cardia of, 869
  curvatures of, 869, 870
  development of, 130
  fundus of, 869
  gastric follicles of, 872
  landmarks of, 1045
  lenticular glands of, 873
  ligaments of, 870
  lymphatics of, 794
  mucous membrane of, 872
  muscular coat of, 869
  orifices of, 869
  peptic glands of, 872
  pyloric glands of, 872
    end of, 869
  pylorus, 871
  serous coat of, 871
  splenic end of, 869
  structure of, 871
  surfaces of, 870
  vessels and nerves of, 874
Straight sinus, 620
  tubes of kidney, 948
Stratiform fibro-cartilage, 53
Stratum cinereum, 705
  corneum, 89
  lucidum, 90
  opticum, 706
Striæ longitudinales, 692
  laterales, 692
  of muscle, 66
Striped muscle, 64
Stroma of ovary, 985
Stylo-glossus muscle, 392
Stylo-hyoid ligament, 311
  muscle, 388
  nerve from facial, 735
Stylo-mastoid artery, 520
  foramen, 174
  vein, 615
Stylo-maxillary ligament, 311, 384
Stylo-pharyngeus muscle, 394
Styloid process of temporal bone, 174
    of radius, 249
Styloid process of ulna, 247
Subanconeus muscle, 438
Subarachnoid space of brain, 663
    of cord, 653
  fluid, 663
  septum, 653
Subclavian arteries, 542
    branches of, 546
    first part of, left, 543
      right, 542
    peculiarities of, 544
    second portion of, 543
    surgical anatomy of, 544
    third, 544
  groove, 226
  nerve, 754
  triangle, 527
  vein, 625
Subclavius muscle, 429
Subcrureus muscle, 469
Subdural space, 663
Sublingual artery, 515
  fossa, 199
  gland, 854
    vessels and nerves of, 854
Sublobular veins, 893
Submaxillary artery, 518
  fossa, 199
  ganglion, 730
  gland, 853
    nerves of, 854
    vessels of, 854
  lymphatic gland, 640
  triangle, 526
Submental artery, 518
  vein, 614
Suboccipital nerve, 747
  posterior branch of, 747
  triangle, 547
Subpeduncular lobe of cerebellum, 710
Subpubic ligament, 321
Subscapular aponeurosis, 433
  artery, 556
  fossa, 233
  nerves, 755
Subscapularis muscle, 433
Substantia cinerea gelatinosa, 659
  perforata, 688
Sudoriferous glands, 94
Sulci of cerebrum, 673
[Sulcus, inferior frontal, 676, 686]
  [intraparietal, 676, 686]
  [precentral, 676, 686]
  spiralis, 835
  [superior frontal, 676, 686]
  [vertical, 676, 686]
Supercilia, 819
Superciliary ridge, 169
Superficial palmar arch, 566
  cervical artery, 551
  circumflex iliac artery, 597
  perineal artery, 589
Superficialis colli nerve, 750
  volæ artery, 564
[Superior frontal sulcus, 676, 686]
  maxillary bone, 186
    articulations of, 191
    attachment of muscles to, 191
    development of, 190
Superior maxillary nerve, 723
  meatus, 217, 804
  mediastinum, 934
  profunda artery, 561
  thyroid artery, 514
  turbinated crest, 189
    of palate, 194
  vena cava, 627
Supinator brevis muscle, 447
  longus, 444
Supraclavicular nerves, 751
Suprahyoid aponeurosis, 388
Supramarginal convolution, 676
Supramaxillary nerves from facial, 736
Supraorbital arch, 167
  artery, 531
  foramen, 167, 213
  nerve, 721
  notch, 167
Suprarenal arteries, 580
  capsules, 953
    development of, 134
    nerves of, 955
    vessels of, 954
  plexus, 794
  veins, 634
Suprascapular artery, 550
  nerve, 755
  notch, 235
Supraspinales muscles, 410
Supraspinatus muscle, 433
Supraspinous ligaments, 304
  aponeurosis, 433
Supratrochlear foramen, 241
  nerve, 721
Sural arteries, 602
  veins, 631
[Surcingle, 693]
Surgical anatomy, of abdominal aorta, 573
    of anterior tibial, 603
    of arch of aorta, 506
    of axilla, 553
    of axillary artery, 555
    of base of bladder, 1020
    of bend of elbow, 559
    of brachial artery, 560
    [of cæcum and appendix, 882]
    of common carotid artery, 511
      iliac artery, 583
    of dorsalis pedis, 606
    of external carotid, 515
      iliac, 592
    of facial artery, 516
    of femoral artery, 596
    of femoral hernia, 1001
    of hamstring tendons, 479
    of iliac arteries, 530
    of inguinal hernia, 991
    of innominate artery, 509
    of internal carotid, 530
    of ischio-rectal region, 1010
    of laryngo-tracheal region, 930
    of lingual artery, 516
    of muscles of eye, 373
      of lower extremity, 494
    of soft palate, 396
    of muscles of upper extremity, 457
    of œsophagus, 857
    of perineum, 1012

Surgical anatomy—
  of popliteal artery, 601
  of posterior tibial, 607
  of prostate gland, 1019
  of radial artery, 563
  of Scarpa's triangle, 594
  of sterno-mastoid muscle, 386
  of subclavian artery, 544
  of superior thyroid, 515
  of talipes, 487
  of temporal artery, 521
  of thoracic aorta, 570
  of triangles of neck, 525
  of ulnar artery, 567
Suspensory ligament of incus, 830
  of lens, 818
  of liver, 889
  of malleus, 830
  of penis, 964
Sustentacular cells of spleen, 901
Sustentaculum tali, 284
Sutura, 298
  dentata, 298
  harmonia, 298
  limbosa, 298
  notha, 298
  serrata, 298
  squamosa, 298
  vera, 298
Sutural ligament, 296
Suture, basilar, 203
  coronal, 203
  cranial, 203
  ethmo-sphenoidal, 203
  ethmoido-frontal, 203
  frontal, 167, 170, 203
  fronto-parietal, 203
  fronto-sphenoidal, 203
  intermaxillary, 213
  internasal, 213
  interparietal, 203
  lambdoid, 203
  masto-occipital, 203
  masto-parietal, 203
  occipito-parietal, 203
  petro-occipital, 203
  petro-sphenoidal, 203
  sagittal, 203
  spheno-parietal, 203
  squamo-parietal, 203
  squamo-sphenoidal, 204
  temporal, 173
  transverse, 203
Swallow's nest of cerebellum, 710
Sweat-glands, 94
[Sylvian artery, 534, 537]
[Sylvius, fissure of, 675, 686]
  aqueduct of, 701
Sympathetic nerve, 74, 784
  cervical portion, 786
  cranial portion, 785
  lumbar portion, 792
  pelvic portion, 792
  thoracic portion, 791
  plexuses, 792
    cardiac, 792
    epigastric, 793
    hypogastric, 796
    pelvic, 796
    solar, 793
Symphysis of jaw, 197
Symphysis pubis, 265, 321
Synarthrosis, 297
Synovia, 297
Synovial membrane, 96, 296
  articular, 297
  bursal, 297
  vaginal, 297. See also *Individual Joints.*
System, Haversian, 56
Systemic arteries, 501
  veins, 611

T.

Tabatière anatomique, 1060
Tables of the skull, 141
Tactile corpuscles, 75
Tænia hippocampi, 695
  semicircularis, 694
  violacea, 713
Tapetum lucidum, 815
  nigrum, 815
Tarinus, horny band of, 694
Tarsal artery, 606
  bones, 284
  cartilages of eyelid, 820
  ligament of eyelid, 820
  ligaments, 358
Tarso-metatarsal articulations, 360
Tarsus, 284
  articulations of, 357
  synovial membranes of, 360
    development of, 294
Taste-goblets, 800
Teeth, 840
  [apposition of, 843]
  bicuspid, 841
  body of, 841
  canine, 841
  cement of, 845
  crown of, 841
  crusta petrosa of, 845
  cortical substance of, 845
  cuspidate, 841
  deciduous, 843
  dental tubuli of, 844
  dentine of, 844
  development of, 846
  enamel of, 845
  eruption of, 849
  eye-, 841
  false molars, 841
  fang of, 841
  general characters of, 840
  growth of, 848
  incisors, 841
  intertubular substance of, 845
  ivory of, 844
  milk, 840, 843
  molar, 841
  multicuspidate, 841
  [occlusion of, 843]
  permanent, 841
  pulp-cavity of, 843
  root of, 841
  [sixth-year molars, 850]
  structure of, 843
  temporary, 840, 843
  true or large molars, 841
  wisdom, 843
Tegmentum of crus cerebri, 690, 707
Temporal artery, 521
    anterior, 521
Temporal artery—
    deep, 524
    middle, 521
    posterior, 521
    surgical anatomy of, 521
Temporal bone, 170
    articulations of, 176
    attachment of muscles to, 176
    development of, 175
    mastoid portion, 171
    petrous portion, 173
    squamous portion, 170
    structure of, 175
Temporal fascia, 379
  fossæ, 211
  ganglion, 790
  muscle, 379
  nerves of auriculo-temporal, 728
    deep, 728
    of facial, 729
  ridge, 168, 170, 211
  suture, 174
  veins, 614
Temporary cartilage, 50
  teeth, 841, 843
Temporo-facial nerve, 735
Temporo-malar, 723
Temporo-maxillary articulation, 310
Temporo-maxillary vein, 614
Temporo-sphenoidal lobe, 677
Tendo Achillis, 483
    landmarks of, 1054
  palpebrarum or oculi, 370
Tendon, central, or cordiform, of diaphragm, 424
  conjoined of internal oblique and transversalis, 414, 994
  hamstring, 477
    landmarks of, 1052
  structure of, 364
  of wrist, 450
Tenon, capsule of, 805
Tensor palati muscle, 394
  tarsi muscle, 371
  tympani muscle, 830
    canal for, 175, 828
  vaginæ femoris muscle, 468
Tenth nerve, 738
Tentorium cerebelli, 663
Teres major muscle, 435
  minor, 434
Testes, 969
  coni vasculosi of, 971
  coverings of, 969
  development of, 135
  gubernaculum testis, 974
  lobules of, 970
  lymphatics of, 648
  mode of descent, 974
  rete testis, 971
  size and weight of, 969
  structure of, 970
  tubuli seminiferi of, 970
  tunica albuginea, 970
    vaginalis, 969
    vasculosa, 970
  vasa efferentia of, 971
  vas aberrans of, 971
  vas deferens of, 972
  vas recta of, 971
Thalamencephalon, 119
Thalami optici, 699

Thebesii venæ, 637
  foramina, 637
Theca vertebralis, 652
Thigh, muscles of back, 477
  deep fascia, fascia lata, 465
  muscles of front of, 465
  superficial fascia, 465, 1000
Third nerve, 718
  ventricle of the brain, 700
[Thirteenth cranial nerve, 735]
Thoracic aorta, 569
    surgical anatomy of, 570
  artery, acromial, 556
    alar, 556
    long, 556
    superior, 556
  duct, 639
  ganglia of sympathetic, 791
  nerves, anterior, 755
    posterior, or long, 754
  region, muscles of anterior, 427
    lateral, 430
Thorax, general description of, 904
  base of, 904
  bones of, 220
  boundaries of, 904
  cutaneous nerves of, anterior, 766
      lateral, 766
  fasciæ of, 419
  lymphatics of, 649
  muscles of, 419
  parts passing through upper opening of, 904
Throat, landmarks of, 1030
Thumb, articulation of, with carpus, 338
  landmarks of, 1061
  muscles of, 452
Thymus gland, 941
    lobes of, 941
    lymphatics of, 651
Thyro-arytenoideus muscle, 925
Thyro-arytenoid ligament, inferior, 924
    superior, 924
Thyro-epiglottic ligament, 922
Thyro-epiglottideus muscle, 926
Thyro-hyoid ligaments, 921
  membrane, 921
  muscle, 387
  nerve, 743
Thyroid artery, inferior, 550
    middle, 507
    superior, 514
    surgical anatomy of, 515
  branches of sympathetic, 790
  cartilage, 919
    landmarks of, 1032
  foramen, 266
  ganglion, 790
  gland, 939
  isthmus of, 940
  lymphatics of, 651
  veins, inferior, 627
    middle, 616
    superior, 616
Tibia, 278
  articulations of, 281
  attachment of muscles to, 281
  crest of, 280
  development of, 281
  fracture of shaft of, 495
  landmarks of, 1051
Tibia—
  nutrient artery of, 609
  spinous process of, 278
  tubercle of, 279
  tuberosities of, 278
Tibial artery, anterior, 603
      branches of, 605
      peculiarities of, 603
      surgical anatomy of, 603
    posterior, 607
      branches of, 608
      peculiarities of, 607
      surgical anatomy of, 607
  lymphatic glands, 644
  nerve, anterior, 782
    posterior, 781
  recurrent artery, 605
  veins, anterior, 631
    posterior, 631
Tibialis anticus muscle, 479
  posticus muscle, 485
Tibio-fibular articulations, 353
  region, anterior, muscles of, 479
    posterior, 481
Tibio-tarsal ligament, 354
Tongue, 798
  arteries of, 801
  fibrous septum of, 801
  frenum of, 799
  mucous glands of, 800
  mucous membrane of, 799
  muscles of, 391
  nerves of, 801
  papillæ of, 799
  serous glands of, 800
Tonsillar nerves, 738
  artery, 518
Tonsils, 851
  of cerebellum, 710
  landmarks of, 1031
  nerves of, 852
  vessels of, 852
Torcular Herophili, 163, 620
Trabeculæ of corpus cavernosum, 965
  of fœtal skull, 116
  of spleen, 900
  of testis, 970
Trachea, 927
  cartilages of, 929
  glands of, 929
  landmarks of, 1032
  relations of, 927
  structure of, 929
  surgical anatomy of, 930
  vessels and nerves of, 930
Trachelo-mastoid muscle, 408
Tracheotomy, 930
Trachoma glands, 821
Tractus intermedio-lateralis, 660
  opticus, 717
Tragicus muscle, 824
Tragus, 823
Transversalis fascia, 996
  muscle, 415
  colli artery, 551
    muscle, 406
Transverse arteries of basilar, 549
  colon, 883
  facial artery, 521
    vein, 614
  fissure of brain, 697
    of liver, 891
Transverse ligament of atlas, 307
    of hip, 341
    of knee, 347
    of scapula, 326
    tibio-fibular, 354
  mesocolon, 869
  process of a vertebra, 143
  sinus, 622
  suture, 204
Transversus auriculæ, 824
  pedis, 492
  perinæi, 1014
    (in female), 1015
Trapezium bone, 252
  of pons, 672
Trapezius muscle, 400
Trapezoid bone, 254
  ligament, 524
Triangle, inferior carotid, 525
  of elbow, 559
  [of election, 526]
  of Hesselbach, 999
  [of necessity, 525]
  of neck, anterior, 525
    posterior, 527
  occipital, 527
  Scarpa's, 594
  subclavian, 527
  submaxillary, 526
  suboccipital, 547
  superior carotid, 526
Triangular ligament of abdomen, 413, 994
    of urethra, 1015
  interarticular fibro-cartilage, 334
Triangularis sterni muscle, 420
Triceps extensor cruris, 468
  extensor cubiti, 438
Tricuspid valves, 909
Trifacial or trigeminus nerves, 719
Trigone of bladder, 958
    landmarks of, 1046
Trochanter, greater, 271
  lesser, 272
  landmarks of, 1049
Trochanteric fossa, 271
Trochlea of humerus, 241
Trochlear nerve, 719
True pelvis, 268
  corpus luteum, 987
  ligaments of bladder, 957
  ribs, 224
Trunk, articulations of, 301
  muscles of, 399
Tube, Eustachian, 828
  Fallopian, 984
Tuber cinereum, 689
  ischii, 264
Tubercle of the clavicle, 230
  of the femur, 272
  genital, 138
  lachrymal, 189
  laminated, of cerebellum, 710
  of Lower, 908
  for odontoid ligaments, 161
  of Rolando, 669
  of scaphoid of carpus, 250
  of tarsus, 289
  of the tibia, 279
  of ulna, 243
  of zygoma, 171
Tubercles, genial, 199

Tubercles—
  of ribs, 225
Tubercula quadrigemina, 702
Tuberosities of humerus, greater and lesser, 238
  of tibia, 278
Tuberosity of ischium, 264
  maxillary, 187
  of palate bone, 195
  of radius, 248
Tubes, bronchial, 927
  structure of, in lung, 937
Tubular secreting glands, 97
Tubular substance of kidney, 946
Tubuli, dental, 844
  of Ferrein, 948
  lactiferi, 989
  seminiferi, 970
  uriniferi, 946
Tuft, vascular, in Malpighian bodies of kidney, 946
Tunica albuginea, 970
  of eye, 372
  of ovary, 986
  reflexa, 970
  Ruyschiana, 810
  vaginalis, 969
    propria, 970
    oculi, 805
  vasculosa testis, 970
Turbinated bone, superior, 183
    inferior, 196
    middle, 182
Tutamina oculi, 819
Twelfth nerve, 742
Tympanic artery, from internal carotid, 530
    from internal maxillary, 523
  bone, 175
  nerve, 738, 831
    of facial, 734
  plate, 171
  ring, 175
Tympanum, 826
  arteries of, 831
  cavity of, 826
  membrane of, 829
  mucous membrane of, 831
  muscles of, 830
  nerves of, 831
  ossicula of, 830
  veins of, 831
Tyson's glands, 964

U.

Ulna, 243
  articulations of, 247
  coronoid process of, 243
  development of, 247
  fracture of coronoid process of, 459
    of olecranon, 459
    of shaft, 460
  landmarks of, 1059
  muscles attached to, 247
  olecranon, process of, 243
  sigmoid cavities of, 245
  styloid process of, 247
  tubercle of, 243
Ulnar artery, 566
    branches of, 567
    peculiarities of, 567
Ulnar artery—
    recurrent, anterior, 567
    surgical anatomy of, 567
  lymphatic glands, 644
  nerve, 561
    posterior, 567
  vein, anterior, 623
    posterior, 623
Umbilical arteries in fœtus, 126, 916
    how obliterated, 918
  cord, 113
  fissure of liver, 891
  region, contents of, 860
  vein, 126
    how obliterated, 916
  vesicle, 107
Umbilicus, 107, 418
  landmarks of, 1041
Unciform bone, 255
  process of ethmoid, 182
Uncinate lobe, 680
Ungual phalanges, 258
Unstriped muscle, 67
Upper extremity, arteries of, 541
    bones of, 229
    fascia of, 425
    ligaments of, 322
    lymphatics of, 643
    muscles of, 425
    nerves of, 755
    surgical anatomy of, 457
    veins of, 623
Urachus, 955
Ureters, 952
  muscles of, 952
  nerves of, 953
  vessels of, 953
Urethra, development of, 138
    in the child, 1048
  bulbous portion of, 960
  caput gallinaginis, 959
  female, 978
  landmarks of, 1047
  male, 959
  membranous portion, 960
  prostatic portion, 959
  rupture of, course taken by urine, 1014
  sinus of, 959
    pocularis of, 959
  spongy portion of, 960
  structure of, 960
  verumontanum, 959
Urinary organs, 944
    development of, 132
Urogenital sinus, 138
Uterine arteries, 586
  plexus, 797
    of veins, 632
Uterus, 980
  appendages of, 984
  arbor vitæ of, 981
  broad ligaments of, 981
  cavity of, 981
  development of, 136
  dimensions, 981
  ganglia of, 797
    nerves of, 797
  in fœtus, 983
  fundus, body, and cervix of, 981
  ligaments of, 981
  lymphatics of, 648
  masculinus, or utriculus hominis, 135, 960
Uterus—
  during menstruation, 983
  nerves of, 983
  in old age, 983
  after parturition, 983
  during pregnancy, 983
  at puberty, 983
  round ligaments of, 988
  shape, position, 980
  structure of, 981
  vessels, 983
Utricle of vestibule, 837
Uvea, 811
Uvula of throat, 851
  of cerebellum, 710
  vesicæ, 959

V.

Vagina, 979
  columns of, 980
  lymphatics of, 648
  orifice of, 977
Vaginal arteries, 586
  plexus of nerves, 797
    of veins, 632
  portal plexus, 894
  process of temporal, 171, 174
  processes of sphenoid, 178
  synovial membranes, 297
Vagus nerve, 738
  ganglion of root of, 739
    of trunk of, 739
Valley of cerebellum, 709
Valsalva, sinuses of, 504, 911, 912
Valve of Bauhin, 882
  coronary, 908
  of cystic duct, 896
  Eustachian, 908
  of gall-bladder, 896
  of Hasner, 822
  ileo-cæcal, 882
  of Kerkring, 877
  mitral, 912
  of Vieussens, 703
Valves in right auricle, 908
  of lymphatics, 85
  pulmonic, 909
  semilunar aortic, 912
  tricuspid, 909
  of veins, 84
Valvulæ conniventes, 877
Vas aberrans, 971
  deferens, 972
    structure of, 972
Vasa aberrantia, from brachial artery, 560
  afferentia of lymphatic glands, 639
  brevia arteries, 577
    veins, 635
  efferentia of testis, 971
    of lymphatic glands, 639
  intestini tenuis arteriæ, 577
    recta, 971
  vasorum of arteries, 80
    of veins, 84
Vascular system, general anatomy of, 78
    changes in, at birth, 918
    peculiarities in the fœtus, 915
Vastus externus muscle, 468
  internus and crureus, 468

Veins, general anatomy of, 83
  anastomoses of, 611
  coats of, 84
  development of, 128
  muscular tissue of, 83
  plexuses of, 611
  size, form, etc., 611
  structure of, 84
  valves of, 84
  vessels and nerves of, 84
Veins or vein, descriptive anatomy of, 612
    of alæ nasi, 614
  angular, 614
  articular of knee, 631
  auditory, 838
  auricular anterior, 614
    posterior, 615
  axillary, 625
  azygos, left lower, 628
    left upper, 628
    right, 627
  basilic, 624
  basi-vertebral, 629
  of bone, 55
  brachial, 625
  brachio-cephalic or innominate, 625
  bronchial, 628
  buccal, 614
  cardiac, 636
    anterior, 636
    great, 636
    posterior, 636
  cardinal, 129
  cava superior, 627
    inferior, 633
  cephalic, 624
  cerebellar, 619
  cerebral, 618
  cervical, ascending, 617
    deep, 617
  choroid of brain, 619
  circumflex, iliac, 631
    superficial, 630
  condyloid posterior, 617, 620
  of corpora cavernosa, 965
  of corpus spongiosum, 632
  of corpus striatum, 618
  cystic, 636
  deep, or venæ comites, 611
  dental inferior, 614
  digital of hand, 624
  of diploë, 617
  dorsalis nasi, 614
    pedis, 631
  dorsi-spinal, 628
    of penis, 632
  epigastric, 631
    superficial, 630
  of eyeball, 819
  facial, 613
  femoral, 631
  frontal, 613
  of Galen, 618
  gastric, 635
  gastro-epiploic, 635
  gluteal, 632
  hemorrhoidal, 632
  of head, 612
  hepatic, 634
  iliac, common, 632
    external, 631
    internal, 631
  ilio-lumbar, 632
Veins or vein—
  inferior cava, 633
  innominate, 625
  intercostal, superior, 625
  interlobular, of kidney, 951
    of liver, 893
  interosseous of forearm, 624
  intralobular of liver, 893
  jugular, anterior, 615
    external, 615
      posterior, 615
    internal, 616
  of kidney, 949
  labial, inferior, 614
    superior, 614
  laryngeal, 627
  lateral sacral, 632
  lingual, 616
  of liver, 894
  longitudinal inferior, 620
  lumbar, 633
    ascending, 633
  mammary internal, 626
  masseteric, 614
  mastoid, 615
  maxillary internal, 614
  median cutaneous, 624
    basilic, 624
    cephalic, 624
  medulli-spinal, 629
  meningeal, 614
  meningo-rachidian, 628
  mesenteric inferior, 634
    superior, 634
  nasal, 614
  oblique, 637
  obturator, 632
  occipital, 615
  œsophageal, 627
  ophthalmic, 621
  ovarian, 634
  palatine, inferior, 614
  palmar, deep, 625
  palpebral, inferior, 614
    superior, 614
  pancreatic, 635
  pancreatico-duodenal, 635
  parotid, 614
  peroneal, 631
  pharyngeal, 616
  phrenic, 634
  plantar, external, 631
    internal, 631
  popliteal, 631
  portal, 611, 636, 894
  profunda femoris, 631
  pterygoid plexus, 614
  pudic, external, 630
    internal, 632
  pulmonary, 612
  radial, 623
  ranine, 614, 616
  renal, 634, 949
  sacral, middle, 632
    lateral, 632
  Salvatella, 623
  saphenous, external, or short, 631
    internal, or long, 630, 1000
    landmarks of, 1057
  sciatic, 632
  spermatic, 633
  spheno-palatine, 616
  spinal, 628
  splenic, 635
Veins or vein—
  stylo-mastoid, 615
  subclavian, 625
  sublobular, 893, 894
  submaxillary, 614
  submental, 614
  superficial, 611
  supraorbital, 614
  suprarenal, 634
  suprascapular, 615
  sural, 631
  systemic, 611
  temporal, 614
    middle, 614
  temporo-maxillary, 614
  thyroid inferior, 626
    middle, 616
    superior, 616
  tibial anterior, 631
    posterior, 631
  transverse cervical, 615
    facial, 613
  ulnar anterior, 623
    deep, 624
    posterior, 623
  umbilical, 916
  vaginal of liver, 894
  vasa brevia, 635
  vertebral, 616
  Vidian, 616
Veins, plexuses of, ovarian, 634, 988
  pampiniform, 633, 968, 988
  pharyngeal, 616
  pterygoid, 614
  spermatic, 633, 968
  uterine, 632
  vaginal, 632
  vesico-prostatic, 632
Velum pendulum palati, 850
  interpositum, 699
Vena cava, superior, 627
      fœtal, 129
      inferior, 633
Venæ comites, 611
  hepaticæ revehentes, 128
    advehentes, 128
  interlobulares of kidney, 950
  rectæ of kidney, 951
  Thebesii, or minimæ cordis, 637, 915
  vorticosæ, 809
Venter of ilium, 261
  of scapula, 233
Ventricle of Arantius, 667
  [of the cord, 656, 661, 667]
Ventricles of brain, third, 700
    fourth, 712
    fifth, 697
    [sixth, 656, 661, 667]
  lateral, 692
  lining membrane of, 714
  of corpus callosum, 691
  of heart, left, 912
    right, 909
  of larynx, 924
Vermiform process of cerebellum,
      inferior, 710
      superior, 708
Vernix caseosa, 123
Vertebra prominens, 147
  development of, 152
Vertebræ, 142
  cervical, 143
  development of, 150

- Vertebræ—
  - dorsal, 147
  - general characters, 143
  - ligaments of, 301
  - lumbar, 149
  - movements of, 1039
  - sacral, 152
  - spines of, 1037
    - landmarks of, 1037
  - structure of, 150
- Vertebral aponeurosis, 405
  - artery, 546
  - column, 158
    - articulation of, 301
    - ossification of, 150
  - foramen, 144
  - ligaments, 302
  - region, muscles of, anterior, 397
    - lateral, 398
  - ribs, 225
  - vein, 616
- Vertebro-chondral ribs, 225
- Vertebro-sternal ribs, 224
- Vertex of skull, 204
- Vertical plate of palate bone, 194
  - [sulcus, 676, 686]
- Verumontanum, 959
- Vesical artery, inferior, 586
  - middle, 586
  - superior, 586
  - plexus of nerves, 796
- Vesicle, auditory, 122
  - cerebral, 118
  - germinal, 100
  - ocular, 121
  - of Purkinje, 99
  - umbilical, 107
- Vesicles, Graafian, 986
- Vesico-prostatic plexus of veins, 632
- Vesico-uterine ligaments, 981
- Vesicula prostatica, 959
- Vesiculæ seminales, 972
  - vessels and nerves of, 973
- Vesicular nervous matter, 68
- Vestibular artery, 838
  - nerve, 838
- Vestibule of ear, 832
- Vestibule of ear—
  - aqueduct of, 174, 832
  - of vulva, 977
- Vestigial fold of pericardium, 626
- Vibrissæ, 802
- Vidian artery, 524
  - canal, 180
  - nerve, 727
- Vieussens, valve of, 703
- Villi, 877
- Viscera, position of, in abdominal regions, 860
  - landmarks of, 1044
  - pelvic, position of, at outlet of pelvis, 1017
- Visceral arches (fœtal), 117
- Vitelline membrane, 99
  - circulation, 124
  - spheres, 101
- Vitellus, 99
- Vitreous humor of the eye, 817
  - table of the skull, 142
- Vocal chords, inferior or true, 924
  - superior or false, 923
- Voice, organs of, 919
- Voluntary muscles, 64
- Vomer, 197
  - alæ of, 197
  - articulations of, 197
  - development of, 197
- Vortex of heart, 914
- Vulva, 976
  - development of, 138

W.

- Wagner, tactile corpuscles of, 75
- Waters, Dr., researches on the lung, 937
- Watney on the structure of villi, 877
  - of thymus, 942
- Weight of organs. See *Individual Organs.*
- Wharton's duct, 854
- White substance of cord, 657
  - of Schwann, 70
  - nerve-substance, 69
- White fibrous tissue, 45
- Willis, circle of, 550
- Winslow, foramen of, 861
  - ligament of, 347
- Wisdom tooth, 843
- Wolffian body, 133
- Womb. See *Uterus.*
- Wormian bones, 184
- [Wrinkles of forehead, 368, 371]
- Wrisberg, cartilages of, 921
  - ganglion of, 793
  - nerve of, 757
- Wrist-joint, 335
  - landmarks of, 1060
- Wry-neck, 386

X.

- Xiphoid appendix, 222

Y.

- Y-ligament, 344
- Y-shaped centre of acetabulum, 266
- Yellow elastic fibrous tissue, 46
  - cartilage, 53
  - spot of retina, 813
- Yolk, 100
  - cleavage of, 101

Z.

- Zinn, ligament of, 372
- Zona fasciculata, 953
  - glomerulosa, 953
  - pellucida, 99
  - reticularis, 953
  - vasculosa, 986
- Zygoma, 170
  - roots of, 171
  - tubercle of, 171
- Zygomatic arch, 212
  - fossæ, 212
  - lymphatic glands, 640
  - process, 193
- Zygomaticus major muscle, 375
  - minor, 375

THE END.

CLASSIFIED LIST
OF
MEDICAL AND SURGICAL PUBLICATIONS
ISSUED BY
LEA BROTHERS & CO.,
706 & 708 SANSOM STREET, PHILADELPHIA.

ANATOMY.

GRAY'S Anatomy, Descriptive and Surgical. New and revised American from eleventh London edition. To which is added the third edition of HOLDEN'S LANDMARKS, MEDICAL AND SURGICAL. In one imperial octavo volume of 1098 pages, with 685 engravings. Cloth, $6.00; leather, $7.00; half Russia, raised bands, $7.50. With veins, arteries and nerves in colors: Cloth, $7.25; leather, $8.25; half Russia, $8.75.

ALLEN'S System of Human Anatomy, Including its Medical and Surgical Relations. For the use of practitioners and students of medicine. With an introductory section on Histology, by E. O. SHAKESPEARE, M. D. In six sections, containing 813 double-columned quarto pages, with 380 figures on 109 lithographic plates, and 241 woodcuts in the text. Price per section, in handsome portfolio, $3.50. Also bound, in cloth, $23.00; half Russia, raised bands and open back, $25.00.

TREVES' Surgical Applied Anatomy. In one 12mo. volume of 540 pages, with 61 illustrations. Cloth, $2.00. See *Students' Series of Manuals*, page 1.

CLARKE & LOCKWOOD'S Dissectors' Manual. In one 12mo. volume of 396 pages, with 49 illustrations. Cloth, $1.50. See *Students' Series of Manuals*, page 1.

CURNOW'S Medical Applied Anatomy. In one 12mo. volume. (*Preparing.*) See *Students' Series of Manuals*, p. 1.

WILSON'S System of Human Anatomy, General and Special. Edited by W. H. GOBRECHT, M. D. In one large and handsome octavo volume of 616 pages, with 397 illustrations. Cloth, $4.00; leather, $5.00.

ELLIS' Demonstrations in Anatomy; Being a Guide to the Knowledge of the Human Body by Dissection. From the eighth and revised English edition. In one very handsome octavo volume of 716 pages, with 249 illustrations. Cloth, $4.25; leather, $5.25.

ROBERTS' Compend of Anatomy. In one 16mo. volume of 196 pages. Cloth, 75 cents.

CLELAND'S Directory for the Dissection of the Human Body. In one small 12mo. volume of 182 pages. Cloth, $1.25.

HOLDEN'S Landmarks, Medical and Surgical. A new American from the third London edition, with additions by W. W. KEEN, M. D. In one handsome royal 12mo. volume of 148 pages. Cloth, $1.00.

HORNER'S Special Anatomy and Histology. Cloth, $6.00.

HARTSHORNE'S Handbook of Anatomy and Physiology. Second edition, revised. In one royal 12mo. volume of 310 pages, with 220 woodcuts. Cloth, $1.75.

BELLAMY'S Student's Guide to Surgical Anatomy. In one royal 12mo. vol. of 300 pages, with 50 cuts. Cloth, $2.25.

PHYSIOLOGY.

CHAPMAN'S Text-book of Human Physiology. Very handsome octavo volume of 925 pages, with 605 engravings. Cloth, $5.50; leather, $6.50.

DALTON'S Treatise on Human Physiology. Designed for the use of students and practitioners of medicine. Seventh edition, thoroughly revised. In one beautiful octavo volume of 722 pages, with 252 illustrations on wood. Cloth, $5.00; leather, $6.00; half Russia, $6.50.

FOSTER'S Text-book of Physiology. New (fourth) American edition. In one 12mo. volume of about 1000 pages, with about 300 illustrations. (*Preparing.*)

POWER'S Human Physiology. In one 12mo. volume of 396 pages, with 47 illustrations. Cloth, $1.50. See *Students' Series of Manuals*, page 1.

BELL'S Comparative Physiology and Anatomy. In one 12mo. volume of 561 pages, with 229 illustrations. Cloth, $2.00. See *Students' Series of Manuals*, page 1.

ROBERTSON'S Physiological Physics. In one 12mo. volume of 537 pages, with 219 illustrations. Cloth, $2.00. See *Students' Series of Manuals*, page 1.

DRAPER'S Medical Physics. In one octavo volume of 734 pages, with 376 illustrations. Cloth, $4.00.

CARPENTER'S Principles of Human Physiology. Eighth edition. Octavo.

DALTON'S Circulation of the Blood. In one 12mo. volume of 293 pages. Cloth, $2.00.

LEHMANN'S Manual of Chemical Physiology. Cloth, $2.25.

CHEMISTRY.

BLOXAM'S Chemistry, Inorganic and Organic. New American from the fifth London edition. In one very handsome octavo volume of 727 pages, with 292 illustrations. Cloth, $2.00; leather, $3.00.

FOWNES' Manual of Chemistry; Theoretical and Practical. Embodying Watts' Inorganic Chemistry. A new American edition. In one large royal 12mo. volume of 1061 pages, with a colored plate, and 168 illustrations on wood. Cloth, $2.75; leather, $3.25.

CHEMISTRY—continued.

ATTFIELD'S Chemistry, General, Medical and Pharmaceutical; including the Chemistry of the U. S. Pharmacopœia. A Manual of the General Principles of the Science, and their Application to Medicine and Pharmacy. Tenth edition, specially revised by the Author for America. In one very handsome 12mo. volume of 728 pages, with 87 illustrations. Cloth, $2.50; leather, $3.00.

HOFFMANN & POWER'S Chemical Analysis, as Applied to the Examination of Medicinal Chemicals and their Preparations. Third edition, thoroughly rewritten. In one octavo volume of 621 pages, with 179 illustrations. Cloth, $4.25.

REMSEN'S Theoretical Chemistry. With special reference to the Constitution of Chemical Compounds. New (3d) edition, thoroughly revised and rewritten. In one 12mo. volume of 316 pages. Cloth, $2.00.

SIMON'S Manual of Chemistry. New (2d) edition. In one 8vo. volume of 478 pages, with 44 engravings and 7 colored plates of deposits. Cloth, $3.50. (*Just ready.*)

CHARLES' Physiological and Pathological Chemistry. In one 8vo. volume of 463 pages, with 38 illustrations and 1 colored plate. Cloth, $3.50.

FRANKLAND & JAPP'S Inorganic Chemistry. In one 8vo. volume of 677 pages, with 51 illustrations and a colored plate. Cloth, $3.75; leather, $4.75.

CLOWES' Elementary Treatise on Practical Chemistry and Qualitative Inorganic Analysis. Specially adapted for Use in the Laboratories of Schools and Colleges and by Beginners. New American from the fourth and revised English edition. In one very handsome royal 12mo. volume of 387 pages, with 55 illust. Cloth, $2.50.

CLASSEN'S Elementary Quantitative Analysis. Translated with Additions, by EDGAR F. SMITH, A. M., Ph. D. In one handsome royal 12mo. volume of 324 pages, with illustrations. Cloth, $2.00.

RALFE'S Clinical Chemistry. In one 12mo. volume of 314 pages, with 16 illustrations. Cloth, $1.50. See *Students' Series of Manuals*, page 1.

GREENE'S Manual of Medical Chemistry. In one 12mo. volume of 310 pages, with 74 illustrations. Cloth, $1.75.

WÖHLER & FITTIG'S Outlines of Organic Chemistry. Translated, with Additions, from the eighth German edition, by IRA REMSEN, M. D., Ph. D. In one handsome royal 12mo. volume of 550 pages. Cloth, $3.00.

DICTIONARIES.

DUNGLISON'S Medical Lexicon; A Dictionary of Medical Science; Containing a Concise Explanation of the various Subjects and Terms of Anatomy, Physiology, Pathology, Hygiene, Therapeutics, Pharmacology, Pharmacy, Surgery, Obstetrics, Medical Jurisprudence, and Dentistry; Notices of Climate and of Mineral Waters; Formulæ for Officinal, Empirical and Dietetic Preparations; with the Accentuation and Etymology of the Terms, and the French and other Synonymes—so as to constitute a French as well as an English Medical Lexicon. By ROBLEY DUNGLISON, M. D. A new edition, thoroughly revised, and very greatly modified and augmented. By RICHARD J. DUNGLISON, M. D. In one very large and handsome royal octavo volume of 1139 pages. Cloth, $6.50; leather, raised bands, $7.50; half Russia, raised bands, $8.00.

HOBLYN'S Dictionary of the Terms used in Medicine and the Collateral Sciences. Revised, with numerous Additions, by ISAAC HAYS, M. D. In one large royal 12mo. volume of 520 double-columned pages. Cloth, $1.50; leather, $2.00.

MANUALS.

STUDENTS' Series of Manuals. A series of manuals by eminent teachers or examiners. Pocket-size octavos of 300-540 pages, richly illustrated. The following may be announced: TREVES' MANUAL OF SURGERY, in three volumes, each, $2; KLEIN'S HISTOLOGY (3d Ed.), $1.50; PEPPER'S SURGICAL PATHOLOGY, $2; TREVES' SURGICAL APPLIED ANATOMY, $2; POWER'S HUMAN PHYSIOLOGY (2d Ed.), $1.50; RALFE'S CLINICAL CHEMISTRY, $1.50; CLARKE & LOCKWOOD'S DISSECTORS' MANUAL, $1.50; BRUCE'S MATERIA MEDICA AND THERAPEUTICS (4th Ed.), $1.50; ROBERTSON'S PHYSIOLOGICAL PHYSICS, $2; GOULD'S SURGICAL DIAGNOSIS, $2; and BELL'S COMPARATIVE PHYSIOLOGY AND ANATOMY, $2 (*now ready*). BELLAMY'S OPERATIVE SURGERY, PEPPER'S FORENSIC MEDICINE, and CURNOW'S MEDICAL APPLIED ANATOMY (*shortly*). For separate notices see various subject-heads.

HARTSHORNE'S Conspectus of the Medical Sciences; containing Handbooks on Anatomy, Physiology, Chemistry, Materia Medica, Practical Medicine, Surgery and Obstetrics. In one large royal 12mo. volume of 1028 closely-printed pages, with 477 illus. Cloth, $4.25; leather, $5.00.

MANUALS—continued.

SERIES of Clinical Manuals. A collection of authoritative monographs in a cheap and portable form. The following volumes are now ready: BALL ON DISEASES OF THE RECTUM AND ANUS, $2.25; CARTER & FROST'S OPHTHALMIC SURGERY, $2.25; HUTCHINSON ON SYPHILIS, $2.25; MARSH ON DISEASES OF THE JOINTS, $2; MORRIS ON SURGICAL DISEASES OF THE KIDNEY, $2.25; OWEN ON SURGICAL DISEASES OF CHILDREN, $2; BUTLIN ON THE TONGUE, $3.50; PICK ON FRACTURES AND DISLOCATIONS, $2; SAVAGE ON INSANITY AND ALLIED NEUROSES, $2; and TREVES ON INTESTINAL OBSTRUCTION, $2. The following are in press: BROADBENT ON THE PULSE, and LUCAS ON DISEASES OF THE URETHRA. For separate notices see various subject-heads.

NEILL & SMITH'S Analytical Compendium of the Various Branches of Medical Science; for the use and examination of students. In one large royal 12mo. volume of 974 pages, with 374 woodcuts. Cloth, $4.00; strongly bound in leather, with raised bands, $4.75.

LUDLOW'S Manual of Examinations upon Anatomy, Physiology, Surgery, Practice of Medicine, Obstetrics, Materia Medica, Chemistry, Pharmacy and Therapeutics. To which is added a Medical Formulary. In one handsome royal 12mo. volume of 816 pages, with 370 illustrations. Cloth, $3.25; leather, $3.75.

MATERIA MEDICA AND THERAPEUTICS.

STILLÉ & MAISCH'S National Dispensatory; containing the Natural History, Chemistry, Pharmacy, Actions and Uses of Medicines, including those recognized in the Pharmacopœias of the United States, Great Britain and Germany, with numerous references to the French Codex. Fourth edition, with appendix. Revised to cover the new British Pharmacopœia. In one magnificent imperial octavo volume of 1794 pages, with 311 accurate illustrations. Cloth, $7.25; leather, $8.00; half Russia, open back, $9.00. Furnished with Patent Ready-Reference Thumb-letter Index for $1.00 in addition to price in any of above styles of binding.

BRUNTON'S Pharmacology, Therapeutics and Materia Medica. New (third) edition, in one handsome octavo volume of 1305 pages, with 230 illustrations. Cloth, $5.50; leather, $6.50. *(Just ready.)*

PARRISH'S Treatise on Pharmacy. Designed as a Textbook for the Student and as a Guide for the Physician and Pharmaceutist. With many Formulæ and Prescriptions. Fifth edition, thoroughly revised, by THOMAS S. WIEGAND, Ph. G. In one handsome octavo volume of 1093 pages, with 256 illustrations. Cloth, $5.00; leather, $6.00.

MAISCH'S Manual of Organic Materia Medica. Being a Guide to Materia Medica of the Vegetable and Animal Kingdoms. For the use of Students, Druggists, Pharmacists and Physicians. New (3d) edition. In one 12mo. volume of 523 pages, with 257 illustrations. Cloth, $3.00.

EDES' Text-book of Therapeutics. and Materia Medica In one octavo volume of 544 pages. Cloth, $3.50; leather, $4.50.

STILLÉ'S Therapeutics and Materia Medica; a Systematic Treatise on the Action and Uses of Medicinal Agents, including their Description and History. Fourth edition, revised and enlarged. In two large and handsome octavo volumes of 1936 pages. Cloth, $10.00; leather, $12.00; very handsome half Russia, raised bands, $13.00.

FARQUHARSON'S Guide to Therapeutics and Materia Medica. Third American edition, specially revised by the Author, and edited, with additions, embracing the U. S. Pharmacopœia. New edition. In one royal 12mo. volume of about 550 pages. *(Preparing.)*

BRUCE'S Materia Medica and Therapeutics. New (fourth) edition. In one 12mo. volume of 591 pages. Cloth, $1.50. See *Students' Series of Manuals*, page 1.

BARTHOLOW'S New Remedies of Indigenous Source. Their Physiological Actions and Therapeutical Uses. Octavo, about 300 pages. *(Preparing.)*

HERMANN'S Experimental Pharmacology. Translated, with additions, by R. MEADE SMITH, M. D. In one 12mo. volume of 199 pages, with 32 illustrations. Cloth, $1.50.

GRIFFITH'S Universal Formulary; containing the Methods of Preparing and Administering Officinal and other Medicines. The whole adapted to physicians and pharmaceutists. Third edition, thoroughly revised, with numerous additions, by JOHN M. MAISCH, Phar. D. In one large octavo volume of 775 pages. Cloth, $4.50; leather, $5.50.

PATHOLOGY.

PAYNE'S General Pathology. Designed as an introduction to the practice of medicine. Very handsome octavo, 524 pages, 153 engravings and 1 colored plate. Cloth, $3.50. *(Just ready.)*

COATS' Pathology. In one handsome octavo volume of 829 pages, with 339 illustrations. Cloth, $5.50; leather, $6.50.

VAUGHAN & NOVY on Ptomaines and Leucomaines, or Physiological and Pathological Alkaloids. In one 12mo. volume of 311 pages. Cloth, $1.75. *(Just ready.)*

GREEN'S Pathology and Morbid Anatomy. New (sixth) American, from the seventh revised and enlarged English edition. In one handsome octavo volume of about 500 pages, with 150 illustrations. *(Preparing.)*

SCHÄFER'S Essentials of Histology, Descriptive and Practical. In one octavo volume of 252 pages, with 281 illustrations. Cloth, $2.25.

CORNIL & RANVIER'S Manual of Pathological Histology. Translated, with Notes and Additions, by E. O. SHAKESPEARE, M.D., and J. HENRY C SIMES, M.D. Octavo.

KLEIN'S Histology. Third edition. In one 12mo. volume of 361 pages, with 181 illustrations. Cloth, $1.50. See *Students' Series of Manuals*, page 1.

WOODHEAD'S Practical Pathology. In one 8vo. vol. of 497 pages, with 136 colored illus. in the text. Cloth, $6.00.

PEPPER'S Surgical Pathology. In one 12mo. volume of 511 pages, with 81 illustrations. Cloth, $2.00. See *Students' Series of Manuals*, page 1.

PRACTICE.

A SYSTEM of Practical Medicine, by American Authors. Edited by WILLIAM PEPPER, M. D., LL. D. Complete work now ready. In five extra-sized octavo volumes, containing 5573 pages, with 198 illustrations. Per volume, cloth, $5.00; leather, $6.00; half Russia, $7.00. *For sale by subscription only.*

FLINT'S Treatise on the Principles and Practice of Medicine; designed for the use of Students and Practitioners of Medicine. New (sixth) edition. Thoroughly revised by the Author, assisted by WILLIAM H. WELCH, M. D., and AUSTIN FLINT, JR., M. D. In one large and closely-printed octavo volume of 1160 pages, with 5 woodcuts. Cloth, $5.00; strongly bound in leather, with raised bands, $6.00; very handsome half Russia, raised bands, $7.00.

REYNOLDS' System of Medicine. Edited by H. HARTSHORNE, M.D. In three large octavo volumes of 3056 closely-printed double-columned pages, with 317 illustrations. Per volume in cloth, $5.00; in leather, $6.00; half Russia, $6.50. Sold only by subscription.

BRISTOWE'S Treatise on the Theory and Practice of Medicine. Second American edition. Edited, with additions, by JAMES H. HUTCHINSON, M. D. In one large and handsome octavo volume of 1085 closely-printed pages. Cloth, $5.00; leather, $6.00; half Russia, $6.50.

HARTSHORNE'S Household Manual of Medicine, Surgery, Nursing and Hygiene. Extra-sized octavo, 956 pages, 283 woodcuts, 8 full-page plates. Cloth, $4; very handsome half Morocco, $5.

HARTSHORNE'S Essentials of the Principles and Practice of Medicine. A Handbook for Students and Practitioners. Fifth edition, revised and improved. In one handsome royal 12mo. volume of 669 pages, with 144 illustrations. Cloth, $2.75; half bound, $3.00.

FOTHERGILL'S Practitioner's Handbook of Treatment; or, The Principles of Therapeutics. Third edition. In one very handsome octavo volume of 661 pages. Cloth, $3.75; leather, $4.75.

THE YEAR-BOOK of Treatment for 1887. A Critical Review for Practitioners of Medicine. A classified summary of medical progress by 23 eminent physicians and surgeons. In one octavo volume of 321 pages. Cloth, $1.25.

THE YEAR-BOOK of Treatment for 1886. Similar to above. 12mo., 320 pages. Cloth, $1.25.

WATSON'S Lectures on the Principles and Practice of Physic. A new American from the fifth revised English edition. Edited, with additions, and several hundred illustrations, by HENRY HARTSHORNE, M. D. In two large octavo volumes of 1840 pages, with 190 woodcuts. Cloth, $9.00; leather, $11.00.

RICHARDSON'S Preventive Medicine. In one handsome octavo volume of 729 pages. Cloth, $4.00; leather, $5.00; half Russia, $5.50.

BARTHOLOW on Electricity as Applied to the Practice of Medicine and Surgery. New (third) edition. In one 8vo. volume of 308 pages, with 110 illustrations. Cloth, $2.50.

BROADBENT on the Pulse. In one 12mo. volume. *(Preparing.)* See *Series of Clinical Manuals*, page 2.

SCHREIBER on Massage. Translated by MENDELSON. In one 8vo. volume of 274 pages, with 117 illustrations. Cloth, $2.75.

FINLAYSON'S Clinical Manual for the Study of Medical Cases. For the use of Students and Practitioners of Medicine. New edition. In one 12mo. volume of 682 pages, with 158 illustrations. Cloth, $2.50.

TANNER'S Manual of Clinical Medicine and Physical Diagnosis. Third American from the second London edition. In one 12mo. volume of 362 pages, Cloth, $1.50.

STURGES' Introduction to Clinical Medicine. In one 12mo. volume of 127 pages. Cloth, $1.25.

FENWICK'S Student's Guide to Medical Diagnosis. From the third revised and enlarged English edition. In one 12mo. volume of 328 pages, with 87 illustrations. Cloth, $2.25.

DAVIS' Clinical Lectures on Various Important Diseases. Second edition. In one 12mo. vol. of 287 pages. Cloth, $1.75.

TODD'S Clinical Lectures on Certain Acute Diseases. In one octavo volume of 320 pages. Cloth, $2.50.

FLINT'S Essays on Conservative Medicine and Kindred Topics. In one 12mo. volume of 210 pages. Cloth, $1.38.

BARLOW'S Manual of the Practice of Medicine. Cloth, $2.50.

LYONS' Treatise on Fever. In one octavo volume of 362 pages. Cloth, $2.25.

HUDSON'S Lectures on the Study of Fever. In one octavo volume of 308 pages. Cloth, $2.50.

LA ROCHE on Yellow Fever, considered in its Historical, Pathological, Etiological and Therapeutical Relations. In two large 8vo. volumes of 1468 pages. Cloth, $7.00.

ORGANS OF RESPIRATION AND CIRCULATION.

BROWNE'S Practical Guide to Diseases of the Throat and Nose, and Associated Affections of the Ear. New (2d) edition. In one 8vo. volume of 628 pages, with 120 illustrations in color and 200 woodcuts, designed and executed by the author. Cloth, $6.50.

COHEN on Throat and Nasal Passages. New edition. In one octavo volume of 750 pages, with 200 illus. *(Preparing.)*

SEILER'S Handbook of Diseases of the Throat, Nose and Naso-Pharynx. New (3d) edition. In one 12mo. volume of about 300 pages, with about 100 illustrations and 2 colored plates. *(In press.)*

FLINT'S Manual of Auscultation and Percussion, of the Physical Diagnosis of Diseases of the Lungs and Heart, and of Thoracic Aneurism. Fourth revised and enlarged edition. In one handsome 12mo. volume of 239 pages, with 14 illustrations. Cloth, $1.75.

FLINT'S Practical Treatise on the Physical Exploration of the Chest and the Diagnosis of Diseases Affecting the Respiratory Organs. Second and revised edition. In one handsome octavo volume of 591 pages. Cloth, $4.50.

ORGANS OF RESPIRATION, etc.—continued.

FLINT on Phthisis; its Morbid Anatomy, Etiology, Symptomatic Events and Complications, Fatality and Prognosis, Treatment and Physical Diagnosis; in a series of Clinical Studies. In one 8vo. volume of 442 pages. Cloth, $3.50.

SMITH on Consumption; its Early and Remediable Stages. In one octavo volume of 253 pages. Cloth, $2.25.

WILLIAMS on Pulmonary Consumption; its Nature, Varieties and Treatment. With an Analysis of One Thousand Cases to Exemplify its Duration. In one octavo volume of 303 pages. Cloth, $2.50.

FULLER on Diseases of the Lungs and Air Passages; their Pathology, Physical Diagnosis, Symptoms and Treatment. Second edition. In one 8vo. vol. of 475 pages. Cloth, $3.50.

LA ROCHE on Pneumonia. In one octavo volume of 490 pages. Cloth, $3.00.

GROSS' Practical Treatise on Foreign Bodies in the Air-Passages. In one octavo volume of 452 pages, with 59 illustrations. Cloth, $2.75.

SLADE on Diphtheria. In one 12mo. volume. Cloth, $1.25.

WALSHE on the Diseases of the Heart and Great Vessels. In one octavo volume of 416 pages. Cloth, $3.00.

FLINT'S Practical Treatise on the Diagnosis, Pathology and Treatment of Diseases of the Heart. Second and revised edition. In one octavo vol. of 550 pages. Cloth, $4.00.

ORGANS OF DIGESTION.

STILLÉ on Cholera. Its Origin, Causation, Symptoms, Prevention and Treatment. In one 12mo. volume of 164 pages, with a chart. Cloth, $1.25.

HABERSHON on Diseases of the Alimentary Canal. Second American from the third and enlarged English edition. In one octavo volume of 554 pages. Cloth, $3.50.

CHAMBERS' Manual of Diet in Health and Disease. In one handsome octavo volume. Cloth, $2.75.

PAVY'S Treatise on the Function of Digestion; its Disorders and their Treatment. From the second London edition. In one handsome volume, small octavo. Cloth, $2.00.

VENEREAL AND SKIN DISEASES.

TAYLOR'S Clinical Atlas of Venereal and Skin Diseases. Including Diagnosis, Prognosis and Treatment. In eight folio parts, measuring 14 x 18 inches and comprising 400 pages of text, with 65 large woodcuts and 192 figures on 58 full-page colored plates. Parts I. and II. *(Just ready.)* Parts III. and IV. *(Shortly.)* Price, per part, $2.50. For sale by subscription only. Specimen of plates, by mail, 10 cents. Address the Publishers.

HYDE on the Skin. New (2d) edition. In one very handsome octavo volume of 676 pages, with 85 illustrations, and two colored plates. Cloth, $4.50; leather, $5.50. *(Just ready.)*

BUMSTEAD & TAYLOR on the Pathology and Treatment of Venereal Diseases, including the results of recent investigations upon the subject. Fifth edition. In one octavo volume of 896 pages, with 139 illustrations and 13 chromo-lithographic figures. Cloth, $4.75; leather, $5.75; half Russia, $6.25.

CORNIL on Syphilis. Translated by J. Henry C. Simes, M. D., and J. William White, M. D. In one very handsome octavo volume of 461 pages, with 84 beautiful illustrations. Cloth, $3.75.

CULLERIER'S Atlas of Venereal Diseases. Translated and edited by Freeman J. Bumstead, M. D., LL. D. In one large imperial 4to. volume of 328 pages, double columns, with 26 plates, containing about 150 figures, beautifully colored, many of them the size of life. Strongly bound in cloth, $17.00.

HUTCHINSON on Syphilis. In one 12mo. volume of 542 pages, with 8 chromo-lithographic plates. Cloth, $2.25. See *Series of Clinical Manuals*, page 2.

LEE'S Lectures on Syphilis, and on Some Forms of Local Disease Affecting Principally the Organs of Generation. In one handsome octavo volume of 246 pages. Cloth, $2.25.

HILL on Syphilis and Local Contagious Disorders. In one handsome 8vo. volume. Cloth, $3.25.

FOX'S Epitome of Skin Diseases, with Formulæ. For Students and Practitioners. Third edition, revised by T. C. Fox, M. R. C. S. In one 12mo. volume of 238 pages. Cloth, $1.25.

WILSON'S Student's Book of Cutaneous Medicine and Diseases of the Skin. In one 12mo. volume of 535 pages. Cloth, $3.50.

HILLIER'S Handbook of Skin Diseases, for Students and Practitioners. Second American edition. In one 12mo. volume of 358 pages, with illustrations. Cloth, $2.25.

DISEASES OF THE URINARY ORGANS.

ROBERTS' Practical Treatise on Urinary and Renal Diseases, including Urinary Deposits. Fourth American from the fourth revised London edition. In one large octavo volume, of 609 pages, with 81 illustrations. Cloth, $3.50.

PURDY on Bright's Disease and Allied Affections of the Kidneys. In one handsome 8vo. volume of 288 pages, with illustrations. Cloth, $2.00.

GROSS' Practical Treatise on the Diseases, Injuries and Malformations of the Urinary Bladder, the Prostate Gland and the Urethra. Third edition, thoroughly revised by Samuel W. Gross, A. M., M. D. In one handsome 8vo. volume of 574 pages, with 170 illustrations. Cloth, $4.50.

THOMPSON'S Lectures on Diseases of the Urinary Organs. Second American edition. In one octavo volume of 203 pages, with 25 woodcuts. Cloth, $2.25.

THOMPSON on the Pathology and Treatment of Stricture of the Urethra and Urinary Fistulæ. From the third English edition. In one octavo volume of 359 pages, with 2 plates and 47 woodcuts. Cloth, $3.50.

LUCAS on Diseases of the Urethra. In one 12mo. volume. *(Preparing.)* See *Series of Clinical Manuals*, page 2.

MORRIS on Surgical Diseases of the Kidney. In one 12mo. volume of 554 pages, with 40 woodcuts and 6 colored plates. Cloth, $2.25. See *Series of Clinical Manuals*, page 2.

BASHAM on Renal Diseases: a Clinical Guide to their Diagnosis and Treatment. In one royal 12mo. volume of 304 pages, with illustrations. Cloth, $2.00.

DISEASES OF THE NERVES AND MIND.

ROSS' Handbook of the Diseases of the Nervous System. In one octavo volume of 726 pages, with 184 illustrations. Cloth, $4.50; leather, $5.50.

MITCHELL'S Lectures on Diseases of the Nervous System, Especially in Women. Second edition. In one handsome 12mo. volume of 284 pages, with 5 lithographic charts. Cloth, $1.75.

HAMILTON on Nervous Diseases: their Description and Treatment. Second edition, thoroughly revised and rewritten. In one handsome octavo volume of 598 pages with 72 illustrations. Cloth, $4.00.

CLOUSTON on Insanity. With U. S. Laws on Custody of Insane, by C. F. Folsom, M. D. In one 8vo. volume of 541 pages, with 8 plates. Cloth, $4.00. Dr. Folsom's Abstract of Laws for sale separately, see below.

SAVAGE on Insanity and Allied Neuroses. In one 12mo. volume of 551 pages, with 18 typical illustrations. Cloth, $2.00. See *Series of Clinical Manuals*, page 2.

TUKE on the Influence of the Mind Over the Body in Health and Disease. Second edition. In one octavo volume of 598 pages, with 72 illustrations. Cloth, $3.00.

GRAY'S Practical Treatise on Diseases of the Nervous System. In one handsome octavo volume of about 600 pages. *(Preparing.)*

PLAYFAIR on Nerve Prostration and Hysteria. In one small octavo volume of 97 pages. Cloth, $1.00.

FOLSOM'S Abstract of Statutes of U. S. on Custody of Insane. In one 8vo. volume of 108 pages. Cloth, $1.50. Also bound with Clouston on *Insanity*, above.

JONES' Clinical Observations on Functional Nervous Disorders. In one 8vo. volume of 340 pages. Cloth, $3.25.

GYNÆCOLOGY.

THE AMERICAN Systems of Gynæcology and Obstetrics. In treatises by various authors. Gynæcology edited by Matthew D. Mann, M. D., and Obstetrics edited by Barton C. Hirst, M. D. In four very handsome super-royal octavo volumes of about 900 pages each. Volumes I. and II. of the Gynæcology are now ready, containing 1961 pages, with 562 engravings and 7 plates. Volume I. of the Obstetrics is now ready, containing 854 pages, with 309 engravings and 1 plate. Volume II. of the Obstetrics is in press. Per volume, cloth, $5.00; leather, $6.00; half Russia, $7.00. *For sale by subscription only.*

THOMAS' Practical Treatise on the Diseases of Women. Fifth edition rewritten and greatly enlarged. In one large and handsome octavo volume of 810 pages, with 266 illustrations. Cloth, $5.00; leather, $6.00; half Russia, raised bands, $6.50.

EMMET'S Principles and Practice of Gynæcology. For Students and Practitioners. New (third) edition, revised and enlarged. In one large octavo volume of 880 pages, with 150 illustrations. Cloth, $5; leather, $6.00; half Russia, raised bands, $6.50.

EDIS on Diseases of Women. A Manual for Students and Practitioners. In one handsome 8vo. volume of 576 pages, with 148 illustrations. Cloth, $3.00; leather, $4.00.

MAY'S Manual of the Diseases of Women. In one 12mo. volume of 342 pages. Cloth, $1.75.

TAIT (Lawson) on Diseases of Women and Abdominal Surgery. In one octavo volume of about 600 pages. *(Preparing.)*

BARNES' Clinical Exposition of the Medical and Surgical Diseases of Women. Third American from the third English edition. In one handsome octavo volume of about 800 pages, with about 250 illustrations. *(Preparing.)*

DUNCAN'S Clinical Lectures on the Diseases of Women. In one octavo volume of 175 pages. Cloth, $1.50.

HODGE on Diseases Peculiar to Women; including Displacements of the Uterus. Second edition, revised and enlarged. In one beautifully-printed octavo volume of 519 pages, with original illustrations. Cloth, $4.50.

ASHWELL'S Practical Treatise on the Diseases Peculiar to Women. One volume, 8vo., 520 pages. Cloth, $3.50.

DISEASES OF CHILDREN.

SMITH'S Treatise on the Diseases of Infancy and Childhood. New (sixth) edition, thoroughly revised and rewritten. In one handsome octavo volume of 887 pages, with 40 illustrations. Cloth, $4.50; leather, $5.50; half Russia, $6.00.

OWEN on Surgical Diseases of Children. In one 12mo. volume of 525 pages, with 85 woodcuts and 4 chromo-lithographic plates. Cloth, $2.00. See *Series of Clinical Manuals*, page 2.

WEST on Some Disorders of the Nervous System in Childhood. In one volume, small 12mo. Cloth, $1.00.

CONDIE'S Practical Treatise on Diseases of Children. Sixth edition. In one octavo volume of 779 pages. Cloth $5.25; leather, $6.25.

OBSTETRICS.

THE AMERICAN System of Obstetrics, see the American Systems of Gynæcology and Obstetrics, above.

PLAYFAIR'S Treatise on the Science and Practice of Midwifery. New (fourth) American from the fourth English edition. Edited, with additions, by Robert P. Harris, M. D. In one 8vo. volume of 653 pages, with 201 illustrations. Cloth, $4.00; leather, $5.00; half Russia, $5.50.

LEISHMAN'S System of Midwifery, including the Diseases of Pregnancy and the Puerperal State. Third American from the third and revised English edition, with additions, by J. S. Parry, M.D. In one large and very handsome 8vo. volume of 740 pages, with 205 illustrations. Cloth, $4.50; leather, $5.50; half Russia, $6.00.

PARVIN'S Treatise on Midwifery. In one very handsome octavo volume of 696 pages, with 214 illustrations. Cloth, $4.25; leather, $5.25.

BARNES' System of Obstetric Medicine and Surgery. In one large octavo volume of 872 pages, with 231 illustrations. Cloth, $5.00; leather, $6.00.

OBSTETRICS—continued.

KING'S Manual of Obstetrics. New (third) edition. In one handsome 12mo. volume of 373 pages, with 102 illustrations. Cloth, $2.25.

LANDIS on the Management of Labor. In one 12mo. volume of 329 pages, with 28 illustrations. Cloth, $1.75.

HODGE'S Principles and Practice of Obstetrics. In one large quarto volume of 542 double-columned pages, illustrated with large lithographic plates containing 159 figures from original photographs, and with numerous woodcuts. Strongly bound in cloth, $14.00.

RAMSBOTHAM'S Principles and Practice of Obstetric Medicine and Surgery, in Reference to the Process of Parturition. In one large imperial 8vo. volume of 640 pages, with 64 beautiful plates, and 43 woodcuts. Leather, $7.00.

BARKER'S Obstetrical and Clinical Essays. In one 12mo. volume of about 300 pages. (*Preparing.*)

TANNER On the Signs and Diseases of Pregnancy. From the second English edition. In one 8vo. volume of 490 pages, with 4 colored plates and 16 woodcuts. Cloth, $4.25.

WINCKEL on the Pathology and Treatment of Childbed. A Treatise for Physicians and Students. From the second German edition by CHADWICK, with additions by the Author. In one octavo volume of 484 pages. Cloth, $4.00.

MEIGS on the Nature, Signs and Treatment of Childbed Fever. In one 8vo. volume of 346 pages. Cloth, $2.00.

CHURCHILL'S Essays on the Puerperal Fever, and other Diseases Peculiar to Women. In one 8vo. volume of 464 pages. Cloth, $2.50.

PARRY on Extra-Uterine Pregnancy; its Clinical History, Diagnosis, Prognosis and Treatment. In one handsome octavo volume of 272 pages. Cloth, $2.50.

OTOLOGY AND OPHTHALMOLOGY.

BURNETT on the Ear; its Anatomy, Physiology and Diseases. A practical Treatise for the use of Medical Students and Practitioners. New (second) edition. In one handsome octavo volume of 580 pages, with 107 illustrations. Cloth, $4.00; leather, $5.00.

POLITZER on the Ear. For Students and Practitioners. In one octavo volume of 800 pages, with 257 original illustrations. Cloth, $5.50.

JULER'S Ophthalmic Science and Practice. In one 8vo. volume of 460 pages, with 125 woodcuts, 25 colored plates, and tests for color-blindness and sharpness of vision. Cloth, $4.50; leather, $5.50.

NETTLESHIP'S Student's Guide to Diseases of the Eye. Third and revised edition. With a chapter on the detection of color-blindness, by WILLIAM THOMSON, M. D. In one 12mo. volume of 479 pages, with 164 illustrations. Cloth, $2.00.

NORRIS & OLIVER'S Text-book of Ophthalmology. In one octavo volume of about 500 pages. (*Preparing.*)

WELLS' Treatise on Diseases of the Eye. New (fifth) American edition, thoroughly revised. In one large and very handsome octavo volume of about 800 pages, with about 275 engravings on wood, 6 colored plates, and selections from the test-types of JAEGER and SNELLEN. (*Preparing.*)

BROWNE'S How to Use the Ophthalmoscope. Being Elementary Instructions in Ophthalmoscopy. In one royal 12mo. volume of 116 pages, with 35 woodcuts. Cloth, $1.00.

LAURENCE & MOON'S Handy-Book of Ophthalmic Surgery. For the use of Practitioners. Second edition, revised and enlarged. In one octavo volume of 227 pages, with 66 illustrations. Cloth, $2.75.

LAWSON on Injuries to the Eye, Orbit and Eyelids: their Immediate and Remote Effects. In one 8vo. volume of 404 pages, with 92 illustrations. Cloth, $3.50.

SURGERY.

GROSS' System of Surgery; Pathological, Diagnostic, Therapeutic and Operative. Sixth edition, thoroughly revised. In two beautifully-printed imperial octavo volumes of 2382 pages, with 1623 engravings. Strongly bound in leather, with raised bands, $15.00; half Russia, raised bands, $16.00.

HOLMES' System of Surgery, Theoretical and Practical. In Treatises by various Authors. First American from second English edition. Thoroughly revised, with numerous additions, by J. H. PACKARD, M. D., assisted by a corps of thirty-three of the most eminent American Surgeons. In three large and very handsome imperial octavo volumes of 3137 pages, with 979 engravings and 13 colored plates. Per volume in cloth, $6.00; leather, $7.00; half Russia, raised bands, $7.50; For sale by subscription only.

ERICHSEN'S Science and Art of Surgery; being a Treatise on Surgical Injuries, Diseases and Operations. New American from the eighth and enlarged English edition. In two large and beautiful octavo volumes, containing 2316 pages, with 984 engravings on wood. Cloth, $9.00; leather, $11.00; half Russia, $12.00.

ASHHURST'S Principles and Practice of Surgery. New (fourth) and revised ed. In one large 8vo. vol. of 1114 pp., with 597 illus. Cloth, $6.00; leather, $7.00; half Russia, $7.50.

BRYANT'S Practice of Surgery. Fourth American from the fourth English edition. In one imperial 8vo. volume of 1040 pages, with 727 engravings. Cloth, $6.50; leather, $7.50; half Russia, $8.00.

DRUITT'S Principles and Practice of Modern Surgery. From the twelfth London edition, thoroughly revised by STANLEY BOYD, F. R. C. S. In one handsome octavo volume of 965 pages, with 373 illustrations. Cloth, $4.00; leather, $5.00.

TREVES' Manual of Surgery. In treatises by various authors. Edited by FREDERICK TREVES, F. R. C. S. Three 12mo. volumes, containing 1866 pages, with 213 illustrations. Per volume, cloth, $2.00. See *Students' Series of Manuals*, page 1.

ROBERTS' Principles and Practice of Surgery. In one handsome octavo volume. (*Preparing.*)

SURGERY—continued.

GROSS' Practical Treatise on Impotence, Sterility and Allied Disorders of the Male Sexual Organs. New (third) edition. In one handsome 8vo. volume of 163 pages, with 16 illustrations. Cloth, $1.50.

COLEMAN'S Dental Surgery and Pathology. Revised by THOMAS C. STELLWAGEN, M. D., D. D. S. In one handsome volume of 412 pages, with 331 illustrations. Cloth, $3.25.

THE AMERICAN SYSTEM OF DENTISTRY. In treatises by various authors. Edited by WILBUR F. LITCH, M. D., D. D. S. The complete work is now ready in three very handsome, extra-sized octavo volumes, containing 3180 pages, with 1873 engravings and 9 full-page plates. Per volume, cloth, $6.00; leather, $7.00; half Morocco, $8.50. *For sale by subscription only.*

HAMILTON'S Practical Treatise on Fractures and Dislocations. Seventh edition, thoroughly revised. In one large and handsome octavo volume of 998 pages, with 379 woodcuts. Cloth, $5.50; leather, $6.50; half Russia, $7.00.

STIMSON'S Practical Treatise on Fractures and Dislocations. In two octavo volumes. Volume I., Fractures, 582 pages, 360 illus. Volume II., Dislocations, 540 pages, 163 illus. Complete work *just ready*. Cloth, $5.50; leather, $7.50. Either volume separately, cloth, $3.00; leather, $4.00.

STIMSON'S Manual of Operative Surgery. New (second) edition. In one 12mo. volume of 503 pages, with 342 illustrations. Cloth, $2.50.

SMITH'S (Stephen) Operative Surgery. New (second) and thoroughly revised edition. In one very handsome octavo volume of 892 pages, with 1005 illustrations. Cloth $4; leather, $5.

GIBNEY'S Orthopædic Surgery. In one 8vo. volume, profusely illustrated. (*Preparing.*)

TREVES on Intestinal Obstruction. In one 12mo. volume of 522 pages, with 60 illustrations. Cloth, $2.00. See *Series of Clinical Manuals*, page 2.

PICK on Fractures and Dislocations. In one 12mo. volume of 530 pages, with 93 illustrations. Cloth, $2.00. See *Series of Clinical Manuals*, page 2.

BALL on Diseases of the Rectum and Anus. In one 12mo. volume of 417 pages, with 54 cuts and 4 colored plates. Cloth, $2.25. See *Series of Clinical Manuals*, p. 2.

MARSH on Diseases of the Joints. In one 12mo. volume of 468 pages, with 64 woodcuts and one colored plate. Cloth, $2.00. See *Series of Clinical Manuals*, page 2.

BUTLIN on the Tongue. In one 12mo. volume of 456 pages, with 8 colored plates and 3 woodcuts. Cloth, $3.50. See *Series of Clinical Manuals*, page 2.

GOULD'S Surgical Diagnosis. In one 12mo. volume of 589 pages. Cloth, $2.00. See *Students' Series of Manuals*, page 1.

BELLAMY'S Operative Surgery. In one 12mo. volume. (*Preparing.*) See *Students' Series of Manuals*, page 1.

SKEY'S Operative Surgery. In one octavo volume of 661 pages, with 81 woodcuts. Cloth, $3.25.

COOPER'S Lectures on the Principles and Practice of Surgery. In one octavo volume of 767 pages. Cloth, $2.00.

PIRRIE'S Principles and Practice of Surgery. In one 8vo. volume of 784 pages, with 316 illustrations. Cloth, $3.75.

MILLER'S Principles of Surgery. In one large octavo volume of 683 pages, with 240 illustrations. Cloth, $3.75.

MILLER'S Practice of Surgery. In one large octavo volume of 682 pages, with 364 illustrations. Cloth, $3.75.

MEDICAL JURISPRUDENCE.

TIDY'S Legal Medicine. Volumes I. and II. Imperial octavos, containing 1193 pages. Price per volume, cloth, $6.00; leather, $7.00.

TAYLOR'S Medical Jurisprudence. Eighth American edition. Edited by JOHN J. REESE, M. D. In one large octavo volume of 937 pages, with 70 illustrations. Cloth, $5.00; leather, $6.00; half Russia, $6.50.

TAYLOR on Poisons in Relation to Medical Jurisprudence and Medicine. Third American from the third revised English edition. In one large octavo volume of 788 pages, with 104 illustrations. Cloth, $5.50; leather, $6.50.

PEPPER'S Forensic Medicine. In one 12mo. volume. (*Preparing.*) See *Students' Series of Manuals*, page 1.

PERIODICALS.

THE AMERICAN JOURNAL of the Medical Sciences. Monthly with 1888. Reduced to $4.00 per annum.

THE MEDICAL NEWS. Every Saturday. Per annum, in advance, $5.00.

The American Journal of the Medical Sciences, ... } Per annum,
The Medical News, ... } in advance, $7.50.

THE MEDICAL NEWS VISITING LIST for 1888. 48 pages of indispensable data and 176 pages of ruled blanks for all records of practice. Wallet form, pocket, pencil, rubber, catheter scale and erasable tablet. Issued in 3 styles: Weekly (for 30 patients), Monthly, and Perpetual. Price, each, $1.25. To *advance*-paying subscribers to above periodicals, 75 cents. Thumb-letter index 25 cents extra. Or, Journal, News, Year-Book of Treatment and one volume of Visiting List, $8.50.

MISCELLANEOUS.

THE MEDICAL NEWS PHYSICIANS' LEDGER. Contains 400 pages "ledger" paper, size 9x14, conveniently ruled. Patent flexible back, half Russia, $5.00. Also same ledger, 300 pages, $4.00.

CARPENTER'S Prize Essay on the Use and Abuse of Alcoholic Liquors in Health and Disease. In one 12mo. volume of 178 pages. Cloth, 60 cents.

HOLLAND'S Medical Notes and Reflections. In one octavo volume of 493 pages. Cloth, $3.50.

LANE MEDICAL LIBRARY
STANFORD UNIVERSITY MEDICAL CENTER
STANFORD, CALIFORNIA 94305

Ignorance of Library's rules does not exempt
violators from penalties.

25M-9-70-28042

G77p
1887
Am. ed.

LANE MEDICAL LIBRARY
STANFORD UNIVERSITY
MEDICAL CENTER
STANFORD, CALIF. 94305

E23 Gray, Henry.
G77p Anatomy, descriptive
1887 and surgical. 13117
Am.ed.

NAME	DATE DUE
Fairclough, K	ret. May 18, 1917.
E. M. [illegible]	ret. May 26, 1917.
[illegible] Styles	1917
	ret. Sept. 25, 1917.
Ely	ret Sept 26
F. L. Wicker	JUL 1 3 1919
Kirk P. Burton	OCT 22 1919